website **www.jaypeebrothers.com,** for detailed information on pediatrics books, visit our website **www.jaypeebrothers.com**

INDIAN ACADEMY OF PEDIATRICS



PEDIATRIC PICTORIAL INTERROGATIVE RECKONER

Editor-in-Chief
Ashok Kapse

Academic Editor
G Sudhakar

Editor
Naveen Thacker

Forewords
Santosh T Soans
A Parthasarathy
Digant D Shastri

JAYPEE

CONTENTS

1. **Acanthosis Nigricans** 1
   Mehul Gosai
2. **Adolescent Gynecomastia** 4
   Mukul Tiwari
3. **Amniotic Band Syndrome** 7
   Narayanappa D, Rashmi Nagaraj
4. **Amniotic Band Syndrome** 11
   Mehul Gosai
5. **Ankyloglossia** 13
   Manish Jain
6. **Anteriorly Displaced Anus** 15
   Chetan Trivedi
7. **Ataxia Telangiectasia** 18
   Narayanappa D, Rajani HS
8. **Bernard-Soulier Syndrome** 26
   Ankit Kumar Parmar
9. **Carotenemia** 29
   Ashok Kapse
10. **Rectal or Colonic Polyp** 32
    Kosha Gajera
11. **Choledochal Cyst** 34
    Alok Gupta, Mohit Vhora
12. **Congenital Adrenocortical Hyperplasia** 36
    Kewal Kishore Arora, Swati Mulye
13. **Congenital Diaphragmatic Hernia** 40
    Siddhartha R Nayak
14. **Congenital Dislocation of Knee** 45
    Chirag Bhalvani
15. **Congenital Duodenal Atresia** 48
    Rakesh Bhargav
16. **Congenital Dyserythropoietic Anemia Type 1** 51
    Pramod Jog
17. **Congenital Esotropia** 54
    Barnali Bhattacharya

18. **Chest X-rays in Congenital Heart Disease** 56
Ritesh Sukharamwala

19. **Congenital Hydrocephalus** 62
Darshan Vinodchandra Chauhan

20. **Congenital Hypothyroidism** 66
Nigam Prakash Narain

21. **Congenital Rubella Syndrome** 68
Darshan Vinodchandra Chauhan

22. **Congenital Varicella Syndrome** 71
Darshan Vinodchandra Chauhan

23. **Dental Caries** 74
Piyali Bhattacharya, Deval Arora

24. **Dermatitis Herpetiformis** 78
Kosha Gajera

25. **Desquamating Rash** 81
M Indra Shekhar Rao

26. **Duchenne Muscular Dystrophy** 85
Piyali Bhattacharya

27. **Ectodermal Dysplasia** 89
Piyali Bhattacharya

28. **Empyema Thoracis** 92
Aroon Narendra Trivedi

29. **Erb's Palsy** 99
Chetan Trivedi

30. **Eruptive Xanthomatosis** 103
Ashok Kapse

31. **Erythema Infectiosum** 105
Atul Kulkarni

32. **Erythema Multiforme** 107
Ashok Kapse

33. **Erythema Nodosum** 110
Bakul Jayant Parekh

34. **Erythema Nodosum 2** 113
Aniruddha Ghosh, Ritabrata Kundu

35. **Fanconi Anemia** 115
Nirav Buch

36. **Foreign Body in Bronchus** 118
Aroon Narendra Trivedi

37. **Febrile Urticaria** 123
Vasant Khalatkar

38. **Forehead Hematoma: Unveiling as "Child Abuse"** 126
Uma Siddhartha Nayak

39. **Gastroesophageal Reflux Disease** 133
Bankim Parekh

40. **Griscelli Syndrome** 136
Ankit Kumar Parmar

41. **Hair on End Appearance** 139
Ashok Kapse

42. **Henoch-Schonlein Purpura** 141
Nigam Prakash Narain

43. **Hepatic Abscess** 143
Dhanya Dharmapalan

44. **Herpes Simplex Infection** 146
Aniruddha Ghosh, Ritabrata Kundu

45. **Herpes Zoster Infection** 151
Aniruddha Ghosh, Ritabrata Kundu

46. **Hereditary Angioedema** 154
Ashok Banga, Usha Banga

47. **Hereditary Methemoglobinemia** 157
Sanjay Bafna

48. **Hand–Foot–Mouth Disease** 160
Ketan Shah

49. **Hunter's Disease** 163
Jagdish Chinnappa

50. **Hydrocele** 165
Amar Shah, Aniruddh Shah

51. **Hypospadias** 168
Amar Shah, Aniruddh Shah

52. **Infantile Hemangioma** 171
Upendra Kinjawadekar, Vipin Goyal

53. **Infective Endocarditis** 174
Ritesh Sukharamwala, Chintan Bhatt

54. **Iron Deficiency Anemia** 178
Nirav Buch

55. **Lamellar Ichthyosis** 182
Vijay Shah, Upendra Chaudhari

56. Lymphangioma **186**
Aniruddh Shah, Amar Shah

57. Microtia **188**
Jagdish Chinnappa

58. Mitral Stenosis **189**
Kewal Kishore Arora, Swati Mulye

59. Molluscum Contagiosum **193**
Vijay Shah, Upendra Chaudhari

60. Moyamoya Disease **195**
Alok Gupta, Mohit Vhora

61. Mucormycosis **197**
Vishal Gajimwar, Vasant Khalatkar

62. Necrotizing Fasciitis **201**
Atul Kulkarni

63. Neonatal Post-pyrexial Hyperpigmentation **204**
M Indra Shekhar Rao

64. Neonatal Purpura Fulminans **206**
Narendra Rathi

65. Nephrotic Syndrome **208**
Fagun Shah

66. Neurocysticercosis **212**
Ritesh Shah

67. Neurofibromatosis **216**
Vijay Shah, Upendra Chaudhari

68. Nutritional Rickets **219**
Meenakshi Girish

69. Phimosis **225**
Aniruddh Shah, Amar Shah

70. Post Kala-Azar Dermal Leishmaniasis **227**
Arun Shah

71. Pulled Elbow **231**
Chetan Trivedi

72. Purpura Fulminans **234**
Mehul Gosai

73. Renal Osteodystrophy **237**
Fagun Shah

74. Renal Tubular Disorders **240**
Fagun Shah

75. Rickettsial Fever 242
Atul Kulkarni

76. Roseola Infantum 248
Bakul Jayant Parekh

77. Spina Bifida 250
Mehul Gosai

78. Sacral Agenesis 253
Pramod Jog

79. Scarlet Fever 256
Aniruddha Ghosh, Ritabrata Kundu

80. Scarlet Fever 259
S Balasubramanian, Sumanth Amparayani

81 Staphylococcal Scalding Skin Syndrome 264
Kewal Kishore Arora, Swati Mulye

82. Sturge–Weber Syndrome 267
Ritesh Shah

83. Systemic Lupus Erythematosus 269
Anoop Verma

84. Tuberculous Lymphadenitis with Sinus 271
Abhay K Shah

85. Torsion Testis 275
Manish Jain

86. Trichobezoar 277
Manish Jain

87. Tuberous Sclerosis 279
Kewal Kishore Arora, Swati Mulye

88. Tuberous Sclerosis Complex 284
Ritesh Shah

89. Hair Tuft at the Lumbosacral Spine 288
Alok Gupta, Mohit Vhora

90. Turbinate Hypertrophy 290
Jagdish Chinnappa

91. Turner Syndrome 291
Alok Gupta, Mohit Vhora

92. Umbilical Hernia 295
Aniruddh Shah, Amar Shah

93. Urticaria Multiforme 297
Ashok Kapse, Himanshu P Tadvi

94. Vesicoureteric Reflux **299**
Fagun Shah

95. Varicella Zoster **305**
Anoop Verma

96. Cardiac Causes of Stridor and Dysphagia **307**
Ritesh Sukharamwala, Chintan Bhatt

97. Waardenburg Syndrome **310**
Narayanappa D, Rashmi Nagaraj

Index *315*

Chapter 2

Adolescent Gynecomastia

Mukul Tiwari

CASE STUDY

Rajesh, a 13-year-old boy, presented in the clinic with bilateral enlargement of breasts which started about a year ago and is now static. He is shy to unbutton his shirt in front of his friends when he goes to picnics and outings. His parents are worried about the adverse psychological effect this is causing to his self-esteem.

There has been no complaint of pain or discharge from the nipples. There was no history of mumps or trauma to the testicles. The father gave a similar history of gynecomastia in his teens which lasted for a year and a half (Fig. 1).

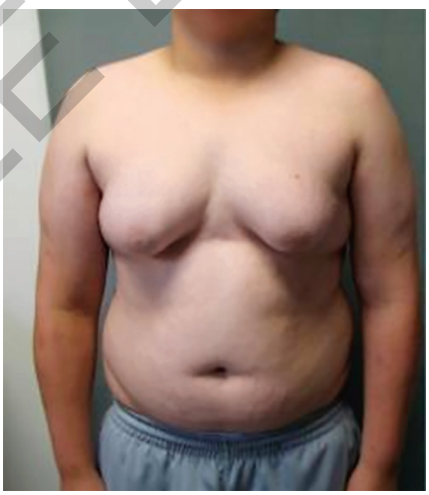

Fig. 1: Case of adolescent gynecomastia.

POSITIVE POINTS IN CLINICAL EXAMINATION

The boy was in Tanner stage 4. He appeared reasonably intelligent. There was no nipple discharge or axillary lymphadenopathy. On breast examination, the boy was found to have true

JAYPEE BROTHERS

gynecomastia which can be differentiated from pseudogynecomastia by having the patient lie on his back with his hands resting behind his head. The examiner places his thumbs on each side of the breast, and attempts to join them. In true gynecomastia, glandular tissue is felt which is symmetrical to the nipple–areolar complex. The boy's testicles were normal in size and consistency. There were no nodules or asymmetry. There were no signs of feminization, including typical body hair distribution and eunuchoid habitus. There were no stigmata of chronic liver disease, thyroid disease or renal disease.

1. **What is adolescent gynecomastia?**
   Physiological adolescent gynecomastia is benign enlargement of the male breast. It results from proliferation of the glandular tissue of the breast. It presents as a rubbery or firm mass behind the nipples. Physiological gynecomastia is usually bilateral but can be unilateral. It results from an altered estrogen–androgen balance, with estrogen predominance. It can occur with normal estrogen levels also, due to increased breast sensitivity to a normal circulating estrogen level. Here the stimulatory effect of estrogen dominates over inhibitory effect of androgen resulting in imbalance. Estrogens have the effect of causing increased vascularity, ductal hyperplasia and proliferation of the periductal fibroblasts. Histologically, the male breast looks similar to female breast tissue. Pseudogynecomastia is deposition of fat behind breast nodule without real growth of glandular tissue.
2. **What is the prevalence rate of adolescent gynecomastia?**
   Prevalence rate of benign pubertal gynecomastia ranges from 4% to 69%. Pubertal gynecomastia usually starts around 10–12 years and generally regresses within 18 months. Persistence beyond 18 years is not common.
3. **What is the main differential diagnosis of gynecomastia?**
   Gynecomastia should be differentiated from pseudogynecomastia (lipomastia), which is characterized by fat deposition without glandular proliferation.
4. **What causes adolescent gynecomastia?**
   Since the gynecomastia was bilateral, the following conditions, which lead to bilateral gynecomastia, are to be considered:
   - Obesity
   - Hypogonadism
   - Cirrhosis
   - Adrenal carcinoma (see Adrenal gland symptoms)
   - Hepatic carcinoma
   - Hypothyroidism
   - Klinefelter's syndrome
   - Pituitary tumor
   - Reifenstein's syndrome
   - Testicular cancer
   - Hemodialysis
   - Testicular irradiation
   - Drugs: ethylstilbestrol, estramustine, chlorotrianisene, Marijuana, heroin phenothiazine
   - Tricyclic antidepressants
5. **What are the necessary investigations?**
   In patients who are clinically diagnosed as having physiologic gynecomastia, no further evaluation is required. Further evaluation is necessary in patients who have breast size

JAYPEE BROTHERS

greater than 5 cm, a lump that is tender, progressive, recent or of unknown duration, if there are signs of malignancy, if the physical examination reveals abnormality of sex organs, thyroid, renal, hepatic disorders. The following investigations are required:

- Liver, kidney and thyroid tests should be performed if the physical examination points towards liver failure, kidney failure or hyperthyroidism.
- If examination of breast tissue suggests malignancy, a biopsy should be performed.
- Mammogram if malignancy is suspected upon clinical examination.
- A fine-needle aspiration or breast biopsy if the case merits.
- Serum testosterone, estradiol, luteinizing hormone (LH) and beta-human chorionic gonadotropin (β-HCG) should be measured. An elevated β-HCG or a markedly elevated serum estradiol suggests neoplasm and a testicular ultrasound should be advised. A low testosterone level, with an elevated LH and normal to high estrogen level indicates primary hypogonadism. Low testosterone, low LH and normal estradiol levels indicate secondary hypogonadism, and hypothalamic or pituitary causes should be looked for. If testosterone, LH and estradiol levels are all elevated, then the diagnosis of androgen resistance should be entertained.
- If the history and physical examinations point towards Klinefelter's syndrome, then a karyotype should be performed.

6. What was the final diagnosis in this case?

The case was clinically diagnosed as having physiological gynecomastia on the basis of the following—age of onset, bilateral, no signs of liver, kidney or thyroid disorder, normal secondary sex characters, etc. Physiological (asymptomatic; pubertal) gynecomastia does not require further tests and should be re-evaluated in 6 months.

JAYPEE BROTHERS

for detailed information on pediatrics books, visit our website **www.jaypeebrothers.com,** for detailed information on pediatric

PEDIATRIC PICTORIAL INTERROGATIVE RECKONER

Salient Features

- Illustrative common to not-so-common clinical cases
- Hundreds of clinically useful pictures
- Easy to comprehend interrogative format
- Highly acclaimed authors
- A handy tool for clinicians to tackle parents' queries.

Ashok Kapse Md (Ped) is consulting Pediatrician practicing in the city of Surat, Gujarat for the last 42 years, besides owning a private pediatric hospital; he is also the Head of the Pediatric Department at prestigious Mahavir Superspecialty Hospital and Senior Professor of Pediatrics for National Board of Examinations. Over the years, he developed intense interest in infectious diseases particularly Dengue Illnesses. He has published many articles in the field of infectious diseases. He was the National Chairperson of Infectious diseases Chapter of Indian Academy of Pediatrics (IAP) for the year 2005–06. During his long and illustrious career, Dr Kapse has won many awards, which include nine prestigious oration awards. Dr Ashok Kapse is a highly sought after speaker, as he has delivered hundreds of lectures on Dengue, Malaria, Typhoid and Antibiotic uses across India. He has addressed 10 international conferences till date. He is an avid clinical photographer, his pictures figure into various books and atlases including Atlas of Tropical Diseases published by American Academy of Pediatrics.

G Sudhakar MD (Ped) DCH is a Consultant Pediatrician at Rainbow Children's Hospital, Kurnool, Andhra Pradesh. He is the retired Professor of Pediatrics from Kurnool Medical College, Kurnool. He is also the National Instructor for PALS, GEM, ATM, NALS/NRP, RAP, EPID, IAP Mission Uday Courses.

Naveen Thacker MD (Ped) FIAP is the Director of Deep Children Hospital and Research Centre at Gandhidham, Gujarat, India and Adjunct Professor of Pediatrics at Pramukhswami Medical College, Karamsad, Anand, Gujarat, India. He has been elected as Executive Director of International Pediatric Association (IPA) for the year 2019–21. He was elected as the President of Asia Pacific Pediatric Association (APPA) for the year 2016–18 and the National President of Indian Academy of Pediatrics in 2007. He served as CSO representative on Gavi Board for 4 years. He was among the top influencer for the fight against Polio released by UNICEF on World Polio Day 2017 and has been blessed with some prestigious awards such as Outstanding Asian Pediatrician Award 2012, Rotary International Regional Award for Polio-free World 2010, Rotary Ratna Award District 3050, 2010, and prestigious FIAP award.

Available at all medical bookstores
or buy online at www.jaypeebrothers.com



JAYPEE BROTHERS
Medical Publishers (P) Ltd.
www.jaypeebrothers.com
Join us on facebook.com/JaypeeMedicalPublishers

Shelving Recommendation
PEDIATRICS

