led information on pediatric books, visit our website **www.jaypeebrothers.com,** for detailed information on pediatric books, visit our website **www.jaypeebrothers.co**







# IAP Textbook of Pediatric & Neonatal Emergencies

*Editor-in-Chief*
**Santosh T Soans**

*Chief Academic Editor*
**Nitin Chawla**



***Get Full Access with added features at***

***emedicine360.com***



# Contents


**1. Pediatric Emergency: An Introduction** **1**
*Nitin Chawla, Bharat Choudhary*

1.1 Medicolegal Aspects in Pediatrics *1*
*Puneet Setia*

1.2 Organization of the Pediatric Emergency Services *5*
*Sakshi Agarwal, Bharat Choudhary*

1.3 Child Abuse *14*
*Nivedita Prabhakar, Bharat Choudhary*

1.4 Communication in Emergency Department *23*
*Nitin Chawla*

1.5 Procedural Sedation and Analgesia in Pediatric Emergencies *26*
*Bharat Paliwal*

**2. Pediatric Resuscitation and Acute Life Support** **36**
*Lokesh Tiwari*

2.1 Cardiopulmonary Resuscitation and Systemic Approach to Manage a Sick Child *36*
*Lokesh Tiwari*

2.2 Airway Management and Positive Pressure Ventilation *47*
*Lokesh Tiwari, Jyoti Chaturvedi, Manish Kumar, Gautam Kumar*

2.3 Oxygen Therapy *61*
*Lokesh Tiwari, Gautam Kumar, Ramanuj Sharma, Chhitiz Anand*

2.4 Respiratory Failure *69*
*Lokesh Tiwari, Chhitiz Anand, Ramanuj Sharma*

2.5 Circulatory Failure: Shock *79*
*Lokesh Tiwari*

2.6 Circulatory Failure: Arrhythmias *95*
*Lokesh Tiwari, Arun Prasad, Pradeep Kumar, Gautam Kumar*

2.7 Cardiac Arrest *104*
*Lokesh Tiwari, Manish Kumar, Amit Shekharay, Gautam Kumar*

2.8 Heart Failure *109*
*Nataraj Palaniappan*

2.9 Neonatal Resuscitation *118*
*Bhabesh Kant, Lokesh Tiwari*

2.10 Anaphylaxis *121*
*Lokesh Tiwari, Ramanuj Sharma*

**3. Cardiorespiratory Emergencies** **128**
*Atul Jindal*

3.1 Upper Airway Emergencies *128*
*Snehamayee Nayak, Atul Jindal*

3.2 Acute Severe Asthma *137*
*Atul Jindal, Jagadish Prasad Goyal*

3.3 Bronchiolitis *144*
*Kavita Tiwari, Atul Jindal*
3.4 Acute Chest Pain *153*
*Rajesh Kumar, Atul Jindal*
3.5 Respiratory Failure in Children *160*
*Dayanand Hota, Atul Jindal*
3.6 Lower Respiratory Tract Infection *169*
*Purnima Margekar, Atul Jindal*
3.7 Foreign Body *177*
*Rolly Agrawal, Atul Jindal*
3.8 Sore Throat *182*
*Shashank Shekhar, Atul Jindal*

**4. Renal Emergencies** **189**
*Sidharth Kumar Sethi*
4.1 Pediatric Acute Kidney Injury *189*
*Sidharth Kumar Sethi*
4.2 Acid-Base Disturbances *194*
*Aditi Sinha*
4.3 Approach to Edema in Children *203*
*Satya Prasad Veeturi, Neelima Kharidehal*
4.4 Approach to Hematuria *207*
*Rajiv Sinha, Rana Saha*
4.5 Hypertensive Urgency in Children *211*
*Rupesh Raina, Meghana Vemuganti*
4.6 Renal Replacement Therapy for Acute Kidney Injury *217*
*Sidharth Kumar Sethi, Rupesh Raina, Aliza Mittal, Mignon McCulloch, Timothy E Bunchman*
4.7 Acute Peritoneal Dialysis in Children with Acute Kidney Injury *221*
*Sidharth Kumar Sethi*
4.8 Drug Dosing in Critically Ill Patients with Acute Kidney Injury *224*
*Aliza Mittal, Lt. Col. Suprita Kalra*

**5. Neurological Emergencies** **241**
*Lokesh Saini*
5.1 Fluid and Electrolytes Disturbances in Acute Neurological Disorders *241*
*Vijai Williams, Jaivinder Yadav*
5.2 Acute Seizure and Status Epilepticus *247*
*Sudhanshu Tiwari, Amit Devgan, Vishal Sondhi*
5.3 Neonatal Seizures in Emergency *259*
*Jyotindra Narayan Goswami, Shivan Kesavan*
5.4 Acute Headache and Status Migrainosus *264*
*Jaya Shankar Kaushik, Harish Bhardwaj, Surbhi Gupta*
5.5 Acute Onset Movement Disorder *273*
*Harsh Patel, Lokesh Saini*
5.6 Status Dystonicus in Childhood *277*
*Anil Vasudev Israni, Lokesh Saini*
5.7 Acute Ataxia *282*
*Rachana Dube, Priyanka Madaan*

5.8 Disorders of Consciousness in Children *285*
*Priyanka Madaan, Lokesh Saini*
5.9 Approach to Acute Vision Loss *290*
*Prabhjot Kaur, Prashant Jauhari*
5.10 Brain Death *295*
*Lokesh Saini, Priyanka Madaan*
5.11 Childhood Stroke *299*
*Renu Suthar, Indar Kumar Sharawat*
5.12 Neurointensive Monitoring in Pediatrics *309*
*Shivlal Soni, Deepak Rajappa, Lokesh Saini*

**6. Gastroenterological Emergencies (Medical) 315**
*Maninder Dhaliwal*
6.1 Acute Abdomen *315*
*Vidyut Bhatia, Shinjini Bhatnagar, Veereshwar Bhatnagar*
6.2 Management of Acute Diarrhea and Dehydration *325*
*Veena Raghunathan, Maninder Dhaliwal*
6.3 Upper Gastrointestinal Bleeding *332*
*Veena Raghunathan, Sakshi Kakra*
6.4 Acute Liver Failure *338*
*Saxena R, Dhaliwal M*

**7. Other Systemic Emergencies 353**
*Nitin Chawla*
7.1 Emergencies in Children with Autoimmune Rheumatic Diseases *353*
*Manjari Agarwal, Sumidha Mittal, Sujata Sawhney*
7.2 Oncologic Emergency *360*
*Chintan Vyas*
7.3 Pediatric Hematologic Emergencies *370*
*Nitin Chawla, Parag Shankarrao Dekate*
7.4 Approach to IEM Emergencies *380*
*Ravi Sharma*
7.5 Tropical Fever: 2018 Update *390*
*Ankit Mehta*
7.6 Diabetic Ketoacidosis and Hyperosmolar Hyperketotic State *394*
*Chetan R Mundada, Sai Praneeth Reddy*
7.7 Adrenal Emergencies in Children *403*
*Kalyan Chakraborty*

**8. Neonatal Emergencies 410**
*Praveen Venkatagiri*
8.1 Neonatal Shock and Hemodynamic Monitoring *410*
*Hemant Parakh, Srimukhi Anumolu*
8.2 Respiratory Failure in Newborn *415*
*Abhishek Somasekhara Aradhya, Praveen Venkatagiri*
8.3 Approach to Neonatal Cardiac Emergencies *424*
*Snehal Desai, Pankaj Mohanty*
8.4 Neonatal Jaundice *433*
*Deepak Sharma, Srinivas Murki, Anil Narang*

8.5 Neonatal Acute Kidney Injury *449*
*Rupesh Raina, Deepak Kumar, Sidharth Kumar Sethi, Meghana Vemuganti*
8.6 Approach to the Neonatal Hyperglycemia *454*
*Pradnya P Wali*
8.7 Neonatal Hypoglycemia *461*
*Samir S Sheikh*
8.8 Bleeding Neonate *468*
*Suja Mariam G*
8.9 Neonatal Transport *473*
*Rahul Kadam*

**9. Surgical Emergencies** **483**
*Leela Kumar Vallamsetty, Anurag Krishna*
9.1 Acute Abdomen in Children *483*
*Anurag Krishna, Leela Kumar Vallamsetty*
9.2 Urological Emergencies *495*
*Anurag Krishna*
9.3 Ocular Emergencies *499*
*Archita Singh, Tarjani Makwana, Noopur Gupta, Radhika Tandon*
9.4 ENT Emergencies in Children *509*
*Rupa Mehta, Nitin M Nagarkar*
9.5 Pediatric Orthopedic Emergencies: Approaches and Recommendations *515*
*Mayank Mahendra*
9.6 Oral Emergencies *525*
*Divesh Sardana, Raj Kumar Verma, Ankita Bhati*

**10. Environmental Emergencies** **529**
*Ankita Roy, Nitin Chawla*
10.1 Electric Burns *529*
*Nidhi Kaeley, Pradeep Yadav KL*
10.2 Drowning and Submersion Injury *533*
*Bhupeshwari Patel, Shikha Malik*
10.3 Pediatric Heat-related Illness: Recommendations for Prevention and Management *542*
*Ankita Roy, Nitin Chawla*

**11 Toxicology** **553**
*Ashwath Ram RN*
11.1 General Approach to Child with Poisoning *553*
*Ashwath Ram RN, Kishore Narhari, Shambhavi Tiwari, Krithi Accamma*
11.2 Analgesics and Anti-inflammatory *559*
*Ashwath Ram RN, Krithi Accamma, Nitin Chawla, Shambhavi Tiwari*
11.3 Common Drugs *577*
*Ashwath Ram RN, Kishore Narhari, Madhavi*
11.4 Household Products and Pesticides *592*
*Ashwath Ram RN, Nitin Chawla, Sumesh Vennara*
11.5 Natural Toxins and Envenomations *600*
*Ananth Pojala, Ashwath Ram RN, Girish Shringi, Priyanka Sake*
11.6 Foods, Dietary and Metals *611*
*Ashwath Ram RN, Priyanka Sake, Robin Thomas, Tushar Agarwal*

CHAPTER

# 3

# Cardiorespiratory Emergencies

*Atul Jindal*

## 3.1 UPPER AIRWAY EMERGENCIES

*Snehamayee Nayak, Atul Jindal*

### CASE SCENARIO

An 1-year-old boy presented to emergency with high-grade fever and difficulty in breathing for 1 day. On examination, he was irritable anxious looking with drooling of saliva from mouth. He had inspiratory stridor with visible chest retractions, respiratory rate 50/min with good air entry on both lung fields. His heart rate was 160/min with warm extremities and normal peripheral perfusion. What do you think the child was suffering from?

- Croup
- Bronchial asthma
- Acute epiglottitis
- Pneumonia.

The child definitely has upper airway obstruction as evidenced by inspiratory stridor, drooling of saliva, and his tachycardia and irritability can be due to hypoxia.

What do you mean by "upper airways" and what is the pathophysiology of upper airway obstruction?

### UPPER AIRWAY

#### Anatomy

Upper airways extend from the nose to the vocal cords including nose, paranasal sinuses, eustachian tube, nasopharynx, oropharynx, tonsils, adenoids, and laryngopharynx. However, due to functional similarities, epiglottis, glottis, subglottis, and extra thoracic trachea have also been considered as upper airways by some authors. These are the conducting part of the airways. Anatomically upper airways are divided into supraglottic, glottic, and subglottic region. Apart from being the conducting pathway of the respiratory system, other functions of upper airways are olfaction, speech, and mucosal defense.

Though upper airway diseases are the most common cause of visit to pediatrician, there are few life-threatening conditions that need urgent care in emergency department. They mostly manifest as upper airway obstruction. Moreover, upper airways of infants and children are more prone for obstruction due to the underlying anatomic peculiarities:

- Large and prominent occiput in infants results in flexion of neck in supine position
- Relatively large tongue may fall back and obstruct airways
- Anterior and cephalad placed glottis
- Subglottis is the narrowest part of the larynx which is nondistensible.

#### What are the Effects of Upper Airway Obstruction?

There are two laws describing pathophysiology of upper airway obstruction.

JAYPEE BROTHERS

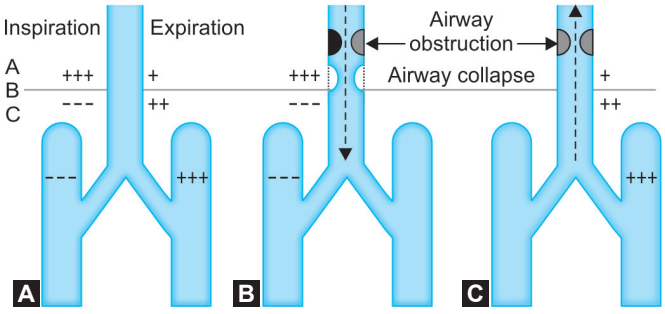


**Figs. 1A to C:** (A) Extrathoracic airways; (B) Thoracic inlet; (C) Intrathoracic airways and lungs. Part (A) Normal pressure difference between lungs and airways during inspiration (left) and expiration (right); (B) During inspiration net pressure differential results in collapse of airways distal to obstruction (venturi effect); (C) During expiration positive pressure in lungs exceeds atmospheric pressure, so airway remain open.

1. Venturi effect—pressure exerted on a partially closed tube of gas is equal in all directions except during linear air movement. Linear movement of air in a partially closed tube creates an additional pressure in forward direction of the tube and collapse of the lateral walls. Hence, during inspiration, the noncartilaginous parts of the airways have a tendency to collapse in the presence of partial obstruction. During inspiration, greater negative pressure is conducted to the lungs and major airways and in the presence of partial obstruction of the airways, it results in collapse of part of airways distal to the obstruction. Whereas during expiration, positive pressure in airways exceeds atmospheric pressure and there is no obstruction to airflow. **Figures 1A to C** demonstrate this mechanism of dynamic obstruction of airways during inspiration in the presence of partial obstruction
2. Poiseuille's law—velocity of the steady flow of a fluid through a narrow tube varies directly as the pressure and fourth power of the radius of the tube. Moreover, during turbulent flow, it varies as fifth power of radius. Small size of infants' trachea makes it more susceptible to obstruction. Anteroposterior diameter of normal glottis in infants is around 3.5 mm. Even 1 mm of edema decreases the lumen diameter by 30% and decreases velocity simultaneously to a greater extent.

## How to Identify Upper Airway Obstruction?

Supraglottic obstruction—supraglottis extends from the nose to vocal cords. This part is more susceptible for obstruction due to lack of cartilaginous tissue and multiple tissue planes encouraging rapid spread of infection. Obstruction in this part manifests as:

- Soft stridor (stertor)
- Drooling and dysphagia
- Hot potato voice
- Ineffective coughing efforts.

Stertor is a low pitched inspiratory sniffing sound generated from oropharynx and epiglottis (mostly in supraglottic obstruction). This is more prominent when the child is asleep, whereas stridor due to glottis and subglottic obstruction is worse when child is awake and exacerbated by exertion (Hollinger's law).

Glottic and subglottic obstruction—it manifests as:

- Hoarse voice
- Brassy cough
- Inspiratory/expiratory/biphasic stridor.

Stridor due to laryngeal involvement is inspiratory/biphasic. Intrathoracic tracheal obstruction due to congenital malformations manifests as expiratory stridor.

## Approach to Upper Airway Obstruction

- *Age of presentation:*
  - Newborn and early infancy—consider choanal atresia, Pierre-Robin syndrome, laryngeal web, laryngotracheomalacia, laryngeal web, tracheal stenosis, vascular ring
  - Toddlers—foreign body (FB) aspiration, acute laryngotracheobronchitis (ALTB), epiglottitis, retropharyngeal abscess
  - Older children—peritonsillar abscess.
- *Acuity of presentation:*
  - Hyperacute—FB aspiration, anaphylaxis
  - Within few hours of symptom onset—epiglottitis.
- *Associated symptoms:*
  - Fever—no fever in FB aspiration, low grade fever in ALTB, high grade fever in epiglottitis, retropharyngeal abscess, bacterial tracheitis
  - Drooling and dysphagia—epiglottitis, retropharyngeal abscess
  - Restriction of neck movement—retropharyngeal abscess
  - Barking cough and brassy voice—croup
  - Tripod position—epiglottitis, retropharyngeal abscess
  - Supine position and crying aggravates stridor—laryngomalacia.

From the history and clinical examination of a child presenting with stridor, which part of airways is affected, most probable diagnosis can be made. **Flowchart 1** helps in differential diagnosis of stridor.

JAYPEE BROTHERS

**Flowchart 1:** Approach to stridor in children.

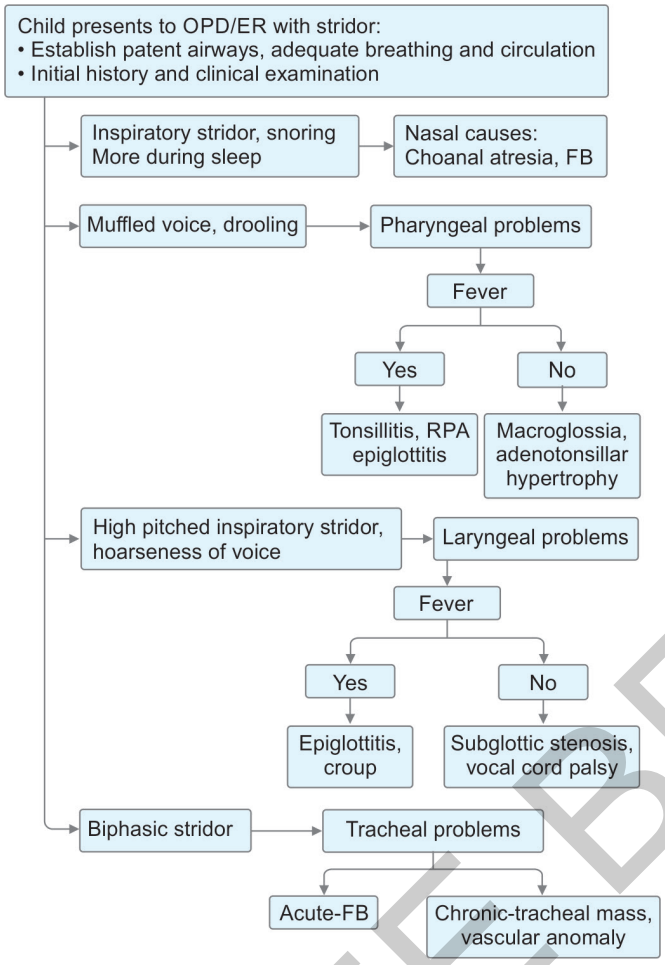


**Table 1** describes common causes of upper airway obstruction and stridor in children.

## Investigations

Evaluation of stridor is primarily based on clinical assessment and investigations play a little role. Moreover, the patient needs to be stabilized and his airways need to be secured first prior to planning any investigation.

- Neutrophilic leukocytosis may be present in retropharyngeal abscess, acute epiglottitis, and bacterial tracheitis
- Blood culture and swab culture from local site may help in isolating the organism
- X-ray neck anterior-posterior (AP) and lateral view with head in slight extension in deep inspiration:
  - Thumb sign—swollen epiglottis in acute epiglottitis **(Fig. 2)**
  - Steeple sign—symmetrical narrowing of subglottic space in croup **(Fig. 3)**
  - Increased retropharyngeal space—greater than ½ the width of adjacent vertebral body up to C5 and more than width of adjacent vertebra below C5.
- Radiopaque FB may be visible in X-ray.

### *Endoscopy*

Flexible nasopharyngoscopy, laryngoscopy, and bronchoscopy help in establishing the diagnosis. Rigid bronchoscopy is preferred for FB removal whereas fiber-optic bronchoscope has more diagnostic use.

**TABLE 1:** Common causes of upper airways obstruction in children.

| | *Choanal atresia* | *Laryngeal foreign body* | *Retropharyngeal abscess* | *Acute epiglottitis* | *Acute laryngotracheobronchitis (ALTB)* |
|---|---|---|---|---|---|
| Pathology | Anatomical obstruction | Small objects like nuts, beans, parts of toys | Bacterial *Staphylococcus aureus* | Bacterial Haemophilus influenza type-B | Viral Parainfluenza1, 2, 3 Influenza A, B, RSV, Measles, mycoplasma |
| Age of presentation | Newborn | Any age | 1–4 years | 2–6 years | 3 months–5 years Peak at 2 years |
| Clinical presentation | Excessive crying, Crying improves cyanosis, low pitched inspiratory stridor, No fever | Sudden onset, Choking, Cough paroxysms | High fever, no cough, severe dysphagia, hoarse voice, neck stiffness | Rapid progression within hours, severe dysphagia, inspiratory stridor, marked drooling, tripod position, hot-potato voice | Initial presentation as URTI, low grade fever, hoarse barking cough, inspiratory stridor |

*Contd...*

JAYPEE BROTHERS

*Contd...*

| | *Choanal atresia* | *Laryngeal foreign body* | *Retropharyngeal abscess* | *Acute epiglottitis* | *Acute laryngotracheobronchitis (ALTB)* |
|---|---|---|---|---|---|
| X-ray | Bony obstruction | Radiopaque foreign bodies may be visible | Widening of retropharyngeal space | Thumb sign | Steeple sign |
| Management | Oral airways surgical | Rigid bronchoscopy and removal of FB | Airways management Antibiotics, incision and drainage | Airways management, Antibiotics | Airways management Epinephrine nebulization Oral steroids |

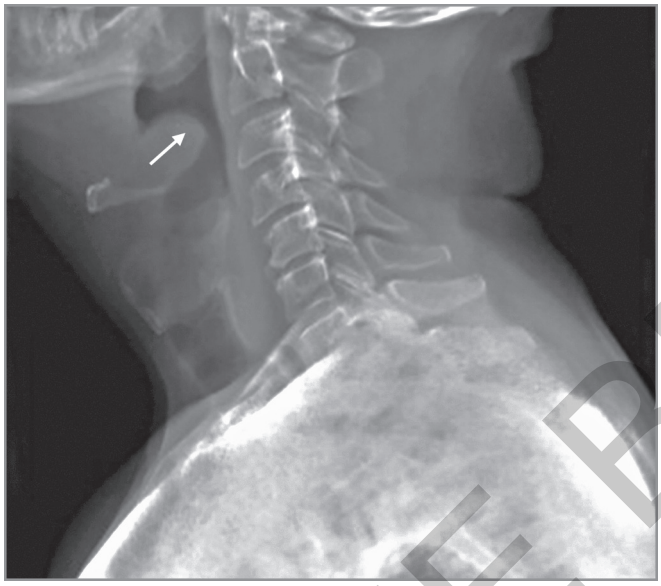

**Fig 2:** Arrow showing edematous and enlarged epiglottis known as thumb sign.

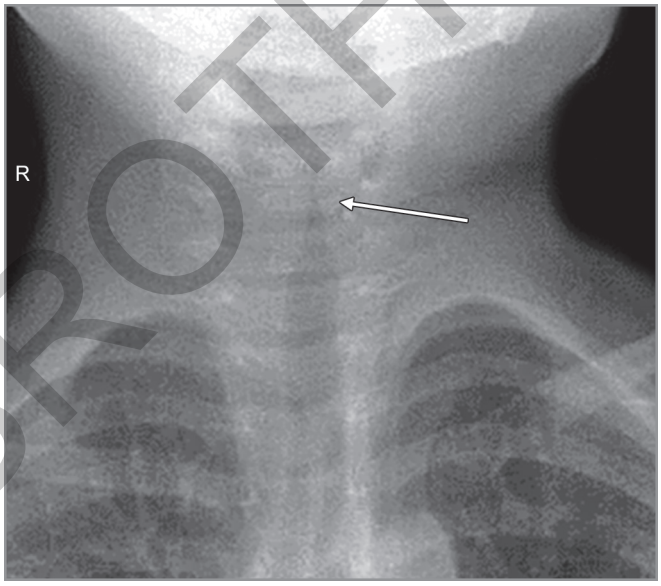


**Fig 3:** Arrow showing tapering of upper trachea known as steeple sign.

Computed tomography (CT) and magnetic resonance imaging (MRI) may be necessary for diagnosing vascular anomalies and anatomical defects resulting in stridor in children.

## Monitoring

Children with moderate to severe upper airway obstruction who have stridor at rest need continuous monitoring by pulse oximetry and end tidal $CO_2$ monitoring intermittently by prongs. Arterial blood gas (ABG) may help in identifying hypercapnia but it may agitate the patient and further aggravate hypoxia.

## Management

Airway management is the most important step in cases of stridor in order to avoid hypoxic respiratory failure.

**Flowchart 2** shows how to approach a case of acute upper airway obstruction. Warm humidified oxygen should be given in a nonthreatening way to maintain $SpO_2$ ≥95%. ALTB patients improve rapidly on exposing to cold mist. Depending upon the cause of upper airway obstruction, different types of airway adjuncts are used. **Table 2** represents different airway adjuncts used to maintain airway patency.

## Specific Management of Different Congenital and Acquired Upper Airway Obstructions

*Choanal atresia:* Surgical treatment of symptomatic newborns with bilateral choanal atresia followed by topical application of mitomycin to prevent fibroblast proliferation.

JAYPEE BROTHERS

**Flowchart 2:** Algorithm for approach to upper airways obstruction in ER.

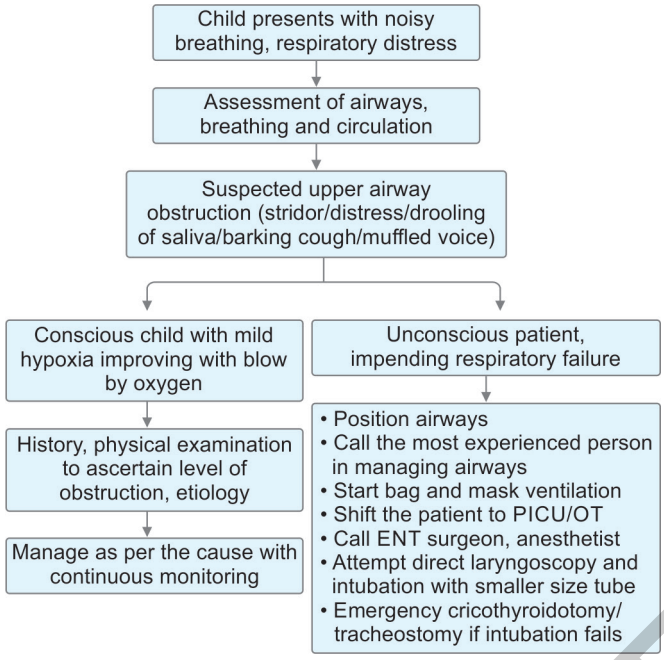


*Laryngomalacia:* Mild cases usually improve spontaneously after infancy. However, severe cases causing repeated upper airway obstruction and chronic hypoxia need laser surgical ablation.

*Acute laryngotracheobronchitis:* Children with ALTB/croup present with prodromal symptoms of low-grade fever, cough, cold followed by barking type of cough, stridor, and chest indrawing. Mild cases have occasional barking cough with no stridor at rest and no indrawing. Moderate cases have frequent barking cough with stridor at rest and retraction but good air entry on bilateral lung fields. Severe croup cases have stridor at rest with severe chest indrawing and poor air entry in bilateral lung fields and these children might be hypoxic manifested as significant agitation and cyanosis. Westley croup score is an objective measure to identify the severity of croup and it is primarily used for research purposes to quantitatively measure the response to therapy. **Table 3** describes various parameters and their corresponding scores used. Laboratory investigations are not helpful in diagnosis. However, in some cases, X-ray neck may reveal subglottic narrowing as classical "steeple sign".

**TABLE 2:** Airway adjuncts.

| *Airways* | *Size* | *Indication* | *Advantages* | *Disadvantages* |
|---|---|---|---|---|
| Nasopharyngeal | Different sizes available Approximately from tip of nose to angle of mandible | Collapse of base of tongue and/or pharynx | Can be used in alert and semi-conscious patient | Causes epistaxis |
| Oral | Different sizes available. Aprroximately from angle of mouth to angle of mandible | Unconscious patient with no gag reflex | Helps in frequent suctioning airways | • Easily dislodged<br>• Trauma to palate |
| Oral intubation | Different sizes of endotracheal tube (ET tube) available. Size-uncuffed tube: $\frac{\text{age in years}+4}{4}$ | For mechanical ventilation | Easy | • Injury to larynx and pharynx |
| Nasal intubation | | Massive oral cavity injury trismus | Not displaced easily | • Requires expertize<br>• Sinusitis |
| Fibreoptic nasal | | Suspected cervical spine injury<br>Massive oral cavity injury | Guided procedure<br>Less trauma | • Requires expertize<br>• Expensive<br>• Difficult in presence of secretions |
| Laryngeal mask airways | Different sizes available | Failure of intubation | Immediate secure airway by less experienced person | May cause aspiration |

*Contd...*

JAYPEE BROTHERS

*Contd...*

| *Airways* | *Size* | *Indication* | *Advantages* | *Disadvantages* |
|---|---|---|---|---|
| Cricothyroidotomy | | Failure of intubation<br>No laryngeal injury | | • Can cause chronic and acute laryngeal injury<br>• Surgical procedure |
| Tracheostomy | | • Laryngeal trauma<br>• Oropharyngeal obstruction<br>• Need for recurrent intubation | • Easy to secure airways<br>• Easy to clear secretions | • Surgical procedure<br>• Infection |

Management of croup depends on severity of presentation.

Initial management consists in maintaining airways, clearing secretions, and providing humidified oxygen if the child is hypoxic. Continuous monitoring of saturation should be done by pulse oximetry.

*Epinephrine nebulization:* Due to its nonselective α-adrenergic and β-agonistic action, epinephrine reduces mucosal edema. L-epinephrine injection 0.5 mL/kg maximum 5 mL added to 2–3 mL of NS in nebulizing chamber and nebulization is given along with oxygen. Stridor is significantly reduced within 30 minutes of adrenaline nebulization. Risk of rebound increase in symptoms is there; hence, the patient should be kept for observation for at least 2 hours.

*Corticosteroids:* Oral, intramuscular, or intravenous (IV) dose of dexamethasone is effective in reducing upper airway edema. Onset of action is within 1 hour and peak effect is noted in 6–12 hours. Single dose of dexamethasone 0.6 mg/kg is effective. Researchers have demonstrated that single oral dose of 0.15 mg/kg of dexamethasone is as effective as 0.6 mg/kg. There is no significant difference between oral dexamethasone and prednisolone in reducing croup symptoms. Corticosteroids reduce the need for epinephrine nebulization, intubation, and frequency of readmission. Inhaled corticosteroid as budesonide nebulization 2–4 mg can also be given.

*Heliox:* Helium-oxygen mixture 60:40 or 70:30 promotes laminar gas flow in obstructed airways. This is used for severe croup. But this is not available in most centers in India.

Antitussives and decongestants have no role in croup. Analgesics provide comfort by reducing pain and fever.

*Acute epiglottitis:* It presents as acute onset fever, irritability, throat pain, and drooling of saliva. The patient assumes a tripod position with hot potato voice and a soft stridor. Progression to respiratory failure occurs very quickly. Incidence of acute epiglottitis has reduced dramatically due to universal immunization against *Haemophilus influenzae*. However, it is a nightmare for emergency doctors and intervention for securing airways should be done in intensive care unit (ICU) or OT settings by team with significant airway expertise. Oxygen should be administered in a nonthreatening way, the child should be allowed to stay in his comfortable position, and painful interventions should be kept to minimum. Airways should be secured by an otorhinolaryngologist or anesthetist in OT. Diagnosis is done by direct visualization of swollen red epiglottis and culture swab is taken from the surface. If intubation required

**TABLE 3:** Westley's croup severity score.

| | | |
|---|---|---|
| Chest wall retraction | None | 0 |
| | Mild | +1 |
| | Moderate | +2 |
| | Severe | +3 |
| Stridor | None | 0 |
| | With agitation | +1 |
| | At rest | +2 |
| Cyanosis | None | 0 |
| | With agitation | +4 |
| | At rest | +5 |
| Level of consciousness | Normal | 0 |
| | Disoriented | +5 |
| Air entry | Normal | 0 |
| | Decreased | +1 |
| | Markedly decreased | +2 |

Mild croup-score: 0–2
Moderate croup: 3–5
Severe croup: 6–11
Impending respiratory failure: 12–17

JAYPEE BROTHERS

0.5 mm smaller endotracheal tube (ETT) for age is inserted. IV antibiotics like ceftriaxone/cefotaxim are administered and airways kept secured for at least 48–72 hours till edema subsides.

*Bacterial tracheitis:* This condition is caused by *Staphylococcus aureus*, rarely by *H. influenzae* and group A beta-hemolytic *streptococcus*. The child initially presents with symptoms of croup followed by high-grade fever, toxic look, and severe respiratory distress. Drooling and dysphagia are rare.

Management of bacterial tracheitis needs maintaining airways by intubation, frequent suctioning, and administration of appropriate antistaphylococcal antibiotics.

*Retropharyngeal abscess:* This is a serious deep neck space infection involving space between posterior pharyngeal wall and prevertebral fascia. Organisms responsible are Group A beta-hemolytic *Streptococcus*, *S. aureus,* and oral anaerobes. It presents as fever, dysphagia, drooling, respiratory distress, and neck stiffness. Diagnosis is made by identification of bulging of posterior pharyngeal wall and soft palate. Lateral X-ray of pharynx reveals swelling of soft tissue of pharynx. Patients may need intubation and surgery for drainage of abscess. Some patients with smaller abscess can be managed by IV antibiotics alone.

*Foreign body obstruction:* Acute onset of coughing, gagging, choking, or cyanosis in a previously normal child should arouse suspicion of foreign bodies in airways. Symptoms and signs might vary depending on the location of FB.

In prehospital settings:

- Let the child cough and expel the FB out
- In case of complete obstruction in infants, five back slaps followed by five chest thrusts are given till the FB is expelled or the child becomes unresponsive
- In children >1 year age, Heimlich's maneuver is performed.

In the emergency department:

- Provide supplemental oxygen in comfortable position at mother's lap
- Avoid painful stimuli. Monitor oxygen saturation
- Plan elective removal of FB in OT by ENT specialist by rigid open tube bronchoscopy.

Other less common causes of upper airway obstruction are as follows.

*Laryngeal papilloma:* This is the most common benign tumor of larynx causing acute onset stridor and dysphonia. Treatment is by surgical excision.

*Vocal cord paralysis:* Bilateral abductor palsy results in abnormal medial position of both vocal cords presenting as stridor and respiratory distress. Absence of fever and poor response to epinephrine nebulization clinch the diagnosis. Definite diagnosis is done by direct laryngoscopy. Treatment is supportive. Intubation/tracheostomy is required for maintaining airways.

*Angioedema:* Subcutaneous edema involving the soft tissues of upper airways may result in stridor and respiratory distress. This condition responds dramatically to epinephrine injection.

*Neurogenic stridor:* Patients presenting to the emergency department with loss of consciousness and seizures might have stridor due to tongue fall and absence of protective airway reflexes. In such conditions, intubation is recommended using intracranial pressure (ICP) precautions for maintaining the patient's airways.

These are the commonly encountered and relatively easily managed conditions of upper airway obstruction. What becomes more terrifying for emergency doctors are the difficult airway cases which lead to "cannot intubate and cannot ventilate" situation.

## DIFFICULT AIRWAYS

### Identification and Management

Difficult airways can result from various anatomical peculiarities and different clinical situations. Commonly encountered difficult airways are Pierre Robin syndrome, diphtheria, facial cellulitis, facial trauma, head and neck injury, acute epiglottitis, congenital or acquired subglottic stenosis, etc.

Most important and crucial step in managing difficult airways is identification of difficult airways and taking help of subspeciality team early.

### Identification of Difficult Airways

During assessment of airways in ER and from history and quick physical examination, one can assess potential difficult airways. These include:

- Neonate or young infant
- History of trauma (facial/laryngeal/tracheal/cervical spine)
- Acute epiglottitis
- Acute inhalational injuries
- Congenital craniofacial anomalies (macroglossia, retrognathia, short neck)

JAYPEE BROTHERS

- Stridor, drooling
- Morbid obesity.

If a patient with above red flag indicators admitted to ER and child is not in cardiorespiratory failure, subspeciality team comprising of otorhinolaryngologist, pediatric pulmonologist, and intensivist should be informed and difficult airway kit should be kept ready in ER. Difficult airway kit should have the following things:

- Resuscitation bag and mask (all sizes)
- Oropharyngeal airways (all sizes)
- Nasopharyngeal airways (all sizes)
- Laryngeal mask airways (LMA) of all sizes
- Laryngoscope blades (straight, curved, McCoy) with Magill's forceps
- Elastic bougie
- Needle cricothyrotomy set (14G Cannula, 5 mL syringe, 3 ETT adapter)
- Surgical cricothyrotomy set.

Difficult airways can be segregated into three groups depending on mechanism and methods to manage the same.

1. Difficult to ventilate
2. Difficult to intubate:
   - Difficulty in laryngoscopy
   - Difficulty in intubation.
3. Failed intubation with inadequate ventilation.

In **Table 2**, we have already discussed various airway adjuncts, their advantages, and disadvantages. In this section, we will discuss use of each adjunct in specific difficult scenario.

Our aim of intubation and ventilation is to provide oxygen to the patient. Hence, ensuring adequate oxygenation and avoiding fall in saturation during airway manipulation should be done strictly. Oxygen saturation should be kept around 95% and one member of the team should be delegated for monitoring saturation and to inform the airway expert when it drops to 92%. High concentration of oxygen should be provided by flow inflating device to a spontaneously breathing patient with airway obstruction. If respiratory failure is present, start bag and mask ventilation with adequate flow of oxygen (ensure that the reservoir is deflated throughout the respiratory cycle).

## Difficult to Ventilate

This can be due to large tongue, pharyngeal problems, and floppy larynx. In such cases, first:

- Reposition the child by head tilt chin lift maneuver/ jaw thrust
- Introduce oropharyngeal/ nasopharyngeal airways
- Bag and mask ventilation by two-person technique. One person to hold the mask by two hands and the other person will press the bag with high pressure.

After the above maneuvers, ventilation is assessed by adequate chest rise and improvement in saturation. One should avoid manipulating airways more than two attempts and wait for experts if adequate ventilation is achieved by bag and mask.

## Difficult to Intubate

- Difficult laryngoscopy—this situation usually arises due to improper positioning during airway manipulation. In such cases:
  - Reposition in such a way that the external auditory meatus and the anterior edge of the shoulder remain in one plane and place a roll below shoulders in infants and below head in older children
  - Apply cricoid pressure backward, upward, and rightward.
  - Insert laryngoscope in the right side of the mouth and keep the tongue in one side
  - Use half dose of sedatives and paralytic agents for intubation (if intubation could not be safely done).
- Difficulty in intubation—in such cases:
  - Use 0.5 mm smaller tube and preferentially cuffed tube if advancing ETT beyond vocal cord is difficult
  - Use introducer/bougie for inserting the ETT
  - For older children, Magill forceps can be used to redirect the ETT to the vocal cord
  - Wait for some time and continue bag and mask ventilation if laryngospasm hinders intubation.

## Failed Intubation

When a child with upper airway obstruction and respiratory failure could not be intubated after taking all the necessary corrective measures and the child is not able to maintain saturation, there arises the "cannot intubate and cannot ventilate" situation. LMA is used as a rescue device in such conditions.

Laryngeal mask airways—it is a supraglottic airway adjunct with small inflatable mask attached to an universal adapter and it is designed in such a way that tip remains in the hypopharynx and the base remains at epiglottis. Different sizes of LMA are available depending on body weight. Prior to inserting the mask is deflated and posterior surface is lubricated. By holding the LMA in a pen holding

JAYPEE BROTHERS

**Flowchart 3:** Difficult airways.

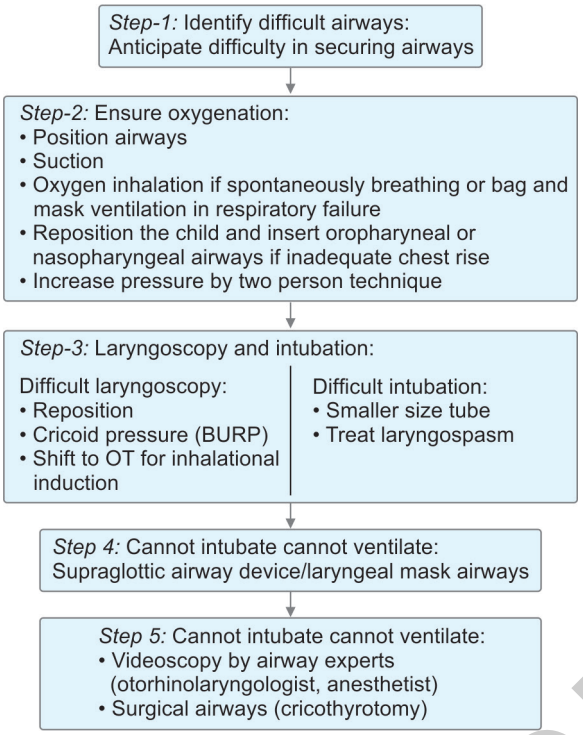


manner, it is slowly advanced in oropharynx until definite resistance is felt. Then the mask is deflated and airways are fixed after inserting the roller gage on both sides of LMA.

### *Surgical Airways*

This is the last resort in difficult airways cases and rarely required. Needle cricothyrotomy is discouraged below 10 years age. One can try this last resort if upper airway obstruction proximal to glottis is present and all maneuvers have failed. After positioning the child, 14-gage IV cannula connected to a syringe is inserted at cricothyroid membrane and advanced at 30° angle till air is aspirated. Adapter of 3-size ETT is fixed at the hub of the cannula and bag ventilation is given. After emergency cricothyrotomy, tracheostomy can be planned.

### *Videoscopic Technique*

Different types of rigid and flexible fiber-optic videoscopic devices are available which help in direct visualization of the airways and intubation. They are used by experts and also not available at all setups.

**Flowchart 3** presents how to approach a case of difficult airways.

## SUMMARY

Upper airway obstructions are life threatening and need swift management by airway experts. Congenital or acquired causes of partial airway obstruction present as stertor or stridor. Etiology of airway obstruction can be assessed from history and physical examination. Investigations are rarely indicated. Expert team comprising of pediatric intensivist, otorhinolaryngologist, anesthetist, intensive care nurse, and respiratory therapist should manage upper airway emergencies.

## KEY MESSAGES

- Most of the etiologies of stridor can be identified from history and investigations are rarely necessary
- Stabilization of airway (A), breathing (B), and circulation (C) should be done first before detailed investigation and examination
- Keep the child in comfortable position as much as possible and give oxygen in a nonthreatening way
- Never attempt intubation in emergency department without resuscitation equipment and difficult airway equipments at hand
- Avoid paralytic agents for intubation
- If stridor with respiratory failure is identified, start bag and mask ventilation and call for expert help (ENT surgeon).

## FURTHER READING

1. Beiner J, Lecuyer M. Calculated decisions: Westley croup score. Pediatr Emerg Med Pract. 2017;14(Suppl 11):1-3.
2. Bjornson C, Russell KF, Vandermeer B, et al. Nebulized epinephrine for croup in children. Cochrane Database Syst Rev. 2013;10:CD006619.
3. Bjornson CL, Johnson DW. Croup-treatment update. Pediatr Emerg Care. 2005;21(12):863-70.
4. Chameides L, Samson RA, Schexnayder SM, et al. Management of respiratory distress and failure. Pediatr Adv Life Supp Prov Manual. 2011.
5. Darras KE, Roston AT, Yewchuk LK. Imaging acute airway obstruction in infants and children. Radiographics. 2015;35(7):2064-79.
6. Grundfast KM, Insalaco LF, Levi J. The 10 commandments of management for acute upper airway obstruction in infants and children. JAMA Otolaryngol Head Neck Surg. 2017;143(6):539-40.
7. Ida JB, Thompson DM . Pediatric stridor. Otolaryngol Clin North Am. 2014;47(5):795-819.
8. Lynn MB, Davies JC. Acute infections that produce upper airway obstruction. In: Chernick Y, Kendig Jr EL (Eds).

JAYPEE BROTHERS

Disorders of the Respiratory Tract in Children, 8th edition. Philadelphia: Saunders; 2012. pp. 424-36.
9. Mandal A, Kabra SK, Lodha R. Upper airway obstruction in children. Indian J Pediatr. 2015;82(8):737-44.
10. Marchese A, Langhan ML. Management of airway obstruction and stridor in pediatric patients. Pediatr Emerg Med Pract. 2017;14(11):1-24.
11. Moraa I, Sturman N, McGuire T, et al. Heliox for croup in children. Cochrane Database Syst Rev. 2013;(12):CD006822.
12. Ortiz-Alvarez O. Acute management of croup in the emergency department. Paediatr Child Health. 2017;22(3):166-73.
13. Preece R. Guidelines for difficult airway equipment in emergency departments. Emergency Med J. 2006;3:230.
14. Roosevelt GE. Acute inflammatory upper airway obstruction (croup, epiglottitis, laryngitis and bacterial tracheitis). In: Kliegmean RM, Stanton BF, Schor NF (Eds). Nelson Textbook of Pediatrics, 20th edition. Philadelphia: Saunders Elsevier; 2016. pp. 2031-5.
15. Russell KF, Liang Y, O'Gorman K, et al. Glucocorticoids for croup. Cochrane Database Syst Rev. 2011;(1):CD001955.
16. Smith DK, McDermott AJ, Sullivan JF. Croup: Diagnosis and Management. Am Fam Physician. 2018;97(9):575-80.
17. The American Society of Anaesthesiologists Task Force. Practice guidelines for the management of difficult airways. Anaesthesiology. 2003;98:1267-77.
18. Toward Optimized Practice. Diagnosis and Management of Croup. Clinical Practice Guideline, January 2008. [online] Available from www.topalbertadoctors.org/download/252/croup_guide-line.pdf [Accessed December, 2018].

# 3.2 ACUTE SEVERE ASTHMA

*Atul Jindal, Jagadish Prasad Goyal*

## PROBLEM STATEMENT

The prevalence of asthma in childhood is 5–6%.[1] According to a large study from PGIMER (n = 43,800), acute exacerbation of asthma was the 3rd most common diagnosis in pediatric emergency (5.2% of all cases) after acute diarrhea and seizures.[2] Despite advancing knowledge of the pathophysiology and treatment of asthma, its morbidity and mortality are on the rise.

It is the leading cause of hospitalizations in children less than 15 years of age.[3]

## DEFINITION

According to various guidelines, asthma exacerbation can be defined as episodes of coughing (particularly at night/early morning), wheezing, breathlessness, or chest tightness which are usually associated with widespread, but variable, airflow obstruction within the lung that is often reversible either spontaneously or with treatment.[4,5]

The term "status asthmaticus" relates severity to outcome and has been used to define a severe asthmatic exacerbation that does not respond to repetitive or continuous administration of short-acting inhaled β2-adrenergic receptor agonists (SABAs) in the emergency setting.[6-8]

According to National Centre for Health Statistics (NCHS) data, 4% of attacks and 21% of all episodes treated in urgent care centers would be considered severe.[9]

## PATHOPHYSIOLOGY

Airway obstruction leads to increased airway resistance, reduced expiratory flow, air trapping with each breath, and lung hyperinflation. The expiration becomes an active process. Diaphragmatic flattening from hyperinflation causes additional mechanical disadvantages. Both forced expiratory volume and forced vital capacity are decreased and total lung volumes are increased.

Gas exchange abnormalities occur because of V/Q mismatch, which includes increased intrapulmonary shunt, and increased dead space (airway over-distension).

Dynamic hyperinflation (air trapping with each breath) in severe asthma can stretch the pulmonary vasculature, increasing pulmonary vascular resistance, and right ventricular after load. During the large negative intrathoracic pressure during inspiration, left ventricular after load is increased, and systolic blood pressure decreases. Exaggerated variation in systolic blood pressure during inspiration is termed as pulsus paradoxus.

## CLINICAL PRESENTATION

The child with status asthmaticus presents with cough and wheezing, and exhibits signs of dyspnea, increased work of breathing, and anxiety. The sick asthmatic child may also present in respiratory failure or even frank cardiopulmonary arrest. Ominous signs include distant or absent breath sounds ("silent chest") in the face of increased respiratory effort.

JAYPEE BROTHERS

The diagnosis can be difficult in the "first time wheezer" or in a child with atypical symptoms **(Box 1)**.

While on an emergent basis there is no diagnostic test for asthma, a family history of asthma, a history of recurrent symptoms, and a good response to therapy support the diagnosis.

*Clinical history to be evaluated:*

- History of cough
- History of fever
- History of respiratory distress/noisy breathing/whistling sounds/cyanosis/lethargy
- Past history of asthma
- If yes, whether on regular treatment? (details of treatment)
- Any previous hospitalization? (If yes, details of duration and treatment?)
- Rule out foreign body inhalation/pneumonia.

Clinical examination and severity assessment in case of acute severe asthma:

- Temperature/heart rate/peripheral pulses/BP/pulsus paradoxus
- Respiratory rate
- Air entry
- Nasal flaring/retractions/accessory muscle usage
- Dyspnea
- Wheeze (phase and length of wheeze)
- Saturation (off oxygen) (on oxygen)
- Other systems examination.

*Assessment of severity:*

Various parameters can be used to assess the severity of acute asthma **(Tables 1 and 2)**. These parameters should be used to assess the initial severity and also to monitor the response to therapy.

**BOX 1:** Differential diagnosis of wheezing in childhood.

1. Infection:
   - Viral:
     - Respiratory syncytial virus/bronchiolitis
     - Parainfluenza, influenza, adenovirus, rhinovirus human metapneumovirus
   - Bacterial pneumonia
   - Chlamydia
2. Asthma*
3. Aspiration syndromes*
4. Heart disease*
5. Anatomic abnormalities:
   - Extrinsic airway anomalies:
     - Vascular ring/sling
   - Intrinsic airway anomalies:
     - Airway hemangioma
     - Cystic adenomatoid malformation
     - Bronchial lung cyst
     - Congenital lobar emphysema
     - Sequestration of lung
     - Mediastinal lymph node/tumor/TB lymphadenitis
   - Malacia of larynx, trachea, or bronchi
6. Foreign body
7. Anaphylaxis
8. Inhalational injuries (burns)
9. Mucociliary clearance disorders:*
   - Cystic fibrosis
   - Primary ciliary dyskinesia
   - Bronchiectasis

Entities marked * are causes of recurrent wheeze.

## PRINCIPLES OF CLINICAL MANAGEMENT

Five clinical entities must be rapidly differentiated in a wheezing child—asthma, pneumonia, foreign body, bronchiolitis, and congestive heart failure. Emergency room management of acute attack includes assessment of severity and appropriate interventions being carried out simultaneously, assessing response to the therapy (based on clinical asthma severity score—CASS)[10] and taking suitable actions in the face of unresponsiveness.

*Remarks:*

- A calm patient usually denotes, at the most, mild distress
- An anxious asthmatic child indicates severe obstruction and probably hypoxia
- "Silent chest" indicates inadequate air exchange and severe airway obstruction
- Unilateral diminished breath sounds (in a case of asthma) can indicate severe postobstructive atelectasis or can be a manifestation of a pneumothorax
- Peak flow and spirometry are useful in older and cooperative children (especially if baseline values are known)
- Peak flow measures obstruction in larger airways, spirometry assesses the more peripheral airways.

### Clinical Predictors of Impending Respiratory Failure

Findings indicating impending respiratory failure include disturbance in level of consciousness (drowsy, confused), inability to speak, markedly diminished or absent breath sounds, central cyanosis, diaphoresis and inability to lie down, pulsus paradoxus more than 20 mm Hg, peak expiratory flow rate (PEFR) less than 25% of predicted or patient's best, abdominal paradox, $SaO_2$ less than 90%, $PaO_2$ less than 60 mm Hg, and $PaCO_2$ more than 45 mm Hg.

JAYPEE BROTHERS

**TABLE 1:** Clinical asthma severity score.[10*]

| *Score* | *RR* | *Room air saturation#* | *Auscultation (wheeze)* | *Retractions##* | *Dyspnea* |
|---|---|---|---|---|---|
| 0 | <30 | 97–100 | None | None | None |
| 1 | 31–45 | 94–96 | End expiration | +/– | Full sentences |
| 2 | 46–60 | 91–93 | All expiration | ++ | Partial sentences |
| 3 | >60 | <91 | Inspiration and expiration without stethoscope | +++ | Single word/grunt |

#Off oxygen for 5 minutes or until saturation drops less than 91%.
##Subjective assessment
*Maximum score is 15. This score should be used for the initial assessment and to monitor the response to therapy. Generally, the severe patients with have a high score (i.e., >7).

**TABLE 2:** Assessment of severity.

| *Parameter** | *Mild* | *Moderate* | *Severe* | *Imminent respiratory arrest* |
|---|---|---|---|---|
| Breathless | Walking<br>Can lie down | Talking (infant-shorter cry/difficult feeding);<br>Prefers sitting | At rest (infant will stop feeding)<br>Hunched forward | |
| Talks in | Sentences | Phrases | Words | |
| Alertness | May be agitated | Usually agitated | Usually agitated | Drowsy/confused |
| Respiratory rate | Increased | Increased | Increased | |
| Accessory muscles and suprasternal retractions | Usually not | Usually | Usually | Paradoxical movement |
| Wheeze | Moderate (end expiration) | Loud | Usually loud | Absence of wheeze |
| Pulse/minute | <100 | 100–120 | >120 | Bradycardia |
| Pulsus paradoxus (mm Hg) | Absent (<10) | 10–25 | >25 | Absence suggests respiratory muscle fatigue |
| Peak expiratory flow rate (after bronchodilator) | >80% | 60–80% | <60% | |
| $PaO_2$ on air and/or $PaCO_2$ (mm Hg) | Normal (need not be tested) | >60<br><45 | <60<br>>45 | |
| Saturation | >95% | 91–95% | <90% | |

*The presence of several parameters, but not necessarily all indicates the severity of the attack.
*Source:* NHLBI/NAEPP/Expert Panel Report 3: Guidelines for the diagnosis and management of Asthma; 2007, p. 380.

## Chest Radiography and Other Laboratory Studies

Laboratory studies are generally not indicated in a routine acute exacerbation. However if the child is unusually ill or there is doubt of an infection, blood samples can be taken for:

- White blood cell count
- Serum electrolytes
- Blood culture.

Chest radiographs are not routinely indicated in the unintubated asthmatic child, as unexpected radiographic abnormalities are very rare.[11] It is indicated if clinical examination suggests the possibility of pneumothorax or pneumonia, or when there is doubt about alternate cause of wheeze like pneumonia or foreign body.

Peak expiratory flow rate may be used in children over 5–6 years of age who are able to cooperate.

Arterial blood gas measurement yields quantitative information on pulmonary gas exchange and is used in severely distressed or ventilated patients. Typical findings during the early phase of severe asthma are hypoxemia and hypocarbia. With increasing airflow obstruction, hypercarbia will develop and indicate impending respiratory failure.

JAYPEE BROTHERS

## Principles of Management of Acute Asthma in Emergency

- Accurate and regular assessment
- Correction of hypoxemia with oxygen
- Rapid reversal of airflow obstruction using inhaled medications
- Early addition of corticosteroids to speed the rate of improvement
- Close monitoring of the clinical response
- Titrate treatment based on clinical response (including parenteral bronchodilators)
- To establish a future plan of management.

## TREATMENT (FLOWCHART 1)

Any child in status asthmaticus requires cardiorespiratory monitoring. A comfortable and supportive environment should be provided, ideally with a parent or family member present. While hypoxemia and anxiety will lead to agitation and restlessness, sedatives are contraindicated in the nonintubated asthmatic patient.

### Oxygen

All patients with asthma have ventilation/perfusion mismatch and thus require humidified oxygen. High-flow supplemental oxygen is best delivered via a partial or nonrebreather mask. In the absence of pre-existing chronic pulmonary disease, there is no evidence that oxygen will suppress the respiratory drive. Titrate to maintain $SaO_2$ more than 92%.

### Inhaled Beta-agonists

Beta 2-receptor agonists remain the mainstay of therapy in status asthmaticus. These agents mediate bronchodilatation via stimulation of $\beta_2$-receptors on airway smooth muscle, which in turn mediates smooth muscle relaxation.

The most common mode of administering a β-agonist in an asthmatic patient is nebulization. The most frequently used agent is salbutamol in a dose of 0.15 mg/kg. Some experts recommend much higher doses of nebulized β-agonists. Tidal volume, breathing pattern, and nebulized gas flow further vary the amount of drug delivery.

Presently, no recommendation regarding the use of the much more expensive (R)-albuterol in children with status asthmaticus can be made.[12]

A Cochrane meta-analysis showed no overall difference between the effects of albuterol delivered by metered-dose inhaler (MDI) spacer or nebulizer, but MDI spacer administration can be difficult in patients in severe distress.[13]

Orally administered β-agonists are ineffective in severe asthma. Subcutaneous epinephrine is rarely indicated and should be utilized only in extreme circumstances where inhaled β-agonists are unavailable or undeliverable (no aeration, intubated patient without proper delivery device), when there are other systemic signs of anaphylaxis, and when intravenous access has not been established in a patient with impending respiratory failure.

For children who need more frequent doses of β-agonist, continuous nebulization appears to be superior to intermittent doses. Use of continuous nebulization with salbutamol may lead to more rapid improvement, improved sleep, and may also be more cost-effective. Continuous administration has been found to be more efficacious and more cost-effective in patients with severe exacerbation of asthma.[14]

For any form of nebulization, the nebulization device should be driven by oxygen. Care must be taken to utilize the correct flow rate. Each nebulizer device has a different flow-particle size relationship, but most devices require 6–12 L/min in order to deliver particles in the 1–3 μm range.

Major adverse effects of β-agonists include tachycardia, prolonged QTc interval, hypokalemia, and tremors. Cardiovascular adverse effects and tremor show tachyphylaxis, whereas bronchodilator response usually does not.

### Corticosteroids (Inhaled and Systemic)

Early use of anti-inflammatory therapy with systemic steroids is effective in the emergency room treatment of acute moderate and severe exacerbations of asthma. Inhaled glucocorticosteroids have a potential benefit in the acute setting because they are delivered directly into the airways, have few systemic side effects, and induce a reduction in the airway hyperreactivity.[15]

A 2003 Cochrane Database review demonstrates improved outcomes for children who receive corticosteroids early in their emergency department course.[16]

In the following situations, steroids can be started at the outset:

- A child with a very severe attack of asthma
- Previous history of life-threatening attack or severe attacks not responding to bronchodilators
- If the child is on oral steroids or high doses of inhaled steroids for prophylaxis.

JAYPEE BROTHERS

for detailed information on pediatric books, visit our website **www.jaypeebrothers.com,** for detailed information on pediatric books, visit our website **www.jaypeebrot**

IAP Textbook of

# Pediatric & Neonatal Emergencies

*IAP Textbook of Pediatric and Neonatal Emergencies* comes with a unique feature of having both pediatric and neonatal emergencies together. This feature makes the tedious efforts of reading easier and exam-friendly. This book is a ready reference for most of the emergencies of the newborn and children. A wide range of emergencies, common approach in acute care, their pearls and pitfalls have been emphasized. The book is designed for all specialties requiring a working knowledge in acute care of pediatrics and neonatology. Some of our key chapters are on communication, toxicology, neurological emergencies, renal emergencies among many more. All the chapters are written for easy understanding and feasible application in the routine practice by the specialists. We hope that all health professionals caring for children in acute care settings, would find the book useful in their practice, improving overall patients' outcome.

**Available at all medical bookstores**
**or buy online at www.jaypeebrothers.com**




**JAYPEE BROTHERS**
**Medical Publishers (P) Ltd.**
**www.jaypeebrothers.com**

Join us on facebook.com/JaypeeMedicalPublishers

Shelving Recommendation
**PEDIATRICS**

