nformation on pathology books, visit our website www.jaypeebrothers.com, for detailed information on pathology books, visit our website www.jaypeebrothers.com

Get Full Access
with added features at
emedicine360.com

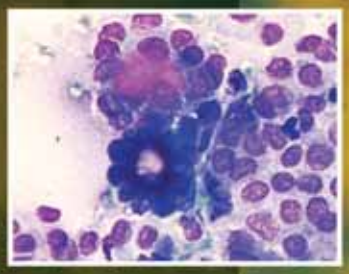
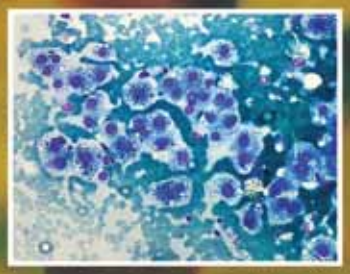
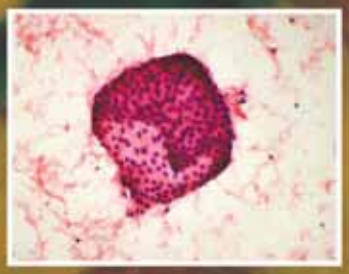
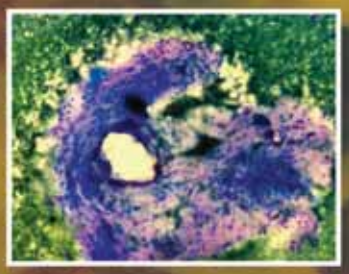

Diagnostic Cytology

3rd Edition

Pranab Dey

JAYPEE

CONTENTS

SECTION 1: GENERAL CYTOLOGY

CHAPTER 1: Cell **3**
Eukaryotic Versus Prokaryotic Cells 3
Cell Membrane 3
Cytoplasmic Organelles 9
Nucleus 17
Deoxyribonucleic Acid 20

CHAPTER 2: Cell Cycle and Cell Proliferation **26**
Cell Cycle 26
Cell Division 27
Cell Cycle Checkpoint 29
Cell Cycle Regulator Proteins 30
Cell Cycle Control and Cancer 31
Cell Proliferation Markers 32
Stem Cell 35

CHAPTER 3: Cellular Reaction to Injury and Cell Death **38**
Cellular Adaptation 38
Reversible Cell Injury 39
Irreversible Cell Injury 39
Autophagy 45
Necrosis 48
Programmed Necrosis: Necroptosis 48
Pyroptosis 50
Ferroptosis 50
Inflammation 51

CHAPTER 4: Molecular Genetics: Basic Principles and Clinical Applications **53**
Chromosome 53
Cytogenetics 57
Molecular Cytogenetic Techniques 58

CHAPTER 5: Neoplasm **65**
Benign Neoplasm 65
Biological Characteristics of Malignant Tumor or Cancer 66
Hallmarks of Cancer 66
Cancer Stem Cells 69
Molecular Basis of Cancer 70
Oncogenes and Cancer 71
Functional Properties of Oncogene 72
Microribonucleic Acid and Cancer 73
Genomic Instability 74
Tumor Suppressor Genes 77

JAYPEE BROTHERS

Tumor Microenvironment 80
Preneoplastic Lesions 82
Morphology of Cancer Cell 82
Cell and Cytoplasm 83
Nucleus 83
Characterization of Type of Cancer Cell 87
Diagnostic Pitfalls of Malignancy 89

CHAPTER 6: Tissue and Cell Organization **92**
Epithelial Tissue 92
Connective Tissue 94

SECTION 2: CLINICAL CYTOLOGY (EXFOLIATIVE)

CHAPTER 7: Normal Anatomy, Histology and Cytology of Female Genital Tract **101**
Vulva 101
Vagina 101
Histology 101
Uterus 101
Ovaries 103
Fallopian Tubes 103
Normal Cells in Cervical Smear 103
Changes of Squamous Epithelium 105
Bethesda System of Reporting 108

CHAPTER 8: Cervical Carcinogenesis, Preneoplastic and Neoplastic Condition **119**
Human Papillomavirus and Cervical Carcinogenesis 119
Cervical Preneoplastic Lesions 121

CHAPTER 9: Cervical Cancer Screening Program **140**
Parameters to Measure the Validity of Screening Tests 140
Screening Guidelines 140
Types of Modalities for Cervical Cancer Screening 141
Essential Elements for Successful Cervical Cancer Screening 143
HPV Vaccination 144

CHAPTER 10: Effusion Cytology **147**
Anatomy and Histology of Body Cavities 147
Effusion 147
Specimen Collection and Processing 148
Benign Cell Population in Effusion 149
Effusion Due to Non-neoplastic Causes 152
Malignant Effusion 154
Metastatic Tumors 157
Primary Serosal Tumor 169

CHAPTER 11: Urine Cytology **178**
Anatomy and Histology 178
Normal Cytology 180
Specimen Collection 182

JAYPEE BROTHERS

Processing of Urinary Sample 183
Crystals and Casts in the Urine 183
Non-neoplastic Lesions in the Urinary Tract 184
Neoplastic Lesions 187
Paris System of Classification 188
Cytology of Malignancy in Urine 190
Ancillary Techniques 194
Diagnostic Accuracy of Urine Cytology 196

CHAPTER 12: Respiratory Cytology **198**
Normal Anatomy and Histology 198
Sampling Techniques 199
Normal Cytology 201
Benign Cellular Abnormalities 203
Infections 205
Lung Carcinomas 209
Classification of Lung Cancer 209
Individual Tumors 213

CHAPTER 13: Gastrointestinal Tract **225**
Sampling Techniques 225
Esophagus 226
Stomach 231
Small and Large Intestine 237
Large Intestine 238
Anal Cytology 238

CHAPTER 14: Cerebrospinal Fluid **240**
Anatomy 240
Gross Appearance of Cerebrospinal Fluid 240
Cytology 240
Sampling of Cerebrospinal Fluid 240
Infective Conditions 242
Demyelinating Diseases 243
Neoplasm 243
Primary Central Nervous System Lymphoma 246
Other Primary Central Nervous System Tumor 246
Diagnostic Accuracy 247

SECTION 3: LABORATORY TECHNIQUES

CHAPTER 15: Basic Technique and Approach to Fine-needle Aspiration Cytology **251**
Fine-needle Aspiration Technique 252
Fine-needle Sampling 254
Staining of The Smear 255
Ancillary Techniques 256
FNAC of Deep-seated Lesions 256
Suboptimal Material in FNAC 258
Evaluation of FNAC Smear 258

JAYPEE BROTHERS

CHAPTER 16: Routine Laboratory Techniques 260
Sample Collection 260
Fixation 262
Preservation of the Sample Prior to Processing 263
Processing of Laboratory Samples 263
Processing 264
Staining 267
Dehydration and Clearing of the Smear 269
Mounting 269
Coverslip 269
Storage 269

CHAPTER 17: Special Stains and Immunocytochemistry 271
Special Stains 271
Immunocytochemistry 273
Samples for Immunocytochemistry 274
Diagnostic Immunocytochemistry 278

CHAPTER 18: Light microscope 288
Visible Light 288
Image Formation in Human Eye 288
Light Microscope 289
Image Formation in a Compound Microscope 289
Care and Handling of the Microscope 290
Fluorescence Microscopy 290
Confocal Microscopy 291

CHAPTER 19: Digital Pathology 293
Workflow of Digital Pathology 293
Essential Components of a Digital Pathology Laboratory 293
Advantages of Digital Pathology 294
Limitations of Digital Pathology 294
Whole Slide Imaging 295
Artificial Neural Network 298

CHAPTER 20: Flow Cytometry 302
Brief History of Flow Cytometry 302
Basic Principles of Flow Cytometry 302
The Instrument at a Glance 303
Fluorescence-activated Cell Sorter 303
Control 304
Flow Cytometric Immunophenotyping 304
Immunophenotyping of Lymphoma 305
DNA Content and Ploidy Analysis 309
Future of Flow Cytometry 311

CHAPTER 21: Automation and Liquid-based Cytology 312
Liquid-based Cytology 312
Automation in Screening 315
Automated Screening Devices 315
Available Automated Screening Devices 315

JAYPEE BROTHERS

Comparison of Manual and Automated Devices 316
Problems of Implementing Automation 316

CHAPTER 22: Polymerase Chain Reaction and Next Generation Sequencing 318
Components of Polymerase Chain Reaction 318
Steps of Polymerase Chain Reaction 318
Types of Polymerase Chain Reaction 319
Applications of Polymerase Chain Reaction 320
DNA Sequencing 321
First-generation Sequencing 321

CHAPTER 23: Quality Control and Laboratory Organization 327
Preanalytical Phase 327
Analytical Phase 327
Postanalytic Phase 328
Interlaboratory Comparison 328
External Quality Assurance 329
Laboratory Organization 329
Laboratory Safety 331
COVID-19 (Sars-Cov-2) Infection and Biosafety 332

SECTION 4: FINE-NEEDLE ASPIRATION CYTOLOGY

CHAPTER 24: Head, Neck, and Orbit 337
Head and Neck 337
Cystic Lesions 337
Branchial Cyst 337
Thyroglossal Cysts 338
Epidermal Inclusion Cyst 338
Cystic Hygroma 338
Mucocele 338
Neoplastic Lesions 339
Nasopharyngeal Carcinoma 340
Ameloblastoma 341
Parathyroid Tumors 341
Meningioma 342
Olfactory Neuroblastoma 343
Orbital Lesions 344
Malignant Neoplasm of Eyelid 345
Lesions of the Lacrimal Gland 345
Intraorbital Tumors 345

CHAPTER 25: Salivary Gland 349
Anatomy and Histology of the Salivary Gland 349
Indications of FNAC of the Salivary Glands 349
Contraindications 350
Complications 350
Fine-needle Aspiration Cytology: Technical Consideration 350
Overview of the Diagnostic Challenges 350

JAYPEE BROTHERS

Normal Salivary Gland Cells 351
Salivary Gland Lesions 352
Neoplastic Lesions 354
The Milan System of Reporting the Cytology of Salivary Gland 355

CHAPTER 26: Thyroid **372**
Approach to Fine-needle Aspiration Cytology of the Thyroid 372
Techniques 372
Anatomy and Histology 373
Diagnostic Accuracy 374
Bethesda Terminology 374
Normal Aspirated Material 375
Diseases of Thyroid 375
Ancillary Techniques 394
Management of Post-FNAC Diagnosis of Thyroid Lesion 395

CHAPTER 27: Breast **399**
Indications of FNAC of Breast 399
Contraindications 399
Diagnostic Accuracy 399
Limitations of FNAC 400
Clinical History 400
Triple Test 401
Core Needle Biopsy Versus FNAC 401
Adequacy of the Sample 401
Histology of Breast 402
Normal Cytology of Breast 402
Inflammatory Lesions 402
Benign Noninflammatory Lesions 405
Proliferative Breast Disease 408
Ductal Carcinoma In Situ 410
Carcinoma 413
Other Types 415
Male Breast Lesions 421
Ancillary Investigations on Breast Aspiration Material 422
Reporting of Breast FNAC 422
Ancillary Techniques 423
Molecular Classification of Breast Carcinoma 424
Nipple Discharge 425

CHAPTER 28: Lymph Node **429**
Normal Anatomy and Histology of the Lymph Node 429
Approach of Lymph Node FNAC 431
Aspiration 431
Normal Component of a Lymph Node 431
Diagnostic Accuracy 431
Benign Lesions in the Lymph Node 432
Metastatic Malignancy 441
Lymphomas 443
Lymphoma Classification 443

JAYPEE BROTHERS

Lymphomas of Large Cells 450
Hodgkin Lymphoma 455
Approach to Diagnosis of Lymph Node Lesions 458
Leukemic Infiltration 460

CHAPTER 29: Mediastinum **463**
Anatomy of the Mediastinum and General Considerations 463
Clinical History 463
Techniques 463
Lesions 464
Approach to the Diagnosis of Mediastinal Tumors 471

CHAPTER 30: Liver and Spleen **473**
Liver 473
Normal Cells 473
Liver Lesions 474
Spleen 485
Non-neoplastic Process 485

CHAPTER 31: Pancreas **488**
Pancreas 488
Cysts of Pancreas 489
Neoplastic Lesion of Pancreas 490
Carcinoma 491
Neuroendocrine Tumor 493
Neuroendocrine Carcinoma 495

CHAPTER 32: Kidney and Adrenal **499**
Normal Cells 499
Renal Lesions 500
Renal Neoplasms 500
Metastatic Tumors of Kidney 506
Pediatric Renal Tumors 507
Adrenal 510
Adrenocortical Neoplasm 510
Pheochromocytoma 511
Metastatic Tumors 513

CHAPTER 33: Gonads and Prostate **516**
Testis 516
Female Genital System 521
Prostate 525

CHAPTER 34: Soft Tissue Lesions **529**
Diagnostic Accuracy 529
FNAC Technique and Information Needed for Diagnosis 530
Ancillary echniques 530
Individual Soft-tissue Tumors 531

CHAPTER 35: The Skin **548**
Non-neoplastic Lesions 548
Rare Benign Diseases of the Skin 548

JAYPEE BROTHERS

Neoplastic Lesions of the Skin 549
Malignant Tumors of the Skin 552

CHAPTER 36: Bone **558**
Normal Cells 558
Bone Forming Tumor 559
Cartilage Forming Tumor 561

CHAPTER 37: Round Cell Tumor **572**
Diagnostic Approach 572
Cytomorphology 572

CHAPTER 38: Infection **577**
Common Samples 577
Stains and Other Tests 577
Bacterial 577
Parasites 579
Fungal Infection 581
Viral Infections 583

REVIEW QUESTIONS **585**

INDEX **621**

JAYPEE BROTHERS

VIDEO CONTENTS

Indexing of the videos on Laboratory Techniques for the book of Diagnostic Cytology (3rd edition)

1. Fluorescent in situ hybridization technique: *Chapter 4*
2. Fine needle aspiration cytology: *Chapter 15*
3. Fluid processing by simple centrifugation: *Chapter 16*
4. Cytospin technique: *Chapter 16*
5. Millipore filtration technique: *Chapter 16*
6. Cell block technique: *Chapter 16*
7. Papanicolaou's staining: *Chapter 16*
8. May–Grünwald–Giemsa staining: *Chapter 16*
9. Automated and manual immunocytochemistry: *Chapter 17*
10. Flow cytometry: *Chapter 20*
11. Liquid based cytology of cervical smear: *Chapter 21*
12. Liquid based cytology of Non-gynecological sample: *Chapter 21*
13. Polymerase chain reaction technique: *Chapter 22*
14. Next Generation Sequencing: *Chapter 22*

JAYPEE BROTHERS

Low Power	LP
Lupus erythematous	LE
Lymphoblastic lymphoma	LBL
Lymphocytic and/or histiocytic	L & H
Lymphoepithelial sialadenitis	LESA
Lymphoglandular body	LGB
Lymphoplasmacytic lymphoma	LPL
Malignant fibrous histiocytoma	MFH
Malignant mesothelioma	MM
Malignant peripheral nerve sheath tumor	MPNST
Malignant round cell tumor	MRCT
Mantle cell lymphoma	MCL
Marginal zone lymphoma	MZL
Matrix attachment region	MAR
May–Grünwald–Giemsa	MGG
Mediator of DNA damage checkpoint 1	MDC1
Medium Power	MP
Medullary carcinoma	MCL
Messenger RNA	m-RNA
Micro RNA	miRNA
Micronucleus	MN
Microsatellite instability	MSI
Mitochondria	MT
Mucinous cystic neoplasia	MCN
Mucoepidermoid carcinoma	MEC
Mucosa associated lymphoma	MALT
Multicolor FISH	M-FISH
Multiple endocrine neoplasia	MEN
Myxoid Liposarcoma	MLS
Nasopharyngeal carcinoma	NPC
National Health Service, United Kingdom	NHS UK
Natural killer T	NKT
Negative for intraepithelial lesion or malignancy	NILM
Neuroblastoma	NB
Neuron-specific enolase	NSE
Nodular lymphocytic predominant HL	NLPHL
Non-Hodgkin lymphoma	NHL
Nontuberculous mycobacteria	NTM
Nuclear matrix proteins	NMP
Nuclear pore complex	NPC
Nucleocytoplasmic	N/C
Nucleolar organizing regions	NOR
Numerical aperture	NA
Oil immersion	OI
Open reading frames	ORF
Oral contraceptive pill	OCP
Orange G	OG
Origin recognition complex	ORC
Outer nuclear membrane	ONM
p53-binding protein 1	53BP1
Pancreatic endocrine tumor	PET
Papillary neoplasia of low malignant potential	PUNLMP
Papillary thyroid carcinoma	PTC
Periodic acid–Schiff's	PAS
Peripheral neuroectodermal tumor	PNET
Peripheral T-cell lymphoma	PTCL
peritoneal mucinous carcinomatosis	PMCA
Phosphatidylinositol 3-phosphate	PI3P
Phosphatidylserine	PtdSer
Phycoerythrin	PE
Phyllodes tumor	PT
Placental alkaline phosphatase	PLAP
Plasma cell myeloma	PCM
Platelet-derived growth factor	PDGF
Pleomorphic adenoma	PA
Polyclonal carcinoembryonic antigen	p-CEA
Polymerase chain reaction	PCR
Polymorphous low-grade adenocarcinoma	PLGA
pre replicative	pre-RC
Precursor miRNA	pre-miRNA
Primary effusion lymphoma	PEL
Primary mediastinal large B-cell lymphoma	PMLBCL
Primary miRNA	pri-miRNA
Primitive neuroectodermal tumor	PNET
Progesterone receptor	PR
Programmed cell death	PCD

JAYPEE BROTHERS

Proliferating cell nuclear antigen	PCNA
Proliferative breast disease	PBD
Prostate-specific antigen	PSA
Psammoma bodies	PB
Rhabdomyosarcoma	RMS
Reactive lymphoid hyperplasia	RLH
Reed-Sternberg's	RS
Renal cell carcinoma	RCC
Replication licensing factors	RLF
Retinoblastoma	Rb
Reverse transcriptase PCR	RT-PCR
Rhabdomyoma	RM
Rhabdomyosarcoma	RMS
Ribonucleic acid	RNA
Ribosomal RNA	rRNA
Ring finger-binding protein	RFBP
Rough endoplasmic reticulum	RER
Scavenger receptors	SR
Sebaceous carcinoma	SC
Single strand conformation polymorphism	SSCP
Sinus histiocytosis with massive lymphadenopathy	SHML
Small cell carcinoma	SCC
Small lymphocytic lymphoma	SLL
Smooth endoplasmic reticulum	SER
Soft tissue sarcoma	STS
Solid and cystic papillary neoplasm	SCPN
Spectral karyotyping	SKY
Spindle assembly check point	SAC
Squamous cell carcinomas	SQC
Squamous intraepithelial lesion	SIL
Standard operating protocol	SOP
Synovial sarcoma	SS
Syringocystadenoma papilliferum	SCAP
Systemic lupus erythematosus	SLE
TATA-binding protein	TBP
Telomeric repeat amplification protocol	TRAP
Terminal deoxynucleotidyl transferase mediated dUTP Nick End Labeling	TUNEL
The Bethesda System	TBS
Thyroid-stimulating hormone	TSH
Thyroid-stimulating immunoglobulin	TSI
Thyroid transcription factor	TTF
Transbronchial fine-needle aspiration cytology	TBNA
Transfer RNA	tRNA
Transitional cell carcinoma	TCC
Trichomonas vaginalis	TV
Tumor necrosis factor–receptors	TNF-receptors
Ultrasonography	USG
Upstream regulatory region	URR
Urothelial carcinoma	UC
Vascular endothelial growth factor	VEGF
Vascular permeability factor	VPF
Visual inspection of cervix with acetic acid	VIA
Wilms' tumor	WT
World Health Organization	WHO

JAYPEE BROTHERS

CHAPTER

30 Liver and Spleen

LIVER

The fine needle aspiration cytology (FNAC) of the liver is mainly useful for the diagnosis of neoplastic lesion particularly to distinguish a primary liver tumor from a metastatic one and also to identify the type of metastatic or primary malignancy. FNAC is done under the guidance of ultrasonography (USG), computed tomography (CT) scan, or via endoscopy. The diagnostic accuracy of liver FNAC is near about 100%. The sensitivity and specificity of FNAC of the liver in the diagnosis of malignancy are about 95% and 100%, respectively. FNAC is of little help in the diffuse parenchymal lesions of the liver such as cirrhosis, hepatitis, etc., except in certain conditions such as amyloidosis and hemochromatosis. Occasionally metastatic malignancy may be diffusely infiltrative such as breast carcinoma and lymphoma. FNAC may be helpful in such conditions.[1-4]

Ultrasonography guidance FNAC of the liver can be done from multiple sites in a single sitting, and the adequate material can be obtained from a lesion as small as 1 cm diameter. A space-occupying lesion in the liver may be hepatocellular carcinoma, metastatic carcinoma, hydatid cyst, amebic, or pyogenic abscess. FNAC diagnosis in these lesions guides the surgeons or physician to manage the case accordingly.

There is almost no complication of the FNAC of the liver lesion. However, rarely focal hemorrhage, biliary peritonitis, and anaphylactic shock (in hydatid cyst) may occur. Bleeding diathesis is the contraindication of liver FNAC and therefore, prothrombin time or prothrombin index should be done before this procedure. The diameter of the needle preferably should be small, and 22–25 gauge needle reduces the risk of any complication. It is better to avoid FNAC from a hydatid cyst as there is a chance of spillage of cyst fluid and the development of the allergic reaction.

NORMAL CELLS

Normal cellular contents of FNAC of the liver are:

Hepatocytes (**Fig. 30.1**): Hepatocytes are present in small clusters or discretely. The cells are large polygonal with abundant cytoplasm containing golden brown bile pigment. The nuclei are centrally placed round monomorphic with finely granular chromatin and prominent nucleoli (**Box 30.1**). Pseudoinclusions are also noted. A mild degree of nuclear pleomorphism may be seen in the benign hepatocyte.

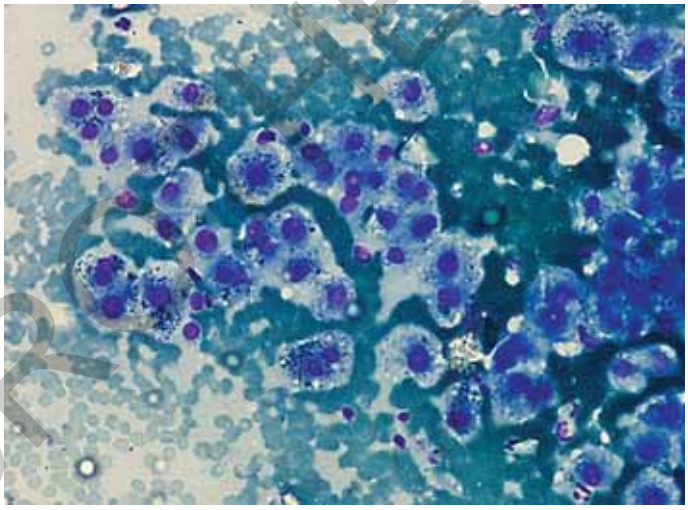

FIG. 30.1: Benign hepatocytes in the cluster. Polygonal cells with abundant cytoplasm having monomorphic nuclei. The cytoplasm contains bile pigment (MGG × HP).

Box 30.1 **Heptocytes.**

- Polygonal cells
- Abundant cytoplasm
- Central round nuclei
- Prominent nucleoli
- Nuclear pesudoinclusion
- Bile pigments in cytoplasm

Bile Ductules

The bile ductular cells are present usually in small cohesive clusters. The cells are well spaced and give a honeycomb-like appearance (**Fig. 30.2**; **Box 30.2**). The individual cells are

JAYPEE BROTHERS

small with scanty cytoplasm and small round monomorphic nuclei.

Kupffer Cells

The Kupffer cells are usually single cells, and they present in between the hepatocytes. These are cells of histiocytic in origin. The Kupffer cells have scanty cytoplasm, bean-shaped nuclei with inconspicuous nucleoli. Phagocytosed materials are often noted within the Kupffer cell.

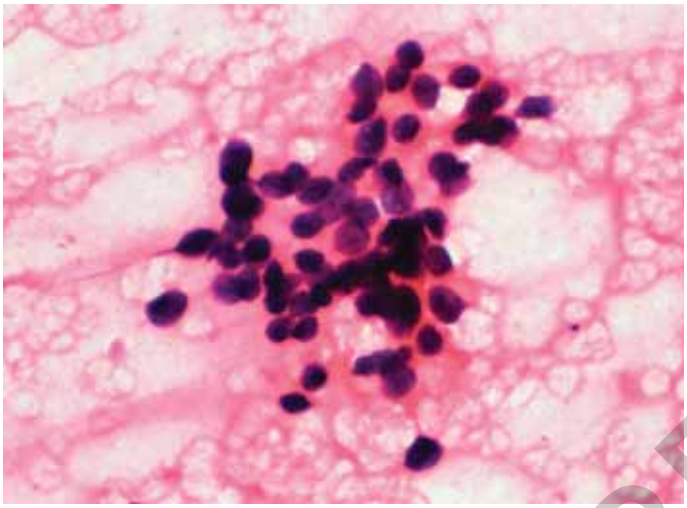

FIG. 30.2: Bile ductular cells in small clusters. The cells are round monomorphic, having scanty cytoplasm (H&E × MP).

Box 30.2 Bile ductular cells.

- Small clusters or honeycomb sheet
- Small round cells
- Scanty cytoplasm

Endothelial cells

These cells surround the cluster of hepatocytes. Individual cells have spindle-shaped elongated nuclei with prominent nucleoli and scanty delicate cytoplasm.

LIVER LESIONS

The updated World Health Organization classified the tumor of liver as mentioned in **Table 30.1**.

Non-neoplastic Lesions

Cysts

Congenital Cysts

These are usually unilocular. The wall of the cyst is lined by cuboidal to columnar epithelium. FNAC of the congenital cyst yields clear fluid, and the smear is usually hypocellular that shows predominantly macrophages and cuboidal to columnar epithelial cells.

The ciliated foregut cyst is also solitary and remains beneath the falciform ligament. These cysts are lined by ciliated columnar epithelium. FNAC smears of the cyst show mucus cells and ciliated columnar cells. At times the cilia may be lost, and the cells may be mistaken as malignant cells.

Hydatid Cysts

Hydatid cyst is caused by *Echinococcus granulosus*, a tapeworm. Infection of this parasite invades multiple organs in the human body. The liver is the commonest site of hydatid cyst. The cyst in the liver is usually solitary, and on imaging the cyst is covered by a membrane and filled with fluid. The membrane is acellular. From the germinal layer, many multiple daughter cysts may grow. The daughter cysts contain many scolices with hooklets.

TABLE 30.1: World Health Organization classification of liver tumors.

Benign	Malignant	Benign biliary tumor and their precursors	Malignant biliary neoplasm
Hepatocellular adenoma • HNF1A inactivated hepatocellular adenoma • Beta-catenin activated hepatocellular adenoma	Hepatocellular carcinoma–NOS • Hepatocellular carcinoma—Fibrolamellar • Hepatocellular carcinoma—Scirrhous • Hepatocellular carcinoma—Clear cell • Hepatocellular carcinoma—Steatohepatitis • Hepatocellular carcinoma—Neutrophil rich • Hepatocellular carcinoma—Lymphocyte rich Hepatoblastoma	• Bile duct adenoma • Adenofibroma • Biliary intrahepatic neoplasia • Intraductal papillary neoplasm: low grade, high grade and invasive • Mucinous cystic neoplasm: low grade, high grade and invasive	• Cholangiocarcinoma • Undifferentiated carcinoma • Combined cholangio-sand hepatocellular carcinoma • Neuroendocrine tumor: grade 1, grade 2 and grade 3 • Neuroendocrine carcinoma • Mixed neuroendocrine and non-neuroendocrine tumors

JAYPEE BROTHERS

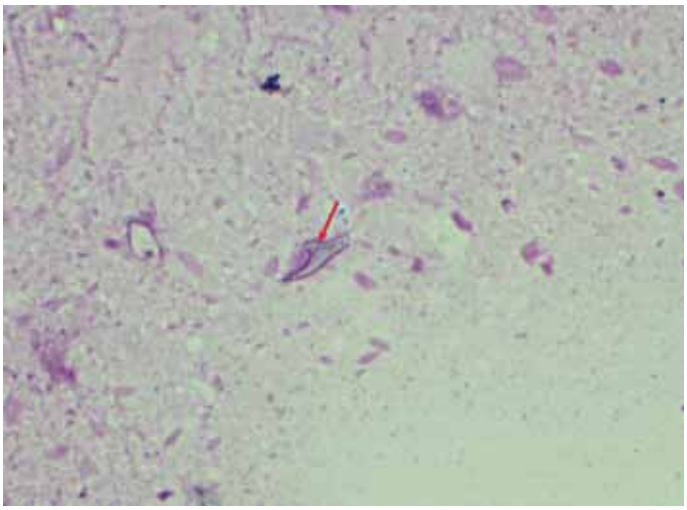

FIG. 30.3: Hooklet of hydatid cyst in an aspirate from the liver (MGG × HP).

Box 30.3 Hydatid cyst.

- Laminated membrane
- Scolices
- Hooklets
- Multinucleated giant cells

Cytology (Fig. 30.3): FNAC from the hydatid cyst is not recommended because of the risk of anaphylactic shock. However, it may be done accidentally from the hydatid cyst. FNAC yields clear fluid. The smear shows polymorphs, laminated membrane, like structure, occasional multinucleated giant cells, and many scoleces with hooklets (**Box 30.3**). The presence of hooklets is diagnostic of hydatid cyst.

Pyogenic Abscess

This is usually caused by bacterial infection due to sepsis or ascending cholangitis. The common organisms are streptococci and staphylococci. Cytology smear shows numerous polymorphs, necrotic debris, and degenerated hepatocytes. The hepatocytes in the wall of the cyst may show significant reactive atypia (**Box 30.4**).

Amebic Abscess

This is due to infection of the ameba. FNAC smear shows both polymorphs and lymphocytes along with the amebic trophozoites. *Entamoeba histolytica* has small vesicular nuclei and vacuolated cytoplasm with phagocytosed RBC.

Benign Lesion

Focal Nodular Hyperplasia

More than 90% focal nodular hyperplasia (FNH) are seen in females of reproductive age-group. Occasionally it may occur in pediatric age group.[5] FNH possibly results due to hyperplastic response to arterial malformation. CT scan of the liver shows a mass with a central stellate scar. The scar enhances in the arterial phase and disappears in the portal venous phase. FNAC of FNH yields a chunk of liver tissue that is difficult to spread on the slide. The smear shows abundant discrete benign hepatocytes along with many fibroblasts in the background (**Box 30.5**). The hepatocytes look completely benign and a diagnosis of FNH is not possible in the cytology smear.

Box 30.4 Pyogenic abscess.

- Polymorphs
- Necrotic debris
- Degenerated hepatocytes
- Reactive atypia of hepatocytes

Box 30.5 Focal nodular hyperplasia.

- Benign hepatocytes
- Many fibroblasts
- Bile ductular cells

Liver Cell Adenomas

Liver cell adenomas predominantly occur in females under 30 years of age who take oral contraceptive for more than five years.[6] The liver cell adenoma may present with pain abdomen due to rupture of the adenoma into the surrounding tissue. CT scan of the liver shows an encapsulated, well-circumscribed, low-density mass with the marked centripetal pattern of enhancement on the arterial phase.

Histology of the liver cell adenoma shows only benign hepatocytes without any portal triads.

Cytology (Figs. 30.4 and 30.5)

FNAC smear of the liver cell adenoma shows abundant three-dimensional clusters and also dissociated cells. The hepatocytes are normal polygonal in shape with often vacuolated cytoplasm (**Box 30.6**). Nuclei are round and monomorphic appearances. The background of the smear does not show any bile duct epithelium. The cytological features of liver cell adenoma are nonspecific, and the diagnosis is impossible on FNAC smear alone. Clinical history, CT scan findings, along with cytology may be helpful in diagnosis of liver cell adenoma.

Differential Diagnosis

- Hepatocellular carcinoma (HCC)
- *Reactive hepatocytes:* The cells in reactive hepatocytes show more nuclear pleomorphism than liver cell adenoma. The absence of bile duct epithelial cells favors liver cell adenoma.

JAYPEE BROTHERS

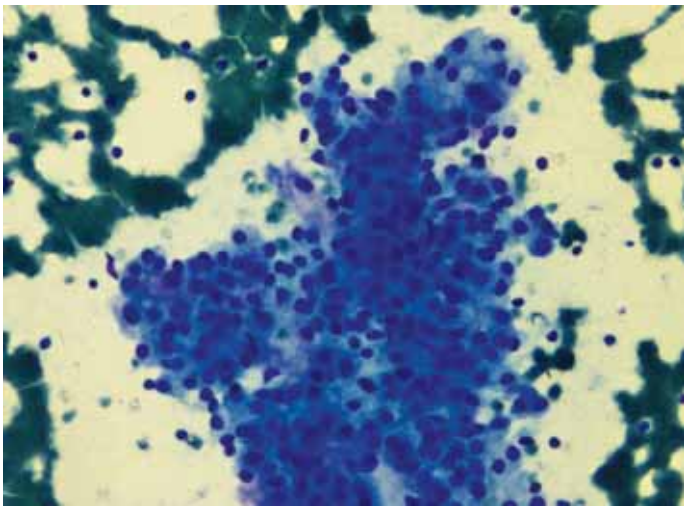

FIG. 30.4: Large cluster of benign-looking hepatocytes in FNAC smear of liver cell adenoma (MGG × MP).

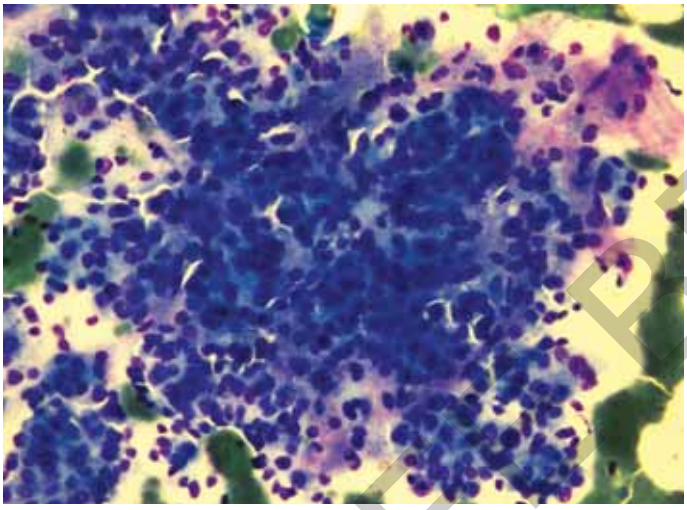

FIG. 30.5: FNAC smear of liver cell adenoma showing benign-looking hepatocytes (MGG × HP).

Box 30.6 Liver cell adenoma.

- Three-dimensional clusters of hepatocytes
- Normal looking hepatocytes
- Mild atypia
- Absence of bile duct epithelial cells
- *CT scan:* Well-encapsulated, low-density mass with centripetal enhancement on arterial phase

- *Cirrhotic nodule:* Lack of atypia and absent bile ductules favor liver cell adenoma

Malignant Tumor

Hepatocellular Carcinoma[7-15]

Hepatocellular carcinoma (HCC) is a malignant tumor that develops from the hepatocytes. It is one of the most common malignant tumors in Asia and also a worldwide major public health problem. Males are more commonly affected by HCC than females. It may be in any group, however, the incidence of HCC is more in 30–40 years of age.

It is also the most common primary malignant tumors of the liver. The common etiologic causes of HCC are:

- Hepatitis B and hepatitis C infection
- Alcoholic cirrhosis
- Dietary ingestion of a high dose of aflatoxin
- Long-standing use of oral contraceptives
- High-dose anabolic steroid
- Iron overload.

Out of all these causes, chronic viral infections by HBV and HCV are the most common etiological factors. It has been noted that individuals with chronic HBV infection carry 100 times more risk of HCC than uninfected people. HBV vaccination reduces the incidence of HCC.

Cirrhosis of the liver is another important risk factor of HCC, and almost 90% of HCC develops from cirrhosis. In 60% of HCC cases, alpha-fetoprotein (AFP) level is high. This is one of the important diagnostic markers of HCC. A significantly raised level of AFP level or continuous rising level of the same suggests the possibility of HCC.

The patient of HCC usually presents with generalized weakness, malaise, and pain abdomen. Physical examination of the patients shows hepatomegaly, jaundice, and ascites.

Biochemical Features

The patients of HCC may show a rise in liver enzymes such as aspartate aminotransferase, alanine aminotransferase, alkaline phosphatase, gamma-glutamyl-transpeptidase, and bilirubin. These raised enzymes depend on the underlying liver disease and damage. They are nonspecific for HCC. AFP is also raised in HCC. Serum AFP level of more than 500 ng/mL is highly suggestive of HCC. Des-gamma-carboxy prothrombin (DCP), abnormal prothrombin, is produced from the tumor cells in HCC. The serum level of DCP is a useful marker of HCC and is well correlated with tumor size and inversely correlated with the grade of HCC. A combination of AFP and DCP is more effective as diagnostic serological markers rather than a single marker.

Imaging Study

Various radiological imaging studies are helpful for the detection of HCC, such as USG, CT scan, magnetic resonance imaging, and color Doppler ultrasonography.

Cytology (Figs. 30.6 to 30.11)

FNAC smear of the liver should be thoroughly studied in low power magnification of the microscope (**Box 30.7**). The smears should be studied for:

- The pattern of the spread of cells,
- Individual tumor cells,
- Background hepatocytes or other evidence.

JAYPEE BROTHERS

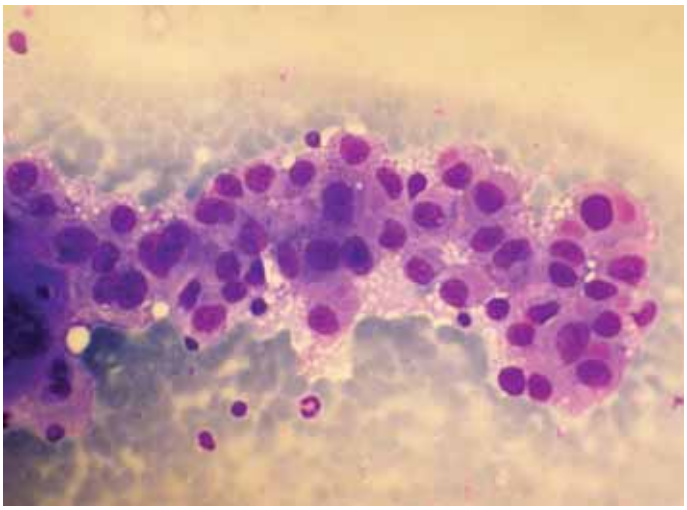

FIG. 30.6: Hepatocellular carcinoma. The cells are arranged in the long cord (MGG × HP).

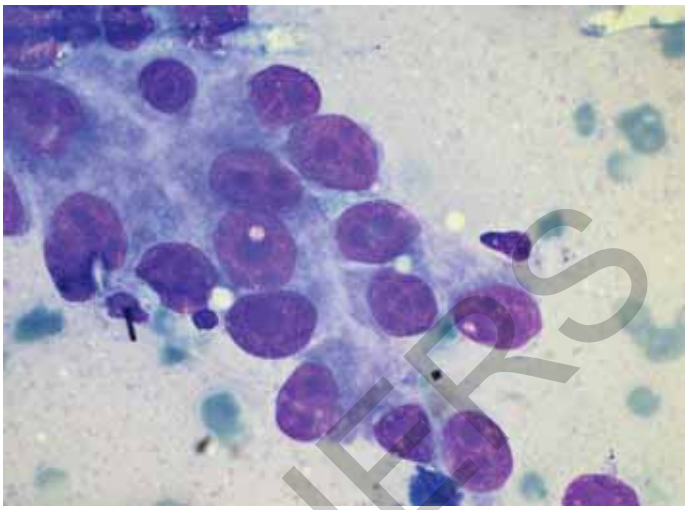

FIG. 30.9: Hepatocellular carcinoma: Higher magnification showing large cells resembling hepatocytes. The nuclei are large, pleomorphic and show multiple prominent nucleoli (MGG × OI).

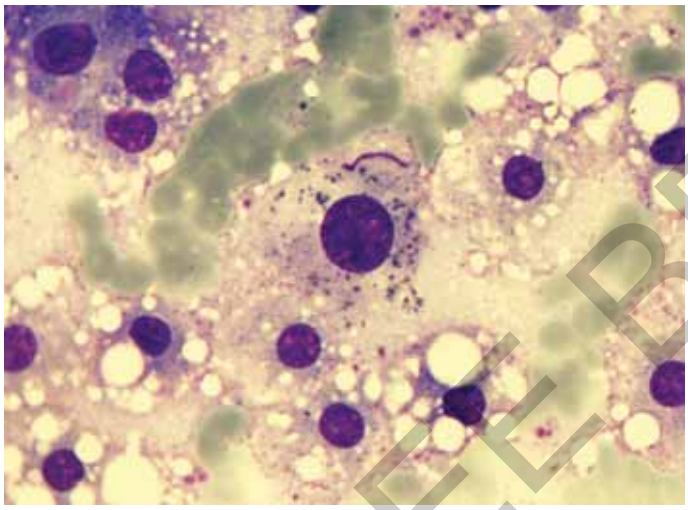

FIG. 30.7: Hepatocellular carcinoma: Bile within the malignant hepatocytes (MGG × HP).

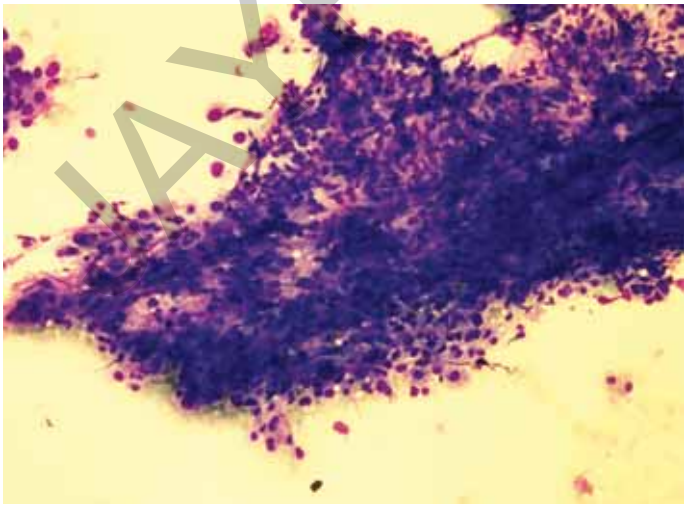

FIG. 30.8: Hepatocellular carcinoma: Transgressing capillaries within the hepatocytes (MGG × MP).

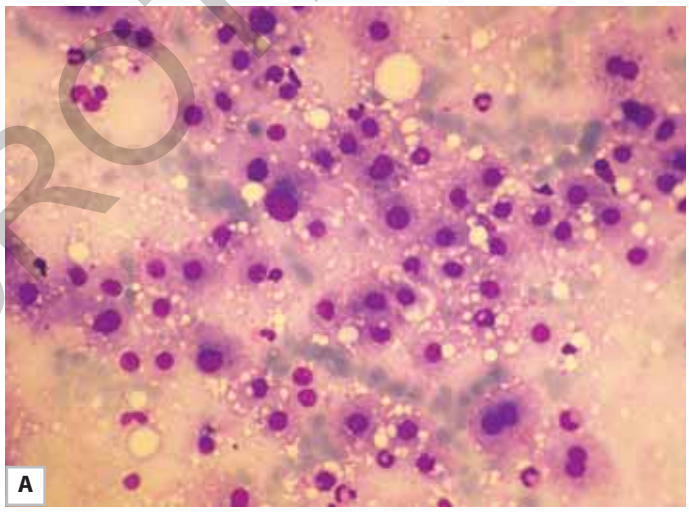

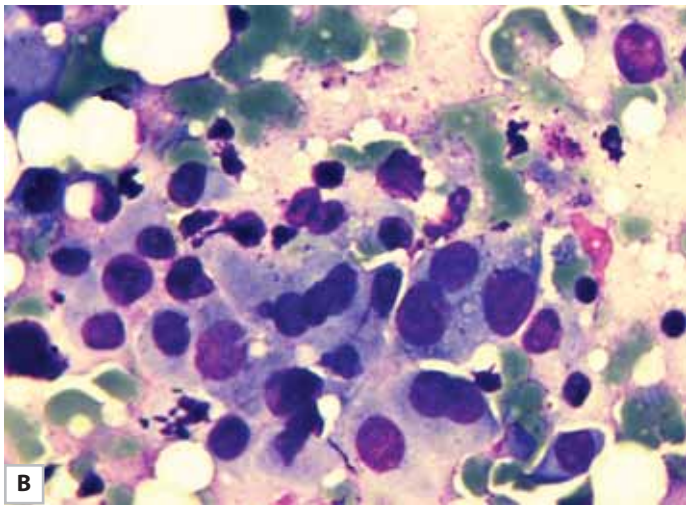

FIGS. 30.10A AND B: (A) Hepatocellular carcinoma: Well-differentiated hepatocellular carcinoma resembles normal hepatocytes (MGG × MP). (B) Poorly differentiated hepatocellular carcinoma: Large moderately pleomorphic cells (MGG × HP).

JAYPEE BROTHERS

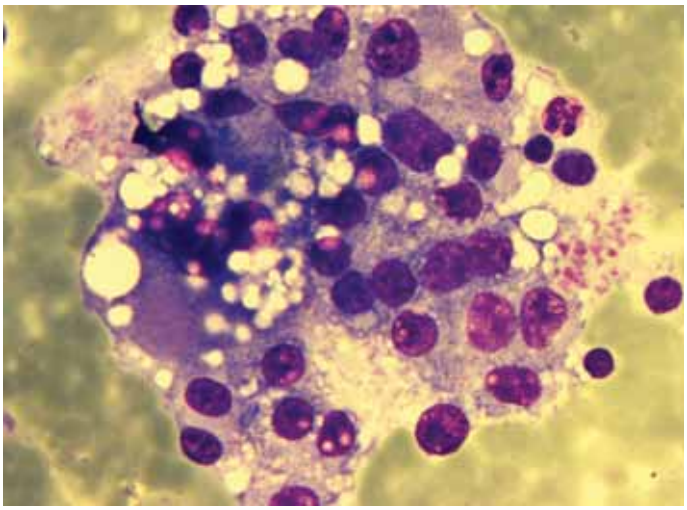

FIG. 30.11: Clear cell type hepatocellular carcinoma: Cells with marked clear vacuolated cytoplasm (MGG × HP).

Box 30.7 Hepatocellular carcinoma.

- Hypercellular
- Trabecular, acinar, cord of cells
- Polygonal malignant cell resembling hepatocytes
- Well-defined cell margin
- Atypical bare nuclei.
- Transgressing capillaries within clusters
- Enlarged pleomorphic nuclei
- Macronucleoli
- Intracytoplasmic bile pigments
- Intracytoplasmic eosinophilic globules

Immunocytochemistry: Positive for alpha-fetoprotein, HepPar 1, Glypican-3, polyclonal carcinoembryonic antigen (p CEA), and CD10

Smears with hypercellularity and regularly arranged cells usually indicate the possibility of HCC.

The tumor cells are arranged in the following pattern:

- Trabecular: Trabecular pattern is characterized by a column of three to four cells and surrounded by endothelial cells.
- Acinar or glandular: The acinar pattern shows a central lumen surrounded by five to eight cells.
- Thin cords: One to two cells thick rows of cells

The single most important feature of HCC is that the tumor cells resemble hepatocytes. The individual tumor cells are large polygonal with a well-defined cytoplasmic border. The nuclei show a mild to severe degree of pleomorphism with large prominent macronucleoli. The nuclear membrane is well-defined, irregular and often shows folds and deep indentations. The nuclear chromatin is finely granular. Intranuclear cytoplasmic inclusions may also be seen in HCC and they are not specific.

TABLE 30.2: Differentiating points between hepatocellular carcinoma and metastatic adenocarcinoma.

Features	Hepatocellular carcinoma	Metastatic adenocarcinoma
Pattern of cells	Trabecular, acinar, small cluster	Glandular
Transgressing capillaries	Present	Absent
Associated benign hepatocytes	Usually absent	Present
Bare nuclei	Present	Absent
Cell shape	Polygonal	Columnar
Cytoplasm	Eosinophilic granular	Vacuolated
Macronucleoli	Present	Usually absent
Intracytoplasmic bile pigment	Present	Absent
HbsAg	Positive	Negative
Alpha-fetoprotein level in serum	Raised	Mostly normal
Immunocytochemistry HepPar 1, Glypican-3, pCEA and CD10	Positive	Negative

Intracytoplasmic pale hyaline globules resembling Mallory hyaline bodies and vacuoles containing fat and glycogen may also be noted. The presence of intracytoplasmic bile pigments is found in almost one-third of HCC cases, and this is specific for the diagnosis of HCC.

Transgressing thin capillaries lined by the endothelial cells within the large clusters of tumor cells are also noted. Uncommonly pseudoacini are seen with central dark brown blobs of bile. The cytology smears also show many atypical stripped bare nuclei that are similar to the nuclei present in intact hepatocytes. Isolated tumor giant cells may also be noted.

Reactive or regenerative hepatocytes may often show nuclear enlargement and pleomorphism. Bi- and multinucleated hepatocytes are also seen. The differentiating cytological features of HCC from reactive hepatocytes are abundant cellularity, the trabecular pattern of cells, moderate to marked nuclear atypia, stripped atypical nuclei, and macronucleoli.

On FNAC, it is difficult to differentiate a metastatic adenocarcinoma from the HCC. However, certain cytological features such as polygonal cells resembling hepatocytes, trabecular pattern of cells, background stripped nuclei, eosinophilic granular cytoplasm, and intracellular bile pigments favor a diagnosis of HCC rather than metastatic adenocarcinoma (**Table 30.2**).

JAYPEE BROTHERS

At times, it is difficult to differentiate liver cell adenoma from HCC. Both the conditions may show abundant cellularity and nuclear atypia. However, clinical history of cirrhosis, raised AFP level, absence of a history of steroid intake along with the cytological features of the trabecular arrangement of the cell surrounded by endothelial lining, stripped atypical cell, and significant nuclear atypia favor a diagnosis of HCC.

Variants of HCC

Fibrolamellar Variant of HCC

It is a distinct clinicopathological entity. The fibrolamellar HCC is a rare variant of HCC and is commonly noted in the second and third decade of life. This tumor presents as single nodule, and therefore, it is surgically resectable. In histology section, the tumor cells are arranged in sheets or small trabeculae. The cells are separated by hyalinized collagen bundles with a characteristic lamellar pattern.

Cytology (Box 30.8): Aspiration cytology smears show dyscohesive large polygonal liver cells (**Figs. 30.12A** and **B**) with abundant dense granular eosinophilic oncocytic cytoplasm. The nuclei are round, monomorphic, with coarse chromatin. Cytoplasmic pale bodies are also characteristic of this tumor. Many benign spindle-shaped fibroblasts and fragments of collagen are seen in the background.

Clear Cell Variant

The clear cell variant comprises almost 10% of cases of HCC. Here the cells show abundant clear vacuolated cytoplasm due to the accumulation of glycogen. Focal clear cell change may also be seen in classical HCC. This case may be difficult to distinguish from metastatic renal cell carcinoma.

Giant Cell Variant of HCC

Pure giant cell HCC is very uncommon. In this tumor, the FNAC smear shows multiple tumor giant cells. The cell may be large mononuclear or multinucleated.

Small Cell Variant

The cytology smears of this variant of HCC resemble a neuroendocrine tumor. The tumors show dyscohesive or acinar arrangement of small round to oval cells with scanty cytoplasm. Nuclear features of the cells resemble neuroendocrine tumor. Trabecular pattern is absent in this variant.

Spindle Cell Variant

The pure form of the spindle cell variant is uncommon. The cytology smear shows spindle-shaped hepatocytes in small clusters along with many giant hepatocytes. The individual cells show spindle-shaped nuclei with moderate nuclear pleomorphism. If the smear contains predominantly spindle cells, it may be difficult to differentiate this tumor from a metastatic spindle cell sarcoma such as fibrosarcoma or leiomyosarcoma.

HCC with Fatty Change

In this variant, the smears show malignant hepatocytes with remarkable fatty changes. This variant of HCC may be mistaken for a fatty change in the liver. Poorly differentiated HCC with fatty change may be mistaken for metastatic liposarcoma.

Box 30.8 Fibrolamellar variant of HCC.

- It is commonly noted in second and third decade of life
- Surgically resectable
- Dyscohesive large polygonal liver cells
- Dense granular eosinophilic oncocytic cytoplasm
- Cytoplasmic pale bodies
- Nuclei are round, monomorphic with coarse chromatin
- Many benign spindle-shaped fibroblasts and fragments of collagen

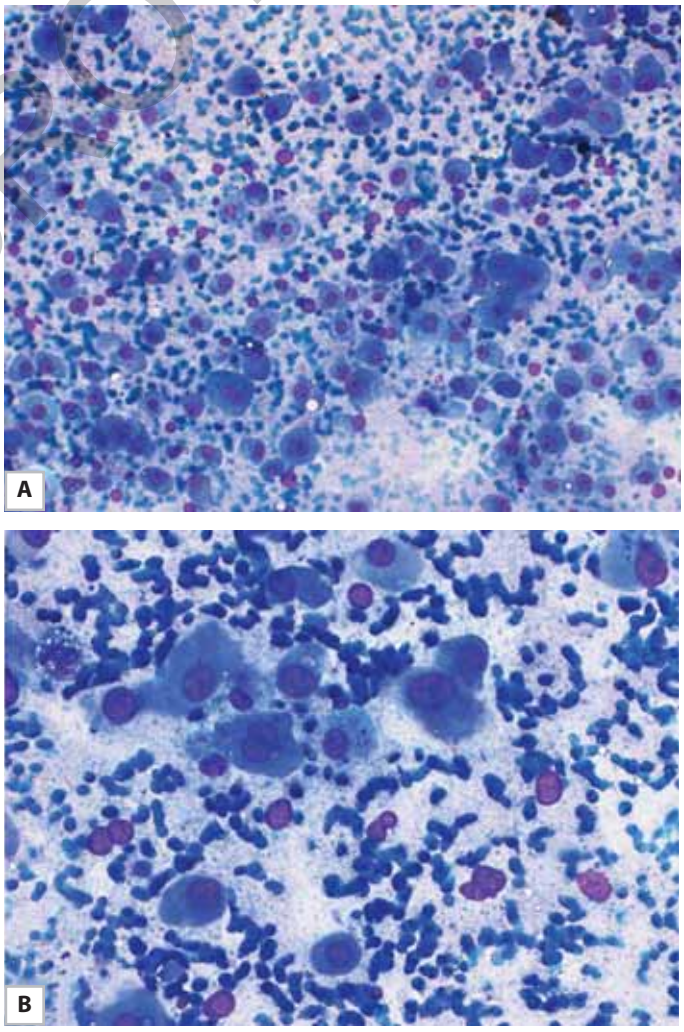

FIGS. 30.12A AND B: Fibrolamellar carcinoma. (A) Abundant discrete tumor cells (MGG × LP). (B) The cells show abundant cytoplasm with centrally placed mildly pleomorphic nuclei (MGG × HP).

JAYPEE BROTHERS

Box 30.9 Immunocytochemical markers of HCC.

Alpha-fetoprotein
- Cytoplasmic positivity
- Neoplastic hepatocytes
- Low sensitivity, good specificity
- Confirmation of HCC

Hepatocyte (HepPar1)
- A hepatocyte mitochondrial epitope
- Cytoplasmic granular positivity
- High sensitivity (100%) in well-differentiated HCC
- 90% specific for HCC
- Distinguishes HCC from cholangiocarcinoma and metastatic adenocarcinoma

Glypican-3
- Sulfate proteoglycan on cell membrane
- Very high sensitivity and specificity
- Only malignant hepatocytes are positive

p-CEA
- Stains bile canaliculi and bile duct epithelium
- Low sensitivity and high specificity
- Distinguishes HCC from metastatic adenocarcinoma

Immunocytochemistry and Serological Markers of HCC (Box 30.9)

Immunocytochemistry or serological markers are helpful for confirmation of the primary malignancy in the liver or the histogenetic origin of the tumor.

Alpha Fetoprotein

This is one of the commonly used markers for the diagnosis of HCC. This protein is secreted by the neoplastic liver cells, and the normal hepatocytes do not express AFP. The sensitivity of this marker is near about 50%.[16] The specificity of AFP is relatively high. However, the raised AFP level may be noted in malignancies other than HCC, such as gastric adenocarcinoma and large cell neuroendocrine carcinoma.[17] There is a growing tendency to drop this marker from the diagnostic panel of HCC.

Hepatocyte (HepPar1)

Human hepatocyte antibody (HepPar 1) recognizes a hepatocyte mitochondrial epitope. It shows cytoplasmic granular positivity. HepPar1 is relatively sensitive, specific, and very helpful in detecting HCC, especially the well-differentiated HCC.[18,19] Unfortunately, its sensitivity drops remarkably in poorly differentiated HCC. HepPar1 staining may also be seen in tumors other than HCC, such as gastric, pulmonary, colon, breast, and pancreatic adenocarcinoma.[16]

Polyclonal Carcinoembryonic Antigen (p-CEA)

The presence of intercellular canaliculi is one of the important diagnostic features of HCC. p-CEA stains bile canaliculi and duct but not the hepatocytes. In well-differentiated HCC, this can be demonstrated as a long linear pattern, whereas in poorly differentiated HCC, it is thick and short.

CD10

This is expressed in normal and neoplastic liver cells and therefore helps in differentiation HCC from metastatic carcinoma. It shows a similar canalicular pattern to p-CEA.

Glypican-3

This is a member of the sulfate proteoglycans family. The *glypican-3* gene is located on xq26.1. *Glypican-3* is expressed in the cell membrane and plays an essential role in cell growth, migration, and differentiation. Immunocytochemistry displays cytoplasmic reaction with membranous accentuation. It is a highly sensitive and specific marker of HCC and is more useful than HepPar 1 in detecting poorly differentiated HCC. *Glypican-3* is especially useful in detecting mass lesions of HCC from other benign and premalignant liver nodules such as liver cell adenoma, dysplastic nodules, and focal nodular hyperplasia nodules.

Differential Diagnosis

- Reactive hepatocytes
- Adenocarcinoma
- Liver cell adenoma.

Cholangiocarcinoma

This is far less common than HCC. The tumor arises from the bile duct epithelium, intrahepatic bile ducts, or extrahepatic biliary tree. Cholangiocarcinoma is often associated with clonorchis sinensis infestation, hemochromatosis, thorotrast injection, and chronic ulcerative colitis.[20] The patients usually present with weakness, malaise, and obstructive jaundice.

Cytology (Figs. 30.13A and B)

FNAC smear shows small clusters and microglandular arrangement of cells. The individual cells are cuboidal to columnar with scanty cytoplasm and resemble atypical bile duct epithelial cells (**Box 30.10**). Nuclei are mildly enlarged with prominent nucleoli. Occasional cells show vacuoles in the cytoplasm. On FNAC smear, cholangiocarcinoma cannot be distinguished from metastatic pancreatic adenocarcinoma. The cells of cholangiocarcinoma are positive for CK 7, CK 17, CK19, EMA, and diffusely positive for p-CEA. In contrast, HCC cells are positive for CK 8 and CK18.[21] Cholangiocarcinoma is characteristically positive for both CK 7 and CK 19.

Differential Diagnosis

- Metastatic adenocarcinoma
- *HCC:* Small ovoid cells with clean background in cholangiocarcinoma distinguish it from HCC that shows polygonal cells with many bare nuclei. HCC cells are CK 8 and CK 18 positive and negative for CK 7, CK 17, CK 19.

JAYPEE BROTHERS

for detailed information on pathology books, visit our website www.jaypeebrothers.com, for detailed information on pathology books, visit our website www.jaypeebroth

Diagnostic Cytology

Salient Features

- The book describes the general cytology, exfoliative cytology, laboratory techniques, and fine-needle aspiration cytology.
- The main asset of the book is the demonstration of different cytological techniques in a video format.
- A simple, concise, illustrative book with a large number of tables, boxes, line arts, and microphotographs.
- The molecular pathology and immunocytochemistry of various tumors are described.
- All the updated classification of the World Health Organization and International Academy of Cytologists are included.
- The digital pathology, whole-slide scanning and artificial neural network, polymerase chain reaction, and next-generation sequencing are described in detail

Pranab Dey MBBS MD MIAC FRCPath is working as a Professor of Cytology for more than 30 years. He has vast experience in research and teaching in cytology and gynecologic pathology and has more than 400 research publications in various international journals. He is considered as one of the top 2% scientists in the world. He is the author of a total of 12 books in the fields of cytology and histopathology and is considered as the leading author in the book on Pathology by the international review committee.

Printed in India

Available at all medical bookstores
or buy online at www.jaypeebrothers.com



JAYPEE BROTHERS
Medical Publishers (P) Ltd.
EMCA House, 23/23-B, Ansari Road,
Daryaganj, New Delhi - 110 002, INDIA
www.jaypeebrothers.com

Join us on facebook.com/JaypeeMedicalPublishers

Shelving Recommendation
PATHOLOGY

ISBN 978-93-5465-057-4

9 789354 650574