iled information on dental books, visit our website www.jaypeebrothers.com, for detailed information on dental books, visit our website www.jaypeebrothers.com







Essentials of Medicine for Dental Students

FOURTH EDITION

Anil K Tripathi
Kamal K Sawlani

JAYPEE

Contents

CHAPTER 1 Clinical Methods 1

- History 1
- Physical Examination 3
- Scheme of the General Examination 13
- Frequently Used Terms 13

CHAPTER 2 Gastrointestinal System 16

- Symptoms and Signs of Gastrointestinal Diseases 16
- Stomatitis and Oral Ulcers 21
- Gingival Hyperplasia 23
- Dysphagia 23
- Gastritis 25
- Peptic Ulcer 26
- Diarrhea, Dysentery and Food Poisoning 28
- Malabsorption 31
- Implications on Dental Practice 33

CHAPTER 3 Hepatobiliary System 35

- Liver: Structure and Function 35
- Jaundice 37
- Acute Hepatitis 39
- Acute Viral Hepatitis 39
- Chronic Hepatitis 43
- Cirrhosis of Liver 47
- Portal Hypertension 48
- Upper Gastrointestinal Bleeding 49
- Hepatic Encephalopathy 49
- Ascites 51
- Hepatomegaly 52
- Splenomegaly 53
- Implications on Dental Practice 53

CHAPTER 4 Hematological System 55

- Anemia 55
- Iron Deficiency Anemia 57
- Megaloblastic Anemia 59
- Aplastic Anemia 61
- Hemolytic Anemia 62
- Anemia of Acute Blood Loss 64
- Leukemia 64
- Acute Leukemias 64
- Lymphomas 70
- Multiple Myeloma 73
- Normal Hemostasis 74
- Platelet Disorders 76
- Von Willebrand Disease 78
- Coagulation Disorders 78
- Splenomegaly 81
- Lymphadenopathy 82
- Implications on Dental Practice 83

CHAPTER 5 Cardiovascular System **86**

- Symptoms and Signs of Cardiovascular Diseases 86
- General Examination 87
- Cardiac Examination 90
- Investigations 90
- Acute Rheumatic Fever 91
- Rheumatic Valvular Heart Disease 92
- Aortic Stenosis (AS) 95
- Aortic Regurgitation (AR) 96
- Infective Endocarditis 97
- Hypertension 100
- Ischemic Heart Disease/Coronary Artery Disease 108
- Stable Angina 109
- Unstable Angina 110
- Acute Myocardial Infarction or STEMI 112
- Heart Failure 114
- Acute Pulmonary Edema (Cardiogenic) 119
- Congenital Heart Disease 120
- Syncope 122
- Arrhythmia 124
- Bradyarrhythmias 124
- Tachyarrhythmias 127
- Implications on Dental Practice 130

CHAPTER 6 Respiratory Diseases **133**

- Symptoms 133
- Examination 135
- Investigations 137
- Pneumonia 138
- Lung Abscess 141
- Bronchiectasis 142
- Bronchial Asthma 143
- Chronic Obstructive Pulmonary Disease 147
- Cor Pulmonale 151
- Pulmonary Eosinophilia 152
- Pulmonary Embolism 153
- Tuberculosis 156
- Respiratory Failure 163
- Pleural Diseases 164
- Pneumothorax 165
- Interstitial Lung Disease 167
- Lung Cancers (Bronchogenic Carcinoma) 168
- Swine Influenza A (H1N1)—"Swine Flu" 171
- Implications on Dental Practice 171

CHAPTER 7 Renal Diseases **175**

- Structure and Functions of Normal Kidneys 175
- Syndromes in Nephrology 175
- Investigations In Renal Disease 176
- Nephrotic Syndrome 176
- Acute and Rapidly Progressive Glomerulonephritides 180
- Acute Kidney Injury 181
- Chronic Kidney Disease 184
- Renal Replacement Therapy 186
- Implications on Dental Practice 186

CHAPTER 8 Nervous System **188**

- Examination of Cranial Nerves 188
- Examination of a Comatose Patient 194
- Epilepsy 196
- Meningitis 200
- Headache 204
- Facial Pain 207

- Facial Nerve Palsy 209
- Cerebrovascular Diseases 211
- Implications on Dental Practice 212

CHAPTER 9 Endocrine and Metabolic Disorders 215

- Thyroid Disorders 215
- Calcium Metabolism 219
- Parathyroid Disorders 221
- Pituitary Gland 222
- Diabetes Mellitus 227
- Implications on Dental Practice 237

CHAPTER 10 Infections 240

- Measles (Rubeola) 240
- Mumps 241
- Rubella (German Measles) 242
- Chickenpox (Varicella) and Herpes Zoster (Shingles) 243
- Herpes Simplex 245
- Infectious Mononucleosis 247
- Diphtheria 249
- Enteric Fever (Typhoid Fever) 250
- Gonorrhea 251
- Syphilis 252
- Amebiasis 255
- Malaria 256
- Human Immunodeficiency Syndrome (HIV)/Acquired Immunodeficiency Syndrome (AIDS) 259
- COVID-19 268
- Implications on Dental Practice 271

CHAPTER 11 Medical Emergencies in Dental Practice 274

- Postural Hypotension (Orthostatic Hypotension) 275
- Syncope 275
- Hypertensive Crisis 276
- Acute Pulmonary Edema 276
- Chest Pain 277
- Asthmatic Attack 277
- Airways Obstruction 278
- Hyperventilation 278
- Seizures 278
- Stroke (Cerebrovascular Accident) 279
- Anaphylaxis 280
- Hypoglycemia 280
- Adrenal Crisis 281
- Excessive Bleeding 281
- Dental Procedures in Pregnant Women 281
- Cardiopulmonary Resuscitation 281

CHAPTER 12 Critical Care 283

- Shock 283
- Acute Respiratory Distress Syndrome 288
- Cardiovascular Collapse 289
- Cardiac Arrest 290
- Cardiopulmonary Resuscitation 290

CHAPTER 13 Anaphylaxis and Drug Allergy 293

- Anaphylaxis 293
- Drug Allergy 295
- Implications on Dental Practice 297

CHAPTER 14 Nutrition 298

- Diet and Nutrition 298
- Protein Energy Malnutrition 299
- Obesity 300
- Vitamins 301
- Implications on Dental Practice 308

CHAPTER 15 Preoperative Evaluation **310**

- Medical History 310
- Physical Examination 311
- Airway Examination 311
- Modified Mallampati Classification 311
- Preoperative Laboratory Tests 312
- Risk Assessment 312

Test Paper *315*

Answers *322*

Reference Laboratory Values *326*

Index *329*

CHAPTER 2

Gastrointestinal System

SYMPTOMS AND SIGNS OF GASTROINTESTINAL DISEASES

The gastrointestinal (GI) system extends from the mouth to the anus. The symptoms arising from GI tract diseases are complex and varied. Some important symptoms are:

- Abdominal pain
- Nausea and vomiting
- Heart burn
- Altered bowel habits (diarrhea, constipation)
- Abdominal distension
- Bleeding (hematemesis and melena)
- Dysphagia (difficulty in swallowing)
- Odynophagia (painful swallowing)
- Loss of appetite.

Symptoms

Abdominal Pain

Causes of abdominal pain are given in **Table 2.1**. Some important causes of abdominal pain are:

- Appendicitis
- Gallstones
- Liver abscess
- Pancreatitis
- Peptic ulcer
- Intestinal obstruction
- Renal stones
- Gynecological diseases.

The extra-abdominal diseases like myocardial infarction, pneumonia, herpes zoster and spinal diseases may present with abdominal pain.

The points to be noted in relation to the abdominal pain are site, nature, severity, radiation, time of onset, aggravating and relieving factors.

Table 2.1: Causes of abdominal pain.

Local causes:
- Appendicitis
- Perforation of appendix
- Gallstones
- Cholecystitis
- Peptic ulcer
- Perforation of ulcer
- Pancreatitis
- Intestinal obstruction
- Ureteric obstruction
- Pyelonephritis
- Mesenteric ischemia
- Pelvic inflammatory disease
- Cystitis
- Liver abscess
- Hepatitis
- Splenic infarction

Referred pain:
- Acute myocardial infarction
- Lower lobe pneumonia
- Empyema
- Pleurodynia
- Pneumothorax
- Testicular torsion

Miscellaneous:
- Diabetic ketoacidosis
- Porphyria
- Herpes zoster
- Spinal cord or nerve root compression
- Lead poisoning
- Angioneurotic edema
- Functional/psychiatric disorder

Site: The pain may be localized or generalized. Localized pain in epigastrium may be due to peptic ulcer disease, acute pancreatitis while right hypochondrial pain occurs in liver and gallbladder diseases like hepatitis and cholecystitis **(Table 2.2)**.

JAYPEE BROTHERS

Table 2.2: Causes of localized abdominal pain.

Site of pain	Diseases
Epigastrium	Peptic ulcer, acute pancreatitis, gastritis, GERD
Right hypochondrium	Hepatitis, cholecystitis, liver abscess, subdiaphragmatic abscess
Right lower quadrant	Appendicitis, tubo-ovarian disease, inguinal hernia, ectopic pregnancy, renal stone
Left lower quadrant	Diverticulitis, tubo-ovarian disease, inguinal hernia, ectopic pregnancy, renal stone
Periumbilical	Bowel obstruction, early appendicitis
Hypogastrium	Cystitis

Generalized abdominal pain is found in gastroenteritis, bowel obstruction, mesenteric ischemia, metabolic diseases (diabetes, porphyria), and peritonitis.

Nature: The nature could be colicky or a diffuse dull ache. Colicky pain is spasmodic in nature with episodes of pain lasting for a few seconds or even up to minutes intervening with pain free periods. This is typical of bowel obstruction, ureteric obstruction or bile duct obstruction. Diffuse severe abdominal pain is found in peritonitis.

Radiation: The pain due to ureteric stone starts in lumbar region and radiates to groin. In acute pancreatitis, pain may radiate to the back. Diseases of right hypochondrial region may cause radiation of pain to right shoulder.

Relieving and aggravating factors: Pain of gastric ulcer increases after meals while early morning pain is present in duodenal ulcer. Pain of peptic ulcer disease is relieved on taking antacids. Pain due to peritonitis increases on abdominal movements, palpation, coughing and sneezing. The patient with peritonitis prefers to lie quietly in bed.

Nausea and Vomiting

Nausea is a feeling of need to vomit. Nausea and vomiting due to gastrointestinal causes are generally associated with abdominal pain. Vomiting and nausea may also be due to causes such as pregnancy, medications, toxins, infections, central nervous system disorders and motion sickness **(Table 2.3)**.

Table 2.3: Causes of nausea and vomiting.

Abdominal causes	Extra-abdominal causes
• Intestinal obstruction • Pyloric obstructions • Gastroenteritis • Gastroesophageal reflux • Gastroparesis • Cholecystitis • Pancreatitis • Hepatitis • Appendicitis • Biliary colic • Ureteric colic • Abdominal irradiation	• Motion sickness • Labyrinthitis • Myocardial infarction • Increased intracranial pressure • Psychiatric illnesses • Drugs • Pregnancy • Uremia • Ketoacidosis

Heart Burn

Heart burn is the burning pain in the epigastrium, chest and neck due to the reflux of acid into the esophagus. There may be sour eructation or a bitter taste in the mouth. The pain can be confused with angina. Heart burn occurs more frequently when the patient lies flat in bed or bends forward.

Altered Bowel Habits

Altered bowel habits include constipation and diarrhea.

- Constipation is referred by patients as incomplete evacuation of stool, passage of hard stools, defecation with straining, or infrequent defecation (less than 3 times a week). The common causes of constipation are intestinal obstruction, medications, motility disorders and hypothyroidism **(Table 2.4)**
- Passage of unformed and liquid stools and/or increased frequency of stools is called diarrhea. Acute diarrhea generally occurs due to infections. Chronic diarrhea (of more than 4 weeks) raises the possibility of inflammatory bowel diseases and malabsorption.

Abdominal Distension

- Generalized distension of the abdomen may occur due to fat, fluid, flatus, feces or fetus **(Fig. 2.1)**. Flatulence (excessive wind) usually represents functional bowel disease where large amount of air is swallowed. Certain foods may also produce flatulence.
- Localized distension may result from organ enlargement (liver, spleen, kidneys and ovary) or small bowel obstruction **(Fig. 2.2)**.

GI Bleeding

Bleeding may occur in the upper or lower gastrointestinal tracts.

- Upper GI bleeding (bleeding from esophagus, stomach and duodenum) commonly presents with hematemesis or melena. *Hematemesis* is vomiting of blood or "coffee grounds" material while *melena* is foul smelling, black

Table 2.4: Causes of constipation.

- Painful hemorrhoids
- Anal fissure
- Colonic obstruction
- Irritable bowel syndrome
- Drugs (calcium channel blockers, antidepressants, opiates, iron, anticholinergic)
- Hypercalcemia
- Hypothyroidism
- Diabetes
- Pregnancy
- Parkinsonism
- Spinal cord injury
- Depression
- Low fiber intake
- Low fluid intake

JAYPEE BROTHERS



Fig. 2.1: Massive ascites with umbilical hernia.



Fig. 2.2: Localized abdominal distension due to splenomegaly.

tarry stools. Melena indicates that blood has remained in GI tract for some time (at least 14 hours). Common causes of upper GI bleeding are peptic ulcer, variceal rupture **(Fig. 2.3)**, erosive gastritis, gastric neoplasm and Mallory-Weiss tear **(Table 2.5)**.



Fig. 2.3: Endoscopic view of esophageal varices.

Table 2.5: Causes of GI bleeding.

Causes of upper GI bleeding	Causes of lower GI bleeding
• Peptic ulcer • Esophageal varices • Gastroduodenal erosions • Neoplasms • Mallory-Weiss tears • Vascular ectasia	• Hemorrhoids • Anal fissure • Diverticula • Neoplasm • Colitis • Inflammatory bowel disease • Ischemia of colon • Radiation

- Passage of bright red blood in stool (*hematochezia*) indicates lower GI bleeding (small intestine and colon), arising below the ligament of Treitz. Common causes of lower GI bleeding are hemorrhoids, anal fissures, neoplasms, diverticula, inflammatory bowel diseases, infections and ischemia of the colon **(Figs. 2.4A and B)**. Massive upper GI bleeding may present as *hematochezia* if blood does not remain in the bowel for long time.
- Occult GI bleeding refers to bleeding that is not visible but can be identified by a positive fecal occult blood test. Chronic blood loss of < 100 mL/day may not cause any

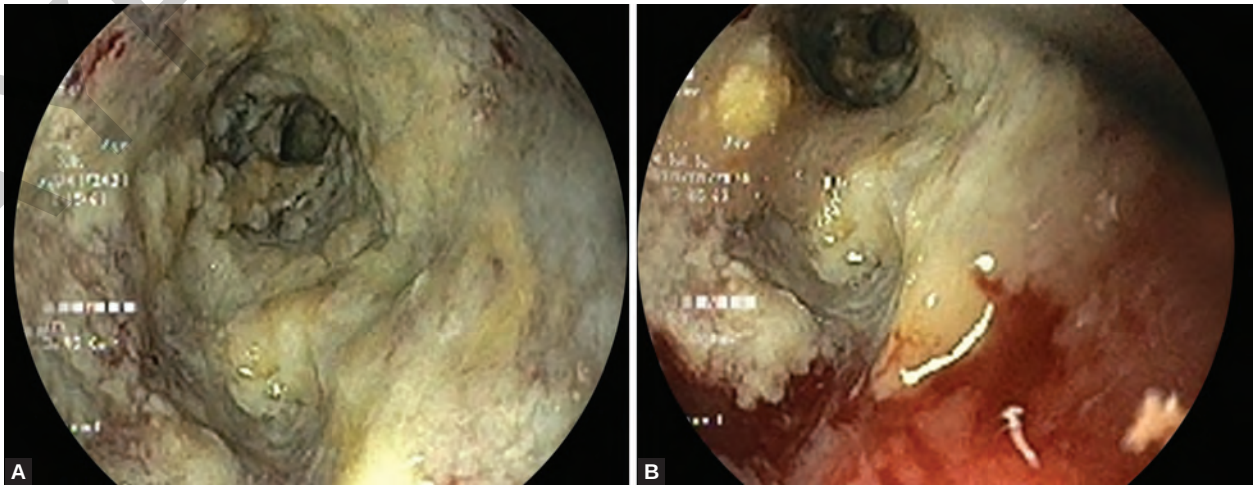

Figs. 2.4A and B: Endoscopic view of carcinoma rectum.

JAYPEE BROTHERS

change in appearance of stools although it may present as iron deficiency anemia.

Dysphagia

Difficulty in swallowing may occur due to problem in oropharynx (oropharyngeal dysphagia) or in the esophagus (esophageal dysphagia).

Odynophagia

Odynophagia is a painful swallowing that may limit oral intake. It usually occurs in erosive disease of oropharynx or esophagus. Common causes are esophagitis due to candida, herpes virus and CMV. Corrosive injury and drug induced ulcers may also cause odynophagia.

Other Symptoms

- *Hiccups* can arise due to distension or irritation of the upper GI tract. However, they may also occur because of non-GI causes.
- *Weight loss, anorexia and fatigue* are non-specific manifestations and can be seen in malignancy, malabsorption, inflammatory and psychiatric conditions.
- *Dyspepsia* generally refers to symptoms of upper abdominal discomfort, bloating, belching, burning, fullness, early satiety, nausea and vomiting. This is usually benign and occurs due to overeating, high fat diet, alcohol, coffee and medicines. Dyspepsia may be the symptom of peptic ulcer or gastric cancer. Functional or non-ulcer dyspepsia is the most common cause of chronic dyspepsia. In this condition no obvious organic cause is found.

General Examination

Certain features in general examination are important and should be recorded **(Table 2.6)**.

One should look for the presence of jaundice, signs of chronic liver disease (spider nevi, palmer erythema, gynecomastia, testicular atrophy, parotid swelling), clubbing (seen in inflammatory bowel disease, cirrhosis), edema, anasarca and anemia. Scratch marks (pruritus) may suggest cholestasis. Assessment of nutritional status particularly about weight loss is an important in chronic malabsorption, chronic liver disease, malignancies and severe protein loss.

Left supraclavicular lymph node (Virchow node) and umbilical nodule (Sister Mary Joseph nodule) may be present in cases of metastatic gastric adenocarcinoma

Careful examination of lips, teeth, gums, tongue and buccal mucosa is performed for the presence of glossitis, bald tongue, ulcers, cheilitis and angular stomatitis.

Table 2.6: Important clinical features on general examination.

Diseases	Features on examination
Chronic liver disease (CLD)	Spider nevi, palmer erythema, gynecomastia, parotid swelling, testicular atrophy
Inflammatory bowel disease	Clubbing
Obstructive jaundice	Scratch marks
Iron and vitamin deficiency	Angular stomatitis, oral ulcers
Malignancy, malabsorption, CLD	Cachexia
Gastric carcinoma	Virchow node (Left supraclavicular lymphadenopathy) Abdominal nodule (Sister Mary Joseph nodule)

Abdominal Examination

The examination of the abdomen should be performed in a systemic manner. This includes inspection, palpation, percussion and auscultation. Procedure should be clearly explained to the patient.

Inspection

The patient should be supine and the abdomen should be adequately exposed. The inspection should be performed under proper lighting conditions. Following points should particularly be noted;

- *Shape of the abdomen:* The abdomen may be distended or sunken (scaphoid). The generalized distension of the abdomen may occur due to fat, fluid, flatus, feces or fetus. Localized distension could be due to organ enlargement or small bowel obstruction. Sunken abdomen is seen in starvation and malignancy.
- *Umbilicus:* Umbilicus is everted and horizontal in ascites. Umbilical hernia may occur in massive ascites **(Fig. 2.1)**.
- *Movements of the abdominal wall:* Movements of abdominal wall are absent in peritonitis. Visible pulsations can be seen normally in thin persons or can also be due to aortic aneurysms. Visible peristalsis may be present in gastric outlet obstruction and small bowel obstruction.
- *Prominent veins:* Prominent superficial veins may be present in inferior vena cava obstruction **(Fig. 2.5)** or portal hypertension (caput medusae).



Fig. 2.5: Prominent veins over abdomen.

JAYPEE BROTHERS

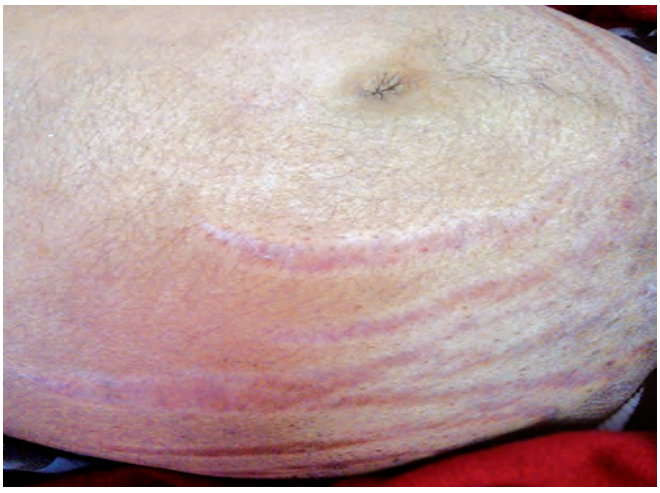

Fig. 2.6: Purple striae.

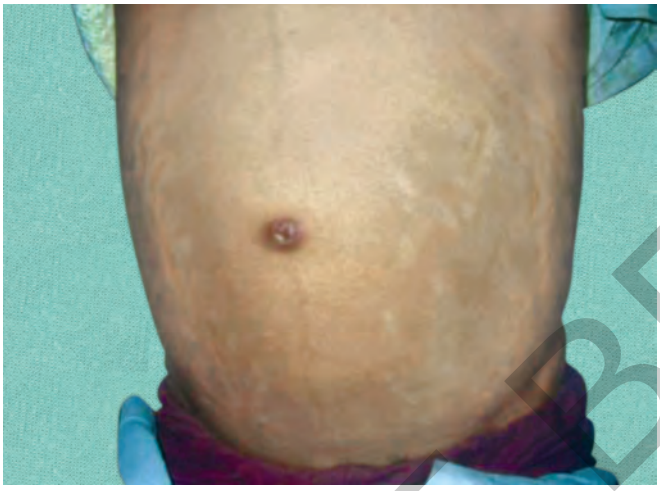

Fig. 2.7: Abdominal stria in a patient with ascites.

- *Skin:* Skin over the abdomen is shiny and smooth in marked distension. Purple striae are seen in Cushing's syndrome **(Fig 2.6)**. Striae atrophica or gravidorum are pink or white linear marks produced by gross stretching of abdomen as in ascites and pregnancy **(Fig. 2.7)**.
- *Inspection* of groin, genitalia and hernial sites should also be done.

Palpation

- The patient is asked to bend the knees to relax abdominal muscles and to breathe deeply.
- The palpation begins anti-clockwise from left iliac fossa.
- The palpation should be gently performed with warm hands. Initially superficial palpation is done to find out tender areas, which are to be examined in the end.
  - Organs such as liver, spleen, kidneys, ovaries, uterus and urinary bladder are palpated to detect any enlargement. Further details about the enlarged organs like size, surface, borders, consistency, and tenderness are noted.

Features of enlarged liver:

» Enlarged liver is palpable in the right hypochondrium **(Fig. 2.8)**.
» It moves with respiration.
» Fingers cannot be insinuated between the costal margin and the lump.
» The upper border of the liver should also be demarcated by percussion in order to assess the size (see hepatomegaly in Chapter 3).

Features of enlarged spleen:

» Enlarged spleen is palpable in the left hypochondrium **(Fig. 2.9)**.
» It moves with respiration
» Fingers cannot be insinuated between the costal margin and the lump.
» A notch is felt at the medial border of the spleen.
» This is not palpable bimanually.

Features of enlarged kidney:

» Enlarged kidney may be palpable in lumbar region
» This is bimanually palpable.
» Colonic band of resonance is present anterior to the kidney lump.



Fig. 2.8: Palpation of the liver.



Fig. 2.9: Palpation of the spleen.

JAYPEE BROTHERS



Fig. 2.10: Method to elicit fluid thrill.

  - » Kidney lump is ballotable (it can be pushed from the one hand to the other).
- Any area showing tenderness or rigidity should be noted. *Murphy's sign* may be present in acute cholecystitis, which is tenderness in right upper quadrant with arrest of inspiration due to pain.
- *Fluid thrill* detects the presence of free fluid in the abdomen (ascites). An assistant is asked to put the side of hand in the midline of the abdomen. Examiner places one hand flat in the lumbar region of one side and taps the opposite lumbar region with other hand. A wave or thrill is felt by the hand held flat in the other lumbar region **(Fig. 2.10)**. The assistant's hand does not allow the transmission of impulse through the abdominal wall. Fluid thrill is a sign of tense and massive ascites.

Percussion

The normal note of the abdominal percussion is tympanitic (resonant). Percussion is useful in confirming the enlargement of liver and spleen and detecting fluid in the peritoneal cavity (ascites).

Shifting dullness: Shifting dullness is a sign of moderate ascites and may be absent when the ascites is tense. Percussion is performed in supine patient from the midline of the abdomen toward the flank till dullness is detected **(Figs. 2.11A and B)**. Keeping the hand on the abdomen in the same position (at the point of dullness), patient is rolled laterally to the opposite side. Percussion is repeated after a minute from flank toward the umbilicus. In case of fluid (as in ascites), the previously dull point at flank becomes resonant because of shifting of fluid towards the umbilicus. To confirm, the test is repeated on the other side of the abdomen.

Auscultation

The bowel sound is exaggerated in small bowel obstruction. These may be absent in paralytic ileus. Vascular bruit may be heard in case of stenosis or aneurysm of the vessels.

STOMATITIS AND ORAL ULCERS

The inflammation of oral mucosa is called *stomatitis*. This can lead to disruption of mucosa leading to ulcers **(Fig. 2.12)**. Important causes of stomatitis/oral ulcers are given in **Table 2.7**.

Recurrent aphthous ulcers and herpes simplex ulcers are among the commonest causes of oral ulcers.

Angular Stomatitis (Cheilosis)

Cheilosis is characterized by the presence of cracks or fissures at the corners of the mouth. Important causes are:

- Ill fitting dentures (in elderly)
- Severe iron deficiency
- Vitamin B complex deficiency
- Candidiasis.

Aphthous Ulcer (Ulcerative Stomatitis, Canker Sore)

- Ulcerative stomatitis is a common condition.

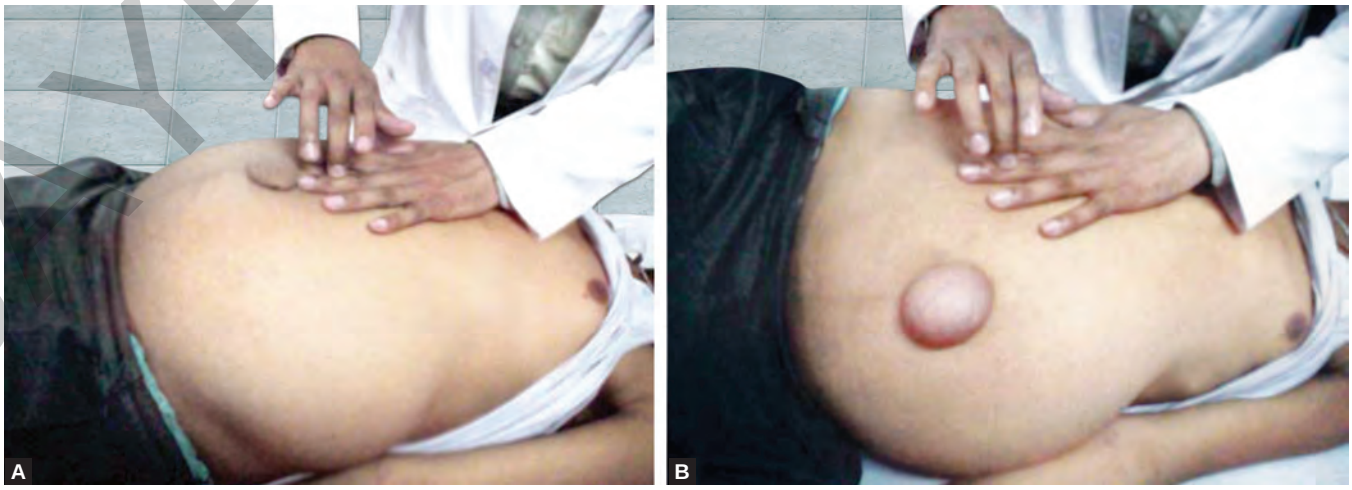

Figs. 2.11A and B: Method to elicit shifting dullness: (A) Supine position and (B) Lateral position.

JAYPEE BROTHERS

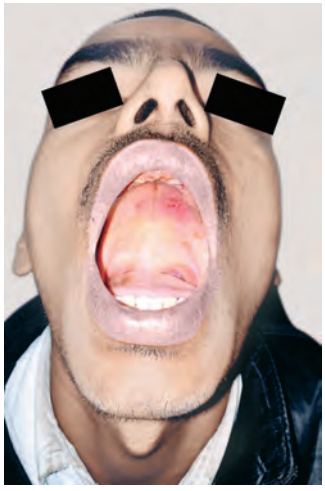

Fig. 2.12: Oral ulcer.

Table 2.7: Causes of oral ulcers.

Aphthous ulcer (ulcerative stomatitis)
Infections: • Viral (Herpes, CMV, EBV, HIV) • Fungal (Candida) • Bacterial (Vincent's infection, syphilis)
Dermatological: • Pemphigus, pemphigoid, lichen planus
Drugs: • Chemotherapy drugs • Erythema multiforme, Stevens-Johnson syndrome
Systemic diseases: • Behçet's syndrome, SLE
Nutritional: • Vitamin deficiency (Vitamin B and C), iron deficiency
Neoplasia: • Squamous cell carcinoma, leukemia, Kaposi's sarcoma
Gastrointestinal: • Crohn's disease, celiac disease
Traumatic: • Dentures
Chemical or thermal burns: • Corrosives, hot liquids

- Etiology is unknown (idiopathic), however, human herpes virus-6 has been associated with this condition. Stress is an important predisposing factor.
- Aphthous ulcers are recurrent single or multiple, superficial painful lesions with central yellow gray slough surrounded by erythematous borders.
- These involve non-keratinized oral mucosa such as buccal mucosa, labial mucosa, floor of the mouth, soft palate, lateral and ventral tongue.
- The painful stage lasts for 7–10 days followed by complete healing within a week.
- Size of the ulcers is generally less than 1 cm, however it can be larger. In cases with large and persistent ulcers, biopsy is needed to differentiate them from other causes such as carcinoma, erythema multiforme, herpes simplex, pemphigus, pemphigoid, Behçet's disease and inflammatory bowel disease.
- Local anesthetic gel or mouth washes give symptomatic relief. Topical steroids (triamcinolone or fluocinonide) can accelerate healing. Severe cases may need a course of oral prednisolone.

Vincent's Infection (Necrotizing Ulcerative Stomatitis, Trench Mouth)

- These are painful, sloughing deep ulcers which primarily involve gums.
- There is severe inflammation and necrosis of gingiva with bleeding.
- It may be associated with halitosis, fever and cervical lymphadenopathy.
- The causative organisms are fusiform bacilli and spirochetes.
- Malnutrition, poor oral hygiene and immunosuppression (such as AIDS, chemotherapy) predispose to this condition.
- Treatment includes debridement and hydrogen peroxide mouth wash. Antibiotic (penicillin) is helpful in acutely ill patients.

Herpetic Stomatitis

- Herpetic stomatitis or gingivostomatitis is caused by herpes simplex virus (HSV) type I and rarely by HSV type 2.
- This occurs mainly in children and young adults.
- Lesions involve lips and oral mucosa. Labial lesions are in the form of vesicles that rupture and crust **(Figs. 2.13A and B)**. Intraoral vesicles are very painful and they rapidly ulcerate.
- There may also be fever, malaise, halitosis and cervical lymphadenopathy.
- Labial lesions are common in recurrent herpes simplex (herpes labialis).
- Lesions usually heal within 10–14 days.
- Topical or oral antiviral (acyclovir, valcyclovir, famciclovir) drugs enhance healing in severe cases. Daily acyclovir may be needed to prevent recurrent herpetic lesions, particularly in immunocompromised cases.

Oral Candidiasis

Candida albicans is normal mouth commensal. It can produce thrush in babies, diabetics, patients on corticosteroids or broad spectrum antibiotics and immunosuppressed states (AIDS, cancer chemotherapy). This can involve any part of the mouth **(Fig. 2.14)**. Oral candidiasis can present in following forms:

- *Pseudomembranous type (thrush):* Creamy white curd-like patches are seen over erythematous mucosa. These

JAYPEE BROTHERS



Figs. 2.13A and B: (A) Herpes labialis; (B) Herpes labialis; crusting of lesions.



Fig. 2.14: Oral candidiasis.

can be easily scraped and reveal raw bleeding surface. Painful deglutition (odynophagia) suggests pharyngeal and esophageal involvement.

- *Erythematous type:* These are flat, red, sore areas in the oral cavity.
- *Candidal leukoplakia:* There is non-removable white thickening of mucosal epithelium due to candida.
- *Angular cheilitis:* Sore fissures at the corner of the mouth can be caused by candida.

Diagnosis: The diagnosis can be made clinically and is confirmed by the demonstration of spores and mycelia on KOH wet preparation or biopsy of the lesion.

Treatment: Clotrimazole lozenges or nystatin mouth washes are effective in oral candidiasis. Ketoconazole (200–400 mg oral daily) or fluconazole (200 mg oral daily) is given for 1–2 weeks in oroesophageal candidiasis in immunocompromised patients. Itraconazole is given in refractory cases.

Nutritional Deficiency

Swollen bleeding gums and ulcers are common in vitamin C deficiency. Deficiency of vitamin B complex (B_2, B_{12}, folic acid) can cause glossitis, oral ulceration and cheilosis. Cheilosis, glossitis and dysphagia are also found in iron deficiency cases.

Hematological Diseases

All forms of leukemia, particularly acute myelomonocytic leukemia can produce oral ulcers, gingival swelling and bleeding. Oral ulcers are also found in agranulocytosis (see in Chapter 4). Mucositis and ulcers are complications of chemotherapy and radiation therapy.

GINGIVAL HYPERPLASIA

Gingival hyperplasia is swelling or enlargement of gingiva. Apart from oro-dental causes, gingival swelling can be manifestation of systemic diseases. Hence, understanding various systemic causes of gingival hyperplasia is very important.

Gingival swelling can be:

a. Generalized
b. Localized

Important causes of generalized gingival swelling are scurvy (Vitamin C deficiency), acute myeloid leukemia and drugs (phenytoin, cyclosporine and calcium channel blockers). Causes of gingival hyperplasia are given in **Table 2.8**.

Diagnosis can be made by proper history including drug intake and the underlying features of causative disease. Hematological investigations can rule out the presence of leukemia.

Treatment includes management of underlying cause and withdrawal of offending drug.

DYSPHAGIA

Dysphagia is defined as difficulty in swallowing. Odynophagia is painful swallowing while phagophobia is fear of swallowing or refusal to swallow.

Classification

Dysphagia is divided into following types:

- *Oropharyngeal dysphagia:* There is problem in transferring food from mouth to the esophagus. This is associated with nasal regurgitation and pulmonary aspiration during swallowing. The causes of oropharyngeal dysphagia can be

JAYPEE BROTHERS

Table 2.8: Causes of gingival hyperplasia.

Generalized gingival hyperplasia

Acquired
- Acute myeloid leukemia (M4 and M5 type)
- Vitamin C deficiency
- Drugs: Phenytoin, cyclosporine, calcium channel blockers (nifedipine, verapamil, diltiazem, amlodipine), sodium valproate, tranexamic acid
- Wegener's disease (strawberry gums)

Congenital
- Mucopolysaccharidosis
- Primary amyloidosis
- Hereditary gingival fibromatosis

Localized gingival hyperplasia

Acquired
- Lymphomas
- Multiple myeloma
- Squamous cell carcinoma
- Kaposi sarcoma
- Pregnancy
- Sarcoidosis
- Wegener's disease
- Giant cell epulis (primary hyperparathyroidism)

Congenital
- Fabry's syndrome
- Tuberous sclerosis
- Sturge-Weber angiomatosis

Table 2.9: Causes of oropharyngeal dysphagia.

Mechanical
- Oropharyngeal tumors
- Post-surgical/radiation changes
- Zenker's diverticulum
- Retropharyngeal abscess/mass
- Thyroid disorders
- Plummer-Vinson syndrome
- Inflammatory lesions

Motor
- Brain injury, cerebral palsy, parkinsonism, stroke
- Rabies, tetanus
- Cranial nerve palsy, Guillain-Barre syndrome
- Myasthenia gravis, botulinum toxin
- Myositis, myopathies

subgrouped into (a) mechanical and (b) motor dysphagia. Important causes are given in **Table 2.9**.

- *Esophageal dysphagia:* Difficulty in swallowing the food down the esophagus. Patients with mechanical obstruction complain of dysphagia mainly for solids whereas those with motility disorders have dysphagia for both solids and liquids. Causes are given in **Table 2.10**. **Figures 2.15A to C** show a case of esophageal carcinoma.

Table 2.10: Causes of esophageal dysphagia.

Mechanical
- Esophageal cancer
- Peptic stricture
- Inflammatory esophagitis
- Schatzki's ring (lower esophageal mucosal ring)
- Posterior mediastinal mass
- Aortic aneurysm

Motor
- Achalasia
- Scleroderma
- Diffuse esophageal spasm

Odynophagia

Odynophagia is a painful swallowing that may limit oral intake. Important causes are infectious esophagitis due to candida, herpes, or CMV **(Fig. 2.16)**. It can also be due to corrosive injury (due to caustic ingestion) or pill-induced ulcers (pill esophagitis).

Diagnosis

Following investigations are helpful in making the diagnosis:
- Endoscopy (esophagogastroscopy)
- Video esophagography
- Barium esophagography
- Esophageal manometry
- Esophageal pH recording
- Imaging studies (CT scan)
- Specific tests to rule out neuromuscular disorders.

Treatment

General

- Modification of diet
- Enteral feeding through a gastrostomy tube

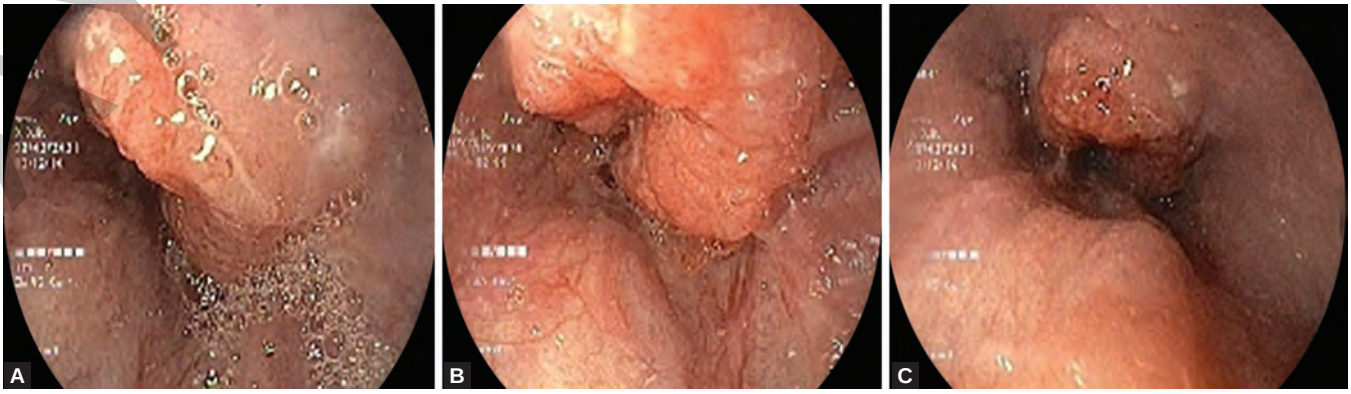

Figs. 2.15A to C: Carcinoma esophagus.

JAYPEE BROTHERS



Fig. 2.16: Endoscopic view of esophageal candidiasis.



Fig. 2.17: Multiple gastric erosions.

- Endoscopic removal of obstructing food bolus in acute dysphagia
- Nutrition counseling.

Medical

- Proton pump inhibitors (for mucosal inflammation in reflux disease)
- Antimicrobial agents (infectious esophagitis)
- Viscous lidocaine solution for symptomatic relief
- Anticholinergic medications in cases with drooling of saliva and oropharyngeal dysphagia.

Endoscopic Therapy

- Esophageal dilatation
- Esophageal stent placement
- Pneumatic dilatation of lower esophageal sphincter (LES) for achalasia.
- Botulinum toxin injection to LES in achalasia.

Surgical

Laparoscopic myotomy in achalasia.

GASTRITIS

Gastritis is a histological diagnosis characterized by inflammation of the gastric mucosa.

Acute Erosive and Hemorrhagic Gastritis

Acute gastritis is usually erosive and hemorrhagic. Important causes of erosive and hemorrhagic gastritis are:

- Drugs (aspirin, NSAIDs)
- Alcohol
- Stress due to severe illness
- Congestive gastropathy due to portal hypertension.

Stress ulceration in patients with head trauma is called *Cushing's ulcer* and in severe burns,*Curling's ulcer.* Stress injury is not characterized by inflammation, thus the term 'gastritis' is a misnomer.

Erosive gastritis is usually asymptomatic. It may present with anorexia, nausea, vomiting and abdominal pain. Hematemesis and melena are most important manifestations of erosive gastritis.

Diagnosis is made by endoscopy which reveals superficial hemorrhages and erosions **(Fig. 2.17)**. Biopsy may be required to differentiate it from peptic ulcer and cancer.

Management

- The treatment of acute gastritis consists of administration of sucralfate suspension (1 g 4–6 hrly) and H_2 receptor antagonist (ranitidine 150 mg twice daily, famotidine 20 mg twice daily) or proton pump inhibitors (omeprazole 20 mg once daily, esomeprazole 40 mg once daily, rabeprazole 20 mg once daily, pantoprazole 40 mg once daily, lansoprazole 30 mg once daily, dexlansoprazole 30 mg once daily).
- The consumption of alcohol and drugs [Non-steroidal anti-inflammatory drugs (NSAIDs)] should be avoided.
- Stress gastritis can be prevented by the administration of sucralfate, H_2 receptor antagonist or proton pump inhibitor in critically ill patients.

Acute Gastritis Due to Infections

A variety of infections can lead to acute inflammatory changes in the gastric mucosa. This presents as sudden onset of epigastric pain, nausea and vomiting.

H. pylori infection can lead to acute gastritis which generally progresses to chronic gastritis.

Acute bacterial infections (aerobic and anaerobic bacteria) can lead to progressive life-threatening necrotizing gastritis (phlegmonus gastritis). The treatment includes antibiotics and emergency gastrectomy.

Herpes simplex virus, CMV and candida can cause gastritis in immunocompromized patients such as AIDS.

JAYPEE BROTHERS

Chronic Gastritis

Histologically chronic gastritis is characterized by chronic inflammation with predominant infiltration by lymphocytes and plasma cells. The early stage of chronic gastritis is superficial gastritis. This is followed by the stage of atrophic gastritis. The final stage is gastric atrophy. The subsequent development of metaplasia may be precancerous. The two main types of chronic gastritis are autoimmune gastritis and *H. pylori* related chronic gastritis.

Autoimmune Gastritis (Type A Gastritis)

- This is characterized by the involvement of fundus and body of the stomach, *sparing antrum*.
- Circulating autoantibodies are found against parietal cells and intrinsic factor.
- This type of gastritis is generally asymptomatic. However, it may be associated with vitamin B_{12} deficiency *(pernicious anemia)*.
- Features of other *autoimmune involvement* (such as thyroid disease) may be present.
- There is four-fold increase in the incidence of gastric cancer, hence follow up endoscopy is suggested.
- The treatment of pernicious anemia includes regular parenteral B_{12} supplementation.

Helicobacter pylori Gastritis (Type B Gastritis)

- *H. pylori is* the most common cause of chronic gastritis.
- The incidence of *H. pylori* gastritis increases with age.
- Initially, the antrum is predominantly involved, later pangastritis occurs.
- The majority of patients are asymptomatic with no sequelae.
- It is associated with peptic ulcer disease, with a 2–6 fold increase in the risk of *gastric adenocarcinoma* and low grade B-cell gastric lymphoma (MALT lymphoma).
- Eradication of *H. pylori* is often recommended. Regular follow up endoscopy is needed.

Patients with peptic ulcer disease and MALT (mucosa associated lymphoid tissue) lymphoma are tested and treated for *H. pylori*. Antibiotics are given to treat *H. pylori* (see peptic ulcer).

Uncommon Types of Gastritis

Other types of gastritis are granulomatous gastritis (tuberculosis, sarcoidosis, candidiasis, syphilis, Crohn's disease), eosinophilic gastritis and lymphocytic gastritis.

PEPTIC ULCER

Peptic ulcer is defined as the presence of ulcer in the lower esophagus, stomach and duodenum. The ulcer is a breach in the mucosa due to an imbalance between mucosal defensive factors and luminal factors such as acid and pepsin. A break in the mucosal surface of more than 5 mm and depth to the submucosa are characteristics of an ulcer.

Duodenal ulcer is more common than gastric ulcer and occurs at younger age group (30–55 years) as compared to gastric ulcer (55–70 years).

Etiology

The common etiological factors of peptic ulcer are:

- *H. pylori* infection
- NSAIDs (Non-steroidal anti-inflammatory drugs)
- Smoking
- Acid hypersecretory states (Zollinger-Ellison syndrome).

Multiple factors may be responsible for the ulcer in a particular patient. Whatever the cause, the common abnormality is an imbalance between mucosal defensive factors and the aggressive factors (acid, pepsin).

H. pylori Infection

H. pylori infection is a very common and important factor in the etiology of peptic ulcer. The prevalence of *H. pylori* infection is around 75% in duodenal ulcer and 30–60% in gastric ulcer. The infection leads to a state of hypergastrinemia, increased gastric acid secretion and decreased duodenal bicarbonate secretion. These factors result in patches of gastric metaplasia in the duodenal bulb. Colonization of theses patches by *H. pylori* subsequently causes inflammation and formation of duodenal ulcer. The gastric ulcer in *H. pylori* infection occurs predominantly due to reduced gastric mucosal resistance.

NSAIDs-induced Ulcers

The chronic use of NSAIDs is more commonly associated with gastric ulcer than duodenal ulcer. Users of NSAIDs are also more likely to suffer from serious ulcer-related complications. These drugs reduce prostaglandins synthesis in the gastric mucosa by inhibiting enzyme cyclooxygenase 1 (COX-1). Prostaglandins play an important role in the gastric cytoprotection and repair. Drugs which selectively inhibit COX-2 at the site of inflammation (valdecoxib, celecoxib, etoricoxib) without affecting COX-1 activity are less likely to cause gastric ulcer.

Smoking, Diet and Other Risk Factors

Smokers are more likely to develop peptic ulcers and related complications. The healing of the ulcer and response to therapy are diminished in smokers.

There is no association of any specific diet, alcohol or caffeine with the formation of ulcers, although certain foods can cause dyspepsia. Chronic obstructive lung disease, chronic kidney disease, coronary artery disease, obesity, old age and tobacco use are risk factors for development of peptic ulcer **(Table 2. 11)**.

JAYPEE BROTHERS

Table 2.11: Risk factors for peptic ulcer disease.

- *Helicobactor pylori*
- NSAIDs
- Chronic obstructive lung disease
- Chronic kidney disease
- Coronary artery disease
- Obesity
- Diabetes
- Old age
- Tobacco use

Clinical Features

- Recurrent abdominal pain is the most common symptom.
- Pain is localized to epigastrium and is burning or gnawing type. It may be dull aching, vague or described as hunger pain. Pain in duodenal ulcer is relieved by taking meals and antacids whereas pain in gastric ulcer may increase after meals. Nocturnal pain (at 3–4 am) usually indicates duodenal ulcer.
- Nausea and weight loss are commonly present in gastric ulcer.
- Physical examination may be normal or may reveal epigastric tenderness in uncomplicated peptic ulcer.

Complications of peptic ulcer are given in **Table 2.12**. Constant pain not relieved by food or antacids suggests penetration. Severe pain (acute abdomen) may occur in case of perforation of peptic ulcer. Melena or hematemesis occurs in case of bleeding. Peptic ulcer is the most common cause of upper GI bleeding.

Investigations

- Endoscopy is the investigation of choice for the diagnosis of peptic ulcer **(Figs. 2.18 and 2.19)**. Biopsy of the lesion is needed to detect malignancy and *H. pylori* infection.
- Barium studies of the upper GI tract done earlier are not generally needed as it is less sensitive to detect ulcers.
- Abdominal CT imaging may be required to detect complications of peptic ulcer disease such as perforation, penetration and gastric outlet obstruction.
- *H. pylori* infection can be diagnosed by noninvasive tests like serology, fecal antigen assay and urea breath test. Rapid urease test, histology and culture can be performed upon the biopsy sample.
- There may be anemia. Stool may be positive for occult blood. Leukocytosis suggests complications such as penetration or perforation.

Table 2.12: Complications of peptic ulcer.

- GI hemorrhages
- Perforation
- Ulcer penetration (into pancreas, liver)
- Gastric outlet obstruction



Fig. 2.18: Multiple antral ulcers.

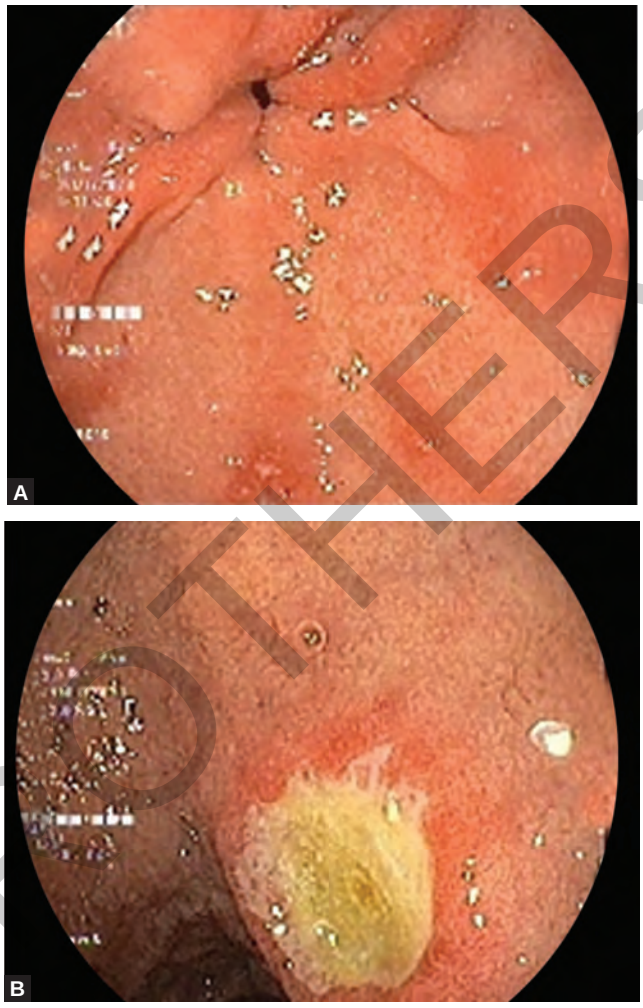

Figs. 2.19A and B: (A) Antral ulcers; (B) Duodenal ulcer.

Treatment

General Measures

- No specific dietary restriction is needed.
- Meals should be taken at regular intervals.
- Smoking or tobacco in any form should be stopped completely.
- Drugs like aspirin and NSAIDs must be avoided.

JAYPEE BROTHERS

for detailed information on dental books, visit our website www.jaypeebrothers.com, for detailed information on dental books, visit our website www.jaypeebrot

Essentials of Medicine for Dental Students

Salient Features

- The contents of he book are in accordance with the BDS curriculum as per Dental Council of India.
- The text is simple, clear, and concise and illustrated with the help of figures and tables. Many more has been added in the new edition to make the subject more comprehensible.
- The information provided is latest and is according to National/International guidelines where applicable.
- Recently introduced drugs have been mentioned in the text, particularly those in regard to diabetes mellitus, HIV, Hepatitis C, blood cancers, and tuberculosis.
- Tips are given at the end of each chapter explaining the importance and implication of knowledge in real practice.
- A section is dedicated to the ongoing Pandemic due to COVID 19.
- Multiple Choice Questions and Fill in the Blanks are given in each chapter for Self Assessment.

Anil K Tripathi MD FRCP (London) FRCP (Glasgow) FRCP (Ireland) FAMS FICP FIACM FISHTM Fellow NIH (USA) WFH Fellow (UK) is Professor and Head, Department of Clinical Hematology, King George's Medical University, Lucknow, Uttar Pradesh, India. He is Former Director, Dr RML Institute of Medical Sciences, Lucknow, and also had an additional charge of Director, Sanjay Gandhi Postgraduate Institute, Lucknow. He has been President of Indian Society of Hematology and Blood Transfusion. He has done MBBS and MD from GSVM Medical College, Kanpur and received several gold medals and prizes for having first rank. He is a thorough clinician and a renowned teacher. He has a teaching experience of more than 36 years. He is examiner for BDS, MBBS, MD, DM and PhD courses at various prestigious universities. He has extensive research experience in the field of Hematology and HIV/AIDS. He has mentored 7 PhD theses. He was Visiting Scientist at National Institutes of Health, USA and Visiting Fellow at Oxford Hemophilia Center, UK. He has received National award from Department of Science and Technology, Government of India. He has also received several prestigious oration awards and fellowships including Fellow of National Academy of Medical Sciences India, FRCP (London), FRCP (Glasgow), and FRCP (Ireland). He has been awarded Vigyan Ratna and Vigyan Gaurav awards, the highest award given by Government of Uttar Pradesh for outstanding achievements in Science and Technology. He has written 5 textbooks, 4 chapters in books and published more than 140 research papers.

Kamal K Sawlani MD FICP is Professor, Department of Medicine, King George's Medical University, Lucknow, Uttar Pradesh, India. He has done MBBS from King George's Medical College, Lucknow and MD (Medicine) from Maulana Azad Medical College, New Delhi. He has extensive teaching experience of BDS, MBBS and MD students for more than 25 years. He has many publications in national and international journals to his credit. He has written chapters in various books and updates. He is Vice President of Association of Physicians of India-UP Chapter. He has been Co-Editor of *Medicine Update 2013* and Executive Editor of *Textbook of Family Medicine 2013*. He has worked as Associate Editor of Journal of Internal Medicine of India. He has also completed postgraduate certificate course in Hospital Management from National Institute of Health and Family Welfare, New Delhi and bagged best student award. He is actively associated with various medical/academic societies.

Printed in India

Available at all medical bookstores or buy online at www.jaypeebrothers.com

JAYPEE BROTHERS
Medical Publishers (P) Ltd.
EMCA House, 23/23-B, Ansari Road,
Daryaganj, New Delhi - 110 002, INDIA
www.jaypeebrothers.com

Join us on facebook.com/JaypeeMedicalPublishers

Shelving Recommendation
DENTISTRY

ISBN 978-93-5465-126-7

9 789354 651267