nformation on obstetrics & gynecology books, visit our website www.jaypeebrothers.com, for detailed information on obstetrics & gynecology books, visit our website www.jaypeebrothers.com

Management of High-Risk Pregnancy

A Practical Approach

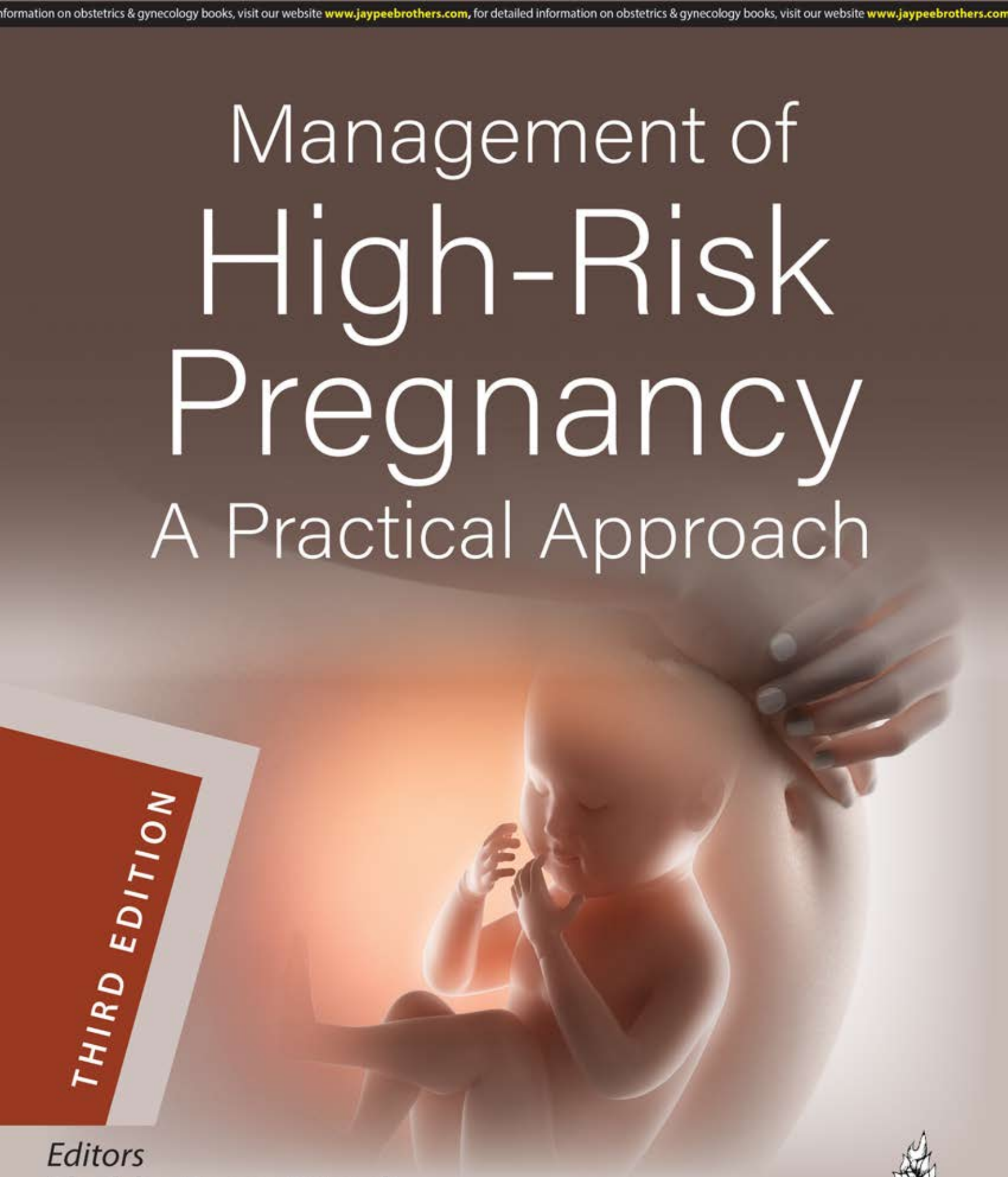

THIRD EDITION

Editors
Shubha Sagar Trivedi
Manju Puri
Swati Agrawal

Foreword
Sir Sabaratnam Arulkumaran

JAYPEE

Management of
HIGH-RISK PREGNANCY
A Practical Approach

Third Edition

Editors

Shubha Sagar Trivedi
MS FRCOG (Hon. Causa) FIMSA FICOG
Former Director Professor and Head
Department of Obstetrics and Gynecology
Lady Hardinge Medical College and Smt Sucheta Kriplani Hospital
New Delhi
Former Professor and Head, Department of Obstetrics and Gynecology
SGT University, Gurugram, Haryana, India

Manju Puri
MD FICOG
Director Professor and Former Head
Department of Obstetrics and Gynecology
Lady Hardinge Medical College and Smt Sucheta Kriplani Hospital
New Delhi, India

Swati Agrawal
MD FICOG FMAS
Professor
Department of Obstetrics and Gynecology
Lady Hardinge Medical College and Smt Sucheta Kriplani Hospital
New Delhi, India

Foreword
Sir Sabaratnam Arulkumaran

JAYPEE BROTHERS MEDICAL PUBLISHERS
The Health Sciences Publisher
New Delhi | London

JAYPEE BROTHERS

Contents

1. **High-risk Pregnancy: Before, After, and Beyond** 1
   Anju Bhatia
2. **Prenatal Diagnosis** 10
   Mandakini Pradhan, Ratna Biswas, Neeta Singh
3. **Screening and Management of Congenital Anomalies** 25
   Manisha Kumar, Shivangi Shanker Srivastava
4. **Recurrent Pregnancy Loss** 43
   Sangeeta Gupta, Shivangini Rana
5. **Antepartum Hemorrhage** 51
   Madhu Goel, Monika Bhatia, Shubha Sagar Trivedi
6. **Multifetal Pregnancy** 64
   Reena Yadav
7. **Fetal Growth Restriction** 80
   Kanwal Gujral, Sakshi Nayar
8. **Antepartum Fetal Surveillance** 90
   Anubhuti Rana, Seema Singhal
9. **Polyhydramnios Oligohydramnios** 102
   Prabha Lal
10. **Preterm Labor** 110
    Kanika Chopra, Monika Bhatia, Shubha Sagar Trivedi
11. **Premature Rupture of Membranes** 124
    Sharda Patra
12. **Prolonged Pregnancy** 136
    Amita Suneja, Sandhya Jain, Raksha Soni
13. **Rh Negative Pregnancy** 142
    Aruna Nigam, Sumedha Sharma
14. **Pregnancy in Previous Cesarean Section** 152
    Shubham Bidhuri, Ritu Rana, Saritha Shamsunder
15. **Malpresentations** 166
    Usha Gupta, Swati Agrawal
16. **Anemia in Pregnancy** 186
    Manju Puri, Nidhi Malhotra
17. **Hypertensive Disorders of Pregnancy** 202
    Swati Agrawal, Monika Bhatia, Shubha Sagar Trivedi
18. **Diabetes Mellitus in Pregnancy** 218
    Kazila Bhutia, Qiu Ju Ng, Manju Puri
19. **Thyroid Disorders in Pregnancy** 236
    Kiran Aggarwal
20. **Heart Disease in Pregnancy** 249
    Shalini Malhotra, Reva Tripathi, Monika Bhatia, Divya Verma

JAYPEE BROTHERS

21. **Jaundice in Pregnancy** 263
Chitra Raghunandan, Swati Agrawal, Manoj Kumar Sharma

22. **Renal Disease in Pregnancy** 281
Pakhee Aggarwal, Suneeta Mittal

23. **Pregnancy with Epilepsy** 290
Monika Madaan

24. **Autoimmune Disorders in Pregnancy** 297
Kiran Guleria, Bindiya Gupta, Sneha Shree

25. **Thromboembolism in Pregnancy** 306
Sarita Singh, Swaraj Batra, Reena Jain

26. **Psychiatric Disorders in Pregnancy** 318
Prerna Kukreti, Madhavi Puri

27. **Tuberculosis in Pregnancy** 329
Abha Singh, Bhawani Singh

28. **Malaria in Pregnancy** 334
Abha Singh, Bhawani Singh

29. **HIV Infection in Pregnancy** 338
Sudha Salhan

30. **TORCH Infections in Pregnancy** 347
K Aparna Sharma, Deepika Deka

31. **Obesity and Pregnancy** 356
Sirisha Rao Gundabattula

32. **Gynecological Diseases in Pregnancy** 365
Smiti Nanda, Vani Malhotra

33. **Critical Care in Obstetrics** 378
Nidhi Bhatia, Satinder Gombar, Kanti Gombar

34. **Drugs in Pregnancy** 393
Pikee Saxena, Manju Saini

Index *411*

JAYPEE BROTHERS

CHAPTER 5

Antepartum Hemorrhage

Madhu Goel, Monika Bhatia, Shubha Sagar Trivedi

INTRODUCTION

Antepartum hemorrhage (APH) continues to be one of the most serious complications of pregnancy and is an important cause of maternal and perinatal morbidity and mortality. APH is defined as bleeding from or into the genital tract after the period of viability but before the delivery of baby. As per the Royal College of Obstetricians and Gynaecologists (RCOG), bleeding from 24^{+0} weeks of pregnancy and before the birth of baby is considered APH.[1] APH occurs in about 3–5% of all pregnancies.[2]

Complete assessment and management of APH in a well-equipped hospital with facilities for resuscitation, replacement of blood and blood products, and expertise in operative delivery improve the maternal and fetal outcome. Massive and uncontrollable hemorrhage can occur in this condition; prompt and aggressive management by an experienced team can save lives.

CAUSES OF ANTEPARTUM HEMORRHAGE

Antepartum hemorrhage can occur due to a variety of causes. These could be placental, extraplacental, vasa previa or indeterminate **(Flowchart 1)**. Most common are placental causes and include placenta previa and abruptio placentae. Abruptio placentae also called accidental hemorrhage, refers to premature separation of a normally situated placenta in the upper segment of the uterus, whereas placenta previa is conventionally defined as the presence of placenta in lower uterine segment. However, the term placenta previa should be used when the placenta lies directly over the internal os. For pregnancies at more than 16 weeks of gestation, the term low-lying placenta should be used when the placental edge is less than 20 mm from the internal os on transabdominal or transvaginal scanning (TVS).[3] Extraplacental causes of APH are uncommon and include cervical or vaginal lesions such as cervical polyp, varicose veins, cervicitis, and neoplasms, especially carcinoma of the cervix. Rarely, APH is due to vasa previa where fetal vessels lie below the presenting part and blood loss in this situation is fetal. It is a rare but important cause of fetal loss in APH. In about one-third cases of APH, no definite cause is found, and these are classified as indeterminate, unexplained, or unclassified APH. Excessive show may also present as APH but can be diagnosed by the associated mucoid discharge.

Rarely bleeding from hemorrhoids or urinary tract may be confused with vaginal bleeding.

PLACENTA PREVIA

Placenta previa and low-lying placenta are important causes of APH. The incidence of placenta previa has increased because of the increasing rates of cesarean sections, increasing maternal age at conception, and increase in IVF pregnancies.

Incidence of Placenta Previa

Placenta previa occurs in about 0.3% of pregnancies.[4]

The frequency with which the zygote implants in the lower part of the uterus is much higher but many of these pregnancies end in early pregnancy losses. In many others, the placenta migrates consequent to differential growth of lower uterine segment as compared to upper and comes to lie in the upper uterine segment. The incidence of placenta previa diagnosed by TVS at 15–20 weeks was reported to

Flowchart 1: Causes of antepartum hemorrhage.

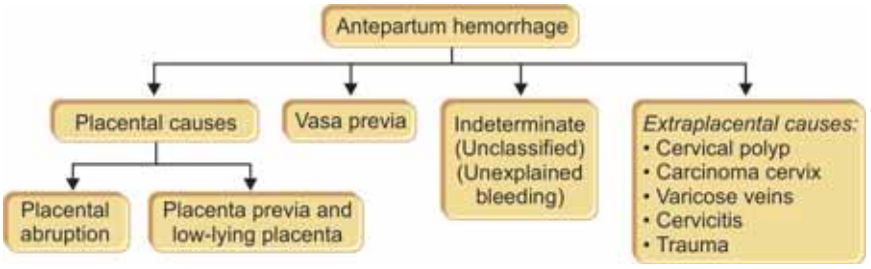

JAYPEE BROTHERS

be 1.1%; but only 14% of these persisted until delivery.[5] A recent study also reported that the majority of the placenta previa detected in second trimester no longer overlie the internal os in the third trimester. The overlying distance of the placenta, a previous cesarean delivery, and assisted reproductive technology (ART) were found to increase the risk of persistence of a placenta previa.[6]

Etiology

Various factors predisposing to placenta previa are described here.

Uterine scars and pathology: Placenta previa is found more commonly in women with previous history of cesarean section, myomectomy, endometritis, manual removal of placenta, and dilatation and curettage. Incidence of placenta previa rises with number of previous cesarean sections with resultant increase in the risk of life-threatening placenta accreta spectrum (PAS); hence the need to reduce the incidence of cesarean section and to promote vaginal delivery wherever possible. Previous cesarean delivery increases the risk of occurrence of placenta previa from 0.65% after one cesarean to 10% after four or more cesarean sections.

Multiparity: The incidence of placenta previa is much higher in parous women. An incidence of 2.2% in women with parity 5 or more has been reported.[7]

Advanced maternal age: Advanced maternal age is associated with an increased risk of placenta previa. Older nulliparous as well as older multiparous women were found to be at high odds of placenta previa (adjOR, 2.02; 95% CI, 1.68–2.44 and adjOR, 2.11; 95% CI, 1.83–2.44, respectively).[8]

Placental size: Incidence of placenta previa is higher in twin pregnancy, presumably because of large placental size.

Assisted conception: Possibly due to increase in multiple pregnancies with assisted conception.

Placental pathology: Marginal or velamentous cord insertion, succenturiate lobe, bipartite placenta, and fenestrated placenta are more commonly associated with placenta previa.

Smoking: It increases the risk of placenta previa, may be due to compensatory placental enlargement.

Previous history of placenta previa: Incidence of placenta previa is higher in a woman with previous history of placenta previa. It is 4–6% which is almost 8–12 times higher. A 4.8% recurrence rate of placenta previa has been reported in the second birth.[9]

Associated Conditions

Abnormal placentation: PAS disorders may be associated with placenta previa, especially if there is a previous cesarean scar. A recent meta-analysis concluded that cesarean delivery appeared as a consistent risk factor for placenta previa, placenta accreta, and placental abruption in subsequent pregnancy.[10]

Malpresentations: Placenta previa and low-lying placenta prevent engagement of fetal head and may predispose to malpresentation. It is often associated with high-floating head, breech presentation, oblique, or transverse lie.

Congenital anomalies: Incidence of fetal congenital anomalies is almost twice as high in women with placenta previa. The reason is not known.

Classification

Originally, placenta lying in lower uterine segment was labeled as placenta previa and was graded from 1 to 4, depending upon the distance of placental edge from internal os. More recently, a multidisciplinary workshop of American Institute of Ultrasound in Medicine has recommended that the term placenta previa should be used when the placenta lies directly over the internal os and the term low-lying placenta should be used when placental edge is less than 20 mm from the internal os on transabdominal or transvaginal sonography after 16 weeks of gestation.[11]

The term complete previa has been used in the past to describe a placenta that covers the cervical os and marginal previa when it is less than 2 cm from internal os.

Clinical Features

Placenta previa may be asymptomatic. A high head, oblique lie or transverse lie should arouse the suspicion of placenta previa. Many a times, placenta previa presents as APH. Painless, causeless, and recurrent bleeding in late pregnancy is strongly suggestive of placenta previa.

The onset of bleeding is usually sudden, it may follow intercourse, although in most cases, it is causeless. The bleeding may vary from being slight to profuse; usually the first bout of bleeding is threatening but not alarming and stops spontaneously, only to recur later. The subsequent bouts of bleeding can be heavier and massive.

Bleeding in some cases may not occur till the onset of labor. PAS should be suspected in such cases.

The absence of abdominal pain and uterine contractions has classically been considered an important distinguishing feature between placenta previa and accidental hemorrhage. However, placental separation in placenta previa may incite mild uterine contractions sometimes, which usually cease subsequently. Hence, sonography must be done in all cases of bleeding during second half of pregnancy to exclude placenta previa.

The general condition of the woman corresponds to the amount of blood loss. If the bleeding has been profuse, the signs of hypovolemic shock will be present. There may

JAYPEE BROTHERS

be restlessness, agitation, syncope, anxiety, or confusion. Pallor, cold and clammy skin, tachycardia, hypotension, and dyspnea denote significant bleeding. Oliguria and anuria are signs of persistent hypovolemic shock.

On abdominal examination, the size of the uterus corresponds to the period of gestation. The uterus is relaxed, soft without any area of tenderness. The fetal parts are easily palpable in contrast to placental abruption where fetal parts are difficult to palpate because of the tense and tender uterus. The presenting part is usually high, and fetus may be in oblique or transverse lie. Fetal heart sounds are present unless there is a major degree of placental separation or hypovolemic shock.

Diagnosis

Most of the cases of placenta previa are diagnosed on a routine transabdominal anomaly scan at 18–20 weeks and confirmed on subsequent ultrasound, abdominal and/or transvaginal, at 32 and 36 weeks.

However, placenta previa should be suspected in any woman who presents with causeless, painless vaginal bleeding after 20 weeks of pregnancy with no previous ultrasound report. Clinical features must always be kept in mind in such patients.

Diagnosis is confirmed on ultrasonography. Transvaginal sonography is an accurate and safe diagnostic procedure for confirming placenta previa. In women with placenta previa, placental cord insertion should be evaluated to rule out the possibility of vasa previa in case insertion is velamentous.

An evaluation for presence of placenta accreta, increta, or percreta (PAS) is indicated, especially in cases of placenta previa with previous cesarean section and in cases with other high-risk factors for placenta accreta.

Management of Placenta Previa

Management of placenta previa and low-lying placenta diagnosed at 18–20 weeks scan (fetal anomaly scan) depends on the clinical course and subsequent scans and is summarized in **Flowchart 2**.

Placenta previa may be asymptomatic or may present with recurrent bleeding episodes, sometimes profuse, and it may be associated with placenta accreta. Management is thus, described accordingly.

Management of Asymptomatic Women Diagnosed at Second Trimester Ultrasound Scan

The patient is usually diagnosed with placenta previa or low-lying placenta in the second trimester scan where the

Flowchart 2: Management of placenta previa and low-lying placenta diagnosed at 18–20 weeks' scan.

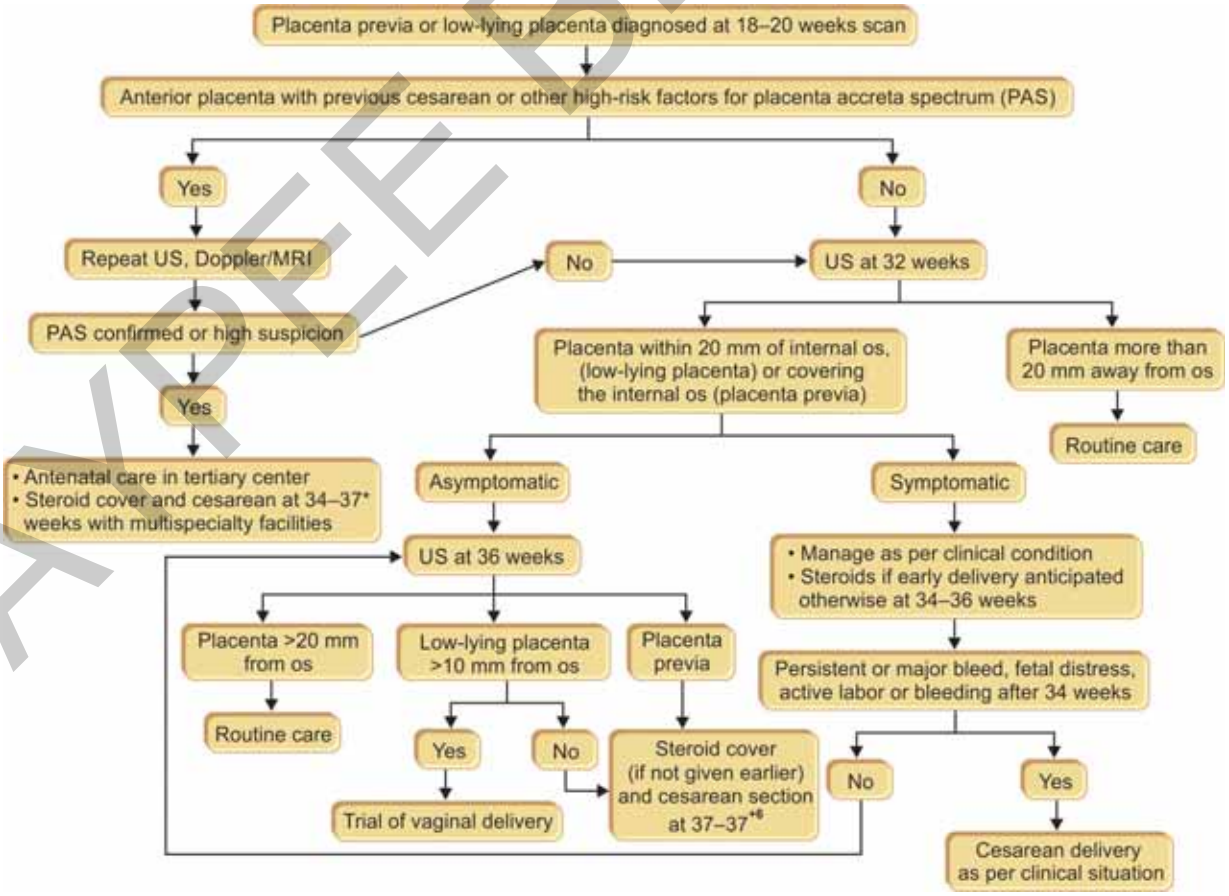

*Society for Maternal and Fetal Medicine Recommendations, 2017.[12]

JAYPEE BROTHERS

placental edge is either covering the internal os or is within 20 mm from the internal os. These patients should have routine antenatal care. In addition, they should be advised to avoid intercourse, avoid lifting heavy weights, and should be made aware of the chances of spotting or bleeding and to report in the hospital in case they have bleeding per vaginum.

Repeat ultrasound: A transvaginal ultrasound is repeated at 32 weeks in these patients. If the placental edge is more than 2 cm away from the internal os, the patient continues with routine antenatal care. In those with persistent placenta previa or low-lying placenta, TVS is repeated at 36 weeks.

Vasa previa should be ruled out on ultrasound in these cases as it can occur in patients with resolution of placenta previa.

As per RCOG guidelines, cervical length should also be measured at the time of scan as this may help in decision making in management of asymptomatic women with placenta previa. A short cervical length on TVS before 34 weeks has been shown to be associated with increased risk of preterm delivery and excessive bleeding at cesarean section.[11]

Antenatal corticosteroids: A single course of antenatal corticosteroids between 34 and 35^{+6} weeks is recommended in women with placenta previa and low-lying placenta, which may be given prior to 34 weeks of gestation in women at higher risk of preterm birth.[11] Society for Maternal-Fetal Medicine (SMFM) recommends administration of antenatal corticosteroids to women who are eligible and are managed expectantly, the gestational age is between 34 and 36^{+6} weeks, and antenatal corticosteroids have not been given earlier (Grade 1A).[12]

Hospital or home management: A decision is taken regarding hospital or home management after considering all the factors. An asymptomatic placenta previa can be managed at home provided the woman can reach hospital immediately in case bleeding occurs. Studies have not shown any difference regarding maternal or fetal morbidity with home management versus hospitalization prior to the first bleed in these women.[11]

Route and time of delivery: According to RCOG guidelines, in cases of placenta previa, i.e., where the placental edge covers the internal os at 36 weeks scan, cesarean delivery is planned between 36 and 37 weeks.[11]

Society for Maternal-Fetal Medicine, however, recommends delivery at 36 to 37^{+6} weeks of gestation for stable women with placenta previa without bleeding or other obstetric complications.[12]

If the placental edge does not cover the os but is <2 cm from the internal os (low-lying placenta), the risks and benefits of a trial of labor should be discussed with the patient. The risk of bleeding increases as the distance between the placental edge and internal os decreases.

In a recent systematic review and meta-analysis, it was found that vaginal delivery was successful in 43% cases when placental distance from internal os (IOD) was 0–10 mm, 85% when the distance was 11–20 mm, and 82% when IOD was >20 mm. A shorter IOD had a higher chance of APH. They concluded that low-lying placenta is not a contraindication for trial of labor.[13]

Vasa previa is sometimes associated with low-lying placenta and should be looked for, which, if present, is an indication for elective cesarean.

Management of Women Who Present with Active Bleeding

Many women with placenta previa, diagnosed or undiagnosed, present with bleeding per vaginum. All women with APH should be admitted to the hospital. One should be prepared to manage massive hemorrhage and preterm delivery in a woman with placenta previa.

Management in hospital: All women admitted with APH should have an immediate overall assessment to establish if any urgent intervention is required as in women with continued or profuse bleeding. Resuscitation is initiated, if indicated.

If there is no maternal or fetal compromise, a detailed assessment is done.

- A comprehensive history is taken. Gestational age is calculated by last menstrual period or previous ultrasonography (USG) done in early pregnancy. Information about placental localization on previous ultrasounds and its relationship to previous scars, if any, is reviewed.
- Assessment of general condition of patient is done. Maternal pulse, blood pressure, respiratory rate, and oxygen saturation are recorded. Pallor is assessed for its presence and severity. Presence of pallor, tachycardia, tachypnea, and hypotension are signs of excessive blood loss, and patient may be in hemorrhagic shock.

Estimate of the amount of blood loss is done. Exact assessment may be difficult. Vulva is inspected to assess the amount of blood loss, its color, and to determine whether bleeding has stopped or is continuing. A pregnant woman with APH presenting in hemorrhagic shock has already lost 15–20% of her circulating blood volume (1–1.5 L, approximately).

Abdominal examination: It is important to exclude uterine tenderness, increased tone, and contractions and to note whether uterine fundal height is corresponding with gestational age or is more as in placental abruption. Lie and presentation should be noted. In placenta previa, the uterus is usually soft, relaxed, nontender with fundal height corresponding to the period of gestation.

JAYPEE BROTHERS

Fetal heart is auscultated for any evidence of fetal distress. No per speculum or per vaginal examination is done in patients with active bleeding as it can incite hemorrhage.

An intravenous line is established with wide bore cannula no. 16 or 18. Ringers lactate or normal saline is infused to achieve or maintain hemodynamic stability and adequate urine output (at least 30 mL/h).

A blood sample is taken for full blood count, blood group and type, cross-matching, and for coagulation studies. Transfusion of blood products in a woman with an actively bleeding placenta previa should be guided by the volume of blood loss and changes in hemodynamic parameters, e.g., blood pressure, maternal and fetal heart rates, peripheral perfusion, and urine output, as well as the hemoglobin level. The volume replacement is done at the rate of 3 mL of crystalloid or 2 mL of colloid for every mL of blood loss till packed cell volume is arranged.

If possible, an USG should be performed for placental localization, confirmation of lie, to rule out associated abruption, and for fetal well-being.

No tocolytic drugs should be administered in an actively bleeding patient with threatened preterm labor. If the patient is not actively bleeding, the tocolytics may be administered in preterm placenta previa for 48 hours to provide corticosteroid cover to the fetus.[14]

A course of corticosteroids should be given to women with preterm pregnancy. However, if she must be taken for emergency cesarean section, one should administer the first dose of corticosteroids and not wait for 48 hours. In Rh-negative patient, anti-D should be given in women presenting with APH. Readministration is not necessary, if the bleeding/delivery occur within 3 weeks of the last injection.

Magnesium sulfate therapy for neuroprotection in pregnancies between 24 and 32 weeks is indicated in cases where a decision to deliver within 24 hours but not emergently is taken. Emergency delivery should not be delayed for administration of magnesium sulfate.

Depending on the maturity of fetus, amount of bleeding, maternal and fetal condition, and whether the woman is in labor or not, further management can be expectant or active.

Expectant management: Aim of the expectant management is to prolong the pregnancy till the fetus matures. It is indicated when the following conditions are present:

- Preterm pregnancy
- Live fetus
- No serious fetal malformations
- Bleeding is not excessive
- Patient is hemodynamically stable
- Patient is not in labor.

Absolute bed rest is advised till at least 48 hours after the bleeding stops. Careful monitoring of pulse, blood pressure, fundal height, fetal heart rate, and vaginal bleeding is done. Antenatal steroids for fetal lung maturity should be administered in women with gestation between 24 and 36^{+6} weeks. Rh-negative woman should be given anti-D immunoglobulin. Ultrasound examination, if not done earlier, is done to localize placenta and to exclude any fetal malformation. Anti-anemic treatment in form of hematinics is given and woman is kept in hospital under observation. Use of cervical cerclage to prevent bleeding and prolong pregnancy is not recommended. Tocolytics have been tried with a view to prolong the pregnancy but are not advocated for lack of evidence. Very cautiously tocolysis is sometimes given for antenatal corticosteroid cover in women with APH and uterine activity. Expectant management is continued till fetal maturity is attained or if bleeding continues or becomes excessive.

Most women who initially present with symptomatic placenta previa respond to conservative treatment and do not require immediate delivery but they are at high risk of recurrent bleeds and 25–40% requiring emergency delivery because of bleeding.

Prolonged hospitalization may be required and is a safer option. Decision to discharge the woman depends on her condition, the number of episodes of bleeding, proximity to the hospital, as well as likely compliance. Carefully selected women with placenta previa whose bleeding has stopped for a minimum of 48 hours and who have no other pregnancy complications can be discharged after explaining the risks and proper counseling. They should understand that there is a risk of profuse bleeding and they should be able to reach the hospital immediately.

Active management: Active management of placenta previa involves delivering the woman by cesarean section. It is indicated, if there is severe and persistent vaginal bleeding or if maternal hemodynamic stability cannot be achieved or maintained. In cases where there is significant vaginal bleeding after 34 weeks of gestation, neonatal benefits from avoiding preterm birth decrease with advancing gestational age and the maternal risks from persistent or recurrent bleeding increase, hence delivery is indicated. Delivery is also indicated in symptomatic women with placenta previa, if she is in labor, there is fetal distress or pregnancy is 36 weeks or more **(Box 1)**.

BOX 1: Indications of active management of placenta previa.

- The woman is in labor
- There is fetal distress
- If there is severe and persistent vaginal bleeding or if maternal hemodynamic stability cannot be achieved or maintained
- Significant vaginal bleeding after 34 weeks of gestation—the neonatal benefits from avoiding preterm birth decrease with advancing gestational age and the maternal risks from persistent or recurrent bleeding probably increase
- Intrauterine fetal death or congenitally malformed baby
- In women who have been asymptomatic or on expectant treatment and reach 37 weeks of pregnancy

JAYPEE BROTHERS

Cesarean section in placenta previa: Cesarean section is required in all cases of placenta previa where placenta lies over the internal os and it is the recommended treatment.

Cesarean section should be performed by a senior obstetrician along with a senior anesthesiologist. Blood should be available in all cases. Antenatal evaluation for PAS is recommended especially in anterior placenta previa in women with previous cesarean section.

The choice of anesthetic technique for cesarean section for placenta previa must be made by the anesthetist in consultation with obstetrician and the patient. General anesthesia had been advocated in the past but there is increasing evidence to support the safety of regional block with decreased blood loss.

Lower segment cesarean section is preferred, and it must be performed by an experienced obstetrician. An ultrasound done prior to cesarean section may help in planning the incision on the uterus and access the membranes avoiding the placenta. Care should be taken while giving an incision on the lower segment as it is highly vascular in such cases. In cases where placenta is implanted anteriorly, the placenta is either separated manually to reach the margin of the placenta or cut through; membranes are ruptured and baby delivered. In both these conditions, the cord must be clamped promptly to prevent further fetal blood loss. Complete hemostasis should be achieved in all cases.

Diffuse and profuse bleeding may occur from the placental bed because placental site is in the lower uterine segment which does not contract and retract as efficiently as the upper segment. Medical and surgical interventions to stop the bleeding are required simultaneously. Uterotonics, including oxytocin, methylergonovine maleate (Methergine), 15 methyl prostaglandin F2 alpha (Carboprost), or misoprostol should be used systematically to manage uterine atony. Tranexamic acid one gram (10 mL of a 100 mg/mL solution) is infused over 10–20 minutes. It can be given along with uterotonic drugs. It can also be given prophylactically to decrease blood loss.

For hemostasis at placental site, packing or pressure with gauze may stop or decrease the bleeding. Hemostatic sutures are applied, over sewing the placental site or interrupted sutures can be placed. Intrauterine balloon tamponade and uterine compression sutures have been described for controlling bleeding.

In cases of focal placenta accreta with persistent bleeding, excision may be done if the area is small and easily accessible.

If bleeding persists, bilateral uterine artery ligation or internal iliac artery ligation may be required and is often effective.

Rapid replacement of blood and blood products should be carried out for stabilization of patient's hemodynamic status.

If all the measures fail to control the bleeding, timely hysterectomy may be lifesaving and should not be delayed.

Newborn must be monitored carefully and may require blood transfusion.

Delivery in a woman with low-lying placenta: The optimal route for delivery of pregnancies where the distance between the placental edge and internal os is 0–20 mm is debatable.

Although a variety of factors influence the decision to perform cesarean delivery, a trial of labor can be given in patients in whom the placenta is more than 10 mm away from the internal os.[6,8,14] In these cases, the fetal head may tamponade the adjacent placenta, thus preventing hemorrhage.

If this distance is ≤ 10 mm, there is high risk of intrapartum hemorrhage necessitating emergency cesarean delivery.

If a trial of vaginal delivery with a low-lying placenta is attempted, the facilities to perform an emergency cesarean delivery should be there. Early artificial rupture of membranes (ARM) may be considered in these cases.

PLACENTA ACCRETA SPECTRUM

Placenta accreta spectrum, formerly known as morbidly adherent placenta, refers to the range of pathologic adherence of the placenta, including placenta increta, percreta, and placenta accreta.[15]

Placenta accreta is when the villi simply adhere to the myometrium; placenta increta, when the villi invade the myometrium **(Fig. 1)**; and placenta percreta, when villi invade the full thickness of the myometrium including the uterine serosa and sometimes bladder, ureter and other adjacent pelvic structures. Variations in the lateral extension of myometrial invasion also divide PAS disorders into the focal, partial, or total categories, depending on the number of placental cotyledons involved.[16]

Placenta accreta spectrum carries high risk of maternal mortality and morbidity and its incidence is increasing globally.

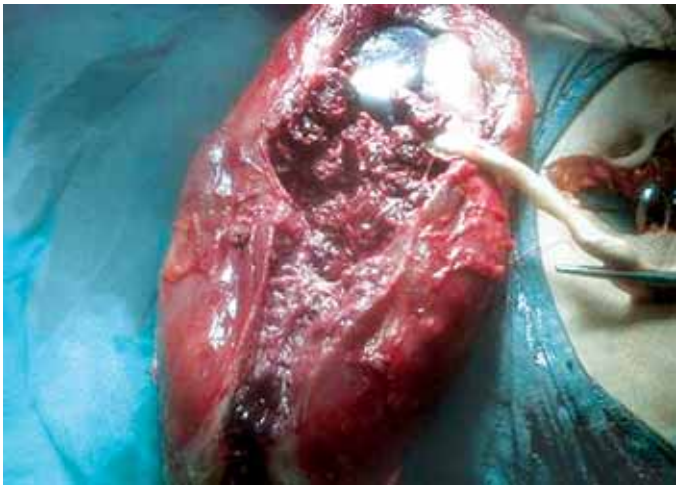

Fig. 1: Placenta increta.

JAYPEE BROTHERS

It is essential to identify this condition before or during delivery, particularly the invasive forms.

Variable incidence has been reported across the world ranging from 1 in 300 to 1 in 2,000 pregnancies. The incidence of PAS is increasing because of the increasing rates of cesarean section. In a large multicentric US cohort study, it was found that in women with placenta previa and previous cesarean delivery, the risk of placenta accreta was 3%, 11%, 40%, 61%, and 67% for first, second, third, fourth, and fifth or more cesarean deliveries, respectively.[17]

Risk Factors for Placenta Accreta Spectrum

The most common risk factor for PAS is previous cesarean, more the number of previous cesarean sections, higher is the risk for PAS. Placenta previa is another significant risk factor. Other risk factors include advanced maternal age, multiparity, prior uterine surgeries, previous history of dilatation and curettage, and Asherman's syndrome. Previous cesarean with anterior placenta previa should alert the obstetrician to the presence of placenta accreta.

Diagnosis

Diagnosing PAS in antenatal period is crucial.

Placenta accreta spectrum must be looked for in all pregnancies with high-risk factors listed above especially in women with previous cesarean section diagnosed with placenta previa on second and third trimester ultrasound. Features of PAS include multiple vascular lacunae within the placenta, loss of the normal hypoechoic zone between the placenta and myometrium, decreased retroplacental myometrial thickness (less than 1 mm), abnormalities of the uterine serosa–bladder interface, and extension of placenta into myometrium, serosa, or bladder. However, ultrasound does not rule out PAS and hence index of clinical suspicion should remain high in the presence of high-risk factors. Color Doppler can further help in the diagnosis of PAS. MRI complements ultrasound and helps to assess the depth of penetration of placenta and is especially useful in posterior placenta.

Management

Placenta accreta spectrum disorders are emerging as one of the most serious obstetric complications, and causing significant maternal mortality and morbidity worldwide. As per ACOG Obstetric Care Consensus 2018, outcomes in PAS are optimized when delivery occurs at a level III (subspecialty care), or level IV (regional perinatal healthcare centers) before the onset of labor or bleeding.[15]

Timing of Delivery in PAS

In the absence of risk factors for preterm delivery in women with PAS, planned delivery at 35^{+0} to 36^{+6} weeks of gestation is said to provide the best balance between fetal maturity and the risk of unscheduled delivery.[11] FIGO consensus guidelines suggest that women who are stable with no prepartum hemorrhage, preterm premature rupture of membranes, or uterine contractions may be considered for planned delivery at 36–37 weeks.

However, contingency plan for emergency cesarean/hysterectomy, massive blood transfusion, and multidisciplinary management of the patient should be in place.

Preoperative Management

- Optimization of hemoglobin of the patient antenatally.
- Risk of postpartum hemorrhage (PPH), need for hysterectomy, ICU care, and elective ventilation are to be explained and informed consent taken.
- Arrange requisite amount of blood. Massive blood transfusion may be required in some cases.
- Senior obstetrician and anesthetist should be present.
- Multidisciplinary involvement in preoperative planning.
- Schedule cesarean section at 34 to 36^{+6} weeks in a facility equipped to manage PAS.
- Antenatal corticosteroids.

Intraoperative Management

The best approach to PAS is cesarean hysterectomy with placenta left in situ. Attempt to separate the placenta should not be made.

Depending upon the individual case and imaging results, surgical planning is done. Vertical abdominal incision may be preferable in women with morbidly adherent placenta or where difficulties are anticipated in approaching the lower segment.

Evaluation is carried out to plan the uterine incision. In placenta previa accreta, incision in the uterus is given above the site of placental edge and upper segment cesarean is preferable.

It is important that after delivery of the baby, injection oxytocin is withheld, no attempt is made to separate the placenta otherwise there can be torrential hemorrhage.

In case the diagnosis of placenta accreta is not certain, spontaneous separation of placenta should be awaited. In absence of spontaneous separation, a decision for expectant management or hysterectomy is taken depending upon the preplanned management or the clinical situation.

In women with major degree of placenta accreta, hysterectomy is a safer option. Although successful conservative management has been described, there is limited evidence to support it in placenta percreta.[3]

Expectant management may, however, be required in unsuspected, emergency cases where expertise or facilities for emergency hysterectomy are not available and patient is not bleeding. Expectant management may also be done if the patient is not bleeding and fertility is an issue. In expectant

JAYPEE BROTHERS

management, cord is cut close to placenta and uterus is closed. Careful monitoring and observation are continued for any vaginal bleeding in postoperative period.

The woman and her relative must be informed that hysterectomy may be required later because of complications such as hemorrhage and sepsis. Placenta is expelled or resorbed in some; but about 20–40% need hysterectomy. Uterine artery embolization and postoperative methotrexate have been tried with variable results.

In case hysterectomy is planned, all measures should be taken to minimize the blood loss. In cases of adherent bladder, separation may be done after bilateral uterine artery ligation. Internal iliac artery ligation or uterine artery embolization may be required in cases with excessive bleeding. Placing of balloon-tipped intra-arterial catheters in internal iliac arteries preoperatively has been described. These are inflated after delivery to occlude the vessels and reduce the blood loss. These catheters can also be used to embolize the vessels.

Planned Delayed Hysterectomy

Planned delayed or secondary hysterectomy is an alternative "definitive" surgical management for PAS disorders where extensive invasion of surrounding structures renders immediate hysterectomy extremely difficult.[16] Decreased vascularity, involution of uterus, and placental resorption make delayed hysterectomy easier and can be performed 3–12 weeks postpartum. The risk of coagulopathy, sepsis, and hemorrhage must be kept in mind with full preparedness for a difficult emergency hysterectomy at any time. Conventionally, these hysterectomies are performed by laparotomy, but laparoscopic approach including robotic surgery has been described in selected cases with an aim to reduce morbidity.[18,19]

ABRUPTIO PLACENTA

Abruptio placenta, also known as ablatio placenta or accidental hemorrhage, is a serious condition that despite the modern medical advances cannot be predicted or prevented and can lead to high fetal loss and maternal complications. Abruptio placentae, the premature separation of a normally situated placenta accounts for 30% of cases of APH. It occurs in about 0.5–1% of deliveries,[20] the severe form occurring in about 1 in 500 deliveries.

Etiology

The exact cause of separation of normally situated placenta is not always known.

Following are some of the conditions which lead to abruptio placentae:

- *External trauma*: Fall or blow on abdomen or rarely external cephalic version.
- Acute decompression of polyhydramnios. Sudden diminution of surface area of uterus where placenta is attached leads to placental detachment.
- Preterm rupture of membranes predisposes to placental abruption.
- Hypertension is the most commonly associated condition with placental abruption. In severe abruption, gestational hypertension or chronic hypertension was found in 50% of the cases. In milder form of abruption, the incidence of hypertension is not high.
- Other predisposing factors include advanced maternal age, multiparity, uterine leiomyoma, smoking, and previous history of abruption (10% risk of recurrence), ART pregnancy, and cocaine abuse.
- Folic acid deficiency though implicated has not been proved to be the cause of abruption.
- First trimester bleeding predisposes to abruption.
- In many cases, no cause is found. Although not proven, congenital or acquired thrombophilia may be responsible in some cases.

Pathophysiology

Placental abruption is initiated by hemorrhage into the decidua basalis. As the decidual hematoma expands, it separates and compresses the placenta. The blood may separate the membranes and escape vaginally giving rise to revealed type of abruptio placentae **(Figs. 2A and B)**. The placental detachment is usually incomplete with this and complications are fewer and less severe. The revealed form of abruptio placentae is more common and is found in approximately 80% of the cases. In early stages, there may not be any clinical features suggestive of abruption. On inspection of the placenta after delivery, a circumscribed depression with dark clotted blood is found. Abruption, if recent, however may not show any evidence of separation on placental examination following delivery.

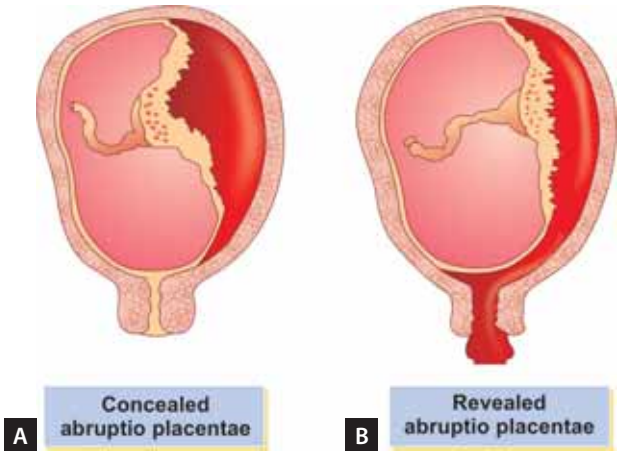

Figs. 2A and B: Types of abruptio placentae. (A) Concealed abruptio placentae; (B) Revealed abruptio placentae.

JAYPEE BROTHERS

In concealed variety, the placental margins or the membranes remain adherent to the uterine wall and blood keeps collecting behind the placenta. This is a severe form of abruptio placentae and is seen in about 20% of the cases. Following the separation of the placenta, the blood does not escape out but is retained behind the placenta within the uterine cavity. Fetal death, coagulation disorders, and other maternal complications are more common with concealed variety of abruption. Blood may enter the amniotic cavity after breaking through the membranes. In some cases, the fetal head which is closely applied to the cervix may prevent the blood to escape.

In more severe form of concealed placental abruption, widespread extravasation of blood occurs into the uterine musculature and beneath the serosa giving rise to Couvelaire uterus which appears ecchymotic and purple on laparotomy. These myometrial hematomas do not interfere with uterine contractility and do not warrant hysterectomy.

Clinical Features

Clinical presentation may vary depending upon the severity and type of abruption whether concealed or revealed. In mild cases, there may not be any symptoms or signs.

In majority of the cases, vaginal bleeding is the predominant feature and is found in about 70–80% of the cases. Bleeding is most often associated with abdominal pain. Back pain and uterine contractions may be observed in some cases. Uterine tenderness and rigidity are present in most of these cases and are important signs of placental abruption. Depending on the severity of abruption, fetal heart sounds may or may not be present. Fetal distress is found in about 50% of the cases and fetal death occurs in about 15% of the cases.

In mild cases of abruption, vaginal bleeding may not be associated with abdominal pain and may not produce any signs of abruption. Uterus may feel nontense and nontender. Diagnosis is made on examination of placenta after delivery, which reveals a retroplacental clot.

Typical signs of placental separation may be absent initially in a case of abruptio placentae. As the blood collects behind the placenta, the uterus becomes tender and tense and the uterine height may rise. Hence, every woman who presents with vaginal bleeding must be monitored carefully to detect this condition. Uterine tenderness and rigidity may be absent in abruption of a posteriorly situated placenta.

In severe forms of concealed hemorrhage, no vaginal bleeding may be observed but the uterus is found to be tense and tender and fetal heart sounds are usually absent. The woman may develop a hemorrhagic diathesis due to disseminated intravascular coagulation (DIC) with depletion of fibrinogen as well as other clotting factors. This may lead to active bleeding from all the sites. Hypovolemic shock and renal failure may develop.

Diagnosis

Diagnosis of abruptio placentae is clinical and high index of suspicion is required to diagnose mild and atypical cases. All cases of vaginal bleeding or pain in latter half of pregnancy and those with history of trauma must be evaluated and observed carefully to diagnose or exclude abruption. Ultrasound is not always helpful in diagnosing abruptio placentae, it may be normal in these cases, but it helps to exclude placenta previa. There may be no findings on ultrasound in revealed abruption as there is no retroplacental clot. Retroplacental clot, if present, may take a variety of appearances from hypoechoic to isoechoic to hyperechoic and the diagnosis of abruption may be confused by the retroplacental complex which appears hyperechoic on ultrasound. The hyperechoic retroplacental complex which is usually no more than 2 cm in thickness demonstrates very high blood flow by color Doppler. When the retroplacental clot is large, ultrasound identifies it as hyperechoic or isoechoic compared with the placenta. This echogenicity may also be misinterpreted as a thick placenta. In women on expectant management with small retroplacental clot, resolution of the clot appears hyperechoic within 1 week and sonolucent within 2 weeks.

Depending upon the degree of abruption and its clinical effects, the cases are graded as follows:

Grade 0: Clinical features suggestive of placental separation are absent; the diagnosis is made retrospectively when retroplacental clots are detected incidentally following delivery.

Grade I: There is hemorrhage with uterine irritability and pain, but there is no maternal or fetal compromise.

Grade II: In this grade, APH is accompanied by classic features of abruptio placentae and the fetus is alive. The uterus is tense and tender and fetal heart abnormalities are present.

Grade III: Along with the features of grade II, there is fetal death. It has associated maternal shock, coagulation failure, or renal failure.

Management of Abruptio Placentae

Management of abruptio placentae depends on the severity of the case and on the condition of the mother and the fetus. All cases require intensive monitoring and individualized management **(Flowchart 3)**.

In cases of mild abruption, where the uterus is soft and nontender, the pregnancy should be terminated by induction of labor with low rupture of membranes and oxytocin. Many cases of abruption are already in established labor and only ARM is done. They may not require oxytocin.

Careful watch on progress of labor, condition of woman and fetus is important. Signs of hemorrhage, revealed or concealed, should be looked for. Vital signs, uterine height,

JAYPEE BROTHERS

Flowchart 3: Management of abruptio placentae.

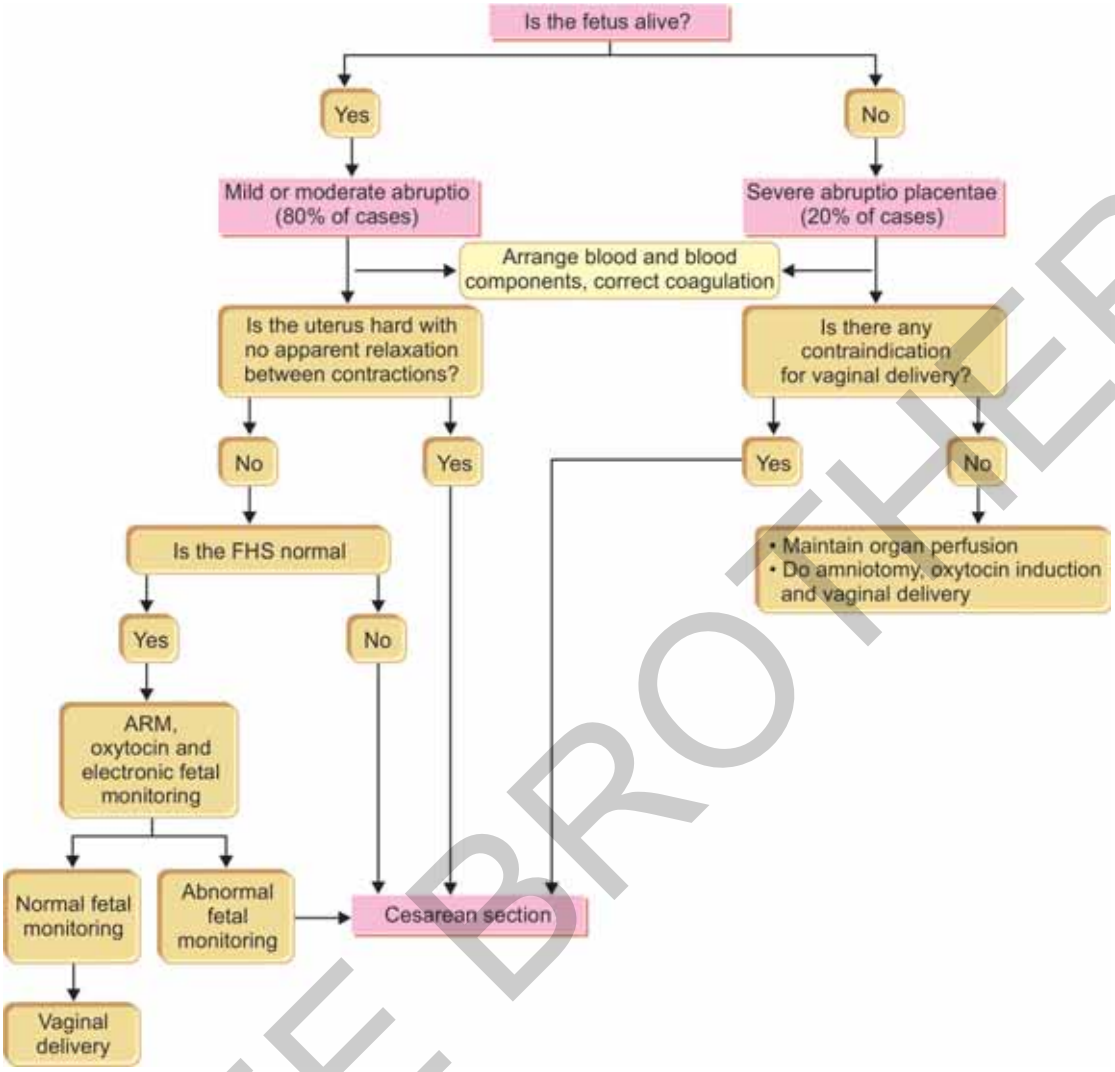

(ARM: artificial rupture of membranes; FHS: fetal heart sound)

vaginal bleeding, urinary output, and coagulation profile should be carefully monitored. Blood and fresh frozen plasma (FFP) should be arranged. An early delivery of fetus with adequate replacement of fluid or blood and careful monitoring results in good outcome. Cesarean section is indicated, if patient deteriorates or fetal distress develops. Coagulation profile, if found to be abnormal, should be promptly treated.

If the fetus is alive and the uterus is rigid, it implies that the abruption is large but is less than 50%, chances of fetal distress are high and therefore, patient should be prepared for immediate cesarean section with blood and fluid replacement. Coagulation profile should be checked, and if deranged must be corrected promptly prior to cesarean section.

Women with fetal death should preferably be delivered vaginally. Amniotomy should be done as soon as possible and if required, oxytocin drip is started. Strict watch on uterine contractions is maintained as the uterus is hypertonic. Careful monitoring of vital signs, coagulation profile, and urinary output is important.

Women with severe pre-eclampsia with abruption may appear to be normotensive despite excessive blood loss. The blood loss with severe abruptio placentae associated with fetal death was often found to be about half the total blood volume.[21]

These patients, therefore, require prompt and adequate transfusion of fluids and blood. Two wide bore intravenous access lines should be established to allow rapid administration of fluids and blood. Hematocrit and coagulation studies should be done 4–8 hourly depending on the grade of placental abruption. Indwelling urinary catheter should be inserted and urine output is monitored. Hematocrit should be maintained at 30% or more, to sustain the oxygen carrying capacity of the blood. Urinary output of at least 30 mL/h signifies effective intravascular volume and prevents acute tubular or cortical necrosis, an important cause of maternal mortality in abruptio placentae.

JAYPEE BROTHERS

Central venous pressure may be monitored by putting a catheter in internal jugular vein and maintaining it at 10 cm of water. This helps in preventing fluid overload. Lung bases must be auscultated for any crepts suggestive of fluid overload.

Third stage of labor should be managed actively. Oxytocin infusion and uterine massage is usually sufficient to prevent PPH. Total blood loss should be estimated, retroplacental clots must be measured and recorded. Very often the blood loss is underestimated, and woman may go into hypovolemic shock. Close monitoring must be continued after delivery with special watch for PPH and urinary output.

Only in very mild cases of placental abruption with slight bleeding where fetus is preterm and maternal, and fetal condition is stable, expectant treatment can be given in the hospital under very close supervision. Periodic ultrasound examinations are done to monitor fetal growth and the size of the clot. Tocolysis to prolong pregnancy is not advocated in case the woman goes into preterm labor.

In cases with incidental finding of a small retroplacental clot on ultrasound, conservative management with careful monitoring is advisable. Predisposing factors such as smoking or hypertension should be looked for and managed.

Management of Coagulopathy

In severe abruption, acute DIC may occur leading to fall in fibrinogen levels, other coagulation factors and elevation of fibrin degradation products and D-dimers. Fibrinogen levels may fall below 140 mg/dL and there may be fall in platelet count along with prolongation of partial thromboplastin time (PTT) and prothrombin time (PT). In absence of facilities for coagulation studies, a simple bedside clot observation test is invaluable in managing these cases. Venous blood sample is drawn and is placed in a clean dry test tube. It is observed for clot formation and clot lysis. Failure of clot formation within 10 minutes or dissolution of a firm clot when the tube is gently shaken at the end of an hour suggests clotting deficiency due to lack of fibrinogen, platelets, and other coagulation factors.

Aggressive blood and coagulation factors replacement should be carried out. As per RCOG guidelines, up to 4 units of FFP and 10 units of cryoprecipitates may be given while awaiting the results of coagulation studies.[1]

Platelet transfusion in a bleeding patient is indicated if count is below 50,000/mm^3 and in all patients with a platelet count less than 20,000/mm^3 even if there is no bleeding. Coagulation defect must be corrected if cesarean section is to be carried out. Platelet count of at least 50,000/mm^3 and 80,000/mm^3, respectively for vaginal delivery and cesarean section is desirable.

Acute Kidney Injury

Acute kidney injury (AKI) or renal dysfunction is rare with lesser degrees of placental abruption but is seen in cases when there is delayed or incomplete treatment of hypovolemia. AKI is usually reversible and long-term prognosis is good. Renal dysfunction is more likely in cases of preeclampsia. The possibility of renal cortical or tubular necrosis must be considered if oliguria persists after an adequate intravascular volume has been restored. An attempt should be made to improve renal circulation and promote diuresis by increasing fluid volume under close monitoring. If renal failure persists, dialysis is indicated.

Prognosis

Maternal: Maternal mortality in abruptio placentae ranges from 0.5 to 5%. Hemorrhage, coagulation failure, hypovolemic shock, and renal failure are responsible for high mortality. Early diagnosis and prompt and definitive therapy result in lowered maternal mortality and morbidity. In a large, population-based study, women with placental abruption in the first or a later pregnancy were found to have a 1.8-fold increased risk of CVD mortality later in life.[22] The recurrence risk of abruption is 6–17% after previous one abruption and 25% after previous two abruptions.

Fetal: Perinatal mortality rates of 4–68% have been reported and depend upon the severity of the abruption and the neonatal facilities available. Live-born infants have a high morbidity due to hypoxia, birth trauma, and prematurity. Neonatal anemia may be marked in these cases.

OTHER CAUSES OF ANTEPARTUM HEMORRHAGE

Besides placenta previa and abruptio placentae, APH is caused by incidental causes, marginal placenta, and vasa previa.

Local Lesions of Cervix

These include cervicitis, cervical erosion, polyps, varicose veins in vagina or cervix, and cancer cervix. Per speculum examination will reveal these lesions but they may coexist with other causes of APH-like placenta previa, which should therefore, be excluded.

Vasa Previa

This is a rare condition occurring in 1 in 2,000–3,000 deliveries.[23] Clinically, it presents as fetal distress and is confirmed by testing vaginal blood for presence of fetal hemoglobin in cases of APH. Cesarean section is indicated, if fetal blood is detected. Fetal mortality is high, if the condition is not diagnosed. Antenatal diagnosis with Doppler ultrasound has been advocated in high-risk cases, that is, those with low-lying placenta, velamentous insertion of cord, multifetal pregnancies, and those following IVF.[24] Ultrasound done at the time of anomaly scan has high accuracy and low-false positive rate in diagnosing vasa previa, although about 20% of these may resolve by third trimester.

JAYPEE BROTHERS

Routine screening for presence of vasa previa at the time of anomaly scan, however, is not recommended but it is useful to look for it in high-risk cases such as those with low-lying placenta. In the presence of confirmed vasa previa in the third trimester, elective cesarean section should be done prior to the onset of labor.[25]

Society for Maternal-Fetal Medicine recommends delivery between 34 and 37 weeks of gestation for stable women with vasa previa (Grade 1B).[12]

Indeterminate or Unexplained Bleeding

Many cases of APH have no evidence of placenta previa, abruption, or any local cause. The cause of bleeding in these cases is not known. It can be due to marginal separation of placenta in some cases. The bleeding is usually slight. Increased risk of preterm births, NICU admission, and a lower birthweight have been observed in these cases.[26] Perinatal mortality is high in this group. The management of these patients is individualized, and is usually expectant till 38 weeks. Close maternal and fetal monitoring is required.

KEY POINTS

- Antepartum hemorrhage is defined as bleeding from or into the genital tract after the period of viability of pregnancy but before delivery of the baby and occurs in 3–5% of all pregnancies.
- Antepartum hemorrhage can be due to placental, extraplacental, and indeterminate causes or rarely, it can be due to vasa previa.
- When the placenta lies directly on the internal os, it is called placenta previa, and when it is within 2 cm of internal os, it is labeled as low-lying placenta and these occur in about 1 in 200 deliveries.
- Placenta accreta spectrum (morbidly adherent placenta) must be suspected in cases of anterior placenta previa in women with previous cesarean section and these cases should be managed as a case of placenta accreta, unless proved otherwise.
- Placenta accreta spectrum disorders carry a high risk of massive hemorrhage, high morbidity and mortality and should be managed in specialist centers with multidisciplinary facilities.
- Bleeding in placenta previa is painless, causeless, and recurrent, the uterus is soft and nontender, usually the presenting part is high or there may be malpresentation. Diagnosis is confirmed by ultrasound.
- Expectant treatment is given, if pregnancy is less than 36 weeks, fetus is live with no serious congenital malformation, bleeding is not excessive, patient is not in labor and is hemodynamically stable.
- Delivery is indicated, if pregnancy is more than 36 weeks or if the patient is in labor, bleeding is excessive, or fetus is dead or malformed.
- Antenatal corticosteroids should be administered to women who are eligible and are managed expectantly, the gestational age is between 34 and 36^{+6} weeks, and antenatal corticosteroids have not previously been given.
- Cesarean section is the treatment of choice in placenta previa; trial of vaginal delivery can be given in selected cases of low-lying placenta.
- Abruptio placentae is the premature separation of normally situated placenta and occurs in about 1% of deliveries.
- Bleeding in abruptio placentae is usually associated with pain. Uterus is tense and tender, fetal parts are not easily made out and fetal heart may be absent. In concealed variety of abruptio placentae, there is no external bleeding, but patient may be in shock with all the other signs of abruptio placentae.
- Severe hemorrhage, shock, coagulation failure, and renal failure may be present in severe cases of abruptio placentae.
- Prompt and adequate administration of fluid, blood, and FFP; early delivery with careful monitoring of vital signs, coagulation profile, and urine output are included in the management of abruption.
- Vaginal delivery is preferred with careful fetal monitoring in mild cases of abruptio with relaxed uterus and also in cases with dead fetus.
- Cesarean section is indicated in severe cases of abruptio with a live fetus and in cases with associated conditions requiring cesarean section.
- Coagulation disorder, if present, must be corrected before surgical procedure.
- All women with APH are at high risk for PPH and should be managed appropriately.

REFERENCES

1. RCOG. (2011). Antepartum hemorrhage. RCOG Green top guidelines No. 63. 1st edition. [online] Available from: https://www.rcog.org.uk/en/guidelines-research-services/guidelines/gtg63/. [Last Accessed December, 2020].
2. Calleja-Agius J, Custo R, Brincat MP, Calleja N. Placental abruption and placenta praevia. Eur Clin Obstet Gynaecol. 2006;2:121-7.
3. Reddy UM, Abuhamad AZ, Levine D, Saade GR; Fetal Imaging Workshop Invited Participants. Fetal imaging: executive summary of a joint NICHD, SMFM, AIUM, ACOG, American College of Radiology, Society for Pediatric Radiology, and Society of Radiologists in Ultrasound Fetal Imaging Workshop. J Ultrasound Med. 2014;33:745-57.
4. Cunningham FG, Leveno KJ, Bloom SL, Dashe JS, Hoffman BL, Casey BM, Spong CY (Eds). William's Obstetrics, 25th edition. New York: McGraw Hill Education; 2014.
5. Lauria MR, Smith RS, Treadwell MC, Comstock CH, Kirk JS, Lee W, et al. The use of second-trimester transvaginal sonography to predict placenta previa. Ultrasound Obstet Gynecol. 1996;8(5):337-40.

JAYPEE BROTHERS

6. Jansen CHJR, Kleinrouweler CE, van Leeuwen L, Ruiter L, Mol BW, Pajkrt E. Which second trimester placenta previa remains a placenta previa in the third trimester: a prospective cohort study. Eur J Obstet Gynecol Reprod Biol. 2020;254:119-23.
7. Babinski A, Kerenyi T, Torok O, Grazi V, Lapinski RH, Bertwitz RL. Perinatal outcome in grand and greatgrand multipara: the effects of the parity on obstetric factors. Am J Obstet Gynecol. 1999;181(3):669-74.
8. Biro MA, Davey MA, Carolan M, Kealy M. Advanced maternal age and obstetric morbidity for women giving birth in Victoria, Australia: a population-based study. Aust NZJ Obstet Gynaecol. 2012;52(3):229-34.
9. Roberts CL, Algert CS, Warrendorf J, Olive EC, Morris JM, Ford JB. Trends and recurrence of placenta previa: a population-based study. Aust N Z J Obstet Gynaecol. 2012;52(5):483-6.
10. Klar M, Michels KB. Cesarean section and placental disorders in subsequent pregnancies: a meta-analysis. J Perinat Med. 2014;42(5):571-83.
11. Jauniaux E, Alfirevic Z, Bhide AG, Belfort MA, Burton GJ, Collins SL, et al. Placenta praevia and placenta accreta: diagnosis and management. Green-top Guideline No. 27a. BJOG. 2019;126(1):e1-48.
12. Society for Maternal-Fetal Medicine (SMFM). Consult Series #44: Management of bleeding in the late preterm period. Am J Obstet Gynecol. 2018;218(1):B2-8.
13. Jansen C, de Mooij YM, Blomaard CM, Derks JB, van Leeuwen E, Limpens J, et al. Vaginal delivery in women with a low-lying placenta: a systematic review and meta-analysis. BJOG. 2019;126(9):1118-26.
14. Bose DA, Assel BG, Hill JB, Chauhan SP. Maintenance tocolytics for preterm symptomatic placenta previa: a review. Am J Perinatol. 2011;28(1):45-50.
15. Cahill AG, Beigi R, Heine RP, Silver RM, Wax JR. Placenta accreta spectrum. Am J Obstet Gynecol. 2018;219(6):B2-16.
16. Allen L, Jauniaux E, Hobson S, Papillon-Smith J. FIGO Consensus Guidelines on Placenta Accreta Spectrum Disorders: nonconservative surgical management. Int J Gynecol Obstet. 2018;140(3):281-90.
17. Silver RM, Landon MB, Rouse DJ, Leveno KJ, Spong CY, Thom EA, et al; National Institute of Child Health and Human Development Maternal-Fetal Medicine Units Network. Maternal morbidity associated with multiple repeat cesarean deliveries. Obstet Gynecol. 2006;107(6):1226-32.
18. Arendas K, Lortie KJ, Singh SS. Delayed laparoscopic management of placenta increta. J Obstet Gynaecol Can. 2012;34(2):186-9.
19. Rupley DM, Tergas AI, Palmerola KL, Burke WM. Robotically assisted delayed total laparoscopic hysterectomy for placenta percreta. Gynecol Oncol Rep. 2016;17:53-5.
20. Giordano R, Cacciatore A, Cignini P, Vigna R, Romano M. Antepartum hemorrhage. J Perinat Med. 2010;4(1):12-6.
21. Pritchard JA, Brekken AL. Clinical and laboratory studies on severe abruptio placentae. Am J Obstet Gynecol. 1967;97(5):681-700.
22. DeRoo L, Skjærven R, Wilcox A, Klungsøyr K, Wikström AK, Morken NH, et al. Placental abruption and long-term maternal cardiovascular disease mortality: a population-based registry study in Norway and Sweden. Eur J Epidemiol. 2016;31(5):501-11.
23. Smorgick N, Tovbin Y, Ushakov F, Vaknin Z, Barzilay B, Herman A, et al. Is neonatal risk from vasa previa preventable? The 20 year experience from a single medical centre. J Clin Ultrasound. 2010;38(3):118-22.
24. Sinha P, Kaushik S, Kuruba N, Beweley S. Vasa previa: a missed diagnosis. J Obstet Gynecol. 2008;28(6):600.
25. Jauniaux ERM, Alfirevic Z, Bhide AG, Burton GJ, Collins SL, Silver R; on behalf of the Royal College of Obstetricians and Gynaecologists. Vasa praevia: diagnosis and management. Green-top Guideline No. 27b. BJOG. 2018.
26. McCormack RA, Doherty DA, Magann EF, Hutchinson M, Newnham JP. Antepartum bleeding of unknown origin in the second half of pregnancy and pregnancy outcome. BJOG. 2008;115(11):1451-7.

JAYPEE BROTHERS

for detailed information on obstetrics & gynecology books, visit our website www.jaypeebrothers.com, for detailed information on obstetrics & gynecology books, visit our website www.jaypeebr

Management of
High-Risk Pregnancy
A Practical Approach

Salient Features

- A comprehensive book on practical management of high-risk pregnancy
- Blends latest guidelines and recommendations with knowledge and experience of eminent faculty of reputed teaching hospitals
- Highlights essential details as images, algorithms and key points
- A "must have" book for postgraduates, residents, teachers and practicing obstetricians.

Shubha Sagar Trivedi MS FRCOG (Hon. Causa) FICOG FIMSA is the former Director Professor and Head, Department of Obstetrics and Gynecology, Lady Hardinge Medical College, New Delhi and former Professor and Head, Department of Obstetrics and Gynecology, SGT University, Gurugram, Haryana. She has also worked as faculty at Maulana Azad Medical College, New Delhi. As commonwealth fellow she worked at Hammersmith Hospital, London and Northern General Hospital, Sheffield, UK. Gold medalist and recipient of many awards in MBBS, best paper awards in national and international conferences, she received Fellowship of RCOG (Hon. Causa) UK. Dr Trivedi has been actively involved in teaching, training, research and clinical work for more than 45 years in Medical College Hospitals and has guided more than 40 postgraduate students including PhD student of Delhi University in their research and thesis. She has published more than 100 research papers in National and International Journals, has contributed chapters in more than 15 books and has written two very popular books, *Anemia in Pregnancy and Management of High-Risk Pregnancy: A Practical Approach*. Dr Trivedi has been the President of large academic bodies, such as AOGD, NARCHI (Delhi) and DGES. She is the Editorial Advisor of Journal of International Medical Science Academy and Advisor to AOGD.

Manju Puri MD FICOG is an Alumni of PGIMS, Rohtak, Haryana. Currently she is Director Professor and former Head, Department of Obstetrics and Gynecology at Lady Hardinge Medical College, New Delhi. She is a passionate teacher, astute clinician, and a skilled surgeon. She has vast experience of more than 35 years with special interest in high-risk pregnancy. She is an ardent proponent of providing respectful care to mothers and their newborns. She has a flair for quality improvement and has been pivotal in spreading the culture of quality improvement among not only obstetricians but also the nursing officers and support staff in the department of Obstetrics and Gynecology at Lady Hardinge Medical College, New Delhi and in other states in India. She is a keen researcher and was the principal investigator of the project titled "Health care Artificial Intelligence Catalyst (HAIC)".

Swati Agrawal MD is Professor, Department of Obstetrics and Gynecology, Lady Hardinge Medical College, New Delhi. She is also a certified Colposcopist from the International Federation of Cervical Pathology and Colposcopy and WHO-IARC. She has been a Gold Medalist in MBBS and is the proud recipient of many awards such as FOGSI Late Dr Pravin Mehta Training Fellowship in Endoscopy (2019), FOGSI Dr Kamini Rao Orator (2018), FOGSI-Ethicon Travelling Fellowship (2011-12) and Mrs Kumudha R Baliga Medal for Best Senior Resident in Lady Hardinge Medical College and Smt Sucheta Kriplani Hospital (2009). She is a National Mentor for Government of India LaQshya Initiative and has more than 50 publications in National and International indexed Journals to her credit.

Printed in India

Available at all medical bookstores
or buy online at www.jaypeebrothers.com



JAYPEE BROTHERS
Medical Publishers (P) Ltd.
EMCA House, 23/23-B, Ansari Road,
Daryaganj, New Delhi - 110 002, INDIA
www.jaypeebrothers.com

Join us on facebook.com/JaypeeMedicalPublishers

Shelving Recommendation
OBSTETRICS & GYNECOLOGY

