brothers.com, for detailed information on obstetrics & gynecology books, visit our website www.jaypeebrothers.com, for detailed information on obstetrics & gynecology books

DC Dutta's Clinics in GYNECOLOGY

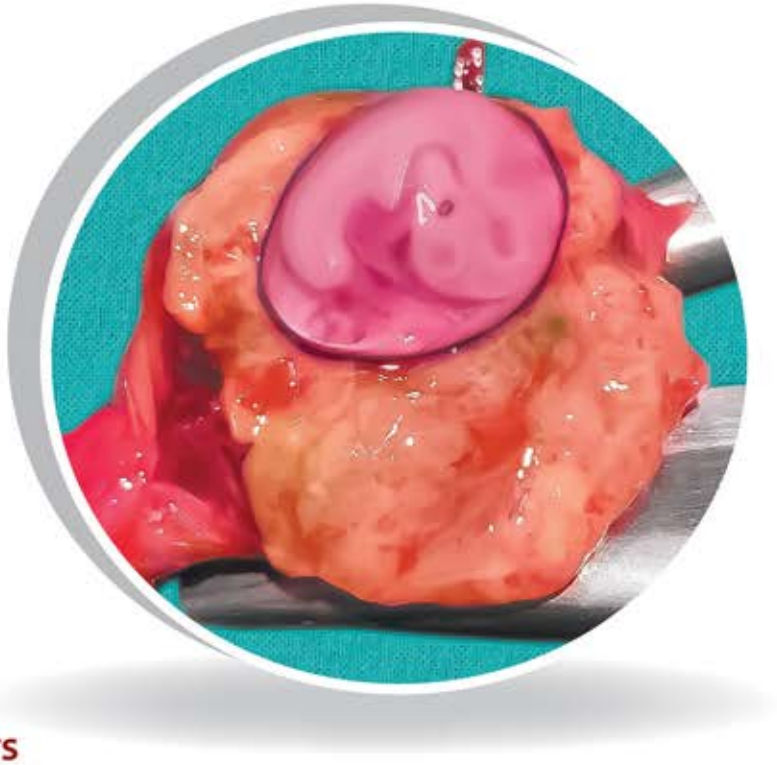

HIGHLIGHTS

- A comprehensive coverage of all subspecialties of Gynecology
- Thoroughly updated with recent advances in Gynecology
- Focused on practical aspects of clinical diagnosis and management
- Richly illustrated with rare clinical pictures, numerous tables, boxes, algorithms
- Model answers are well framed, structured and concise

Hiralal Konar

JAYPEE

CONTENTS

Section 1: Gynecology (OSCE)

1. **Objective Structured Clinical Examination (OSCE) in Gynecology** 3
   - **A. General Gynecology**
     - Case 1: Polycystic ovarian syndrome (PCOS) 3
     - Case 2: Endometriosis—A 5
     - Case 3: Endometriosis—B 7
     - Case 4: Pelvic pain 8
     - Case 5: Hydatidiform mole 9
     - Case 6: Cervical fibroid 10
     - Case 7: Menopause and hormonereplacement therapy (HRT) 11
   - **B. Adolescent Gynecology**
     - Case 8: Primary amenorrhea 12
   - **C. Menstrual Abnormalities**
     - Case 9: Secondary amenorrhea 14
     - Case 10: Hematocolpos (cryptomenorrhea) 14
   - **D. Infertility**
     - Case 11: Infertility—A 16
     - Case 12: Infertility—B 17
   - **E. Oncology**
     - Case 13: Hysterectomy and oophorectomy 19
     - Case 14: Postmenopausal bleeding 19
     - Case 15: Carcinoma cervix—A 21
     - Case 16: Carcinoma cervix—B 24
     - Case 17: Carcinoma cervix—C 25
     - Case 18: Carcinoma endometrium 26
     - Case 19: Carcinoma of the ovary 27
     - Case 20: Inherited cancers and the management 29
2. **Self-Assessment in Gynecology** 31

Section 2: Gynecology Discussion

3. **Recurrent Pregnancy Loss** 57
4. **Heavy Menstrual Bleeding** 62
5. **Congenital HIV Infection and AIDS** 66
6. **Urinary Incontinence** 68
7. **Fibroid Uterus: Management Issues** 70
8. **Polycystic Ovarian Syndrome** 73
9. **Hyperandrogenemia** 78
10. **Association of Subfertility with Endometriosis** 80
11. **Management of Pain in Endometriosis** 83

JAYPEE BROTHERS

12. Adenomyosis Uterus 87
13. High Intensity Focused Ultrasound in the Management of Leiomyomas and Adenomyosis 89
14. Menopause and the Management Issues 91
15. Abnormal Uterine Bleeding 94
16. Abnormal Uterine Bleeding: Investigations and Management Issues 96
17. Management of Adnexal Mass in Peri- and Post-menopausal Women 100
18. Use of Selective Progesterone Receptor Modulators in Gynecology 104

Section 3: Infertility and Assisted Reproductive Technology (ART)

19. Current Concept in Physiology of Ovulation 109
20. Infertility Evaluation and Management 113
21. Female Infertility 115
22. Male Infertility 123
23. Assisted Reproductive Technology (ART) 126
24. Reproductive Outcome in Women with Advanced Maternal Age 133
25. Anti-Mullerian Hormone in Reproductive Biology 135
26. Fertility Management Strategies for Low Responder 137
27. Surrogacy 140

Section 4: Contraception

28. Advances in Contraception including Contraceptive Measures Following Treatment of GTD 145
29. Long-acting Reversible Contraceptives 150
30. Male and Female Sterilization 152
31. Safe Abortion Service and WHO Guidelines 157

Section 5: Gynecological Oncology

32. Carcinoma of the Endometrium (Early Stage Disease) 167
33. Surgical Management of Endometrial Carcinoma 170
34. Role of Pelvic and Para-aortic Lymph Node Dissection in the Surgical Management of Endometrial Cancer 172
35. Ovarian Tumor with Low Malignant Potential 174
36. Gestational Trophoblastic Disease 177
37. Human Chorionic Gonadotropin and the Management of Gestational Trophoblastic Disease 181
38. Fertility Preservation in Women 183
39. Fertility Preserving Options for Women with Ovarian Cancer 185
40. Fertility Preserving Options for Women with Cervical Cancer 187
41. Fertility Preserving Options for Women with Endometrial Cancer 189
42. Chemotherapy in Gynecological Cancers 190
43. Radiotherapy in Gynecological Cancers 194
44. Sentinel Lymph Node Mapping in Gynecologic Cancers 197

JAYPEE BROTHERS

Section 6: Operative Gynecology

45. Abdominal Incisions 201
46. Tubal Ectopic Pregnancy 204
47. Cervical Insufficiency (Incompetence) 206
48. Surgical Management of Heavy Menstrual Bleeding 209
49. Surgical Site Infection 214
50. Endoscopy in Gynecology (Laparoscopic Surgery) 218
51. Prevention of Urinary Tract Injuries in Gynecological Laparoscopic Surgery 220
52. Management of Urinary Tract Injuries Following Laparoscopic Surgery 222
53. Place of Prophylactic Salpingectomy or Salpingo-oophorectomy in Current Gynecologic Practice 225
54. Surgical Management of Polycystic Ovarian Disease 227
55. Bariatric Surgery in Gynecology and Obstetrics 229
56. Robotic Surgery in Gynecology 232
57. Interventional Radiology in Obstetrics and Gynecology 235

Section 7: Maternal Sepsis

58. Maternal Sepsis: Prevention, Recognition and Management 241
59. Guidelines for use of Antimicrobials/Antibiotics in Gynecology 245

Section 8: Practice of SBA and EMQs

60. Model Questions and Answers for Practice of SBA 249
61. Model Questions and Answers for Practice of EMQs 258

Section 9: History in Obstetrics and Gynecology

62. Histoy in Obstetrics and Gynecology 265

Index *269*

JAYPEE BROTHERS

1 Chapter

Objective Structured Clinical Examination (OSCE) in Gynecology

A. GENERAL GYNECOLOGY

CASE 1: POLYCYSTIC OVARIAN SYNDROME (PCOS)

Case Summary

Mrs UC, 30-year-old receptionist, married for 3 years, was seen with the problem of oligomenorrhea-amenorrhea and infertility. She also complained of excess body hair (Fig. 1.1).

Her height was 5'1" and she weighed 80 kg. Her hormone assay done on D-2 of the cycle revealed FSH 5.0 IU/L, LH 13.01 IU/L. Testosterone 3.8 nmol/L prolactin 60 ng/mL; TSH 3.8 mU/L.



Fig. 1.1: Excess growth of facial (upper lip, cheek, chin and male-pattern beard) hair.

Q.1 What is the likely diagnosis?

Ans. Polycystic ovarian syndrome

Q.2 What is the current diagnostic criteria for PCOS?

Ans. According to ASRM/ESHRE, 2018 diagnosis of PCOS is based upon the presence of any two of the following three criteria:

1. Oligo and/or anovulation
2. Hyperandrogenism (clinical and/or biochemical)
3. Polycystic ovaries.

Other causes of hyperandrogenic conditions (adrenal) are to be excluded.

Q.3 What are the symptoms of PCOS?

Ans.
- Obesity
- Infertility
- Menstrual abnormality: Oligomenorrhea, amenorrhea, abnormal uterine bleeding (AUB)
- Hirsutism
- Characteristic skin changes (acanthosis nigricans)
- Acne
- HAIR-AN syndrome (*See* Dutta's Textbook of Gynecology, 8th Edition, p. 385).

Q.4 What are the characteristic changes in the ovary of a woman with PCOS?

Ans. Ovaries are enlarged in volume. The capsule is thickened. On cut section multiple (≥ 2) follicular cysts measuring about 2–9 mm in diameter are seen peripherally (Fig. 1.2). There is stromal hyperthecosis. Transvaginal sonography (TVS) can demonstrate the enlarged ovarian volume with peripherally arranged cysts.

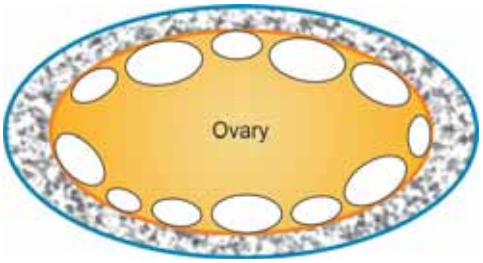

Fig. 1.2: Polycystic ovary.

Q.5 What other investigations would be appropriate for her?

Ans.
- Ultrasound scan (TVS) (Figs. 1.3A and B)
- To detect polycystic ovarian changes
- Investigations for other factors for infertility, e.g., tubal patency test and husband's semen analysis.

Q.6 What is the basic underlying pathology in this condition of PCOS?

Ans. Hyperandrogenic state and chronic anovulation.

Q.7 What are the biochemical abnormalities seen in a case of PCOS?

Ans.
- Hyperandrogenemia [(↑) testosterone, DHEA, androstenedione)]
- Hyperinsulinemia (insulin resistance)
- Hypersecretion of luteinizing hormone (LH)

JAYPEE BROTHERS

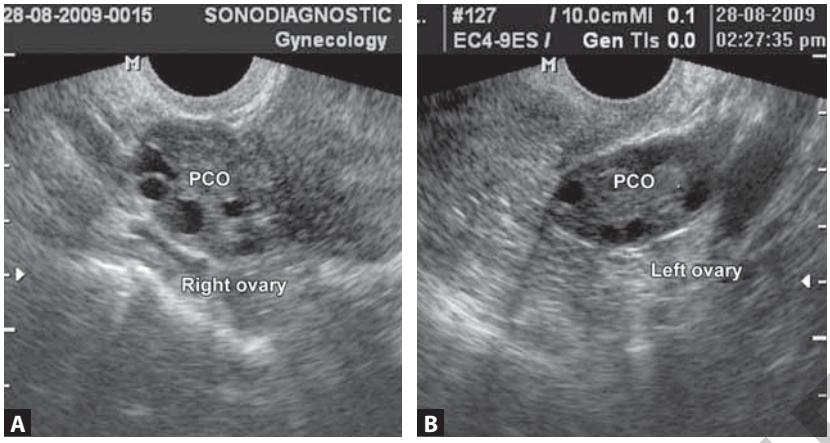

Figs. 1.3A and B: (A) Ultrasonography of the pelvis showing polycystic ovary (right); (B) Ultrasonography of the same patient showing polycystic ovary (left).

Courtesy: Dr (Mrs) S Ghosh, Professor BN Chakravorty, IRM, Kolkata, India.

- Hyperprolactinemia
- (↑) Serum estrogen
- (↓) Sex hormone-binding globulin (SHBG)
- (↑) Lipids.

Q.8 How can obesity and hyperinsulinemia cause hyperandrogenism?

Ans.
- ***Obesity*** → increased insulin resistance and raised insulin level stimulate → ovary (theca cells) → androgens (↑) : ***Obesity*** → (↓) SHBG → (↑) androgens (free).
- ***Hyperinsulinemia*** → ovarian theca cells → (↑) androgens: ***increased insulin*** → (↓) hepatic synthesis of SHBG → more (↑) free androgens.

Q.9 What are the long-term consequences in a woman suffering from PCOS?

Ans.
- Risk of developing diabetes mellitus due to insulin resistance.
- Risk of endometrial carcinoma due to unopposed action of estrogen.
- Risk of developing hypertension and cardiovascular disease due to abnormal lipid profile (dyslipidemia).

Q.10 What is the aim of management of PCOS?

Ans. Aim of treatment is to individualize the patient for her presenting symptoms like infertility, obesity or menstrual abnormality. In obese patients, weight reduction is essential.

Q.11 How do you treat hyperandrogenemia?

Ans.
- Weight reduction
- Combined oral contraceptive pills
- GnRH agonists
- Cyproterone acetate
- Spironolactone
- Flutamide.

Q.12 What medical management will improve her fertility status?

Ans. Weight reduction and induction of ovulation. Adjuvant drugs may be needed (e.g., metformin, bromocriptine) depending upon the associated abnormalities.

Q.13 If the woman is desirous of pregnancy how can you help her?

Ans. Ovulation of induction is to be done as she suffers from chronic anovulation. However, other factors (male factor, tubal patency tests) should be normal.

Q.14 What drug is commonly used for induction of ovulation?

Ans.
- Clomiphene citrate
- However, clomiphene citrate is to be combined with other drugs when other biochemical abnormalities are associated.
  - Clomiphene citrate + metformin → where there is obesity and hyperinsulinemia.
  - Clomiphene citrate + bromocriptine → where there is associated hyperprolactinemia.

Q.15 What is the place of insulin sensitizers in the management of women with PCOS desiring for conception?

Ans. Women with PCOS with body mass index more than 25 are often found insulin resistant. Along with weight reduction, treatment with metformin (insulin sensitizer) is found to reduce hyperinsulinemia and hyperandrogenemia. Pioglitazone and rosiglitazone are also being used in cases, resistant to metformin. Metformin is given in a dose 500 mg thrice daily.

Q.16 What are the different surgical methods?

Ans. Laparoscopic ovarian drilling (LOD) or laser (CO_2) vaporization of the cysts is usually done. LOD reduces systemic and intraovarian androgen levels. The woman ovulates spontaneously following LOD (*See* Ch 54).

JAYPEE BROTHERS

CASE 2: ENDOMETRIOSIS—A

Case Summary

Mrs PL, 24-year-old lady, married for 1 year, complaining of pelvic pain and deep dyspareunia. She was advised diagnostic laparoscopy which revealed the pathology (Fig. 1.4). She does not wish to become pregnant at present.

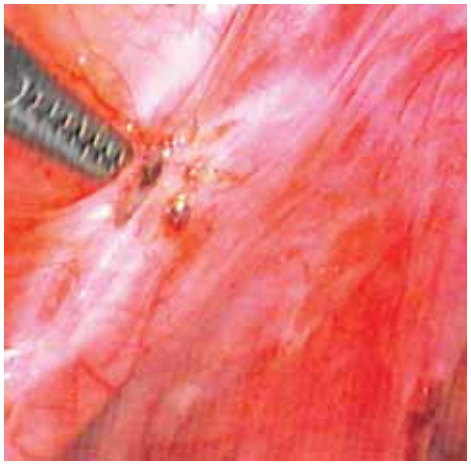

Fig. 1.4: Pelvic endometriosis.

Q.17 What is the likely diagnosis?

Ans. Pelvic endometriosis.

Q.18 What is endometriosis?

Ans. It is the presence of functioning endometrium (both glands and stroma) in sites other than the uterine mucosa.

Q.19 What are the common sites of endometriosis?

Ans.
- Ovary
- Uterosacral ligaments
- Rectovaginal septum
- Pouch of Douglas (POD)
- Sigmoid colon
- Abdominal scar.

Q.20 What are the other symptoms?

Ans. Abnormal menstruation like menorrhagia, dysmenorrhea (secondary), dyspareunia, pain during defecation, rectal bleeding. She may be asymptomatic.

Q.21 What is the naked eye appearance of pelvic endometriotic lesions?

Ans. Lesions may appear as:
- Small black dots (powder burns)
- Red flame shaped areas
- White patches
- Peritoneal windows
- Subovarian adhesions
- Puckering of peritoneum
- Ovaries may be involved—chocolate cysts
- White peritoneal areas.

Q.22 What are the important symptoms of pelvic endometriosis?

Ans.
- Some patients remain asymptomatic (25%)
- Dysmenorrhea (50%)
- Abnormal menstruation—menorrhagia, polymenorrhea
- Infertility (40–60%)
- Dyspareunia
- Pelvic pain
- Abdominal pain
- Bladder symptoms (dysuria)
- Bowel symptoms (rectal bleeding)
- Pain during defecation.

Q.23 How the diagnosis of pelvic endometriosis is confirmed?

Ans. It is commonly done by diagnostic laparoscopy.

Q.24 What is the place of serum CA-125 in the diagnosis of pelvic endometriosis?

Ans. Measurement of serum CA-125 levels is not a diagnostic tool because of its low sensitivity (< 50%). It may be used to predict the recurrence of endometriosis after therapy.

Q.25 What are the causes of infertility in a woman with pelvic endometriosis?

Ans. The possible cause of infertility are:
- ***Ovarian dysfunction:*** Anovulation, defective folliculogenesis or luteal phase defect.
- ***Tubal dysfunction:*** Pelvic adhesions, causing distorsion of normal tube ovary relationship.
- ***Others:*** Abnormal peritoneal fluid, implantation failure, miscarriage.

Q.26 What are the endocrine abnormalities associated with endometriosis?

Ans.
- Corpus luteum insufficiency
- Raised prolactin level
- Luteolysis due to increased PGF2α.

Q.27 What associated condition such a patient may present with?

Ans. Infertility.

Q.28 What are the complications of endometriosis?

Ans.
- Leakage or rupture of chocolate cyst
- Infection of chocolate cyst
- Infertility
- Obstructive features (ureteral obstruction).

Q.29 What are the different modalities of therapy for pelvic endometriosis?

Ans.
- Expectant
- Medical NSAIDs: Hormonal
- Surgery
- Conservative

JAYPEE BROTHERS

- Combined surgical and medical
- Definitive
- Assisted reproduction (*See* Ch 23).

Q.30 What are the factors that determine the type of treatment to a particular woman?

Ans. To an individual woman the determining factors are:

- Age of the woman
- Size and extent of lesion
- Severity of symptoms
- Desire for a child
- Stage of the disease [American Fertility Society (AFS) scoring system—*See* Dutta's Textbook of Gynecology, 8th Edition, p. 257]
- Results of previous therapy.

Q.31 What are the different hormones that can be used for the treatment of pelvic endometriosis?

Ans.

- Combined oral contraceptives (COCs)
- Progestogens
  - Oral:
    - Medroxyprogesterone acetate
    - Dydrogesterone
    - Dienogest
    - Parenteral (IM): Medroxyprogesterone
    - Intrauterine contraceptive device (IUCD): Levonorgestrel intrauterine system (LNG-IUS)
  - Danazol
  - Gestrinone
  - GnRH analogs.

Q.32 What are the important side effects of danazol and GnRH analogs?

Ans.

- ***Danazol:*** It causes symptoms due to pseudomenopause and it is less tolerated.
- ***GnRH analogs:*** It works by creating medical oophorectomy compared to danazol, GnRH analogs are well-tolerated.

Q.33 What are the indications of surgery for pelvic endometriosis?

Ans.

- Symptomatic endometriosis which is not responsive to hormone therapy.
- Severe endometriosis—to correct the distortion of pelvic anatomy or for improvement of symptoms.
- Chocolate cyst ≥ 4 cm needs ovarian cystectomy and adhesiolysis.

Q.34 What are the different types of surgery that can be done?

Ans. Either by laparotomy or laparoscopy.

Q.35 What is meant by conservative surgery?

Ans. Preservation of the reproductive organs and restoration of their anatomy for enhancement of fertility (function).

Q.36 What is meant by expectant treatment?

Ans. Expectant treatment means doing nothing actively. The woman is kept under observation.

Q.37 What is the place of expectant treatment?

Ans. Role of any treatment for minimal to mild endometriosis is controversial. Cumulative pregnancy rate is similar following expectant treatment and that after conservative surgery.

Q.38 Who are the cases for expectant treatment?

Ans. Minimal endometriosis when observed in

- Unmarried women
- Young married woman who is desirous of a baby
- Women approaching menopause.

Q.39 What type of laparoscopic surgery is commonly done?

Ans. Destruction of endometriotic implants over the peritoneal surface is commonly done. It is done by diathermy or by laser vaporization. Ovarian endometrioma (chocolate cyst) can be resected laparoscopically. Laparoscopic uterosacral nerve ablation (LUNA) is done when pain is very severe.

Division of adhesions (adhesiolysis) can also be done by laparoscopy.

Q.40 What are the treatment options for this woman?

Ans. ***Combined oral contraceptive pill*** for a period of 6–9 months would be most appropriate for her. Continuous therapy without the usual 7 days break would make her amenorrheic. This will help regression of the endometriotic deposits. This will also improve her symptoms. At the same time contraception is also provided.

Other options depending on the severity of endometriosis would be:

- ***Medical therapy:*** Continuous progestogen, dienogest or GnRH analogs.
- ***Surgical therapy:*** Laparoscopic laser or electrodiathermy to ablate the endometriotic implants.

Q.41 What would be the appropriate management when she desires to conceive?

Ans. Pregnancy itself provides remission to the problem. For this case, following the initial treatment, expectant management would be appropriate for next 6 months. About 60–70% women will become pregnant within a year provided there is no other factor for infertility.

Q.42 What is the optimum treatment for scar endometriosis?

Ans. Treatment is done by excision. Hormone therapy is ineffective.

JAYPEE BROTHERS

Q.43 What is adenomyosis?

Ans. Adenomyosis is a condition when there is ingrowth of endometrium (both the glands and stroma) directly within the myometrium (*See* Ch 12).

Q.44 How does a woman with adenomyosis present?

Ans. Usually the woman is parous, with age above 40 years.

Common symptoms are:

- Menorrhagia
- Dysmenorrhea.

Q.45 How can you differentiate a fibroid uterus from an adenomyosis?

Ans. *See* Ch 12.

Q.46 What should be the treatment of adenomyosis in a parous and elderly woman?

Ans.

- Treatment of adenomyosis (Figs. 1.5A and B) is predominantly surgical.
- Medical management (hormones) is often ineffective.
- Conservative surgery includes partial resection of adenomyomata.
- Total hysterectomy with or without bilateral salpingo-oophorectomy is the optimum treatment for a woman who is parous and aged.
- Currently, LNG-IUD is being used and found to be effective in improving the symptoms of menorrhagia and pelvic pain.

CASE 3: ENDOMETRIOSIS—B

Case Summary

Mrs BK, 24-year-old, married lady has been examined in the outpatient clinic for her pelvic pain which gets worse during menstruation.

Q.47 What more relevant questions you will ask her to make the provisional diagnosis?

Ans. Regarding the pain, e.g., character of pain, duration, exact relationship with the period, deep dyspareunia and fertility status.

Q.48 What clinical signs will help you to make the differential diagnosis?

Ans. Pelvic tenderness, nodularity in the pouch of Douglas, fixed retroversion of the uterus, adnexal mass, tenderness and bulky uterus. The differential diagnosis includes pelvic endometriosis, adenomyosis, chronic pelvic inflammatory disease.

Q.49 To confirm the diagnosis what single investigation would be most valuable?

Ans.

- Diagnostic laparoscopy by double puncture procedure.
- Laparoscopy revealed the diagnosis (Fig. 1.6).

Q.50 Is this pathology going to affect her future fertility?

Ans. There is an association of pelvic endometriosis and infertility. Amongst the infertile patients, 15%

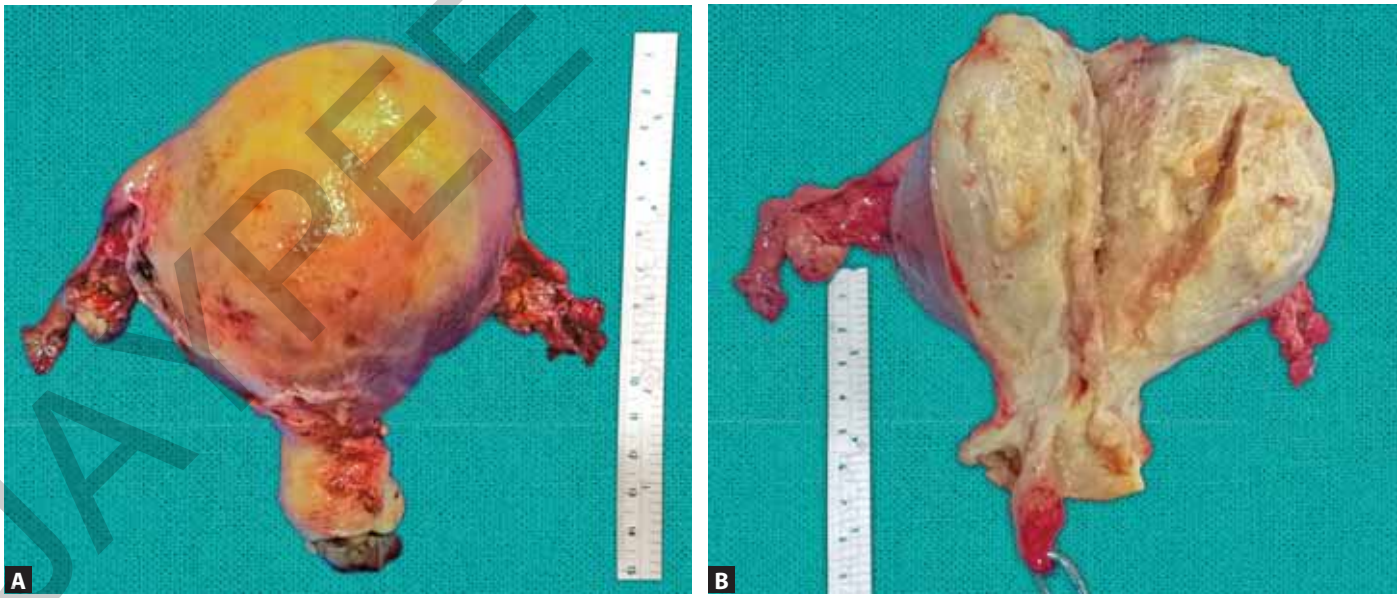

Figs. 1.5A and B: (A) Postoperative specimen of a uterus with tubes and ovaries. Mrs SE, a 46-year-old, parous lady, was admitted for menorrhagia and intractable dysmenorrhea. She did not respond to any medical therapy. She was investigated. She underwent hysterectomy and bilateral salpingo-oophorectomy. The uterus is seen uniformly enlarged; (B) The specimen of the same patient is cut opened to show myohyperplasia with hemorrhagic spots within the myometrium.

JAYPEE BROTHERS

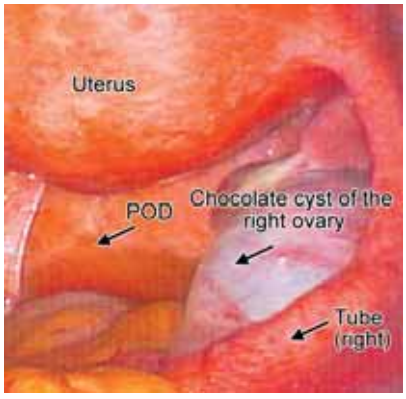

Fig. 1.6: Chocolate cyst of the right ovary (arrows).

suffer from endometriosis. Whereas patients with endometriosis suffer from infertility in 40–60% cases. The possible explanations are—anovulation, luteal phase defect, luteinized unruptured follicle syndrome, pelvic adhesions, dyspareunia, increased macrophage activity, altered prostaglandin balance and altered immune response.

Q.51 Should a patient with mild endometriosis be treated?

Ans. There is no advantage of any therapy over expectant management in cases with minimal or mild endometriosis. The association of infertility and endometriosis is not absolute unless there is tubal obstruction or extensive pelvic adhesions.

Q.52 What would be the appropriate treatment for this patient?

Ans. The content of chocolate cysts can be drained and the cavity is to be lavaged with normal saline. The lining of the cyst wall is then separated from the ovarian tissue. This may be done either by laparoscopy or by laparotomy. The principle of surgery is similar to ovarian cystectomy. Bleeding points are electrocoagulated by bipolar diathermy. In a small size chocolate cyst, the contents are aspirated and the cavity is irrigated repeatedly. This may be done under TVS guidance or laparoscopically under anesthesia.

Q.53 What is the overall result of laparoscopic cystectomy for endometrioma?

Ans. It is effective in relieving pain in about 74% of cases of mild to moderate disease. Pregnancy rate is about 60% in cases with moderate disease. However, improved pregnancy rate is observed within the first 6 months of conservative surgery.

CASE 4: PELVIC PAIN

Case Summary

Mrs CM, 36-year-old lady, had been suffering from lower abdominal pain and severe deep dyspareunia for last 8 months.

Q.54 What are the common causes of acute pelvic pain in gynecology?

Ans.
- Acute pelvic inflammatory disease (PID)
- Ruptured chocolate cyst
- Twisted ovarian cyst
- Ruptured corpus luteum cyst
- Disturbed tubal ectopic pregnancy
- Ovarian hyperstimulation syndrome.

Q.55 What are the common causes of chronic pelvic pain?

Ans.
- Dysmenorrhea
- Premenstrual tension syndrome
- Pelvic endometriosis
- Ovarian remnant syndrome—trapped or residual ovarian syndrome
- Psychosomatic
- Pelvic vericosities
- Uterine fibroid
- Adenomyosis
- Ovarian cyst
- Pelvic inflammatory disease (PID) (chronic)
- Retroversion or prolapse of the uterus

Q.56 What are the causes of dyspareunia?

Ans. ***Superficial***
- Narrow introitus
- Tough hymen
- Tender perineal scar
- Vulval infection
- Vulvar vestibulitis syndrome
- Vaginal—septum, infection, agenesis.

Deep
- Pelvic endometriosis
- Chronic PID
- Prolapsed ovary in the polycystic ovarian disease (POD).

Q.57 Mention some of the important causes of postmenopausal bleeding.

Ans.
- Senile endometritis
- Senile vaginitis
- Dysfunctional uterine bleeding
- Decubitus ulcer
- Genital malignancy:
  - Carcinoma of the cervix, endometrium, vagina, vulva, fallopian tube
  - Uterine sarcoma.
- Retained foreign body—pessary, IUCD (Fig. 1.7)
- Urethral caruncle
- Withdrawal bleeding following estrogen intake.

JAYPEE BROTHERS

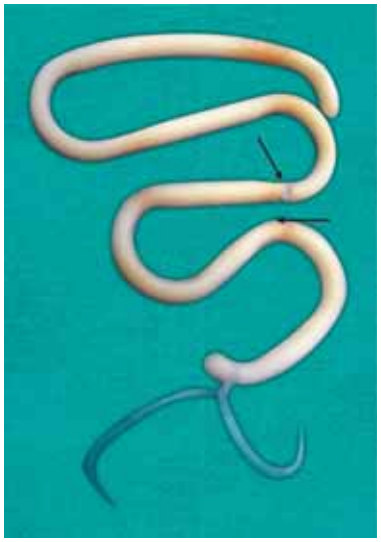

Fig. 1.7: Lippes loop. This has been removed from a 65-year-old lady hysteroscopically. She presented with postmenopausal bleeding. She had this at her age of 27 years. It was embeded within the endometrium and became brittle (arrows).

CASE 5: HYDATIDIFORM MOLE

Case Summary

Mrs AL, 24-year-old lady, was admitted in her first pregnancy at 16 weeks of amenorrhea with vaginal bleeding and passage of grape-like structures. On examination she looked pale, uterus was found 20 weeks size. There was no FHS on auscultation.

Q.58 What is the provisional diagnosis?

Ans. Hydatidiform mole.

Q.59 What investigations should be done for her?

Ans. Ultrasonography of the uterus (Fig. 1.8) and urine or serum for β-hCG. Once the diagnosis is confirmed, other investigations are complete hemogram, ABO and Rh-grouping, LFT and X-ray chest and thyroid profile.

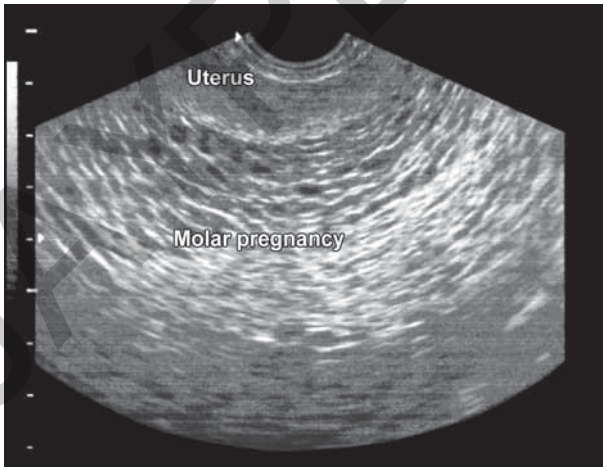

Fig. 1.8: Ultrasonography—snowstorm appearance in hydatidiform mole.

Courtesy: Dr (Mrs) S Ghosh, Professor BN Chakravorty, IRM Kolkata, India.

Q.60 What is the initial management for this problem?

Ans.
- Correction of anemia with blood transfusion
- To prevent infection
- Suction and evacuation of the uterus with or without oxytocin drip should be done. Tissue should be sent for histological examination.

Q.61 What are the common complications of this problem?

Ans.
- Hemorrhage
- Infection
- Pre-eclampsia
- Perforation of the uterus
- Respiratory distress due to pulmonary embolization of trophoblastic cells
- Coagulation failure
- Development of choriocarcinoma (2–10% cases).

Q.62 How should this patient be followed up and for how long?

Ans. Serial urinary β-hCG estimation weekly till negative. Usually, it becomes negative by 4–6 weeks time. Once negative, she is followed up at every month with serum hCG report for 6 months to 1 year.

Q.63 What precautionary measures she should be advised while on follow-up?

Ans. She should avoid pregnancy for at least 6 months to 1 year. For contraception, she can use barrier methods. Combined oral pills (low dose) may be used following normalization of β-hCG.

Q.64 What are the reasons that the patient needs to be followed up following initial treatment?

Ans.
- Detection of cases with persistent trophoblastic disease.
- Early detection of choriocarcinoma.

Q.65 What is her prospect of future pregnancy and chance of recurrence of the problem?

Ans. Prospect of future successful pregnancy is high, provided she is followed up. The risk of recurrence is less than 5%.

Q.66 What is the karyotype pattern of a complete hydatidiform mole and that of a partial mole?

Ans. In complete moles—karyotype pattern in majority is normal—46XX (90%). There is fertilization of 'an empty ovum' by a single sperm carrying 23 chromosomes. The usual 46XX chromosome pattern is the result of doubling of the paternal set of chromosomes (Fig. 1.9).

In about 10% cases, an empty ovum is fertilized by two sperm (dispermy), one carrying X and the other carrying Y chromosome. The chromosomal pattern is 46XY. All the chromosomes are derived paternally.

JAYPEE BROTHERS

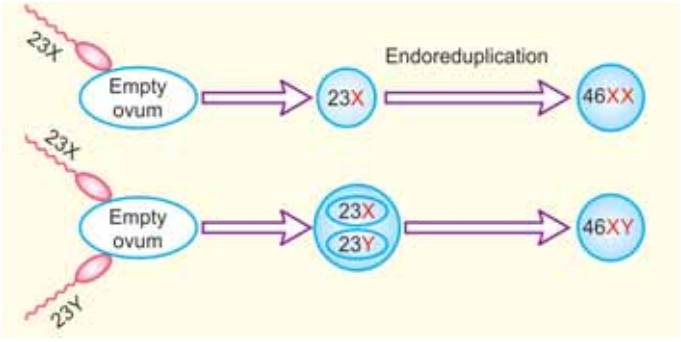

Fig. 1.9: Karyotype pattern of a complete mole—genome is entirely paternal in origin.

Partial moles (Fig. 1.10) consist of both the placenta and the fetus. Partial moles usually (90%) have triploid karyotype (Fig. 1.11). A normal ovum is fertilized by double sperm (dispermy), resulting in 69 chromosomes with sex chromosome configuration of 69XXX, 69XXY and 69XYY. The extra haploid set of chromosomes usually is derived from the father. The fetus is usually triploid, dies in the first trimester or is growth retarded with multiple malformations (syndactyly, hydrocephaly).



Fig. 1.10: Partial mole with a stillborn baby.
Courtesy: Dr S Mitra, Professor, Department of G and O, KPC Medical College, Kolkata.

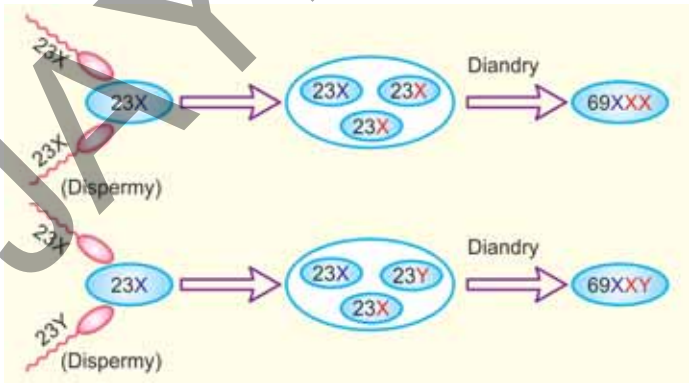

Fig. 1.11: Triploid chromosomal pattern of a partial mole. Genome is both paternal and maternal in origin.

CASE 6: CERVICAL FIBROID

Case Summary

Mrs CR, 40-year-old, had under gone surgery to remove her pathology. The specimen is seen in Figure 1.12.

Q.67 What is the diagnosis?
Ans. Posterior cervical fibroid.

Q.68 With what signs and symptoms she may have presented?
Ans. Vaginal discharge, pressure symptoms:
- ***Bowel:*** Constipation, incomplete evacuation.
- ***Urinary:*** Frequency, retention.
- Lateral pelvic wall pressure to cause leg pain or edema.

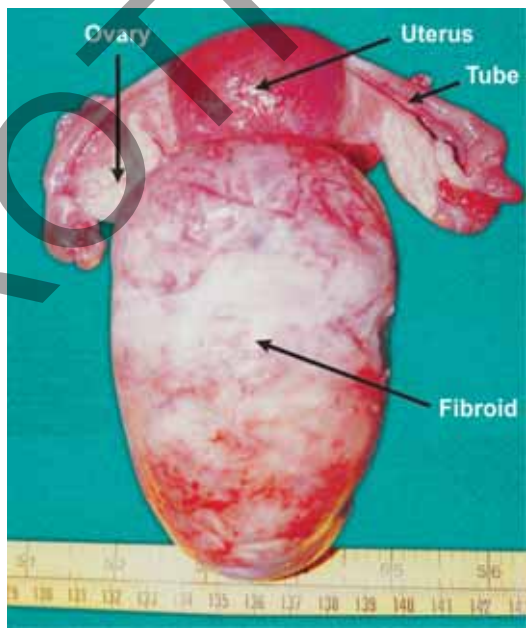

Fig. 1.12: Huge cervical fibroid.

Q.69 What surgery had been done for her?
Ans. Total abdominal hysterectomy with bilateral salpingo-oophorectomy.

Q.70 What are the dangers of this operation?
Ans. Hemorrhage, injury to bladder, rectum and the ureter.

Q.71 How the dangers could be minimized?
Ans.
- Delineation of the course as well as the proximity of the ureters to the fibroid could be done preoperatively by intravenous urography.
- Ureteric catheterization may be done preoperatively as a precautionary measure.
- Enucleation of the myoma first followed by hysterectomy.
- Preoperative GnRH analog therapy for 3 months may facilitate surgery.

JAYPEE BROTHERS

for detailed information on obstetrics & gynecology books, visit our website www.jaypeebrothers.com, for detailed information on obstetrics & gynecology books, visit our web

DC Dutta's Clinics in GYNECOLOGY

Salient Features

- A comprehensive review of the most subspecialties in Gynecology
- The content has been expanded with the recent advances extensively
- Transformative technologies have been discussed for the clinical diagnosis and management
- Strong emphasis on evidence-based medicine is given
- Hundreds of clinical problems and topics have been covered
- Profusely illustrated, numerous boxes, tables, imaging studies graphs and few rare photographs have been incorporated
- Clinically oriented Questions and Answers, SBAs and EMQs are presented for practice
- Model answers are framed in a concise and structured format
- Focused on practical aspects of clinical diagnosis and management
- Uniformity and consistency of standard for each chapter is an added beauty.

Printed in India

Available at all medical bookstores or buy online at www.jaypeebrothers.com

JAYPEE BROTHERS
Medical Publishers (P) Ltd.
EMCA House, 23/23-B, Ansari Road,
Daryaganj, New Delhi - 110 002, INDIA
www.jaypeebrothers.com

Join us on facebook.com/JaypeeMedicalPublishers

Shelving Recommendation
GYNECOLOGY

ISBN 978-93-5465-139-7