eebrothers.com, for detailed information on otorhinolaryngology books, visit our website www.jaypeebrothers.com, for detailed information on otorhinolaryngology books



2nd Edition

# Rhinoplasty
## An Expert Manual

Swapan Kumar Ghosh

*Foreword*
**Ullas Raghavan**

JAYPEE

# Contents


1. History of Rhinoplasty ..... 1
2. Anatomy and Physiology ..... 4
3. Instruments and Preoperative Assessment ..... 24
4. Anesthesia ..... 32
5. Basic Technique ..... 38
6. Incisions and Approaches ..... 40
7. Mobilization of Soft Tissues (Skeletonization) ..... 47
8. Nasal Spine ..... 50
9. Removal of Hump ..... 52
10. Septoplasty ..... 62
11. Osteotomies ..... 82
12. Shortening the Nose and Narrowing of Middle Third of Nose ..... 90
13. Tip Plasty ..... 92
14. Sutures and Dressing ..... 118
15. Postoperative Care ..... 120
16. Augmentation Rhinoplasty ..... 122
17. Rhinoplasty in Atrophic Rhinitis ..... 152
18. Surgery of the Crooked Nose ..... 158
19. Surgery of Alar, Columellar Deformity, and Vestibular Stenosis ..... 177
20. Nasal Reconstruction ..... 193
21. Revision Rhinoplasty ..... 211
22. Preservation Rhinoplasty ..... 220

*Index* ..... *227*

CHAPTER

10

# Septoplasty

## INTRODUCTION

Symptomatic deviated septum was found in 26% of patients with nasal obstruction in a study done on randomly chosen adults.[1] Trauma is a major cause of septal deviation. It may be a recent trauma or a childhood trauma. In childhood, even insignificant nasal trauma can produce unilateral microfractures affecting the growth of the septal cartilage. Trauma usually causes asymmetric damage to the septal cartilage. After some time, there will be overgrowth of the dominant side of the septal cartilage in comparison to the other side leading to a deviation with the convex side showing the dominant growth pattern.

Mladina classified the septal deviations into seven types:

- *Type 1:* Unilateral vertical crest in the valve area that does not reach the valve itself
- *Type 2:* Unilateral vertical crest in the valve area touching the nasal valve
- *Type 3:* Unilateral vertical crest located posteriorly in the nasal cavity
- *Type 4:* S-shaped deviation
- *Type 5:* Almost horizontal septal spur
- *Type 6:* Massive unilateral bony spur
- *Type 7:* Combination of these types.[2]

Freer (1902) and Killian (1904) introduced the submucous resection (SMR) operation for treatment of deviated septum. SMR is the foundation of modern septoplasty techniques.[3,4] In SMR, the dorsocaudal L-strut of at least 1 cm width is preserved while the rest of the nasal septum is removed. However, the straightened cartilage and bone pieces may be reinserted between the mucoperichondrial flaps to prevent complications.

In 1947, Cottle described the hemitransfixion incision and the procedure of conservative septal surgery.[5] In septoplasty, the area of deviation is corrected or resected leaving behind as much cartilage and bone as possible.

Septoplasty can be done at any age above 6 years.

The success of functional rhinoplasty depends on proper postoperative function of the septum, turbinates, and nasal valve area. During inspection of the nose in basal view, the caudal septum may be seen projecting into one of the nostrils and can reveal alar collapse during nasal breathing. Internal valve disorder can be diagnosed by Cottle test. Rhinomanometry is commonly used to assess nasal obstruction. Among various methods of rhinomanometry,

JAYPEE BROTHERS

**TABLE 1:** Nasal Obstruction Symptom Evaluation (NOSE) questionnaire.

| | *No problem* | *Mild* | *Moderate* | *Bad* | *Severe* |
|---|---|---|---|---|---|
| 1. Nasal congestion | 0 | 1 | 2 | 3 | 4 |
| 2. Nasal blockage or obstruction | 0 | 1 | 2 | 3 | 4 |
| 3. Difficulties in nasal breathing | 0 | 1 | 2 | 3 | 4 |
| 4. Disturbance in sleeping | 0 | 1 | 2 | 3 | 4 |
| 5. Difficulties in nasal breathing during exercise or exertion | 0 | 1 | 2 | 3 | 4 |
| Total score ( × 5): 0–100 | | | | | |

anterior active rhinomanometry is most commonly done. Measurement of intranasal volume, and the size and location of minimal cross-sectional area are done by acoustic rhinomanometry. But the use of rhinomanometry is limited and subjective symptoms reported by the patients and the validated Nasal Obstruction Symptom Evaluation (NOSE) questionnaire are used as subjective assessments of nasal airway **(Table 1)**. The NOSE survey is a brief questionnaire consisting of five self-rated items, each scored from 0 to 4. The NOSE score represents the sum of the responses to the five individual items and multiplying the sum by 5. The final score ranges from 0 to 100.

## INDICATIONS

- Nasal obstruction due to septal deviation.
- *Epistaxis:* Septoplasty is done to gain access to a posterior bleeding vessel for cauterization or packing. Septal deviation may also cause mucosal drying and crusting leading to intermittent epistaxis.
- *Sinusitis due to septal deviation:* Septoplasty may be combined with functional endoscopic sinus surgery (FESS).
- *Chronic dacryocystitis with septal deviation:* Endoscopic dacryocystorhinostomy (DCR) is combined with septoplasty.
- *Nasal bone fracture with dislocation or fracture of septum:* Reduction of nasal bone fracture is combined with septoplasty.
- In rhinoplasty, septoplasty is done to harvest septal cartilage graft and as a part of septorhinoplasty.
- *Hypophysectomy*: By transseptal-transsphenoidal approach.

For septoplasty, hemitransfixion incision is made at the caudal edge of the septal cartilage preserving the integrity of the membranous septum. Then, an anterior tunnel is made between the septal cartilage and the mucoperichondrium. Theoretically, unilateral elevation may leave a better blood supply to the septal cartilage, but elevation of the mucoperichondrium in both sides provides better exposure in severe septal deviations. The blood vessels of the septum run between the perichondrium and the mucosa.

JAYPEE BROTHERS

Elevation of the mucoperichondrial flap from the septal cartilage is done at the avascular subperichondrial plane during septoplasty. Unilateral anterior tunnel is usually made in concave side of the septum. Inferior tunnels are made by elevating mucoperiosteum separately on both the sides over the premaxillary and maxillary crests **(Fig. 1)**. The anterior and inferior tunnels are joined without causing any injury or perforation of the flaps **(Fig. 2)**. The inferior part of the septum is detached from the anterior nasal spine, premaxilla, and the maxillary crest and a strip of cartilage is excised along the inferior border. Next, the posterior part of the septal cartilage is detached from the bony septum by a firm pressure with the septal elevator. The septum can now be moved aside like a swinging door and gives access to the bony septum. The mucoperiosteal flaps are elevated from the ethmoid and vomer on both sides and the deviated part of the bony septum is either excised or fractured.

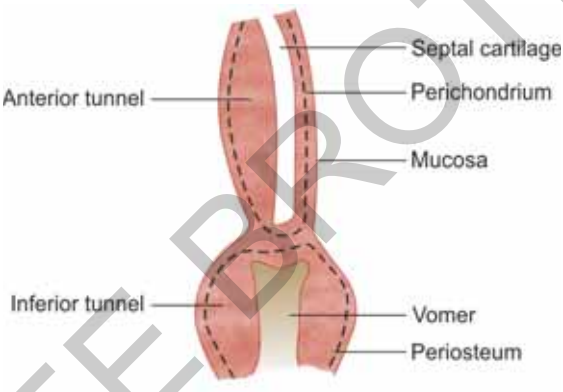


**Fig. 1:** Anterior tunnel and bilateral inferior tunnels during septoplasty.

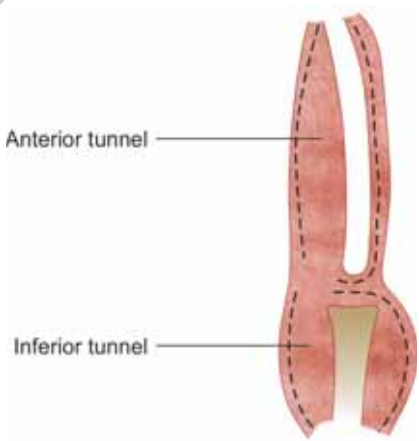


**Fig. 2:** Anterior and inferior tunnels made continuous in right side.

JAYPEE BROTHERS

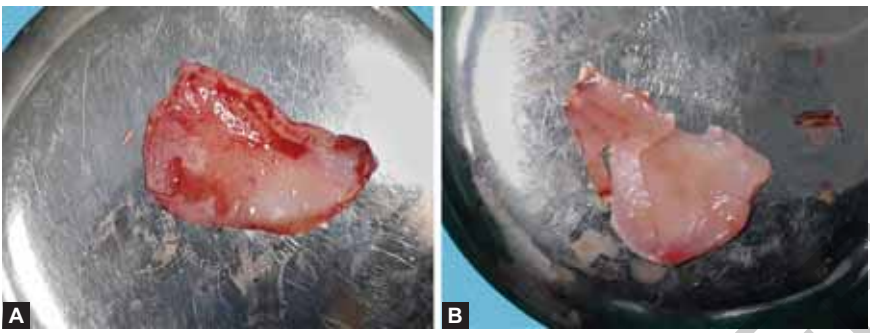


**Figs. 3A and B:** Deviated excised cartilage (A) can be made straight by incisions (B) and replaced between the mucoperichondrial flaps and sutured with the remnant cartilage.

The bony septum is sharply "bitten off" with a small Takahashi forceps. If the bony septum is twisted out, there is a chance of damage of the cribriform plate leading to cerebrospinal fluid (CSF) leak.

The bony spur along the floor is removed by a gouge but the anterior nasal spine is preserved. When the upper lateral cartilages prevent the straightening of the external deviation, these must be separated from the septum and spreader grafts are placed. The deviated septal cartilage can be weakened on its concave side by cross-hatching with partial-thickness incisions to relieve intracartilaginous tension.[6] Vertical scoring is done to correct vertical bending and horizontal scoring is done to correct horizontal bending of the cartilage. Parts of the excised cartilage may be replaced between the mucoperichondrial flaps, to avoid their direct adherence **(Figs. 3A and B)**.

A weakened deviated septum can be supported by bilateral stenting sandwich grafts. These grafts are placed in the submucoperichondrial plane on both sides of the deviation. Septal cartilage or perpendicular plate of ethmoid may be used as grafts. If ethmoid bone is used, small holes are made over it by a 3-mm drill bur. A 4-0 PDS suture is used to fix the stenting grafts.

For caudal deviation of septum, multiple vertical half-thickness cuts are done on the concave side. Excision of excess cartilage is done from the caudal end of the septal cartilage. Suture fixation is done with Vicryl suture taken from the concave side. Splinting by a small piece of septal cartilage or ethmoid bone may be done from the convex side. Vertical wedge resection on the convex side may also be done. The caudal end of the septum is fixed with the anterior nasal spine.

## Swinging Door Technique

Metzenbaum (1929) advocated the use of the swinging door technique **(Fig. 4)**.[7] A dislocated caudal septum can be corrected by the swinging door technique, with or without splints. Here, incision is made at the site of angulation. A small

JAYPEE BROTHERS

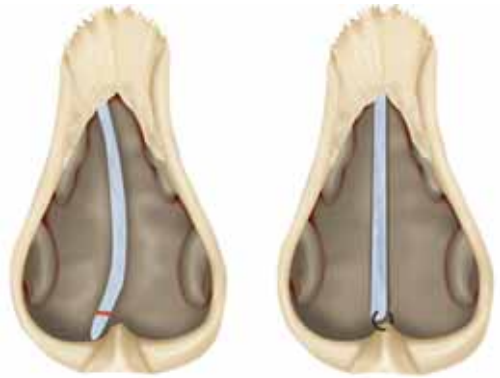

**Fig. 4:** Swinging door technique.

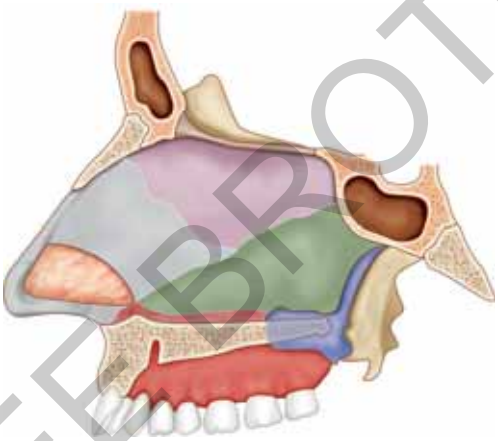

**Fig. 5:** Septal extension graft.

strip of cartilage can be excised at the site of angulation to achieve mobility. The caudal septum is fixed with the nasal spine by a suture taken either through the soft tissue over the spine area or through a drill hole made in the spine. Sometimes, the septum is "flipped" to the contralateral side of the nasal spine, and sutured to the periosteum. To accommodate the caudal septum in its new position, a pocket is made between the medial crura. In severe cases, caudal batten grafts or caudal septal extension grafts can be used to straighten the caudal septum **(Fig. 5)**. The batten graft is secured to the caudal septum by 4–0 PDS.[8]

Lastly, transfixation suture is done after making a new pocket in the columella.

During septoplasty, tears at the mucoperichondrial flaps usually occur at the junction of the septal cartilage with the crest of maxilla. As the resilient connective tissue fibers present at the junction are stronger than the

JAYPEE BROTHERS

mucoperichondrium itself; there is a chance of tearing the mucoperichondrium rather than the fibers of the junction if one attempts blunt dissection.[9] The nasal cavity should be packed lightly for 1 or 2 days.

Siegel et al. (2000) and Samad et al. (1992) observed that success rate for septoplasty operation is approximately 70%.[10,11]

Septoplasty can also be done by external approach or by endoscope in selected cases.

## SEPTOPLASTY BY EXTERNAL APPROACH

The external approach for septoplasty is a technique to correct severe septal deviations, caudal deformities, and mid-dorsal abnormalities when an endonasal approach may be inadequate. In external approach, nasal valve is corrected and dorsal onlay graft is placed if needed. Unobstructed access is obtained to the nasal spine and caudal part of the septum **(Figs. 6 and 7)**.

Spreader grafts are cartilage struts usually used to reconstruct the dorsal nasal roof, and restore the internal valves. The grafts are taken from the septal cartilage, but in case of shortage, conchal cartilage and costal cartilage can be used. They should be 20–25 mm in length, 3–4 mm in height, and 2–3 mm in thickness.[12] During septoplasty in crooked nose, the deviated dorsal segment can be corrected by splinting it with two spreader grafts from both sides by external approach. The concave side can be cross-hatched to break the cartilage memory. Splinting spreader grafts are sutured by 4–0 PDS to keep the dorsal segment straight **(Fig. 8)**.

In revision septoplasty, when the caudal segment is inadequate, a caudal septal extension graft should be used. The graft is sutured to the anterior nasal spine and to the caudal septum **(Figs. 9 and 10)**.[13]

L-strut graft is used when both the dorsal and caudal segments are deviated. Before placing the graft, cross-hatching of the segments is done. The graft is



**Fig. 6:** Elevation of perichondrium in septoplasty by external approach in cadaver.

JAYPEE BROTHERS



**Fig. 7:** Septoplasty by external approach.

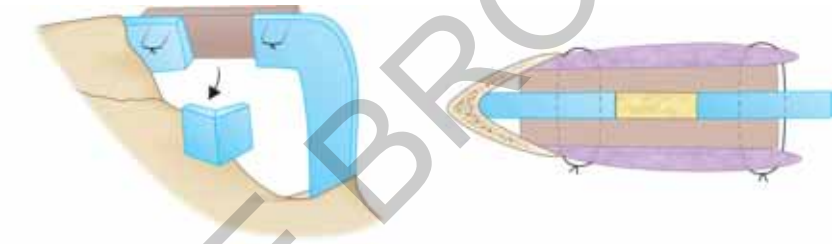

**Fig. 8:** Dorsal septal deviation corrected by excision and spreader grafts.



**Fig. 9:** Septal extension graft sutured with caudal septum.

JAYPEE BROTHERS



**Fig. 10:** Suturing of septal extension graft in cadaver.

fixed to a piece of cartilage at the key area and to the anterior nasal spine by multiple sutures.[14] In revision cases, the sixth costal cartilage is used to make a one-piece L-strut.[15] If a big L-strut cannot be obtained, two different pieces of cartilage can be used to replace dorsal and caudal segments. The two pieces are sutured on each other to form an L-strut.[16] If septal cartilage is not obtained in sufficient quantity, conchal cartilage or slices made from eighth rib can be taken as graft.[17]

### Tongue-in-groove Technique

The "tongue-in-groove technique," when used in combination with septoplasty helps in correction of caudal septal deviations. Patients having a long caudal septum causing hanging columella are ideal for this technique.[18] Dissection is done to separate two medial crura. The medial crura are moved backward on the midline caudal septum in a "tongue-in-groove" manner and sutured to caudal septum with 5-0 PDS. Thus, procedures like trimming of caudal septum and placement of columellar strut are not required.[19]

## ENDOSCOPIC SEPTOPLASTY

Endoscopic septoplasty is a conservative technique where the elevation of the nasal septal flap can be limited minimizing trauma. Furthermore, diagnosing and treating abnormalities of the lateral wall of the nose can be done at the same sitting in the endoscopic approach.

The first endoscopic septoplasty techniques were described by Stammberger (1990) and Lanza (1991).[20,21]

JAYPEE BROTHERS

for detailed information on otorhinolaryngology books, visit our website www.jaypeebrothers.com, for detailed information on otorhinolaryngology books, visit our webs

# Rhinoplasty
## An Expert Manual

***Salient Features***

- This book is a completely revised, updated, and enlarged edition. A chapter on "Preservation Rhinoplasty" has been added
- It is written in simple and straightforward language with concise but comprehensive coverage of the subject and up-to-date information and explanatory illustrations
- It has many photographs of cadaver dissections describing anatomy of nose and surgical procedures
- Steps of the operations have been described with numerous preoperative and postoperative photographs of the patients
- Suits the requirements of medical students for MS (ENT) and plastic surgery examinations.

**Swapan Kumar Ghosh** MS DLO DNB is Professor, Department of ENT, Burdwan Medical College, Purba Bardhaman, West Bengal, India. He has been an Examiner for undergraduate and postgraduate students at various universities in India. He is a distinguished Teacher and has been actively engaged in teaching and training of undergraduate and postgraduate students for over 29 years. He is a pioneer in rhinoplasty surgery in eastern India. He has about 27 research publications in indexed journals. He has reviewed over 225 articles for publication in various national and international journals. He has delivered guest lectures on rhinoplasty in many continuing medical education (CME) programs and workshops. He went to the USA as a Visiting Physician in 2016. He presented papers on rhinoplasty at the International Conference in London in 2017 and ME-OTO conferences in Dubai in 2018 and 2024 as a faculty. He also attended "Advanced Rhinoplasty Cadaveric Dissection Course" in Singapore in 2019.

*Printed in India*

**Available at all medical bookstores or buy online at www.jaypeebrothers.com**




**JAYPEE BROTHERS**
**Medical Publishers (P) Ltd.**
EMCA House, 23/23-B, Ansari Road,
Daryaganj, New Delhi - 110 002, INDIA
www.jaypeebrothers.com

Join us on facebook.com/JaypeeMedicalPublishers

Shelving Recommendation
**OTOLARYNGOLOGY**

ISBN 978-93-5465-211-0