ers.com, for detailed information on ophthalmology books, visit our website www.jaypeebrothers.com, for detailed information on ophthalmology books

Get Full Access
with added Features at
Includes Surgical Videos
emedicine360.com

RETINA

Medical & Surgical Management



2nd Edition

Editor-in-Chief
Atul Kumar

Foreword
Shunji Kusaka

JAYPEE

RETINA

Medical and Surgical Management

SECOND EDITION

Editor-in-Chief

Atul Kumar
MD FAMS FRCS (Ed)
Professor and Chief
Dr Rajendra Prasad Centre for Ophthalmic Sciences
All India Institute of Medical Sciences
New Delhi, India

Associate Editors

Divya Agarwal MD DNB FAICO
Dr Rajendra Prasad Centre for Ophthalmic Sciences
All India Institute of Medical Sciences
New Delhi, India

Harpreet Kaur Narde MD
Dr Rajendra Prasad Centre for Ophthalmic Sciences
All India Institute of Medical Sciences
New Delhi, India

Nawazish Shaikh MD
Dr Rajendra Prasad Centre for Ophthalmic Sciences
All India Institute of Medical Sciences
New Delhi, India

Aman Kumar MS
Dr Rajendra Prasad Centre for Ophthalmic Sciences
All India Institute of Medical Sciences
New Delhi, India

Ayushi Sinha MD
Dr Rajendra Prasad Centre for Ophthalmic Sciences
All India Institute of Medical Sciences
New Delhi, India

Prabhav Puri MD
Dr Rajendra Prasad Centre for Ophthalmic Sciences
All India Institute of Medical Sciences
New Delhi, India

Raghav Ravani MD FICO
Dr Rajendra Prasad Centre for Ophthalmic Sciences
All India Institute of Medical Sciences
New Delhi, India

Foreword

Shunji Kusaka

JAYPEE BROTHERS

JAYPEE BROTHERS MEDICAL PUBLISHERS
The Health Sciences Publisher
New Delhi | London

Contents

Section 1: Basic Sciences and Diagnostics

1. **Clinical Anatomy and Physiology of Vitreous and Retina** 3
   Raghav Ravani, Divya Agarwal, Aman Kumar, Yogita Gupta, Rohan Chawla, Atul Kumar

2. **Retinal Imaging** 17
   Atul Kumar, Devesh Kumawat, Divya Agarwal, Raghav Ravani, Kavitha Duraipandi, Anu Sharma

3. **Electrophysiology** 49
   Raghav Ravani, Devesh Kumawat, Priyanka Ramesh, Divya Agarwal, Atul Kumar

4. **Diagnostic Ophthalmic Ultrasonography** 60
   Raghav Ravani, Divya Agarwal, Yogita Gupta, Meghal Gagrani, Atul Kumar

Section 2: Retinal Degenerations and Fundal Dystrophies

5. **Degenerative Myopia and Retina** 73
   Atul Kumar, Rohan Chawla, Devesh Kumawat, Divya Agarwal, Raghav Ravani

6. **Retinitis Pigmentosa and Allied Disorders** 85
   Vinod Kumar, Karthikeya R, Raghav Ravani, Annu Chohan, Prabhav Puri, Aman Kumar, Atul Kumar

7. **Hereditary Vitreoretinopathies** 96
   Vinod Kumar, Neha Goel, Aman Kumar, Divya Agarwal

8. **Macular Dystrophies** 100
   Vinod Kumar, Neha Goel, Karthikeya R, Aman Kumar

9. **Choroidal and Other Fundal Dystrophies** 113
   Vinod Kumar, Aman Kumar, Karthikeya R, Pradeep Kumar

Section 3: Macular Disease and Degeneration

10. **Central Serous Chorioretinopathy** 123
    Mayank Bansal, Aman Kumar, Divya Agarwal, Ashish Markan, Raghav Ravani, Itika Garg, Atul Kumar

11. **Age-related Macular Degeneration** 135
    Atul Kumar, Nawazish Shaikh, Divya Agarwal, Mayank Bansal, Raghav Ravani, Annu Chohan

12. **Choroidal Neovascular Membranes** 164
    Pranita Sahay, Nawazish Shaikh, Shilky Singh, Anand S Brar, Atul Kumar

13. **Vitreomacular Interface and Anomalous Posterior Vitreous Detachment** 179
    Vineet Mutha, Yogita Gupta, Divya Agarwal, Nawazish Shaikh, Atul Kumar

14. **Vitreomacular Traction** 183
    Atul Kumar, Nawazish Shaikh, Vineet Mutha, Meghal Gagrani, Kabiruddin Molla

JAYPEE BROTHERS

15. **Epiretinal Membranes** 189
Atul Kumar, Nawazish Shaikh, Kavitha Duraipandi, Raghav Ravani, Nasiq Hasan

16. **Macular Hole** 195
Atul Kumar, Harpreet Kaur Narde, Raghav Ravani, Manasa S, Aman Kumar, Divya Agarwal, Ankita Srivastava

17. **Myopic Foveoschisis** 209
Atul Kumar, Ayushi Sinha, Divya Agarwal, Raghav Ravani, Aditi Mehta, Sriram Simakurthy

18. **Optic Nerve Head Pit with Maculopathy** 214
Atul Kumar, Karthikeya R, Raghav Ravani, Ayushi Sinha, Yogita Gupta

19. **Submacular Hemorrhage** 219
Atul Kumar, Dheepak Sundar, Raghav Ravani, Ayushi Sinha, Farin Shaikh

20. **Cystoid Macular Edema** 228
Pranita Sahay, Raghav Ravani, Ayushi Sinha, Atul Kumar

21. **Low Vision Management in Retinal Diseases** 234
Anu Sharma, Ananya Goswami

Section 4: Retinal Vascular Disorders

22. **Retinal Arterial Occlusion** 251
Raghav Ravani, Sahil Agrawal, Yogita Gupta, Ananya Goswami, Vineet Mutha

23. **Ocular Ischemic Syndrome** 257
Raghav Ravani, Suman Lata, Rohan Chawla, Ananya Goswami, Atul Kumar

24. **Retinal Vein Occlusion** 261
Prateek Kakkar, Siddhi Goel, Atul Kumar, Ananya Goswami, Alisha Kishore

25. **Hypertensive Retinopathy and Choroidopathy** 278
Vineet Mutha, Raghav Ravani, Yamini Attiku, Ananya Goswami, Chirakshi Dhull

26. **Retinal Artery Macroaneurysm** 282
Raghav Ravani, Yogita Gupta, Abhidnya Surve, Ayushi Sinha, Atul Kumar

27. **Diabetic Retinopathy: Epidemiology, Pathogenesis, Classification and Clinical Trials** 287
Neha Goel, Vinod Kumar, Ayushi Sinha, Divya Agarwal, Atul Kumar

28. **Diabetic Macular Edema** 308
Stanford C Taylor, Cynthia Montana, Manthan Shah, Rajendra S Apte, Ayushi Sinha, Divya Agarwal

29. **Proliferative Diabetic Retinopathy** 332
Pramod S Bhende, Nagesha CK, Jaya Prakash V, Ayushi Sinha, Divya Agarwal

30. **Retinopathy in Hematological Disorders** 345
Prateek Kakkar, Rohan Chawla, Nasiq Hasan, Amit Gadkar, Ayushi Sinha, Atul Kumar

31. **Macular Telangiectasia** 355
Atul Kumar, Pooja Shah, Rohan Chawla, Kalathil Reshmi Shaji, Ayushi Sinha, Raghav Ravani

32. **Miscellaneous Retinal Vascular Diseases** 363
Prateek Kakkar, Nawazish Shaikh, Prabhav Puri, Farin Shaikh, Atul Kumar

JAYPEE BROTHERS

Section 5: Pediatric Retinal Disease

33. Etiopathogenesis, Clinical Features and Screening of Retinopathy of Prematurity 375
Parijat Chandra, Nitesh Salunkhe, Prabhav Puri, Kalathil Reshmi Shaji

34. Laser Treatment for Retinopathy of Prematurity 384
Mangat R Dogra, Deeksha Katoch, Prabhav Puri

35. Role of Antivascular Endothelial Growth Factor Drugs and Surgical Management of Retinopathy of Prematurity 391
Parijat Chandra, Ruchir Tewari, Prabhav Puri, Kalathil Reshmi Shaji

36. Familial Exudative Vitreoretinopathy 399
Atul Kumar, Dheepak Sundar, Rohan Chawla, Prabhav Puri, Deeksha Rani

37. Coats' Disease 405
Rohan Chawla, Shreyans Jain, Ruchir Tewari, Deeksha Rani, Prabhav Puri

38. Fundus Coloboma 409
Vineet Mutha, Anin Sethi, Prabhav Puri, Deeksha Rani, Atul Kumar

Section 6: Choroidal and Retinal Inflammations

39. Noninfectious Inflammations 419
Reema Bansal, Amod Gupta, Vishali Gupta, Deeksha Rani, Aman Kumar

40. Infectious Inflammation 434
Reema Bansal, Mohit Dogra, Deeksha Rani, Amod Gupta, Aman Kumar

Section 7: Surgical Retina

41. Retinal Detachment 449
Parveen Sen, Sufiyan Shaikh, Sharan Shetty, Ananya Goswami, Kaustubh Deshmukh

42. Basic Principles and Laser Delivery Systems 472
Atul Kumar, Kavitha Duraipandi, Raghav Ravani, Ananya Goswami, Sagnik Sen

43. Scleral Buckling 511
Parveen Sen, Sufiyan Shaikh, Sharan Shetty, Ananya Goswami, Kaustubh Deshmukh

44. Pneumatic Retinopexy 521
Atul Kumar, Devesh Kumawat, Raghav Ravani, Ananya Goswami, Sagnik Sen

45. Vitreous Substitutes 525
Raghav Ravani, Anin Sethi, Ananya Goswami, Atul Kumar, Harpreet Kaur Narde

46. Pars Plana Vitrectomy 536
Atul Kumar, Devesh Kumawat, Kalathil Reshmi Shaji, Raghav Ravani

47. Giant Retinal Tears 544
Atul Kumar, Devesh Kumawat, Kalathil Reshmi Shaji, Nawazish Shaikh, Raghav Ravani, Hemant K Joshi

48. Surgery for Proliferative Diabetic Retinopathy 550
Pramod S Bhende, Atul Kumar, Nawazish Shaikh, Vineet Mutha, Kalathil Reshmi Shaji

JAYPEE BROTHERS

49. Complications of Vitreoretinal Surgery 562
Parveen Sen, Sufiyan Shaikh, Sharan Shetty, Kaustubh Deshmukh, Kalathil Reshmi Shaji, Nawazish Shaikh

50. Posterior Dislocation of Lens 571
Devesh Kumawat, Vineet Mutha, Nasiq Hasan, Kalathil Reshmi Shaji, Nawazish Shaikh, Atul Kumar

51. Postoperative Endophthalmitis 578
Chaitra Jayadev, Raghav Ravani, Ayushi Sinha, Atul Kumar

52. Newer Innovations and Techniques in Vitreoretinal Surgery 595
Atul Kumar, Divya Agarwal, Rohan Chawla

Section 8: Ocular Trauma

53. Classification of Ocular Trauma and Evaluation of Patient 607
Thirumalesh MB, Astha Jain, Sumeet Agarwal, Prabhav Puri

54. Blunt Ocular Trauma 613
Thirumalesh MB, Astha Jain, Deeksha Rani, Prabhav Puri, Divya Agarwal, Alisha Kishore

55. Optic Nerve Avulsion 621
Thirumalesh MB, Vineet Mutha, Prabhav Puri, Abhishek Sheemar, Sagnik Sen

56. Sympathetic Ophthalmia 623
Aditya Modi, Neha Pareka Sudhakar, Thirumalesh MB, Aswini Behera, Deeksha Rani, Raghav Ravani, Prabhav Puri

57. Post-traumatic Endophthalmitis 630
Thirumalesh MB, Raghav Ravani, Meghal Gagrani, Alisha Kishore, Deeksha Rani, Prateek Kakkar, Prabhav Puri

58. Retained Intraocular Foreign Body 633
Thirumalesh MB, Vineet Mutha, Prabhav Puri, Divya agarwal, Raghav Ravani, Atul Kumar, Deeksha Rani, Abhidnya Surve

59. Shaken Baby Syndrome 640
Pooja Shah, Raghav Ravani, Amit Gadkar, Prabhav Puri, Deeksha Rani

Section 9: Miscellaneous Retinal Conditions

60. Cancer Associated and Related Autoimmune Retinopathies 645
Ruchir Tewari, Rohan Chawla, Ayushi Sinha, Atul Kumar

61. Toxic Retinopathies 652
Vinod Kumar, Pradeep Kumar, Akshay Tayade, Ayushi Sinha, Ajay Panwar

62. Photic Retinopathy 661
Aditya Modi, Neha Pareka Sudhakar, Ayushi Sinha

63. Phakomatoses 668
Karthikeya R, Shashwat Behera, Alisha Kishore, Ayushi Sinha, Atul Kumar

Index 689

JAYPEE BROTHERS

Video Contents

Chapter No.	*Video Titles*
15	**Epiretinal Membrane (ERM) Peeling**
16	**Intraoperative Optical Coherence Tomography (iOCT) Guidance in Inverted Internal Limiting Membrane (ILM) Flap Technique for Macular Hole**
16	**ILM Peeling Technique**
17	**Myopic Traction Maculopathy (MTM) with Center Sparing ILM Peel**
18	**Optic Disc Pit Maculopathy**
19	**Submacular Bleed Management**
47	**Giant Retinal Tear (GRT) Surgery**
47	**GRT2**
50	**Phacofragmentation for Dislocated Nucleus**
58	**Retained Intraocular Foreign Body (RIOFB) Management**

JAYPEE BROTHERS

4

CHAPTER

Diagnostic Ophthalmic Ultrasonography

Raghav Ravani, Divya Agarwal, Yogita Gupta, Meghal Gagrani, Atul Kumar

INTRODUCTION AND HISTORY

Ultrasonography (USG) as a noninvasive imaging tool to obtain images has applications in medical science to aid in diagnosis and management of various pathologies. USG is based on the piezoelectric effect to produce acoustic waves more than 20 kHz. It is based on pulse-echo technique. Rapidly repeating bursts of ultrasonic energy are beamed into the ocular and orbital tissues, which are reflected back, depending upon the tissue reflectivity and are then detected, amplified, and converted to electronic display with the help of transducer.

Mundt and Hughes first used the USG as a diagnostic tool in the field of ophthalmology in 1956.[1] First cross-sectional (2D) scan was developed by Baum and Greenwood.[2] Bronson introduced contact B scan and the standardization of A scan[3] and combination of A scan instrument with contact B scan leading to modern day standardized echography was carried out by Ossoinig.[4,5] Coleman developed first ophthalmic 3D scan.[6] Recently, real-time digital 2D B-scan video recording and Doppler USG have become a part of the present day's standardized echography.[7-10]

Ophthalmic USG includes ocular USG and orbital sonography. This chapter deals with ocular USG in reference to retina.

PHYSICS OF THE EQUIPMENT

The ultrasonic transducer is the heart of the USG apparatus. It produces and transmits the sound waves to the ocular tissues. The reflected waves are collected, and converted into electric signal by the transducer depending upon the reflectivity of the tissue. It is the frequency of the transducer that determines the depth of penetrance and resolution of the image. As the frequency increases the resolution of image and thus of the small defects or details in the eye increases, but the penetration decreases. Thus only limited frequencies can be used clinically. The posterior segment scan uses 8–10 MHz frequency while the anterior segment ultrasound biomicroscopy (UBM) with improved resolution uses frequency of 50–100 MHz.[11]

ULTRASOUND IMAGING

Examination Modes

Various examination modes in ophthalmic USG are:

- *A scan:* Amplitude modulation scan
- *B scan:* Brightness modulation scan
- Vector A scan
- Doppler USG
- UBM.

A scan: Biometry for axial length and corneal thickness measurement can be done using A scan. It is called as Time-Amplitude scan. The probe used in A scan has probe frequency of around 8 MHz, which emits parallel and nonfocused ultrasound beam with beam width of 5 mm at highest dB and 0.5 mm width at lowest dB. The machine uses mathematical and physics formulae to calculate the speed of sound as it passes through different ocular tissues. This can then be used to measure distance within ocular structures and thus axial length **(Fig. 4.1)**.

B scan: It is used for diagnostic purpose and for echo structure assessment. It is called as brightness mode 2D scan **(Fig. 4.2)**.

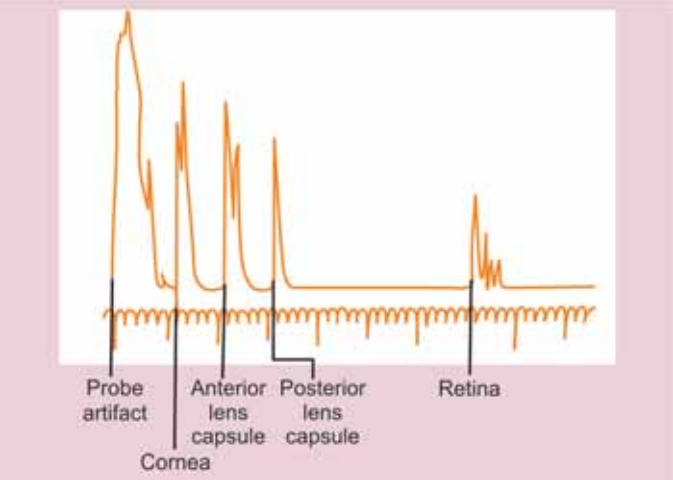

Fig. 4.1: An ophthalmic USG image in A-scan mode showing different tissue spikes.

JAYPEE BROTHERS

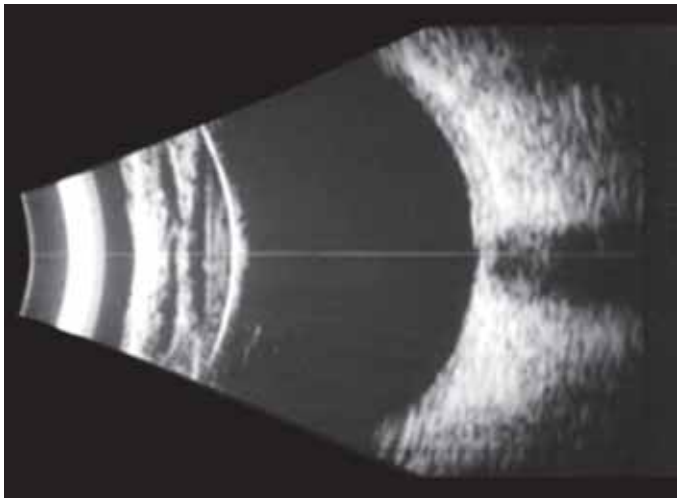

Fig. 4.2: Representative image of a normal B scan of eye.

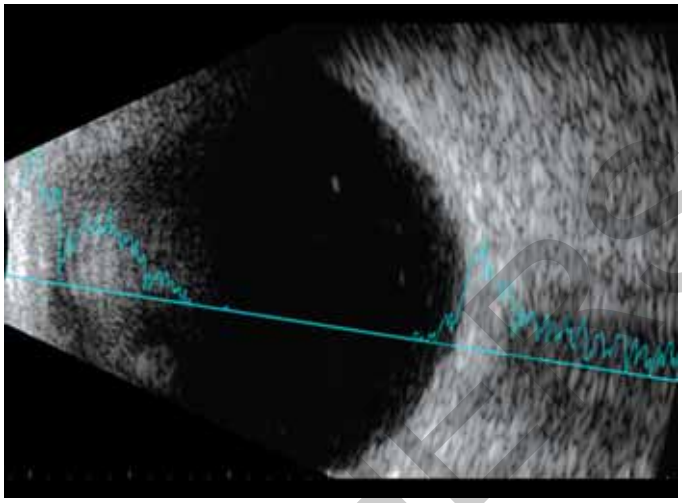

Fig. 4.3: Representative image of vector A scan.

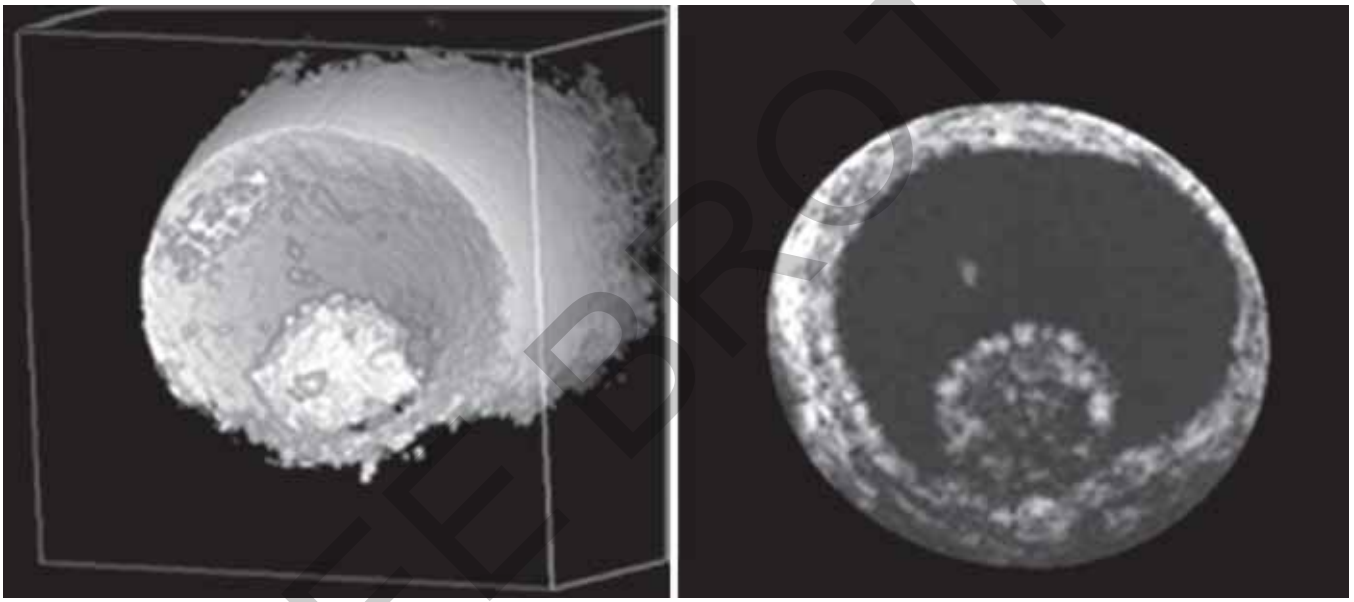

Fig. 4.4: Representative images of 3D scan of eye.

The probe used in B scan is thicker with a marker on the sleeve close to the transducer tip which serves as a guide for imaging orientation purposes such that the marker on the probe corresponds to the top of the scan plane. The transducer uses probe frequency of around 10 MHz, which emits focused sound waves.

Vector A scan: It is a combination of both A and B scans **(Fig. 4.3)**.

Doppler USG: It is important in vascular lesions and is obtained by using frequency shifts from acoustic reflections to measure movement within a tissue and flow within vessels. High flow and low flow states can be differentiated by designating false color codes to the images based on ultrasonic frequency of each.

Ultrasound biomicroscopy (UBM): This modality uses high-frequency echograms thus providing better resolution of anterior structures of the eye, especially the cornea, lens, iris and ciliary body. The probe used in UBM has an exposed transducer that is dipped in the cup of coupling fluid placed on the cornea for procuring high-resolution images. The probe is thicker than the B-scan probe with exposed tip with a marker for imaging orientation purposes such that marker on the probe always corresponds to the left side of a UBM scan.

Three-dimensional scan: Unlike some subspecialties, the use of 3D ultrasound in ophthalmology is limited. 3D ultrasonic images of the eye can be reconstructed from a series of scan planes[7-10] **(Fig. 4.4)**.

Examination Technique

The detailed imaging of the eye involves three views as per the probe positioning: axial, transverse, and longitudinal.

JAYPEE BROTHERS

Axial View

- *Horizontal axial view*: By placing the probe at the center of the cornea with marker positioned toward the nasal side **(Fig. 4.5)**, this view allows simultaneous imaging of the lens, optic nerve and the macula with nasal side oriented at top of the scan.
- *Vertical axial view*: By placing the probe at the center of the cornea and marker toward the superior aspect **(Fig. 4.5)**, this view allows simultaneous imaging of lens and the optic nerve.
- *Oblique axial view*: This scan is obtained by placing the probe at center of cornea and marker toward the superior aspect and rotating the probe 45° to the right or the left **(Fig. 4.5)**.

Transverse View

Transverse view provides lateral sweep of one quadrant of the fundus **(Fig. 4.6A)**.

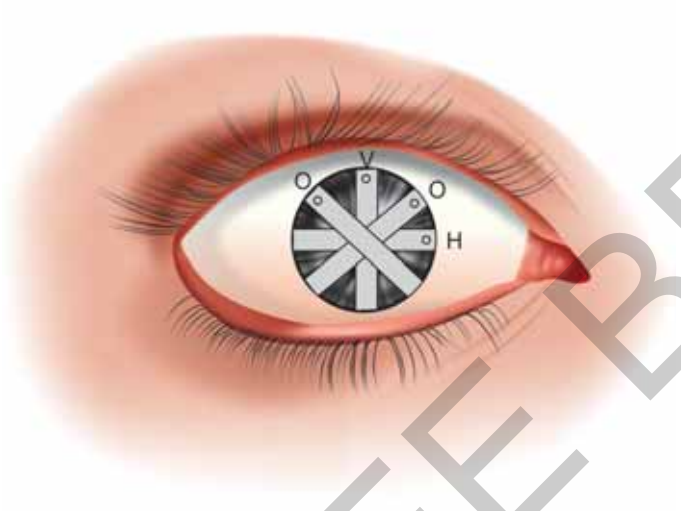

Fig. 4.5: Schematic diagram showing the technique for axial scan.

- *Horizontal transverse view*: The tip of the probe is placed on the limbus pointing either superiorly or inferiorly with marker positioned at the nasal side of the eye to image the superior or inferior fundus, respectively such that the nasal side is oriented at the top **(Fig. 4.6B)**.
- *Vertical transverse view*: The tip of the probe is placed on the nasal limbus with probe pointing toward the opposite side and marker positioned on the superior side to view the temporal fundus such that the superior side is oriented at top of the scan **(Fig. 4.6B)**. Similarly changing the position of the probe to the temporal limbus can image the nasal fundus.

Longitudinal View

Longitudinal view provides an anteroposterior scan of a specific meridian of the fundus **(Fig. 4.7A)**.

The longitudinal scans are described as clock hours according to the placement of the probe **(Fig. 4.7B)**. The probe is place on the limbus pointing to the opposite direction with marker directed toward the limbus such that the top of the scan is the anterior peripheral side, while the bottom is the posterior side (close to the optic nerve). To obtain a more peripheral view of a particular meridian, the probe can be shifted away from the limbus.

Ultrasound in Ocular Conditions

Retinal Detachment

Rhegmatogenous retinal detachment on B scan appears as membrane like echogenicity which is continuous, can be traced till the periphery associated with high amplitude reflectivity (80–100%) on vector A scan. The membrane is attached to the disc with a U or V configuration and has limited after-movements on dynamic B scan with clear space underneath suggestive of clear subretinal fluid.

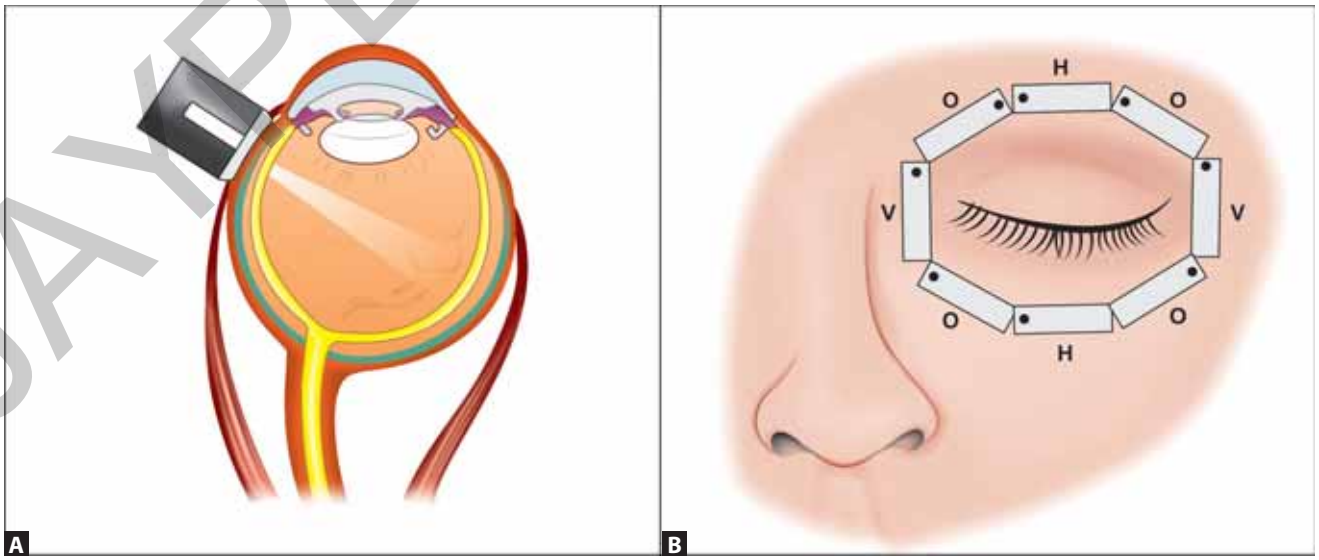

Figs. 4.6 A and B: (A) Schematic diagram showing the lateral sweep on one quadrant of fundus in transverse scan; (B) Technique of probe placement for acquiring transverse scan.

JAYPEE BROTHERS

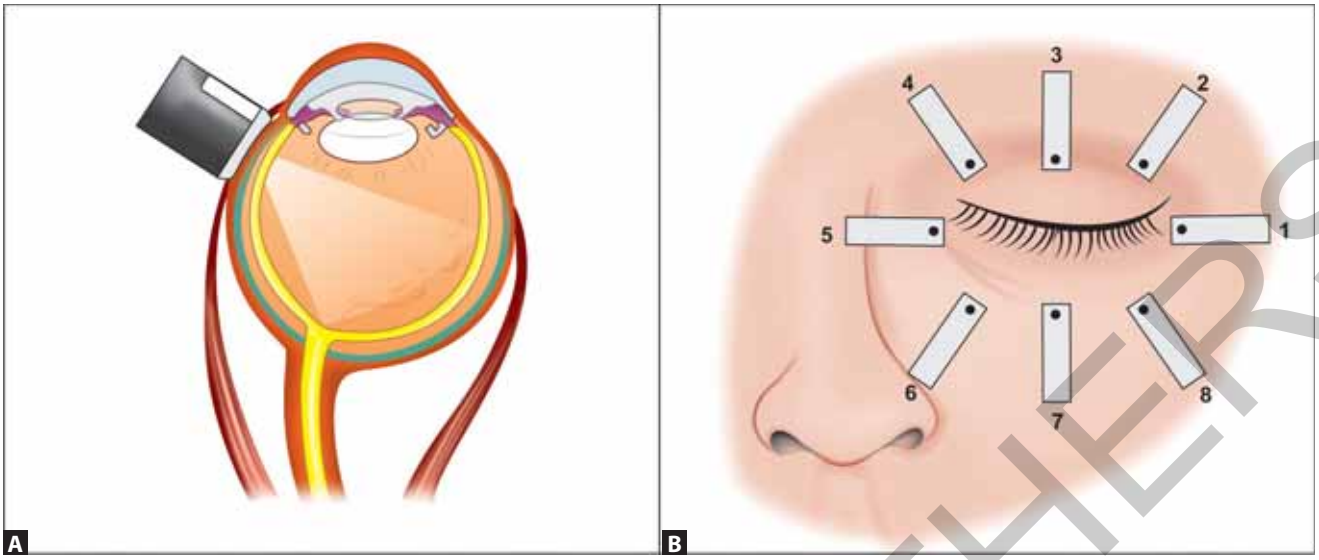

Figs. 4.7A and B: (A) Schematic diagram of longitudinal scan; (B) Technique of probe placement for acquiring longitudinal scan.

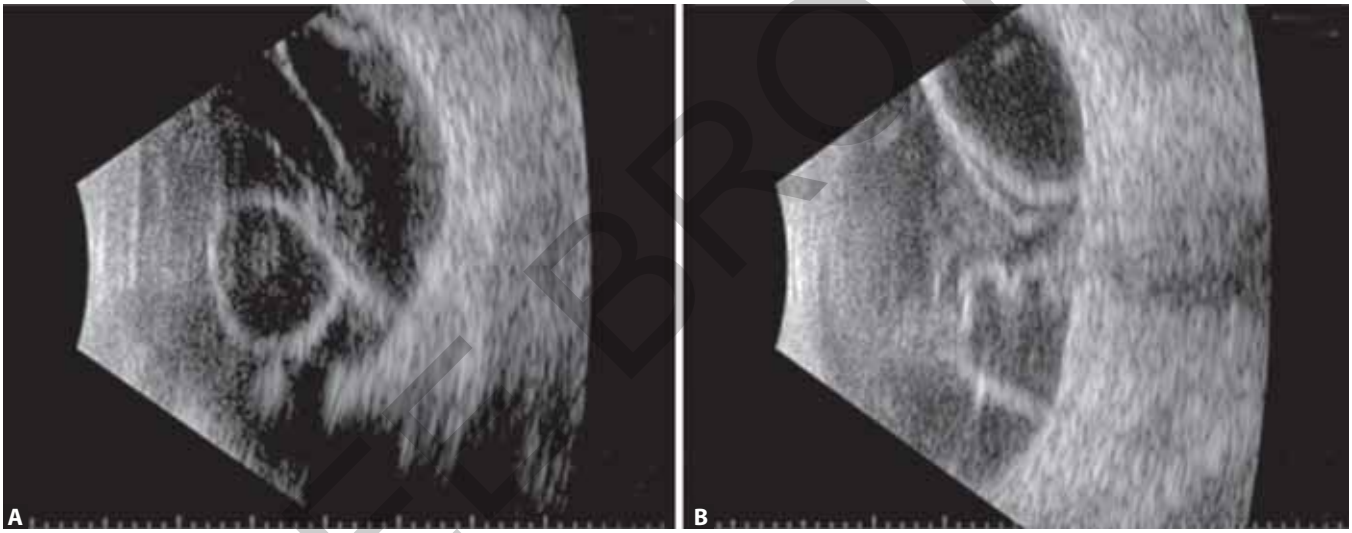

Figs. 4.8A and B: (A) Old retinal detachment (RD) with intraretinal cyst on B-scan; (B) RD with large choroidal detachment.

Long-standing retinal detachment may show intraretinal cysts and echo dots underneath the membrane suggestive of thick SRF **(Figs. 4.8A and B)**.

Tractional retinal detachment on B scan shows adherence of posterior vitreous at the apex of the tent-like configuration of the localized retinal detachment with limited or no after-movements that does not extend to the ora serrata **(Figs. 4.9 and 4.10)**.

Retinopathy of Prematurity

Ultrasonography proves to be helpful tool in patients with retinopathy of prematurity (ROP), especially in patients with media haze, advanced stages of ROP with tractional retinal detachments from extensive fibrovascular tissue, e.g. stage 5 ROP. The ultrasound helps to define the configuration of the detachment and may show peripheral retinal loops, ridge or cholesterol debris in the subretinal space.

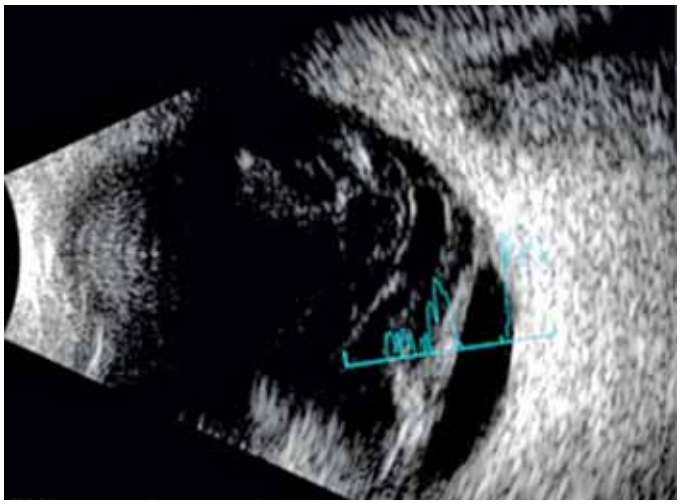

Fig. 4.9: Tractional retinal detachment with tent-like configuration and showing high reflectivity.

JAYPEE BROTHERS

Retinoblastoma

It is the most common intraocular tumor of childhood and forms an important differential diagnosis in a child with leukocoria. Echographically, retinoblastoma (RB) is characterized by presence of mass lesion with irregular configuration with presence of areas of high reflectivity with 100% amplitude spike on A scan which persists till low gain with acoustic shadowing suggestive of intralesional calcification **(Figs. 4.11A and B)**.

Usually the A scan shows moderate internal reflectivity, but presence of necrosis and calcification gives highly reflective irregular spikes with moderate to high sound attenuation. The globe may be normal to enlarged in size. Echography may show presence of concomitant retinal detachment in the exophytic variety of RB. Occasionally, echography may show extraocular extension of the tumor, which is of great prognostic and therapeutic importance. **Table 4.1** shows the list of ocular conditions with intraocular calcification.

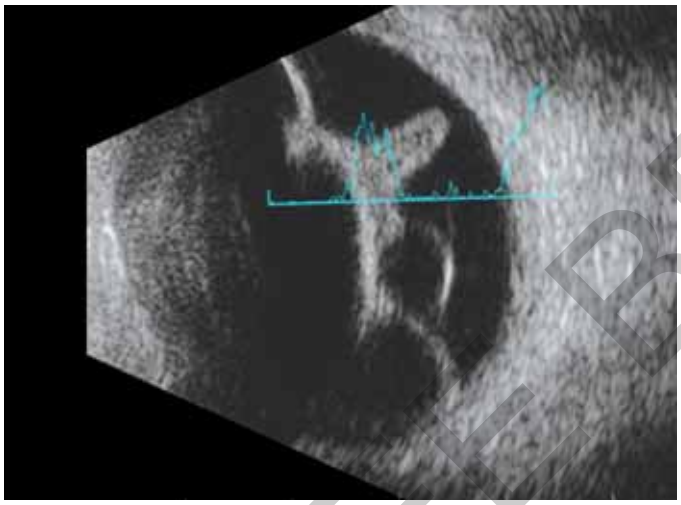

Fig. 4.10: B scan showing a classical diabetic table-top tractional retinal detachment with vector A scan showing high reflectivity spike from the detached retina.

Vitreous Hemorrhage or Exudates

Vitreous cavity may be filled with numerous dot-like echoes with mild-to-moderate amplitude spike on standardized echography (vector scan) suggestive of vitreous hemorrhage or exudates **(Fig. 4.12A)**.

Breakthrough Vitreous Hemorrhage

Subretinal hemorrhage commonly occurs with choroidal neovascular membranes in age-related macular degeneration. Subretinal bleed may dissect through the macula and causes dense premacular hemorrhage **(Fig. 4.12B)**.

Subhyaloid Hemorrhage

It is seen as either organized mass-like echoes under membrane-like vitreous reflection or as diffuse point-like echoes under mild amplitude membrane-like echo with good after-movements of posterior hyaloid membrane **(Fig. 4.13)**.

Asteroid Hyalosis

It is degenerative vitreous condition, usually asymptomatic in which calcium-pyrophosphate globules collect within the vitreous gel. These acts as reflectors and provide distinctive high amplitude echoes floating in the vitreous that are mobile and follow the dynamic vitreous movements. There is usually a clear space visible between particles and posterior globe wall **(Fig. 4.14)**.

Posterior Vitreous Detachment

It is a degenerative process of the vitreous resulting in separation of posterior hyaloid layer from the internal limiting membrane of the retina. Ultrasonographically, posterior vitreous detachment appears as a thin, smooth membrane-like echogenicity with variable attachment to retina and optic disc with clear subvitreal space. It may be small, interrupted, peripheral or continuous with mild-to-moderate amplitude reflectivity on vector A scan with good after-movements on

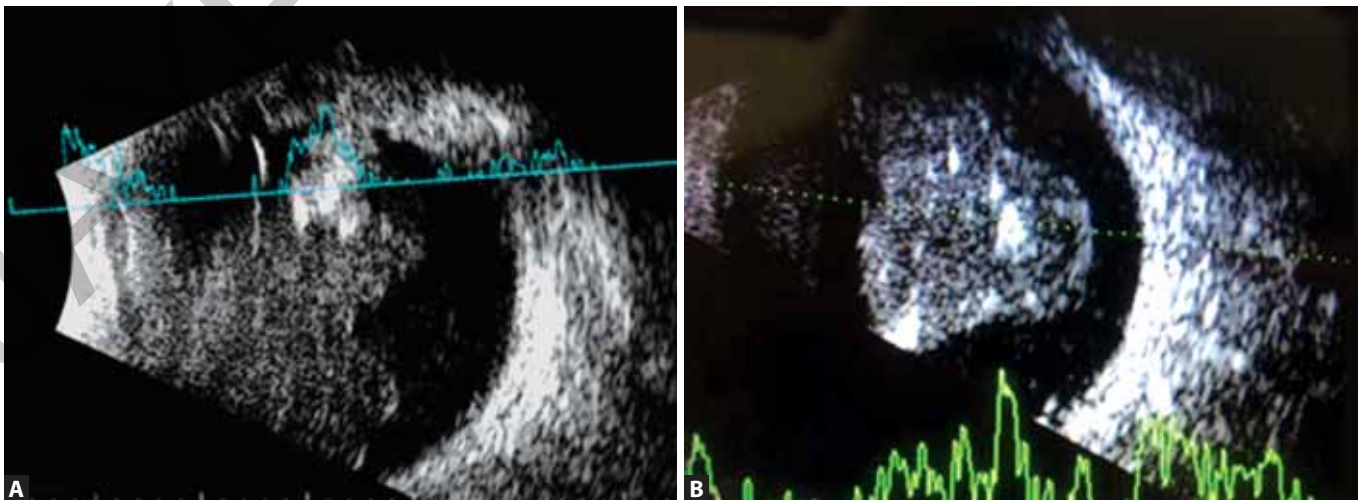

Figs. 4.11A and B: B scans showing presence of mass lesion with irregular configuration with intralesional calcification in both scans. There are classically high-reflectivity spikes producing the "*VW pattern*", in the latter scan.

JAYPEE BROTHERS

dynamic B scan and variable or nonpersistence till low gain **(Fig. 4.15)**.

Intraocular Cysticercosis

Cysticercosis can present with intraocular cysts. On USG, it is seen as a sharply outlined oval cyst in vitreous cavity or subretinal space with highly reflective echo dense nodule adjacent to the cyst wall—scolex with suckers and hooklets **(Fig. 4.16)**.

TABLE 4.1: Ocular conditions with intraocular calcification.

Retinal lesions	• Retinoblastoma • Astrocytic hamartoma • Tuberous sclerosis • Coats disease • PHPV/PFV • RPE metaplasia • Toxoplasmosis (chorioretinitis)
Choroidal lesions	• Choroidal osteoma • Choroidal hemangiomas (calcify occasionally)
Miscellaneous	• Optic nerve head drusen • Metastatic calcification, e.g., hyperparathyroidism, pseudohypoparathyroidism, and renal tubular acidosis • Dystrophic calcification, e.g., phthisis bulbi

(PHPV: persistent hyperplastic primary vitreous; PFV: persistent fetal vasculature; RPE: retinal pigment epithelium)

Intraocular Foreign Body

Retained intraocular foreign body (RIOFB) is commonly seen as a result of penetrating injury with projectile object. On USG, RIOFB may be seen as hyper-reflective echogenicity with high amplitude reflectivity (100%) with acoustic shadowing and reverberation echoes behind it and A-scan spike persisting even at low gain **(Figs. 4.17A and B)**.

Ultrasonography helps in localizing the foreign body and approximate sizing of the foreign body. Foreign bodies less than 0.2 mm in size and those in the orbit which are obscured by hemorrhages are best picked up by orbital CT scan.

Posteriorly Dislocated Intraocular Lens

This may appear as point-like echogenicity in the vitreous cavity with high amplitude spike with posterior reverberations with or without orbital shadowing **(Fig. 4.18)**. The intraocular lens (IOL) shows gravity dependent movement and moves against the direction of eye movement.

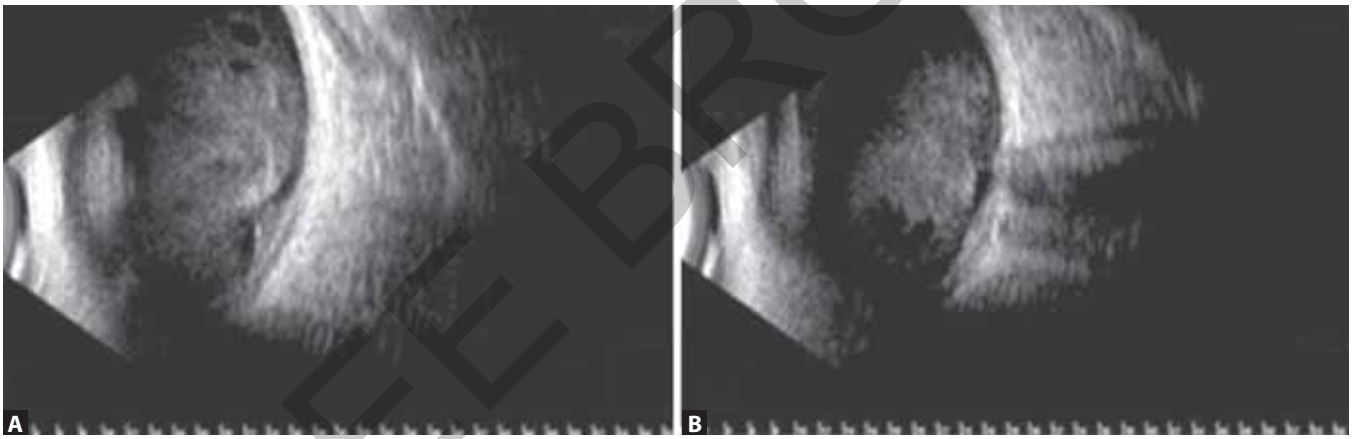

Figs. 4.12A and B: (A) B-scan ultrasonography showing numerous subretinal dot-like echoes suggestive of subretinal blood with breakthrough vitreous hemorrhage; (B) B-scan ultrasonography showing dense premacular hemorrhage.

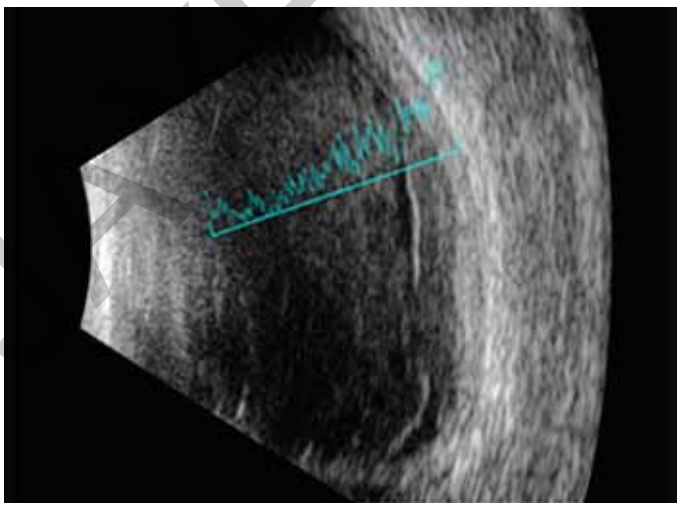

Fig. 4.13: Vector scanning shows retrohyaloid bleed with associated vitreous hemorrhage.

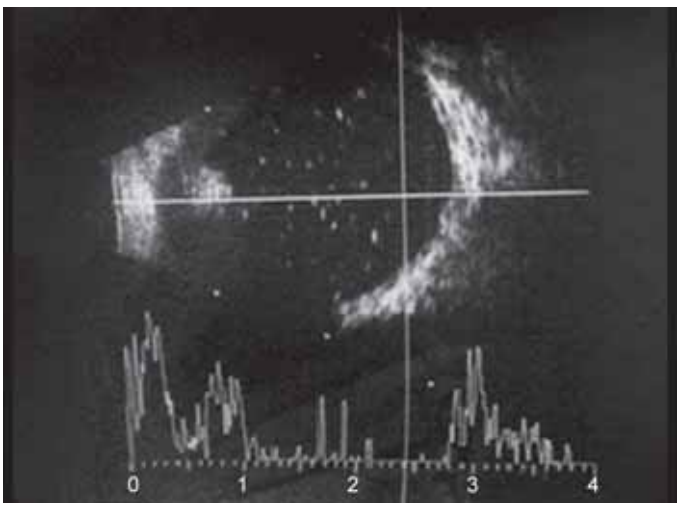

Fig. 4.14: B-scan of a patient with asteroid hyalosis.

JAYPEE BROTHERS

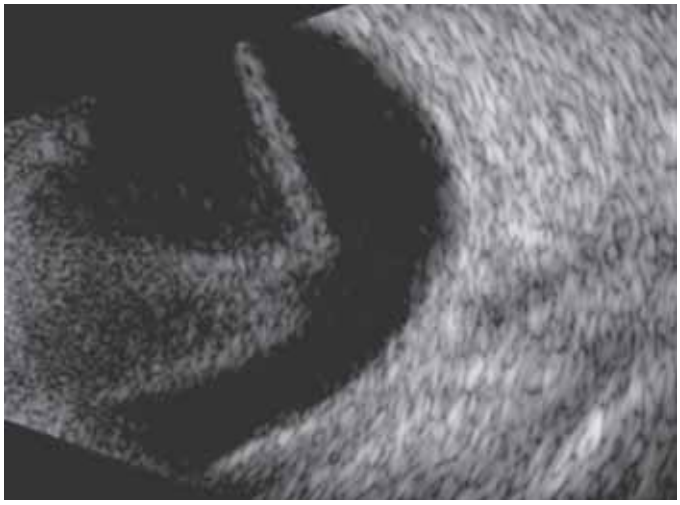

Fig. 4.15: Vitreous hemorrhage with complete posterior vitreous detachment.

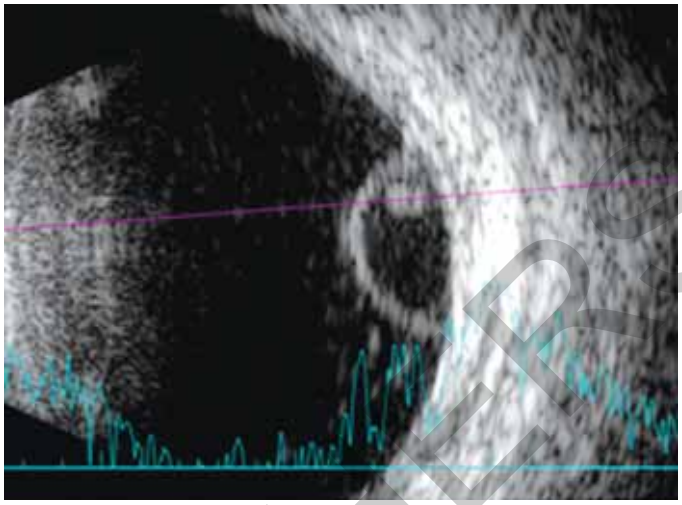

Fig. 4.16: B-scan ultrasound of a patient with intraocular cysticercosis.



Figs. 4.17A and B: (A) An impacted high-echo foreign body in the region of the optic nerve; (B) Vector scan shows an anteriorly placed foreign body showing high-reflectivity spike (overloaded spike, over 100% reflectivity).

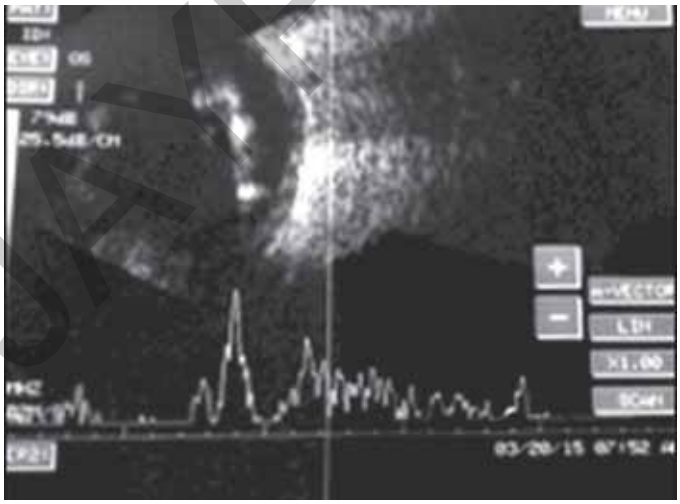

Fig. 4.18: B-scan ultrasonography of a patient with posteriorly dislocated intraocular lens showing acoustic reverberations.

Choroidal Detachment

Choroidal detachment (CD) may be either serous or hemorrhagic. It is usually seen in the periphery and is usually localized, but may be total. Echographically, CD is characterized by smooth, thick, convex, dome-shaped and immobile elevation with limited after-movement on dynamic B scan. A scan shows steep, high amplitude (100%) spike with characteristic double-peaked spike **(Fig. 4.19)**. Serous CD shows echolucent areas with no reflectivity beneath the choroid. In contrast, the hemorrhagic CD shows dense opacities with variable reflectivity beneath the choroid.

Choroidal Melanoma

B-scan echography shows a pathognomonic collar-button or mushroom-shaped lesion. This appearance is indicative of break in Bruch's membrane and invasion of tumor

JAYPEE BROTHERS

(Figs. 4.20A to C). A choroidal excavation may be seen on B scan but is not pathognomonic of malignant melanoma. This may be associated with concomitant serous retinal detachment usually extending from margins of the tumor. Scleral thickening with dilation of Tenon's space is suggestive of scleritis associated with tumor necrosis. Occasionally, calcification and extrascleral echolucent nodule behind the sclera suggestive of extrascleral spread may be noted.[12] A large angle kappa (sloping internal signals from higher to lower as the sound beam passes through the lesion) is seen on A scan **(Fig. 4.20B)**.



Fig. 4.19: B-scan ultrasonography showing choroidal detachment with retinal detachment.

Metastatic Carcinoma

Metastatic malignancies especially from the lung and breast are seen in eyes, and present with exudative retinal detachment and choroidal metastasis on USG **(Fig. 4.21)**.

Posterior Uveitis

Echography shows diffuse vitreous echogenic opacities with mild-to-moderate amplitude spike with good after-movements. It is to be differentiated clinically from vitreous hemorrhage, which has similar echographic characteristics.

Posterior Scleritis

The characteristic of B scan echographic finding is presence of the classic T-sign, which represents thickened posterior

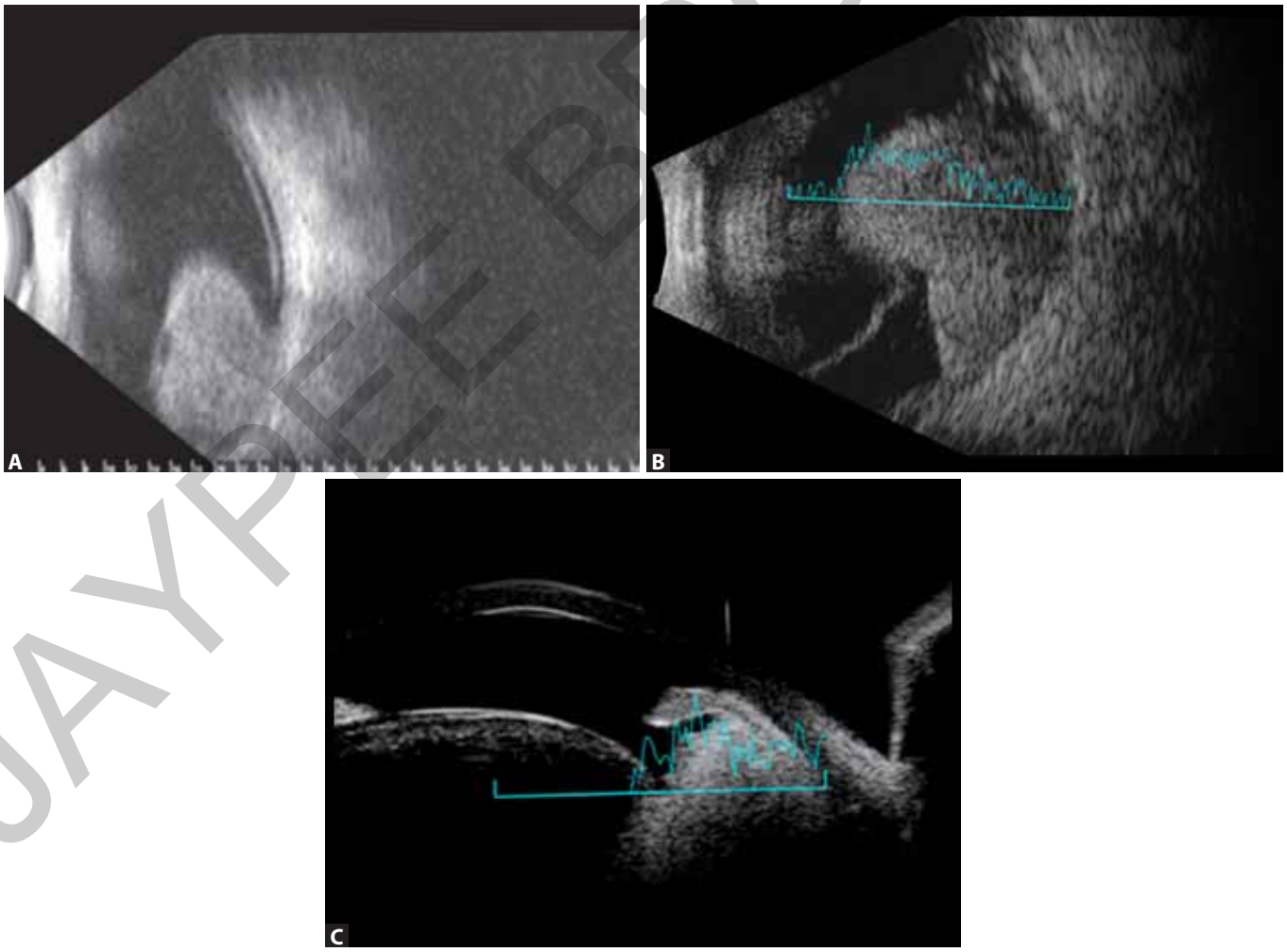

Figs. 4.20A to C: (A and B) B-Scan ultrasonography showing characteristic collar-button or mushroom-shaped lesion of choroidal melanoma in both USG pictures. A large angle kappa on A scan is seen in Figure B; (C) A ciliary body melanoma is visible on ultrasound biomicroscopy in the lowermost scan, again with large angle kappa.

JAYPEE BROTHERS

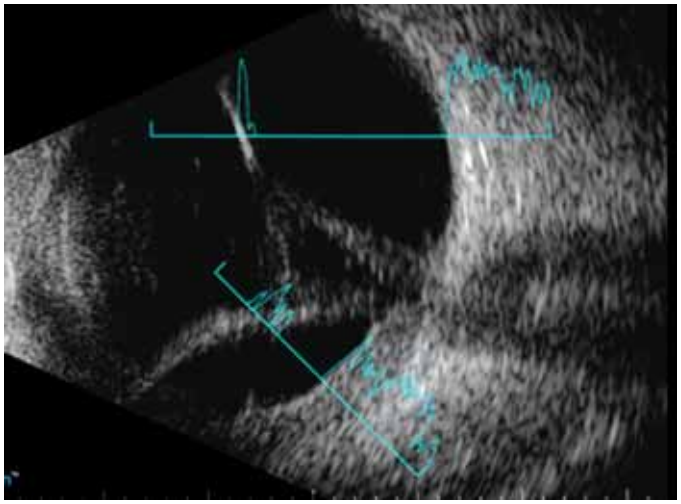

Fig. 4.21: B scan with vector A scan showing high reflectivity spikes from the choroidal metastatic deposits in a patient of metastatic breast cancer, along with retinal detachment.

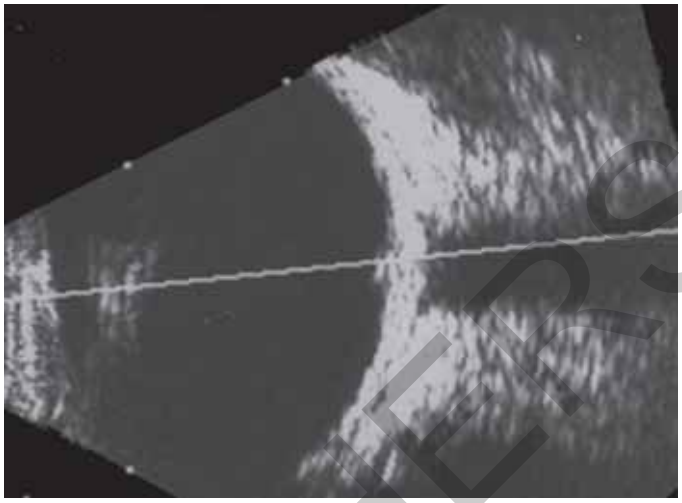

Fig. 4.22: Classical T sign seen in an eye with thickened sclera and subtenon's fluid collection.

sclera with underlying fluid collection in the Tenon's space **(Fig. 4.22)**.

Infectious Endophthalmitis

The vitreous opacities and exudates along with anterior chamber exudates and corneal edema or opacities preclude detailed posterior segment evaluation in patients with endophthalmitis. Thus B-scan echography plays a key role in evaluation of such patients for diagnosis and follow-up of patients on medical treatment. Echography shows vitreous cavity filled with low-to-moderate intensity spikes with point-like or membrane-like echogenicity with good after-movements and not persisting at low gain **(Fig. 4.23)**.

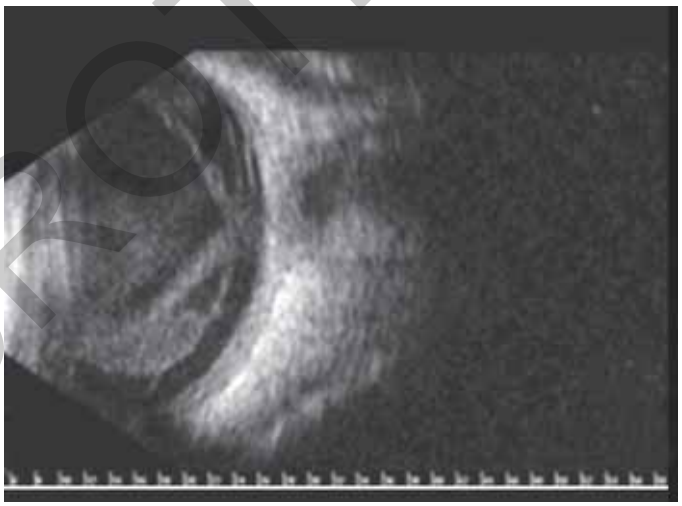

Fig. 4.23: B-scan ultrasonography of a patient with endophthalmitis.

Ultrasound Biomicroscope

Ultrasound biomicroscope is an instrument for in vivo imaging of anterior segment in noninvasive fashion, with the help of high-frequency ultrasound transducer producing cross-sections of the living eye at microscopic resolution.

Ultrasound biomicroscope was first conceptualized at the Princess Margaret Hospital at Toronto, Canada in 1989 by Dr Charles Pavlin, Professor Stuart and Professor Foster. Initially they developed three probes—50, 80, and 100 MHz for clinical trials. 80 and 100 MHz probes were used to see the cornea and the anterior chamber as the depth of penetration is only 2 mm. They found that 50 MHz is an ideal compromise between depth and resolution to visualize the entire anterior segment. It can visualize structures behind iris plane which are difficult to visualize with anterior segment OCT such as iris cysts, ciliary body swelling/tumors, integrity of posterior capsule, anterior proliferative vitreoretinopathy, etc.

Instrument of UBM

Ultrasound biomicroscope mainly consists of a probe, hard disc, video monitor, mouse, foot switch, and printer. There are three main components of the hard disc of the UBM machine—transducer, high-frequency signal processor, and precise motion control device.

The transducer is made up of a piezoelectric crystal produces 50 MHz radiofrequency pulse that travels the body tissue and reflected back to the transducer, which is processed by the signal processing unit. UBM is specially designed to handle high-frequency signals. Special motion control device is used to enable subtle movements to scan adjacent areas in the anterior segment. Series of eye cups are provided with the machine to create a water bath for the coupling agent **(Fig. 4.24)**.

It produces cross-sectional images of anterior segment structures providing a lateral resolution of 50 µm and an axial resolution of 25 µm with a depth of penetration of approximately 4–5 mm. The field of view is 4 mm × 4 mm and the scan rate is 5 frames/sec.

P60 machine: The next generation of ultrasonic biomicroscope provides unprecedented image accuracy and flexibility with 12.5 MHz, 20 MHz, 35 MHz, and 50 MHz probes.

JAYPEE BROTHERS



Fig. 4.24: Series of cups to create a water bath for ultrasound biomicroscopy.

Method

After anesthetizing the eye by instilling 4% lignocaine in the eye, a plastic eye cap is used to gently part the lids and of 2% methylcellulose or saline is used as the coupling agent. The patient is asked to fix at with the fellow eye on a ceiling target to maintain a steady fixation. The probe is kept approximately 2 mm from the eye surface to prevent injury to the cornea. The probe is manually moved perpendicular to the structure to be scanned in each clock hour from the center of the cornea to the ora serrata. **Table 4.2** summarizes the key differences between USG and UBM.

Indications for UBM in Retinal and Uveal Diseases

Misplaced IOL Position

Displaced haptics can be imaged and their position in relationship to the ciliary body can be ascertained.[13] Dislocated lenses frequently have a haptic over the pars plana. Any tissue attachment to the ciliary body can be assessed **(Fig. 4.25)**.

Trauma

Cyclodialysis is complete disinsertion of the ciliary body from the scleral spur and may be accompanied by a supracillary effusion. UBM is very useful to detect cyclodialysis clefts **(Fig. 4.26)**.[14]

Anterior Proliferative Vitreoretinopathy

Typical features of anterior PVR on UBM may be used to help guide surgery and estimate anatomical prognosis. Circumferential contraction or anterior displacement around the ora serrata can be seen on UBM **(Fig. 4.27)**.

The anterior displacement could be further classified based on UBM images into C-shaped anterior displacement, ciliary body adhesion, and pupil adhesion.

Retained Intraocular Foreign Body

Ultrasound biomicroscope plays an important role in the localization and management of an anteriorly situated intraocular foreign body in ciliary body or pars plana region.[15]

Miscellaneous Conditions

Glued IOL: **Figure 4.28** shows a glued IOL with haptic track visible on UBM.

TABLE 4.2: Key differences between USG B scan and UBM scan.

USG B scan	*UBM*
Structures imaged in the posterior segment have a thickness of more than a millimeter	The anterior segment has a depth of 4–5 mm and the structures are close to each other so we require a higher frequency probe
Frequency of the probe used is 10 MHz	Frequency of the probe used is 50 MHz
10 MHz frequency probe has a depth of 4 cm	The depth of penetration is 4 mm
It has an axial resolution of 940 microns	It has an axial resolution of 30–40 microns

(USG: ultrasonography; UBM: ultrasound biomicroscopy)

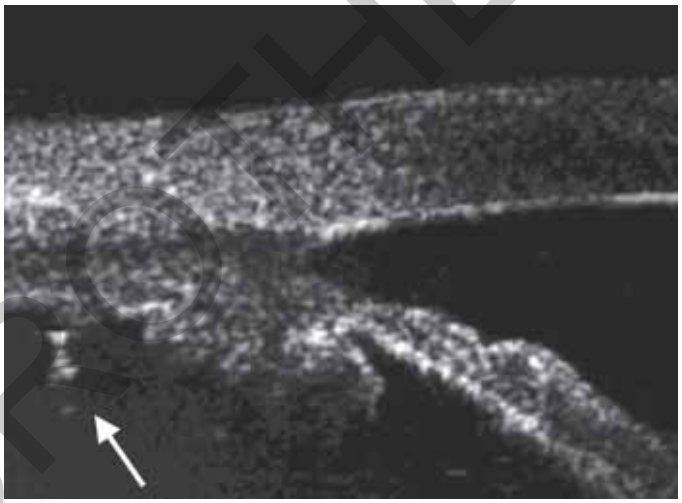

Fig. 4.25: Ultrasound biomicroscopy of a patient with malpositioned intraocular lens showing acoustic reverberation (arrow).

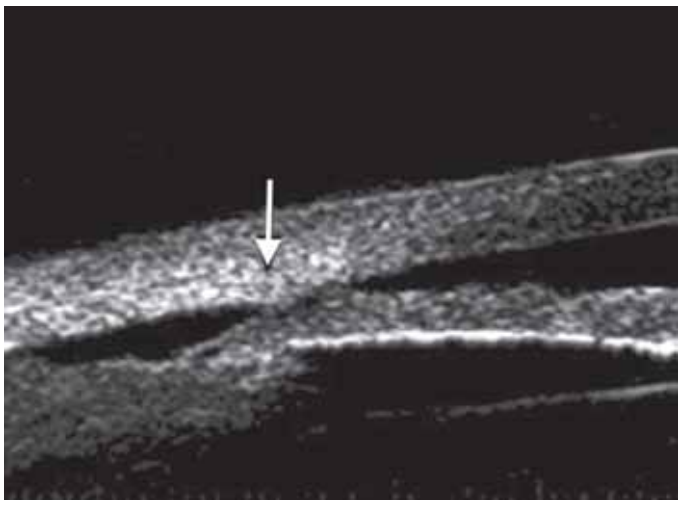

Fig. 4.26: Ultrasound biomicroscopy of a patient showing cyclodialysis cleft (arrow).

Even caterpillar hairs stuck onto the ciliary body have rarely been detected on UBM.[15,16]

Limitations

The most important limitation of UBM is poor depth of penetration. UBM cannot visualize structures deeper more than

JAYPEE BROTHERS

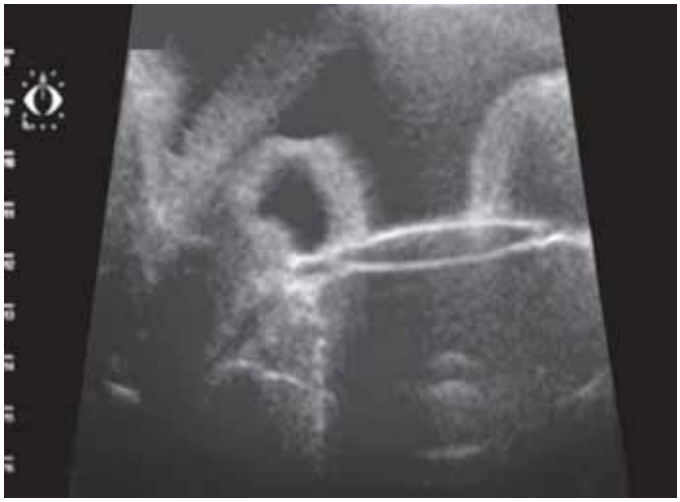

Fig. 4.27: Ultrasound biomicroscopy of a patient with anterior proliferative vitreoretinopathy and iris bombe formation.

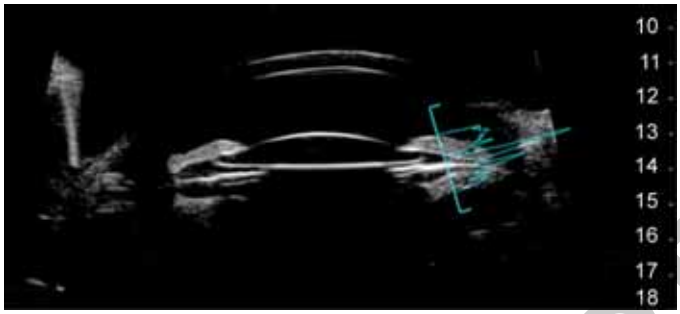

Fig. 4.28: Glued intraocular lens with haptic track in sclera visible on ultrasound biomicroscopy.

4 mm from the surface. UBM cannot be performed in presence of an open corneal or scleral wound. Being a contact procedure, it cannot be performed in the immediate postoperative period due to the risk of infection.

REFERENCES

1. Mundt GH, Hughes WF. Ultrasonics in ocular diagnosis. Am J Ophthalmology. 1956;41:488.
2. Baum G, Greenwood J. The application of ultrasonic locating techniques to Ophthalmology, part 1. Am J Ophthalmology. 1958; 46:319.
3. Bronson N, Fisher Y, Pickering N. Ophthalmic contact B-scan ultrasonography. Westport, CT: Intercontinental; 1976.
4. Ossoinig K. Clinical echo-Ophthalmology. In: Current Concepts of Ophthalmology. Vol III. St Louis, MO: CV Mosby Co; 1972. pp. 101-30.
5. Ossoinig KC. The evaluation of kinetic properties of echo signals. In: Oksala A, Gernet H (Eds). Ultrasonics in Ophthalmology. Basel, Switzerland: Karger; 1967. pp. 88-96.
6. Coleman DJ, Silverman RH, Rondeau MJ, et al. New perspectives: 3-D volume rendering of ocular tumors. Acta Ophthalmology Suppl. 1992;(204):22.
7. Lezzi R, Rosen R, Tello C. Personal computer-based 3-dimensional ultrasound biomicroscopy of the anterior segment. Arch Ophthalmology. 1996;114:520-4.
8. Cusumano A, Coleman D, Silverman R. Three dimensional ultrasound imaging: clinical applications. Ophthalmology. 1998; 105:300-6.
9. Coleman D, Silverman R, Daly S. Advances in ophthalmic ultrasound. Radiol Clin North Am. 1998;36:1073-82.
10. Reinstein D, Raevsky T, Coleman D. Improved system for ultrasonic imaging and biometry. J Ultrasound Med. 1997;16:117-24.
11. Sherer MD, Starkoski BG, Taylor WB, et al. A 100 MHz B-scan ultrasound backscatter microscope. Ultrasound Imaging. 1989; 11:95-105.
12. Barash D, Joan M. Brien O'. The role of ultrasound in the management of ocular tumors ophthalmology. Clinics of north America. 1999;12:205-11.
13. Irène MEL, Carl-Gustaf L. Ultrasound biomicroscopy examination of intraocular lens haptic position after phacoemulsification with continuous curvilinear capsulorhexis and extracapsular cataract extraction with linear capsulotomy. Acta Ophthalmologica Scandinavica. 2013;77:45-9.
14. Park M, Kondo T. Ultrasound biomicroscopic findings in a case of cyclodialysis. Ophthalmologica. 1998;212:194-7.
15. Guha S, Bhende M, Baskaran M, et al. Role of ultrasound biomicroscopy (UBM) in the detection and localisation of anterior segment foreign bodies. Ann Acad Med Singapore. 2006;35(8): 536-45.
16. Bhende M, Biswas J, Sharma T, et al. Ultrasound biomicroscopy in the diagnosis and management of pars planitis caused by caterpillar hairs. Am J Ophthalmology. 2000;130:125-6.

JAYPEE BROTHERS

for detailed information on ophthalmology books, visit our website www.jaypeebrothers.com, for detailed information on ophthalmology books, visit o

RETINA

Medical & Surgical Management

Salient Features

- Encompasses the recent updates and latest advances in diagnostics, clinical management guidelines, instrumentation and vitreoretinal surgeries
- Provides the readers a holistic view about the retinal subspecialty which will prove to be extremely useful to the readers
- A comprehensive textbook for residents, subspecialty fellows and practicing ophthalmologists which covers topics in a simplified manner with various clinical images and illustrations
- Incorporates all the latest advances in the field of vitreoretina
- Highlights the essential, clinically important aspects of vitreoretinal medical and surgical practice
- New sections about emerging role of 3D 'heads up' vitreoretinal surgery and microscope integrated optical coherence tomography in retinal surgeries have been added.

Atul Kumar MD FAMS FRCS (Ed) underwent residency training (MD) in Ophthalmology, followed by senior residency (SRship in vitreoretina) at Dr Rajendra Prasad Centre (RPC) for Ophthalmic Sciences, All India Institute of Medical Sciences (AIIMS), New Delhi, India. He began his luminous academic career as an Assistant Professor at the Retina Unit at RPC-AIIMS in 1987. He got further trained in retina with a fellowship from the University of Maryland, Baltimore, USA, 1991. Very early in his career, he won the Best Scientific Paper Award at the All India Ophthalmological Society Annual Meeting in 1994 and the International Council of Ophthalmology-Nakajima Award. Professor Atul Kumar has been a Member of the Editorial Board of the Indian Journal of Ophthalmology (IJO) and other several reputed national and international journals. He has more than 400 research publications to date. His achievements include Fellowship of the National Academy of Medical Sciences, India, 2006; Fellowship of Royal College of Surgeons, Edinburgh; prestigious Padma Shri Award by the President of India for his contribution to healthcare in the field of Vitreoretinal Diseases and Surgery, 2007; Honorary Vitreoretinal Consultant to the Armed Forces, 2015; Advisor, Ophthalmology, Government of India, 2016; and BC Roy Award for Medical Sciences, 2016. He is presently the Chief and Professor at RPC-AIIMS, the National Apex Institute for Ophthalmology. In this role, he has envisioned and spearheaded the rapid pace of development of RPC-AIIMS into one of the very best in the world for patient care, academics, research, and training. He has played a pivotal role in spearheading the National Blindness and Visual Impairment Survey and National Diabetic Retinopathy Survey, which were conducted by the Department of Community Ophthalmology, RP Centre, AIIMS, New Delhi, between 2015 and 2019. He has authored multiple chapters and books in the field of vitreoretina, ocular trauma and ophthalmic sterilization.

Printed in India

Available at all medical bookstores
or buy online at www.jaypeebrothers.com



JAYPEE BROTHERS
Medical Publishers (P) Ltd.
EMCA House, 23/23-B, Ansari Road,
Daryaganj, New Delhi - 110 002, INDIA
www.jaypeebrothers.com

Join us on facebook.com/JaypeeMedicalPublishers

Shelving Recommendation
OPHTHALMOLOGY

