anesthesia books, visit our website www.jaypeebrothers.com, for detailed information on anesthesia books

Yearbook *of* Anesthesiology 11

Yearbook of Anesthesiology 11

2020

Indian College of Anaesthesiologists

Editors
Mukul Chandra Kapoor
Baljit Singh

JAYPEE

Contents

1. New Technologies to Secure the Airway 1
Syed Moied Ahmed, Manazir Athar

- Assessment Methods and Tools *2*
- Recent Concepts in Airway *6*
- Newer Devices in Airway Management *10*
- Devices for Special Airway Situations *14*

2. Tubeless Anesthesia for Laryngeal Surgery 19
Manisha Mehta Kumar

- Preoperative Planning *20*
- Conduct of Anesthesia *25*
- Postoperative Care *32*

3. Assessment of Frailty in the Aged 34
Asha Tyagi, Vandna Arora

- How to Assess Frailty? *35*
- Frailty: An Indian Perspective *40*

4. Management of Patients on Direct Oral Anticoagulants 43
Aveek Jayant

- Applied Pharmacology *44*
- Uses *48*
- Laboratory Monitoring of DOAC *50*
- Perioperative Risk Assessment *50*
- Emergency Hemostatic Management of Patients on a DOAC *53*
- Summary *54*

5. Noncardiac Surgery in Patients with Heart Failure 57
Agya Prempeh, Shalini Dhir, Achal Dhir

- Definition and Terminology *59*
- Diagnosis of Heart Failure *61*
- Management of Heart Failure *63*
- Future Directions *71*

6. The LVAD-supported Patient Presenting for Noncardiac Surgery 79
Marc Stone, Vahid Kiarad

- INTERMACS, EUROMACS, PEDIMACS, JMACS, and IMACS *81*
- The INTERMACS "Profile" *81*
- Current MCS Strategies and Indications for MCS *82*
- Current Devices *83*
- Perioperative Management of the LVAD-Supported Patient *85*
- Intraoperative Management *88*
- Postoperative Management *97*

JAYPEE BROTHERS

7. Fluids in Thoracic Surgery 100
Sarah McDonald, Peter Slinger

- The Endothelial Glycocalyx *101*
- Lung Injury *102*
- Pneumonectomy *102*
- Esophagectomy *103*
- Enhanced Recovery after Surgery *104*
- Restrictive Fluid Management and Acute Kidney Injury *105*
- Goal-Directed Therapy *107*

8. Ultrasound-guided Nerve Blocks for Cardiac and Thoracic Surgery 111
Shibani Das, Deep Arora

- Anatomy *112*
- Surgical Incisions for Cardiothoracic Surgery *114*
- Regional Anesthesia Techniques *115*
- Practical Aspects *122*

9. Regional Anesthesia in Children..... 125
Rakhee Goyal, Tripiti Sinha

- Surgeries in the Head and Neck *128*
- Recent Advances *136*
- Safety Data *136*
- Clinical Pearls *137*
- Summary *138*

10. Effect of Spontaneous Breathing in Patients with Acute Respiratory Disease Syndrome 142
Saurabh Kumar Das, Reshma Tewari

- Mechanism of Spontaneous Breathing *143*
- Benefits of Maintaining Spontaneous Breathing *144*
- Effect of Maintaining Spontaneous Breathing in Patient with Injured Lungs *145*
- Risk Factors of Spontaneous Respiration-induced Lung Injury *146*
- Monitoring Spontaneous Respiratory Effort that may Potentially Cause Lung Injury *147*
- Management *147*

11. Thoracic and Lung Ultrasound in Anesthesia and Critical Care 150
Vivek Sharma, Jyotindu Debnath

- Generation of Image in USG *151*
- Evolution of Thoracic Ultrasound *153*
- Prevention of Nosocomial Infections *161*
- Future Perspectives *162*

JAYPEE BROTHERS

12. Delirium in Critical Care 163
Krishna Kumar M

- Etiology and Pathophysiology *166*
- Diagnosis and Screening *168*
- Management of Delirium *170*

13. Perioperative Neurological Dysfunction 181
Mukul Chandra Kapoor

- Nomenclature *182*
- Diagnosis *182*
- Perioperative Neurocognitive Disorder and Surgery *186*
- Potential Contributors to Perioperative Neurological Dysfunction *189*
- Pathogenesis *190*

14. Brain Function Monitoring in Surgery 203
Shalvi Mahajan, Hemant Bhagat

- Electrophysiology Monitoring *204*
- Cerebral Blood Flow Monitoring *208*
- Cerebral Oxygenation Monitoring *210*
- Intracranial Pressure Monitoring *211*
- Intracranial Biochemistry *213*
- Intraoperative USG in Brain Monitoring *213*

15. Spinal Anesthesia for Ambulatory Surgeries..... 217
Tanmoy Das, Achirabha

- Ambulatory Surgery *218*
- Spinal Anesthesia *219*
- Enhanced Recovery after Surgery and Spinal Anesthesia *225*
- Comparison of Epidural and Peripheral Nerve Block with Spinal Anesthesia for Ambulatory Surgery *225*
- Spinal Anesthesia for Ambulatory Surgery in COVID-19 Pandemic and Beyond *226*

16. Placenta Accreta Spectrum: An Emerging Challenge in Obstetric Anesthesia 229
Usha Shenoy

- Clinical Presentation *232*
- Obstetric Management *233*
- Anesthetic Implications *235*
- Anesthesia Technique *240*

17. Anesthetic Management of Cytoreductive Surgery and Hyperthermic Intraperitoneal Chemotherapy 245
Sohan Lal Solanki, Abhini Prabhakar

- Rationale *246*
- Technique *247*
- Indications *247*

JAYPEE BROTHERS

- Chemotherapy *249*
- Physiological Effects of HIPEC *250*
- Prehabilitation and Preoperative Optimization *251*
- Intraoperative Management *252*
- Postoperative and ICU Management *258*
- Operating Room Personnel Safety *259*
- Survival and Outcomes *260*
- Recent Advances *260*
- Future of CRS-HIPEC *261*

18. Anesthetic Implications in Robotic Urological Surgeries 265
Seema Brar, Vinod Malhotra

- Advantages and Disadvantages *266*
- Physiological Effects *267*
- Robotic Urological Surgeries *271*

19. What is new in Cardiopulmonary Resuscitation? 280
Nadine Rott, Bernd W Böttiger, Wolfgang A Wetsch

- Introduction and Scope *280*
- SARS-CoV-2/COVID-19 *281*
- Epidemiology *282*
- System Saving Lives *282*
- Basic Life Support *283*
- Advanced Life Support *284*
- Special Circumstances *285*
- Post-resuscitation Care *286*

20. Anesthetic Concerns in Consumers of Cannabis and Other Psychotropic Agents 288
Nidhi Bhatia, Anju Grewal

- Legal Status *289*
- Types of Cannabis Users: Medical Versus Recreational *289*
- Pharmacodynamics of Cannabis *289*
- Pharmacokinetics *291*
- Anesthetic Concerns in Cannabis Users *92*
- Cannabis and Conduct of Anesthesia *294*
- Opioids and Perioperative Pain *295*
- Postoperative Concerns *295*
- Cannabis Hyperemesis Syndrome *295*
- Cannabis Withdrawal Syndrome *295*
- Anesthetic Concerns in Consumers of Psychotropic Agents *296*

21. Opioid-free Anesthesia: Feasible but does not Provide Additional Value 299
Devjit Srivastava

- General Anesthesia and Opioids *300*
- Balanced/Multimodal Analgesia *300*
- Opioid-sparing Balanced Anesthesia *301*
- Opioid-free Anesthesia Approach *301*

JAYPEE BROTHERS

22. Perioperative Venous Thromboembolism Prevention 307
Fabio de V Papa, C David Mazer

- Introduction: Scope of the Problem *308*
- The Importance of Risk Assessment *308*
- VTE Prophylaxis for Specific Surgical Specialties *311*

23. Anesthesia during the COVID Epidemic, its Downswing, and its Resurgence 319
Sandhya Yaddanapudi

- Administrative Processes *320*
- Anesthesia for a COVID-19 Patient *324*
- Resuscitation *329*
- Effect of the Pandemic on Anesthesia Personnel *330*
- Effect of the Pandemic on Training in Anesthesia *332*
- Aftermath of the Pandemic *333*

24. Perioperative Patient Safety 336
Rangraj Setlur, Nikahat Jahan

- Definitions and Terms *339*
- An Overview of Perioperative Safety *340*

25. Leadership and Management Skills are Essential to an Anesthesiologist..... 350
Kirandeep Sandhu

- What Is Leadership? *351*

Index..... 367

JAYPEE BROTHERS

CHAPTER 8

Ultrasound-guided Nerve Blocks for Cardiac and Thoracic Surgery

Shibani Das, Deep Arora

ABSTRACT

Opioids have been the mainstay for anesthesia and analgesia for cardiothoracic surgery. Regional anesthesia has also been a part of anesthetic technique for cardiothoracic surgery in some centers in the form of thoracic epidural, paravertebral, and intercostal nerve blocks. Recent years have seen a surge in new ultrasound-guided nerve blocks. They are safer, technically less challenging, and hence associated with a better risk–benefit ratio. These blocks are finding their way in routine practice of anesthesia for cardiac and thoracic surgery. In this chapter, we look at these newer block techniques and their application in the field of cardiothoracic anesthesia.

Keywords: Fascial plane blocks of chest wall; regional anesthesia for cardiothoracic surgery; proxy paravertebral blocks; persistent pos-thoracotomy pain.

KEY POINTS

- Traditionally, opioids have been the mainstay of anesthesia and analgesia in cardiothoracic surgery.
- Regional anesthesia techniques in the form of thoracic epidural, paravertebral, and intercostal nerve blocks have been used in many centers as part of anesthesia and analgesia for these procedures.
- The last decade has seen a global increase in the use of ultrasound-guided nerve blocks.
- Quite a few of these have been introduced in the field of cardiothoracic surgery.
- The relevant anatomy and nerve block techniques are discussed in this chapter.

INTRODUCTION

Medical science has progressed in leaps and bounds over the last century. There is one aspect, however, where it has failed to make any significant difference and that is in the field of acute postoperative pain management.

Results of a national US survey published in 2014 reflected the magnitude of the problem; nearly 80% of the patients reported having experienced moderate-to-severe postoperative pain in inpatient as well as outpatient setting. Consequences of inadequately treated postoperative pain range from physiological (cardiac, pulmonary, gastrointestinal, immunological, wound healing), psychological (anxiety, sleep disturbance, patient satisfaction) to economic (length of stay). In a significant number of patients, inadequately managed acute postoperative pain can become chronic persistent postsurgical pain.[1]

JAYPEE BROTHERS

Persistent post-thoracotomy pain affects an alarming 57% of patients at 3 months and 47% at 6 months after surgery.[2] Chronic pain can develop in 27% of patients following sternotomy.[3] One of the best ways to prevent acute postoperative pain from progressing to chronic pain is to properly manage it.

Traditionally, opioids have been the mainstay of the anesthetic technique of interoperative and postoperative pain management.[4] Opioids are good at mitigating static pain. However, they are not very effective in dealing with dynamic pain that accompanies deep breaths and coughing unless given in high dose.[5] Additionally, they have their own side effects and complications that do not go well with the current concept of enhanced recovery after surgery (ERAS) protocol.

Regional anesthesia techniques are superior than opioids in taking care of dynamic as well as static pain.

ANATOMY

The knowledge of anatomy is mandatory to select the appropriate nerve block and perform it with safety. Thorax is a part of the trunk that lies between the neck and the abdomen. It has the rib cage that contains the thoracic organs inside the thoracic cavity.

Anterolateral chest wall consists of intercostal muscles between adjacent ribs. The serratus anterior muscle (SAM) is found overlying the ribs and intercostal muscles from first to eighth ribs. It is thicker posteriorly. It is covered by Latissimus dorsi muscle posteriorly and pectoral muscles anteriorly. The cross section of the mid-thoracic wall is shown in **Figure 1**.

The somatic nerve supply of the chest wall comes from the thoracic spinal nerves [intercostal nerves (ICNs)], each of which divides into a dorsal and a ventral ramus. There is an overlap in the dermatomal innervation provided by ICNs. Therefore, anesthetizing a dermatome would require blocking that specific level ICN as well as one above and one below.

The dorsal ramus divides into medial, intermediate, and lateral branches, which innervate the paraspinal muscles and the overlying skin.

The ventral rami of thoracic spinal nerves run between the innermost and the internal intercostal muscle layers. The innermost intercostal muscle is insignificant in the upper thorax. Here, the transversus thoracis muscle separates the internal intercostal muscle from the pleura. The first thoracic ventral ramus sends a large branch to the brachial plexus and a small branch continues as the first ICN. The third to sixth ICNs give off a lateral cutaneous branch near the mid-axillary line that penetrates through the internal intercostal, external intercostal, and SAMs and divides into an anterior and a posterior cutaneous branch, which innervate the anterolateral and posterolateral chest walls, respectively. The lateral cutaneous branch of the

JAYPEE BROTHERS

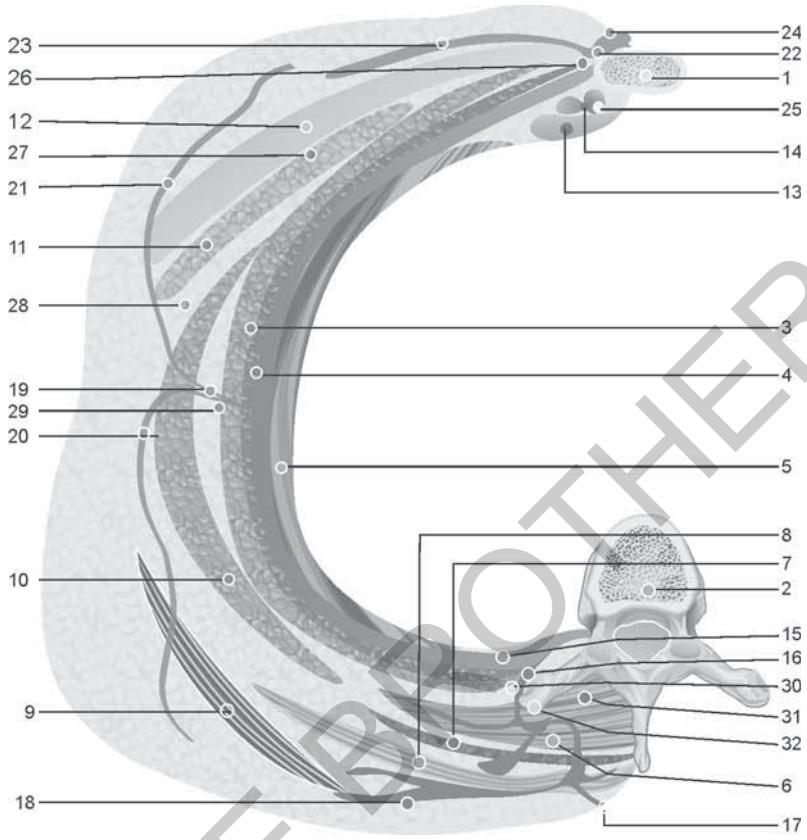

Fig. 1: Cross-section of mid-thoracic wall. 1. sternum, 2. vertebral body, 3. external intercostal muscle, 4. inner intercostal muscle, 5. innermost intercostal muscle, 6. erector spinae muscle, 7. rhomboid major muscle, 8. trapezius, 9. latissimus dorsi, 10. serratus anterior, 11. pectoralis minor, 12. pectoralis major, 13. transversus thoracic muscle, 14. internal thoracic blood vessels, 15. ventral ramus, 16. dorsal ramus, 17. medial cutaneous branch of dorsal ramus, 18. lateral cutaneous branch of dorsal ramus, 19. lateral cutaneous branch of ventral ramus, 20. posterior division of lateral cutaneous branch, 21. anterior division of lateral cutaneous branch, 22. anterior cutaneous branch of ventral ramus, 23. lateral division of anterior cutaneous branch, 24. medial division of anterior cutaneous branch, 25. deep anterior cutaneous branch block (e.g., transversus thoracis plane block), 26. superficial anterior cutaneous branch block (e.g., pecto-intercostal plane block), 27. pectoral nerves block target plane (e.g., Pecs I block), 28. target plane for superficial lateral cutaneous branch block (e.g., Pecs II and superficial serratus anterior plane block), 29. target plane for deep lateral cutaneous branch block (e.g., deep serratus anterior plane block), 30–32. targets for proxy paravertebral blocks (30. midpoint transverse process to pleura block, costotransverse foramen block, subtransverse process interligamentary block; 31. erector spinae plane block; 32. retrolaminar block).

second ICN continues as the intercostobrachial nerve and does not divide into lateral and medial branches. The ventral rami of seventh to twelfth thoracic nerves innervate the anterior abdominal wall.[6]

JAYPEE BROTHERS

The ICN terminates near the edge of the sternum as the anterior cutaneous branch, which passes anterior to the internal thoracic vessels, through the internal intercostal, the external intercostal (which is just a membrane here), and the pectoralis major muscles to innervate the parasternal region.

Posterior chest wall extends from the posterior axillary line to the thoracic spinous processes. Erector spinae group of muscles, comprising, from medial to lateral, spinalis, longissimus thoracis, and iliocostalis, are found in the paraspinal area, between the spinous and the transverse processes (TPs). The latissimus dorsi muscle covers the erector spinae from T7 downward. Superiorly, trapezius covers the erector spinae, the rhomboids, and the scapula. Transversospinalis muscle group is found deep to spinalis and consists of multifidus, rotatores, and intertransverse muscles. These muscles together with the superior costotransverse ligament (SCTL) form the intertransverse tissue complex, which forms the posterior boundary of the thoracic paravertebral space.

Lateral to the TPs, the fascial plane between the erector spinae and the intercostal muscles is contiguous with that between the serratus anterior and the intercostal muscles in the anterolateral chest wall.

Supraclavicular nerves from the superficial cervical plexus innervate the skin over the upper part of the anterior chest.

Nerves from the brachial plexus also contribute to the nerve supply of the chest wall. Medial and lateral pectoral nerves from the medial and lateral cords, respectively, innervate the pectoral muscles. The long thoracic nerve (C5–7) is responsible for the innervation of the SAM. The latissimus dorsi receives its nerve supply from the thoracodorsal nerve (C6–8).[7]

Nociceptive stimuli from the bronchi, pleura, and pericardium are carried by the phrenic and the vagus nerves. This route is responsible for the referred pain to shoulder after thoracotomy, which is not amenable to thoracic epidural analgesia.[8]

SURGICAL INCISIONS FOR CARDIOTHORACIC SURGERY

Small surgical incisions were used to drain local infections in the chest before the advances in anesthesia, like positive-pressure ventilation and lung isolation. Larger incisions became possible with these advancements and posterolateral thoracotomy became a widely used approach. Now, video-assisted thoracoscopic surgery has made it possible to carry out more complex procedures through small thoracic incisions again.

A thoracotomy incision is defined according to its relation to the latissimus dorsi muscle, which is arbitrarily considered lateral. Posterolateral thoracotomy, through the fifth intercostal space, provides good access to pulmonary hilum and is used for pulmonary resections. Anterolateral thoracotomy gives easy access to the heart and aorta. Clamshell thoracotomy is a bilateral anterolateral thoracotomy with transverse sternotomy. It is

JAYPEE BROTHERS

used to gain access for bilateral lung procedures. Axillary thoracotomy is used for first rib resection and for procedure on upper thoracic sympathetic chain. VATS involves three to four small incisions for introduction of camera and instruments; a few of these can be incorporated in the standard thoracotomy incision should the need to perform an open procedure arise. Medial sternotomy provides easy access to the heart, great vessels, thymus, and anterior mediastinum. It is used for most cardiac surgical procedures.[9] Insertion of a permanent pacemaker requires an infraclavicular incision to create a subcutaneous or subpectoral pocket.[10]

Transcatheter aortic valve replacement is a new minimally invasive procedure that has emerged as a viable alternative to open surgical aortic valve replacement in moderate-to-severe aortic stenosis, especially in poor-risk patients. A transfemoral approach is most commonly used and involves dissection in the groin.[11]

REGIONAL ANESTHESIA TECHNIQUES

Conventional Blocks

Thoracic epidural anesthesia has been used with general anesthesia for cardiac surgery with good results—decreased risk of myocardial infarction, mechanical ventilation duration, and risk of death by suppressing the surgical stress response and improving perioperative analgesia. However, its use in the presence of heparinization during cardiac bypass and in the presence of hemodynamic instability remains controversial.[12] Failure rates as high as 32% have been associated with thoracic epidurals.[13]

Thoracic paravertebral block is as effective a technique as the thoracic epidural but with less side effects.[14] It was described and practiced as a landmark-based loss of resistance technique. The use of ultrasound guidance has increased its success rate.[15] In a study on human volunteers, comparing the MRI spread of local anesthetic (LA; 4 levels) with the clinical effect (10 levels) of ultrasound-guided thoracic paravertebral block, Marhofer et al. found a poor correlation.[16]

Intercostal nerve blocks have a limited role now with the advent of new ultrasound-guided fascial plane blocks of the thoracic wall.

Ultrasound-guided Fascial Plane Blocks

The application of point-of-care ultrasound to the field of regional anesthesia has rekindled research in the fields of anatomy, radiological imaging, clinical efficacy, and patient safety. Numerous new fascial plane block techniques have been described. Many such blocks can be used to provide anesthesia and analgesia for cardiac and thoracic surgical procedures in combination with general anesthesia and as a part of multimodal postoperative analgesia.

JAYPEE BROTHERS

Unlike the conventional blocks, the fascial plane blocks do not target a specific nerve or plexus. They aim to deposit LA in a fascial plane through which the nerves of interest traverse and/or that communicates with an adjacent compartment containing the nerves. Volume of LA used in the fascial plane blocks needs to be large to "flood" the fascial plane. It raises two concerns that need to be kept in mind. First, the systemic absorption may contribute to the clinical effect of the block. Second, LA systemic toxicity (LAST) is a possibility, especially with bilateral catheters, which can be prevented by using total dosage within permissible limits, adjunct like adrenaline to reduce systemic absorption, and monitoring the patient for at least 30 minutes after the block. The speed of the injection also affects the spread of LA within the fascial compartment. Fascial plane block characteristics are different from those of specific targeted plexus and nerve blocks. Fascial plane blocks produce analgesia without any discernible sensory and motor block. This dissociative block can be explained by the low mass of LA reaching the nerves so as to preferentially block the unmyelinated C fibers with relative sparing of A delta and gamma fibers.[17] The exact mechanism of action of the fascial blocks is still not fully understood. The fascia has its own dynamics, pumping action, and nociceptors that may influence the block properties besides other factors, such as the anesthetic depth, use of muscle relaxant, position of the patient, and presence or absence of breathing (spontaneous vs. positive pressure, living vs. cadaver).[18]

The fascial blocks are usually done under ultrasound guidance. For thoracic wall plane blocks, a high-frequency linear probe is used. However, in obese patients, a curvilinear low-frequency probe may be needed. The needle stays away from the nerves, blood vessels, pleura, and other vital structures.

One can block thoracic spinal (intercostal) nerves and their branches in various locations and planes so as to target:

- The anterior cutaneous divisions of the ventral rami
- The lateral cutaneous divisions of the ventral rami
- The dorsal and ventral rami

Anterior Cutaneous Divisions Block Techniques

As the ventral rami of spinal thoracic ICNs approach the sternal border anteriorly, they turn superficial, piercing through the internal intercostal and the pectoral major muscles to become the anterior cutaneous branches. They can be blocked in the plane, either deep or superficial to the intercostal muscles. The block results in parasternal anesthesia (T2–6), which is useful for sternotomy, sternal fractures, and procedures involving the medial aspect of the breast and medial part of the anterior thoracotomy incisions. For midline incisions/injuries, the block has to be performed on both sides. One has to carefully calculate and stick to the safety limit of LA dosage in order to avoid LAST.

JAYPEE BROTHERS

The plane between the transversus thoracis and the internal intercostal muscles is the target of transversus thoracis plane (TTP) block.[19] It must be borne in mind that the internal thoracic vessels are also found in this plane. With the resolution of the current commercially available ultrasound machines, these vessels may not be seen. Furthermore, the transversus thoracis muscle is a small muscle that overlies the pleura on the right and the pericardium on the left side of the sternum. These factors result in a very small margin for error for this particular block.

The anterior cutaneous branch can also be blocked in a plane between the pectoralis major and the intercostal muscles (pecto-intercostal plane block, subpectoral interfascial plane block, parasternal Pecs). The block needle pierces through the pectoralis major, and a slight loss of resistance is felt as it enters the fascial plane.[20] This point of entry into the fascial plane can be on top of a rib/costal cartilage so as to increase the safety margin. A catheter can be threaded once the plane opens up with fluid injection for an extended period of analgesia.

A few other blocks have been described, but essentially, they all target the same plane **(Fig. 2)**.[21]

Lateral Cutaneous Divisions Block Techniques

The serratus anterior muscle (SAM) plane block was described by Blanco in 2013 for breast surgery. 30 mL of LA is injected either superficial or deep to the SAM through the latissimus dorsi over the fifth rib in the mid axillary line. LA deposited superficial to the muscle blocks the intercostobrachial,

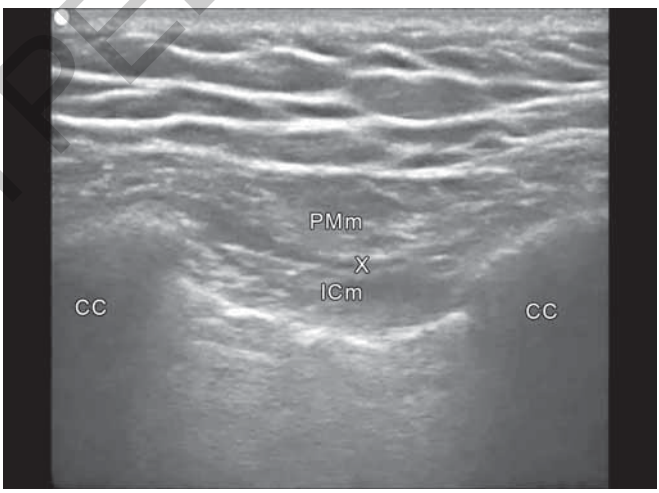

Fig. 2: Ultrasound image for pecto-intercostal plane block showing fascial plane (X) between pectoralis major (PMm) and intercostal muscles (ICm). Probe is placed longitudinally about 1 cm away from the sternal border over the costal cartilages (CC).

JAYPEE BROTHERS

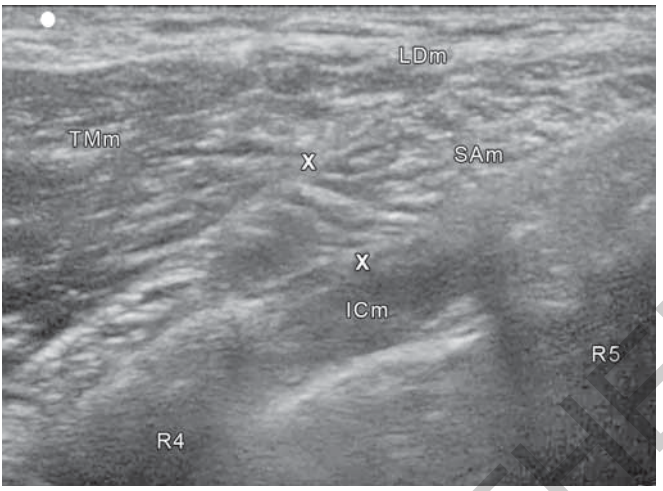

Fig. 3: Ultrasound image for serratus anterior plane block showing latissimus dorsi (LDm), teres major (TMm), and serratus anterior (SAm) muscles over fourth (R4) and fifth (R5) ribs with probe placed longitudinally in the mid-axillary line. LA may be deposited in the fascial layer (X) superficial or deep to the serratus anterior muscle.

second to ninth intercostals, and long thoracic and thoracodorsal nerves. Deeper injection spares the long thoracic and thoracodorsal nerves, which run superficial to the SAM.[22] This block has been shown to be beneficial for thoracotomy.[23] The thoracotomy incision extending into the anterior cutaneous branch territory may need to be supplemented with a parasternal block, like those discussed earlier, for better efficacy **(Fig. 3)**.

Pecs II block (modified Pecs I block) was described by Blanco in 2012. It targets the lateral and medial pectoral nerves and lateral cutaneous branches of T2–4 consistently, with a variable spread to T6. The LA is delivered in two planes. 10 mL is injected in the plane between pectoralis major and minor to block the pectoral nerves. 20 mL is injected in a deeper plane between serratus anterior and pectoralis minor muscles. The ultrasound probe is put in an oblique fashion on the anterior axillary line, over the third rib. Needle insertion is made in plane from the superior-medial to the inferior-lateral direction **(Fig. 4)**.[24]

Pecs I block was the first of the three fascial plane blocks of the chest wall described by Blanco, and is included here though it does not block the lateral cutaneous branches of ICNs. It deposits 20 mL of LA in the fascial plane between the two pectoral muscles. The ultrasound probe is positioned under the clavicle as for infraclavicular brachial plexus block. The pectoral muscles overlying the axillary vessels are seen with the fascial plane between the muscles containing the pectoral branch of the thoracodorsal artery. Pectoral nerves arise from the brachial plexus, traverse through this plane, and are supposed to be purely motor. However, in procedures that involve muscle

JAYPEE BROTHERS

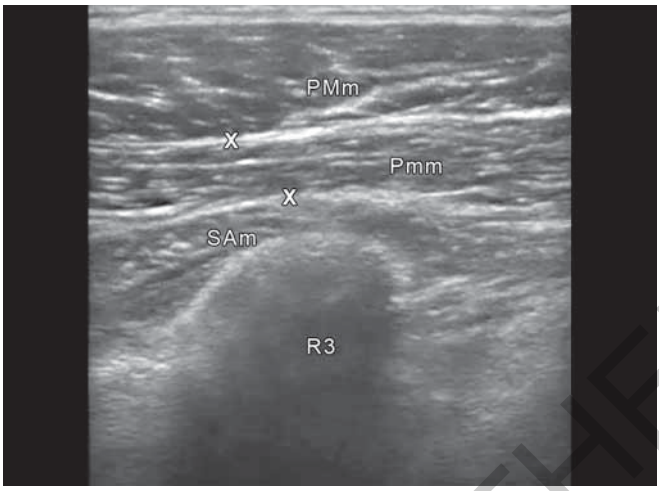

Fig. 4: Ultrasound image for Pecs II block showing the fascial planes (X) between pectoralis major (PMm), minor (Pmm), and serratus anterior (SAm) muscles over third rib (R3). Probe is placed obliquely (superior-medial to inferior-caudal) near the anterior axillary line.

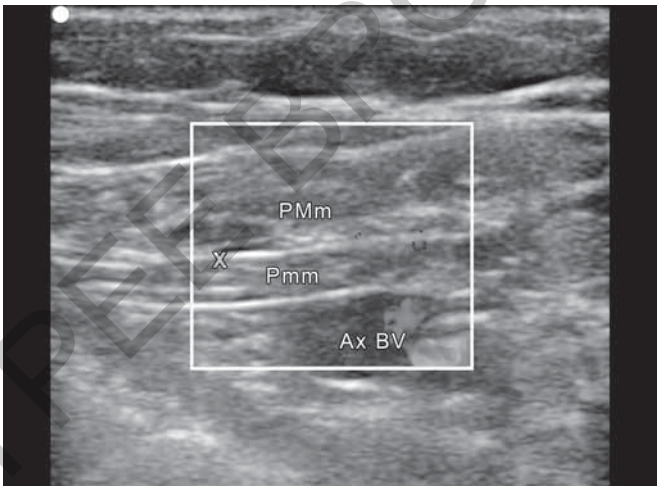

Fig. 5: Ultrasound image for Pecs I block showing the fascial plane (X) between pectoralis major (PMm) and minor muscles (Pmm) over the axillary blood vessels (Ax BV). A high frequency linear ultrasound probe is placed longitudinally in infraclavicular region as for infraclavicular brachial plexus block.

JAYPEE BROTHERS

stretch, as during permanent pacemaker insertion, these nerves may play a role. Pecs I block does not result in any cutaneous anesthesia **(Fig. 5)**.[25]

Rhomboid intercostal sub-serratus plane (RISS) block is a paraspinal intercostal plane block. It was described by Elsharkawy et al. in 2018. It targets the same plane as the SAM plane block albeit over the posterior aspect of the chest wall, the auscultation triangle, with an aim to block the dorsal rami and

the lateral cutaneous divisions. The needle insertion site is away from most of the surgical incisions and is therefore amenable to preoperative catheter insertion. It spares the long thoracic nerve.[26]

The serratus anterior plane block is yet another variation that attempts to combine Pecs I, Pecs II, and SAM plane blocks in one. The needle is inserted in plane from the medial to lateral direction over the fourth rib to deposit the LA in the plane between the Pecs major and the SAMs. The authors explain that the needle insertion point is away from the axilla in order to avoid injuring the long thoracic nerve and the accompanying blood vessels. The nerves blocked are the lateral cutaneous branches of the ICNs.[27]

Dorsal and Ventral Rami Blocks (Proxy Paravertebral Blocks)

Thoracic epidural and paravertebral blocks block somatic as well as visceral pain. The fascial plane blocks described thus far take care of somatic pain only. This section deals with a set of block techniques that can be called proxy paravertebral blocks as the ultimate destination of the LA is the paravertebral space.

For a successful thoracic paravertebral block, the needle has to pass through the SCTL to deposit the LA in the paravertebral space. That was the thinking till 2017 when Costache et al. described the midpoint transverse process to pleura (MTP) block and demonstrated that the SCTL need not be pierced. LA that is deposited superficial to it still reaches the paravertebral space. Hence, it is considered a safer approach with a lower risk of pneumothorax.[28]

Retrolaminar block was described in 2006 as a landmark-guided technique.[29] Zeballos et al. used ultrasound guidance to perform this block for breast[30] and rib fracture analgesia.[31] The LA, which is deposited deep to the paraspinal muscles over the vertebral lamina, spreads into the paravertebral and the epidural spaces through the inter transverse ligament **(Fig. 6)**.

Erector spinae plane block is the most recent ultrasound-guided truncal fascial plane block. It was described by Forero et al. in 2016 for thoracic neuropathic pain.[32] It has since been applied widely to produce ipsilateral analgesia from the head to toe, for acute as well as chronic pain conditions in all age groups.[33] LA is deposited deep to the erector spinae muscle on top of the tip of the TP. 3.4 mL volume of LA is required for each vertebral level to be blocked.[34] It has been inconsistently shown to spread longitudinally across multiple segments, anteriorly to the paravertebral space, and laterally toward the lateral cutaneous branches **(Fig. 7)**.

Costotransverse block[35] and costotransverse foramen block[36] have been described in 2019 by Neilsen et al. and in 2020 by Shibata et al. as alternate approaches to thoracic paravertebral space. They are essentially modifications of the MTP technique described earlier. The LA is deposited medial to the SCTL and anterior to the intertransverse ligament near the base of the TP from where it travels to the thoracic paravertebral space.

JAYPEE BROTHERS

for detailed information on anesthesia books, visit our website www.jaypeebrothers.com, for detailed infor

Yearbook *of* Anesthesiology 11

This *Yearbook of Anesthesiology* is the 11th yearbook of the popular Anesthesiology publication by the Indian College of Anaesthesiologists. This book contains chapters on recent advances in Anesthesiology covering all subspecialties of Anesthesiology. International experts in different fields have written the chapters.

Medicine is an ever-evolving field. Research and advances in the medical field are taking place at breakneck speed. The subject of Anesthesiology has seen tremendous advancement in the last few decades. To keep pace with this immense progress, we need to be abreast with the ever-expanding knowledge base. This book is an attempt to bridge the knowledge gap created by advances in the specialty.

The book is easy-to-read and written in a simple style. The knowledge in the book will benefit young Anesthesiologists preparing for exit examinations and interviews. Practicing Anesthesiologists will benefit from the recent updates in the management of patients with comorbidities. This book will help physicians in small centers and remote areas not regularly exposed to complex cases and with limited access to recently published literature.

Printed in India

Available at all medical bookstores
or buy online at www.jaypeebrothers.com



JAYPEE BROTHERS
Medical Publishers (P) Ltd.
EMCA House, 23/23-B, Ansari Road,
Daryaganj, New Delhi - 110 002, INDIA
www.jaypeebrothers.com

Join us on facebook.com/JaypeeMedicalPublishers

Shelving Recommendation
ANESTHESIA

