site www.jaypeebrothers.com, for detailed information on radiology books, visit our website www.jaypeebrothers.com, for detailed information on radiology books, visit our website www.jaypeebrothers.com

Bestselling Book by Subject Specialists

diginerve
A Jaypee Initiative
• Video Lectures • Dr. Wise AI Chatbot
• Question Bank • Notes
Download App

Thoroughly Updated with all Recent and Image-based Questions

Review of RADIOLOGY

A Must-buy Book for NEET-PG, INI-CET & FMG Exams

Based on facts and concepts from Som and Curtin, Dahnert, Grainger, Sutton, Scott, Rumack, CT and MRI (Haaga), and CME Series Updated based on latest editions of standard books

INI-CET Pattern Questions

6th Edition



Rajat Jain
Virendra Jain

JAYPEE

Contents

Recent Questions and Answers *xiii-xxviii*

Section A: General Radiology

1. General Radiology 3

Section B: Systemic Radiology

2. Neuroradiology 47
3. Cardiothoracic Radiology 84
4. Gastrointestinal and Genitourinary System 136
5. Musculoskeletal Radiology 184

Section C: Radiotherapy and Nuclear Scans

6. Radiotherapy and Chemotherapy 229
7. Nuclear Scans 257

Section D: Special Section

Few Thumb Rules in Radiology 275

Image-Based Questions 285
AIIMS New Pattern Questions with Answers 311

CHAPTER

4

Gastrointestinal and Genitourinary System

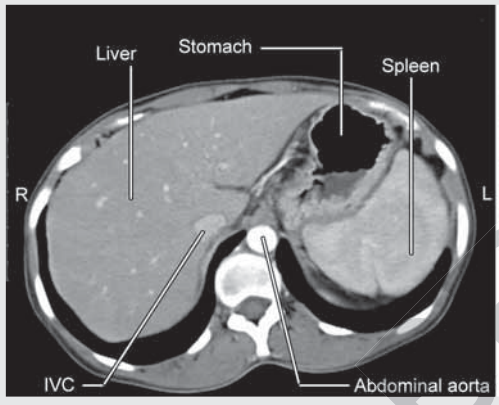

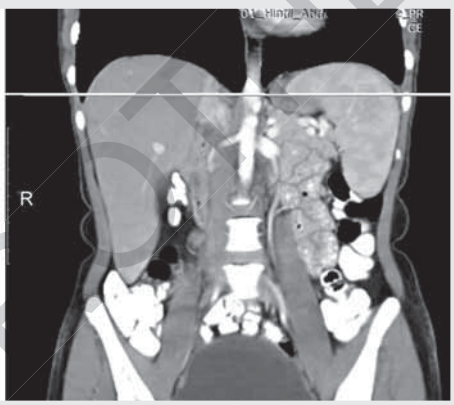

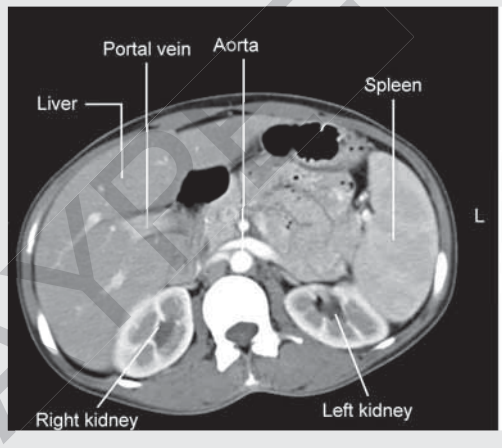

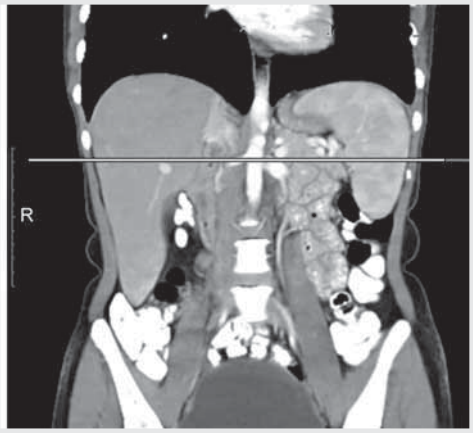

JAYPEE BROTHERS

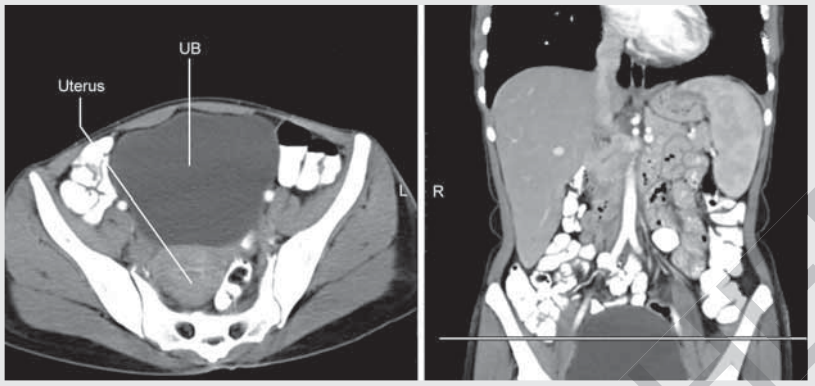

ESOPHAGUS

- Barium studies are **better to diagnose motility disorders** and dysphagia if more for liquids than solids (as seen in achalasia cardia).
- **Gold std** for **motility disorders**Q → **Manometry** like for:
  - Scleroderma
  - Achalasia cardia
  - Diffuse esophageal spasm
- **IOC for intraluminal lesions and complications of esophageal diseases- endoscopy**
- Endoscopic ultrasonography is **investigation of choice** for rest of the esophageal lesions specifically intramural and extraluminal. (Can't be seen on endoscopy)
- EUS: Even can differentiate b/w **T_1 to T_3 lesions for TNM staging-more accurate** [CT/MRI can only d/d b/w (T_1–T_3) and (T4) lesions as these cannot tell exact layer of infiltration in the wall of esophagus] [5-layers]
- EUS even considered IOC for local staging of Ca esophagus over **PETCT But for metastatic workup-PETCT is IOC**

important

Barium studies are done under fluoroscopic guidance which is real time X-ray imaging and motility can be assessed unlike other studies where fix images are taken.

important



Achalasia Cardia
(Bird's beak sign)

Esophageal Markings on Barium Column

Normal

- Aortic arch and main bronchus
- Impression by LA in front
- At entry into diaphragm

JAYPEE BROTHERS

Abnormal

- Right-sided aortic arch indents the esophagus on Right
- Coarctation of aorta → **Reverse '3' sign** (due to pre- and poststenotic dilatations)
- *Aneurysms of aortic arch and descending aorta (dysphagia aortica → dysphagia in old due to unfolding of aorta)
- ***Aberrant Right subclavian A → Indentation on posterior wall (Dysphagia lusoria)**
- **LA/LV enlargement (MS) → Anterior impression on esophagus**

Achalasia Cardia

- **Birds beak at GE junction**[Q]
- If long duration disease, dilated esophagus with air fluid level can be seen on CXR-PA (Erect)
- If barium retained for > 5 minutes—supportive evidence on barium studies
- Premalignant
- Amyl nitrate and hot water improve while methacholine worsen symptoms.

important

Bird's beak has a smooth surface and rat's tail has an irregular surface hence is a feature of carcinoma/secondary achalasia due to Ca.

Diffuse Esophageal Spasm

- Corkscrew on barium, seish kebab, rosary bead

important

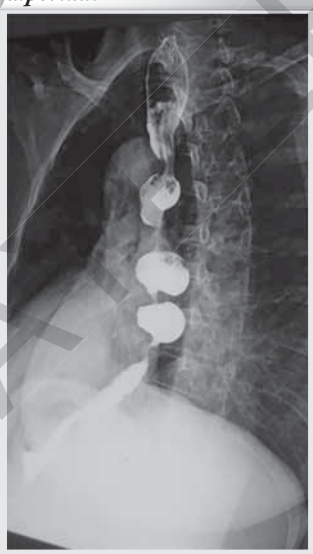

Cork screw appearance in diffuse esophageal spasm

Scleroderma

- Patulous esophagus (GE junction) + lung ILD + mediastinal nodes with GE reflux [Involvement of distal esophagus as scleroderma does not involve voluntary muscles in upper esophagus].

GERD

- 24-h pH monitoring **(Gold std)**[Q]
- IOC for complications—endoscopy

Ca Esophagus

- If Ca develops in long standing case of achalasia cardia—dilated esophagus can be seen both prox. and distal to lesion on barium.

Features on Barium Study

- Irregular mucosal outline-**Rat tail appearance**[Q]
- Narrowing
- **Shouldering of ends (arrow in figure)**

IOC → Endoscopic ultrasound + biopsy

JAYPEE BROTHERS

Biopsy for confirmation of malignancy
Endoscopic ultrasound for local staging

Computed Tomography

- Most widely used for distant spread
- Prone position is preferred
- Criteria for Invasion
  - Loss of triangle of fat between esophagus, aorta, and spinal column
  - > 90° contact with Aorta
  - Nodular protrusion into airway

Echo Endoscope/Endoscopic Ultrasonography

- [EUS] (7-12 MHz)-highest spatial resolution.
- **Radial–perpendicular to scope–**for staging.
- **Linear–parallel to axis** → for FNAC/Biopsy.

**Lower esophageal cancer if epicenter within 5.00 cm from GE junction (AJCC–Guidelines for Ca stomach)
**Coeliac and perioesophageal cervical nodes are regional rather than metastasis.
**(N) esophagus < 5 mm thick on CT
Thickness of wall of esophagus < 5 mm normally on CT

important

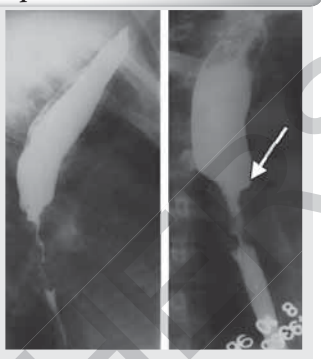

Shouldering in Ca Esophagus

important

Most malignant nodes do not enlarge and hence nodal enlargement cannot be taken as a criteria for spread of disease. Rounding, loss of central fat and hypoechoic nodes

HERNIA AND DYSPHAGIA

First investigation in patient suspected with dysphagia is barium swallow.

Bochdalek's Hernia

- MC congenital
- Through a defect in posterolateral diaphragm
- Can show 13 pairs of ribs [B-PL]

Post-traumatic

- On barium herniation of bowel loop in thorax through rent → **Love bird sign**

Hiatus Hernia

- GE junction > 2 cm above hiatus [normal in rolling hernia]
- Widened hiatus > 2.5 cm
- > 3 gastric folds above hiatus [under fluoro direct visualization]
- Schatzki's or B-Ring [Sq-columnar junction] > 2 cm above hiatus

important

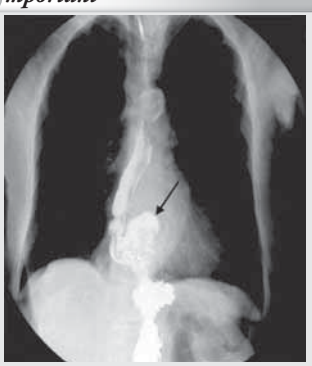

Sliding hiatus hernia on barium swallow study

JAYPEE BROTHERS

High Resolution Manometry is Gold Std for Sliding Hiatus Hernia.

Important



Zenker's diverticulum

Zenker [Pharyngoesophageal] Diverticulum

- X-ray- can show air fluid level posterior to prox. end of esophagus
- **Barium – IOC** → contrast filled out pouching through killian dehiscence
- Endoscopy is difficult → contraindicated in suspected c/o of Zenker's with potential danger of rupture

Killian-Jamieson Pouch/Diverticula

- Protrusion from anterolateral wall d/t weaknesss in upper cervical esophagus just below the level of cricopharyngeus d/t passage of inferior laryngeal nerve through it.

Dysphagia Lusoria

- Dysphagia due to aberrant vascular loop around esophagus
- MC is aberrant right SCA-**Angiography → gold std**.

Dysphagia Aortica

- In old age due to unfolding of aorta. Loop of aorta causes external compression on lower esophagus

Important

- Most common benign sub mucosal lesion of esophgos leiomyoma
- EUS can show origin from M.mucosa/muscularis propria
- **Best: biopsy** as GIST and leiomyoma look same on EUS

ESOPHAGITIS

Barium Findings

Eosinophilia	– Low caliber esophagus
Barrett's esophagitis	– granular/reticular appearance
Candida	– Large linear mural plaques
Radiation/caustic injury	– Long stricture
HIV/CMV	– Large ovoid/diamond shape.

Important

Acquired hypertrophy of pylorus d/t → peptic ulcer/inflammation → does not show shouldering

STOMACH

Hypertrophic Pyloric Stenosis

Hypertrophied muscles lengthens and narrows canal

- **IOC → USG**[Q]

JAYPEE BROTHERS

- **Criterias on USG:** Elongated pylorus with thickened muscle **(most specific)**
  - ≥ 16 mm length
  - ≥ 13 mm transverse diameter
  - ≥ 4 mm circular muscle thickness
- Barium Signs of IHPS
  - String sign [most specific sign] (2)
  - Shouldering (antral) (due to retrograde bulge of muscles) (5)
  - Double track sign/triple track sign/double string sign
  - Beak sign (antral)
  - Pyloric canal is curved upward posteriorly
  - Diamond sign/Twining recess (3)
  - Pyloric teat sign
  - Olive pit sign (4)
  - Caterpillar sign
  - Kirklin mushroom sign → d/t indentation of base of-duodenal bulb (1)
- Treatment of choice is ramstedt pyloromyotomy

important

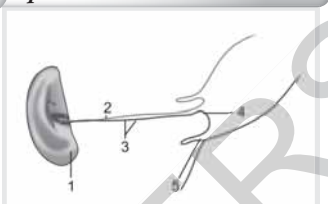

Antral signs

Peptic Ulcer

Benign	Malignant
• Margin-Smooth ulcer **mound** d/t mucosal edema [circular filling defect/**ulcer collar**	• **Heaped up nodular margins**
• Sharphy punched out lesion-dependent position	• Overt neoplastic tissue with shaggy and necrotic base
• Ring shadow in nondependent ulcer	• **Gastric folds do not reach the ulcer crater**
• **Hampton's line (in fallible sign-pathognomonic)** (overhanging mucosa at margin)	• **Carman's Meniscus sign**
• Penetrating sign if within wall rather than mass with-smooth/clean base of ulcer	• Kirkland complex
• **Radiating folds are smooth symmetric reaching up to edge of ulcer in sponge like manner [spoke wheel patterns]** [ulcer crater may extend beyond wall]	• Intraluminal crater rather than only in wall

Contd...

important

If perforation suspected → use water soluble contrast as barium can lead to granuloma formation/peritoneal fibrosis.

important

You don't see shouldering in antral narrowing due to gastritis unlike in IHPS.

important

Breast ca metastasis can also be like linitis plastica i.e. diffuse thickening of stomach wall.

JAYPEE BROTHERS

Important

- Double bubble sign
  - Ladd bond/malrotation
  - Annular pancreas
  - Duodenal atresia/ stenosis
- Single bubble sign → IHPS
- **Triple/many multiple bubble** → jejunal/Ileal obstruction
- **Apple core sign** → Ca colon (mainly → R sided)
- **Napkin ring** → Ca colon [(L) sided]
- **Coiled spring sing** → Intussusception
- **String of Kantor sign** → Crohn's disease
- **String sign** → IHPS/ICTB
- **Rams horn shape** → stenotic disease due to scarring and fibrosis causing narrowing of gastric antrum and pylorus into a funnel
- **Wind sock** appearance → duodenal web/diverticulum.
- **Hide bound** appearance → scleroderma of intestine

Contd...

Benign	Malignant
• Can show area gastricae in ulcer crater	• Strong enhancement at the site of ulcer than adjacent wall on CECT
• Normal peristalsis	• Abnormal peristalsis

**Superficial erosions are till muscularis, mucosa → mound of edema only if complete erosions
****Trifoliate duodenum** → chronic duodenal ulcer with scarring.
**In barium study it is recommended do both prone and supine views to exclude anterior wall perforation.

Gastritis

- Thick folds > 5 mm (most useful), [For H. Pylori Gastritis]
- Prominent area gastricae [most specific]-for H. Pylori gastritis
- Antral narrowing
- Inflammatory polyps

Gastric Striae

- Transverse folds impressions by gastric mascularis mucosa in c/o antral gastritis.

Emphysematous Gastritis

- It is due to acute gas forming infection

Important

**Presence of gastric varices in absence of esophageal varices is a sign of splenic vein thrombosis [due to pancreatitis/ca pancreas].

Gastric Emphysema

- Air in wall of stomach, without infection

Phlegmonous Gastritis

- If pan mural inflammation

Linitis Plastica

- Better appreciated on fluoroscopy than endoscopy:
- Causes
  - Adenocarcinoma
  - Diffuse scirrhous carcinoma **[leather bottle appearance]**
  - NHL **[If adenopathy is bulky and also below renal hila and with splenomegaly]**
  - Breast metastasis
  - Kaposi sarcoma

Important

Marked irregular narrowing of antrum and Ist part of duodenum → **Pseudopost Billroth I-appearance [Crohn's disease].

JAYPEE BROTHERS

Bull's Eye Lesions in Stomach (due to central ulceration)

- Submucosal metastasis [MC-melanoma]
- Lymphoma
- Carcinoma breast, bronchus, pancreas
- Carcinoid
- Leiomyoma
- Kaposi sarcoma
- Ectopic pancreas [central dip due to rudimentary duct]

important

**Wilkie's SMA compression synd-If compression and dilatation of duodenum (transverse IIIrd part) present even on prone films.

Rotation/Volvulus

Organoaxial rotation [more common]

- Axis along cardia and pylorus
- If horizontal originally then→Greater curvature up and lesser low (more common)
- If stomach vertically oriented → (R) → (L) shift

- **Mesentericoaxial (mainly traumatic)**
  - Antropylorus at a higher level then fundus and cardia [known as → Upside down stomach]

important



Apple core sign
Ca – ascending color
– apple core sign on barium studies

Radiological Signs of Malabsorption on Barium

- Dilatation
- Rapid transit
- Flocculation of contrast [**Snow flake-like deposits**]
- Segmentation of barium column
- Fold thickening
- Excessive secretion
  - Causing dilution of contrast
  - Reduced mucosal coating

Other Barium Signs

- **"Moulage sign"**→Tube-like appearance of bowel seen in Crohn's disease
- **Stacked coin appearance** → In HSP due to submucosal hemorrhages
- **Hide bound appearance** → scleroderma
- **Scalloped edges of sigmoid colon**-pneumatosis intestinalis
- **Saw tooth appearance** → Diverticulosis
- **String sing**
  - Crohn's (of Kantor's)
  - TB
  - IHPS

important

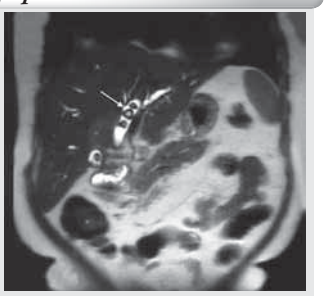

CBD/Gallstone on MRI
Filling defect on T_2W images

JAYPEE BROTHERS

QUESTIONS

1. **Which of the following is not seen on ultrasound in acute pyelonephritis?**
   a. Grossly enlarged kidney
   b. Focal area of hypoechogenicity
   c. Perinephric collection (pus in the perinephric space)
   d. Increased vascularity
2. **On barium contrast radiography, which among the following is false:**
   a. Ileum is featureless
   b. Colon has haustrations
   c. Jejunum is feathery
   d. Distal part of duodenum has a cap
3. **Central dot sign is seen in:**
   a. Primary sclerosing cholangitis
   b. Liver hamartoma
   c. Caroli's disease
   d. Polycystic liver disease
4. **The radiological procedure for studying vesico-ureteric reflux is:**
   a. Ascending pyelogram
   b. Cystogram
   c. Intravenous pyelogram
   d. Micturating cystourethrogram
5. **Which of the following is true regarding the principle of use of MRCP?**
   a. Intraluminal dye is used to create the three-dimensional view of the structures
   b. Dye is instilled percutaneously first, then MRI is used
   c. Use of heavily T2-weighted image without contrast to create the three-dimensional image of the biliary tree using MIP algorithm
   d. Use of systemic gadolinium as a contrast agent to create the three-dimensional image of the biliary tree
6. **Micturating cystourethrography is used in the diagnosis of:**
   a. Vesicoureteric reflex and posterior urethral valve
   b. Rupture urethra
   c. Stricture urethra
   d. Ca of the bladder
7. **Investigation of choice in small renal calculi:**
   a. Low dose non-enhanced CT
   b. High dose non-enhanced CT
   c. Low dose enhanced CT
   d. High dose enhanced CT
8. **Distribution of functional renal tissue is seen by:**
   a. Dimercaptosuccinic acid (DMSA)
   b. Diethylene triamine penta-acetic acid (DTPA)
   c. Mercaptoacetyle triglycine 3 (MAG3) - Tc99
   d. I 123 iodocholesterol
9. **On X-ray, small bowel can be differentiated by large bowel by having:**
   a. String of beads sign
   b. Haustrations
   c. Peripherally placed concave coil of intestine
   d. Air fluid level
   e. Valvulae conniventes
10. **Renal agent used for assessing cortical scarring:**
    a. TC-99 m DTPA
    b. TC-99 m DMSA
    c. TC-99 m Glucohepatanate
    d. 1-131- Hippuran
11. **For suspected ureteric calculus, the modality of choice is:**
    a. Noncontrast CT
    b. Ultrasonography
    c. X-ray KUB
    d. Cystoscopy

JAYPEE BROTHERS

12. Which one of the following imaging modalities strive for evaluation of extra-adrenal pheochromocytoma?
a. Ultrasound
b. CT
c. MRI
d. MIBG scan

13. For renal stone, diagnosis is not done by:
a. IVP b. MRI
c. PET-scan d. CT-scan

14. Of the following imaging modality is most sensitive investigation of choice to detect early renal tuberculosis:
a. Intravenous urography
b. Ultrasound
c. Computed tomography
d. Magnetic resonance imaging

15. Posterior urethra is best visualized by:
a. Static cystogram
b. Retrograde urethrogram
c. Voiding cystogram
d. Cr cystogram

16. Radiation exposure is least in the following procedure:
a. Micturating cystourethrogram
b. IVP
c. Bilateral nephrostogram
d. Spiral CT for stones

17. All of the following form radiolucent stones except:
a. Xanthine
b. Cysteine
c. Indinavir associated stones
d. Allopurinol associated stones

18. Most sensitive and specific investigation for diagnosis of renovascular hypertension:
a. MRI
b. Captopril-enhanced radionuclide scan
c. Spiral CT angiography
d. Catheter angiography

19. Abdominal ultrasonography in a 3-year-old boy shows a solid circumscribed hypoechoic renal mass. Most likely diagnosis is:
a. Wilms' tumor
b. Renal cell carcinoma
c. Mesoblastic nephroma
d. Oncocytoma

20. Which of the following is not an appropriate investigation for anterior urethral stricture?
a. Magnetic resonance imaging
b. Retrograde urethrogram
c. Micturating cystourethrogram
d. High-frequency ultrasound

21. Transrectal ultrasonography in carcinoma prostate is most useful for:
a. Guided prostatic biopsies
b. Seminal vesicle involvement
c. Measurement of prostatic volume
d. To detect hypoechoic area

22. Papillary necrosis features are all except:
a. Egg in cup
b. Hyperdense nephrogram
c. Calyceal horns
d. Ring shadows

23. The most important sign of significance of renal artery stenosis on an angiogram is:
a. A percentage diameter stenosis >70%
b. Presence of collaterals
c. Stenosis > 50%
d. Thrombosed renal artery

24. Dense persistent renogram is obtained by:
a. Dehydrating the patient
b. Increasing the dose of contrast media
c. Rapid (bolus) injection of dye
d. Using nonionic media

JAYPEE BROTHERS

ANSWERS

1. **Ans. d.** Increased vascularity
2. **Ans. d.** Distal part of duodenum has a cap
3. **Ans. c.** Caroli's disease
4. **Ans. d.** Micturating cystourethrogram
5. **Ans. c.** Use of heavily T2-weighted image without contrast to create the three-dimensional image of the biliary tree using MIP algorithm
6. **Ans. a.** Vesicoureteric reflex and posterior urethral valve
7. **Ans. a.** Low-dose non-enhanced CT to reduce penetration and hence ↑ resolution like in mammography
8. **Ans. a.** Dimercaptosuccinic acid (DMSA)
9. **Ans. e.** Valvulae conniventes
10. **Ans. b.** TC-99 m DMSA
11. **Ans. a.** Noncontrast CT
12. **Ans. d.** MIBG scan
13. **Ans. c.** PET-scan
14. **Ans. a.** Intravenous urography
15. **Ans. c.** Voiding cystogram
16. **Ans. c.** Bilateral nephrostogram
17. **Ans. b.** Cysteine
18. **Ans. d.** Catheter angiography
19. **Ans. a.** Wilms' tumor
20. **Ans. a.** Magnetic resonance imaging
21. **Ans. a.** Guided prostatic biopsies
22. **Ans. b.** Hyperdense nephrogram
23. **Ans. b.** Presence of collaterals
24. **Ans. a.** Dehydrating the patient
25. **Ans. c.** Barium examination showing tertiary contractions
26. **Ans. b.** Duodenal atresia
27. **Ans. d.** Carcinoma of stomach
28. **Ans. a.** Peptic ulcer
29. **Ans. a.** Single bubble appearance
30. **Ans. d.** All of the above
31. **Ans. c.** Sigmoid volvulus
32. **Ans. b.** Small bowel obstruction
33. **Ans. a.** Crohn's disease
34. **Ans. d.** Longitudinal ulcers are more common
35. **Ans. d.** Lesser curvature ulcer with a nodular rim
36. **Ans. b.** High gastric-residue
37. **Ans. c.** Ileal atresia
38. **Ans. d.** Cupola sign
39. **Ans. a.** String sign of Kantor
40. **Ans. b.** Ulcerative colitis
41. **Ans. a.** Apple-core appearance
42. **Ans. d.** Dilution of barium
43. **Ans. d.** Lt lateral decubitus with horizontal beam
44. **Ans. c.** Lateral decubitus
45. **Ans. c.** Thumb printing
46. **Ans. a.** Valvulae conniventes
47. **Ans. b.** Peripheral distribution
48. **Ans. b.** Valvulae conniventes
49. **Ans. d.** Meconium ileus
50. **Ans. a.** For showing presence of a small pneumoperitoneum
51. **Ans. c.** Left lateral recumbent view
52. **Ans. a.** Radiological finding in supine posture for pneumoperitoneum
53. **Ans. a.** Colonic diverticulosis
54. **Ans. b.** Chronic pancreatitis
55. **Ans. d.** Simple cyst
56. **Ans. b.** Polyp
57. **Ans. a.** Liver
58. **Ans. d.** Contrast-enhanced CT scan of the liver
59. **Ans. c.** Focal nodular hyperplasia
60. **Ans. a.** Dilation of pancreatic duct
61. **Ans. d.** Quadrate lobe
62. **Ans. b.** Cullen's sign
63. **Ans. a.** Fuzzy outline of pancreas
64. **Ans. a.** Acute pancreatitis
65. **Ans. b.** Carcinoma head of pancreas
66. **Ans. d.** Serous cystadenoma
67. **Ans. d.** CT scan

JAYPEE BROTHERS

for detailed information on radiology books, visit our website www.jaypeebrothers.com, for detailed information on radiology books, visit our website www.jaypeebrothers.com, for detailed information on radiolo

Review of RADIOLOGY

Image-based learning is an integral part of radiology and studying radiology without images might be a futile attempt to learn it. The paucity of such publications has motivated the authors to bring out this well organized, up to date book of radiology which has all the relevant images and image-based questions along with an online pool of images, covering all the important signs and systemic diseases, which surely do not have any substitute or replacement.

Review of Radiology is an attempt by authors to ensure answers for all the questions related to imaging from all the subjects of clinical domain, like surgery, medicine, obstetrics & gynecology, pediatrics, orthopedics, ENT and ophthalmology. All the topics and concepts given in all the sections (General Radiology, Systemic Radiology, Radiotherapy and Nuclear Scans, Few Thumb Rules in Radiology, Image-based Questions) are not only just for the examinations but also for students' future clinical training and day-to-day working in hospitals.

Review of Radiology is surely an ideal book without which learning of medicine and preparation of entrance examination/USMLE is incomplete.

Rajat Jain MD (MAMC) DNB FRCR (UK) MNAMS is currently working as a Consultant and Head, Department of Radiology, Shree Aggarsain International Hospital, New Delhi. He is a graduate from MAMC, Delhi as RANK-1 in Delhi PG 2007 and also a member of Maulana Azad Medical College Old Student Association, Joint Secretary, Indian Radiological Imaging Association, Radiological Society of North America, American Roentgenology Ray Society, European Society of Radiology and College of Physicians and Surgeons of Ontario, Canada. He also completed his postgraduation in radiology from the same institution. Dr Rajat Jain has done his FRCR from United Kingdom after completing his postgraduation. He has a massive experience of more than a decade with 13,000 hours of core teaching in radiology. An excellent motivator with the key insight of how to crack your exams with flying colors being a Delhi PG rank-1, he is a guiding force to students throughout their entire studies till they become a postgraduate. He is a well-known name among the PG-aspirants in India. He is involved in PG teaching from last 13 years and is loved by students across the country. He is also well-known for his counseling and preparation strategy for the Postgraduate Entrance Exams. He is an author of several research papers and review articles in Journals of National and International Repute. He has also contributed in several chapters in Textbook of Radiology read by postgraduate students.

Virendra Jain MBBS (UCMS) MD (MAMC) FRCR (UK) is currently working as a Consultant Radiologist at University Hospitals of Derby and Burton, NHS Foundation Trust, UK. He is a graduate from University College of Medical Sciences (UCMS) and Postgraduate from Maulana Azad Medical College (MAMC). He topped (Rank-1) Delhi Postgraduate Medical Entrance Examination in 2011. He has done his FRCR from the United Kingdom and has further enriched his knowledge in pediatric radiology from Harvard Medical School and Musculoskeletal Radiology from University of Iowa, USA. He is a member of Indian Radiological Imaging Association, Radiological Society of North America and European Society of Radiology. He is popular for his involvement with postgraduate aspirants and in PG teaching for the last 6 years. He has research papers in journals of international repute and has co-authored in a Textbook of Radiology which is read by postgraduate students.

Printed in India

Available at all medical bookstores or buy online at www.ejaypee.com

JAYPEE BROTHERS
Medical Publishers (P) Ltd.
EMCA House, 23/23-B, Ansari Road, Daryaganj, New Delhi - 110 002, INDIA
www.jaypeebrothers.com

Join us on facebook.com/JaypeeMedicalPublishers
Follow us on instagram.com/JaypeeMedicalPublishers

Shelving Recommendation
RADIOLOGY

ISBN 978-93-5465-369-8