information on physiotherapy books, visit our website www.jaypeebrothers.com, for detailed information on physiotherapy books, visit our website www.jaypeebrothers.com



Physiotherapy in Orthopaedic and Rheumatologic Conditions

Megha Sandeep Sheth
Priya Singh Rangey
Neeta Jayprakash Vyas
Srishti Sanat Sharma
Shivani Siddharth Sheth

JAYPEE

Contents

Section 1: Basic Concepts of Physiotherapy in Orthopedics and Rheumatology

1. Introduction to Orthopedics and Rheumatology **3**
Megha Sandeep Sheth, Priya Singh Rangey, Shivani Siddharth Sheth, Srishti Sanat Sharma, Neeta Jayprakash Vyas

Physiology of Pain 4
Inflammation and Healing 6
Nontraumatology in Orthopedics 6
Traumatology in Orthopedics 7
Physiotherapy in Orthopedic and Rheumatological Conditions 8

2. Clinical Decision Making for Physiotherapy in Orthopedic Conditions **11**
Dinesh M Sorani, Sheshna Rathod

Clinical Decision Making 12
Clinical Reasoning 14
Models of Clinical Decision Making 15
Documentation 16
Clinical Prediction Rule 16
International Classification of Functioning, Disability and Health 18
Clinical Decision Making in Various Areas of Musculoskeletal Disorders 19

Section 2: Clinical Evaluation and Relevant Investigations: Physiotherapy Perspective

3. Assessment in Musculoskeletal Conditions **35**
Saravanan Murugan

Diagnosis in Physiotherapy 35
Subjective Examination 36
Objective Examination 39

4. Common Investigations in Orthopedic Conditions **52**
Aniruddha Pradyuman Barot, Megha Sandeep Sheth

Arthrography 52
Bone Scans/Scintigraphy 53
Computed Arthrography 53
Computed Tomography Scan 53
Diagnostic Ultrasound 54
Diskography 54
Dual Energy X-ray Absorptiometry Scan 54
Electromyography 56
Fluoroscopy 57
Laboratory Investigations 57
Magnetic Resonance Imaging 58
Myelography 60
Nerve Conduction Velocity Study Myelography 60
Quantitative Computed Tomography 61
Radiographs (Plain Film X-rays) 61
Venograms and Arteriograms 63
Xeroradiography 63

5. Disability Evaluation in Orthopedic Conditions **65**
Drashti Niket Shah

Impairment, Disability, and Handicap 65
Classification of Disability 66
Types of Disability 66
Models of Disability 67
Prevention of Disability 67
Guidelines for Evaluation of Permanent Physical Impairment 68
Functional Disability 72
Managing Disability 72

6. Physical Therapy Diagnosis and International Classification of Functioning, Disability, and Health **74**
Bhavana Mhatre

Physical Therapy: Role and Function 74
Examination and Evaluation 75
WHO-ICF Model of Functioning and Disability 77
The ICF Model: Interaction between ICF Components 82

Section 3: Management Strategies in Orthopedic Practice

7. Electrotherapeutics for Orthopedic Interventions **87**
Jayaprakash Damodaran

Cryotherapy 88
Superficial Heating Agents 93
Ultrasonic Therapy 99
Extracorporeal Shock Wave Therapy 106
LASER 106
Therapeutic Low and Medium Frequency Currents 111
Electromagnetic Radiation 119

8. Principles of Manual Therapy—Soft Tissues 138
Amit M Patel, Suman Malukani
Muscle Energy Technique 139
Strain–Counterstrain Technique (Jones Technique) 141
Instrument-Assisted Soft Tissue Mobilization 143
Myofascial Release Therapy 144
Foam Rolling Technique 146

9. Principles of Manual Therapy—Joints 150
Himanshu Mathur
History of Manual Therapy 150
Insight to Neurophysiology of Pain 151
Principles of Manual Therapy 151
Principles Relevant to Schools of Manual Therapy 153

10. Decision-making for Therapeutic Exercises in Orthopedic Conditions 162
Nehal Shah
Classification of Therapeutic Exercises 163
Decision-Making of Exercises on the Basis of Impairments 174
Actual Scenario and Planning the Treatment Strategy 179

11. Neural Tissue Dysfunction in Musculoskeletal Practice 181
Twinkle Dabholkar, Bhavana Mhatre
Continuum of the Nervous System as Basis of Neurodynamics 182
Framework to Base Neurodynamic Techniques 182
Mechanical Events in the Nervous System 182
Events that cause Movement of the Neural Tissue 183
Physiological Effects of Mechanical Events 184
Neuropathies and Neuropathodynamics 185
Neurodynamic Tests 185
Standard Neurodynamic Test Procedures 186
Planning Neurodynamic Examination 188
Treatment Interventions for Neuropathodynamics 188

12. Interventional Pain Management 191
Samir Desai
Pain Basics 192
Diagnosis of Pain 193
Treatment of Pain 194
Interventions for Various Pain Conditions 195
Advanced Modalities 205
Psychological Aspects of Chronic Pain 206
Future of Pain Medicine 207

13. Principles of Pain Management—Physiotherapy 208
M Balaganapathy, Vandita Soni
Definition of Pain 209
Incidence and Prevalence of Pain 209
Categories of Pain and its Types 210
Risk Factors of Pain 210
Mechanism of Pain Management 211

14. Orthoses 217
Shivani Siddharth Sheth
Terminology and Types of Orthoses 217
Function/Purpose of Orthosis Prescription 218
Biomechanical Principles 219
Components of Orthosis 220
Contraindications to Orthoses 221
Disadvantages of Orthoses 221
Orthoses Maintenance 221
Upper Limb Orthoses 222
Wrist-Hand Orthosis 222
Lower Limb Orthoses 226
Shoe 226
Ankle-Foot Orthoses 227
Knee-Ankle-Foot Orthoses 228
Knee Orthoses 229
Hip-Knee-Ankle-Foot Orthoses 229
Trunk-Hip-Knee-Ankle-Foot Orthoses 230
Spinal Orthoses 230
Cervical Orthosis 230
Head Cervical Orthosis 232
Head Cervical Thoracic or Cervicothoracic Orthosis 233
Lumbar Orthosis 234
Sacral Orthosis 234

15. Ergonomics 236
Deepankar Dass
Transformation of Nonergonomic Clinic to an Ergonomic One 237
Ergonomics in Physical Therapy 238
Good Ergonomic Practice 238
Benefits of Good Ergonomic Workplaces 238
Strategies to Reduce Ergonomic Risk Associated with the Tasks 238
Common Risk Factors for Physiotherapist While Treating Patients 238
Significance of Ergonomics in Physiotherapy 240
Contribution of Physiotherapist in Ergonomics 240
Ergonomics for Patient Rehabilitation 240

Section 4: Clinical and Physiotherapy Approaches in Management

16. Spinal Conditions: Clinical 247
Amit Jhala, Sharvin Sheth, Dhruv Patel
Lumbar Disk Prolapse 248
Lumbar Spinal Stenosis 253
Cervical Disk Prolapse 258
Spondylolysis and Spondylolisthesis 261
Cervical Spine Injury 266
Thoracolumbar Injuries 271

17. Spinal Conditions: Physiotherapy Part-I 280
Sona Kolke, Priya Singh Rangey
General Goals of Management of Low Back Pain 281
Physiotherapy Management of Intervertebral Disk Prolapse 288

Cervical Radiculopathy 290
Cervicogenic Headache 295
Thoracic Outlet Syndrome 300
T4 Syndrome 306
Hyperkyphosis 307
Scoliosis 311
Sacroiliac Joint Dysfunctions 315
Pubic Symphysis Pain 317
Coccydynia 318

18. Spinal Conditions: Physiotherapy Part-II 322
Yagna Unmesh Shukla

Anatomy of Spinal Cord 322
Causes of Spinal Cord Injuries 323
Classification of Spinal Cord Injuries 324
Clinical Presentation of Spinal Cord Injuries 324
Impairments in Spinal Cord Injury 324
Assessment of Spinal Cord Injury 327
Prognosis 329
Rehabilitation Team for Management of Spinal Cord Injuries 329
Medical Management 329
Physiotherapy Management in Spinal Cord Injuries 329

19. Upper Limb Fractures 342
Binal Gajjar

Clavicle Fracture 343
Scapula Fracture 345
Proximal Humerus Fracture 346
Shaft of Humerus Fracture 347
Supracondylar Humerus Fracture 351
Intercondylar Fractures of the Humerus 354
Fracture of Single Condyle of the Humerus 354
Olecranon Fracture 355
Radius Head and Neck Fracture 356
Forearm Bone Fractures 357
Colles' Fracture 359
Smith's Fracture 361
Scaphoid Fracture 361
Metacarpal Fractures 363
Phalanx Fractures 363

20. Upper Limb Dislocations 366
Parth Trivedi

Signs and Symptoms of Upper Limb Dislocations 367
Management Guidelines 367
Complications 367
Acromioclavicular Joint Dislocation 367
Sternoclavicular Joint Dislocation 369
Shoulder Joint Dislocation 370
Elbow Dislocation 376
Carpal Dislocations 378
Carpometacarpal Dislocation 379
Metacarpophalangeal Joint Dislocation 380
Interphalangeal Joint Dislocation 381

21. Lower Limb Fractures 384
Sarfraznawaz F Shah

Conservative versus Surgical Management for Lower Limb Fractures 385
Pelvic Fractures 385
Neck of the Femur Fracture 389
Intertrochanteric Femur Fracture 391
Femur Shaft Fracture 393
Distal Femur Fracture 396
Patellar Fracture 398
Tibial Plateau Fracture 399
Shaft of Tibia and Fibula Fracture 401
Pott's Fracture (Bimalleolar Ankle Fracture) 402
Fracture of the Calcaneus 402
Talus Fracture 403
Midfoot or Midtarsal or Chopart's Joints Fracture 404
Tarsal Navicular Fracture 405
Cuboid Fractures 405
Lisfranc Fracture or Tarsometatarsal Fracture 406
Metatarsal Bone Fracture 406
Metatarsophalangeal Joint Fracture 406
Fractures of Phalanges of the Toes 407

22. Lower Limb Dislocations 410
Ketan Pandya

Dislocation of Hip 410
Knee Dislocation 413
Patellar Instability 414
Ankle Dislocation 419

23. Thoracic Injuries 421
Dipmala Nikhil Silajiya

Evaluation and Management 421
The Deadly Dozen Injuries 423
Thoracic Fractures 428
Chest Surgeries 429
Physiotherapy Management 434

24. Temporomandibular Joint Dysfunction 441
Yagna Unmesh Shukla

Anatomy and Biomechanics of Temporomandibular Joint 442
Temporomandibular Joint Disorder 444
Oral Submucous Fibrosis 451

25. Tendon Injuries 455
Bindesh Patel

Structure of a Tendon 455
Pathophysiology of Tendinopathies and Tendon Healing 457
Classification of Tendon Injuries 458
Common Tendon Injuries 458
Hand Deformities Arising due to Tendon Injuries 462

26. Soft-tissue Injuries: Clinical 466
Rohan Vakta

Classification of Soft-tissue Injuries 466
Reinjuries 478

Diagnosis 478
Common Soft-tissue Injuries in Orthopedic Practice 480
Recent Advances for Soft-tissue Injury Management 481

27. Soft-tissue Injuries: Physiotherapy 482
Bhavana Gadhavi
Relevant Anatomy 483
Common Soft-tissue Injuries 483
Ligament Injuries 484
Injury to the Synovial Membrane (Synovium) 487
Injury to the Bursa 488
Muscle and Tendon Injury 488
Meniscal Injuries 492

28. Rehabilitation in Reconstructive Surgeries 502
Reji K Samuel
Common Orthopedic Reconstruction Surgeries 503
Shoulder Arthroscopy 503
Elbow Arthroscopy 507
Wrist Arthroscopy 510
Hip Arthroscopy 513
Knee Arthroscopy 516
Ankle Arthroscopy 517
Wrist Arthrodesis 519
Knee Arthrodesis 521
Ankle Arthrodesis 521
Periacetabular Osteotomy 522
High Tibial Osteotomy 525
Spinal Reconstruction 527
Nerve Injury and Reconstruction 528
Tendon Injury and Reconstruction 530

29. Arthroplasty 534
Alpa Purohit
Hip Arthroplasty 535
Knee Arthroplasty 542
Ankle Arthroplasty 548
Shoulder Arthroplasty 549
Elbow Arthroplasty 552
Wrist Arthroplasty 554

30. Essentials of Rheumatology 559
Ruhani Desai
Arthritis 559
Connective Tissue Disease 563
Vasculitis 568

31. Rheumatoid Arthritis 574
Nupur Shah
Etiology 574
Pathophysiology 575
Clinical Features 575
Classification of Rheumatoid Arthritis 579
Red Flags 579
Diagnosis 580
Prognosis 580
Pharmacological Management 581
Surgical Management 581
Physiotherapy Assessment 581
Physiotherapy Management 582

32. Ankylosing Spondylitis 587
Bhoomika Brahmbhatt
Etiology 588
Epidemiology 588
Pathology 588
Clinical Features 588
Extra-articular Manifestations 589
Radiological Features 589
Differential Diagnosis 590
Complications 590
Diagnosis 590
Physical and Functional Examination 591
Management 596
Physiotherapy Management 597
Evidence-based Medicine 600
Prognosis 600
Mnemonics for AS 600

33. Osteoarthritis 603
Keerthi Rao
Definition 604
Types of Osteoarthritis 604
Pathophysiology 604
Risk Factors 606
Clinical Symptoms 607
Diagnosis 607
Investigation Tools 608
Pharmacological Management 609
Surgical Management 610
Physiotherapy Management 610
Common Arthritic Conditions and their Manifestations 619
Cervical Spondylosis 632
Lumbar Spondylosis 636

34. Other Rheumatoid Conditions 641
Paryushi Rami
Juvenile Idiopathic Arthritis 641
Metabolic Arthritis 644
Hemophilic Arthritis (Bleeder's Joint) 646
Seronegative Spondyloarthropathies 648
Neuropathic Arthritis (Charcot's Joint) 650

35. Nutritional Deficiency, Metabolic and Hormonal Disorders 653
Ajit Dabholkar, Tejashree Dabholkar
Congenital and Metabolic Disorders Leading to Fractures 653
Osteogenesis Imperfecta 654
Other Skeletal Dysplasias 656
Metabolic Causes of Fracture 657
Charcot's Arthropathy 668
Crystal Arthropathies 670
Nutritional Aspects of Bone Health and Fracture Healing 673
Musculoskeletal Disorders and Hormonal Imbalance 675

36. Sports Injuries: Assessment 684
Paras Bhura, Camy Bhura
Classification of Sports Injuries 684
Risk Factors for Injuries 686
Common Sports Injuries 687
Diagnostic Tools for Injury Assessment 689
Sports Assessment 689
Doping in Sports 696

37. Sports Injuries: Rehabilitation 699
Saravanan Murugan
Understanding Sports Injury 701
Principles of Training 703
Sports Injury Assessment 705
Sports Rehabilitation 706
Principles of Therapeutic Exercise in Sports Rehabilitation 709
Therapeutic Modalities in Sports Rehabilitation 724
Manual Therapy in Sports Rehabilitation 728
Aquatic Therapy in Sports Rehabilitation 729
Taping in Sports Rehabilitation 730

38. Repetitive Strain Injury 734
Ajit Dabholkar, Tejashree Dabholkar
Epidemiology 735
Pathophysiology of Repetitive Strain Injury 735
Risk Factors for Causation of Repetitive Strain Injuries 736
The Surveillance Model 737
Diagnosis 738
Stages of Disorders 738
Classification of Repetitive Strain Injury 739
Prevention of Repetitive Strain Injury 746
Ergonomic Risk Assessment and Intervention 747
Health Promotion and General Fitness 754
Return to Work 754
Need for Occupational Health and Safety 755
Work Conditioning and Work Hardening 756

39. Inflammations and Infections 761
Urmi Bhatt
Synovitis 763
Bursitis 765
Tendinitis 772
Osteomyelitis 774
Septic Arthritis 779
Prosthetic Joint Infections 780
Syphilis Infection of Joints 781
Skeletal Tuberculosis 782

40. Bone Tumors 787
Sweta Jagdishchandra Upadhyay
Classification of Bone Tumors 787
General Principles of Diagnosis and Management of Tumors 788
Benign Bone Tumors 791
Malignant Bone Tumors 792
Primary Bone Tumors 792
Physiotherapy Management 795

41. Management of Common Pediatric Orthopedic Conditions 799
Dhiren Ganjwala, Hitesh Shah
Clubfoot 799
Developmental Dysplasia of the Hip 802
Perthes' Disease 804
Cerebral Palsy 806

42. Management of Common Pediatric Orthopedic Conditions: Physiotherapy 811
Nupur Shah
Physiotherapy Assessment 812
Cerebral Palsy 813
Poliomyelitis 815
Congenital Torticollis 816
Developmental Dysplasia of Hip 819
Coxa Vara 821
Perthes Disease 822
Genu Varum (Bow Legs) 824
Genu Valgum (Knocked Knees) 826
Congenital Talipes Equinovarus (CTEV) 827
Pes Cavus 829

43. Miscellaneous Conditions in Orthopedics 832
Neha Mukkamala, Purvi Patel
Trigger Finger 833
Dupuytren's Contracture 834
De Quervain's Tenosynovitis 835
Ganglion 837
Tennis Elbow/Lateral Epicondylitis 838
Golfer's Elbow/Medial Epicondylitis 840
Carpal Tunnel Syndrome 843
Causalgia 845
Fibromyalgia 846
Myofascial Pain Syndrome 847
Plantar Fasciitis 849
Chondromalacia Patellae 852
Osgood-Schlatter Disease 855
Metatarsalgia 856
Hallux Valgus 857

Index 865

4 Common Investigations in Orthopedic Conditions

Aniruddha Pradyuman Barot, Megha Sandeep Sheth

LEARNING OBJECTIVES

After reading this chapter, the reader should be able to:

- Gain a basic concept about various investigations used in orthopedic conditions.
- Understand their indications and contraindications.
- Understand the advantages and disadvantages of various investigations.
- Gain in-depth knowledge about the practical implications of the common investigations used in orthopedics.

CHAPTER OUTLINE

- Introduction
- Arthrography
- Bone Scans/Scintigraphy
- Computed Arthrography
- Computed Tomography Scan
- Diagnostic Ultrasound
- Diskography
- Dual Energy X-ray Absorptiometry Scan
- Electromyography
- Fluoroscopy
- Laboratory Investigations
  - Biopsy
  - Blood Tests
  - Joint Fluid Aspiration and Analysis
  - Urine Examination
- Magnetic Resonance Imaging
- Myelography
- Nerve Conduction Velocity Study
- Quantitative Computed Tomography
- Radiographs (Plain film X-rays)
- Venograms and Arteriograms
- Xeroradiography

Introduction

Making a medical diagnosis requires a triad of history taking, clinical examination, and investigations. To understand a condition completely, certain investigations are required. They can be radiological or can be conducted at a laboratory. They range from simple X-rays to sophisticated investigations using various materials. Investigations may be invasive or noninvasive. These investigations allow us to know what is happening inside the body and provide a detailed picture of the same. Certain investigations are used to confirm a diagnosis, whereas certain other investigations are used to rule out other possible diagnoses.

It is important to remember that investigations are used to confirm a clinical diagnosis. They should be used as an adjunct to thorough clinical examination and not replace clinical examination.

Judicial use of investigations helps make a thorough examination and diagnosis. It is important to know the use of various investigations and their interpretation.

The following are some of the investigations commonly used in the diagnosis of orthopedic conditions.

Arthrography

- It is a diagnostic method in which air or a water-soluble contrast material which contains iodine, or both, is infused into a joint cavity and after that a radiograph is taken of the same joint.
- The air or contrast material traces the structures inside the joint.
- Arthrography is also known as "arthrogram."
- It is a very useful diagnostic tool especially for detecting lesions of articular cartilage, synovial structures, joint capsule abnormalities, and bursal lesions.

- Arthrography can be used to know the extent of intra-articular injuries, in the diagnosis of spinal pathology or to confirm capsular tears, or loosening of a prosthesis.

Clinical Pointer

Following joints are commonly examined using arthrography:
- Shoulder joint
- Elbow joint
- Wrist joint
- Hip joint
- Knee joint
- Ankle joint

Bone Scan/Scintigraphy

- Bone scans are also known as "bone scintigraphy".
- In this procedure, a small amount of radioactive substance/isotope called "tracer" (e.g., Technetium-99m–labeled methyl diphosphonate complexes) is injected into a vein several hours before the scan, to localize specific organs that concentrate the tracer.
- The tracer is then localized where there is highest level of metabolic activity relative to the rest of the bone.
- A gamma camera picks up the tracer and these areas are highlighted in the scans which are known as "hot spots" that suggest increased mineral turnover.
- Bone scans usually detect fractures, infections (osteomyelitis), lytic diseases, and tumors (skeletal metastasis).
- They are highly sensitive to bone abnormalities; however, do not tell what the abnormality is (low sensitivity).

Clinical Pointer

- The kidneys and bladder are often visible in bone scans because the isotope is excreted by the kidneys.
- A whole body scan takes about an hour to finish.

Computed Arthrography

- This procedure combines two techniques, computed tomography (CT) and arthrography.
- It provides a three-dimensional definition of the joint, and the dye helps to outline the articular surfaces.
- It detects the abnormalities which a conventional CT scan does not provide.

Computed Tomography Scan

- It is a diagnostic technique that is used to create detailed images of internal organs, bones, soft tissues, and blood vessels; the cross-sectional images generated during a computed tomography (CT) scan can be restructured in multiple planes, and can even generate three-dimensional images which can be viewed on a computer monitor, printed on film or transferred to electronic media.
- In contrast to a traditional X-ray that utilizes a fixed X-ray tube, a CT scanner utilizes a mechanized X-ray beam source that pivots around the round opening of a doughnut molded design called a "gantry" (**Fig. 4.1**).

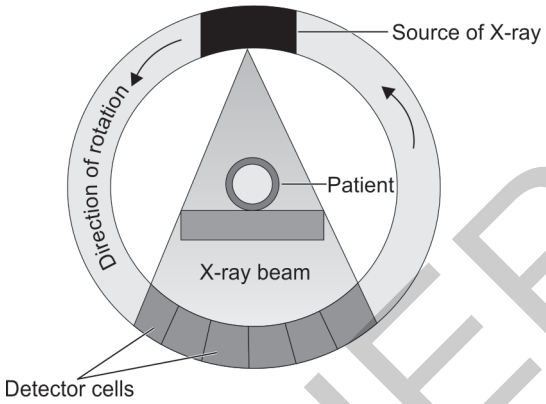

Fig. 4.1: CT scan schematic diagram.
(*For color version, see Plate 1*)



Fig. 4.2: CT scan machine.

- During a CT scan procedure, the patient lies on a bed that gradually travels through the gantry while the X-ray tube turns around the patient, shooting tight light emission beams through the body **(Fig. 4.2).**
- CT scanners utilize special digital X-ray detectors, which are found directly opposite the X-ray beam source.
- As the X-rays leave the patient, they are picked up by the detectors and transmitted to a computer.
- CT scan provides greater details than the conventional X-rays.
- It provides excellent bony architectural details along with good soft tissue resolution.
- CT scan is very useful in detecting intracranial hemorrhage and usually the first imaging study when intracranial hemorrhage is suspected (e.g., subdural or intraparenchymal hemorrhage).
- Most current CT machines take consistent pictures in a helical style instead of taking a progression of pictures of individual slices of the body.
- Helical CT has more advantages over old CT procedures—it is quicker, creates better 3-D pictures of internal regions of the body, and may recognize minor abnormalities better.
- The most current CT scanners, called *multislice CT* or *multidetector CT (MDCT)* scanners, permit more slices to be imaged in a short time period.

JAYPEE BROTHERS

- The *computed axial tomography (CAT)* scan is a radiological technique in which disk lesions, facet diseases, and spinal canal stenosis can be ruled out.
- *Single photon emission computed tomography (SPECT)* scanning is a special type of CT scan technique which is used in orthopedics primarily to detect spondylolysis.

Clinical Pointer

- CT scan is less expensive, quicker and readily available than the magnetic resonance imaging (MRI).
- Useful for detecting bone tumors, nonunion of fractures, intra-articular fractures, and complex fractures.

dIAgno St Ic ul tr ASound

- This technique uses a "transducer," which is a handheld plastic case containing piezoelectric elements/crystals, and produces ultrasound waves when they are exposed to electric current.
- These waves are then directed by the transducer into the body tissues.
- The tissues then reflect back the waves toward the transducer (**Fig. 4.3**).
- The transducer converts the returning waves to electrical impulses and directs them to the imaging unit which then converts the impulses into an image representing the physical structures **(Fig. 4.4).**
- Diagnostic ultrasound provides real-time images **(Fig. 4.5)**, which means tissues can be observed as they move.
- Addition of Color-power-Doppler imaging to ultrasound gives a noninvasive technique for the study of blood flow and vascularity within anatomical structures and lesions.
- Small viewing field, limited depth of penetration within the tissues, and limited contrast resolution are some disadvantages of ultrasound.
- Ultrasound can be used in the diagnosis of tendonitis. Normally, a tendon appears to be homogenous and highly echogenic but during inflammation, there is a diffuse or focal reduction in the echogenicity and the tendon looks rounder in the cross-section due to increase in volume.

Clinical Pointer

- Major advantages of ultrasound are ease of examination, easy availability, and no risk of exposure to radiations.
- Tendon pathology, joint effusion, ligament tears, soft tissue tumors, vascular diseases, developmental dysplasia in children, etc., can be ruled out with the help of diagnostic ultrasound.

dISKogr Aphy

- It is also known as "diskogram."
- It is a diagnostic imaging technique which is used to determine whether a particular intervertebral disk is the source of back pain or not.
- Under the radiographic assistance, a small quantity of contrast material is injected into the nucleus pulposus of an intervertebral disk (**Fig. 4.6**).

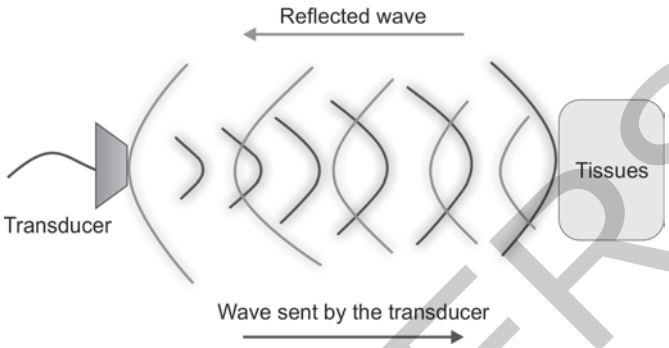

Fig. 4.3: Ultrasound wave—schematic diagram. (*For color version, see Plate 1*)



Fig. 4.4: Ultrasound machine.

- Sometimes this technique is used as a provocative test.
- During the procedure, patients may be asked to describe their pain in terms of location, distribution, and severity. If the injected disk is the source of back pain, patients may feel pain similar to what they experience on a daily basis.
- It is a useful diagnostic imaging technique in determining nucleus pulposus or annular fibrosus lesions.

duAl energy X-r Ay ABSorpt Iome tr y Sc An

- Dual energy X-ray absorptiometry (DEXA) scan is a diagnostic imaging technique which measures the bone mineral density (BMD), to assess a patient's risk of developing osteoporosis or fracture.
- DEXA scan usually focuses on two areas of the body—the hip and the spine (as these are the areas where stress fractures commonly occur due to low bone density).
- In this procedure, the patient is asked to lie down on a padded table, under which an X-ray generator is placed and above the table the imaging device is fitted.
- The patient's legs are placed on a padded box, which causes lumbar spine to be placed flat on the table.
- The machine will send a thin beam of low-dose X-rays with two energy peaks through the bone.

JAYPEE BROTHERS

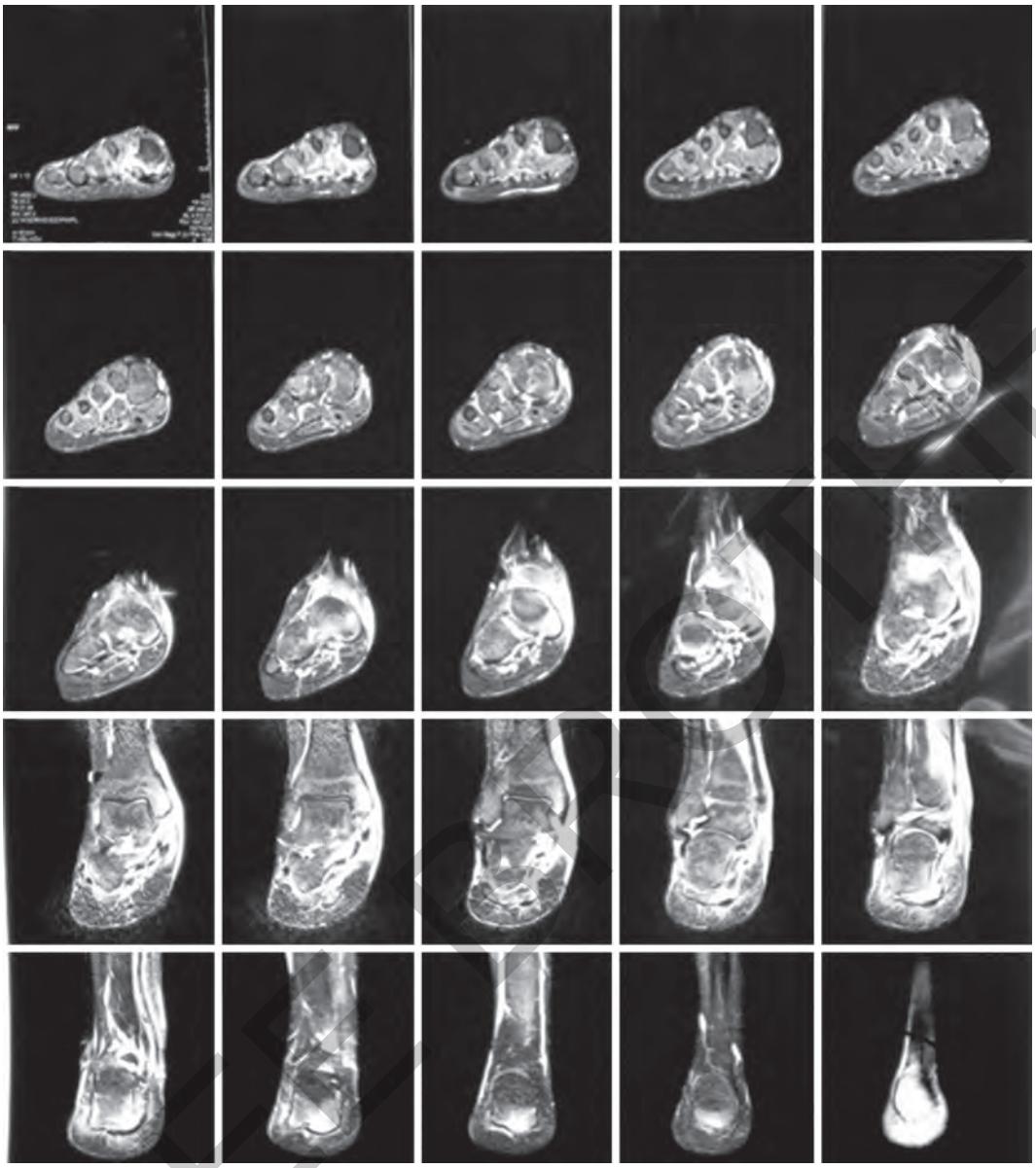

Fig. 4.5: Diagnostic ultrasound used for ankle joint.

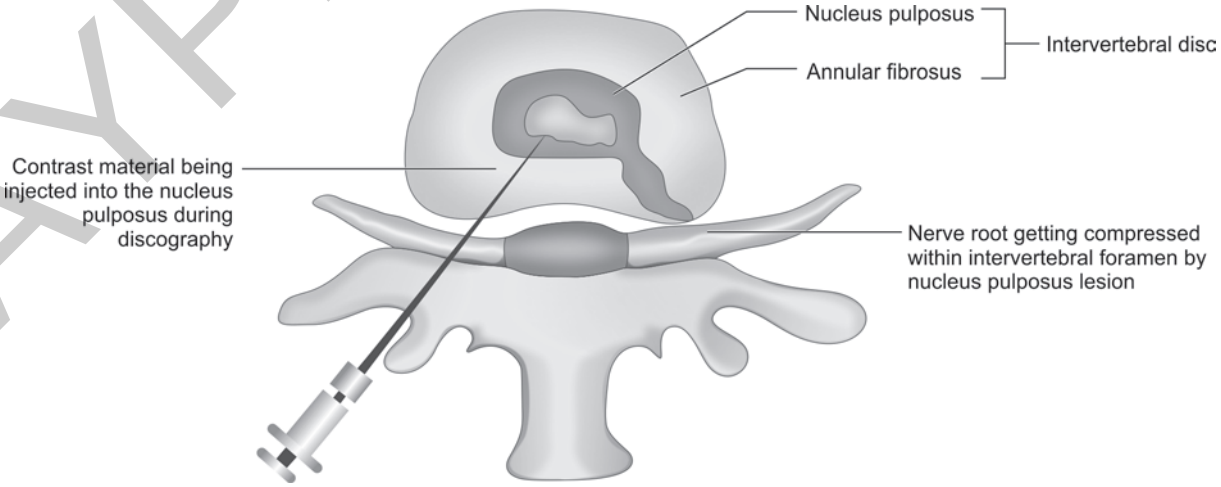

Fig. 4.6: Diskography—schematic diagram.
(*For color version, see Plate 1*)

JAYPEE BROTHERS

Table 4.1: T score interpretation.

Score	*Diagnosis*
T score >−1	Normal bone mineral density
T score of −1 to −2.5	Osteopenia (which indicates a risk of developing osteoporosis)
T score <−2.5	Osteoporosis

- One beam will be absorbed by the soft tissues whereas the other beam will be absorbed by the bone.
- The amount of radiation absorbed by the soft tissues will be deducted from the total radiation to obtain total BMD.
- The results of a DEXA scan are reported in two ways: T score and Z score.
- T score will compare patients' BMD with the optimal peak density of their gender (**Table 4.1**).
- Z score compares patient's results to others of same age, gender, weight, and ethnicity.
- Z score over 2 is considered normal.
- Z score below 2 is considered as below the expected range of person's age.
- Z score <−1.5 suggests factors other than age are responsible for osteoporosis (factors such as tobacco chewing, malnutrition, medication interactions, etc.).

elec tromy ogr Aphy

- Recording of the electrical activity of the muscles is known as "electromyography" (EMG).
- Surface electrodes and needle electrodes are used for this technique (**Fig. 4.7**).
- Needle electrode provides more accurate results for diagnostic purposes.
- Various needle electrodes are used: concentric needle electrode, monopolar electrode, single-fiber electrode, and macroelectrode.
- At first, a muscle is selected as per the suspected clinical diagnosis; then the patient is asked to contract and relax that muscle; after localizing the site for needle insertion (which is slightly away from the motor point), the needle is inserted quickly while the muscle is relaxed.
- Sharp motor unit potentials on minimal muscle contraction suggest the accurate position of the needle.
- Mainly three activities are observed: Insertional activity, spontaneous activity, and voluntary activity.
- EMG helps to determine muscle performance; determine whether the lesion is of neural origin, muscular origin, or neuromuscular junction origin to establish a diagnosis and prognosis and it can be used as a form of biofeedback.
- At the time of needle electrode insertion, certain electrical activity is found which is known as "insertional activity."
- Once the needle is in the selected muscle the patient is asked to completely relax and usually no electrical activity is found on the screen (electrical silence).
- During the period of electrical silence, if any abnormal activity is found on the screen, that is considered to be "spontaneous activity."
- Spontaneous activities originating from muscle fibers such as fibrillation potentials, positive sharp waves, myotonic discharges, complex repetitive discharges and originating from the motor neuron or axon such as fasciculation potentials, myokymic discharges, cramp potentials, etc. can be observed with the help of EMG.
- For instance, fibrillation potentials and positive sharp waves can be found in nerve injuries, radiculopathies, anterior horn disorders, myasthenia gravis, muscular dystrophy, etc.
- *Recruitment pattern* is determined by asking the patient to moderately contract the muscle in which needle electrode is placed (voluntary activity).
- Reduced recruitment pattern is found in neurogenic diseases or end stage of myopathy (**Fig. 4.8**).



Fig. 4.8: Abnormal recruitment pattern being observed in pronator teres muscle with median nerve injury.

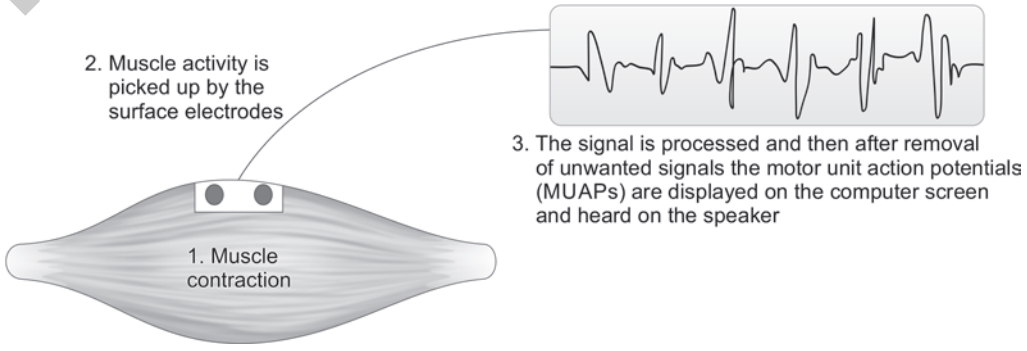

Fig. 4.7: Electromyography procedure.

JAYPEE BROTHERS

Fluoro Scopy

- It is diagnostic imaging technique in which X-ray image is continuously shown on a monitor.
- Fluoroscopy is used during many types of medical procedures, e.g., cardiac catheterization, diskography, arthrography, lumbar puncture, barium X-rays, etc.
- At times it is used for positioning of fracture fragments, guiding joint replacements, and to determine abnormal motion.

lABor At or y Inve St Ig At Ion S

Biopsy

- A biopsy is a procedure in which tissues or cells are removed from the body and observed under a microscope.
- It is an ideal procedure for diagnosis of bone and soft tissue tumors and infections.
- There are four basic types of biopsy—fine needle aspiration, incisional biopsy, excisional biopsy, and core biopsy.
- In incisional biopsy, a small incision is placed to access tumor while taking care of not contaminating the critical structures.
- Fine needle aspiration is a procedure commonly used for carcinoma.

Blood tests

- *Complete blood count (CBC) test:* It is a part of routine checkup. It measures red blood cells count, white blood cells count, platelet count, differential counts, hematocrit and hemoglobin level, etc. Different varieties of anemia and infection (higher WBC is indicative of infection) can be ruled out from CBC test.

Clinical Pointer

Normal values and ranges:
- RBC: 4.5-6.5 × 10^{12}/L (Male); 3.8–5.8 × 10^{12}/L (Female)
- WBC: 4.0-11.0 × 10^9/L
- Platelet counts: 150–400 × 10^9/L
- Eosinophils: 0.04–0.4 × 10^9/L
- Basophils: 0.0–0.1 × 10^9/L
- Neutrophils: 2.0–7.5 × 10^9/L

- *C-reactive protein (CRP):* It is a common laboratory infection marker in blood serum of the patients, which is a basic parameter for inflammation. CRP is considered to reflect the degree of surgical trauma, too. Preoperative CRP-levels are considered to be a risk factor for the postoperative outcome. For example, the preoperative CRP-level based on unanticipated infection or trauma predicts the postoperative course. High levels have a poor outcome. CRP level <10 mg/dL is considered as normal.
- *Erythrocyte sedimentation rate (ESR):* This is an important measure as it indicates inflammation. The test measures the rate at which red blood cells stick together, fall, and settle down at the bottom of the test-tube within an hour. Higher rate suggests greater amount of inflammation. Normal ESR is 2–12 mm/1st hour (Westergren).
- *Hematocrit and hemoglobin count:* Chronic inflammatory conditions lead to decreased red blood cells count. Normal range for hemoglobin is in between 13.0–18.0 g/dL for males and 11.5–16.5 g/dL for females. Normal range for hematocrit is between 0.40–0.52 for males and 0.36–0.47 for females.
- *Rheumatoid arthritis (RA) factor:* Rheumatoid factors are proteins that are produced by immune system of the body that can attack healthy tissues. Higher levels of RA factor may be suggestive of autoimmune disorders such as rheumatoid arthritis or Sjogren's syndrome. RA factor level <14 IU/mL is considered as normal.
- *Serum calcium level:* It is checked to measure the amount of calcium present in the blood. Also, to rule out any bone disorders or calcium regulation disorders such as diseases of parathyroid gland or the kidneys. Normal level: 2.15–2.55 mmol/L.

Clinical Pointer
- Higher serum calcium levels may indicate: Paget's disease, hyperparathyroidism, sarcoidosis, prolonged immobilization, excessive intake, metastatic bone tumor, hyperthyroidism, etc.
- Lower serum calcium levels may indicate: Hypoparathyroidism, malabsorption, renal failure, vitamin D deficiency, osteomalacia, etc.

- *Alkaline phosphatase:* A study done by Dr AK Sipani in 2020 concluded that the serial measurement of serum alkaline phosphatase levels during the fracture healing process in combination with clinicoradiological examination can be an additional, useful and cost-effective tool in predicting whether fractures are at risk of developing complications such as delayed union and nonunion. Normal alkaline phosphatase level ranges between 100 and 300 IU/L.
- *Serum phosphorus level:* Phosphorus helps in bone growth. A serum phosphate test determines the level of phosphorus in the body. Teeth and bones both contain a good amount of phosphorus; however, the blood contains phosphorus too. High phosphate level (hyperphosphatemia) or low phosphate levels (hypophosphatemia), both are detrimental to health. Normal level: 0.7–1.5 mmol/L.

Clinical Pointer
- Higher serum phosphate level may indicate: Diabetic ketoacidosis, reduced kidney function, hypocalcemia, hypoparathyroidism, etc.
- Lower serum phosphate level may indicate: Malnutrition, alcoholism, hypercalcemia, hyperparathyroidism, vitamin D deficiency, etc.

- *Uric acid level:* Serum uric acid level determination helps to find out how well the body is able to produce and remove uric acid. Normal range is between 0.14 and 0.46 mmol/L. Higher levels are associated with a condition known as "Gout." It is a form of arthritis in which pain and swelling of joints occur, especially in the feet and big toes.

JAYPEE BROTHERS

- *Vitamin D level:* It is done to measure the level of 25-hydroxyvitamin D [25(OH)D] in the blood. Abnormal vitamin D levels may indicate bone disorders, nutrition-related problems, organ damage, or other medical conditions. Normal level: 20–40 ng/mL.

Joint Fluid Aspiration and Analysis

- In this a needle is inserted into a joint cavity, and synovial fluid is aspirated which is then examined.
- Any bacterial infection, inflammation, uric acid crystals when gout is in suspicion, etc., can be examined pathologically and accordingly treatment is decided.

urine examination

- A urine analysis consists of checking the appearance, contents, and concentration of urine.
- Diabetes mellitus, urinary tract infection, kidney diseases, etc., can be ruled out from the routine urine analysis. Presence of casts and crystals may suggest kidney disorders. Presence of glucose increases the suspicion of diabetes.

Clinical Pointer

Following parameters are usually considered during urine analysis:

- Acidity/pH of urine
- Protein (proteinuria)
- Sugar (glycosuria)
- Ketones
- Bilirubin
- Albumin (albuminuria)

mAgne t Ic r eSon Ance ImAg Ing

- Magnetic resonance imaging (MRI) scan uses a strong magnetic field and radio waves to generate images of parts of the body that cannot be seen with X-rays, ultrasound, or CT scans.
- It helps to visualize within the joints, cartilage, ligaments, muscles, and tendons, which makes it helpful for detecting various sports injuries.
- Most MRI machines are large, tube-shaped magnets (**Figs. 4.9 and 4.10**).
- When a patient lies inside an MRI machine, the magnetic field momentarily realigns water molecules in their body.

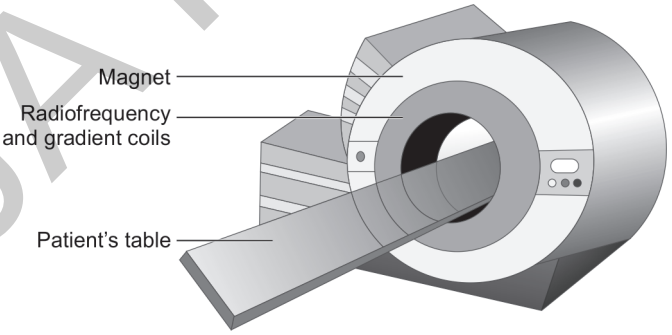

Fig. 4.9: MRI machine—schematic presentation.
(*For color version, see Plate 1*)



Fig. 4.10: MRI machine.

- Radio waves cause these aligned atoms to produce indistinct signals, which are used to create cross-sectional MRI images, like slices of bread.
- In the MRI procedure, the patient is asked to remove the jewelry, hearing aids, removable dental work, eye glasses, hair pins, clothing, and is given ear plugs and a gown to wear.

Clinical Pointer

Any metal implants in the body are a contraindication for MRI.

- After that they are asked to lie down on a scan table, which slides down to a doughnut-shaped opening of the MRI machine.
- The operator sits in another room to operate the controls of the MRI machine.
- Through a window the patient is under continuous supervision of the operator.
- A speaker in the MRI machine helps the patient to hear the commands given by the operator.
- A clicking sound indicates that the magnetic field is created and pulses of radio waves are sent by the scanner.
- The patient is asked to remain still during the procedure, as any movement distorts the signal and may affect the scan quality.
- Once the scan is complete the scan table is taken out and the patient is helped for getting off the scan table.
- The MRI machine can also produce three-dimensional images that can be observed from different angles.
- Although CT assesses only a single tissue parameter - X-ray attenuation, MRI analyzes multiple tissue characteristics comprising hydrogen (proton) density, T1 and T2 relaxation times of tissue, and blood flow within tissue.
- The soft tissue contrast provided by MRI is markedly better than for any other imaging modality.
- Differences in the density of protons available to contribute to the MRI signal distinguish one tissue from another.
- Most tissues can be distinguished by significant differences in their characteristic T1 and T2 relaxation times.

JAYPEE BROTHERS

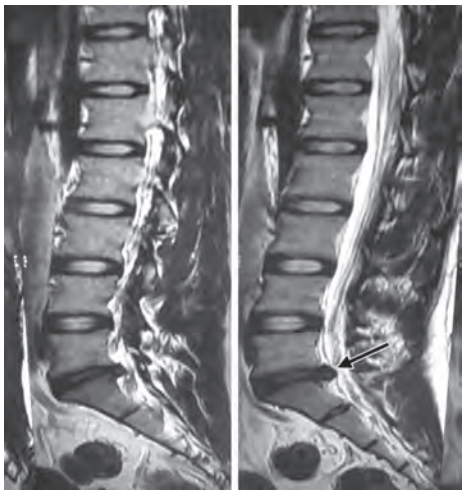

Fig. 4.11: T2 weighted image showing L5-S1 postero-central disk herniation (arrow). Note that the cerebrospinal fluid appears white along with reduction of water content in nucleus pulposus of intervertebral disk.

- T1 images show good anatomical detail of soft tissues, whereas T2 images are used to demonstrate soft-tissue pathology that alters tissue water content.
- One of the good ways to distinguish between a T1 weighted image and a T2 weighted image is "Water looks White in T2 weighted image," which suggests hyperintense signal on MRI (**Figs. 4.11 and 4.12; Table 4.2**).

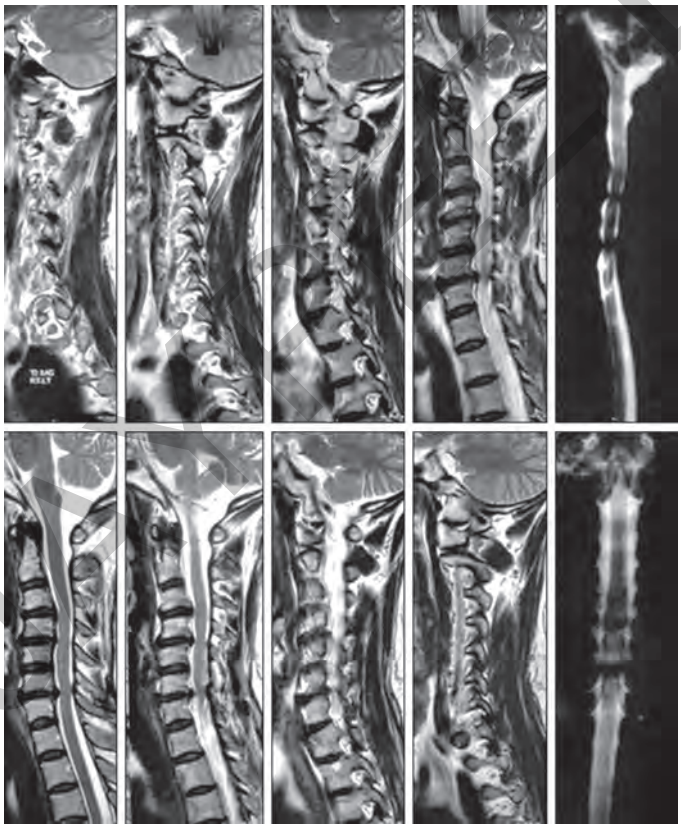

Fig. 4.12: MRI sequence of cervical spine.

- Scanners using a magnetic field of 1.5 T are most commonly used.
- As MRI is water imaging, it detects the water more efficiently hence any pathological condition of the body associated with edema can be easily identified.
- MRI is used to assess spinal cord tumors, intracranial disease, and some types of CNS diseases (e.g., multiple sclerosis); it essentially replaced myelography in the evaluation of disk pathology.
- It also helps in the diagnosis of muscle, ligamentous and meniscal tears, synovial pathology, abnormal patellofemoral tracking, cartilage, joint pathology, bone marrow pathology, stress fractures, and osteochondral lesions.

Clinical Pointer

MRI is useful in detecting following pathologies:
- Recurrent shoulder dislocation
- Rotator cuff tear
- Brachial plexopathy
- Ligamentous tear
- Meniscal tears
- Avascular necrosis
- Any infections

The comparison of MRI and CT scan in the evaluation of different disease conditions is given in **Table 4.3.**

Table 4.2: Difference between T1 weighted and T2 weighted images on MRI.

Characteristics	*T1 weighted image*	*T2 weighted image*
Cortex	Gray	Light gray
Cerebrospinal fluid	Dark	White
Fat (within bone marrow)	Bright	Light
Inflammation/ infection	Dark	Bright

Table 4.3: Comparison of MRI and CT scan.

Sr. No.	*Pathology*	*MRI works better than CT scan*	*CT scan works better than MRI*
1.	Hip avascular necrosis	Yes	—
2.	Osteomyelitis	Yes	—
3.	Ligamentous lesions	Yes	—
4.	Cartilage lesions	Yes	—
5.	Joint pathologies	Yes	—
6.	Joint fracture	—	Yes
7.	Joint loose body	—	Yes
8.	Bone neoplasm	Yes	—
9.	Spondylosis	—	Yes
10.	Soft tissue neoplasm	Yes	—
11.	Radiculopathy	Yes	—
12.	Spinal trauma	—	Yes
13.	Infection	Yes	—

JAYPEE BROTHERS

myelography

- It is an invasive imaging technique used to visualize the soft tissues of the spine.
- In this technique under real time X-ray known as "Fluoroscopy," a radiopaque dye is injected into the epidural space and allowed to flow through different levels of spinal cord, which in turn outlines the thecal sac, spinal cord, and spinal nerve roots.
- At the end a plain X-ray film is taken.
- Some side effects of myelography such as headache, dizziness, nausea, vomiting, and seizures have been noted.
- Nowadays CT scan and MRI have replaced this imaging technique.

Clinical Pointer

Myelography is useful in detecting following pathologies:
- Nerve root entrapment
- Spinal stenosis
- Disk herniation
- Disk diseases
- Spinal cord tumors

nerve conduction velocity Study myelography

Nerve condition velocity (NCV) study determines the speed at which peripheral motor or sensory nerve conducts an impulse.

- It assesses the extent of injury.
- NCV study is done on any peripheral nerve that is superficial enough to be stimulated through the skin at two different points (e.g., median nerve is stimulated at the wrist and cubital fossa to get distal and proximal latency).
- Motor nerve conduction velocity (MNCV) and sensory nerve conduction velocity (SNCV) studies—both should be performed.
- For MNCV study, stimulating electrodes give stimulation to the selected nerve, the muscle supplied by that nerve contracts, and the surface electrodes placed on the muscle which are known as recording electrodes receive the signals which are known as compound muscle action potential (CMAP) and display it on the computer screen (**Fig. 4.13**).
- The CMAP is known as "M wave" (**Fig. 4.14**), which is described on the basis of the following parameters:
  - *Onset latency:* Time taken by the action potential to travel from the point of stimulation to the nerve terminal along with the neuromuscular transmission and the time required to activate the underlying nerve.
  - *Amplitude*: Measured from baseline to negative peak or from negative peak to positive peak.
  - *Duration*: CMAP duration usually is measured from the initial deflection from baseline to the first baseline crossing (i.e., negative peak duration), but it also can be measured from the initial to the terminal deflection back to baseline.
  - *Nerve conduction velocity*: Conduction velocity (CV) is determined by dividing the distance between the two points of cathodal stimulation by the difference between the two latencies. NCV is measured in meter per second. Normal value for MNCV in the upper limb varies from 40 to 55 m/s and for lower limb from 50 to 70 m/s (**Fig. 4.15**).

$$\text{Conduction velocity} = \frac{\text{Conduction distance}}{\text{Proximal latency} - \text{Distal latency}}$$

- *Sensory nerve conduction velocity* is calculated by dividing the distance (mm) between stimulating and recording sites by the latency (ms), but often latencies are sufficient measurements.
- Sensory nerves can be tested by using orthodromic conduction (physiological direction) or antidromic conduction (opposite to normal conduction).

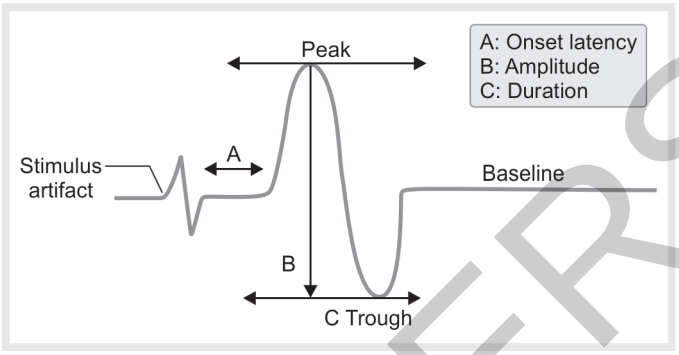

Fig. 4.14: "M wave."

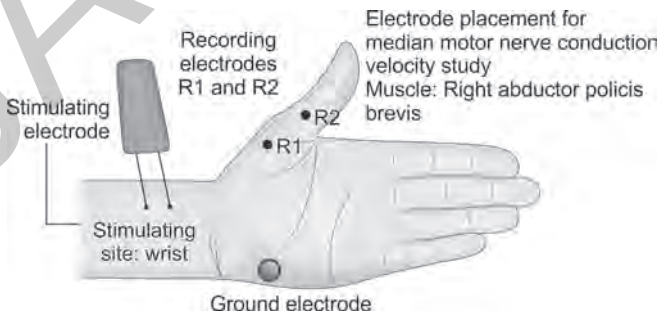

Fig. 4.13: Motor nerve conduction velocity procedure.

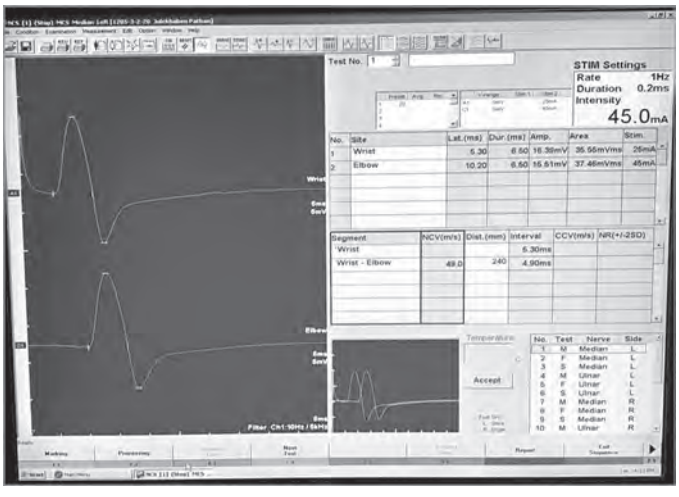

Fig. 4.15: Median motor nerve conduction velocity study showing carpal tunnel syndrome.

JAYPEE BROTHERS

- Ring electrodes can be used for this procedure.
- Normal SNCV varies between 40 and 75 m/s.

Quantitative computed tomography

- Musculoskeletal quantitative computed tomography (QCT) can be used to precisely and reproducibly measure bone mass or muscle mass.
- QCT is used primarily in the diagnosis and management of osteoporosis and other disease states that may be characterized by abnormal BMD, as well as to monitor response to therapy for these conditions.
- Lumbar spine and hip joint are the most common choices for QCT evaluation.
- *Li Na et al. in 2013,* compared QCT with a DEXA scan for the detection rate for osteoporosis to find that DEXA scan determines BMD in two dimensions, including both trabecular and cortical bone, with the results expressed as area density (grams per square centimeter).
- On the other hand, QCT allows measurement of volumetric trabecular bone density without superimposition of cortical bone and other tissues, with the results expressed in milligrams per cubic centimeter of calcium hydroxyapatite.

Radiographs (plain film X-rays)

- Conventional plain film radiography, also known as X-rays, is the primary means of diagnostic imaging for musculoskeletal problems.
- It gives good anatomical resolution along with the advantage of being relatively cheap and readily available diagnostic imaging technique.
- Because X-rays have the potential for causing cell damage, there should be a clear indication of need before a radiograph is taken.
- X-rays are observed as if the patient was standing in front of the observer in the anatomical position.

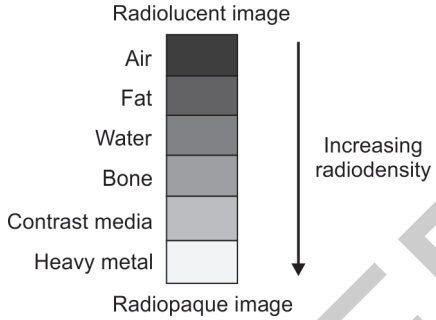

Fig. 4.16: Radiographic density as related to object radiodensity. Note that shade may vary depending upon the thickness of the tissue.

- Commonly two projections are ordered, anteroposterior (AP) projection and lateral projection, as X-rays take planar images and as it is difficult to identify the lesion in only one view.
- Other views may be obtained, depending on clinical conditions and specific needs.
- In the lumbar spine, AP, lateral, and oblique views are generally taken.
- X-rays are part of the electromagnetic spectrum and have the ability to penetrate tissue to varying degrees.
- X-ray imaging is based on the principle that different tissues have different densities and produce images in different shades of gray.
- The greater the density of the tissue, the lesser is the penetration of X-rays and the whiter its image appears on the film (**Figs. 4.16 and 4.17**).
- When observing the X-rays, the examiner must identify the film, noting the name, age, date, and gender of the patient, and the examiner must identify the type of projection taken (e.g., AP, lateral, tunnel, skyline, weight-bearing, stress-type, etc.).
- During this procedure, an X-ray beam is passed through the body.

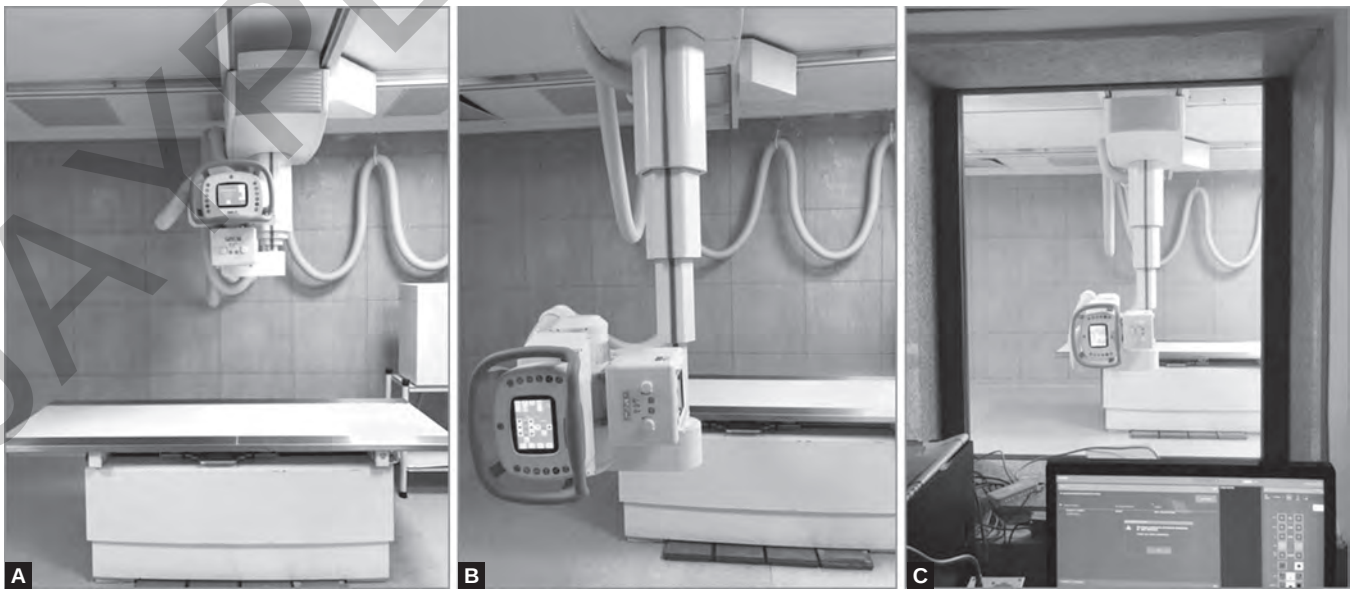

Figs. 4.17A to C: X-ray machine.

JAYPEE BROTHERS

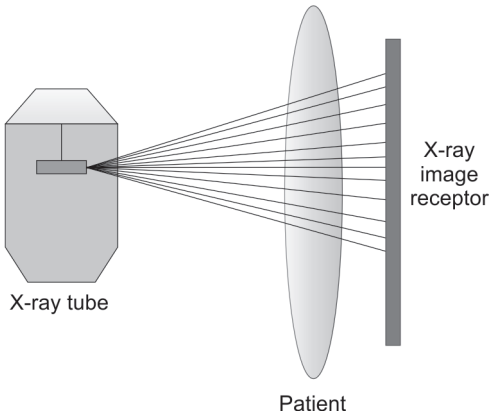

Fig. 4.18: X-ray procedure—schematic diagram.
(*For color version, see Plate 1*)

- A portion of the X-rays is absorbed or scattered by the internal structure and the residual X-ray pattern is conveyed to a detector so that an image may be recorded for future evaluation (**Fig. 4.18**).
- The recording of the pattern may occur on film or through electronic means.
- The X-ray plates that are developed after exposure to the roentgen rays enable the examiner to detect any fractures, dislocations, foreign bodies, or radiopaque materials that may be present.
- The main function of plain X-ray examination is to rule out or exclude fractures or serious disease such as infection (osteomyelitis), ankylosing spondylitis, or tumors and structural body abnormalities such as developmental anomalies, arthritis, and metabolic bone diseases **(Figs. 4.19 to 4.22).**
- Routinely *ABCDs search pattern* is used while referring the radiographic images (**Table 4.4**).
- The observer should keep in mind the maturity of the patient when viewing films.
- For example, skeletal changes occur with age, and the appearance and fusion of the epiphyses, etc.



Fig. 4.20: X-ray of pelvis along with bilateral lower extremities.



Fig. 4.21: X-ray of lumbar spine (lateral view—taken in extension) suggestive of grade 1 spondylolisthesis of L4 over L5 and L5 over S1 (marked by arrows).

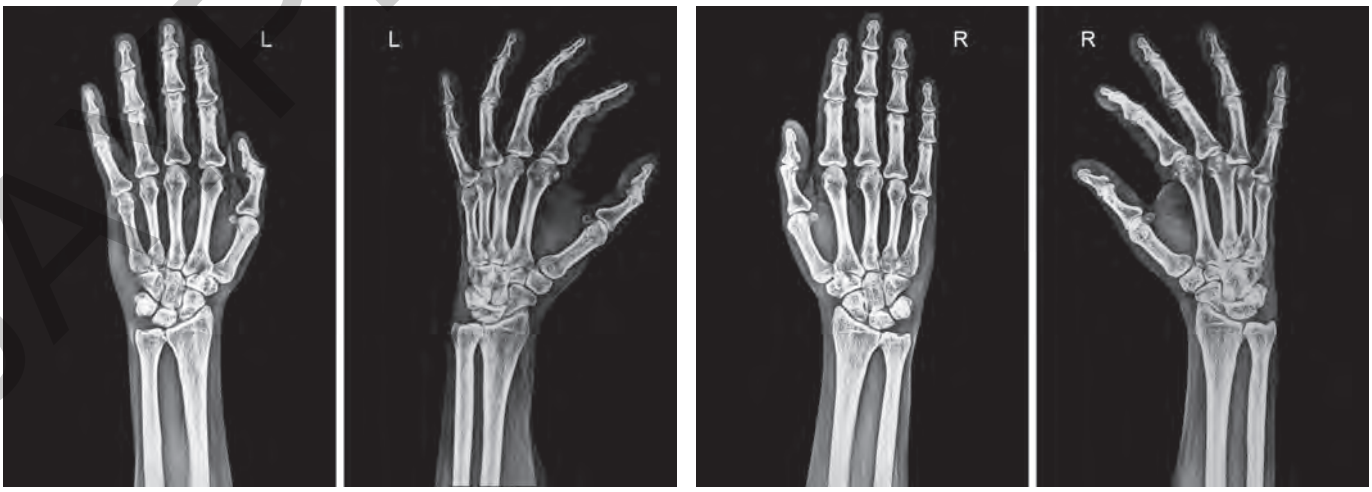

X-ray of left wrist joint and hand X-ray of right wrist joint and hand

Figs. 4.19A and B: Anteroposterior and lateral views of both hands.

JAYPEE BROTHERS

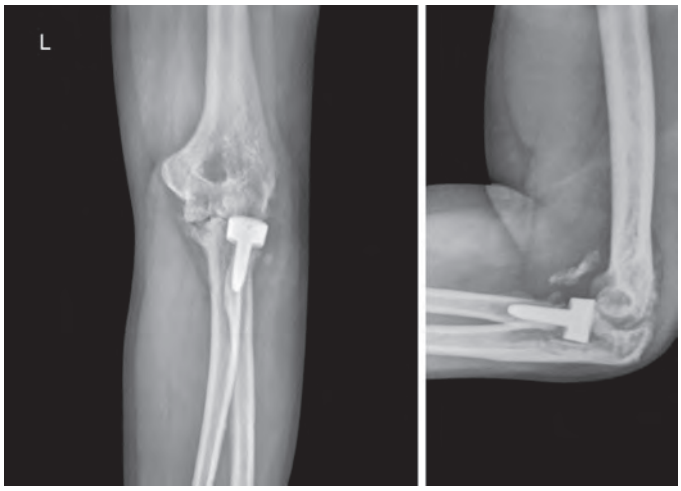

Fig. 4.22: X-ray of left radial head arthroplasty.

venogr AmS And Ar ter logr AmS

- With a venogram or an arteriogram, radiopaque dye/contrast medium is injected into specific vessels to outline abnormal conditions.
- This imaging technique may be used to detect arteriosclerosis, examine tumors, and demonstrate blockage after traumatic injury.

Xeror Adlogr Aphy

- Xeroradiography is a technique in which the normal X-ray film is replaced by xeroradiographic plate.
- On the plate, there is a thin layer of a photoconductor material, which enhances the image.
- The main advantage of it includes enhanced visualization of the borders between images of different densities, low contrast that enables differentiation between fat, bones, and muscles.

Summary

Investigations are an important part of the assessment of a patient. These help in making and confirming a clinical diagnosis. Many investigations exist with varied advantages and disadvantages. As a therapist a basic knowledge about investigations is important. However, these investigations should not replace our clinical expertise. It is important to treat a patient/person and not an X-ray, MRI or similar investigation.

Table 4.4: Interpretation of an X-ray.

Division	*Structures that are being evaluated*	*Normal findings*	*Abnormal findings*
A: Alignment	General skeletal structure	• Gross normal size of the bones • Normal number of bones	• Congenital deformities • Absent bones • Developmental deformities
	General contour of bone	Smooth bony outlines	• Impact fractures • Spurs • Break in cortical continuity
	Alignment of bones with adjacent bones	Normal joint articulation	• Fracture • Subluxation • Dislocation
B: Bone density	General bone density	Enough contrast between soft tissue shade of gray and bone shade of gray	General loss of bone density resulting in reduced contrast between soft tissues and bone
	Abnormalities of texture	Normal trabecular architecture	Trabeculae may look thin, delicate, smudged, and fluffy
	Local bone density	Sclerosis at areas of increased stress such as weight-bearing surfaces or sites of ligamentous, tendinous or muscular attachments	• Excessive sclerosis (increased bone density) • Reactive sclerosis that surrounds a lesion
C: Cartilage spaces	Joint space width	Well-preserved joint spaces with normal thickness of cartilages	Decreased joint space may be suggestive of degeneration or trauma
	Subchondral bone	Smooth surface	Excessive sclerosis may be suggestive of degeneration or trauma
D: Soft tissues	Joint capsules	Indistinct	• Hemorrhage • Effusion
	Muscles	Normal size of soft tissue image	• Wasting
	Fat pads	Radiolucent crescent parallel to bone and length of muscle	• Joint effusion • Swelling
	Miscellaneous soft tissue findings	Soft tissues normally display a water-density shade of gray	• Gas bubbles • Calcification • Foreign bodies

JAYPEE BROTHERS

Review Questions

1. Write an essay on common radiological investigations used in orthopedic conditions.
2. Enlist common laboratory investigations used in orthopedic conditions.
3. Describe the use and interpretation of X-rays in diagnosis.

Bibliography

1. Klein JS, Brant WE, Helms CA, Vinson EN. Brant and Helm's Fundamentals of Diagnostic Radiology, 5th edition. Philadelphia: Lippincott Williams & Wilkins; 2018.
2. Li Na, Li XM, Xu L, Sun WJ, Cheng XG, Tian W. Comparison of QCT and DXA: Osteoporosis detection rates in postmenopausal women. Int J Endocrinol. 2013;2013:895474.
3. Magee DJ. Orthopedic Physical Assessment, 6th edition. Philadelphia: Saunders; 2013. pp. 1-1184.
4. Misra UK. Clinical Neurophysiology: Nerve Conduction, Electromyography, Evoked Potentials, 3rd edition. New Delhi: Elsevier; 2013. pp. 1-438.
5. Myelography. (2019). [online] Available from https://www.radiologyinfo.org/en/info/myelography. [Last Accessed November, 2021].
6. Nanda BK. Electrotherapy Simplified, 1st edition. New Delhi: Jaypee Brothers Medical Publishers Pvt Ltd; 2008. pp. 1-548.
7. Neumaier M, Braun KF, Sandmann G, Siebenlist S. C-reactive protein in orthopedic surgery. Acta Chir Orthop Traumatol Cech. 2015;82(5):327-31.
8. O'Sullivan SB, Schmitz TJ. Physical Rehabilitation, 5th edition. Philadelphia: FA Davis Company; 2006.
9. Preston DC, Shapiro BE. Electromyography and Neuromuscular Disorders: Clinical-Electrophysiologic Correlations, 3rd edition. Philadelphia: Saunders; 2012. pp. 1-664.
10. Provan D. Oxford Handbook of Clinical and Laboratory Investigation, 2nd edition. New York: Oxford University Press; 2005.
11. Ramos RML, Armán JA, Galeano NA, Hernández AM, Gómez JMG, Molinero JG. Absorciometría con rayos X de doble energía. Fundamentos, metodología y aplicaciones clínicas. Radiología. 2012;54:410-23.
12. Sipani AK, Dhar A, Sungte N. Serum alkaline phosphatase: A prospective biomarker for assessment of progress of fracture healing in diaphyseal fractures of long bones in adult patients. J Orthop Sci. 2020;6(2):248-51.
13. Stoller D, Tirman P, Bredella M. Diagnostic Imaging: Orthopedics. Salt Lake City: Amirsys; 2004.
14. Varnau D, Vinnecour KE, Luth M, Cooney DF. The enhancement of prosthetics through xeroradiography. Ortho Prosthet. 1985;39(1):14-28.
15. Vyas NJ. Principles and Practice of Physical Rehabilitation, 1st edition. New Delhi: Jaypee Brothers Medical Publishers Pvt Ltd; 2020. pp. 1-956.

JAYPEE BROTHERS

for detailed information on physiotherapy books, visit our website www.jaypeebrothers.com, for detailed information on physiotherapy books, visit our website www.jaypeebroth

Physiotherapy in Orthopaedic and Rheumatologic Conditions

The goal of the authors when writing this book was to provide a textbook and a reference book for students, clinicians and academicians. It contains important and common orthopaedic conditions encountered amongst patients. The book is divided into four sections depending on the content of the chapters comprising details of basics and foundational concepts of the musculoskeletal system, clinical evaluation and investigations from a physiotherapist's perspective, management strategies used in orthopaedic physiotherapy practice and physiotherapy approaches in traumatic and non-traumatic conditions. Clinical examples provide a clear understanding of the assessment and management processes. It is a unique depiction of all topics related to orthopaedic conditions.

Salient Features

- The information is presented in a well-defined manner and easily comprehensible language
- Detailed description of the physiotherapy management and techniques used in common orthopaedic conditions
- Provides variety of photographs depicting important clinical features and management strategies
- Clinical pointers have been provided for important points and clinical guidance
- Integrated evidence with clinical practice
- Clinical examples for ease of understanding
- Review questions for exam going students.

Megha Sandeep Sheth MPT (Rehabilitation) DNHE is a Lecturer at SBB College of Physiotherapy, Ahmedabad, Gujarat, India for 20 years with clinical experience of over 30 years. She has over 100 publications. Her areas of interest are research in physiotherapy and community health among others.

Priya Singh Rangey MPT (Rehabilitation) PhD Scholar is an Assistant Professor at LJ Institute of Physiotherapy, LJ University, Ahmedabad, Gujarat, India with an academic and clinical experience of 7 years. She has several publications in national and international journals.

Neeta Jayprakash Vyas PT PhD is a Professor Emeritus at Ahmedabad Institute of Medical Sciences, Ahmedabad, Gujarat, India. She has been in the field for almost 40 years and has a vast clinical and academic experience.

Srishti Sanat Sharma MPT (Community Health and Rehabilitation) PhD has an academic and clinical experience of almost 8 years. She is currently working as a Resident Physiotherapist at Physiomed Yorkdale Inc, Toronto, Canada. She is an Ex-Lecturer, CM Patel College of Physiotherapy, Gandhinagar, Gujarat, India.

Printed in India

Available at all medical bookstores or buy online at www.jaypeebrothers.com

JAYPEE BROTHERS
Medical Publishers (P) Ltd.
EMCA House, 23/23-B, Ansari Road,
Daryaganj, New Delhi - 110 002, INDIA
www.jaypeebrothers.com

Join us on facebook.com/JaypeeMedicalPublishers

Shelving Recommendation
PHYSIOTHERAPY

ISBN 978-93-5465-412-1