d information on orthopedics books, visit our website www.jaypeebrothers.com, for detailed information on orthopedics books, visit our website www.jaypeebrothers.c

ASSI
ASSOCIATION OF SPINE SURGEONS OF INDIA

Operation Theater Manual for Spine Surgery



Chief Editor
Shankar Acharya

Associate Editors
Nitin Adsul
Sudhir Ganesan

JAYPEE

Contents

SECTION 1: Operation Theater Essentials

1. **Checklist in Spine Surgery** 3
   Arvind Gopalrao Kulkarni, Praveen Goparaju
2. **Operation Theater Design and Blueprint** 6
   Shankar Acharya, Alok Sharma
3. **Sterilization Techniques and Equipment** 15
   Raghava Dutta Mulukutla, Karthik Kailash, Karthik Yelamarthy, Sudhir Ganesan
4. **Anesthesia for Spine Surgeries** 24
   Balavenkatasubramanian Jagannathan, Vivekanandan Natarajan, Sathish Rajaselvam Parameswaran
5. **Operation Theater Table** 34
   Vishal Kundnani, Saijyot Raut, Praveen Goparaju, Amit Chugh
6. **Operation Theater Illumination** 37
   Shankar Acharya, Varun Khanna, Nitin Adsul
7. **Electrocautery, the Art, Science, and its Application in Spine Surgery** 42
   Shreel Koirala, Sameer Ruparel, Ram Chaddha
8. **Drill in Spine Surgery, Its Attachments, Use, and Upkeep** 48
   HS Chhabra, Ankur Nanda, Amogh Zawar
9. **Ultrasonic Bone Dissector in Spine Surgery** 54
   Bharat Dave, Ajay Krishnan, Devanand Degulmadi, Shivanand Mayi, Raviranjan Rai, Saral Patel, Mirant Dave, Vatsal Parmar
10. **C-arm in Spine Surgery** 61
    Shankar Acharya, Sudhir Ganesan, Nitin Adsul
11. **Full Endoscopic Spine Surgery** 68
    Sukumar Sura, Pramod V Lokhande
12. **Robotics in Spine Surgery** 73
    Vigneshwara Badikillaya, Umesh P Kanade, Harith Reddy, Sajan K Hegde
13. **Spinal Navigation and Allied Techniques** 89
    Chandhan Murugan, KS Sri Vijay Anand, S Rajasekaran
14. **Neuromonitoring, Its Equipment, the Art and Science of it** 100
    Ashok Kumar Jaryal, Bhavuk Garg
15. **The Art and Science of Draping Techniques in Spine Surgery** 106
    Nandan Marathe, Sudhir Srivastava, Kshitij Chaudhary
16. **Cleaning and Maintenance of Operation Theater and Equipment** 115
    G Jyotheswara Reddy, Rishi M Kanna, Ajoy P Shetty
17. **Operation Theater Discipline** 123
    Sudhir Ganesan, Karthik Kailash, Saikrishna Gadde
18. **Recording and Data Storage** 129
    Saumyajit Basu, Rohan Gala

19. Instruments in Spine 138
Shankar Acharya, Deepak Kaucha, Nitin Adsul

20. Suture and Needle Characteristics in Spine Surgery 158
Raunak Milton, Rohit Amritanand

SECTION 2: Surgery Essentials

21. Transoral Approaches to C1-C2 163
Sachin Anil Borkar, Ravi Sharma, Shashank S Kale

22. Anterior Approach to Subaxial Cervical Spine 171
Shankar Acharya, Sudhir Ganesan, Nitin Adsul

23. Anterior Approach to Cervicothoracic Junction 177
G Venkatesh Kumar, Vigneshwara Badikillaya, Appaji Krishnan, Sajan K Hegde

24. Posterior Approach to Subaxial Cervical Spine 181
Charanjit Singh Dhillon, Sarvdeep Singh Dhatt, Chetan Pophale

25. Pedicle Screw Fixation in Subaxial Cervical Spine 187
Mahesh Bijjawara, Bidre Upendra, Raghavendra Rao D

26. Minimally Invasive Posterior Cervical Foraminotomy 193
Sumit Sinha, Harsh Deora, Nishant S Yagnick

27. Full Endoscopic Posterior Cervical Foraminotomy and Discectomy 199
Pramod V Lokhande

28. Endoscopic Anterior Cervical Discectomy 205
Gun Choi

29. Thoracotomy 213
Suresh S Pillai

30. Posterior Approach to Thoracic Spine 220
Samir Dalvie, Pratik Patel

31. Costotransversectomy Approach 228
Rushama Tandon, Akash Shakya, Ashutosh Kapoor, Ayush Sharma

32. Full Endoscopic Spine Surgery for Thoracic Spine 232
Hyeun Sung Kim, Pang Hung Wu, Il Tae Jang

33. Surgical Considerations in Calcifying Thoracic Lesions Causing Myelopathy 237
Subir N Jhaveri, Hitesh N Modi

34. Anterior Thoracoabdominal Approach 243
Sandeep Sonone, Aditya Dahapute

35. Anterior Retroperitoneal Approach 250
V Anand Naik, Ashish Dagar, Nishant Soni

36. Lateral Retroperitoneal Approach 258
Abhishek Srivastava, Anuj Gupta

37. Posterior Approach for Lumbar Spine Decompression—Open 263
Nalli R Uvaraj, Aju Bosco

38. Posterior Approach for Lumbar Spine Decompression—Minimally Invasive Surgery 268
Vishal Peshattiwar, Rajendra Sakhrekar, Mohan Gawande

39. Posterior Approach for Lumbar Spine Fusion—Open 273
Chahal RS, Haritwal Mukesh

40. Posterior Approach for Lumbar Spine Fusion—Minimally Invasive Surgery 280
Srinivasa Reddy P, Karuna K, Rajakumar DV

41. Lumbar Spine Endoscopy—Transforaminal Approach 285
Ankush Garg, Yogita Pitale, Arun Bhanot

42. Full Endoscopic Interlaminar Approach for Lumbar Disk Herniations 291
Pramod V Lokhande

43. Percutaneous Spine Fixation 296
Shankar Acharya, Ratish Kumar Mishra, Nitin Adsul

44. Oblique Lumbar Interbody Fusion 299
Amit Jhala, Sharvin Sheth

45. Thoracic En Bloc Spondylectomy 305
Gautam Zaveri, Mazda Turel

46. Vertebral Column Resection 317
Sajan K Hegde, Appaji Krishnan, Vigneshwara Badikillaya, G Venkatesh Kumar

47. Sacroiliac Fixation: Operation Theater Setup and Techniques 321
HS Chhabra, Gururaj Sangondimath, Kalyan Kumar Varma

48. Spinal Injection Techniques 326
Viksheth Basani, Bibhudendu Mohapatra, Kalidutta Das

49. Iliac Crest Bone Grafting 333
Phani Kiran Surapuraju, Tarun Suri, Akash Yadav

50. Fundamentals of Dural Repair 337
Satish Rudrappa, Letho, Manikandan Thandapani

51. Cement Augmentation Techniques 345
Arvind Bhave

52. Posterior Scoliosis Correction and Fusion 347
Ranjith Unnikrishnan

53. Anterior Scoliosis Correction 352
KV Menon

54. Growth Rod Application 364
Hriday Acharya, Munjal Shah, Akshay Gadia, Arjun Dhawale, Abhay Nene

55. Operation Theater Setup for Surgical Management of Adult Spinal Deformity 367
J Naresh Babu, Aditya Sekhar Nuka, Saikrishna Gadde

56. Vascular Repair Procedures as Required in Spine Surgical Approaches and Procedures 370
Ambarish Satwik, Nikhil Chaudhari

57. Sublaminar Wiring and Stainless Steel Loop Rectangle 379
Raghuprasad Varma, Mandar Borde, Akshay Gadia, Shekhar Bhojraj

Index 387

CHAPTER 22

Anterior Approach to Subaxial Cervical Spine

Shankar Acharya, Sudhir Ganesan, Nitin Adsul

CHECKLIST

Checklist has been extensively explained in Section 1, here we have mentioned the important things needs to be checked before starting the case which are as follows:

- Microscope/loupes
- C-arm
- Burr
- Confirm side of tube fixation
- Endotracheal cuff pressure manometer
- Prepare iliac crest
- Implant as per plan of surgery
- Prophylactic antibiotics
- Catheter
- Drain
- Steroids

OPERATION THEATER LAYOUT

Ideal operation theater layout has been shown in **Figure 1**.

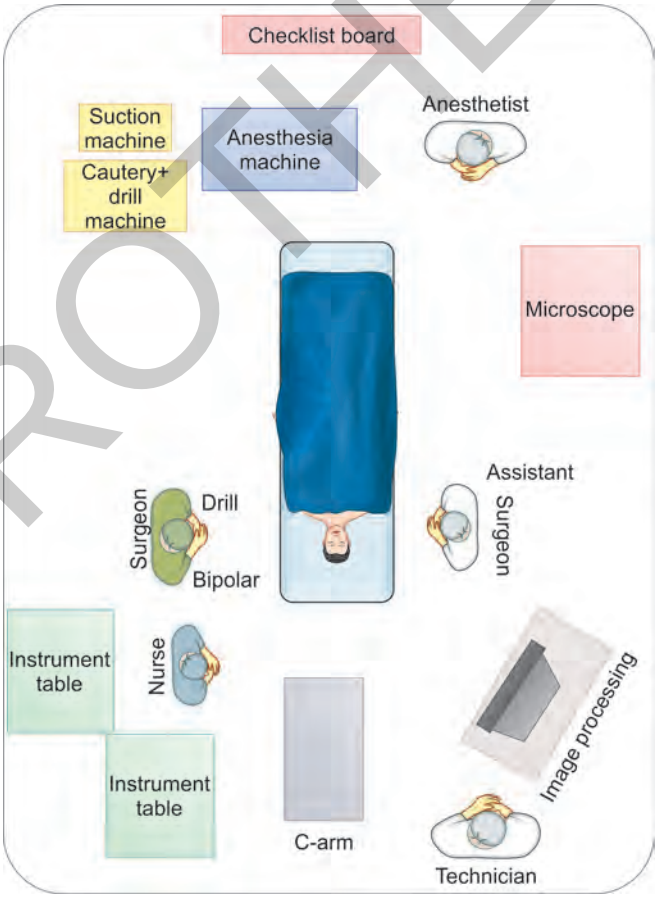

Fig. 1: Operation theater layout for anterior approach to subaxial cervical spine.

PATIENT POSITION AND IMPORTANT KEY POINTS

- Radiolucent table with no metal bar or metal attachments at the head end which can obscure the fluoroscopy imaging.
- Supine position with upper limbs by the side, hips and knee in extension with adequate padding of bony prominences.
- Intravenous (IV) lines in the upper limbs should be carried down with the IV stand placed at the foot end.
- Rolled sheets should be placed under the scapulae to produce extension of the neck.
- Care should be taken not to place the sheets under the neck or too far low down.
- Head is then placed over a ring pillow with adequate but not excessive extension.
- Eyes should be closed and a graze piece can be placed over the eyes with micropore. (Placing adhesive plaster or micropore directly over the eyelids or eyelashes should be avoided as it can cause abrasions and it can peel of the eyelashes while removing the plaster).
- Head can be either turned to the opposite side of the approach (i.e., head turned toward left side in case of a right-sided approach and vice versa) or it can be in neutral position (i.e., head facing the ceiling).
- Anesthetist has to be informed about the positioning of the endotracheal tube. It can be either taken out from the center of the mouth or it can be taken out from the side opposite to that of the approach side (i.e., tube can be placed on the left side in case of a right-sided approach and vice versa).
- Temperature probe and Ryles tube should be placed over the center of the nose and forehead and can be stuck to the forehead with a micropore.

JAYPEE BROTHERS



Fig. 2: Patient position for anterior cervical spine surgery with skin traction.

- Hands to be tucked in by the side of the patient with sheets.
- There are two ways by which traction can be given to the upper limbs. One is by tying a gauze roll over adhesive plaster tied in-between the fingers. The glaze roll is then used to give traction and is tied to the table side rail. Other method is by sticking an adhesive plaster over the top end of the shoulder. Adequate traction is given and the plaster is then stuck either to the bottom of the table or to the sides **(Fig. 2)**.
- Care should be taken not to give excessive traction to avoid any injury to the brachial plexus. Traction should be given only by the doctor and under the supervision of the operating surgeon.
- Hair removal should be done from the operative site preferably from the chin up to the sternal notch.
- C-arm should be positioned in a Top C manner for lateral view to avoid the endotracheal tube and other anesthetic lines.
- Level marking with marker along the Langer lines should be done with the help of fluoroscopy.
- In case of bone grafting, the bone grafting site has to be prepared and a sand bag has to be placed under the ipsilateral iliac blade.
- Forced air warmer should be placed from the middle of the chest downward.
- Monopolar, bipolar cautery and suction should be placed at the foot end.

ANESTHESIA PEARLS

- Surgeries on the cervical spine can be divided into minor and major depending on the extent of blood loss and the number of levels fixed.
- Airway needs to be secured without manipulation of the cervical spine to prevent exacerbation of injury.
- Manual in-line stabilization during laryngoscopy may reduce cervical spine movement.
- Use of a video laryngoscope with an angulated blade may provide good glottis visualization with decreased movement at the cervical spine compared to conventional laryngoscopy.
- Patients with unstable cervical spine on pin traction may need an awake fiberoptic intubation aided by topical airway anesthesia.
- Flexometallic endotracheal tube may prevent tube kinking intraoperatively.
- Cuff pressure monitor can be used to ensure the tracheal tube intracuff pressure is <25 cm of H_2O, to prevent ischemia of the tracheal mucosa.
- The endotracheal tube must be secured firmly using adhesive tapes.
- A backup plan for accidental extubation during surgery must be in place, including availability of laryngeal mask airway, which can be used as a rescue device till a definitive airway is established.
- Throat pack, if necessary to prevent tracheal aspiration of blood, must be noted and a part of the pack left outside the mouth as a reminder to remove it prior to extubation.
- A large bore intravenous cannula is preferable, especially when significant blood loss is anticipated.
- Patients with acute injury to the cervical cord may have features of spinal shock, requiring sympathomimetic support.
- Invasive arterial blood pressure monitoring may be done depending on the presence of comorbidities, cardiac status, and need for frequent blood sampling.
- Central venous line, if deemed necessary, can be inserted peripherally (peripherally inserted central venous catheter) which may enable administration of vasopressors.
- Eyes must be taped and shut to avoid injury to the cornea.
- The neck may be extended and fixed, aided by a tape under the chin.
- The hands are tucked by the side of the patient, ensuring the forearm is not overpronated.
- Padding is kept beneath the medial epicondyle of the humerus to avoid compression injury to the ulnar nerve.
- The position of pulse oximeter is secured and a satisfactory waveform noted prior to commencement of surgery.
- Similarly, the IV cannula is secured firmly to prevent accidental disconnections and free flow of IV fluids ensured.
- A fluid warmer may be used if surgery is expected to last for a longer duration or the need for blood transfusion is imminent.
- A forced air warmer placed from below the level of mid-chest may prevent hypothermia.

JAYPEE BROTHERS

- Anterior approach to the cervical spine may necessitate retraction of the carotid sheath with resultant activation of baroreceptor reflex, causing bradycardia.
- Airway compromise is known to occur in around 2% patients undergoing cervical spine surgery. Patients may have signs of respiratory distress due to airway edema, including noisy breathing, tracheal tug, and use of accessory muscles of respiration.
- If possibility of airway edema is high, patient may be electively ventilated to allow time for resolution.
- Oxygen is to be supplemented and an immediate review by spine surgeon to remove clips/sutures if warranted. Inability to maintain oxygenation may need surgical airway access like cricothyrotomy/tracheostomy.

DRAPING TECHNIQUES

- The procedure of covering a patient and surrounding areas with a sterile barrier to create and maintain a sterile field during a surgical procedure is called draping.
- The purpose of draping is to eliminate the passage of microorganisms between nonsterile and sterile areas. Draping materials may be disposable or nondisposable. Disposable drapes are generally paper or plastic or a combination and may or may not be absorbent. Non-disposable drapes are usually double-thickness muslin. Drapes, of course, must be sterile.
- Double layering is recommended for the cervical spine surgery. Fix the drapes with skin of the neck with suture to avoid the movement of the drapes during the surgery. Ioban is recommended to cover the surgical site. Keep adequate area exposed depending upon the requirement of the surgery. We can use towel clips for securing the iliac crest drapes.
- Handle the drapes as little as possible. Never reach across the operating table to drape the opposite side; go around the table. Hold the drapes high enough to avoid touching nonsterile area but avoid touching the overhead light. Hold the drape high until it is directly over the proper area, then drop (open fingers and release sheet) it down where it is to remain. Never adjust any drape. If the drape is incorrectly placed, leave it in place and place another drape over it. Protect the gloved hands by cuffing the end of the sheet over them. Do not let the gloved hand touch the skin of the patient.
- In unfolding a sheet from the operative site toward the foot or head of the table, protect the gloved hand by enclosing it in the turned back cuff of the sheet. If a drape becomes contaminated, discard it immediately. If the end of a drape falls below waist level, do not handle it further. Drop it and use another drape. If in doubt about sterility, discard the drape. If a hole is found in a drape after it is laid down, cover the hole with another drape or discard the entire drape.

TABLE LAYOUT



(1) Gauze, (2) Micro curettes, (3) Langenbeck retractor, (4) Scissors, (5) Dressing forceps, (6) Tissue forceps, (7) Nerve hook, (8) Dura dissector, (9) Langenbeck periosteal elevator, (10) Surgical blade holder, (11) Kerrison Rongeur-cutting size (2–3 mm), (12) Bone Rongeur (Friedman), (13) Frazier suction tip, (14) Peanut sponge, (15) Curved artery forceps, (16) Caspar cervical distraction system with pins, (17) Phantom TL conical anterior cervical access system with cloward type hand held retractor, (18) Pituitary Rongeur (Love Gruenwald)/Intervertebral Disk Rongeur, and (19) Needle holder)

SPECIAL CONSIDERATIONS

- Dissection should be carried out in the proper plane (by Smith-Robinson approach). Keep palpating the carotid pulse when developing the plane using tissue cutting scissors **(Fig. 3)**.
- Cotton peanuts **(Fig. 4)** is one of the important things required for anterior cervical discectomy and fusion (ACDF). It is used for blunt dissection and to gently sweep away the tissues. It has to be held using a Kocher forceps.
- Once longus colli is reached, use bipolar cautery **(Fig. 5)** or small periosteal elevator to dissect the longus colli from midline toward the lateral side. Do not go too far lateral using cautery for fear of injury to sympathetic chain. Once it is dissected laterally, self-retaining ACDF retractors **(Fig. 6)** have to be placed with blades of appropriate size. The tips of the blades should be under longus colli muscle. If Langenbeck retractors **(Fig. 7)** are used, the retractor ends should be placed under longs colli muscle.
- If two small Langenbeck's retractors are used to retract trachea and esophagus, one has to make sure that the esophagus does not come on the way in between the retractors.
- The level can be confirmed by using an 18-gauge needle or a spinal needle with its tip bent in a "Z" shape to prevent inadvertent entry into the canal.
- As far as possible, make sure that the needle is not inserted into the wrong disk space because it can aggravate disk degeneration at that level.

JAYPEE BROTHERS



Fig. 3: Tissue scissors for dissecting tissue plane.



Fig. 6: Self-retaining retractors.



Fig. 4: Cotton peanuts.

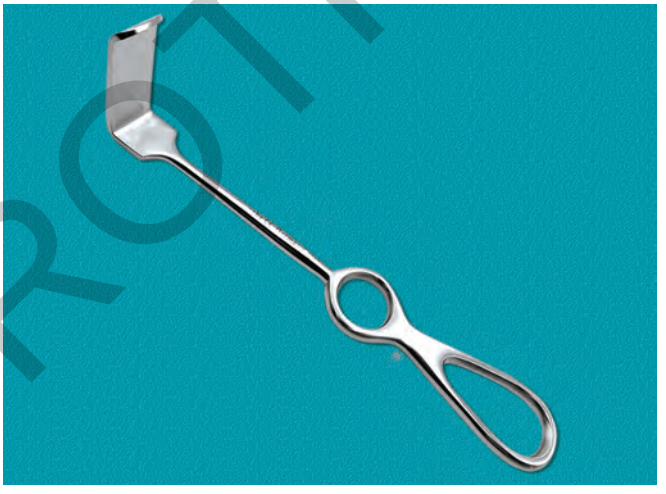

Fig. 7: Langenbeck retractors.



Fig. 5: Bipolar and diathermy cautery.



Fig. 8: Kerrison rongeurs (1 and 2 mm).

- Disk space incision is carried out with size 11 or 15 blade. 2 mm or 3 mm Kerrison rongeur or upcutter **(Fig. 8)** can be used to take of the anterior lip of the superior vertebra. The limit of the disk space laterally is the uncinate processes.
- Caspar pins should be used to distract the disk space **(Fig. 9)**. Caspar pins should be placed in the center of the vertebra and parallel to the end plates. They can be placed in a divergent or convergent way depending on whether we want flexion or extension of the cervical spine. Once the space is opened up, posterior lip should be removed using burr or currette **(Figs. 10 and 11)** and 1 mm upcutter to visualize the posterior longitudinal ligament (PLL).
- Appropriate size cage or bone graft should be inserted after confirming with sizer **(Figs. 12 and 13)**. The sizer should not overdistract the disk space which can be confirmed by distraction of the facet joint in the C-arm lateral view.
- Once the cage or bone graft is being inserted after preparation of the disk space with curette, burr and disk

JAYPEE BROTHERS



Fig. 9: Caspar pin retractor.

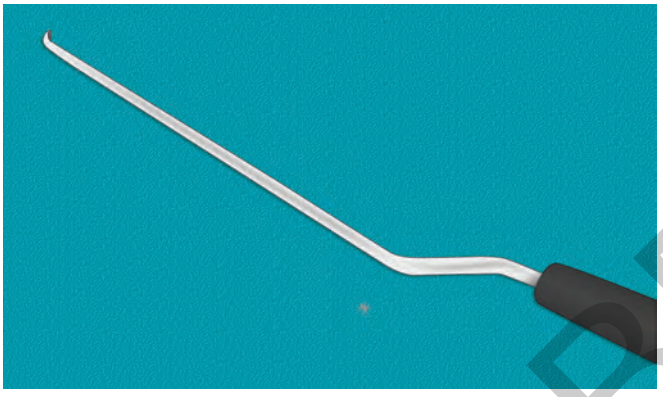

Fig. 10: Curette to remove osteophytes.



Fig. 11: High-speed burr to prepare the end plates and to remove osteophytes.



Fig. 12: Cage size trial.

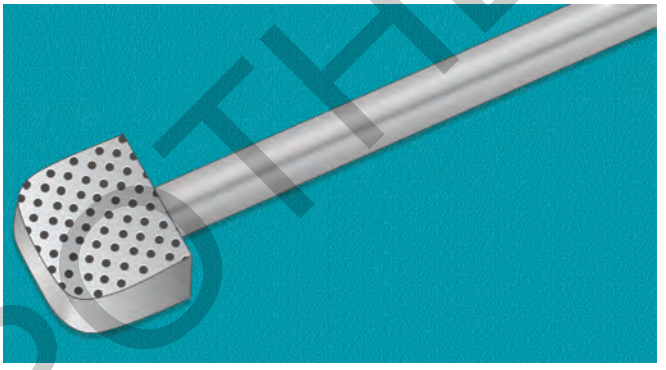

Fig. 13: End plate rasper.

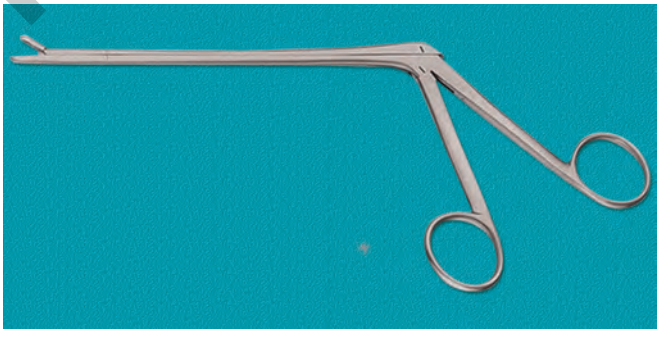

Fig. 14: Disk forceps to remove disk.

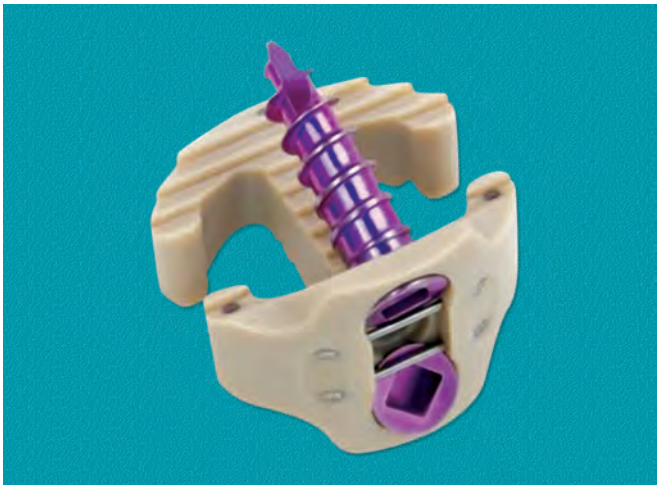

Fig. 15: Anchored spacer.

forceps **(Fig. 14)**, the Caspar pins should be released and gentle tapping can be done till the anterior edge of the cage flushes with the anterior vertebral border.

- In case of anchored spacer **(Fig. 15)**, the screw should be directed in an appropriate way that it is directed toward the posterosuperior corner of cephalic vertebra and

JAYPEE BROTHERS



Fig. 16: Anterior cervical plate.



Fig. 19: Minivac drain.



Fig. 17: Self-drilling screw.



Fig. 18: Self-tapping screw.

posteroinferior corner of caudal vertebra in the lateral view. It should be in the center in anteroposterior (AP) view.

- In case of a cervical plate **(Fig. 16)**, the plate size is very important. If the plate is too short, the screws may enter the disk space and if it is too long, it may extend to the adjacent disk space which may result in adjacent disk degeneration.
- Plate should be contoured into appropriate lordosis so that it is flushed against the vertebral bodies. Screws should be passed parallel to the end plates in lateral view and should be angled medially in AP view **(Figs. 17 and 18)**.
- Center position can be determined either by using C-arm or by using sternal notch as a landmark. Esophagus and trachea should be checked for any contusions or tears.
- If there is no bleeding, one can close the wound without a drain. If drain is required, a minivac drain **(Fig. 19)** can be used to prevent hematoma formation (which is a potential cause for postoperative dyspnea).
- Subcuticular sutures are preferred using 3-0 monocryl or 2-0 undyed vicryl.

SUMMARY

- Proper positioning with adequate but not excessive extension of neck is vital.
- Upper limb traction should be given in a guarded way.
- Anesthetic considerations with positioning of endotracheal tube and adequate air cuff pressure should be monitored.
- All tubes and wires should be taken to the foot end of the patient.
- Special requirements for ACDF include cotton peanuts, bipolar cautery, bent needle tip, cervical retractors, Caspar pin retractors, and minivac drain.

BIBLIOGRAPHY

1. German JW, Ghanayem AJ, Benzel EC, Alexander JT. The cervical spine and cervicothoracic junction. In: Spine Surgery. London: Churchill Livingstone; 2005. pp. 269-80.
2. Grochulla F. Anterior cervical discectomy and fusion. In: Manual of Spine Surgery. Berlin, Heidelberg: Springer; 2012. pp. 127-33.
3. Marawar S, Girardi FP, Sama AA, Ma Y, Gaber-Baylis LK, Besculides MC, et al. National trends in anterior cervical fusion procedures. Spine. 2010;35(15):1454-9.

JAYPEE BROTHERS

for detailed information on orthopedics books, visit our website www.jaypeebrothers.com, for detailed information on orthopedics books, visit our website www.jaypeeb



Printed in India

Available at all medical bookstores
or buy online at www.jaypeebrothers.com

JAYPEE BROTHERS
Medical Publishers (P) Ltd.
EMCA House, 23/23-B, Ansari Road,
Daryaganj, New Delhi - 110 002, INDIA
www.jaypeebrothers.com

Join us on facebook.com/JaypeeMedicalPublishers

Shelving Recommendation
ORTHOPEDICS

ISBN 978-93-5465-437-4