others.com, for detailed information on ophthalmology books, visit our website www.jaypeebrothers.com, for detailed information on ophthalmology books

Scan to Download the App

diginerve
A Jaypee Initiative
Your Guide at Every Step
Video Lectures | Notes | Self-Assessment

Postgraduate Ophthalmology

An Exam Preparatory Manual



Look Inside the Book

Prafulla Kumar Maharana
Ritu Nagpal
Pranita Sahay
Namrata Sharma

JAYPEE

Contents

CHAPTER 1 OCULOPLASTY AND TUMORS 1

1.1 Eyelid Anatomy 1
1.2 Eyelid Embryology and Congenital Eyelid Anomalies 10
1.3 Blepharitis 14
1.4 Blepharoptosis 19
1.5 Entropion and Ectropion 40
1.6 Eyelid Reconstruction 51
1.7 Botulinum Toxin and Dermal Fillers in Ophthalmology 60
1.8 Eyelid Retraction 65
1.9 Anomalies of Eyelid Position and Function 70
1.10 Anatomy of Lacrimal System 85
1.11 Congenital Disorders of the Lacrimal System 90
1.12 Acquired Lacrimal Disorders 96
1.13 Evaluation of Epiphora 108
1.14 Tumors of the Eyelids 111
1.15 Orbital Anatomy 120
1.16 Orbital Fracture 129
1.17 Proptosis 136
1.18 Thyroid Eye Disease 150
1.19 Orbital Cellulitis 171
1.20 Intraocular Tumor 186
1.21 Conjunctival Pigmented Tumors 195
1.22 Orbital Imaging 202
1.23 Congenital Lesions of Orbit 220
1.24 Orbital Cysts and Tumors 225
1.25 Socket 245
1.26 Conjunctival Epithelial Tumors and OSSN 267

CHAPTER 2 NEURO-OPHTHALMOLOGY 280

2.1 Cranial Nerve Palsy 280
2.2 Ocular Myopathies 289
2.3 Anatomy and Physiology 295
2.4 Optic Nerve 307

JAYPEE BROTHERS

2.5 Pupil 335
2.6 Chiasmal and Retrochiasmal Lesion 342
2.7 Miscellaneous 347

CHAPTER 3 STRABISMUS 352

CHAPTER 4 SCLERA 399

CHAPTER 5 RETINA 405

5.1 Common Retinal Disorders and Surgery 405
5.2 Photoreceptors 448
5.3 Vitreous Hemorrhage 450
5.4 Pars Plana Vitrectomy 453
5.5 Posteriorly Dislocated Nucleus 454
5.6 Photodynamic Therapy 455
5.7 Macular Function Tests in Opaque Media 456

CHAPTER 6 UVEA 459

6.1 Uveitis 459

CHAPTER 7 GLAUCOMA 522

7.1 Developmental Anomalies of the Angle 522
7.2 Anterior Cleavage Syndromes 525
7.3 Epidemiology of Glaucoma 528
7.4 Optic Nerve Head Damage and Visual Field Changes 529
7.4.1 Short-wavelength Automated Perimetry 537
7.5 Optical Coherence Tomography In Glaucoma 539
7.6 Juvenile Open-angle Glaucoma 541
7.7 Medical Management of Glaucoma 544
7.8 Laser Peripheral Iridotomy 549
7.9 Newer Antiglaucoma Medications 553
7.10 Advances in Management of Glaucoma 554
7.11 Nonpenetrating Glaucoma Surgery 557
7.12 Selective Laser Trabeculoplasty 559
7.13 Bleb 560
7.14 Complications of Glaucoma Surgery 565
7.15 Releasable Sutures in Trabeculectomy 572
7.16 Classification of Secondary Glaucoma 576
7.17 Drug-induced Glaucoma 580

JAYPEE BROTHERS

7.18 Lens-induced Glaucoma 582
7.19 Normal-tension Glaucoma 585
7.20 Refractory Glaucoma 586
7.21 Primary Congenital Glaucoma and Its Associated Syndromes 589
7.22 Surgical Management of Congenital Glaucoma 591
7.23 Ocular Blood Flow and Glaucoma 593
7.24 Neuroprotective Agents 594
7.25 Advanced Glaucoma and Painful Blind Eye 596

CHAPTER 8 CORNEA AND CONJUNCTIVA 600

8.1 Anatomy and Physiology of Cornea 600
8.2 Acute Conjunctivitis 613
8.3 Ophthalmia Neonatorum 618
8.4 Corneal Infection and Inflammatory Disorders 622
8.5 Corneal Dystrophy 671
8.6 Fuchs Endothelial Corneal Dystrophy 688
8.7 Keratoconus 693
8.8 Limbal Stem Cell Deficiency 702
8.9 Corneal Transplantation 706
8.10 Keratomalacia 761
8.11 Shield Ulcer 768
8.12 Toxic Anterior Segment Syndrome 772
8.13 Ectatic Disorders of the Cornea 777

CHAPTER 9 CATARACT AND REFRACTIVE SURGERY 801

9.1.1 Preoperative Laboratory Testing for Cataract Surgery 801
9.1.2 Congenital Cataract 806
9.1.3 Traumatic Cataract 810
9.1.4 Nondilating Pupil 813
9.1.5 Uveitis and Cataract Surgery 817
9.1.6 Ectopia Lentis 821
9.2 Refractive Surgery 825

CHAPTER 10 OCULAR TRAUMA 859

10.1 Eyelid Trauma 859
10.2 Penetrating Ocular Trauma 862
10.3 Acute Chemical Injury 868
10.4 Blunt Ocular Trauma 874

CHAPTER 11 SYSTEMIC DISORDERS AND EYE 877

JAYPEE BROTHERS

QUESTION BANK 907

Anatomy and Physiology 907
Optics and Refraction 910
Eyelids 912
Lacrimal Drainage System 913
Orbit 914
Conjunctiva 916
Cornea and External Diseases 916
Refractive Surgery 920
Sclera 921
Glaucoma 921
Lens 924
Uveitis 926
Retina 928
Vitreous 932
Ocular Tumors 932
Strabismus 933
Neuro-ophthalmology 935
Investigations 937
Ocular Trauma 938
Community Ophthalmology and Biostatistics 939
Ophthalmic Microbiology, Pharmacology, and Pathology 941
Recent Advances 942
Systemic Disorders and Eye, Drug Toxicity 942
Miscellaneous 943

Index *945*

JAYPEE BROTHERS

CHAPTER 1

Oculoplasty and Tumors

1.1 Eyelid Anatomy

Q 1. Describe in detail eyelid anatomy and its applied aspects.

The eyelids help to keep the corneas moist and protect against injury and excessive light, regulating the amount of light reaching the retina.

Gross Anatomy

The upper eyelid extends over the orbital margin to the eyebrow above and the lower more smoothly into the cheek, where nasojugal and malar sulci may limit it.

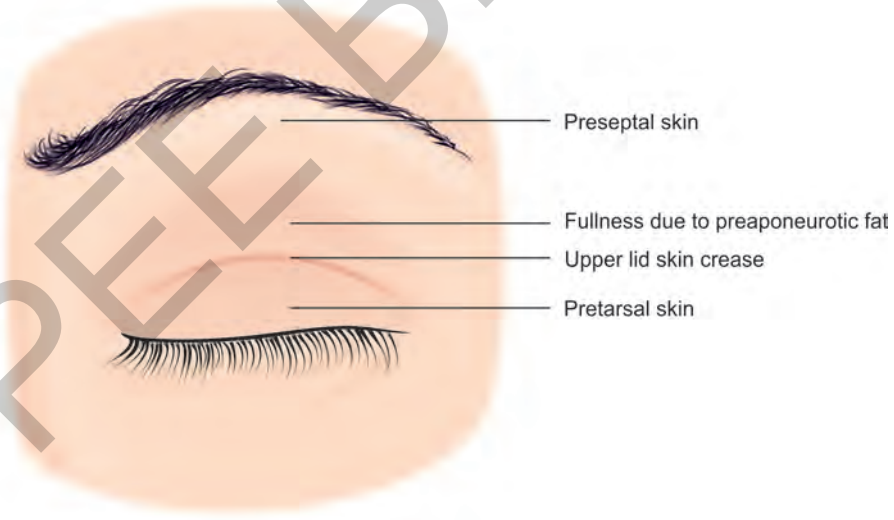

Lid Crease

- Upper/superior lid crease—situated 6–10 mm above the lash line. It is formed by the insertion of levator aponeurosis to orbicularis oculi. It divides the upper lid into:
  - Preseptal part above
  - Pretarsal part below
- Inferior lid crease—4–5 mm from the lash line. It is less evident in adults.
- The nasojugal fold medially and malar fold laterally separate the thin lower eyelid skin from the thicker skin of the cheek. At the nasojugal sulcus, a band of connective tissue passes between orbicularis oculi and levator labii superioris.

The sulci mark the junctions between the loose palpebral and denser tissues in the cheek, hence limiting edema and demarcating adipose herniation.

JAYPEE BROTHERS

Position of Lids

In primary position of gaze, the upper lid covers one sixth of the cornea and the lower lid just touches the cornea.

Canthi

The upper and the lower eyelids meet at medial and lateral canthi.

- Lateral canthus—located 5–7 mm from the lateral orbital margin—lies in contact with the eyeball.
- Medial canthus is separated from the globe by the tear lake (lacus lacrimalis). A yellowish conjunctival fold, the lacrimal caruncle, projects into the lacus, and lateral to it is the pink plica semilunaris.

Palpebral fissure height measured at the level of pupil is as follows:

- 8–10 mm in males
- 10–12 mm in females.

Lid Margins

Lid measures nearly 2 mm in width.

Lacrimal papilla—a small elevation on the medial aspect of lid-harboring lacrimal punctum—divides the lid into two parts:

1. Lacrimal portion medially known as *pars lacrimalis*—rounded and devoid of lashes
2. Ciliary portion laterally known as *pars ciliaris*—has rounded anterior border and sharp posterior border and intermarginal strip in between

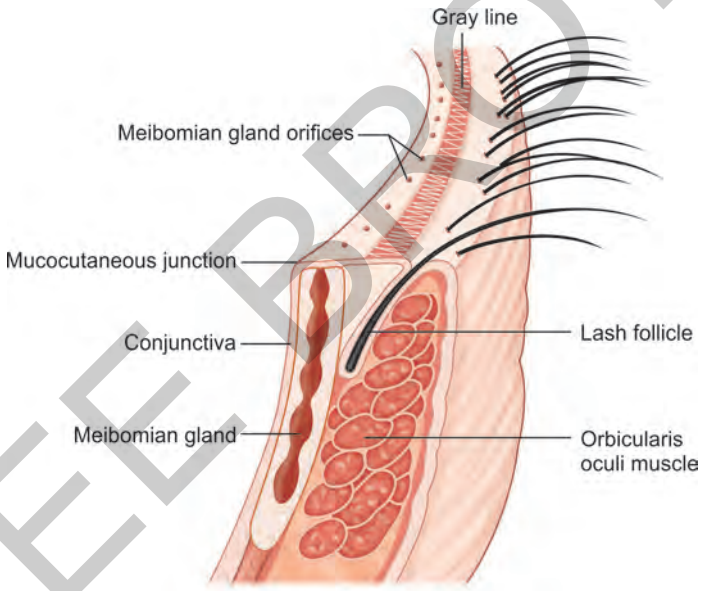

Important landmarks from posterior to anterior are as follows:

- Mucocutaneous junction represents the anterior limit of the marginal strip of tear fluid.
- Meibomian gland orifices
- Gray line—muscle of Riolan (pars ciliaris part of orbicularis oculi) lies deep to it, forms bloodless plane of dissection, and divides the intermarginal strip into anterior and posterior parts.

Structure of Eyelid

From anterior to posterior

1. Skin	Anterior lamella
2. Subcutaneous areolar tissue	
3. Orbicularis oculi muscle	
4. Submuscular areolar tissue	
5. Orbital septa	
6. Eyelid retractors	Posterior lamella
7. Tarsal plate	
8. Conjunctiva	

JAYPEE BROTHERS

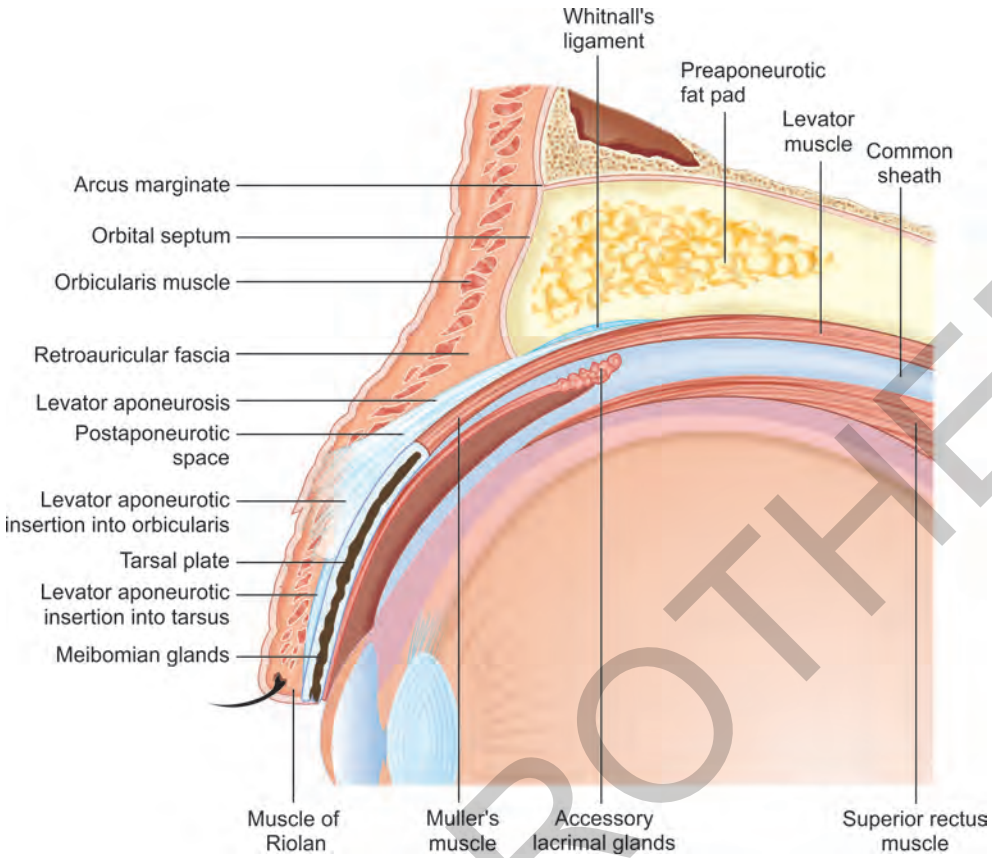

Upper lid

Skin

- Eyelid has the thinnest skin in the body and is loosely attached to orbicularis oculi muscle but more firmly attached to regions of canthal tendons. *These two properties provide more mobility to the lids.*
- Fine hairs are present.

Subcutaneous Areolar Tissue

- Loose areolar tissue with no fat—readily distended by blood or edema
- Absent at lid margins, skin folds, and medial and lateral angles.

Orbicularis Oculi Muscle

Orbicularis oculi muscle is divided into three parts:

1. Orbital—rests on orbital bone
   - *Origin:*
     - Medial canthal ligament
     - Frontal process of maxilla
     - Orbital process of frontal bone
   - Insertion—Its fibers run in an elliptical fashion and insert medially just below the point of origin. Few fibers insert into the dermis at the medial brow.
2. *Preseptal:*
   - Origin—single head in lower lid: medial canthal ligament.
     - *Two heads in upper lid:*
       - *Superficial head:* Common medial canthal ligament
       - *Deep head:* Superior limb of medial canthal tendon (MCT), which is fused to lacrimal sac fundus by layer of fibrovascular fascia
   - Insertion—lateral canthal tendon and lateral horizontal raphe

JAYPEE BROTHERS

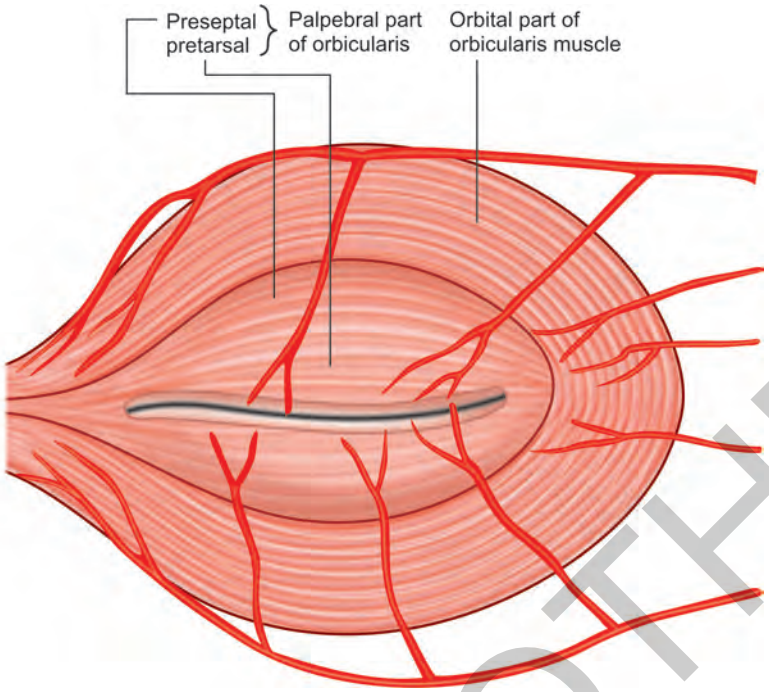

From its orientation, the preseptal orbicularis muscle appears to counteract opposing tone in the retractors of the eyelids, both levator aponeurosis in the upper lid and capsulopalpebral fascia (CPF) in the lower lid. Secondarily, its contraction pulls the lacrimal sac fascia laterally, thereby contributing to the lacrimal pump mechanism.

3. *Pretarsal:*
   - *Origin:*
     - MCT (superficial head)
     - Lacrimal fascia and posterior lacrimal crest (deep head)
   - Insertion—lateral canthal tendon and lateral horizontal raphe

   Horner's muscle/pars lacrimalis is the part of pretarsal fibers, which arise from the lacrimal fascia and helps in the drainage of tears.

   Muscle of Riolan/pars ciliaris—pretarsal orbicularis fibers that lie along the lid margin behind the ciliary follicles.
   Nerve supply—facial nerve.

Applied Anatomy

- Palpebral part causes reflex/involuntary closure of the eyelid and orbital part causes voluntary lid closure.
- Dysfunction of orbicularis can be due to multiple etiologies:
  - Myokymia—benign involuntary spontaneous localized twitching of few superficial muscle bundles of orbicularis oculi
  - Benign essential blepharospasm—focal cranial dystonia of uncertain etiology. It typically affects older individuals and is characterized by involuntary contractions of the orbicularis, procerus, and corrugator muscles.
  - Hemifacial spasms—a unilateral condition seen in older individuals and characterized by tonic and clonic spasms of facial muscles in the distribution of the ipsilateral facial nerve. In most cases, it is caused by a vascular compression of the seventh nerve.
  - Bell's palsy—idiopathic, unilateral, paralysis of the seventh cranial nerve. It is characterized by weakness of the facial muscles on one side including orbicularis oculi resulting in lagophthalmos.

Orbital Septum

- It originates from the orbital rim at thickening called arcus marginale.
- Superior orbital septum fuses with levator aponeurosis 10 mm from the superior edge of the upper tarsal plate.
- Lower orbital septum fuses with the CPF and they together attach to the lower edge of the lower tarsal plate.

Applied Anatomy

- In older patients, and in younger individuals as a familial trait, the septum may be a flimsy, transparent film through which orbital fat pockets easily herniated causing eyelid fat bags.

JAYPEE BROTHERS

- Following trauma to the eyelids, prolapse of orbital fat into the wound occurs with lacerations of the orbital septum. The septum should not be repaired, since this frequently causes shortening of this structure, with resultant lagophthalmos.

Tarsal Plates

- Dense fibrous tissues of 1.0–1.5 mm thickness that provide structural integrity to the eyelids
- Measure—29 mm horizontally
- Upper tarsus—10–11 mm in height
- Lower tarsus—4–5 mm in height
- Meibomian/tarsal glands are embedded in the substance of tarsal plate: approximately 25 in the upper lid and 20 in the lower lid.
- Lateral ends of the tarsal plates are attached to Whitnall's tubercle by lateral canthal tendon. Medial ends are attached by MCT to the anterior lacrimal crest and frontal process of maxilla.

Applied Anatomy

Obstruction of the meibomian gland ductules by lipid and cellular debris, or by abnormalities of keratinization, may result in lipogranulomatous inflammation and frank infection, presenting as hordeolum or chalazion.

Canthal Tendons

1. *Lateral canthal tendon:*
   Formed by:
   - Y-shaped fibrous thickening of orbital septum connecting the tarsal plates and lateral orbital tubercle (tubercle of Whitnall)
   - Common tendon formed by pretarsal orbicularis oculi
   - Lateral raphe formed by preseptal orbicularis oculi
2. *Medial canthal tendon:*
   - Fibrous component—Y-shaped band attaching the medial ends of tarsal plates to the frontal process of maxilla just anterior to the anterior lacrimal crest
   - Muscular component formed by the attachment of preseptal and pretarsal orbicularis oculi

   The MCT has superficial and deep parts.
   - The superficial part is attached to the anterior lacrimal crest—stronger— and gives support.
   - The posterior part is attached to the posterior lacrimal crest and facilitates lacrimal drainage.

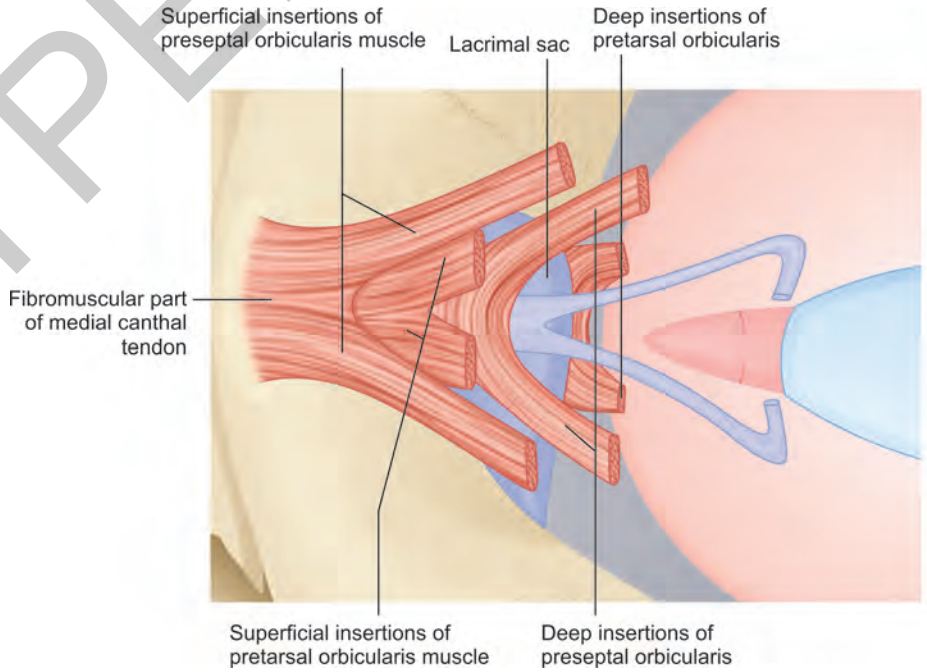

JAYPEE BROTHERS

Levator Palpebrae Superioris

- Origin—from the orbital surface of the lesser wing of sphenoid, above the annulus of Zinn
- Has muscular part—about 40 mm and runs horizontally—above the superior rectus.
- The direction changes at the level of superior transverse ligament of Whitnall, which then continues vertically down as aponeurosis.
- Levator aponeurosis gets inserted to the superior two-thirds of the anterior surface of the upper tarsal plate.
- Medial horn of levator aponeurosis attaches to the posterior limb of MCT and posterior lacrimal crest.
- Lateral horn attaches to the lateral tubercle of Whitnall and fibers of capsulopalpebral fascia (CPF). The lateral horn divides the lacrimal gland into palpebral and orbital parts.
  Nerve supply—superior division of oculomotor nerve

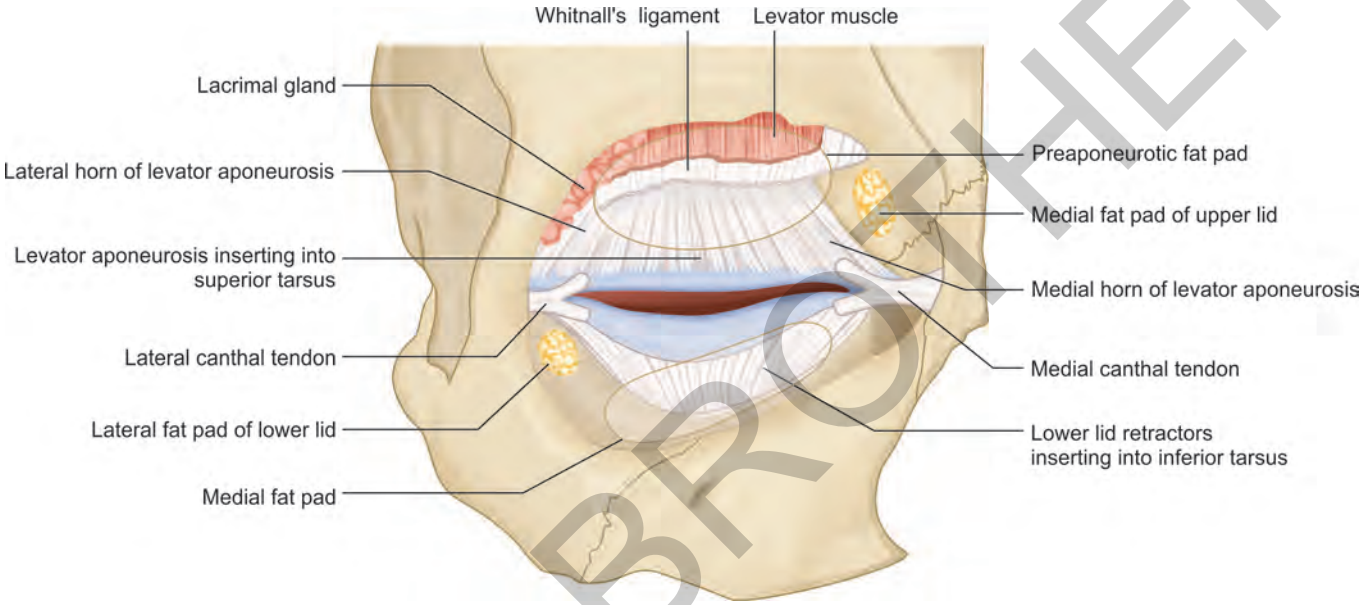

Muller's Muscle

- Origin—from levator palpebrae superioris (LPS) close to muscle–aponeurosis junction.
- Insertion—upper border of tarsal plate of the upper lid.
  Nerve supply—sympathetic nerves

Inferior Lid Retractors

1. *Capsulopalpebral fascia (CPF):*

It originates as capsulopalpebral head
from inferior rectus muscle

↓

Divides into two—encircles inferior oblique

↓

Joins together to form Lockwood ligament

↓

Extends from Lockwood's ligament, sends strands to the inferior fornix, and inserts to the lower border of the inferior tarsal plate

JAYPEE BROTHERS

2. Inferior tarsal muscle—analogous to Muller's muscle—poorly developed

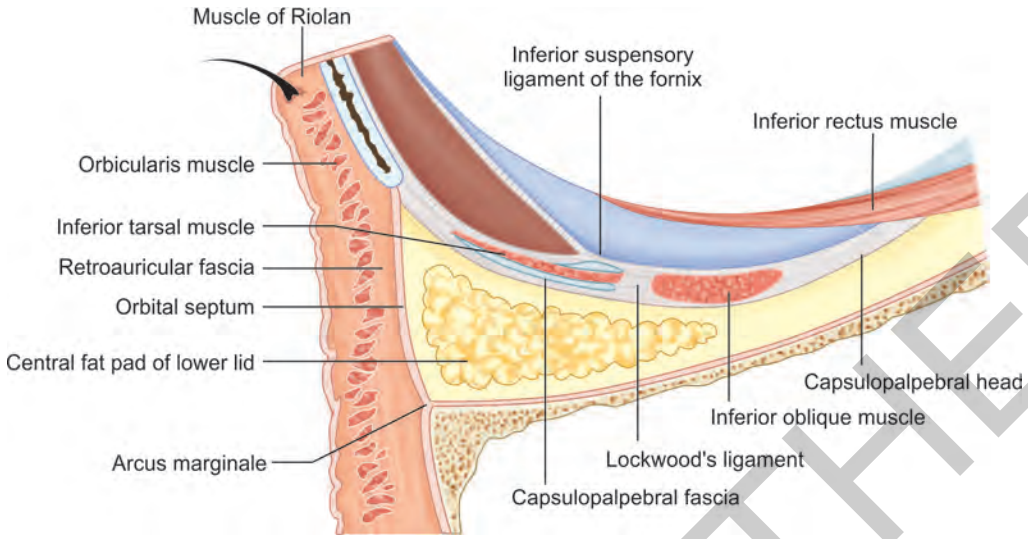

Applied Anatomy

- The most common causes of adult-acquired ptosis are involutional thinning and stretching of the levator aponeurosis.
- With horizontal eyelid lacerations, the presence of orbital fat suggests deep eyelid injury to the level of the orbit and should alert the clinician for the possibility of aponeurotic injury.
- Entropion and ectropion frequently result from involutional stretching of the CPF, horizontal laxity of the tarsus or canthal ligaments, or both.
- Disruption of sympathetic innervation to Muller's muscles, anywhere from its origin in the hypothalamus to its terminal postsynaptic branches in the eyelids, results in Horner's syndrome. This is characterized by the classic triad of ptosis, miosis, and ipsilateral anhidrosis of the face.

Glands of Eyelid

- Lacrimal gland—palpebral part
- Accessory lacrimal gland
  - Krause
  - Wolfring
- Meibomian gland
- Zeis gland
- Moll gland
- Goblet cells—in conjunctiva, plica, caruncle.

Q 2. Describe the lymphatic drainage of eyelids and its applied aspects.

The lymphatic channels form pretarsal and post-tarsal plexuses, connected by cross-channels.

Pretarsal plexus	***Post-tarsal plexus***
Have many valves	No valves
Drains skin and its appendages	Drains the conjunctiva and tarsal glands

JAYPEE BROTHERS

Both groups drain as follows:

1. *Upper lid:*
   - Lateral two-thirds—preauricular and parotid lymph nodes (LNs)
   - Medial one third—submandibular, submental, and anterior cervical LN
2. *Lower lid:*
   - Lateral one third—preauricular and parotid LNs
   - Medial two-thirds—submandibular and submental anterior cervical LN.

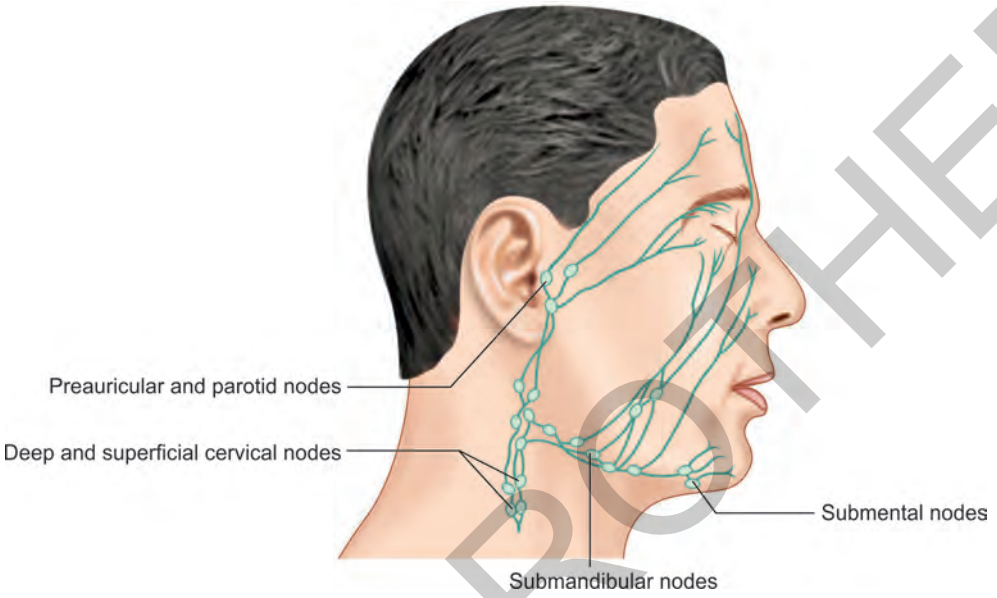

Applied Anatomy

- Extensive excision of subcutaneous eyelid tissues or deep incisions in the inferolateral eyelid area may result in persistent lymphedema due to the disruption of these vessels.
- Regional metastases of eyelid tumors are rare for basal cell and squamous cell carcinoma, but may occur more commonly with sebaceous cell carcinoma.
- The orbitomalar retaining ligament along the inferior orbital rim is the principal suspensory structure for the infraorbital soft tissues, but it also separates the lymphatic drainage fields of the lid from those of the cheek. This explains why significant lower eyelid edema is often seen to stop at the orbital rim.

Q 3. Describe the vascular supply to eyelids. What are the clinical applications of the same?

Eyelid has extensive vascularity, promotes healing, and defends against infection.

Arterial supply is through two main sources:

1. Internal carotid artery (ICA)—ophthalmic artery and its branches
   - Supraorbital—supplies levator, superior rectus, and superior oblique muscles
   - Lacrimal—through lateral palpebral artery
   - Dorsal nasal artery—through medial palpebral artery
2. *External carotid artery (ECA):*
   - Facial artery → angular artery (terminal branch)
   - Internal maxillary artery → gives infraorbital artery in pterygopalatine fossa; supplies the cheek, lower eyelid, and conjunctiva
   - Superficial temporal artery—terminal branch of the ECA
     - *Branches and area supplied:*
       - Frontal artery—frontalis, orbicularis muscles
       - Zygomatic artery—lateral portion of the lids
       - Transverse facial artery—lateral portion of the lower lids and cheek

JAYPEE BROTHERS

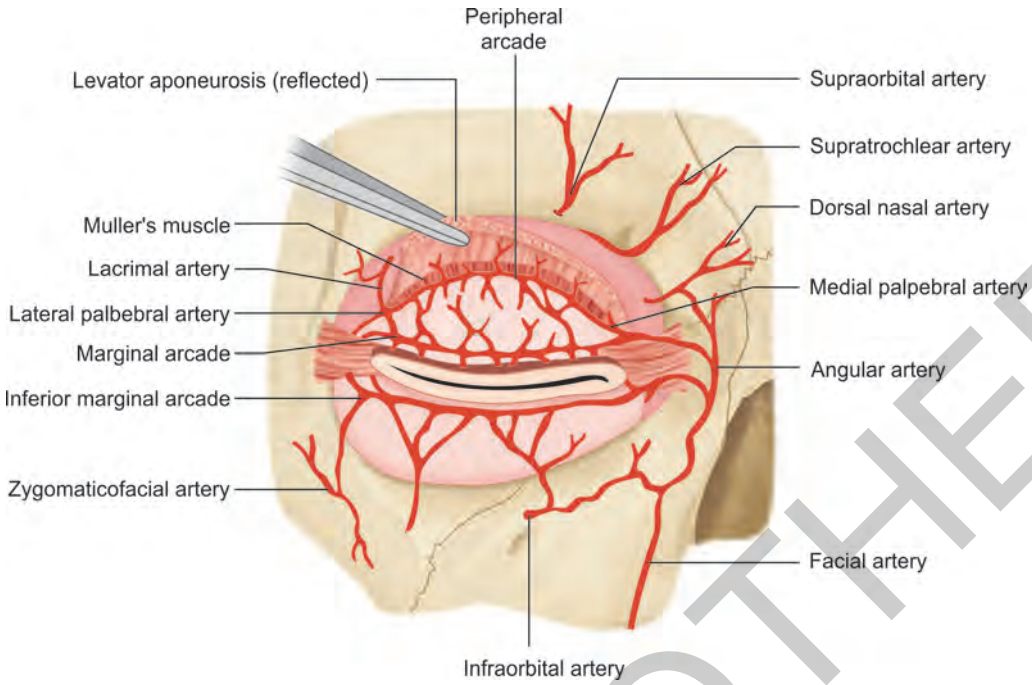

Each eyelid has a *marginal arcade*, which is found on the surface of the tarsus along the eyelid margin. The upper eyelid has an additional arterial supply known as the *peripheral arcade*, which lies between the levator aponeurosis and Muller's muscle.

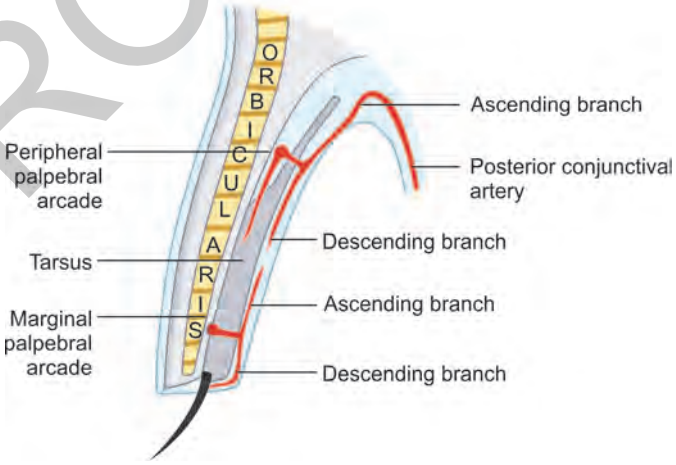

Venous Drainage

- Preseptal tissues:
  - Superficial temporal vein laterally
  - Angular vein medially
- Postseptal tissues:
  - Orbital vein
  - Deeper branches of anterior facial vein
  - Pterygoid plexus.

Applied Anatomy

- Reconstructive flaps of eyelids rarely undergo failure due to ischemia due to rich vascular supply.
- The extensive blood supply of the periocular tissues allows incision and mobilization of the tissues of the glabellar flap (a random flap) without a specific arterial supply.
- Extensive anastomoses provide a rich blood supply to the tissues of the periocular area, which prevents infection and promotes healing after trauma.

Suggested Reading

1. Bron A, Tripathi RC, Tripathi B. Wolff's Anatomy of the Eye and Orbit. UK: Hodder Arnold; 1998.
2. Cantor LB, Rapuano C, Cioffi GA. Orbit, Eyelids, and Lacrimal System. Orbit, Eyelids and Lacrimal system. San Francisco: American Academy Ophthalmology; 2016-17.
3. Collin JR. A Manual of Systematic Eyelid Surgery. Philadelphia: Elsevier Health Sciences; 2006.
4. Leatherbarrow B. Oculoplastic Surgery. Boca Raton, FL: CRC Press; 2010.
5. Sevel D. Developmental and congenital abnormalities and diseases of the nasolacrimal apparatus and orbit in children. Curr Opinion Ophthalmol. 1990;1(6):602-6.
6. Tawfik H, Abdulhafez M, Fouad Y, Dutton J. Embryologic and fetal development of the human eyelid. Ophthalmic Plast Reconstr Surg. 2018;32:407-14.
7. Tyers AG, Collins JR. Colour Atlas of Ophthalmic Plastic Surgery. Hong Kong. 1995;159:128.

JAYPEE BROTHERS

1.2 Eyelid Embryology and Congenital Eyelid Anomalies

1. Describe the embryological development of eyelids in brief and enumerate four congenital anomalies of eyelids.

Origin of Eye Lid Tissue

The eyelids develop from both secondary mesenchyme (mesoderm invaded by cranial neural crest cells) and surface ectoderm **(Table 1)**.

TABLE 1: Development of eyelid structures.

Surface ectoderm	• Conjunctiva • Skin epithelium • Hair follicles • Zeis glands • Glands of Moll • Meibomian glands
Mesenchyme	• Fibers of striated muscles • Endothelial lining of eyelid blood vessels
Neural crest cells	• Tarsal plate • Levator aponeurosis and Muller • Orbital septum • Eyelid melanocytes • Pericytes of eyelid blood vessels • Schwann cells and axons in eyelid nerves • Connective tissue components of the levator and orbicularis muscles

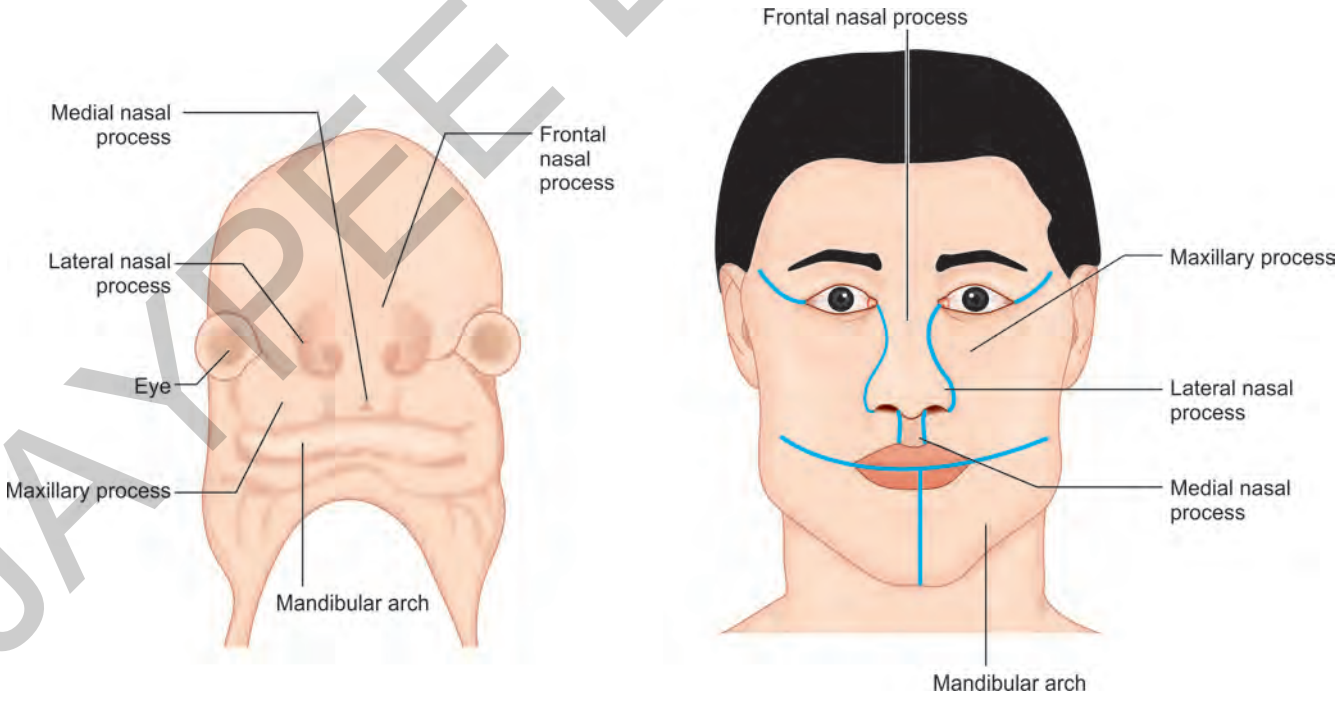

- Upper lid develops from fusion of medial and lateral nasal processes.
- Lower lid forms from extension of maxillary process.

JAYPEE BROTHERS

There are five phases:

1. Eyelid formation
2. Fusion
3. Development
4. Separation
5. Maturation of eyelid structures.

At 6 weeks of gestational age:

First indication of the embryonic eyelid development is seen.

↓

Small grooves or depressions develop in the surface ectoderm immediately above and below the developing eye.

↓

Rapidly deepen to form the eyelid folds (7 weeks)

Also during the seventh week, a solid cord of epithelial cells invaginates into the thickened mesenchyme in the medial one-sixth of the eyelid and bifurcates forming the precursors of puncta and canaliculi.

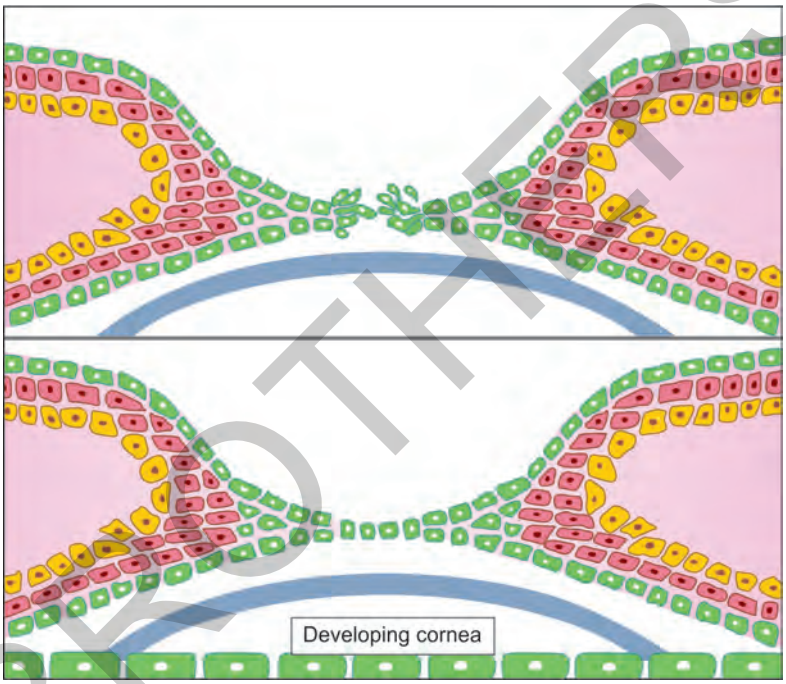

At the beginning of week 8:

The gap between the upper and lower eyelid folds and the cornea is filled by epithelial migration and proliferation

↓

Eyelid fusion

11 Weeks—Primordial tarsal plate, eyelash follicle anlages, primordial orbital septum, and meibomian gland

14th Week—The eyelid clearly divided into separate layers.

Rudimentary eyelashes, sebaceous, and sweat glands could be seen near the eyelid margin, and a primordial tarsal plate has formed.

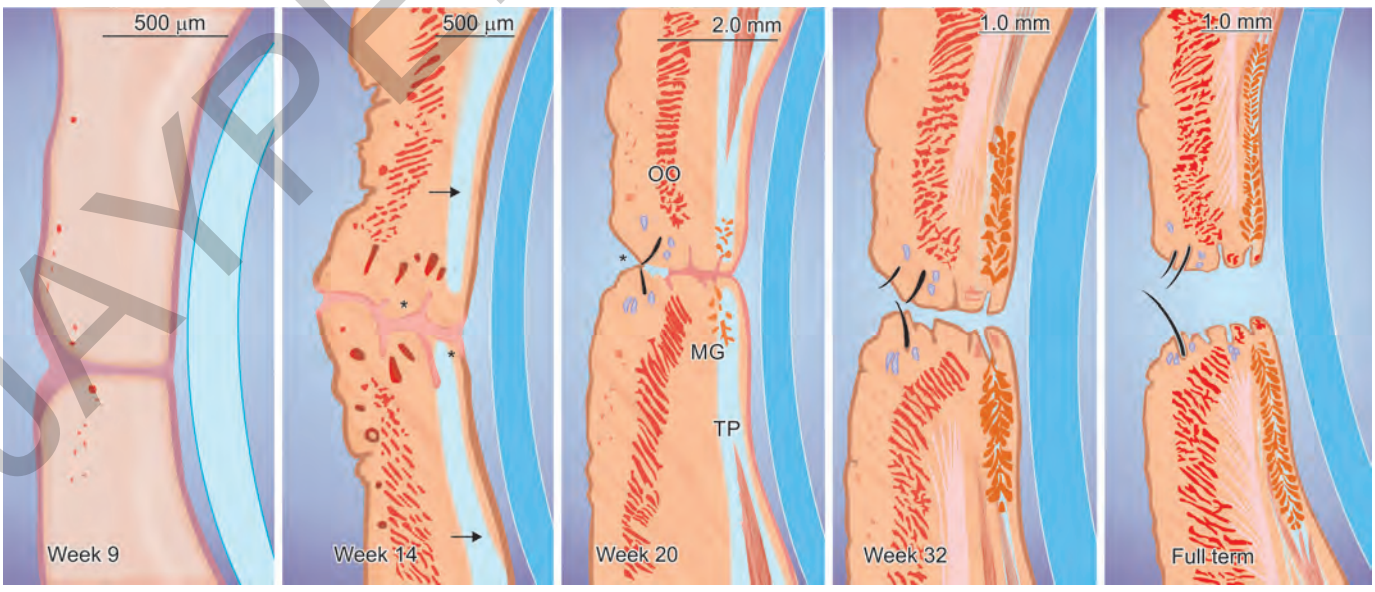

(MG: meibomian gland; OO: orbicularis oculi; TP: tarsal plate)

JAYPEE BROTHERS

20th Week:
- Eyelid separation starts anteriorly.
- Meibomian gland branching is first observed.
- Tarsal plate lengthens significantly.
- Orbicularis oculi muscle looks more fully developed.
- Mature eyelash follicles about to pierce the eyelid margin.

32nd week:
- Nearly fully developed appearance
- Meibomian glands increase in length—present in two-thirds of the length of the tarsal plate
- The eyelids are fully separated.

Full term: Final appearance of the eyelids at birth, which is not dissimilar from the adult counterpart.

2. Describe the common developmental anomalies of eyelids.

The common eyelid anomalies due to an anomaly in the process of development include the following:

Coloboma of the Lid

- An embryological cleft in the eyelid—usually isolated anomaly when it occurs in medial upper eyelid.
- If, in lower eyelid, it will be associated with other congenital conditions such as facial cleft and lacrimal deformities.
- Coloboma of the eyelid has a different embryologic origin from a coloboma of the globe. Although the sequence of eyelid development itself is induced by the developing globe, there is no clear evidence that eyelid coloboma results from globe abnormalities. Coloboma of the eyelid is along the spectrum of craniofacial clefts and can occur either as an isolated malformation or associated with ocular or systemic anomalies.
- Lid coloboma arises from defective eyelid development; either during fusion or during reseparation.

Isolated Coloboma

- *Coloboma associated with corneopalpebral adhesion (CPA; cryptophthalmos):*
  - *Complete:* No discernible eyelid differentiation, and the eyes are completely covered with skin
  - *Incomplete:*
    - A skin-fold devoid of tarsus covers the medial aspect of the palpebral aperture
    - Significant CPA
    - Lower fornix and lateral upper eyelids usually spared
  - *Abortive type/congenital symblepharon variant (CSV):*
    - True coloboma of variable sizes with a diverse range of CPA
    - Lower fornix and lateral upper eyelids usually spared
- *Simple coloboma (SC):* Upper eyelid coloboma in isolation not associated with CPA.

Syndromic Variants

- Fraser syndrome
- Goldenhar syndrome (GS)/oculoauriculovertebral spectrum—GS is a pleiotropic condition with a spectrum of cardiac, renal, and skeletal manifestations besides the typical facial and vertebral anomalies.
- *Rare syndromes:*
  - Manitoba oculotrichoanal syndrome
  - Ablepharon-macrostomia syndrome
  - Nasopalpebral lipoma–coloboma syndrome
  - Amniotic band sequence
  - Oculoectodermal syndrome
  - Neurocutaneous syndromes
  - Encephalocraniocutaneous lipomatosis
  - Delleman syndrome or oculocerebrocutaneous syndrome
  - Linear nevus sebaceous syndrome
  - CHARGE syndrome.

JAYPEE BROTHERS

Cryptophthalmos

- Characterized by partial or complete absence of eyebrow, palpebral fissure, eye lashes, and conjunctiva.
- The partially developed adnexa are fused to anterior segment of the globe and can be unilateral/bilateral.
- Histologically all eyelid structures are attenuated or absent. Underlying eye will be defective.
- *Types*:
  - *Complete (typical) cryptophthalmos:* The lids are replaced by a sheet of skin running from forehead to cheek with absence or poor development of the eyebrow. No lashes or gland structures can be identified. The covered globe gives rise to an elevation in the overlying skin which moves when eye movements occur. The skin is adherent to the underlying cornea, and there is no conjunctival sac. Microphthalmos is usual.
  - *Incomplete (atypical) cryptophthalmos:* Rudimentary lids are present, with a small conjunctival sac placed laterally. The palpebral aperture is about one third of normal length. The globe is usually small and almost completely covered by skin.
  - *Abortive form or congenital symblepharon:* The upper lid, without a defined margin, covers and adheres to up to 75% of the upper cornea. The lid has no punctum, and there is no upper conjunctival fornix. The free part of the cornea may be keratinized and opaque. The globe is usually of normal size but may be small.

The systemic associations of cryptophthalmos include abnormalities of head shape, nose and ears, meningoencephalocele, cleft lip and cleft palate, syndactyly, genital anomalies, and a miscellaneous group of defects including atresia of larynx, kidneys, bladder and anus, and umbilical hernia.

Epiblepharon

- Epiblepharon is characterized by redundant anterior lamella presenting as an abnormal horizontal skin fold overriding the eyelid margin, resulting in misdirected lashes toward the conjunctiva and cornea.
- Symptoms range from none to features of eye irritation. The severity of epiblepharon symptoms may be associated with the type and number of eyelashes irritating the eyes.
- Few and fine eyelashes are often less symptomatic than thick and plentiful lashes. Due to this variability, symptoms of epiblepharon may change with age.
- Child may develop decreased visual acuity due to the development of induced astigmatism.

Epicanthal Folds

Epicanthus is a medial canthal fold that may result from immature midfacial bones or a fold of skin and subcutaneous tissue. There are four types of epicanthi.

1. *Epicanthus tarsalis*—fold is more prominent in upper lid.
2. *Epicanthus inversus*—fold is more prominent in lower lid associated with blepharophimosis, ptosis, and epicanthus inversus syndrome (BPES).
3. *Epicanthus palpebralis*—fold involves upper and lower lid equally.
4. *Epicanthus superciliaris*—fold arises from eyebrow region and runs to lacrimal sac.

Suggested Reading

1. Bron AJ. Wolff's Anatomy of the Eye and Orbit. London; Weinheim; Tokyo: Chapman & Hall Medical; 1997.
2. Cantor LB, Rapuano C, Cioffi GA. Orbit, Eyelids, and Lacrimal System. San Francisco: American Academy Ophthalmology; 2016.
3. Collin JR. A Manual of Systematic Eyelid Surgery. Philadelphia, PA: Elsevier Health Sciences; 2006.
4. Leatherbarrow B. Oculoplastic Surgery. London: CRC Press; 2010.
5. Sevel D. Developmental and congenital abnormalities and diseases of the nasolacrimal apparatus and orbit in children. Curr Opinion Ophthalmol. 1990;1(6):602-6.
6. Tawfik H, Abdulhafez M, Fouad Y, Dutton J. Embryologic and fetal development of the human eyelid. Ophthal Plast Reconstr Surg. 2016;32(6):407-14.
7. Tyers AG, Collins JR. Colour Atlas of Ophthalmic Plastic Surgery. Hong Kong. 1995;159:128.

JAYPEE BROTHERS

for detailed information on ophthalmology books, visit our website www.jaypeebrothers.com, for detailed information on ophthalmology books, visit our w

Postgraduate Ophthalmology

An Exam Preparatory Manual

Postgraduate Ophthalmology: An Exam Preparatory Manual is a book to help the ophthalmology students across the country to become familiar with the type of questions they may come across in their theory examination. Besides it will help the general ophthalmologists to study a particular topic in a more focused manner instead of a comprehensive approach.

The book has several specialty-wise sections. In each section, the authors have attempted to discuss the questions and the answers specific to that question only. Unlike, standard textbook it will provide a more focused discussion rather than an overview of the topic. The questions have been taken from various ophthalmology examinations across India. We have included questions from various ophthalmology examinations including MD and MS Ophthalmology, DNB and Diploma in Ophthalmology.

The answers are formulated in such a way that it will give you an idea about what to expect in your postgraduate examinations. Moreover, at places it is more elaborative to encompass other related questions on the same topic. Figures, flowcharts, tables and learning points have been included in many sections to make it easier for you to understand and memorize.

We have attempted to cover all the sections and questions important for postgraduate ophthalmology examinations. However, considering the vast number of questions it was not possible for us to cover the answers of all the questions here. So, we have provided a question bank at the end of the book which will help the students to prepare well for their theory examination.

Prafulla Kumar Maharana MD DNB is currently working as an Associate Professor of Ophthalmology at Dr Rajendra Prasad Centre (RPC) for Ophthalmic Sciences, All India Institute of Medical Sciences (AIIMS), New Delhi, India. He has the teaching experience of more than 10 years and currently working as the Academic Co-Incharge of Postgraduate Teaching at RPC. He has completed his MD, and Senior Residency from RPC, AIIMS, New Delhi. He has the experience of working as Faculty at LV Prasad Eye Institute (LVPEI), Hyderabad and Bhubaneswar; AIIMS, Bhopal; and AIIMS, Bhubaneswar. He is popularly known among the Residents for his work on Ophthalmology Clinics book series. Besides he has published around 150 PubMed-indexed papers and more than 50 chapters in national and international books. He is currently the Editor of DOS times and Section Editor in the Indian Journal of Ophthalmology.

Ritu Nagpal MD FLVPEI (Cornea) is working as a Consultant at the Eye7 Hospitals, New Delhi, India. She completed her postgraduation in Ophthalmology from the prestigious Dr Rajendra Prasad Centre for Ophthalmic Sciences, AIIMS, New Delhi, following which she underwent a two-year intensive cornea and anterior segment fellowship at the renowned LV Prasad Eye Institute (LVPEI) at Hyderabad, Telangana. After finishing her fellowship, she joined back at Dr Rajendra Prasad Centre for Ophthalmic Sciences and continued her work as a Senior Research Associate for 3 years. She is well-equipped in managing various corneal and ocular surface pathologies and in performing refractive procedures. She has several indexed journal publications and book chapters to her credit and is the Co-Editor of the third edition of "Corneal Transplantation" book. Since her fellowship, she has been involved in participating and presenting at various subspecialty workshops and conferences. She believes in principles of delivering good-quality patient care and practices perfectionism in every part of her work.

Pranita Sahay MD is presently working as Consultant (Cataract, Cornea and Refractive Surgery Services), Centre for Sight Eye Hospital, New Delhi, India. In addition to completing her postgraduation and senior residency from AIIMS (New Delhi), she has done FRCS (Glasgow), FRCOphth (London), FICO (Cornea), FAICO (Refractive Surgery) and DNB. She has over 100 publications to her credit with over 85 publications in international peer-reviewed journals and contributed to 30 book chapters. She has an experience of working at various institutes such as AIIMS, Lady Harding Medical College (LHMC), University College of Medical Sciences (UCMS) and GTB hospital, and Centre for Sight Eye Hospital.

Namrata Sharma MD FRCOphth FRCSEd is a Professor of Ophthalmology (Cataract, Cornea and Refractive Surgery Services) at Dr Rajendra Prasad Centre for Ophthalmic Sciences, All India Institute of Medical Sciences, New Delhi, India. She did her fellowship in Ocular Inflammatory Diseases and Lamellar Keratoplasty Surgeries from the Moorfields Eye Hospital, London, UK. With 2 patents to her credit (Natamycin and Natamatrix), she has been awarded at several national as well as international occasions for her research works. She has published more than 555 publications in various national and international peer-reviewed journals and has authored 119 book chapters and 17 books. Her ongoing research is focused on the effect of collagen crosslinking in cases of infectious keratitis and the use of newer biosynthetic corneas as an alternative to human donor corneas. She was honored as one of the 100 most influential female ophthalmologists in the world in the "2021 Ophthalmologist Power List". She can be reached at *namrata.sharma@gmail.com*.

Printed in India

Available at all medical bookstores
or buy online at www.jaypeebrothers.com

JAYPEE BROTHERS
Medical Publishers (P) Ltd.
EMCA House, 23/23-B, Ansari Road,
Daryaganj, New Delhi - 110 002, INDIA
www.jaypeebrothers.com

Join us on facebook.com/JaypeeMedicalPublishers

Shelving Recommendation
OPHTHALMOLOGY

ISBN 978-93-5465-494-7