eebrothers.com, for detailed information on orthopedics books, visit our website www.jaypeebrothers.com, for detailed information on orthopedics books



The Fellows Manual
Techniques of
Spine Surgery

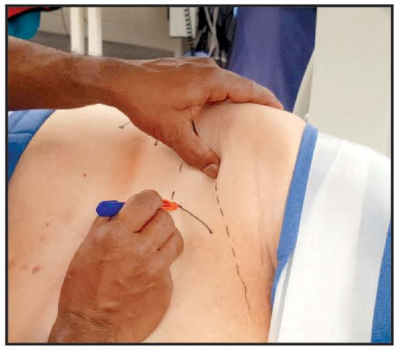

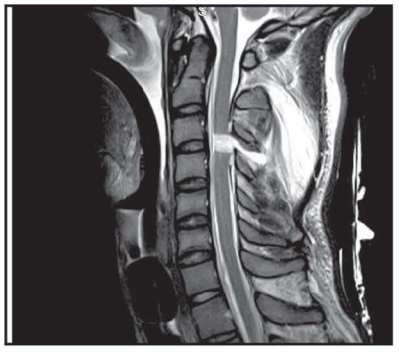



Barrett S Boody
Glenn S Russo
Alexander R Vaccaro
Greg Anderson

JAYPEE

Contents

SECTION 1 Cervical

1. **Occipital Fusion** 3
   Brett D Rosenthal, James D Kang

2. **Posterior Cervical C1–2 Fusion** 8
   Barrett S Boody, Glenn S Russo, Rick C Sasso

3. **Posterior Cervical Decompression and Fusion** 12
   Glenn S Russo, Barrett S Boody, Peter G Whang

4. **Posterior Cervical Foraminotomy** 17
   Yoshihiro Katsuura, Han Jo Kim

5. **Posterior Cervical Laminoplasty** 21
   John G Heller, R Matthew Wham

6. **Anterior Cervical Discectomy and Fusion** 28
   Anthony Viola III, Vadim Goz, Alan S Hilibrand

7. **Anterior Cervical Corpectomy and Fusion** 35
   David Casper, Jacob Hoffmann, Tom Mroz, Jason Savage

8. **Anterior Cervical Discectomy and Disk Arthroplasty** 39
   Bruce V Darden

9. **Pearls of Upper Cervical Spine Trauma Management** 42
   Daniel Leas, Barrett S Boody, Rick C Sasso

10. **Technical Pearls in the Management of Subaxial Cervical Trauma** 55
    Edward M DelSole, Michael Yayac, Alexander R Vaccaro

SECTION 2 Thoracolumbar

11. **Thoracic Transpedicular Decompression and Costotransversectomy** 65
    Preetpaul S Bagi, Glenn S Russo, Shirvinda A Wijesekera

12. **Anterior Thoracic Discectomy/Corpectomy/Anterior Instrumentation** 72
    Yoji Ogura, John R Dimar, Leah Y Carreon

13. **Technical Pearls in the Management of Spinal Oncology** 81
    Mostafa El Dafrawy, Jacob Buchowski

14. **Percutaneous Thoracolumbar Pedicle Screw Fixation** 91
    Barrett S Boody, Glenn S Russo, Greg Anderson

15. **Thoracolumbar Osteotomies: Posterior Column, Pedicle Subtraction, and Vertebral Column Resection** 96
Daniel R Rubio, Sean M Rider, Munish C Gupta

16. **Thoracolumbar Instrumentation** 102
Ron Lehman

17. **Sacral and Pelvic Instrumentation** 110
Barrett S Boody, Glenn S Russo, Joseph D Smucker

18. **Transforaminal Lumbar Interbody Fusion** 115
Barrett S Boody, Glenn S Russo, Jeffrey Rihn

19. **Technical Pearls in the Management of Adult Scoliosis** 118
Lawrence Lenke, James D Lin

20. **Anterior Lumbar Interbody Fusion Technique** 123
Barrett S Boody, Glenn S Russo, Mark Kurd

21. **Technical Pearls in the Surgical Management of Thoracic and Lumbar Trauma** 127
Ashley R Strickland, Rohan Gopinath, Samuel Q Li, Jael E Camacho, M Farooq Usmani, Steven C Ludwig

22. **Open Microdiscectomy and Laminectomy** 137
Tyler Kreitz, Howard An

SECTION 3 Miscellaneous

23. **Minimally Invasive Surgical Discectomy and Laminectomy** 145
Sheeraz Quereshi

24. **Extraforaminal Approaches for Microdiscectomy and Foraminal Decompression in the Lumbar Spine** 149
Barrett S Boody, Glenn S Russo, Rick C Sasso

25. **The Fellows Manual: Techniques of Spine Surgery Minimally Invasive Transforaminal Lumbar Interbody Fusion** 155
Peter B Derman, Sravisht Iyer, Dil V Patel, Joon S Yoo, Kern Singh

26. **Lateral Lumbar Interbody Fusion** 160
Corey T Walker, David S Xu, Juan S Uribe

27. **Ante-Psoas Interbody Fusion** 164
Neel Anand, Sheila Kahwaty

28. **Navigation Techniques** 173
Peter R Swiatek, Wellington K Hsu

29. **Technical Pearls in the Management of Spinal Cord Injury** 180
Daniel Franco, Aria Mahtabfar, Glenn Gonzalez, James Harrop

30. **Dural Repair Strategies** 188
Fadi Al-Saiegh, Anthony Stefanelli, Srinivas Prasad

31. **Minimally Invasive Sacroiliac Joint Fusion** 190
Matthew J Sabatino, Glenn S Russo, Peter G Whang

Index *197*

CHAPTER 4

Posterior Cervical Foraminotomy

Yoshihiro Katsuura, Han Jo Kim

JAYPEE BROTHERS

INTRODUCTION

The posterior cervical foraminotomy is a motion-sparing procedure used to decompress the cervical nerve roots in the setting of radiculopathy. The primary goal of the operation is the removal of the medial half of the facet complex (composed of superior and inferior articular process) to relieve pressure from the cervical nerve root. The most common indication for this procedure is to treat compression from a lateral soft disk herniation or less commonly, from posterior osteophytes originating mainly from the superior articular process of the facet complex.[1] The posterior foraminotomy is advantageous as it may minimize the complications of adjacent segment disease resulting from decreased segmental motion with fusion procedures.[2] Furthermore, posterior approaches do not violate the retropharyngeal space, leaving the esophagus and recurrent laryngeal nerve untouched and thus have less dysphagia and airway complications. Finally, the posterior foraminotomy is advantageous over anterior cervical discectomy and fusion (ACDF) procedures as there is no possibility of pseudoarthrosis. However, as it is true with most posterior cervical procedures, careful attention must be made to preserve soft tissues to avoid postoperative kyphosis.[3] Moreover, bilateral radiculopathy or myelopathy type symptoms are better addressed with other approaches such as ACDF, laminectomy plus fusion, or laminoplasty. Nonetheless, cervical foraminotomy can be a powerful adjunct to any larger posterior cervical procedure to relieve radiculopathy in the setting of myelopathy or prevent C5 palsy. Studies in the past have failed to show superiority of posterior foraminotomy over ACDF, however, in certain indications, it can be advantageous.[4] The prime example is a patient with myeloradiculopathy resulting from multilevel compression which requires a posterior decompression.

ANATOMY

- *The cervical foramen has four boundaries:* The pedicles (superior and inferior), the superior articular facet of the facet complex and lamina (posterior), and the posterolateral aspect of the uncovertebral joint and intervertebral disk (anterior).[5]
- The overall shape of the foramen resembles a funnel, with the medial entrance being narrow, and the lateral exit being wide.[5] It may be divided into three zones: Medial (pedicle zone where most compression occurs, and corresponds to entrance of the cervical foramina), middle (posterior to vertebral artery), and lateral zone (lateral to the vertebral artery).[6]
- *Nerve root structure:* A single cervical nerve root is composed of bundles of ventral and dorsal rootlets (typically 14–23 bundles) which emerge from the spinal cord one segment higher than the nerve root. The dorsal bundles form the dorsal root ganglion and combine with the ventral bundles to form the spinal nerve root lateral to the foramen.[5]
- *Anatomic relations between the nerve root and disk:* The relationship between the nerve root and the disk varies depending on cervical level.
  - *C4–5 nerve roots:* Disk is proximal to or at the level of the nerve root take off (shoulder position).
  - *C6–7 nerve roots:* Disk is caudal to nerve root take off (axillary position).
  - *C8 nerve root:* Disk is caudal and does not directly contact the nerve root.[5]
- Most nerve roots may be fully decompressed with removal of the medial ½ of the facet complex to the level of the pedicle. The exception to this is the C8 nerve root which may require a larger resection as the result of the longer width of the medial portion of the cervical foramina and morphology of the superior articular process of T1.[5,6]

SUGGESTED INSTRUMENTS

- Jackson table with bivector traction set up
- Neuromonitoring
- McCullough retractor set
- High-speed burr 3 mm diamond tip
- Cervical Kerrison rongeurs
- Codman microcurette set
- Micropituitary
- Cervical nerve hook
- Cervical ball hook
- Paralysis is not typically used as it will interfere with motor evoked potentials (MEPs).

APPROACH

- *Position:*
  - After induction of general anesthesia, Gardner-Wells tongs are placed 1 cm superior to the pinna and in-line with the external auditory canal.
  - The patient is then placed prone on a Jackson table with the head secured to bivector traction.[7]
  - 15 lbs of weight is attached to the flexion rope, keeping the extension rope free. The extension rope is generally not critical for this procedure and keeping the head in the flexed position is beneficial for exposure (nonetheless, we always set up the extension rope in case of possible conversion to a fusion procedure). The flexed position allows the cervical facet joints to maximally displace which facilitates removal of the medial facet joint complex. It also elongates and flattens the posterior soft tissues of the neck allowing for easier dissection. It is important to position the body in reverse Trendelenburg in order to prevent venous pooling to the head.
  - The patient's arms are well padded around the cubital and carpal tunnels and tucked using a figure of 8 sheet **(Fig. 1)**.



Fig. 1: *Preoperative draping for posterior cervical procedure:* The arms are padded and tucked in a figure of 8 position and the head is attached to the bivector traction device.

- *Fluoroscopy:*
  - We find that the tendency is to make the incision too proximal, which can result in unnecessary restriction by soft tissues. This prevents the surgeon from sliding the Kerrison cranially under the facet joint. Thus the incision should be places slightly caudal to allow a trajectory which is perpendicular to the facet and lamina.
  - Thus, fluoroscopy is brought in to confirm the levels with a metallic marker on the skin or a spinal needle. A 2–3 cm incision is all that is necessary for a single level, and will typically be more distal than first thought because of the flexed posture of the neck. If soft tissues prevent adequate visualization by X-ray, we recommend using a computed tomography (CT) navigation system which will allow correct identification of levels.
- *Draping:* Skin is then prepped with iodine-based scrub solution or other sterilizing agent and the patient is draped in a sterile fashion.
- *Approach:*
  - A careful midline incision is made through the epidermis of the skin, completing the dermal incision with electrocautery. We do not complete the final 2 mm of dermal incision at the proximal and distal ends of the incision in order to optimize the cosmetic appearance of the incision after healing and to prevent tearing of the epidermis.
  - The fat is carefully dissected with electrocautery until the fascia is encountered. For a unilateral foraminotomy, the dissection through the fascia should only be performed on a single side.
  - Meticulous periosteal dissection is then carried out lateral to the spinous process across the lamina making all attempts to avoid the synovial capsule of the facet joint and the interlaminar space is isolated. The synovial capsule and facet joint should be identified using a blunt instrument (such as a cervical nerve hook) to palpate and define the lateral border of the facet through the soft tissue. This step gives an understanding of the dimensions of the joint complex and how much dissection and resection can take place safely. Usually, you can identify the spinous processes of the levels above and below the foraminotomy site and partially elevate the muscles.
  - A McCullough retractor of the depth appropriate for the soft tissue thickness is selected and placed to expose the medial aspect of the facet joint. If the incision is too small to utilize the full size blade of the McCullough, it is possible to instead utilize the spike blades, which are thinner and when positioned correctly, can provide adequate visualization.

JAYPEE BROTHERS

Decompression

- Once again, we ensure that the neck is in the position of maximal flexion to best expose the cranial border of the superior articular facet once resection is begun.
- An outline of the proposed resection should be made with electrocautery to denude the bone of joint capsule covering the facet to be removed. Again, a blunt instrument can be used to palpate the unexposed lateral border of the facet to determine the extent of resection.
- The cranial and caudal lamina at the medial aspect of the facet joint (interlaminar V) must be identified before starting the bony resection.
- High-speed side cutting burr is then used to remove the inferior articular facet in a medial to lateral and then superior to inferior fashion to uncover the superior articular facet. This resection is not >5 mm lateral (<50% of the facet joint). This creates a resection in the shape of an inverted L making a window to visualize the superior articular facet. Although the inferior articular facet is generally not the source of compression, it must be removed to gain access to the superior articular facet.
- The medial facet resection must be limited to ≤50% (on average 5.9 mm) of the total width of the facet to prevent segmental hypermobility and destabilization of the joint **(Fig. 2)**.[8]
- Attention is now turned to the visible portion of the superior articular facet. The high-speed burr is once again utilized to resect the portion of the facet which is visible in a medial to lateral and cranial to caudal fashion, starting from the lateral portion that is visualized. Again, a window is created by removal of superior articular facet in the shape of an L.
- The ligamentum flavum may be partially resected but should be kept mostly intact to preserve stability of the segment.

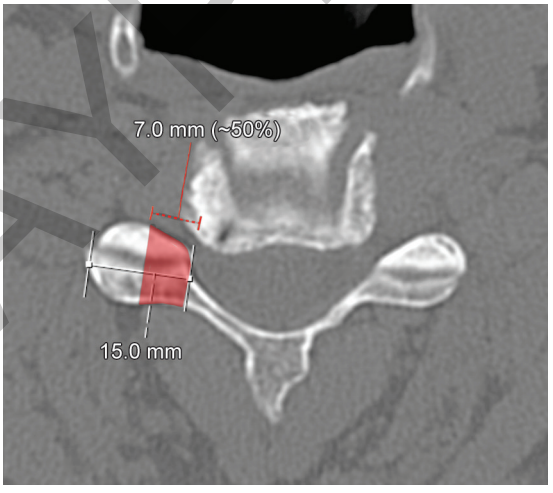

Fig. 2: Cross-sectional demonstration of facet complex which may be safely resected (red outline).

- With the ligament removed, the surgeon is now able to palpate the pedicle (the medial border of which can typically be palpated with 2–3 mm of bony exposure). The surgeon must not exceed 5 mm of lateral resection until you can be sure where the lateral edge of the pedicle is located.
- As we burr down, the cancellous bone becomes visible which is the sign that the far cortex is approaching. As this is the bone closest to the underlying nerve root, care should be taken not to exceed the depth of the far cortex. At this point, the trough may be completed with a cervical Kerrison.
- Once the L-shaped trough is completed, a Codman 1B microcurette is used to excise the bone fragment of the medial superior articular facet fragment. This is performed by slipping the curette ventral to the fragment and applying a gentle a dorsolateral force. This will disrupt any remaining cortical attachments. If the fragment is adherent to soft tissue, a micropituitary may be used to remove the bone.
- Any sharp bone edges are then carefully smoothed with a 1 mm Kerrison rongeur.
- A cervical nerve hook is then used to assess the foraminotomy by palpating the medial and lateral margins of the pedicle to ensure full decompression (decompression should reach the lateral border of the pedicle). The cranial border is assessed for any remnant of bone from the superior articular facet resection. If bone is left, it may cause residual symptoms **(Fig. 3)**.
- In cases of soft disk herniation, the nerve should be gently mobilized with a cervical hook or ball tipped probe to identify any extruded fragments. If the fragment

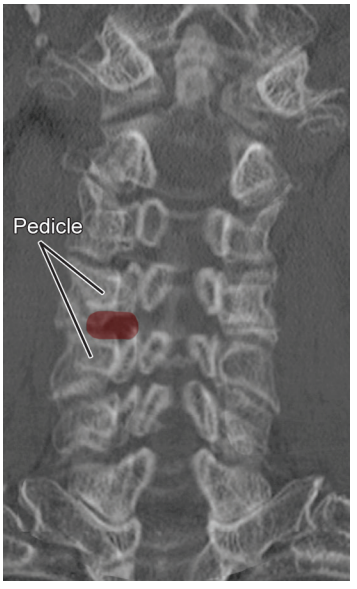

Fig. 3: Computed tomography overlay image demonstrating coronal anatomy and orientation of resection (red oval) in relation to cervical pedicles.

JAYPEE BROTHERS

is contained within annulus, a small annulotomy may be made to carefully express the fragment.

- Hemostasis is achieved using bone wax for bony surfaces and a combination of bipolar electrocautery, thrombin, and gelatin hemostatic matrix for epidural vessels.
- The wound is then irrigated with copious normal saline to remove any bone fragments or dust, and closed in layers.

REFERENCES

1. Jagannathan J, Sherman JH, Szabo T, Shaffrey CI, Jane Sr JA. The posterior cervical foraminotomy in the treatment of cervical disc/osteophyte disease: a single-surgeon experience with a minimum of 5 years' clinical and radiographic follow-up: Clinical article. J Neurosurg Spine. 2009;10(4):347-56.
2. Hilibrand AS, Carlson GD, Palumbo MA, Jones PK, Bohlman HH. Radiculopathy and myelopathy at segments adjacent to the site of a previous anterior cervical arthrodesis. J Bone Jt Surg. 1999;81(4):519-28.
3. Albert TJ, Vacarro A. Postlaminectomy kyphosis. Spine. 1998;23(24):2738-45.
4. Herkowitz HN, Kurz LT, Overholt DP. Surgical management of cervical soft disc herniation. A comparison between the anterior and posterior approach. Spine. 1990;15(10):1026-30.
5. Tanaka N, Fujimoto Y, An HS, Ikuta Y, Yasuda M. The anatomic relation among the nerve roots, intervertebral foramina, and intervertebral discs of the cervical spine. Spine. 2000; 25(3):286-91.
6. Ebraheim NA, An HS, Xu R, Ahmad M, Yeasting RA. The quantitative anatomy of the cervical nerve root groove and the intervertebral foramen. Spine. 1996;21(14):1619-23.
7. Karikari IO, Bumpass DB, Gum J, Sugrue P, Chapman TM, Elsamadicy AA, et al. Use of bivector traction for stabilization of the head and maintenance of optimal cervical alignment in posterior cervical fusions. Glob Spine J. 2017;7(3): 227-9.
8. Zdeblick TA, Zou D, Warden KE, McCabe R, Kunz D, Vanderby R. Cervical stability after foraminotomy. A biomechanical in vitro analysis. J Bone Joint Surg Am. 1992;74(1):22-7.

JAYPEE BROTHERS

or detailed information on orthopedics books, visit our website www.jaypeebrothers.com, for detailed information on orthopedics books, visit our website

The Fellows Manual Techniques of Spine Surgery

With this project, we attempt a unique perspective on surgical education; we want communicate the nuances and reasoning of senior authors' wisdom and experience. We worked to create a concise and valuable guide, written for a sophisticated audience, who already understands the mechanics of a procedure but will benefit from focused commentary on technical pearls and details. We hope that these points will help the readers to streamline their technique and avoid complications.

Barrett S Boody is an Orthopedic Spine Surgeon in Indianapolis, Indiana and is a partner at the Indiana Spine Group. He stays actively involved with research as well as educating residents and fellows and serves as an Assistant Professor of Clinical Orthopedic Surgery at Indiana University School of Medicine, Indianapolis, USA.

Glenn S Russo is a Spine Surgeon in Connecticut where he is a partner at Connecticut Orthopedics. He enjoys a diverse spinal practice in his community and also engages in medical mission work abroad. At the Frank H Netter School of Medicine at Quinnipiac University, he serves as Clinical Assistant Professor and works to train students, residents and fellows. He is involved in leadership and research at his affiliated institutions.

Alexander R Vaccaro is the Richard H Rothman Professor and Chairman, Department of Orthopedic Surgery and Professor of Neurosurgery at Thomas Jefferson University in Philadelphia, Pennsylvania, USA. He has over 1000 peer-reviewed and 210 non-peer reviewed publications. He has published over 372 book chapters and is the Editor of over 65 textbooks, Co-Editor of OKU-Spine I and Editor of OKU-8. He is also Co-Director of the Regional Spinal Cord Injury Center of the Delaware Valley and Co-Director of the Spine Fellowship Program at Thomas Jefferson University Hospital where he instructs current fellows and residents in the diagnosis and treatment of various spinal problems and disorders.

Greg Anderson is a Spine Surgeon in Philadelphia, Pennsylvania, USA. He holds a professorship at the Thomas Jefferson University School of Medicine and is a member of the Rothman Institute. He enjoys teaching Fellows and Residents in the Department of Orthopedic Surgery and has a special interest in less invasive surgical techniques.

Printed in India

Available at all medical bookstores
or buy online at www.jaypeebrothers.com

JAYPEE BROTHERS
Medical Publishers (P) Ltd.
EMCA House, 23/23-B, Ansari Road,
Daryaganj, New Delhi - 110 002, INDIA
www.jaypeebrothers.com

Join us on facebook.com/JaypeeMedicalPublishers

Shelving Recommendation
ORTHOPEDICS

ISBN 978-93-5465-539-5