mation on anesthesia books, visit our website www.jaypeebrothers.com, for detailed information on anesthesia books, visit our website www.jaypeebrothers.com

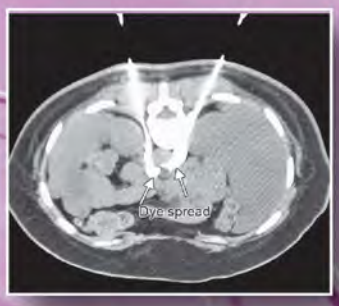





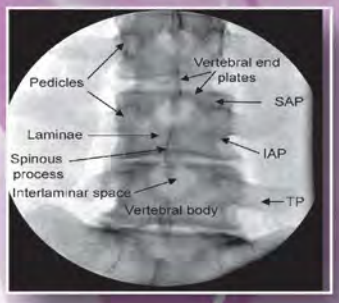

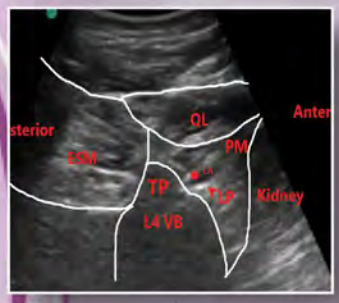



Atlas of Interventional Pain Management Procedures

A Stepwise Approach

with Procedures Videos

Under the Auspices of
Pain Management Research Foundation-India

Access Videos by Scanning the QR Code Inside

Editors
Dwarkadas K Baheti
Sanjeeva Gupta
Sanjay Bakshi
RP Gehdoo

Foreword
Subhash Jain

JAYPEE

Contents

SECTION 1 BASICS: INTERVENTIONAL PAIN MANAGEMENT

1. **Fluoroscopy for Minimally Invasive Spinal and Trigeminal Procedures** 3
   Sanjeeva Gupta, Ganesan Baranidharan, Manohar Sharma, Harun Gupta
2. **Understanding of Radiological Anatomy** 27
   Kenneth Lupton, James Baren, Harun Gupta
3. **Understanding Common Image-guided Procedures** 36
   Kenneth Lupton, Jamen Baren, Harun Gupta
4. **Understanding the Pathology of Common Conditions through Magnetic Resonance Imaging for the Pain Physician** 40
   Harun Gupta, James Baren, Kenneth Lupton
5. **Radiation Protection** 44
   Satish Kamath, Dwarkadas K Baheti
6. **Informed Consent for Interventional Pain Management Procedures** 50
   Dwarkadas K Baheti
7. **Protocol for Interventional Pain Management Procedures** 52
   Dwarkadas K Baheti
8. **Role of Investigations for Interventional Pain Treatment Procedures** 54
   Dwarkadas K Baheti
9. **Medications Used for Interventional Pain Procedures** 59
   Kritika Doshi, RP Gehdoo

SECTION 2 HEAD AND NECK

10. **Trigeminal Nerve Block** 67
    Hemkumar Pushparaj, Manohar Sharma
11. **Percutaneous Cervical Cordotomy** 72
    Manohar Sharma, Hemkumar Pushparaj

SECTION 3 CERVICAL SPINE

12. **Interlaminar Cervical Epidural Block** 79
    Rathi Joseph
13. **Cervical Medial Branch Block** 82
    Sanjeeva Gupta, Babita Ghai
14. **Cervical Medial Branch Radiofrequency Ablation** 88
    Quyen Van Truong
15. **Cervical Radiofrequency Denervation in Lateral Patient Position** 91
    Sherdil Nath, Sanjeeva Gupta

SECTION 4 CHEST AND THORAX

16. **Intercostal Nerve Block** 103
    Dwarkadas K Baheti
17. **Intrapleural Block** 105
    Dwarkadas K Baheti

SECTION 5 LUMBOSACRAL SPINE

18. **Interlaminar Lumbar Epidural Block** 109
    Sanjay Bakshi
19. **Transforaminal Lumbar Epidural Block** 111
    Dwarkadas K Baheti, Sanjeeva Gupta
20. **Lumbar Transforaminal Epidural Steroid Injections: Technical Challenges** 121
    Sanjeeva Gupta, Dwarkadas K Baheti, Sanjay Bakshi
21. **Lumbar Medial Branch Block and Radiofrequency Ablation** 132
    Anil Sharma, Sanjeeva Gupta
22. **Caudal Epidural Block** 146
    Sanjay Bakshi
23. **S1 Nerve Root Block and Technical Challenges** 148
    Sanjeeva Gupta, Manohar Sharma, Sanjay Bakshi
24. **Sacroiliac Joint Block** 153
    Sanjeeva Gupta, Babita Ghai
25. **Sacroiliac Joint Radiofrequency Denervation** ... 156
    Samir Ranjit Jani, Sanjeeva Gupta, Ganesan Baranidharan
26. **Sacroiliac Joint Fusion: A Minimally Invasive Posterior Approach** 170
    Samir Ranjit Jani

27. Piriformis Tendon and Muscle Injection.....175
Yashwant Laxman Nankar, Dwarkadas K Baheti

28. Pudendal Nerve Block and Pulsed Radiofrequency Procedure.....177
Sanjeeva Gupta, Babita Ghai

29. Coccygeal Nerve Block.....179
Yashwant Laxman Nankar, Dwarkadas K Baheti

SECTION 6 NEUROMODULATION

30. Sacral Nerve Stimulation.....185
Hemkumar Pushparaj, Manohar Sharma

SECTION 7 PERIPHERAL BLOCKS

31. Radiofrequency Neurotomy of Suprascapular Nerve for Refractory Shoulder Joint Pain.....193
Nick Plunkett, Allen Pinto

32. Tennis or Golfer's Elbow.....197
Dwarkadas K Baheti

33. Hip Joint Injection.....200
Yehia Kamel

34. Greater Trochanteric Bursa Injection.....203
Yehia Kamel

35. Popliteal Nerve Block.....206
Yashwant Laxman Nankar, Dwarkadas K Baheti

36. Calcaneal Spur Injection.....210
Dwarkadas K Baheti

SECTION 8 SYMPATHETIC BLOCK

37. Stellate Ganglion Block.....215
Preeti Doshi

38. Splanchnic Plexus Block: Fluoroscopy Guided...220
Dwarkadas K Baheti

39. CT-guided Splanchinc Plexus Block.....223
Dwarkadas K Baheti

40. CT-guided Celiac Plexus Block.....225
Dwarkadas K Baheti

41. Celiac Plexus Block: Fluoroscopy Guided.....229
Dwarkadas K Baheti

42. Lumbar Sympathetic Plexus Block.....232
Dwarkadas K Baheti

43. Superior Hypogastric Plexus Block.....235
Dwarkadas K Baheti, Yashwant Laxman Nankar

44. Ganglion of Impar Block.....238
Dwarkadas K Baheti

SECTION 9 ULTRASOUND GUIDED BLOCK

45. Suprascapular Nerve Block.....243
Ritesh Roy, Gaurav Agarwal

46. Brachial Plexus Block (Supraclavicular Approach).....249
Ritesh Roy, Gaurav Agarwal

47. Thoracic Paravertebral Block.....253
Archana Areti, Ritesh Roy, Gaurav Agarwal

48. Ultrasound-guided Transversus Abdominis Plane Block.....258
Gaurav Agarwal, Ritesh Roy

49. Lumbar Plexus Block.....262
Ritesh Roy, Gaurav Agarwal

50. Lateral Femoral Cutaneous Nerve Block.....268
Ritesh Roy, Gaurav Agarwal

51. Sacral Plexus Block.....270
Ritesh Roy, Gaurav Agarwal

52. Pericapsular Nerve Group Block (For Hip Joint).....276
Ritesh Roy, Gaurav Agarwal

SECTION 10 ULTRASOUND-GUIDED DRY NEEDLING

53. Ultrasound-guided Dry Needling.....283
Lakshmi Vas

SECTION 11 ADVANCED PAIN MANAGEMENT

54. Spinal Cord Stimulation.....291
Timothy Ray Deer

55. Intrathecal Drug Delivery System.....294
Samir Ranjit Jani, Dwarkadas K Baheti

56. Transforaminal Endoscopic Discectomy.....298
Kailash M Kothari, Manish Raj, Shiraz Ahmed Munshi

57. Kyphoplasty.....317
Samir Ranjit Jani

Index.....321

CHAPTER

4

Understanding the Pathology of Common Conditions through Magnetic Resonance Imaging for the Pain Physician

Harun Gupta, James Baren, Kenneth Lupton

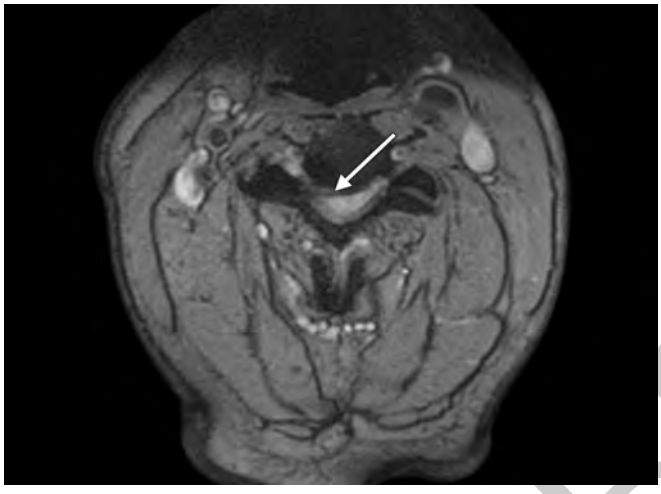

Fig. 1: Axial proton-density weighted MRI cervical spine sequence. A posterior disc-osteophyte bar (white arrow) causes central and right foraminal stenosis.



Fig. 2: Sagittal T2-weighted MRI cervical spine sequence. Multilevel disc-osteophyte bars (white arrows) cause central canal stenosis and efface the underlying thecal sac. Increased signal within the cord at the level of C3–C4 is consistent with myelopathic change (gray arrow).



Fig. 3: CT lumbar spine sagittal reformat showing L5 pars defect (white arrow) with grade 1 spondylolisthesis of L5 on S1.



Fig. 4: Sagittal T1-weighted MRI lumbar spine sequence. An L5 pars defect (white arrow) with grade 1 spondylolisthesis of L5 on S1 is evident. There is also effacement of the epidural fat surrounding the L5 root in the exit foramen indicating foraminal stenosis (grey arrow). A normal neural exit foramen (black arrow) is noted at L4.

JAYPEE BROTHERS

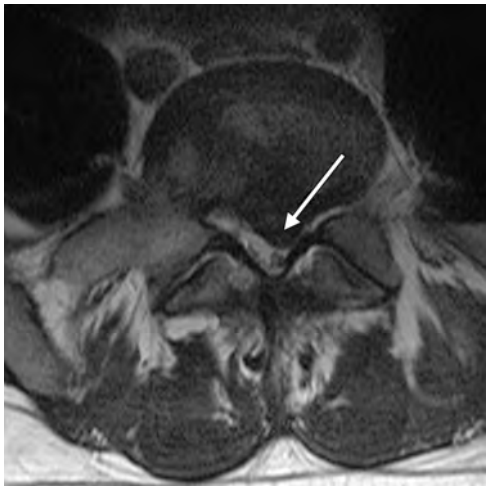

Fig. 5: Axial T2-weighted MRI lumbar spine sequence. Left central/subarticular disc protrusion (white arrow) causing left lateral recess stenosis and compromising the transiting left nerve root.



Fig. 6: Sagittal T2-weighted MRI lumbar spine sequence. L4–L5 disc extrusion (white arrows) with extension posteroinferior to lie at the level of the posterior L5 vertebral body.



Fig. 7: Sagittal T2-weighted MRI lumbar spine sequence. Severe central canal stenosis (white arrow) at L3–L4 with grade 1 anterolisthesis of L3 on L4.



Fig. 8: Sagittal T2-weighted MRI lumbar spine sequence. Severe central canal stenosis (white arrow) at L4–L5 secondary to disc bulge, facet and ligamentous hypertrophy (black arrow) with grade 1 degenerative spondylolisthesis.



Figs. 9A and B: (A) Axial T2-weighted and (B) sagittal T2-weighted sequences of the lumbar spine. A facet joint cyst (white arrows) causes severe central stenosis with thecal effacement and neural compromise.

JAYPEE BROTHERS

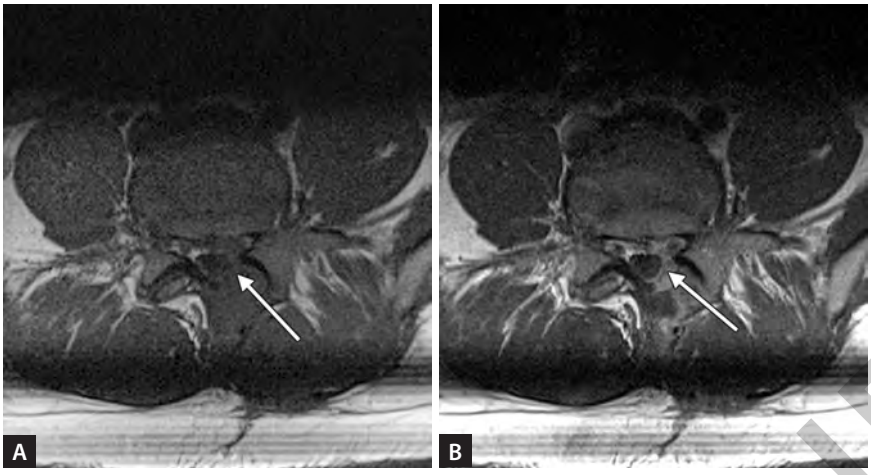

Figs. 10A and B: (A) Pre-contrast and (B) post-contrast T1-weighted axial lumbar spine sequences in a patient who had undergone microdiscectomy and left laminectomy. On the pre-contrast scan, there is low signal (white arrow) within the left epidural region. This enhances on the post-contrast scan (white arrow in B) and is consistent with post-operative scar tissue.



Fig. 11: Coronal oblique T2 fat-saturated sequence of the sacroiliac joints. There is marked edema (white arrows) of the left sacroiliac joint on both the iliac and sacral surfaces of the joint with bony irregularity (black arrow) reflecting erosions. The appearances are typical of sacroiliitis.



Fig. 12: Sagittal short T1 inversion recovery (STIR) MRI lumbar spine sequence. High signal is seen centered around the discs of L1–L2 and L2–L3 reflecting fluid within the discs and adjacent endplate edema (white arrows). The appearances are typical for infective spondylodiscitis.

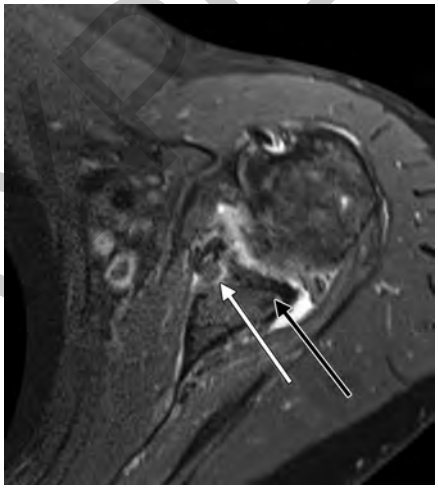

Fig. 13: Axial proton-density fat-saturated MRI shoulder sequence. A bony Bankart lesion is shown with a cleft of high signal undercutting the anteroinferior glenoid (white arrow). The posterior glenoid (black arrow) is marked for reference.

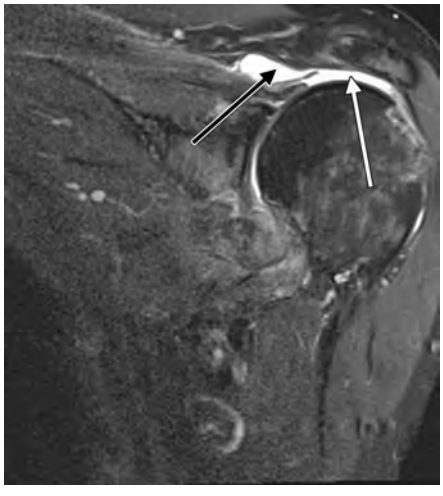

Fig. 14: Coronal proton-density fat-saturated MRI shoulder sequence. A full-thickness supraspinatous tear is demonstrated with no tendon fibers visible at the expected position superior to the humeral head (white arrow). There is also florid subacromial subdeltoid bursitis (black arrow).

JAYPEE BROTHERS



Fig. 15: Sagittal proton-density fat-saturated MRI knee sequence. There is a full thickness anterior cruciate ligament (ACL) tear with poor ligament fiber definition within the ligament (white arrow).



Fig. 16: Sagittal proton-density fat-saturated MRI knee sequence. There is a bucket-handle tear of the medial meniscus (white arrow) with the so-called double posterior cruciate ligament (PCL) sign present. This represents the flipped meniscal fragment (the handle) lying anterior to the normal PCL (black arrow) giving the impression of two ligaments.

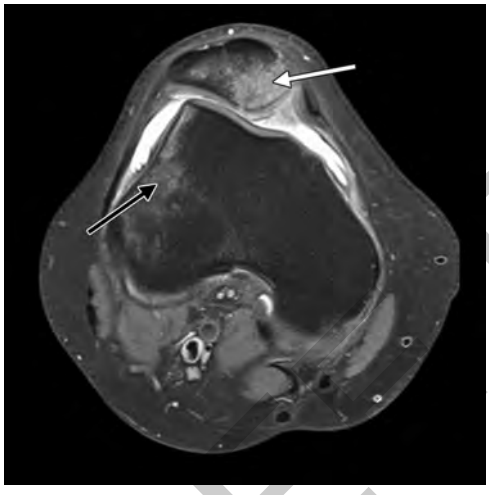

Fig. 17: Axial proton-density fat-saturated MRI knee sequence. Marked subchondral edema is seen at the medial aspect of the patella (white arrow) and the lateral aspect of the lateral femoral condyle (black arrow). This pattern is typical of lateral patellar dislocation.



Fig. 18: Coronal proton-density fat-saturated MRI ankle sequence. A focus of high signal (white arrow) is present at the medial aspect of the talar dome in keeping with an osteochondral injury. This is considered stable given the lack of a rim of high signal demarcating the deep aspect of the injury from the adjacent bone.

JAYPEE BROTHERS

for detailed information on anesthesia books, visit our website www.jaypeebrothers.com, for detailed information on anesthesia books, visit our website www.jaypeeb

Atlas of
Interventional Pain Management Procedures
A Stepwise Approach

Salient Features

- This is a unique atlas with contributions from international experts describing the most simple and advanced pain intervention techniques in a stepwise manner
- The atlas provides a clear guide to identify the bony structures as seen on fluoroscopic examination enabling the operator to perform the spinal interventions safely. *Remember:* Bone is our Eye and Friend when performing spinal interventions under fluoroscopy
- Chapters are consistently designed—covering indications, contraindications, equipment needed, and procedural steps—with the text presented in a bulleted style
- Including several cases in some of the spinal intervention chapters will prepare the readers to overcome the challenges and the variability that are encountered in clinical practice
- Some of the ultrasound-guided techniques described will enable readers to consider performing some pain-relief procedures in remote settings where fluoroscopy or CT guidance is not available.

Dwarkadas K Baheti MD is the Head of Pain Division, Department of Anesthesia, Critical Care and Pain, Lilavati Hospital and Research Center and Consulting Pain Physician to Raheja, Shushrusha and Holy Family Hospitals, Mumbai, Maharashtra, India. He is an Editor of books, *Understanding Anesthetic Equipment: A Practical Approach* (2016, 2018, 2021); *Interventional Pain Management: A Practical Approach* (2010, 2015); *Symptom-oriented Pain Management* (2011, 2016) and *Neuroanesthesia: Practical Tips* (2018). He was an Editor-in-Chief for *World Clinics Anesthesia, Critical Care and Pain*. He has edited *Pain Management; Analgesia Anesthesia for Labor and Delivery* (2013). He is pioneer in social campaign of Pain Awareness Program in India. He has posted many videos on pain management awareness on *YouTube channel*. He is former Professor and Head, Department of Anesthesia and Pain, Bombay Hospital Institute of Medical Sciences, Mumbai, Maharashtra, India. He did his MD from PGIMER, Chandigarh. He was International Scholar to Pain Management Centre, Cleveland Clinic Foundation and UICC Fellow to pain management clinic of Memorial Sloan Kettering Cancer Centre, USA. He was on editorial board of Indian Society for Study of Pain and Bombay Hospital Journal. He is first to perform Epiduroscopy in India and has a largest series of Neurolytic Celiac Plexus Block from India (300+). He has designed blunt tip needle for sympathetic blocks. He was recognized Teacher to Maharashtra University of Health Sciences and College of Physician, Mumbai. He was an Organizing Secretary and Chairperson to Global Update on Pain 2000–2015; Past President of Indian Society for Study of Pain (2001). He is an executive President of Pain Management and Research Foundation-India. He has organized, chaired, lectured and was Course Director many national and international meetings. He has organized many Hands-on Cadaver workshops at many national and international meetings.

Sanjeeva Gupta MD Dip NB FRCA FIPP FFPMRCA completed MD from PGIMER, Chandigarh and moved to the UK. After completing FRCA from London, he trained in Oxford and later in Cambridge where he did his pain training. He has been a Consultant in Pain Medicine at the Bradford Teaching Hospitals, NHS Foundation Trust, UK for over 21 years. He has organized, chaired, and presented at national and international meetings. He is an Instructor for the cadaver courses run by the Spinal Intervention Society and is a Fellow of the Intervention Pain Practice (FIPP). His main interests are precision pain diagnosis and management, radiofrequency techniques in pain management, post-surgical persistent pain, CRPS and neuropathic pain. He is an Editor of the following books: *Interventional Pain Management: Practical Approach* (2016); *World Clinics: Pain Management* (2013); *Symptom-oriented Pain Management* (2017) (M/s Jaypee Brothers Medical Publishers, New Delhi, India); *Oxford Specialist Handbook in Pain Medicine: Spinal Interventions in Pain Management* (2012); *Oxford Specialist Handbook in Oncology: Practical Management of Complex Cancer Pain* (2014) (This book won the "BMA Medical Book of the Year Award, 2015), Oxford University Press. Currently, he is an elected Board Member of the Faculty of Pain Medicine of the Royal College of Anaesthetists, London and a Founder and Chair of the North England Pain Medicine Group. He is also the Co-director of the Leeds Cadaver Course for Pain Interventions.

Sanjay Bakshi MD MBA presently co-owns and manages a pain management practice in Florida. Prior to that, he was in private practice in New York. He started his career as an attending physician at Johns Hopkins in Baltimore, where he also completed his Fellowship in Pain Management. He is board certified in Anesthesia and Pain Management. He is actively involved in teaching and has published numerous books and articles in pain management. During his residency, he received the Dripps Award for the outstanding anesthesia resident. His area of expertise is primarily in minimally invasive therapies for the treatment of pain of spinal origin. Other pain management physicians visit him to see his techniques. He is an Instructor for Cadaver Workshops for Pain Management Fellows and Attending Physicians in Pain Management. He has appeared numerous times on television (including Fox 5, ABC, CBS, Ch 7 News) as well as in the press discussing various interventional pain management techniques. He is an Editor of numerous books including *Interventional Pain Management: A Practical Approach* (2009, 2016), and *Symptom-oriented Pain Management* (2017).

RP Gehdoo MD DA completed his DA and MD in 1984 and 1986, respectively from Dr VM Medical College, Solapur, Maharashtra, India. He has been worked as Professor in Anesthesiology in Tata Memorial Hospital, Mumbai. He is presently working as Professor and Head, Department of Anesthesia, Dr DY Patil Medical College, Navi Mumbai. He is Secretary of Indian Society for Study of Pain (An Indian Chapter of IASP) since 2001. He was the Scientific Chairman for all the three Global Update on Pain conferences held in Mumbai in the year 2000, 2003 and 2006. He has about 145 presentations in different national anesthesia and pain conferences. He has been a PG guide for MD and DA courses as well as Examiner for the examinations, since last 12 years. He is the only Indian to represent in the Asia-Pacific Meet held at Cambodia in March 2007 about the Formulations of International Guidelines for the neuropathic pain management. He is one of the Editor of book, *Interventional Pain Management: A Practical Approach* (2009), M/s Jaypee Brothers Medical Publishers, New Delhi, India.

Printed in India

Available at all medical bookstores
or buy online at www.jaypeebrothers.com

JAYPEE BROTHERS
Medical Publishers (P) Ltd.
EMCA House, 23/23-B, Ansari Road,
Daryaganj, New Delhi - 110 002, INDIA
www.jaypeebrothers.com

Join us on facebook.com/JaypeeMedicalPublishers

Shelving Recommendation
ANESTHESIA

ISBN 978-93-5465-547-0