d information on ophthalmology books, visit our website www.jaypeebrothers.com, for detailed information on ophthalmology books, visit our website www.jaypeebrothers.com

**Bestselling Book on the Subject**
**Concise text with all Recent Questions**

diginerve®
A Jaypee Initiative
• Video Lectures • Dr. Wise AI Chatbot
• Question Bank • Notes
Download App

# Self Assessment and Review of
# OPHTHALMOLOGY

**A Must-buy Book for NEET-PG, INI-CET & FMG Exams**

***Concepts based on latest editions of standard textbooks by eminent authors Kanski, Yanoff-Duker, Peyman, Parson and Khurana***

*Image-based Questions on Clinical Cases*

***Includes Golden Points for NEET***

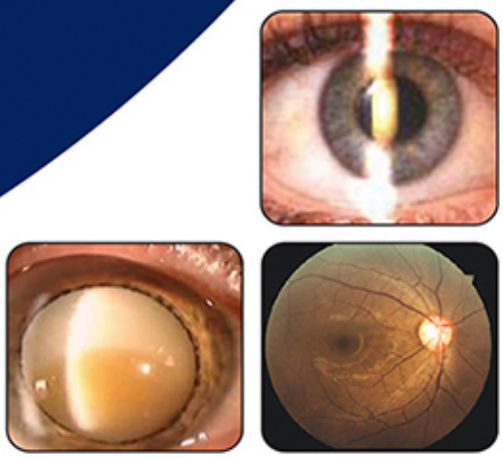

**6th Edition**

**Sudha Seetharam**

JAYPEE

# CONTENTS


| | | |
|---|---|---|
| | *Recent Questions 2020-21* | *xvii–xxviii* |
| 1. | **Ocular Embryology★** | **1** |
| 2. | **Coats of the Eyeball★** | **3** |
| 3. | **Conjunctiva, Sclera and Cornea★★★** | **5** |
| 4. | **Lens★★★** | **36** |
| 5. | **Retina★★★** | **55** |
| 6. | **Uveal Tract★** | **93** |
| 7. | **Optics and Refraction★★** | **105** |
| 8. | **Strabismus★★** | **119** |
| 9. | **Glaucoma★★** | **132** |
| 10. | **Neuro-Ophthalmology★★★** | **154** |
| 11. | **Adnexae and Orbit★★** | **182** |
| 12. | **Assessment of Visual Function★** | **200** |
| 13. | **Ocular Manifestations of Systemic Diseases★** | **204** |
| 14. | **Miscellaneous★** | **205** |


★ Important
★★ Very important
★★★ Extremely important



# 4

# Lens

The lens is a biconvex, transparent crystalline structure which divides the eye into anterior and posterior segments. It is placed in a saucer shaped depression called **patellar fossa**[Q].

- Refractive index: 1.386[Q]
- Refractive power : 14–16 D[Q]
- Equatorial diameter: 10 mm
- It has two surfaces anterior and posterior. **The anterior surface is less convex than the posterior**[Q]**.**
- Radius of curvature:
  - Anterior 10 mm
  - Posterior 6 mm

The lens is made up of

- *Lens capsule*: It is a transparent membrane covering the lens. It is **thickest in the pre-equatorial region**[Q] and **thinnest at the posterior pole**[Q]
- *Lens epithelium*: There is a single layer of epithelium on the anterior surface of the lens but no epithelium on the posterior surface
- *Lens fibres*: These are protein fibres arranged closely in concentric layers. Lens fibres are formed throughout life so that the oldest fibres are at the centre and the newest fibres are most superficial. Hence the lens fibres may be divided into
  - *Nucleus*: It is the central part of the lens containing the older fibres. It is again subdivided into embryonic nucleus (formed in first 3 months of gestation), foetal nucleus (formed till birth), infantile nucleus (formed from birth to puberty), adult nucleus (formed after puberty)
  - *Cortex*: It is the peripheral part containing the newly formed fibres

The lens is suspended from above and below by the ciliary zonules. The attachment of the vitreous to the posterior surface of the lens is called **Weigert's ligament**[Q]**.** The potential space between the lens and vitreous is called **retrolental space of Berger**[Q].

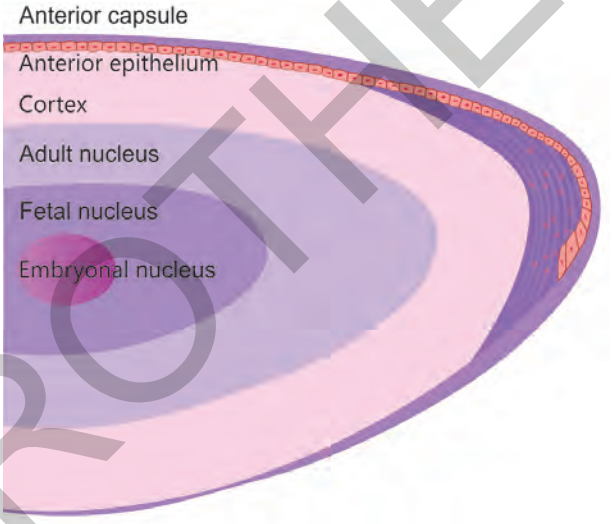


**Fig. 1:** Anatomy of the lens

### Anti-oxidants present in lens

- **Glutathione**[Q]
- **Superoxide dismutase**[Q]
- **Catalase**[Q]
- **Vitamin C**[Q]
- **Vitamin E**[Q]

## CONGENITAL AND DEVELOPMENTAL CATARACT

This is due to disturbance in the growth and development of the lens. Disturbance in development during the period of gestation leads to **congenital cataract** and usually affects the **embryonic or foetal nucleus. Developmental cataract** is due to disturbance in development after birth and hence affects the **infantile or adult nucleus and cortex.** The different morphological varieties are

- *Punctate cataract*: It consists of minute white dots throughout the lens but causes no visual disturbance. It is called **blue dot cataract**[Q]**. It is the most common type of congenital cataract**[Q]

JAYPEE BROTHERS

- *Zonular or lamellar cataract*: **This is the most common type of congenital cataract associated with diminished vision**[Q]. A zone in the foetal nucleus is usually affected. Hypocalcemia in pregnancy is an important cause[Q]
- *Nuclear cataract*: This usually affects the **embryonic nucleus. Rubella in pregnancy is an important cause**[Q]
- *Coronary cataract*: It usually occurs around puberty and is characterized by opacities in the periphery of the lens
- Anterior polar cataract
- Posterior polar cataract

## Senile Cataract

**It is the most common type of acquired cataract**[Q]. The different morphological types are

### Nuclear cataract

- This is an age-related increase in the refractive index of the lens nucleus.
- It causes a myopic shift in refraction known as **index myopia**[Q]
- Improvement of near vision occurs as a result of myopic shift in refraction. This is called second **sight of old age**[Q].
- The main mechanism of formation of nuclear cataract is **conversion of the soluble crystallins to insoluble crystalloids**[Q].

#### *Cortical Cataract*

- The main mechanism of formation of cortical cataract is decrease in concentration of proteins and amino acids and increase in sodium with associated hydration of the lens.
- In cuneiform cataract, there are wedge shaped cortical opacities in the peripheral portion of the lens. Hence it leads to **visual difficulty in dim light when the pupil is dilated**[Q].
- In cupuliform cataract, opacification is seen in the posterior cortex just below the capsule in the centre of the visual axis

#### *Subcapsular Cataract*

- It is usually seen beneath the posterior capsule at the posterior pole. As it lies just at the centre of the visual axis, it is the **most visually significant cataract**[Q].
- It causes **difficulty in vision in bright light**[Q] and for **near work**[Q].
- **Glare is common**[Q]

#### *Mature Cataract*

When the entire lens has become opacified, it is called mature cataract. **Pearly white**[Q] **appearance with absence of iris shadow**[Q] **is seen**. If not operated, it progresses to hypermature cataract.

### Hypermature cataract

It has two varieties

- *Sclerotic cataract*: The lens becomes shrunken and small with calcification on the anterior capsule. There is wrinkling of the lens capsule. It predisposes to **subluxation of lens**[Q]
- *Morgagnian cataract*: There is total liquefaction of the cortex as a result of which the nucleus sinks inferiorly. The liquefied cortex leaks through the intact capsule and blocks the trabecular meshwork. This leads to **phacolytic glaucoma**[Q] **or lens protein glaucoma**. It also causes **phacoanaphylactic uveitis**[Q]

#### *Intumescent Cataract*

This means a swollen cataract due to excessive hydration. The swollen lens pushes the iris forward leading to closure of the angle. This is called as **phacomorphic glaucoma**[Q].

## Traumatic Cataract

It may be seen in different types of injury like:

- *Penetrating injuries as a result of direct injury to the lens*: It is usually **anterior subcapsular or anterior polar cataract**[Q]**.**
- *Blunt trauma or concussion injuries*: Due to the impact of the trauma, the iris diaphragm moves backward and touches the lens capsule. As a result, the iris pigments form a ring on the anterior capsule called as **Vossius Ring**[Q]. The typical cataract is called **rosette cataract**[Q]
- Thermal injury
- Electrical and radiation injury

JAYPEE BROTHERS

## Metabolic Cataract

| | Type of cataract | Cause | Associated features |
|---|---|---|---|
| **Diabetes Mellitus** | **Snowflake cataract**[Q] | Osmotic overhydration<br>Excess glucose is converted to **sorbitol** by the enzyme **aldose reductase**[Q] | **Fluctuation in refractive error is a sign of changing lens hydration**[Q] |
| Galactosemia | **Oil droplet cataract**[Q] | Accumulation of galactose due to deficiency of enzyme Galactose1-P-uridyl transferase | **Reversible cataract**[Q]<br>Disappears when galactose is removed from the diet |
| Fabry's disease | Spoke –wheel like opacities | | |
| **Wilson's disease** | **Sunflower cataract**[Q] | Deficiency of α-2 globulin ceruloplasmin leading to inadequate Cu binding and deposition of Cu in tissues | **Kayser –Fleischer ring (KF)**[Q]<br>Sunflower cataract is also called **pseudo cataract** because it does not cause visual impairment |
| **Lowe's (oculocerebrorenal) syndrome** | Cataract with **posterior lenticonus**[Q] | Inborn error of metabolism | **Microspherophakia**<br>Associated with mental retardation, renal dysfunction, osteomalacia, muscular hypotony, frontal prominence |
| Hypocalcemia | Spokes or riders in the lens | | |

### Toxic Cataract

The drugs causing toxic cataract are:

- *Corticosteroids*: Steroids by systemic route of administration[Q] may lead to toxic cataract. The typical morphology is **posterior subcapsular cataract**[Q]
- Chloroquine
- *Chlorpromazine:* It causes **star shaped or stellate cataract**
- Miotics may cause **anterior subcapsular cataract**
- **Amiodarone**[Q] may cause **anterior subcapsular cataract**[Q]
- INH and Ethambutol
- Smoking

## Complicated Cataract

This name is given to cataract arising due to inflammatory or degenerative diseases of the eye. It is usually **posterior subcapsular cataract**[Q]. It has a typical **bread crumb appearance**[Q] with **polychromatic lustre**[Q]**.** The causes are

- Anterior, intermediate or posterior uveitis
- Retinitis Pigmentosa[Q]
- High Myopia[Q]
- *Angle closure glaucoma*: This is typically **anterior subcapsular cataract**[Q] and is known as **glaucomflecken**[Q]
- Intraocular tumours

## Presenile Cataract

The different conditions associated with presenile cataract are:

- *Myotonic Dystrophy*: The typical cataract is **Christmas Tree Cataract**[Q].
- *Syndermatotic cataract*: It is associated with skin disorders like atopic dermatitis, icthyosis and psoriasis
- **Down's syndrome**[Q]
- Werner's syndrome
- **Neurofibromatosis**

## CLINICAL FEATURES OF CATARACT

- Gradually progressive decrease in vision
- *Glare and coloured haloes*: Coloured haloes are also seen in **mucopurulent conjunctivitis** and **acute angle closure glaucoma.** In conjunctivitis, the haloes disappear on washing the eye. For differentiating haloes of cataract and glaucoma, **Fincham's test**[Q] was used. On holding a stenopaeic slit in front of the eye, the haloes due to cataract will break but the haloes due to glaucoma will remain intact.
- *Monocular diplopia*: This is more common in intumescent cataract.

## MANAGEMENT OF CATARACT

The treatment of cataract is cataract surgery. Cataract surgery has evolved over decades to the highest level

JAYPEE BROTHERS

of predictability and precision today. **The incision in modern day cataract surgery is very small with the benefit of no suture[Q], minimum postoperative astigmatism[Q] and quick visual recovery. The intraocular lenses implanted today after cataract surgery are foldable, can be implanted through a very small incision and provide visual quality similar to the natural lens.**

## Preoperative evaluation of cataract patient[Q]

- *Systemic evaluation*: Diabetes, hypertension, heart disease, lung disease, infections
- *Visual acuity and refraction:* In case of advanced cataract where visual acuity is very poor, **perception of light and projection of rays[Q]** should be assessed. This gives a rough idea about the retina and optic nerve function.
- *Colour vision*: To assess the optic nerve
- *Tests for macular function like* ***Potential Acuity Meter (PAM)*****:** This is used to predict postoperative visual acuity in patients with advanced cataract
- **IOP evaluation by Tonometry[Q]**
- Gonioscopy is done if IOP is high
- **Pupillary reaction**
- Tests for stereoacuity
- Anterior segment evaluation on slit lamp
- *Fundus evaluation:* 90D lens, Direct and Indirect Ophthalmoscope
- **Syringing** to check for patency of the lacrimal drainage pathway
- **USG B-Scan** to assess the posterior segment in advanced cataract where fundus cannot be evaluated clinically.
- *Optical Coherence Tomography (OCT):* to assess the macula in case of any pathology
- **Keratometry and Axial length** to calculate IOL power. Axial length is measured by **A-Scan** biometry.

The different types of cataract surgery are:

- *Intracapsular cataract extraction (ICCE)*: In this technique, the lens along with the capsular bag is removed through a large incision. **The only indication of ICCE today would be subluxated lens[Q].** Intraocular lens has to be iris-fixated, sclera fixated or placed in the anterior chamber.
- *Extracapsular cataract extraction (ECCE)*: In this technique, the lens is removed in toto by making an opening in the anterior capsule. As a result a large limbal incision of 8–9 mm is needed. The capsular bag with an opening in the anterior capsule is left after removal of the lens. **The IOL is placed in the capsular bag[Q]**
- *Small incision cataract surgery (SICS)*: The technique is almost similar to ECCE but a corneoscleral tunnel of 6–7 mm is made instead of a limbal incision
- *Phacoemulsification*: In this technique, the lens is emulsified and aspirated by an ultrasound probe after making a circular opening (capsulorrhexis) in the anterior capsule. So the incision is small, just enough to permit the entry of the probe **(2.8–3.2 mm)[Q]**. **A foldable IOL is implanted in the capsular bag[Q]**

## The steps of Phacoemulsification surgery are

- Wound construction
- Entry into anterior chamber
- Anterior capsulorrhexis (a circular opening is made in the anterior capsule of the lens)
- Hydrodissection (This means injecting fluid beneath the capsule to separate the lens from the capsule. Hydrodelineation is a type of controlled hydrodissection done in posterior polar cataract)
- Phacoemulsification of the lens
- Cortical wash
- IOL implantation
- Wound closure by hydration

- *Micro incision cataract surgery (MICS)*: This is similar to conventional phacoemulsification but the incision is even smaller **(2.2–2.4 mm)**
- *Femtosecond laser assisted cataract surgery[Q]*: This is the most recent advancement in the field of cataract surgery. Femtosecond laser is an **ultra short** pulse laser **($10^{-15}$ seconds)** which has a variety of application in ophthalmic practice. In cataract surgery, Femtosecond laser is used to create the **corneal incision[Q]**, **capsulorrhexis[Q]** and **fragmentation of lens nucleus[Q]**. It may also be used to correct astigmatism by **astigmatic keratotomy[Q].**

## IOL Power Calculation Formulae

- **SRK-II** formula[Q]: This is used for emmetropic eyes (Axial length 22–25 mm). The formula states
- **P = A-2.5L–0.9K** (A = constant, L = Axial length, K = keratometry)
- **Hoffer[Q]** formula: This is used for hypermetropic eyes. (Axial length < 22 mm)
- **SRK-T** formula: This is used for myopic eyes. (Axial length > 25 mm)
- **Haigis/Holladay II** formula: These are used in post-refractive surgery cases

JAYPEE BROTHERS

## Types of Intraocular Lenses

The different types of IOL are:

- *Non-foldable lenses*: These are usually made up of **Polymethylmethacrylate (PMMA)[Q].** They are posterior chamber IOLs, anterior chamber IOLs, iris-fixated IOLs and scleral fixated IOLs
- *Foldable lenses*: These are made up of **Acrylic[Q] (hydrophobic or hydrophilic)** and hydrogels. They are all posterior chamber IOLs which are placed in the capsular bag.

### Types of Foldable IOL

- *Monofocal IOL*: These provide good distance vision but glasses have to be used for near. (Since accommodation is lost after pseudophakia)
- *Multifocal IOL*: These IOLs have separate zones which focus for distance and near. So they provide good vision both for distance and near without glasses. **The main disadvantage is glare and haloes[Q]**
- *Accommodative IOL*: These lenses can move in the capsular bag during accommodation to provide good vision for both distance and near without glasses
- *Toric IOL*: These lenses have a cylindrical power incorporated in them and hence help to correct any associated **corneal astigmatism[Q]**. They may be multifocal or monofocal.

## Complications of Cataract Surgery

The complications related to surgery are

- **Posterior capsular tear with nucleus drop[Q]**
- Vitreous loss
- **Retinal detachment[Q]**
- Postoperative uveitis
- Toxic anterior segment syndrome (TASS)
- Cystoid macular oedema[Q]
- Striate keratopathy
- Pseudophakic bullous keratopathy due to endothelial decompensation

### Complications related to IOL

- *Malposition of IOL*: The IOL may be decentred , subluxated or dislocated leading to
  - *Sunset syndrome[Q]*: Subluxated inferiorly
  - Sunrise syndrome: Subluxated superiorly
  - Windshield wiper syndrome: Lens keeps moving with movement of head
- *Posterior capsule opacification (PCO)[Q]*: The posterior capsule behind the lens may opacify months or years after cataract surgery leading to visual impairment.
  - Morphological types are **Elschnig's pearls[Q]** and **Sommering's ring[Q]**.
  - Treatment is **Nd: YAG capsulotomy**

### Endophthalmitis[Q]

This is the most dreaded and worst possible complication of cataract surgery. **It is a suppurative inflammation starting from the vitreous which extends to all the parts of the eye except the sclera[Q].** If the sclera also becomes involved, the condition is then called as **panophthalmitis[Q].** Post-operative endophthalmitis has the following features

- *Early onset (within 7 days of surgery)*: The most common causative organism is **Staphylococcus epidermidis**
- *Late onset*: The most common causative organisms are **fungi and Propionibacterium acne[Q]**
- Prevention is of utmost importance. The main source of infecting organisms is the patient's own flora. Hence prophylactic topical antibiotics are given 3 days prior to surgery. **Irrigation of the conjunctival cul-de- sac with povidone iodine prior to surgery is a must[Q].**
- Post operative topical antibiotics are given for 1-2 weeks
- The patient presents with sudden onset, pain, redness and decrease in vision. Exudates are seen in the vitreous on examination
- Treatment is **intravitreal tap and intravitreal antibiotics**. If the patient does not improve, **pars plana vitrectomy[Q]** is done
- Treatment of panophthalmitis is **evisceration[Q]**

## MANAGEMENT OF CATARACT IN CHILDREN

- Cataract in children is an important cause for development of **stimulus deprivation amblyopia[Q]**
- **Unilateral cataract is more dangerous than bilateral cataract because the risk of amblyopia is more**
- The ideal age for cataract surgery in children is **4–6 weeks[Q]** because 6 weeks is the critical period for visual maturation in children. Thus early surgery decreases the possibility of amblyopia
- *IOL power selection in children*: In very small children, it is extremely difficult to calculate the IOL power as the axial length and keratometry values are not accurate. In older children, if IOL power is calculated according to the present axial length, there occurs a **myopic shift** as the child grows older. **Hence undercorrection of IOL power from the calculated value is needed.**
  - In children < 1yr of age, IOL is avoided. Patients are left aphakic and advised postoperative contact lenses. Secondary IOL implantation is planned at a later date when the child is older

JAYPEE BROTHERS

- Between 1–8 years of age, IOL is implanted. The power of the IOL is undercorrected from the calculated value according to the age of the patient.
- Beyond 8 years, IOL power is the same as the calculated value from the formulae.

## ANOMALIES OF LENS POSITION

The lens is located in a saucer shaped depression called the patellar fossa between the anterior and posterior chamber of the eye. A lens in abnormal position since birth is called **Ectopia lentis.** Acquired cases are called **subluxation and dislocation.** Subluxation means that a part of the lens still lies with the patellar fossa. Dislocation means that the lens is completely out of the patellar fossa.

| **Congenital causes** |
|---|
| • Marfan's syndrome[Q] (associated with **superotemporal**[Q] subluxation) |
| • Homocystinuria[Q] (associated with **inferonasal**[Q] subluxation) |
| • Weil Marchesani (microspherophakia with anterior dislocation of lens) |
| • Ehler-Danlos syndrome |
| • Hyperlysinemia |
| • Stickler's disease |

*Contd...*

*Contd...*

| |
|---|
| • Sulphite oxidase deficiency |
| **Acquired causes** |
| • **Trauma (most common)**[Q] |
| • Buphthalmos |
| • Megalocornea |
| • High Myopia |
| • Pseudoexfoliation |
| • Hypermature sclerotic cataract |
| • Chronic uveitis |
| • Endophthalmitis |
| • Intraocular tumours |

**Must Remember**

- *Snowflake cataract:* Diabetes mellitus
- *Sunflower cataract:* Wilson's disease
- *Rosette cataract:* Blunt trauma
- *Oil droplet cataract:* Galactosemia
- *Polychromatic lustre:* Complicated cataract
- *Christmas tree cataract:* Myotonic dystrophy

JAYPEE BROTHERS

# QUESTIONS

## Anatomy and Physiology of Lens

**1. The capsule of the crystalline lens is thinnest at:** *(UPPG)*

a. Arterior pole b. Posterior pole
c. Equator d. None

**2. Ascorbate and Alpha Tochopherol are maintained in the lens in reduced state by:** *(AIIMS 2014)*

a. Glucose b. Glycoprotein
c. Glutathione d. Fatty acids

**3. Which of the following does not handle free radicals in the lens?** *(AIPG)*

a. Vitamin A b. Vitamin C
c. Vitamin E d. Catalase

**4. The crystalline lens derives its nutrition from:** *(AIIMS)*

a. Blood vessels b. Connective tissue
c. Aqueous and vitreous d. Capsule of the lens

**5. Transport of ascorbic acid in the lens is done by:** *(AIPG)*

a. Myoinositol b. Choline
c. Taurine d. Na-K ATPase

**6. Ligament of Weigert is:** *(APPG)*

a. Attachment of the vitreous to the posterior capsule of the lens
b. Medial palpebral ligament
c. Attachment of the superior oblique tendon
d. Associated with the middle ear

**7. Zonules suspending the lens are attached to:** *(DNB 2015)*

a. Root of iris b. Ciliary body
c. Limbus d. Vitreous

## Anomalies of Lens Position

**8. Position of the lens in Marfan's syndrome is:** *(COMEDK)*

a. Superior b. Superotemporal
c. Inferior d. Nasal

**9. Typical bilateral inferonasal subluxation of lens is seen in:** *(DNB)*

a. Marfan's syndrome b. Homocystinuria
c. Hyperlysinemia d. Trauma

**10. Ectopia lentis is seen in:** *(PGI)*

a. Marfan's syndrome
b. Congenital rubella
c. Homocystinuria
d. Sulphite oxidase deficiency
e. Myotonic dystrophy

**11. Anterior lenticonus is seen in:** *(AIPG)*

a. Alport's syndrome b. Lowe's syndrome
c. Down's syndrome d. William's syndrome

**12. Spontaneous absorption of lens material is seen in :** *(COMEDK)*

a. Marfan's syndrome
b. Hallerman Streiff syndrome
c. Aniridia
d. Persistent hyperplastic primary vitreous(PHPV)

## Cataract

**13. Phacodonesis is seen in all except:** *(NEET 2016)*

a. Trauma b. Hypermature cataract
c. Pseudoexfoliation d. Diabetes mellitus

**14. Gene commonly indicated in congenital cataract:** *(AIIMS 2014)*

a. PAX-6 b. CRYGS- 3
c. LMX-1B d. PITX-3

**15. Most common type of congenital cataract is:** *(AIIMS)*

a. Capsular b. Zonular
c. Cupuliform d. Blue dot

**16. Most common congenital cataract associated with decreased vision:** *(AIIMS)*

a. Blue dot b. Cupuliform
c. Zonular d. Coronary

**17. Rider's are seen in:** *(AIPG)*

a. Blue dot cataract b. Zonular cataract
c. Sutural cataract d. Coronary cataract

**18. Commonest type of cataract:** *(PGI)*

a. Hereditary b. Trauma
c. Diabetes d. Age related
e. Radiation

**19. Which of the following is true regarding concentration of proteins in senile cataract?** *(AIIMS 2013)*

a. More insoluble protein, less soluble protein
b. More soluble protein, less insoluble protein
c. Equal concentration of soluble and insoluble protein
d. None of the above

**20. High molecular weight protein present in cataractous lens in humans:** *(AIIMS 2015)*

a. HM 1 and HM 2 b. HM 2 and HM 3
c. HM 3 and HM 4 d. HM 4 and HM 1

**21. Most visually significant cataract:** *(AIIMS)*

a. Nuclear cataract
b. Cortical cataract
c. Posterior subcapsular cataract
d. Zonular cataract

**22. Second sight phenomenon is seen in:** *(TNPG)*

a. Nuclear cataract
b. Cortical cataract
c. Posterior subcapsular cataract
d. Mature cataract

**23. Index myopia is seen in:** *(DNB)*

a. Nuclear cataract
b. Cortical cataract
c. Mature cataract
d. Posterior subcapsular cataract

JAYPEE BROTHERS

# IMAGE BASED QUESTIONS

**1. The lens in the photograph shows a typical type of cataract. What history should be elicited from the patient?**

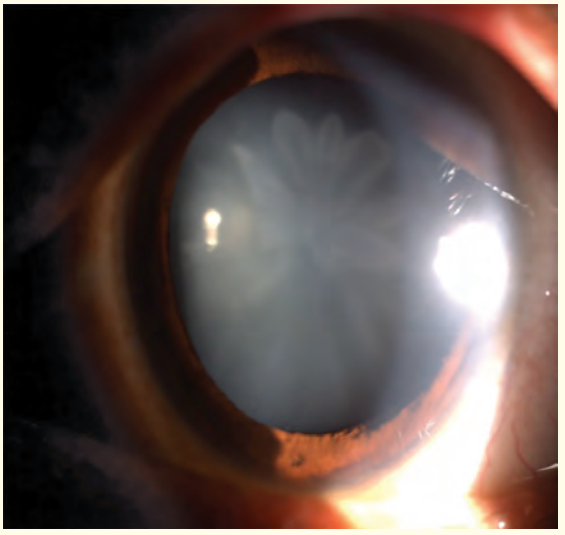

a. Diabetes mellitus
b. Trauma
c. Steroid use
d. History of using glasses

**2. What is the most common complication associated with the condition shown in the clinical photograph?**



a. Phacomorphic glaucoma
b. Phacolytic glaucoma
c. Endophthalmitis
d. Angle closure glaucoma

**3. What is the condition associated with the cataract shown in the photograph?**

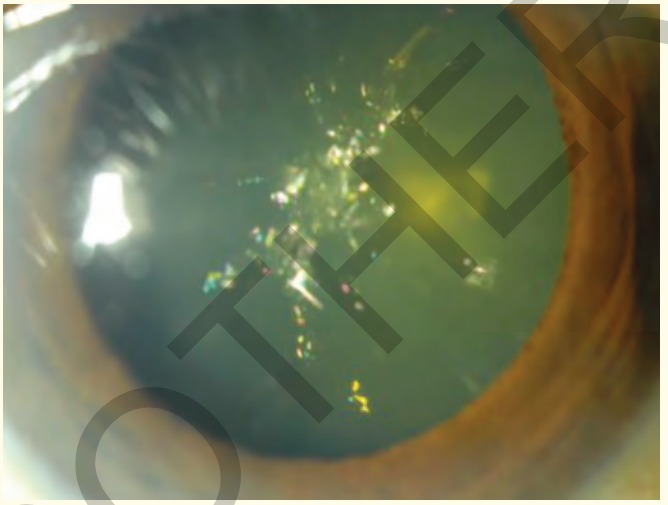

a. Wilson's disease
b. Galactosemia
c. Myotonic dystrophy
d. Down's syndrome

**4. This is the anterior segment photograph of a patient who has history of cataract surgery with IOL done many years ago. He came with complaints of decrease in vision in the pseudophakic eye. What is the diagnosis?**

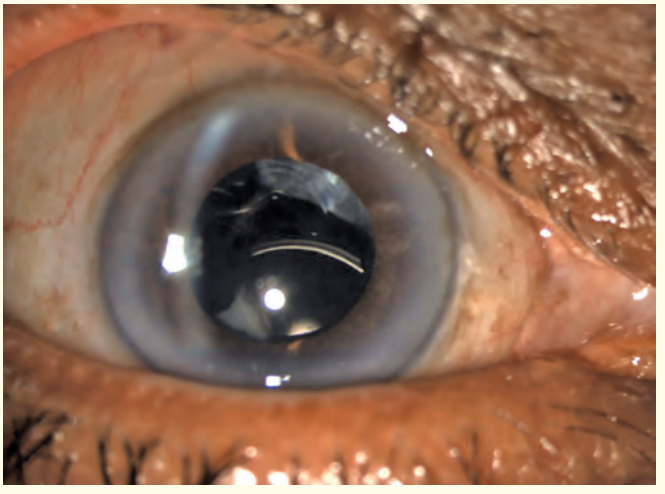

a. Sunrise syndrome
b. Sunset syndrome
c. Dislocated IOL
d. Windshield wiper syndrome

**Answer Key:** 1. b 2. b 3. c 4. b

JAYPEE BROTHERS

**5. The clinical photograph shows cataract with a certain associated condition. All of the following may be strongly associated with this patient except:**

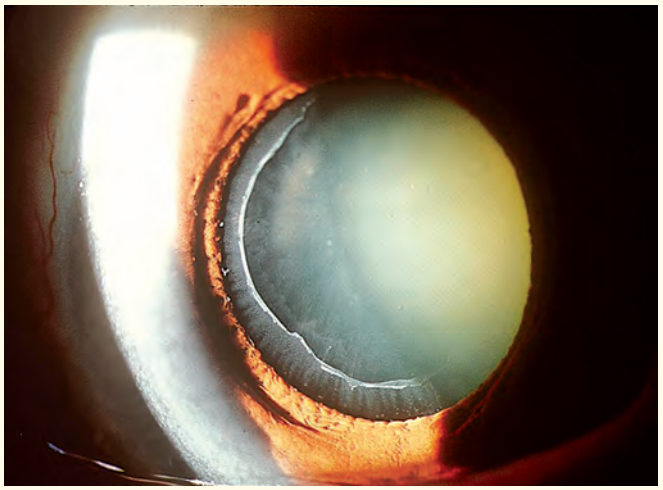

a. Weak zonules
b. Poorly dilating pupil
c. Angle closure glaucoma
d. Subluxation of the capsular bag

**6. A patient presents with the cataract shown in the photograph. What is the most likely complain of the patient?**

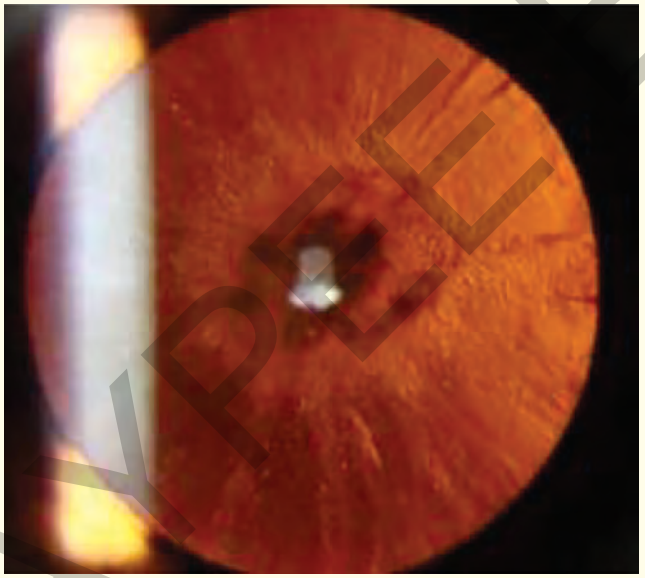

a. Difficulty in vision in bright light
b. Difficulty in vision in dim light
c. Double vision
d. Difficulty in vision in upgaze

**7. A patients presents with severe pain, redness and decrease in vision within 3 days of uneventful cataract surgery. The clinical photograph is given. Fundal glow is not visible. What is the possible diagnosis?**

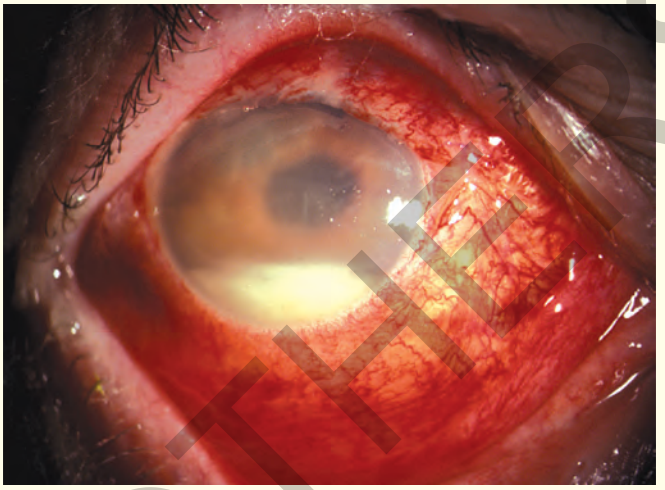

a. Dislocated IOL
b. Endophthalmitis
c. Vitreous haemorrhage
d. Retinal detachment

**8. A patients presents with diminution of vision about 1 year after cataract surgery. From the clinical picture below, identify the diagnosis.** *(May AIIMS 2017)*

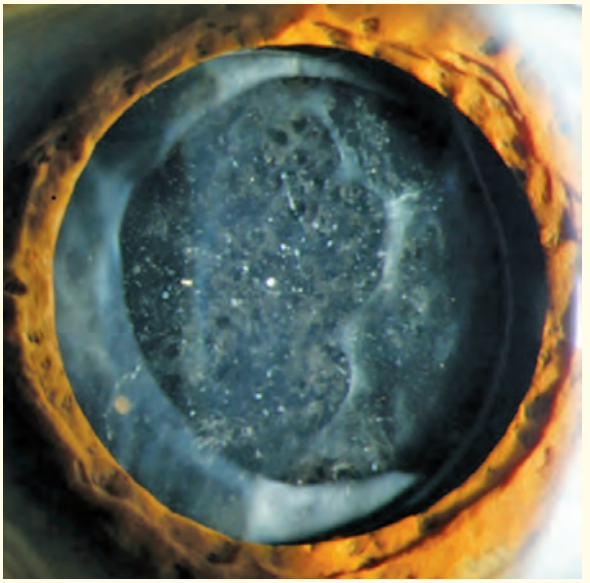

a. Irvine Gass syndrome
b. UGH syndrome
c. After cataract
d. Endophthalmitis

**Answer Key:** **5. c** **6. a** **7. b** **8. c**

JAYPEE BROTHERS

# ANSWERS AND EXPLANATIONS

**1. Answer: b. Trauma** *(Ref: Yanoff & Duker 4th edition p 415)*

The typical cataract seen in the picture is rosette cataract (looks like petals of a flower). Hence the relevant history is that of blunt trauma.

**2. Answer: b. Phacolytic glaucoma**

The photograph shows **hypermature morgagnian cataract** (sunken nucleus with liquefied cortex). The most common complication associated with this **is phacolytic glaucoma.**

**3. Answer: c. Myotonic dystrophy**

*(Ref: Peyman's Principles and Practice of Ophthalmology 2nd edition, p 184-85)*

This is a classical picture of Christmas tree cataract seen in Myotonic dystrophy.

**4. Answer: b. Sunset syndrome**

*(Ref: Yanoff & Duker 4th edition p 401)*

In the photograph it can be seen that the IOL is decentred inferiorly. This is called sunset syndrome.

**5. Answer: c. Angle closure glaucoma**

*(Ref: Peyman's Principles and Practice of Ophthalmology 2nd edition, p 714-15)*

The photograph shows cataract with a white ring on the anterior lens capsule. This white ring is caused by deposition of a fibrillar extracellular material. This condition is called **Pseudoexfoliation syndrome (PXF)**Q

The features of PXF syndrome are:

- Deposition of white flaky fibrillar material in different anterior segment structures like lens capsule, zonules, pupillary margin, iris tissue, angle of anterior chamber
- Weak zonules leading to subluxation of capsular bag during cataract surgery or in late postoperative period
- Poorly dilating pupil
- Secondary glaucoma due to deposition of PXF material in the angle. It is a type of secondary **open angle glaucoma.**

**6. Answer: a. Difficulty in vision in bright light**

*(Ref: Peyman's Principles and Practice of Ophthalmology 2nd edition, p 684-89)*

The picture shows central posterior subcapsular cataract which cause maximum visual disability when the pupil is constricted such as in bright light and near work.

**7. Answer: b. Endophthalmitis**

*(Ref: Peyman's Principles and Practice of Ophthalmology 2nd edition, p 1042-43)*

The clinical photograph shows congestion, corneal oedema with pus in the anterior chamber (hypopyon). This, with associated finding of absent fundal glow points to the possibility of exudates in the vitreous. Hence the diagnosis is endophthalmitis.

The diagnosis is confirmed by USG B-Scan which shows dense vitreous echoes suggestive of vitreous exudates (indicated by arrow)

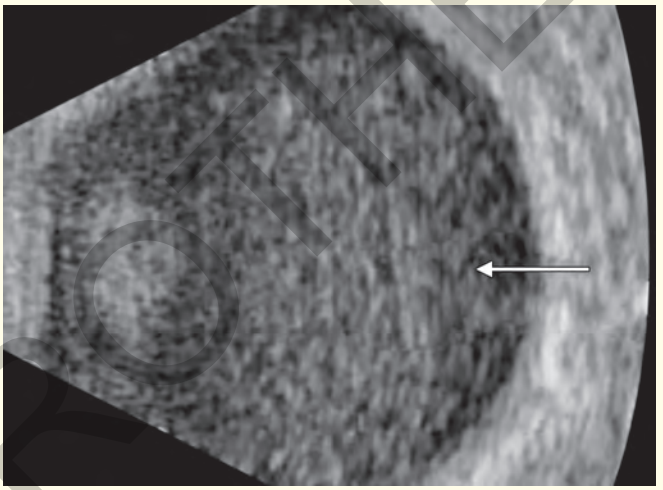

**8. Answer: c. After cataract**

*(Ref: Kanski 8th edition p 293)*

After cataract or posterior capsule opacification (PCO) is the **most common late complication of cataract surgery**Q. It is caused by migration of the lens epithelial cells that have remained in the capsular bag after cataract extraction. Treatment is creation of an opening in the posterior capsule, known as **capsulotomy** with **Nd: YAG laser**Q

**9. Answer: b. $10^{-15}$**

*(Ref: Yanoff & Duker 4th edition p 375-376)*

**Femtosecond l**aser is an infrared laser with a wavelength of **1053nm**Q and an ultra-short pulse duration of **$10^{-15}$ seconds (Femtosecond).** The main advantage of this ultra-short pulse is that the collateral damage to the tissues surrounding the target tissue is minimal. The applications of Femtosecond laser are

- Femtosecond laser assisted cataract surgery where the laser is used for creating the incision, capsulorrhexis and fragmentation of the nucleus
- Corneal refractive surgery: The important procedures are **Femtosecond Lenticule Extraction (FLEx)**, **Small Incision Lenticule Extraction (SMILE),** Intrastromal corneal ring segment (ICRS) implantation.

JAYPEE BROTHERS

for detailed information on ophthalmology books, visit our website www.jaypeebrothers.com, for detailed information on ophthalmology books, visit our website www.jaypeebr

# Self Assessment and Review of OPHTHALMOLOGY

***Salient Features***

- Concise text referenced from Clinical Ophthalmology: Kanski, Ophthalmology: Yanoff and Duker and the new revised edition of Peyman's Principles and Practice of Ophthalmology
- Important points to remember highlighted with superscript Q
- Illustrative diagrams provided for better understanding of concepts
- Image-based questions at the end of each chapter with key points for identification of the images
- Clinical case scenario-based questions included at the end of each chapter
- Collection of representative recent MCQs from NEET/AIIMS/AIPG/PGI/COMEDK/DNB.

**Sudha Seetharam** MBBS MS (Ophthal) completed her MBBS from Medical College, Kolkata and MS (Ophthalmology) from the prestigious Guru Nanak Eye Centre, Maulana Azad Medical College in New Delhi. Presently, she is working as a consultant at Laxmi Eye Institute, Navi Mumbai. She is an astute clinician and keen academician with presentations at many national and international conferences including the American Academy of Ophthalmology. Teaching is her passion and she has been involved in teaching since her days as a postgraduate trainee. Her lectures in Ophthalmology aimed at preparing for postgraduate medical entrance have been widely appreciated by students all over the country. This book which combines her clinical knowledge, research acumen and flair for MCQs promises to be greatly useful for PG aspirants, MBBS students and Ophthalmology PG residents.

She can be reached at dr.sudha.ophthalmology@gmail.com

*Printed in India*

**Available at all medical bookstores or buy online at www.ejaypee.com**

**JAYPEE BROTHERS**
**Medical Publishers (P) Ltd.**
**EMCA House, 23/23-B, Ansari Road,**
**Daryaganj, New Delhi - 110 002, INDIA**
**www.jaypeebrothers.com**

Join us on facebook.com/JaypeeMedicalPublishers
Follow us on instagram.com/JaypeeMedicalPublishers

Shelving Recommendation
**OPHTHALMOLOGY**

ISBN 978-93-5465-552-4