eebrothers.com, for detailed information on orthopedics books, visit our website www.jaypeebrothers.com, for detailed information on orthopedics book

Clinical Assessment and Examination in ORTHOPEDICS

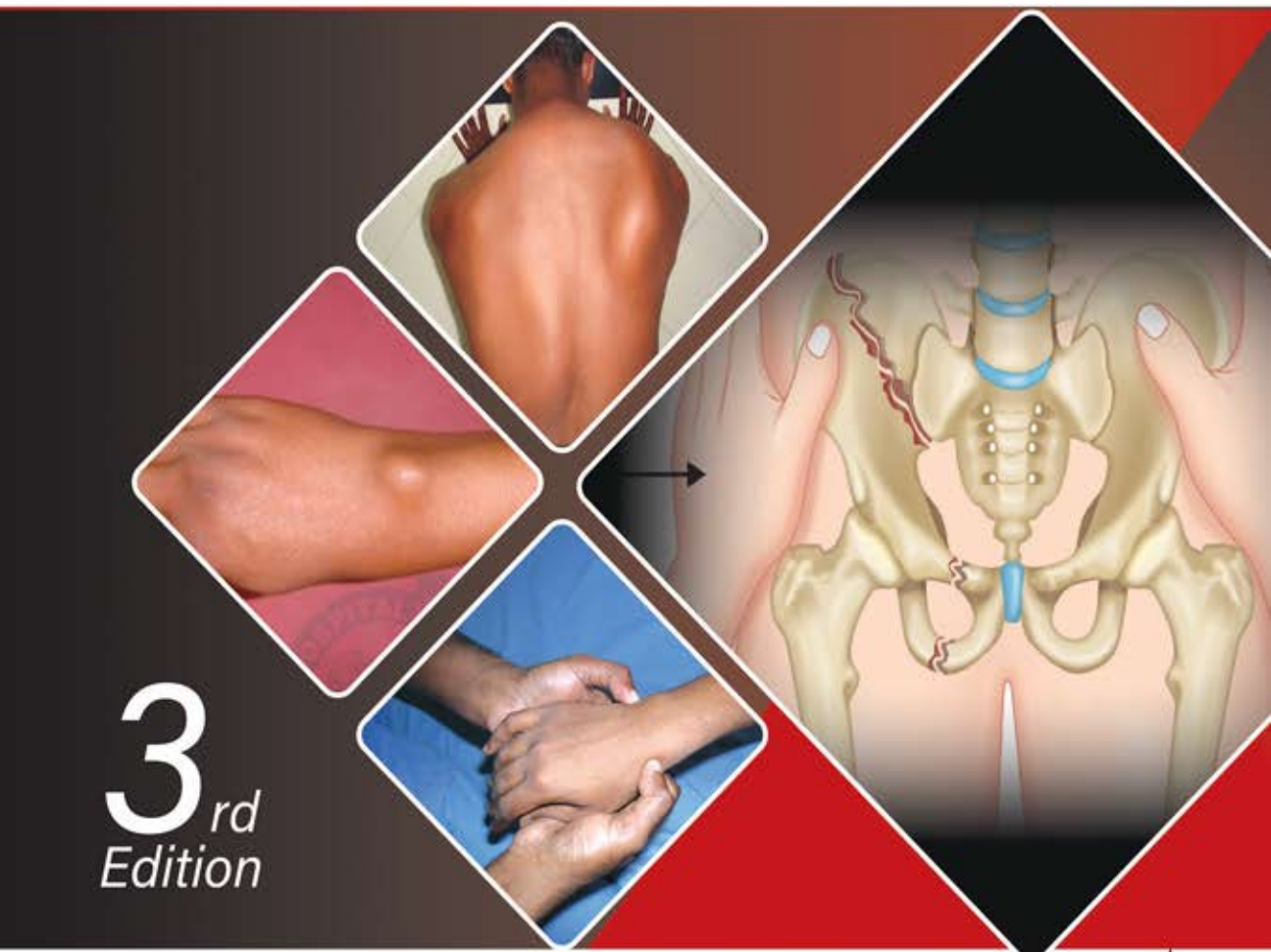

3rd Edition

C Rex

Forewords
S Rajasekaran
Charles SB Galasko

JAYPEE

Clinical Assessment and Examination in Orthopedics

Third Edition

C Rex
MS (Ortho) DNB (Ortho) FRCS (Edin)
FRCS (Trauma and Ortho)
MCh (Ortho) Liverpool PhD DSc (Ortho)
Chief Consultant Orthopedic and
Trauma Surgeon
Head of Department of Orthopedics
Rex Ortho Hospital
Coimbatore, Tamil Nadu, India

Forewords
S Rajasekaran
Charles SB Galasko

JAYPEE BROTHERS

JAYPEE BROTHERS MEDICAL PUBLISHERS
The Health Sciences Publisher
New Delhi | London

Contents

1. History Taking and Clinical Examination 1

- History Taking *1*
- Clinical Examination *3*
- Examination of Bone and Joint Infection *6*

2. Examination of an Injured Patient..... 8

- Initial Assessment *9*
- History *24*
- Physical Examination *24*
- Investigations, Tertiary Survey, and Definitive Care *26*
- Special Note *27*

3. Examination of Patient with Bone and Joint Injuries 31

- History *31*
- Examination *32*
- Specific Conditions *34*

4. Examination of Neuromuscular Disease..... 37

- History *37*
- Examination *37*
- Upper Limb *38*
- Lower Limb *38*
- Special Tests *41*
- Special Conditions *41*

5. Examination of Shoulder..... 42

- Understanding the Shoulder: The Shoulder Crane *42*
- History *43*
- Clinical Examination *45*
- Neck Examination *62*
- Neurovascular Examination *62*
- Common Conditions Affecting Shoulder *62*

6. Examination of Elbow..... 65

- Look *66*
- Feel *68*
- Move *70*
- Measure *71*
- Special Tests *72*
- Neurovascular Examination *75*
- Others *75*
- Common Specific Conditions *75*

JAYPEE BROTHERS

7. Examination of Wrist 78

- History *78*
- Clinical Examination *79*
- Assessment of Instability *81*
- Assessment of Dorsal Radial Wrist Pain *85*
- Assessment of Ulnar Wrist Pain *89*
- Assessment of Dorsal Central Wrist Pain *90*
- Assessment of Palmar Ulnar Wrist Pain *91*
- Palmar Radial Wrist Pain *92*
- Assessment of Distal Radioulnar Joint *93*
- Differential Lignocaine Injection Test *93*
- Specific Conditions *93*

8. Examination of Hand 97

- Look *98*
- Feel *99*
- Move *99*
- Specific Conditions *100*
- Examination of the Hand with Lacerations *105*
- Traumatic Amputations and Microsurgery *107*
- Hand Infections *108*

9. Examination of Peripheral Nerves and Brachial Plexus 110

- Look *110*
- Feel *111*
- Move *112*
- Neurological Examination *112*

Examination of Individual Nerves *113*

- Median Nerve *113*
- Ulnar Nerve *115*
- Radial Nerve *117*
- Compression Neuropathy *118*
- Suprascapular Nerve Entrapment *121*
- Brachial Plexus Injury *121*
- Examination of the Brachial Plexus *122*
- Lower Limb Nerve Injury *124*

10. Examination of Spine 125

- Clinical Red Flags in Back Pain *126*
- Thoracolumbar Examination *128*
- Specific Conditions *139*
- Examination of the Cervical Spine *144*
- Specific Conditions *147*

JAYPEE BROTHERS

11. Examination of Hip 150

- Presenting History *150*
- Local Examination *151*
- Patient Standing *152*
- Supine on Couch *153*
- Lateral on Couch *160*
- Prone Examination *160*
- Conditions Affecting Hip *161*
- Sacroiliac Joint Stress Test *166*

12. Examination of Knee 167

- Presenting Complaint *167*
- Local Examination *169*
- Special Tests to Assess Joint Stability *172*
- Patellofemoral Joint Problems *176*
- Special Note *179*

13. Examination of Ankle and Foot 186

- Presenting Complaint *186*
- Past History *188*
- Family History *188*
- Personal History *188*
- Treatment History *188*
- General Examination *188*
- Local Examination *191*
- Specific Conditions *206*

14. Examination of Rotational Deformities in Lower Limb 217

- History *217*
- Examination *217*

15. Imaging Principles 219

Index 221

JAYPEE BROTHERS

CHAPTER 7

Examination of Wrist

INTRODUCTION

Wrist is a composite joint formed by radiocarpal, ulnocarpal, mid-carpal, and distal radioulnar joints. A focused history and well-performed physical examination of the wrist requires knowledge of anatomy and pathology of this area. Wrist joint is a much superficial joint as compared to joints like shoulder and hip with almost no muscles around it. This makes the clinical examination more precise and reliable. In fact most of the anatomical structures, which could be the source of a painful wrist, are amenable for palpation provided one possesses a good knowledge of anatomy and understanding of the examination technique. Based on physical examination, one should be able to make a diagnosis or narrow the differential diagnosis dramatically. This examination is a summation of anatomical locations where symptoms are provoked by palpation and where signs, often with symptoms, are produced by manipulation.

HISTORY

Age, Dominant Hand, and Occupation

It is important to know all the three features because many pathologies have age-related prevalence like de-Quervain's disease, which is more common in middle-aged women. Some occupations may predispose a patient to repeated stress disorder, like vibration instruments. Moreover, these factors also would influence the treatment option selected for a given patient and the postoperative implication for the patient.

Pain

It includes onset, duration, site, nature, at rest or activity-related, aggravating, and relieving factors.

Swelling

It includes onset, duration, site, progression, variation in size, any other swellings, localized or diffuse around the wrist joint, painful or painless, and other history as discussed in Chapter 1.

Stiffness

It includes early morning stiffness, inability to hold things, or perform routine jobs, subjective weakness, and loss of wrist movements.

Limitation of Activities

This must be quantified in terms of daily activities and difficulty in performing jobs, pursuing hobbies and leisure activities. Objective documentation can be done by various patient reported scores available like disability of arm shoulder and hand (DASH) score and Mayo Wrist score.

Neurological Symptoms

These include weakness, numbness, pins and needles, and altered sensation. Radiation of

JAYPEE BROTHERS

the pain to the hand, ulnar or radial side, and proximally gives a clue to a neural cause of pain.

Clicks

This is a snapping sound from carpal instability or tendon subluxation.

Deformity

This is dinner fork deformity **(Fig. 1A)** in Colles' fracture, deformity from malunion or nonunion of distal radius, caput-ulna deformity in rheumatoid arthritis or any congenital deformities **(Fig. 1B)**, etc.

Miscellaneous History

It includes injury, other joint involvement, and constitutional symptoms.

Past history, family history, personal history, and treatment history must be asked in routine way.

What is patient's expectation?

The demands from the wrist and hand should be taken in consideration when offering a treatment option. For instance, reduced grip strength after distal ulna excision may not result in any functional disability for an elderly lady whereas it could considerably upset a young laborer.

CLINICAL EXAMINATION

Expose upper limbs, screen neck, shoulder and elbow for any obvious abnormalities or scars. Positioning the patient in sitting and placing the hand on a table is helpful.

Look

From Front, Back, and Sides

Attitude of the forearm, wrist, and the hand, the shape, swellings, skin color changes, scars, deformities, wasting of small muscles of the hand, pulp atrophy, sweating, and nail changes are noted.

Feel

Ask the patient for most tender spot and examine it in last. Look at the patient's face. Define the anatomical spot for tenderness, most of the time this gives the pathoanatomical diagnosis. It is generally easier to fragment the wrist examination as volar radial; volar ulnar; dorsal radial; dorsal central, and dorsal ulnar. The examiner goes in a sequence and examines each quadrant systematically keeping in mind the underlying structure and hence the probable cause of pain **(Figs. 2A to D)**. This would commonly allow having a

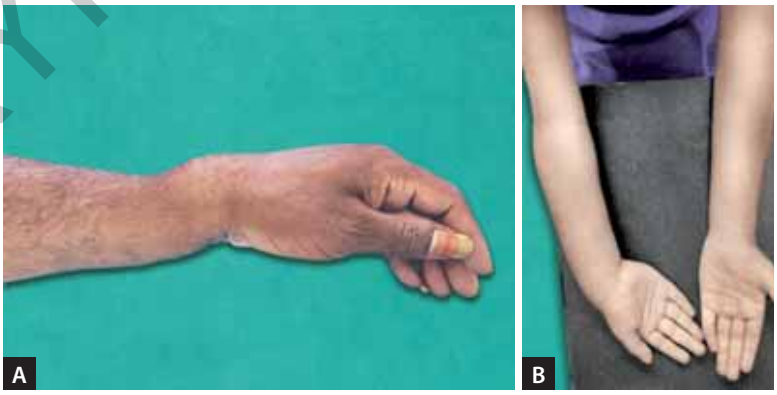

Figs. 1A and B: (A) Dinner fork deformity; (B) Ulnar club hand.

JAYPEE BROTHERS

differential diagnosis, if not the diagnosis itself. The common causes of pain in each quadrant are mentioned in the **Table 1**.

Swellings are examined as discussed in Chapter 1. Feel the tip of styloid processes of radius and ulna. Normally radial styloid is more distal than the ulnar styloid. Put the nail beds of thumb at 90° to the long axis of forearm one at radial styloid and other at ulnar styloid. Comparing the respective levels of these land marks give a clinical measure of ulnar variance **(Fig. 3)**.

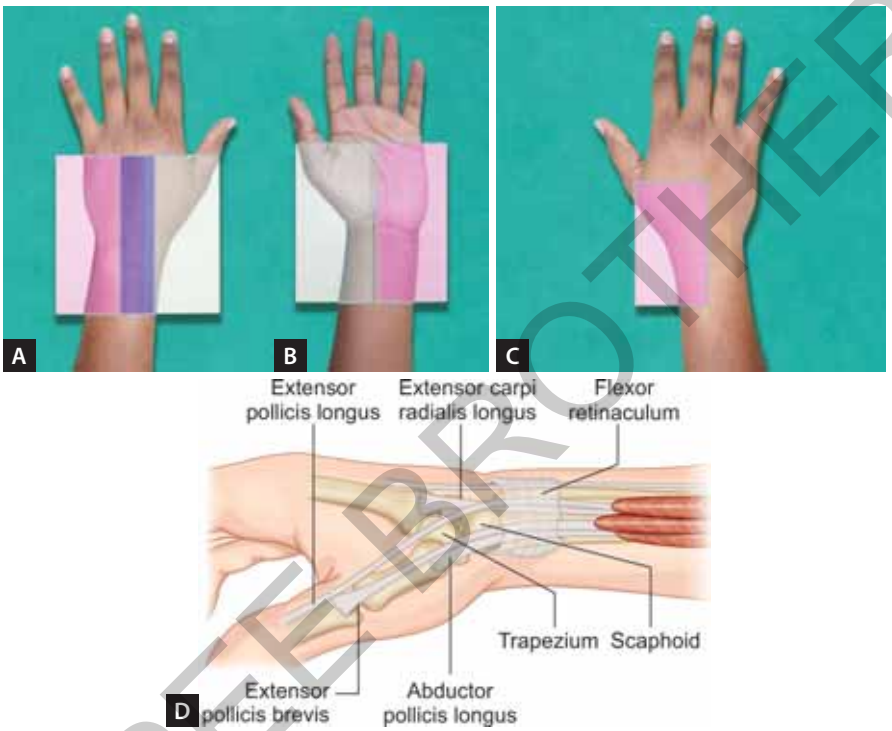

Figs. 2A to D: Localization of pain on dorsomedial, mid-dorsal, dorsolateral, volar radial, and volar ulnar aspect, and respective anatomy underneath.

TABLE 1: Assessment of wrist pain.

	Radial zone	***Central zone***	***Ulnar zone***
Dorsal side of wrist	• De Quervain's syndrome • Intersection syndrome • 1st CMC joint arthritis • Radio-scaphoid arthritis • Chiralgia paresthetica • ECRL/ECRB tendonitis	• Kienbocks disease • Ganglion cyst • Scapholunate dissociation • Extensor tenosynovitis • DRUJ injury	• TFCC injury • Extensor carpi ulnaris tendonitis • Caput-ulna • Ulnar styloid non-union
Volar side of wrist	• Scaphoid fracture/non-union • Volar ganglion • FCR tendonitis	• Carpal tunnel syndrome • Malunited volar barton	• TFCC injury • Ulnar impaction syndrome • Luno-triquetral instability • Pisotriquetral injury • Hook of hamate injury • Guyon's canal compression

JAYPEE BROTHERS



Fig. 3: Palpation of radial and ulnar styloid.

Palpation is an integral part of wrist examination and the examiner must be thorough with the surface bony landmarks to be comfortable in examining the wrist **(Figs. 4A to F)**.

Palpation of the scaphoid tuberosity is important as it is a reference for many clinical tests. It is best palpated by moving radially along the wrist crease at the level of the pisiform to reach a bony prominence, which becomes more prominent on radial deviation whereas becomes less apparent on ulnar deviation. A bony prominence distal to it which is formed by trapezius would rather remain same throughout the wrist deviation movement.

Examine the normal wrist first to identify the degree of laxity.

Move

Active ranges of following movements are assessed:

- Dorsiflexion, palmar flexion, ulnar deviation, radial deviation, supination, and pronation **(Figs. 5A to F)**.
- Full fist formation and full extension.
- Normal range of dorsiflexion is 0–70°, palmar flexion 0–80°, ulnar deviation 0–30°, and radial deviation 0–20°.

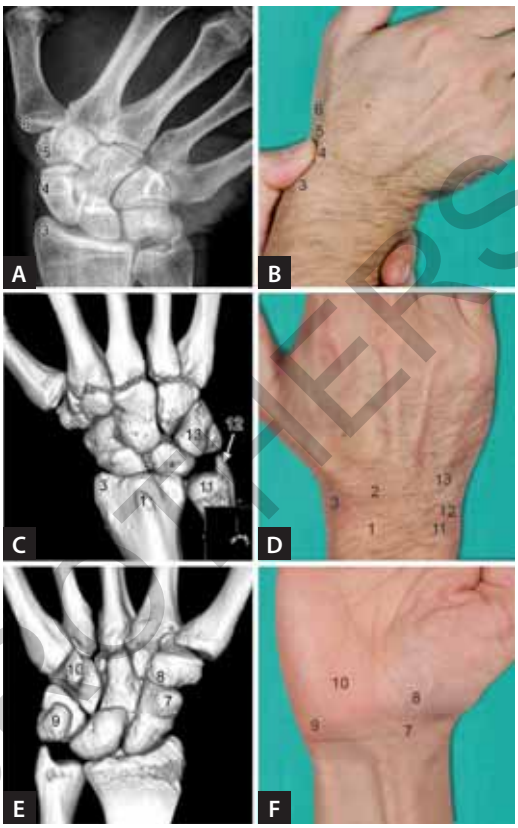

Figs. 4A to F: The anatomical bony landmarks in comparison to 3D-CT reconstruction. 1. Lister's tubercle; 2. Crucifixion fossa at scapholunate junction; 3. Radial styloid process; 4. Waist of scaphoid; 5. Trapezium; 6. Base of 1st metacarpal; 7. Tubercle of scaphoid; 8. Tubercle of trapezium; 9. Pisiform; 10. Hook of hamate; 11. Head of ulna; 12. Ulnar styloid process; 13. Triquetrum.

- Fixed deformities must be noted and assessed to know whether the deformity is same in all positions of adjacent joints.

ASSESSMENT OF INSTABILITY

Pseudostability Test (Modified Fisk's Forward Shift Test) (Fig. 6)

Firmly grip on distal forearm and with other hand grasp the carpometacarpal (CMC) joints. Patient must be very relaxed and the hand is pressed firmly palmarward. The wrist

JAYPEE BROTHERS



Figs. 5A to F: (A) Testing dorsiflexion; (B) Palmar flexion; (C) Radial deviation; (D) Ulnar deviation; (E) Supination; (F) Pronation.

JAYPEE BROTHERS

should be in neutral position. Assess the laxity by comparing with the normal side. Normally, there must be palmar translation and if there is any acute pathology in the wrist this normal translation will not happen due to spasm of muscles.

Scapholunate Instability

Kirk Watson's Test (Scaphoid Shift Test) (Fig. 7)

Scaphoid shift is a provocative maneuver rather than a test, because it does not offer a

simple positive or negative result, but rather a variety of findings, with emphasis being on asymmetry on bilateral examination. The maneuver is performed starting with the wrist in slight extension and full ulnar deviation. The examiner grasps the wrist from the radial side, placing a thumb on the palmar prominence of the scaphoid while wrapping fingers around the distal radius for counter pressure. The wrist is then passively moved into radial deviation and slight flexion by the examiner's other hand. The examiner's thumb resists the attempt of the scaphoid tuberosity to rotate volarly, creating a dorsally directed subluxation stress. This subluxation stress causes the proximal pole of the scaphoid to "shift" dorsally in relation to other bones of the carpus and the distal radius even in normal wrists. The degree of the shift is related to the amount of examiner pressure, the degree of scaphoid flexion, the amount of ligamentous laxity, and the status of the scapholunate (SL) ligament. A ruptured SL ligament allows the proximal pole to move more dorsally and frequently rest on the dorsal lip of the radius. The maneuver is best done with the patient's wrist flexed, because this causes the scaphoid to be angled to such a degree that the proximal pole may be only partially constrained by the bony architecture of the dorsal lip of the radius. As the thumb pressure is withdrawn, there may be a palpable "clunk" as the scaphoid returns to its normal position. Pain that replicates the patient's symptoms or asymmetrical laxity, when comparing with the contralateral wrist, is considered as significant findings. The scaphoid shift maneuver is usually considered a test for SL rupture and scaphoid instability; however, this test is also important for assessing the articular cartilage status of the proximal pole of scaphoid and radial facet, with a gritty sensation or clicking suggesting chondromalacia or loss of articular cartilage. It will also produce symptoms when an occult dorsal ganglion or an occult scaphoid fracture is present. Because the test produces a dorsal displacement of the scaphoid and traction on the SL ligament, if an occult dorsal ganglion is present, the test



Fig. 6: Pseudostability test.



Fig. 7: Kirk Watson's test.

JAYPEE BROTHERS

will generally be painful. Likewise, thumb pressure produces a force that begins on the tuberosity of the scaphoid and travels up the longitudinal axis of the scaphoid. This test will produce a painful stimulus if any fracture exists, and should be considered a mandatory test for all cases diagnosed as "clinical scaphoid fracture". *A painful "shift" with a palpable reduction "clunk" is generally a specific sign of SL instability* resulting from the corresponding ligament injury.

Scapholunate Test (Shear Test) (Fig. 8)

One hand of examiner holding the scaphoid, index finger over the scaphoid tuberosity volarly and thumb over the dorsum of the scaphoid area, examiner's other hand holding lunate with thumb over the dorsum to press the lunate forwards and scaphoid tuberosity dorsally. Abnormal increased mobility with extreme pain when compared to the normal side indicates SL instability. The lunate is felt distal and ulnar to the Lister's tubercle in mid-dorsum.

Lunotriquetral Instability

The LT Compression Test

Load the lunotriquetral (LT) joint in an ulnar-to-radial direction, eliciting pain with LT instability or degenerative joint disease. The examiner's thumb applies a radially direct pressure on the triquetrum just distal to the US at the "ulnar snuffbox", the space between the tendons of FCU and ECU. This maneuver is similar to the radiocarpal glide test described for radiocarpal instability

Reagan's Shear Test

Thumb dorsally on lunate, index finger applies pressure to triquetrum (via pisiform) volarly. This causes pain and abnormal mobility in LT ligament injury.

Masquelet's Ballotment Test (Fig. 9)

Examiner uses both hands to apply shear force across LT articulation. Examiner's index finger placed on the pisiform bone volar side, which lies on the surface of the triquetrum, the other hand holding the lunate with the thumb on the dorsum, triquetrolunate joint is stressed anteroposteriorly. The shear test is assessed for abnormal mobility and pain, and compared with the normal side. This indicates triquetrolunate instability. The landmark for the triquetrum is the pisiform bone, which is the most prominent bony landmark on volar and ulnar aspect of the wrist.



Fig. 8: Scapholunate ballottement test.



Fig. 9: Triquetrolunate ballottement test.

JAYPEE BROTHERS

Radiocarpal Instability (Fig. 10)

The anteroposterior drawer test can be used to assess for instability of either the radiocarpal or midcarpal joints. The examiner stabilizes distal forearm with one hand while the other hand grips the metacarpals, applying longitudinal traction and an anteroposterior force. A "drawer" is elicited though the radiocarpal or midcarpal joint, and compared with the contralateral side.

The radiocarpal glide will test the articular surface of the proximal carpal row and the extrinsic ligaments. The examiner's thumb exerts a radially directed force on the triquetrum. A radial shift of the proximal carpal row relative to the distal radius may be appreciated in the setting of radiocarpal instability. Crepitus may be felt in the setting of articular pathology of the radiocarpal joint.



Fig. 10: Radiocarpal glide test.

Midcarpal Instability

Midcarpal Shift Test of Lichtman (Fig. 11)

Normally as the wrist moves from radial to ulnar deviation, the proximal carpal row rotates smoothly from flexion to extension, while the distal row translates from palmar to dorsal. With midcarpal instability, the proximal row remains flexed and the distal row remains volarly translated longer than normal during ulnar deviation. As ulnar deviation progresses, the soft-tissue and bony restraints cause a sudden "catch-up" of the proximal row into extension and the distal row into dorsal translation, which is often an audible or palpable "clunk"- termed as "Catch up clunk". With the wrist in neutral ulnoradial deviation, the examiner stabilizes the forearm in pronation with one hand, and with the other hand applies a palmarly directed pressure at the level of the distal capitate, noting the ease and extent of palmar translation. The wrist is then axially loaded and passively ulnar deviated. The test is positive, if a painful catch-up clunk occurs with ulnar deviation that reproduces the patient's symptoms. The presences of palmar translation or a clunk alone without the reproduced symptoms are not considered positive, because they can occur in normal asymptomatic patients.

ASSESSMENT OF DORSAL RADIAL WRIST PAIN

Pain can be due to **scaphoid fracture, nonunion, styloid fracture, scapholunate**



Figs. 11A and C: Midcarpal shift test.

JAYPEE BROTHERS

for detailed information on orthopedics books, visit our website www.jaypeebrothers.com, for detailed information on orthopedics books, visit our webs

Clinical Assessment and Examination in Orthopedics

Salient Features

- The basis of clinical diagnosis and treatment plan is entirely dependent on the art of history taking and good clinical examination. This book depicts the ways how an orthopedic patient presents with a problem and an orthopedician should approach to arrive at a right diagnosis. Most of the clinical tests are demonstrated with colorful illustrative images. This book is ready reference for practicing orthopedic surgeon and trainees
- Each chapter has been edited by the eminent authorities in their field so that the current trends are updated and present standard of care in diagnosis is discussed
- This edition has color images of all the examination techniques with clear demonstration so that the reader can familiarize the way of performance by the look and repeated clinical practice
- Updated with present state of accepted most sensitive and specific tests for the diagnosis with evidence based medicine
- Newer tests of added value and information in each subspecialty have been updated
- More elaborate description and major revisions were done in chapters on Trauma, Shoulder, Elbow, Foot and Ankle
- As common things are common, the student or junior Orthopedic trainee should think of the most common condition rather than odd diagnosis and all chapters are written with due diligence insisting on the same note
- This book will give the postgraduate trainees a thoughtful and thorough knowledge for their exit exam and for their future clinical practice
- All the practicing orthopedic surgeon will be able to refine their clinical skills and examination techniques by following a methodical approach in assessment.

C Rex MS (Ortho) DNB (Ortho) FRCS (Ed.) FRCS (Tr & Ortho) MCh (Ortho) Liverpool PhD DSc (Ortho) is the Chief Consultant Orthopedic and Trauma Surgeon, Head of the Department of Orthopedics at the Rex Ortho Hospital, Coimbatore, Tamil Nadu, India. He completed his FRCS Ortho at Royal College of Surgeons of Edinburgh and did his MCh Ortho in University of Liverpool, United Kingdom. He did his PhD and DSc at Victoria Global University, Turks & Caicos. He established a postgraduate institute for orthopedic training that runs various surgical training courses for junior consultants in Trauma and Arthroplasty and conducts Annual Advanced Arthroplasty course. Dr MGR Medical University gave him the Best Doctor award as an honor. He has been a teaching faculty and given guest lectures in Indo-Korean Arthroplasty, Asia Pacific Arthroplasty and Arthroscopy Meet, Indian Orthopaedic Association Conference, Tamil Nadu Orthopaedic Association Conference, Indian Arthroplasty Conference, AO Nailing Course, AO Introductory Basic Course, and International Trauma Conference. He was the Past President of Indian chapter of Institute of Biomaterials, Tribocorrosion and Nanomedicine, Illinois, USA, Past Secretary of Coimbatore Orthopaedic Society and Executive Member of Tamil Nadu Orthopaedic Association. He is an Associate Editor of Indian Orthopaedic Journal and Tamil Nadu Orthopaedic Journal. He is an examiner for postdoctoral fellowship in arthroplasty and arthroscopy for Dr MGR Medical University.

Printed in India

Available at all medical bookstores
or buy online at www.jaypeebrothers.com



JAYPEE BROTHERS
Medical Publishers (P) Ltd.
EMCA House, 23/23-B, Ansari Road,
Daryaganj, New Delhi - 110 002, INDIA
www.jaypeebrothers.com

Join us on facebook.com/JaypeeMedicalPublishers

Shelving Recommendation
ORTHOPEDICS

ISBN 978-93-5465-570-8

9 789354 655708