it our website www.jaypeebrothers.com, for detailed information on obstetrics & gynecology books, visit our website www.jaypeebrothers.com

*Donald School*

# Basic Textbook of Ultrasound in Obstetrics and Gynecology




3rd Edition

Vincenzo D'Addario
Asim Kurjak
Giuseppe Rizzo

JAYPEE

# Contents


**1. Physical Basis, Technique, and Instrumentation ..... 1**

*Fabrizio Taddei, Giuliano Farina*

- Characteristics of the Ultrasound Equipment *1*

**2. Normal and Abnormal Early Pregnancy ..... 11**

*Luigi Carbone, Raffaella Di Girolamo, Giuseppe Maria Maruotti*

- Diagnosis of Pregnancy *12*
- Localization of a Pregnancy *13*
- Determination of Viability *14*
- Assessment of the Number of Embryos *16*
- Molar Pregnancy *17*

**3. Screening in the First Trimester ..... 21**

*Giovanni Monni, Francesca Dessolis, Alba Piras, Rosa Maria Ibba*

- Accuracy of Screening Program *21*
- Ultrasound Markers *21*
- Biochemical Markers *26*
- Noninvasive Prenatal Testing or Screening *27*

**4. Normal Fetal Anatomy in the Second Trimester ..... 32**

*Vincenzo D'Addario, Vincenzo Pinto*

- Head and Brain *32*
- Spine *34*
- Chest *36*
- Abdomen *38*
- Limbs *38*

**5. Accuracy of Ultrasound in Screening for Fetal Malformations ..... 45**

*Vincenzo Pinto, Mariangela Cialdella, Vincenzo D'Addario*

- Prevention of Fetal Malformations *45*
- Sonographic Screening of Congenital Abnormalities *45*
- Clinical Use of the Sonographic Screening of Congenital Anomalies *48*
- Sonographic Screening Trials of Congenital Malformations *49*

**6. General Aspects of Fetal Malformations ..... 52**

*Timothy J Rafael, Frank A Chervenak*

- Sonographic Evaluation of fetal Anatomy *52*
- Absence of a Normally Present Structure *55*
- Presence of an Additional Structure *57*
- Herniation through Structural Defects *58*
- Dilatation behind an Obstruction *62*
- Abnormal Fetal Biometry *63*
- Absent or Abnormal Fetal Motion *64*
- Ultrasound Detection of Chromosomal Abnormalities *65*

**7. Central Nervous System Malformations ..... 70**

*Vincenzo D'Addario, Ritsuko K Pooh*

- Ventriculomegaly *77*
- Disorders of Ventral Induction *82*
- Septo-optic Dysplasia *83*
- Neuronal Proliferation, Migration, and Differentiation Disorders *85*
- Space-occupying Lesions *87*
- Posterior Fossa Abnormalities *90*
- Neural Tube Defects *93*

**8. Malformations of the Gastrointestinal System ..... 99**

*Vincenzo D'Addario, Luca Di Cagno*

- Anterior Abdominal Wall Defects *101*
- Diaphragmatic Defects *104*
- Bowel Disorders *107*
- Non Bowel Cystic Masses *111*
- Hepatic Masses *112*

**9. Malformations of the Urinary System ..... 114**

*Vincenzo D'Addario, Pasquale Capuano*

- Renal Agenesis *115*
- Pelvic Kidney *116*
- Horseshoe Kidney *117*
- Dysplastic Kidneys *118*
- Hydronephrosis *122*
- Hydroureteronephrosis *125*
- Dilated Bladder *125*
- Bladder/Cloacal Exstrophy *127*
- Renal Tumors *128*

**10. Malformations of the Skeletal System ..... 130**

*Vincenzo D'Addario, Pasquale Capuano*

- Normal Anatomy of the Fetal Musculoskeletal System: Ultrasound Approach, Scanning Planes, and Diagnostic Potential *130*
- Achondrogenesis *135*
- Osteogenesis Imperfecta *135*
- Thanatophoric Dysplasia *136*
- Short-Rib Polydactyly Syndrome *136*
- Campomelic Dysplasia *138*
- Chondroectodermal Dysplasia (Ellis–Van Creveld Syndrome) *138*
- Diastrophic Dysplasia *139*
- Hypophosphatasia *139*

- Asphyxiating Thoracic Dystrophy (Jeune Syndrome) *140*
- Achondroplasia *140*
- Limb-reduction Defects *141*
- Joint Contractures, Neuromuscular Diseases, and Anomalies of the Extremities *143*

**11. Malformations of the Thorax ..... 147**

*Vincenzo D'Addario, Pasquale Capuano*

- Ultrasound Approach and Scanning Planes *147*
- Congenital Cystic Adenomatoid Malformation of the Lung *147*
- Pulmonary Sequestration *149*
- Laryngeal Atresia *150*
- Hydrothorax *151*
- Bronchogenic Cysts *152*

**12. Evaluation of Fetal Heart ..... 154**

*Maria Elena Pietrolucci, Ilenia Mappa, Giuseppe Rizzo*

- Ultrasonographic Examination of the Fetal Heart *154*
- Doppler Examination of the Fetal Heart *157*
- 4D Study of the Fetal Heart *158*

**13. Fetal Tumors ..... 165**

*Vincenzo D'Addario, Luca Di Cagno*

- Intracranial Tumors *165*
- Neck and Face Tumors *167*
- Chest Tumors *168*
- Abdominal Tumors *170*
- Sacrococcygeal Teratoma *172*

**14. Ethics and Law in Congenital Defects ..... 176**

*Josè Maria Carrera*

- General Ethical Principles *176*
- Basic Legal Principles *177*
- Specific Legal/Ethical Principles in Prenatal Diagnosis *177*
- Chronology of Ethical and Legal Dilemmas *177*
- Obstetrical Conduct Following Prenatal Diagnosis of a Congenital Defect *179*
- Response According to the Type of Defect *179*

**15. Invasive Procedures ..... 181**

*Giovanni Monni, Alba Piras, Francesca Dessolis*

- Chorionic Villus Sampling *181*
- Amniocentesis *183*
- Fetal Blood Sampling: Cordocentesis *184*
- Chorionic Villus Sampling–Amniocentesis–Fetal Blood Sampling in Multiple Pregnancy *185*
- Training and Audit on Invasive Prenatal Procedures *186*

**16. Twin Pregnancy ..... 188**

*Alexandra Matias, Miguel Pereira-Macedo*

- Types of Twins *188*
- Ultrasound in Dating a Twin Pregnancy *188*
- Ultrasound in the Definition of Chorionicity and Amnionicity *189*
- Ultrasound in the Screening of Aneuploidies *190*
- Ultrasound in the Diagnosis of Fetal Malformations *192*
- Ultrasound in the Diagnosis of Discrepancies in Fetal Growth *192*
- Ultrasound in the Screening and Diagnosis of Twin-to-Twin Transfusion Syndrome *193*
- Ultrasound in the Diagnosis of other Pathologies Unique to Twins *196*
- Conjoined Twins *197*
- Ultrasound in the Screening of Preterm Delivery *198*

**17. Basic Biometry ..... 201**

*Ingrid Marton, Badreldeen Ahmed, Berivoj Mišković*

- Crown–Rump Length *201*
- Biparietal Diameter *202*
- Head Circumference *203*
- Abdominal Circumference *205*
- Femur Length *206*

**18. Assessment of the Gestational Age ..... 209**

*Robin B Kalish*

- Importance of Accurate Gestational Age Assessment *209*
- Assessing Gestational Age Using Last Menstrual Period *209*
- Clinical Methods for Determining Gestational Age *209*
- Ultrasound Assessment of Gestational Age *210*
- Multifetal Pregnancies *212*
- Choosing a Due Date *213*

**19. Assessment of Fetal Growth ..... 216**

*Jia Li Angela Lu, Alessandra Capponi, Giuseppe Rizzo*

- Biparietal Diameter *216*
- Head Circumference *216*
- Abdominal Circumference *216*
- Femur Length *217*
- Estimated Fetal Weight *217*
- Biometric Reference Ranges and Growth Standards *217*

**20. Fetal Growth Abnormalities ..... 224**

*Ilenia Mappa, Maria Luviso, Giuseppe Rizzo*

- Definition and Classification of Fetal Growth Restriction *224*
- Causes and Risk Factors for Fetal Growth Restriction *225*
- Screening and Diagnosis of Early and Late Fetal Growth Restriction *225*
- Treatment of Fetal Growth Restriction *228*

**21. Doppler in Obstetrics ..... 236**

*Roberta Nale, Ilenia Mappa, Giuseppe Rizzo*

- Physical Principles *236*
- Aliasing *237*
- Fetal and Maternal Arterial Doppler *237*
- Cerebral Placental Ratio or Umbilical Cerebral Ratio *242*

**22. The Placenta ..... 249**

*Kelly Yamasato, Ivica Zalud*

- Normal Placenta *249*
- Placental Abnormalities *252*

**23. The Umbilical Cord ..... 257**
*Mladen Predanic*
- Umbilical Cord Development *257*
- Umbilical Cord Anatomy *258*

**24. The Amniotic Fluid ..... 267**
*Jia Li Angela Lu, Alessandra Capponi, Giuseppe Rizzo*
- Amniotic Fluid Physiology and Dynamics *267*
- Anomalies of the Amniotic Fluid Volume *268*

**25. Ultrasound in Labor ..... 272**
*Ilenia Mappa, Maria Luviso, Giuseppe Rizzo*
- Assessment of Fetal Head Position *272*
- Assessment of Fetal Head Station *274*
- Assessment of Fetal Head Flexion *275*
- Ultrasound Use for Diagnosing an Arrested Labor *275*
- Intrapartum Ultrasound before Instrumental Delivery *279*

**26. Screening by Ultrasound in Pregnancy ..... 282**
*Aris Antsaklis, Georgios Daskalakis*
- Screening for Aneuploidies *282*
- Screening for Fetal Malformations *288*
- Screening for Preeclampsia *291*
- Screening for Preterm Delivery *295*

**27. Basic Principles of 3D and 4D Sonography ..... 305**
*Asim Kurjak, Taib Delic*
- 3D and 4D Imaging *306*
- Volume Contrast Imaging *313*
- Spatiotemporal Image Correlation: Fetal Cardiac Imaging *313*

**28. Normal Pelvic Anatomy ..... 316**
*Vincenzo D'Addario, Asim Kurjak, Biserka Funduk-Kurjak*
- Examination Techniques *316*
- Uterus *316*
- Ovaries *320*
- Fallopian Tubes *323*

**29. Uterine Pathologies ..... 325**
*Ingrid Marton, Biserka Funduk-Kurjak*
- Basic Anatomy *325*
- Ultrasound Imaging *326*
- Uterine Perfusion *326*
- Menstrual Cycle and Postmenopausal Changes *327*
- Uterine Abnormalities *328*

**30. Basic Assessment of Normal and Abnormal Ovaries ..... 336**
*Asim Kurjak, Badreldeen Ahmed, Edin Madjedovic*
- Origin and Size *336*
- Internal Architecture *336*
- Associated Lesions *337*
- Differentiation of Pelvic Masses by Ultrasound *337*
- Evaluation of an Ovarian Mass *343*

**31. Fallopian Tubes ..... 345**
*Biserka Funduk-Kurjak, Ingrid Marton, Manal Younis*
- Basic Anatomy *345*
- Ultrasound Visualization *345*
- Abnormalities of the Fallopian Tube *346*
- Ultrasonographic Findings *346*

**32. Ultrasound in Human Reproduction ..... 353**
*Jure Knez, Veljko Vlaisavljević*
- Ultrasound Monitoring of Follicular Development *353*
- Ultrasound as the Tool for Prediction of Success and for Monitoring in Medically-assisted Reproduction *355*
- Role of Sonographic Evaluation of the Endometrium *360*

*Index ..... 365*

CHAPTER

4

# Normal Fetal Anatomy in the Second Trimester

*Vincenzo D'Addario, Vincenzo Pinto*

JAYPEE BROTHERS

## INTRODUCTION

Screening for fetal malformations is one of the main aims of ultrasonography during pregnancy. In most cases, fetal anomalies occur as an unexpected event in not at risk patients: for this reason the only way to rule out congenital malformations is to screen every pregnant patient with a systematic evaluation of the fetal anatomy.

Fetal organogenesis is an evolving process[1] and a complete evaluation of such a complicated evolution should require multiple ultrasonic examinations during pregnancy. In the clinical practice, however, a screening policy should rely on a limited number of scans during pregnancy in order to limit the costs. For this reason, the ultrasonic screening of fetal malformations has to be based on a single examination that has to be planned at a gestational age, which is advanced enough to visualize most fetal anomalies and early enough to plan further diagnostic tests and allow the termination of pregnancy in the case of severe malformation. The gestational age that constitutes the best compromise between the need of an early diagnosis and the natural history of most congenital malformations is the period ranging from 19 to 21 weeks of gestation. This ultrasonic examination is known as "fetal anomaly scan" or "fetal morphology scan".

In order to obtain a systematic evaluation of the fetal anatomy it is essential to establish:

- The orientation of the ultrasonic images on the screen in regard to the patient lie (i.e., the left border of the screen corresponds to the left side of the patient abdomen in the axial scans and to the cephalic pole in the longitudinal ones)
- The fetal lie in the uterus.

To obtain the latter goal, it is necessary to correlate the three-dimensional movements of the probe on the maternal abdomen to the bidimensional images appearing on the screen and to reconstruct a mental three-dimensional model from the pool of images seen. Once the idea of the fetal lie in the uterus is obtained, the probe can be quickly oriented on the correct plane to visualize the desired fetal anatomical structure.[2]

## HEAD AND BRAIN

The measurements of biparietal diameter (BPD) and head circumference are obtained on an axial scan of the fetal head showing the thalami, the cavum septi pellucidi, and the frontal horns of the lateral ventricles (transthalamic scan) **(Fig. 1)**.

By slightly tilting the probe caudally (toward the base of the skull), the atrium of the lateral ventricle filled by the echogenic choroid plexus and continuing in the posterior occipital horn is shown (transventricular scan) **(Fig. 2)**; at this level the atrial width is measured: its normal value is <10 mm independently from the gestational age. During the second trimester the surface of the cerebral hemispheres is still smooth, since the development of the gyri and sulci is a late event, and the Sylvian fissure is wide, such allowing to recognize the lobe of the insula.

By further tilting the probe caudally the posterior fossa is shown with the cerebellum and the cisterna magna (transcerebellar scan) **(Fig. 3)**. At this level, the transverse cerebellar diameter is measured. By tilting the probe on the

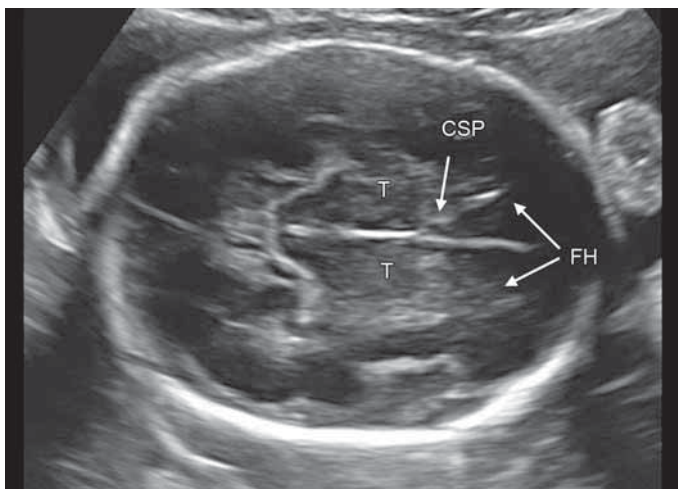


**Fig. 1:** Transthalamic scan for measurement of biparietal diameter and head circumference. (CSP: cavum septi pellucidi; FH: frontal horns; T: thalami)

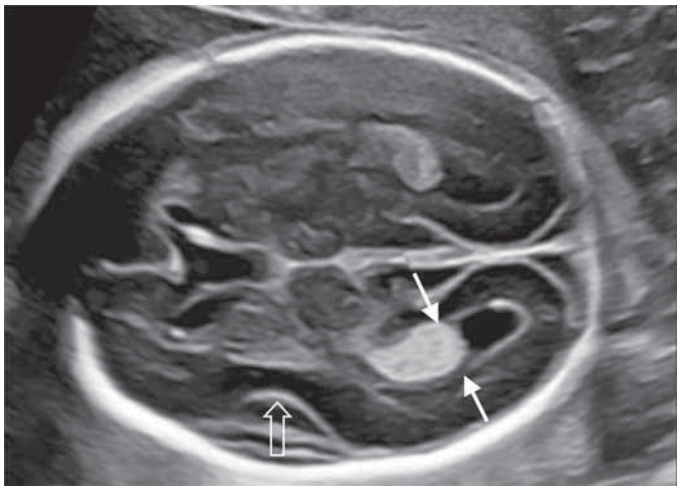

**Fig. 2:** Transventricular scan for measurement of the atrial width. Arrows point to the atrium of the lateral ventricle. (Block arrow: insula)



**Fig. 4:** Transverse scan on the orbits. The lenses can be recognized.

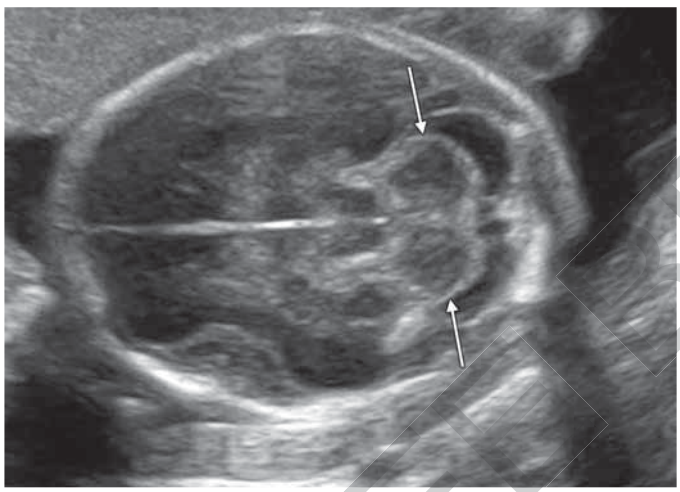

**Fig. 3:** Transcerebellar scan for measurement of the transverse cerebellar diameter (arrows). The cerebellum is contourned by the cisterna magna.

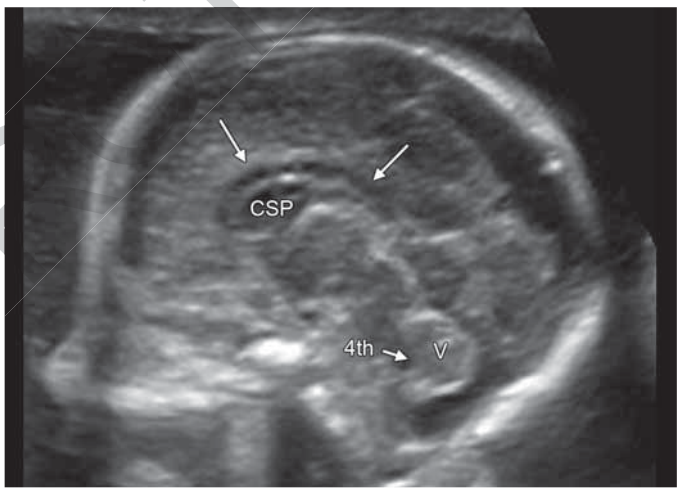


**Fig. 5:** Midsagittal scan of the brain showing the corpus callosum (arrows), the cavum septi pellucidi (CSP), the posterior fossa with the cerebellar vermis (V), and the fourth ventricle (4th).

opposite side, the orbits can be visualized (transorbitary scan) **(Fig. 4)**.

These four simple scans allow an accurate evaluation of the brain anatomy and the recognition of the majority of the brain anomalies. However further scans can be obtained, allowing a more detailed evaluation of the finest brain structures. Particularly, when the fetus is in breech presentation or in transverse lie, sagittal and coronal scans can be obtained. A midsagittal scan shows the corpus callosum above the cavum septi pellucidi as well as the posterior fossa, where the cerebellar vermis and the fourth ventricle can be recognized **(Fig. 5)**. A parasagittal scan shows the different components of the lateral ventricle (so called "three horns view") **(Fig. 6)**. A more external parasagittal scan shows the smooth surface of the brain with the wide insula delimited by the opercula **(Fig. 7)**. The coronal scan will show the

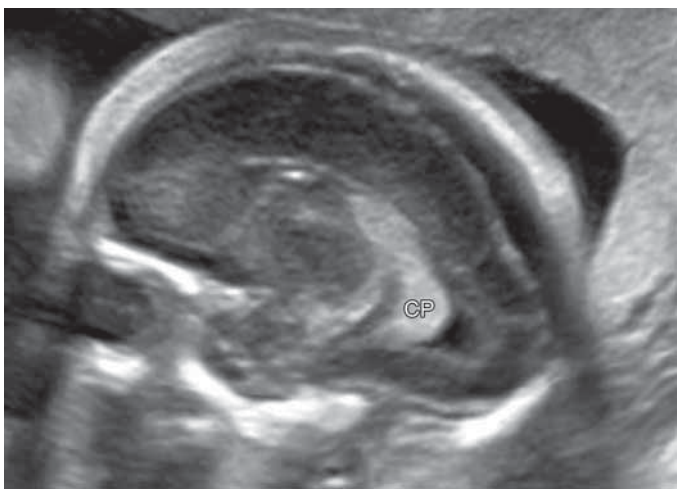


**Fig. 6:** Parasagittal scan of the brain showing the "three horns view" of the lateral ventricle with the choroid plexus (CP) inside.

JAYPEE BROTHERS

lateral ventricles with a different appearance, depending on the level of the scan: the most anterior one will show the frontal horns in the frontal hemispheres (transfrontal plane) **(Fig. 8A)**; moving posteriorly the cavum septi pellucidi and corpus callosum may be seen interposed between the frontal horns above the caudate nuclei (transcaudate plane) **(Fig. 8B)**; then the thalami may be seen below the bodies of the lateral ventricles (transthalamic plane) **(Fig. 8C)**, and finally the occipital horns with their typical round appearance above the cerebellum may be seen in the most posterior plane (transcerebellar plane) **(Fig. 8D)**.

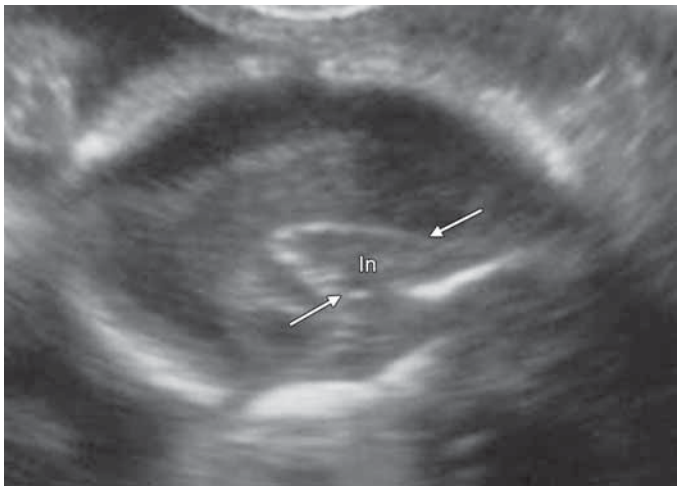


**Fig. 7:** External parasagittal scan showing the smooth surface of the brain, the wide insula (In) and the opercula (arrows).

The fetal face can be evaluated both by midsagittal scan, showing the profile **(Fig. 9)** and by coronal scan, showing the lips and nostrils **(Fig. 10)**.

Axial scans at the level of the mouth show the maxilla in the upper level and the tongue with the pharynx at the lower level **(Figs. 11A and B)**.

## SPINE

The spine can be evaluated in longitudinal, coronal, and axial scans. The longitudinal scan passing through the spinal canal may also show the chest and ribs which produce sharp acoustic shadows **(Fig. 12)**. An alternative way to visualize the spinal canal is the coronal scan passing through the laminae **(Fig. 13)**.

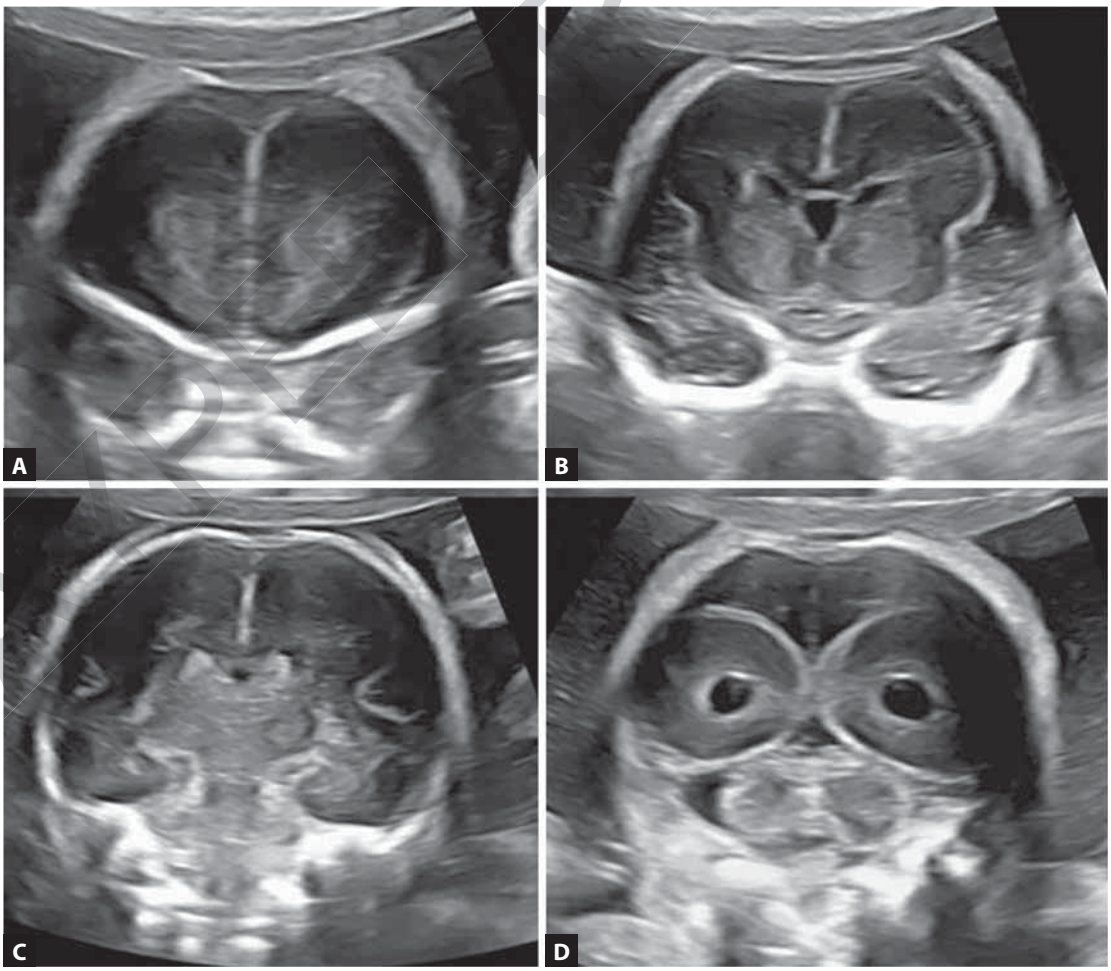


**Figs. 8A to D:** Coronal planes of the brain from the anterior to the posterior aspect: (A) Transfrontal; (B) Transcaudate; (C) Transthalamic; (D) Transcerebellar.

JAYPEE BROTHERS

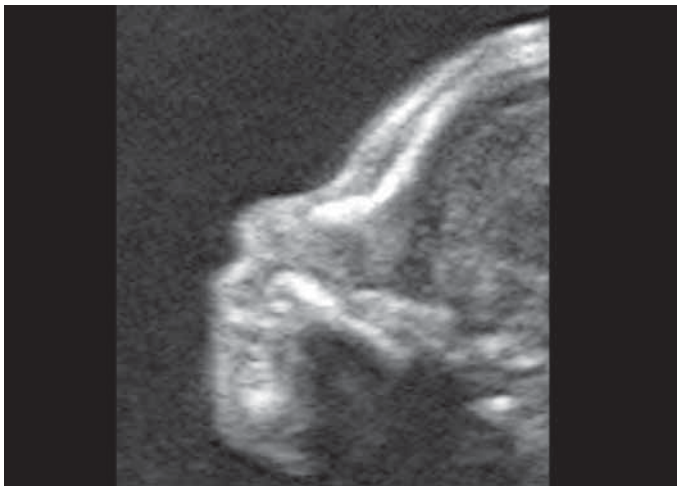

**Fig. 9:** Fetal profile.

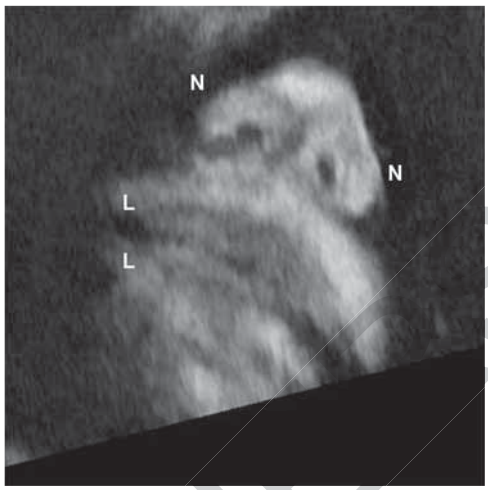


**Fig. 10:** Coronal scan of the lips (L) and nostrils (N).

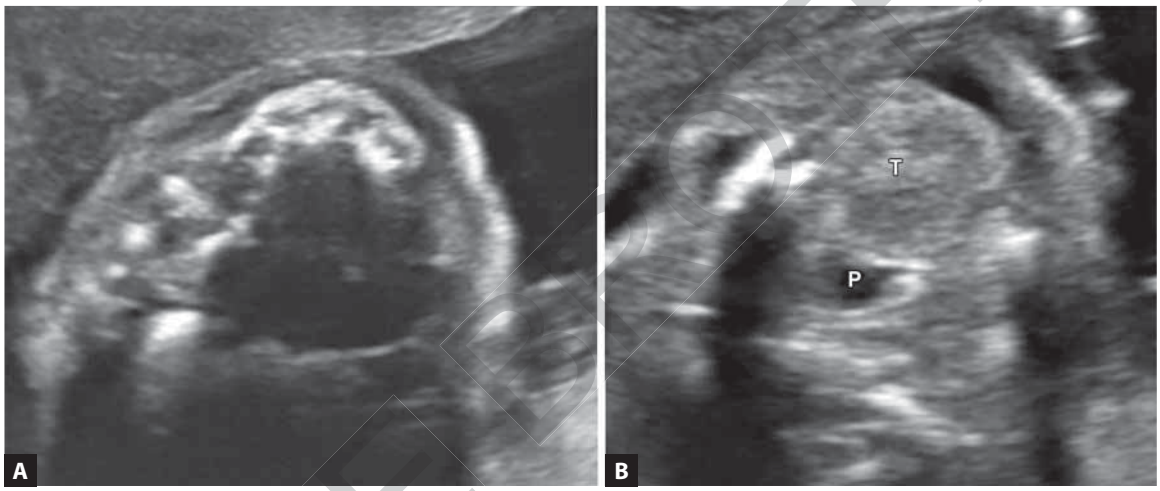


**Figs. 11A and B:** Axial scan of the mouth. (A) At the upper level the maxilla can be seen; (B) At the lower level the tongue (T) and the pharynx (P) are shown.

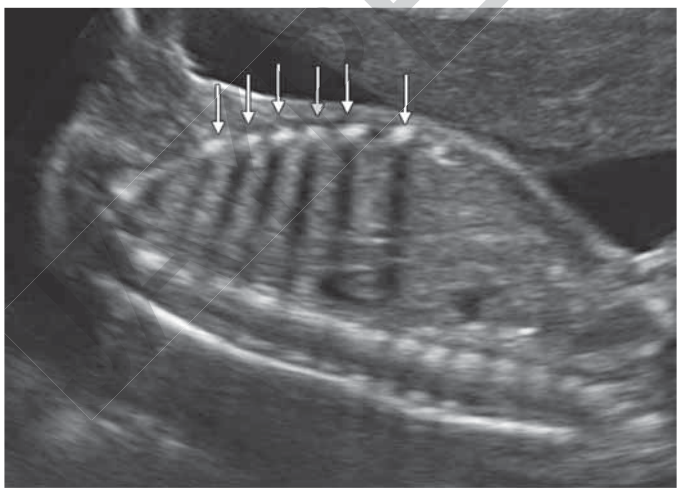

**Fig. 12:** Longitudinal scan of the spine. The ribs (arrows) produce sharp acoustic shadows.

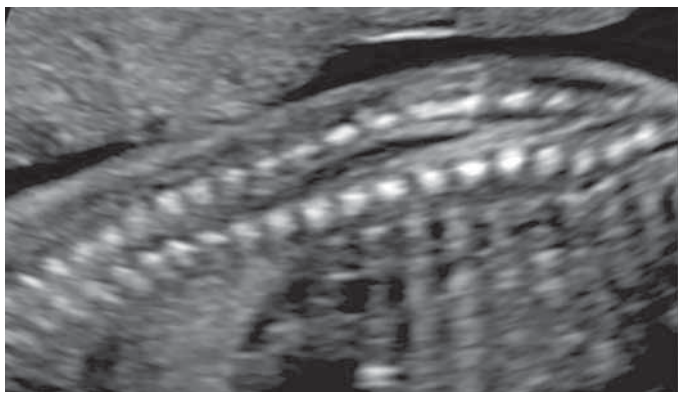

**Fig. 13:** Coronal scan of the spine passing through the laminae and showing the spinal canal.

In the axial scan the vertebrae show three ossification centers independently from the level, one generating the body and two generating the laminae, which will fuse posteriorly in the spinous process. According to the level of the section, the axial view may show the clavicle, the ribs, or the kidneys **(Figs. 14A to C)**.

Close to the spine, further bony structures can be seen, such as the scapulae and the iliac wings **(Figs. 15A and B)**.

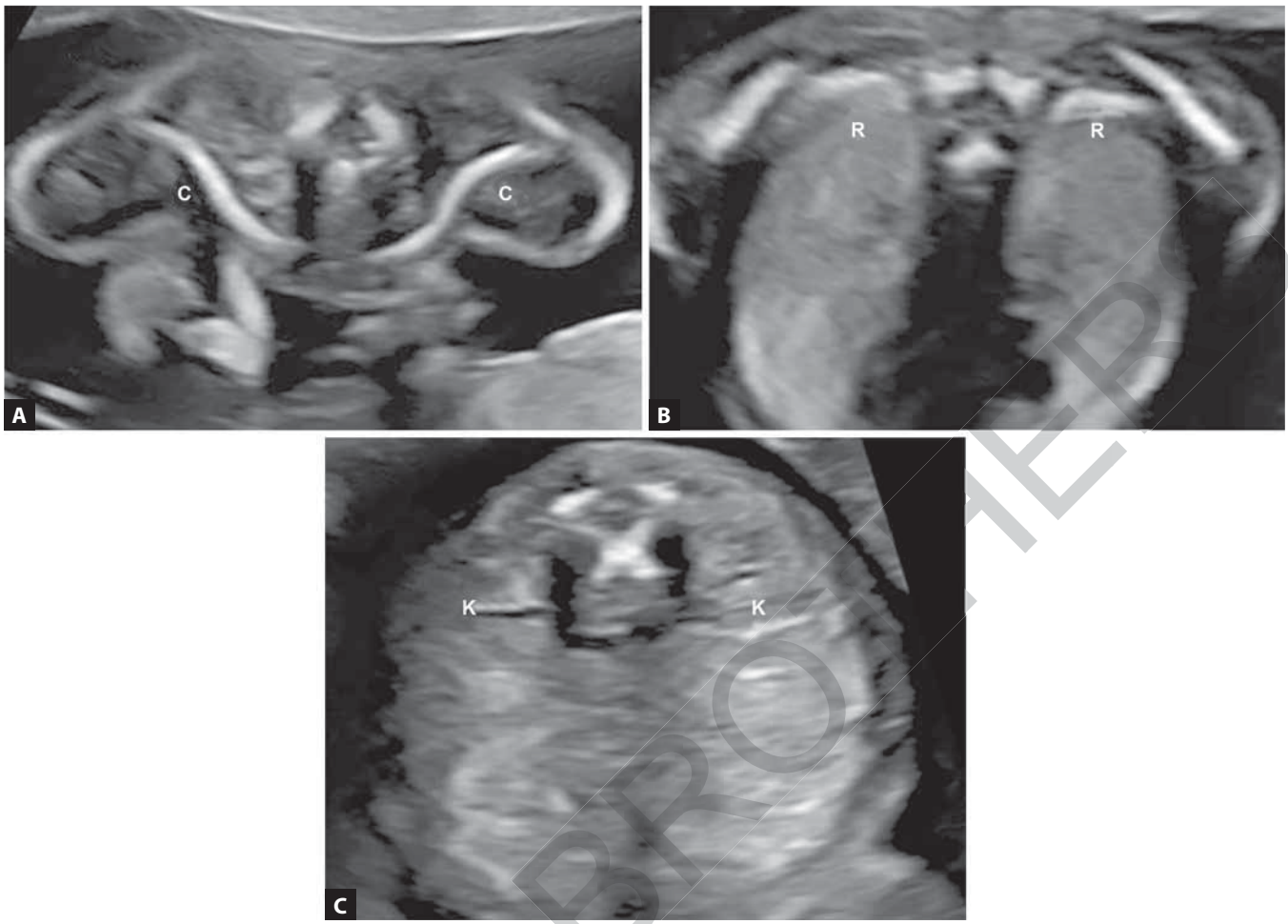


**Figs. 14A to C:** Transverse scan of the vertebrae at different levels: (A) Cervical level, where the clavicles (C) can be seen; (B) Dorsal level, where the ribs (R) can be seen; (C) Lumbar level where the kidneys (K) can be seen. Independently from the level the vertebrae show three ossification centers referring to the body and the laminae.

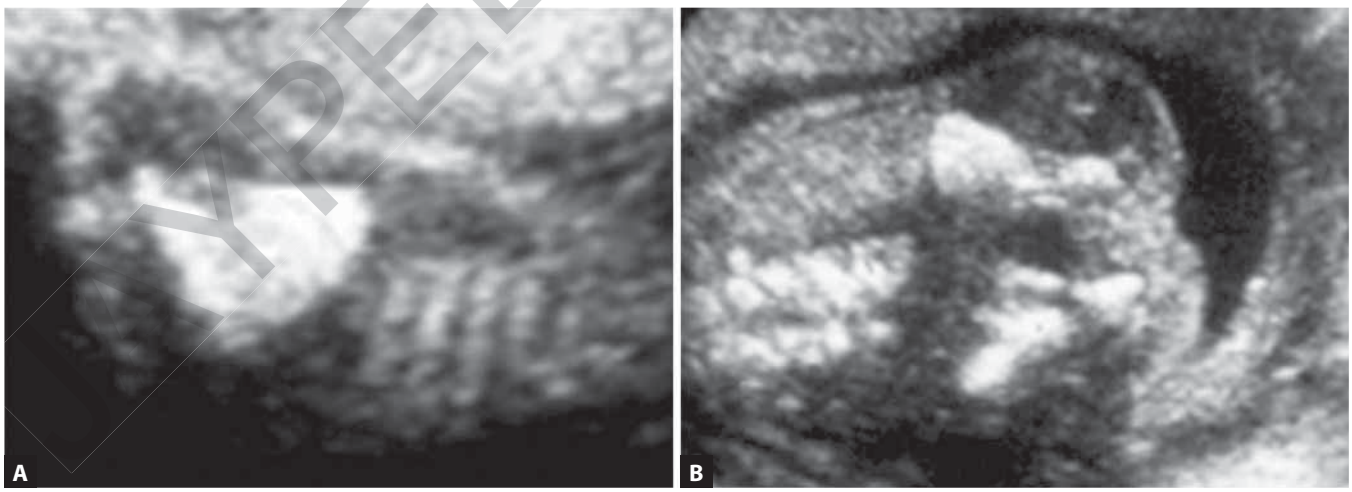


**Figs. 15A and B:** (A) The scapula and (B) the iliac wings can be seen close to the spinal canal.

## CHEST

It is important to establish the correct fetal position in utero in order to confirm the "situs solitus" (both stomach and apex of the heart on the left side of the fetus).

The best section to evaluate the chest structures is the axial one at the level of the heart: this scan shows the hyperechoic lungs "embracing" the cardiac area. In this axial scan, the four-chamber view of the heart is looked for. In order to obtain a correct four-chamber view, the first step

TYPE PROOF

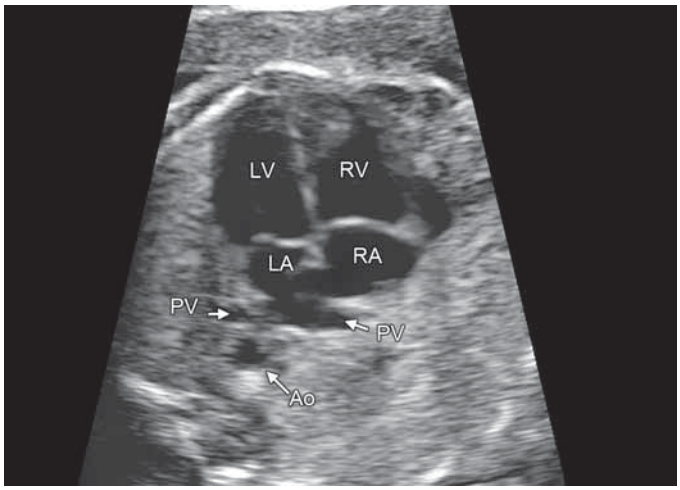


**Fig. 16:** "Four-chamber" apical view of the heart. (Ao: aorta; LA: left atrium; LV: left ventricle; PV: pulmonary veins; RA: right atrium; RV: right ventricle)

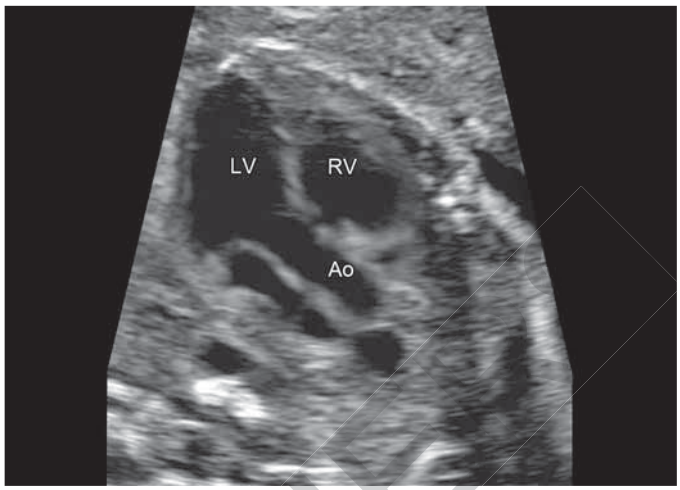


**Fig. 17:** Left long-axis of the heart showing the emerging aorta. (Ao: aorta; LV: left ventricle; RV: right ventricle)

is to localize the stomach in an axial scan on the abdomen, and then moving the transducer cranially without tilting it: in such a way a confirmation of a normally left-sided heart as well as a correct heart section is easily obtained. The four-chamber view can be "apical" when the ultrasonic beam is parallel and "transverse" when it is perpendicular to the interventricular septum. It is better to try to obtain both scans, since the "apical" is optimal for evaluating the atrioventricular valves, and the "transverse" for evaluating the interventricular and interatrial septa.

In the "four-chamber" view the following cardiac structures can be seen **(Fig. 16)**:

- *The atria*: They have approximately the same size; the left one is closer to the spine and contains the foramen ovale's valve.
- Two of the pulmonary veins opening in the left atrium.
- The interatrial septum with the interruption due to the foramen ovale.
- *The atrioventricular valves*: The tricuspid has a slightly lower septal insertion than the mitral valve.
- *The ventricles*: They have approximately the same size but a different shape; the right one is more roundish and contains the "moderator band" close to the apex.
- The interventricular septum.

Once the four-chamber view has been obtained, by slight movements of the transducer, it is possible to visualize the outflow tracts and the subaortic part of the interventricular septum.

The left outflow tract (also called left long axis) is obtained from the four-chamber view, by rotating the transducer toward the right fetal shoulder.

In the left long axis, the following structures can be evaluated **(Fig. 17)**:

- The connection between the left ventricle and the aorta
- The integrity of the subaortic part of the interventricular septum
- The presence and function of the aortic valve.

By rotating the transducer from the long-axis view toward the fetal head, the right short-axis view can be obtained showing the right outflow tract.

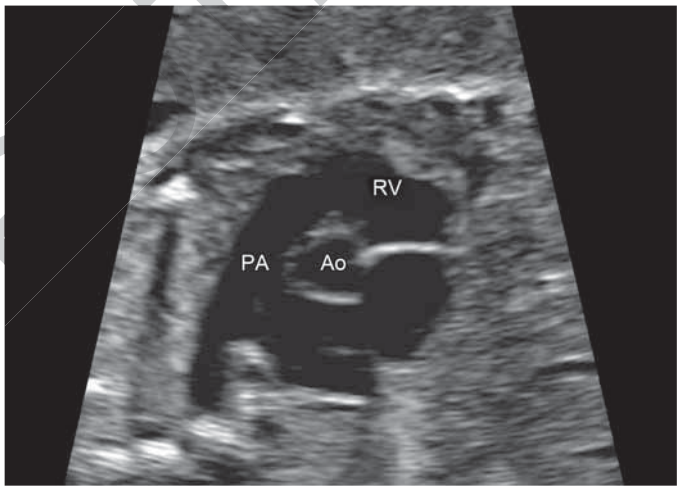


**Fig. 18:** Right short axis of the heart showing the pulmonary artery (PA) emerging from the right ventricle (RV) and crossing the aorta (Ao).

In the right short-axis view the following structures can be seen **(Fig. 18)**:

- The connection between the right ventricle and the pulmonary artery
- The crossover of the pulmonary artery
- The presence and function of the pulmonary valve.

An alternative way to evaluate the heart and large vessels is to obtain a correct four-chamber apical view and then to move the transducer upward to the head: the emerging aorta and the crossover of the pulmonary artery can be seen during such a movement. At the end of this excursion, the so-called

JAYPEE BROTHERS

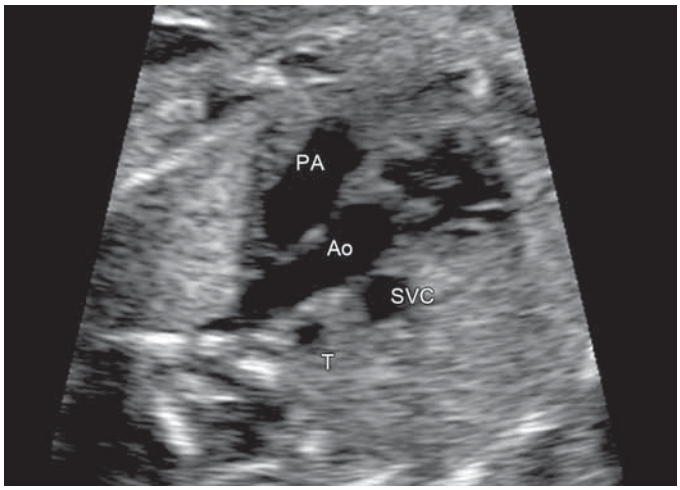


**Fig. 19:** Three vessels-trachea view showing the superior vena cava (SVC), the aorta (Ao), and the pulmonary artery (PA) continuing in the ductal arch and the trachea (T).

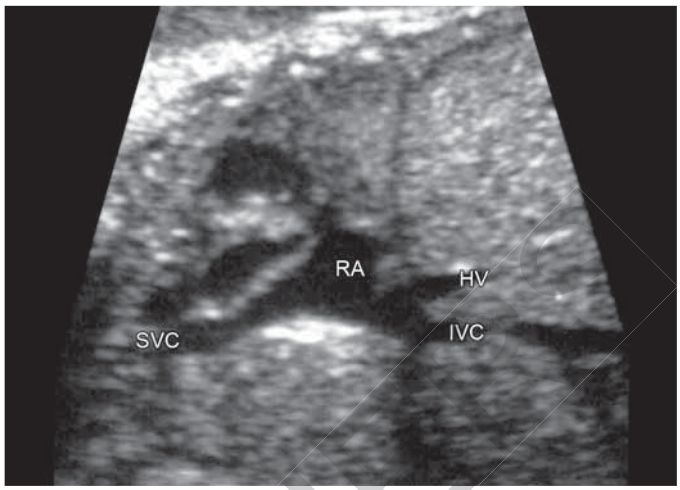


**Fig. 21:** Longitudinal scan showing the superior (SVC) and inferior vena cava (IVC) opening in the right atrium (RA). (HV: hepatic vein)

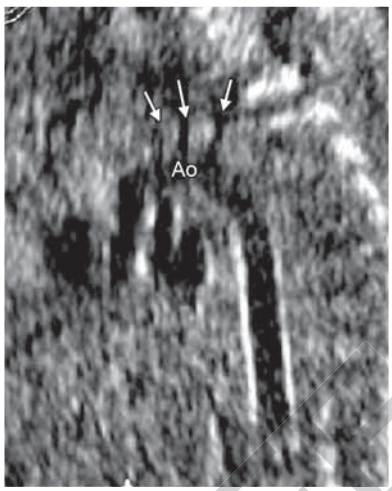


**Fig. 20:** Longitudinal scan of the aortic arch (Ao). The arrows point to the brachicephalic vessels.

three vessels-trachea view (3VT view) can be obtained **(Fig. 19)** showing from the right to the left the superior vena cava, the aortic arch and the pulmonary artery progressing in the ductal arch; the trachea appears as a small anechoic area on the right side of the aorta and posterior to the superior vena cava.

Longitudinal scans may show the aortic arch with the brachicephalic vessels **(Fig. 20)** and the superior and inferior vena cava opening in the right atrium **(Fig. 21)**.

A complete bidimensional echocardiographic evaluation is reported in **Figures 22A to F**.

## ABDOMEN

The best scan to visualize the fetal abdomen is the transverse one at the level where the abdominal circumference is measured; at this level the following structures can be recognized: the intrahepatic tract of the umbilical vein on the anterior aspect, the stomach on the left side, the spine, and the transverse section of the abdominal aorta on the posterior aspect **(Fig. 23)**.

The gallbladder appears as a pear-shaped anechoic structure located in the right side of the abdomen immediately below the right lobe of the liver **(Fig. 24)**.

The bowel during the second trimester appears as an echogenic area with irregular borders in the lower part of the abdomen **(Fig. 25)**.

Longitudinal section of the abdomen and chest shows the diaphragm as a thin hypoechoic curve line dividing the liver from the lung **(Fig. 26)**.

Following the course of the umbilical vein the insertion of the umbilical cord on the abdominal wall is seen **(Fig. 27)**.

The examination of the fetal abdomen also includes the visualization of the kidneys and bladder. The kidneys are visible on the high axial scan of the abdomen and appear as two echogenic structures on both sides of the spine **(Fig. 28)**. The capsule and the pelvis show an echogenicity higher than the renal tissue; a mild physiological dilatation of the renal pelvis can sometimes be seen. In the coronal scan, the kidneys show their typical "bean" shape appearance **(Fig. 29)**.

The visualization of the bladder is easy. It appears as a cystic median structure in the lower abdomen **(Fig. 30)**.

Above the bladder and between the legs the penis in the male fetus **(Fig. 31)** and the labia majora in the female **(Fig. 32)** may be seen.

## LIMBS

The visualization of the limbs requires a correct understanding of the fetal lie in the uterus and some skill in following their movements. The amount of amniotic fluid is very important: in case of oligohydramnios, the recognition of the limbs becomes difficult. The long bones of the four limbs may be recognized **(Figs. 33 and 34)**.

JAYPEE BROTHERS

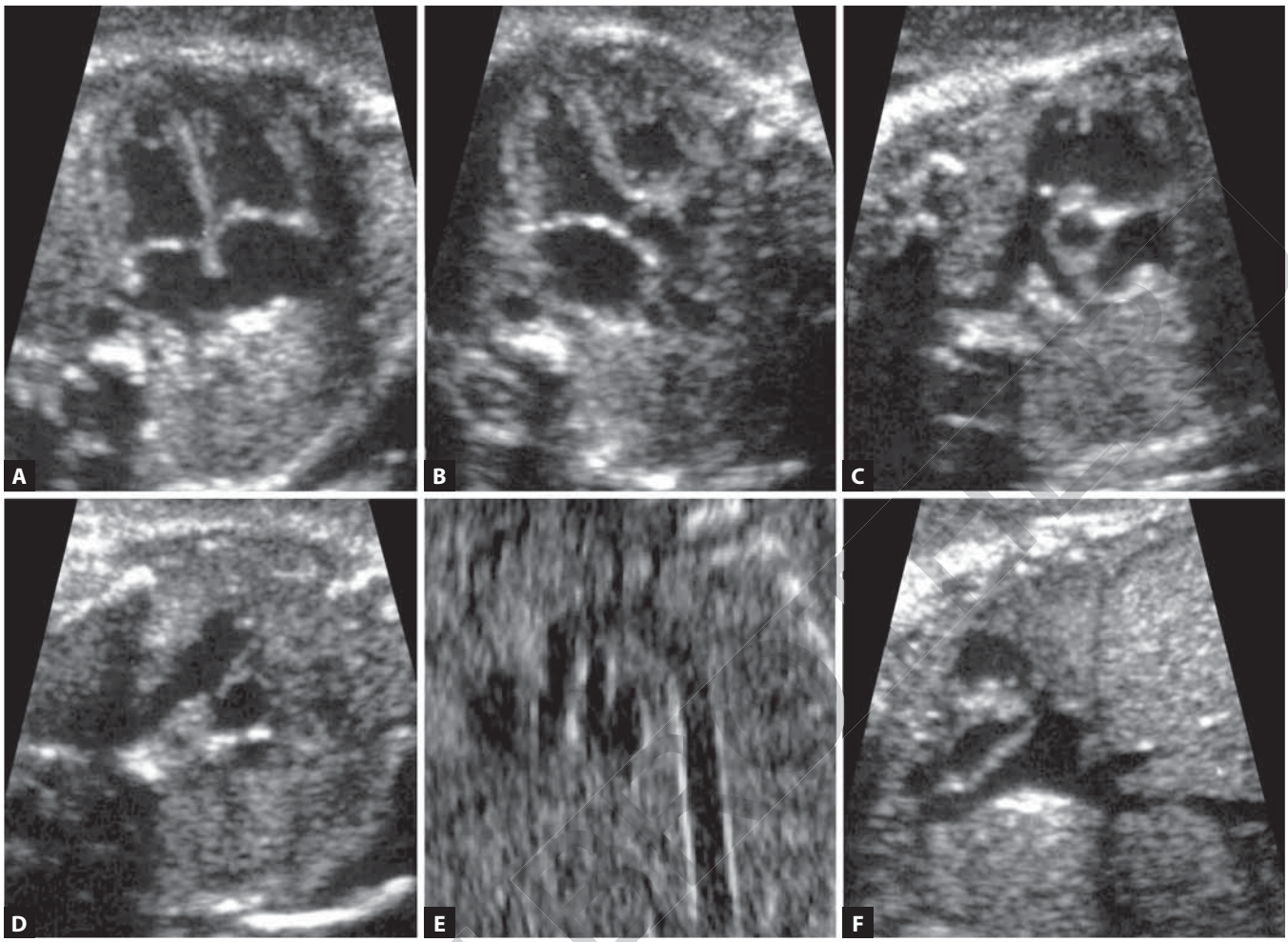


**Figs. 22A to F:** Complete bidimensional echocardiography. (A) Four-chamber view; (B) Left ventricle outflow tract; (C) Right ventricle outflow tract; (D) Three vessels-trachea view; (E) Aortic arch; (F) Superior and inferior vena cava.

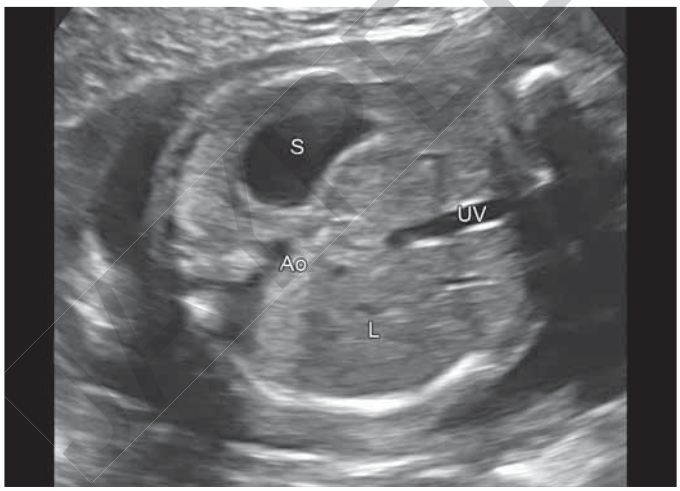


**Fig. 23:** Transverse scan of the abdomen for measurement of the abdominal circumference: The intrahepatic tract of the umbilical vein (UV) crossing the liver (L), the stomach (S), and the transverse section of the abdominal aorta (Ao) can be recognized.




**Fig. 24:** The gallbladder (G) appears as a pear-shaped anechoic structure in the right side of the liver.

The hands and feet should also be visualized but only to define whether they are present or absent. The count of the fingers on the open hand is not always possible since the fetus usually has the hands in the closed position.

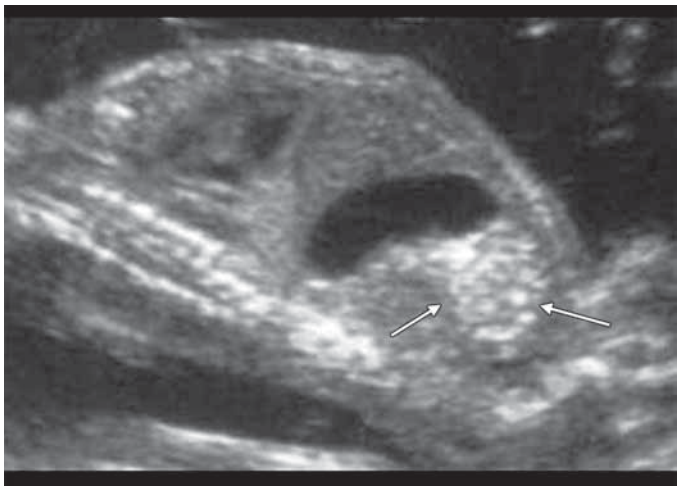

**Fig. 25:** The bowel appears as an echogenic area in the lower part of the abdomen (arrows).



**Fig. 28:** Transverse section of the kidneys: they appear as two roundish moderately echogenic structures. A slight dilatation of the pelvis is frequently seen.

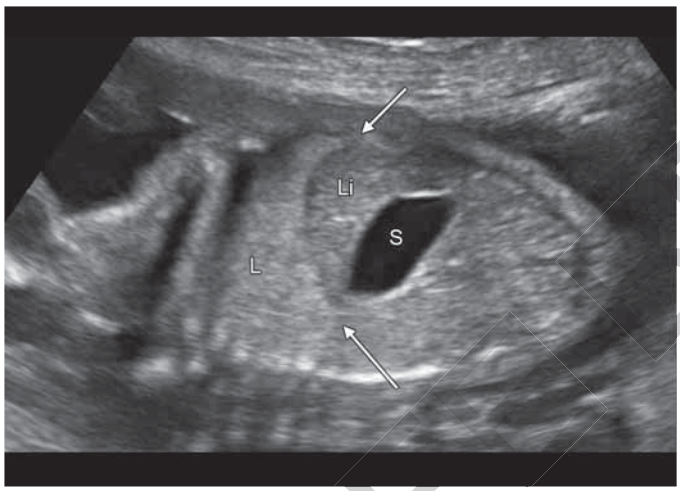


**Fig. 26:** The diaphragm (arrows) appears as a thin curve hypoechoic line dividing the liver (Li) from the lung (L). (S: stomach)

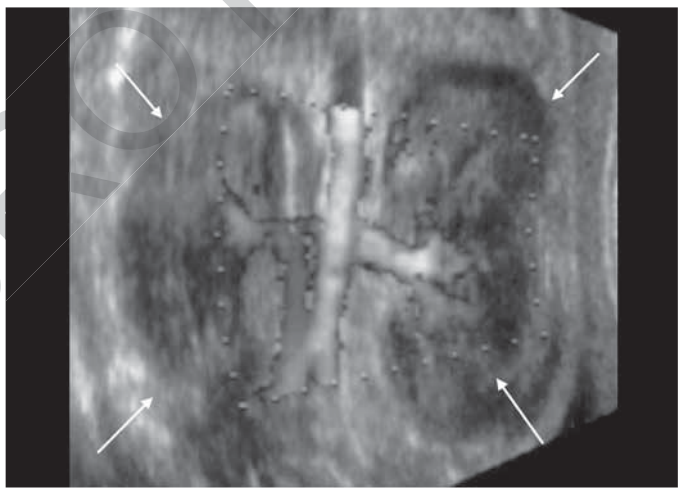

**Fig. 29:** Coronal section of the kidneys showing their typical bean-shaped appearance.

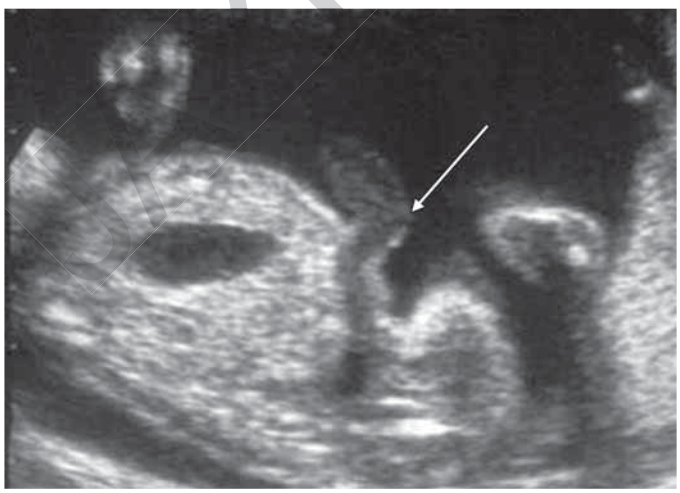

**Fig. 27:** Abdominal insertion of the umbilical cord.

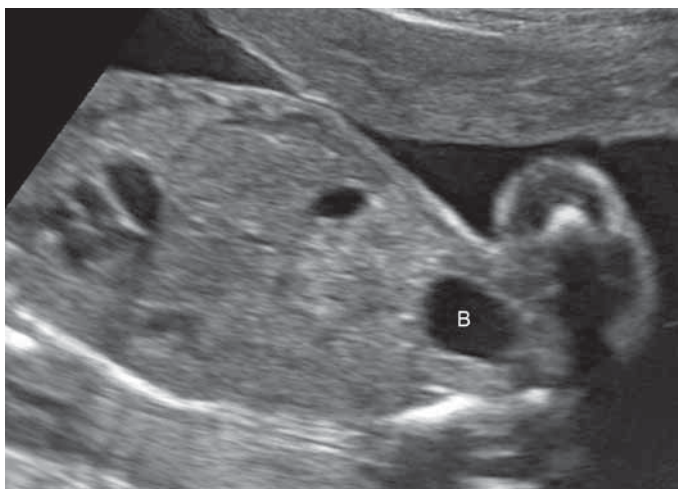


**Fig. 30:** The bladder (B) is easily recognized as a roundish cystic structure in the fetal pelvis.

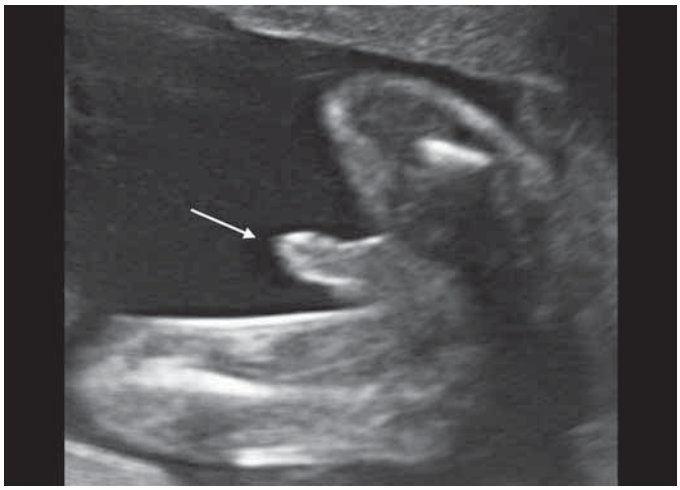

**Fig. 31:** Male genitalia. The arrow points to the penis.

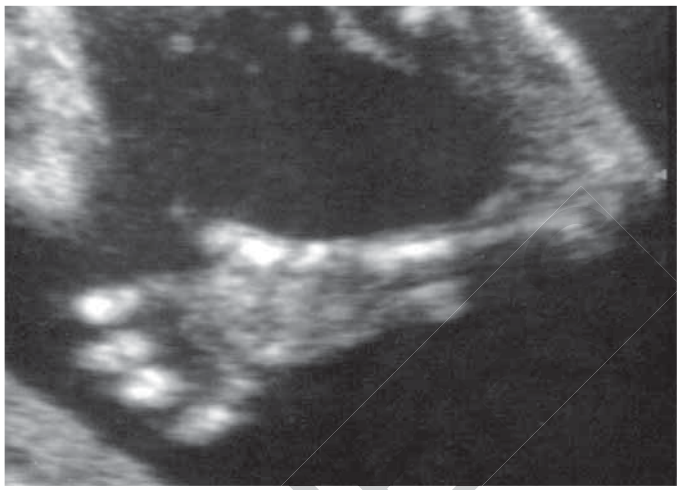

**Fig. 33:** Upper limb.

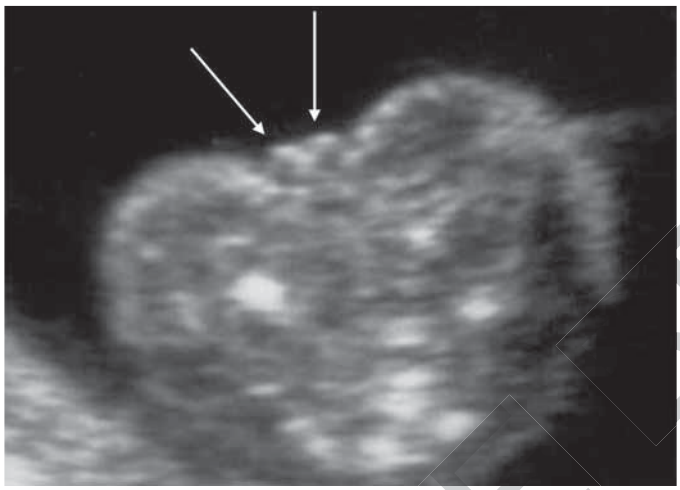

**Fig. 32:** Female genitalia. The arrows point to the labia majora.



**Fig. 34:** Lower limb.

The fetal anatomical features described so far are only a part of the innumerable fetal structures that can be visualized and that will be reported in detail in other section of this book regarding the malformations of the different anatomical systems.

In order to standardize the fetal morphological examination, several scientific societies have suggested guidelines reporting the minimal standards of the fetal structures which should be visualized during a routine scan performed during the second trimester.[3-5]

## Italian Society of Ultrasound in Obstetrics and Gynaecology

*The guidelines of the Italian Society of Ultrasound in Obstetrics and Gynaecology (SIEOG) suggest the visualization and measurement of the following structures[3] as described here* **(Figs. 35A to M)**.

### *Head and Face*

- Measurement of the BPD and head circumference (it means that a correct scan of the skull and brain has been obtained showing the integrity of the calvarium, the cavum septi pellucidi, the thalami, the falx, and the symmetry of the two cerebral hemispheres)
- Measurement of the atrial width (it means that the lateral ventricles have been evaluated)
- Measurement of the transverse cerebellar diameter (it means that the normality of the posterior fossa has been checked)
- Visualization of the orbits
- Visualization of the upper lip.

### *Spine*

Longitudinal view of the spine.

### *Chest*

- Visualization of the lungs on a transverse scan
- "Situs cardiacum"
- "Four-chamber" view
- Left outflow tract
- Right outflow tract.

JAYPEE BROTHERS

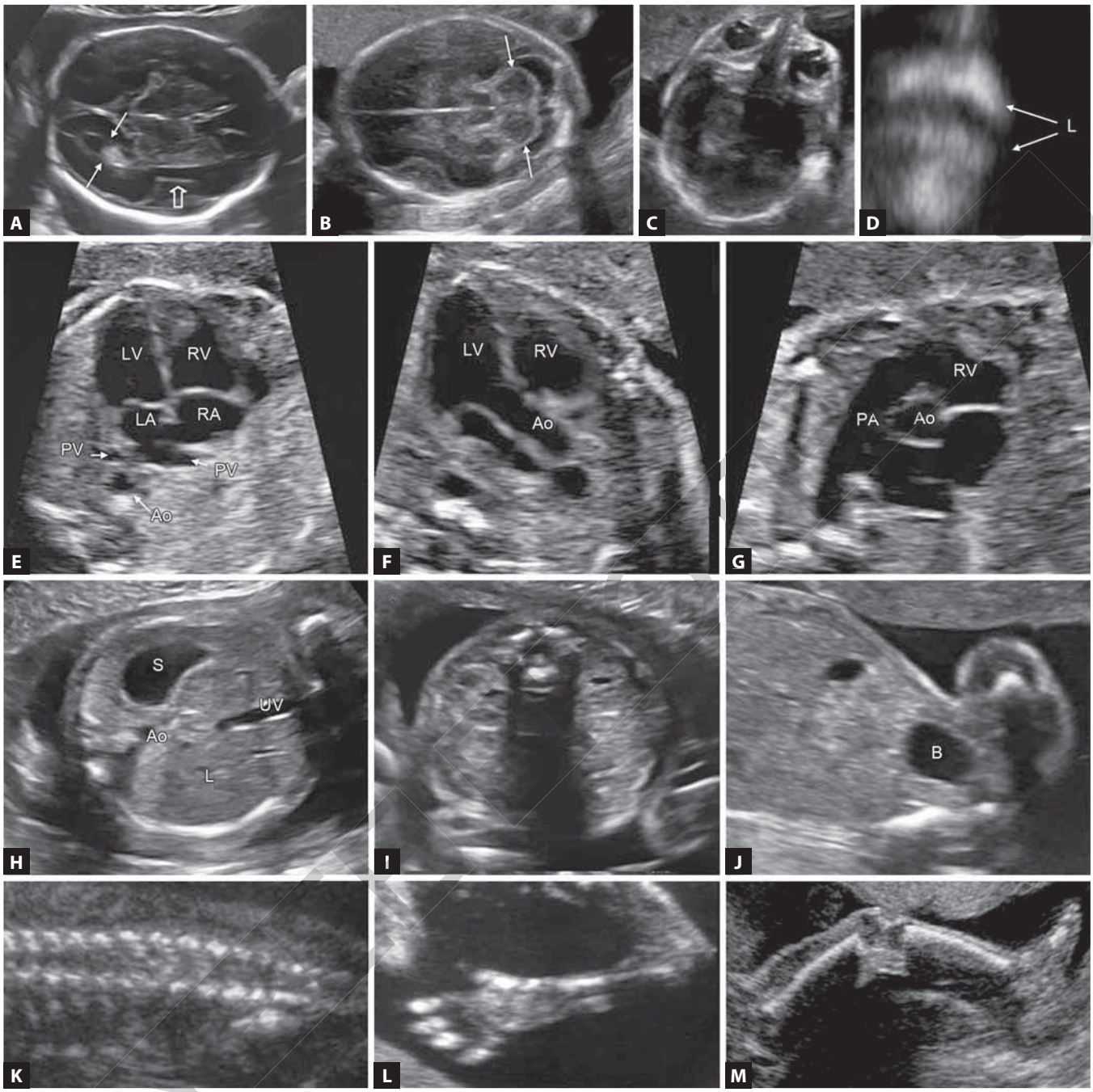


**Figs. 35A to M:** Minimal standards for fetal anatomical survey during the second trimester required by the guidelines of the Italian Society of Ultrasound in Obstetrics and Gynaecology. (A) Transventricular view; (B) Transcerebellar view; (C) Transorbital view; (D) Upper lip; (E) Four-chamber view; (F) Left outflow tract; (G) Right outflow tract; (H) Transabdominal view with the stomach; (I) Transverse view of the kidneys; (J) Bladder; (K) Longitudinal view of the spine; (L) Upper limb; (M) Lower limb. (Ao: aorta; B: bladder; L: liver; LA: left atrium; LV: left ventricle; PV: pulmonary veins; RA: right atrium; RV: right ventricle; S: stomach; UV: umbilical vein).

### *Abdomen*

- Measurement of the abdominal circumference
- Visualization of the stomach and the anterior abdominal profile
- Visualization of the kidneys and bladder.

### *Limbs*

- Visualization of the long bones of the four limbs
- Visualization of the hands and feet (present/absent) without counting the fingers
- Measurement of the femur length.

## American Institute of Ultrasound in Medicine

*The guidelines of the American Institute of Ultrasound in Medicine (AIUM)[4] suggest the visualization of the following structures as described here.*

### *Head, Face, and Neck*

- Cerebellum
- Choroid plexus
- Cisterna magna
- Lateral cerebral ventricles
- Midline falx
- Cavum septi pellucidi
- Upper lip.

*Comment*: A measurement of the nuchal fold may be helpful during a specific age interval to suggest an increased risk of aneuploidy.

### *Chest*

The basic cardiac examination includes a four-chamber view of the fetal heart.

If technically feasible, views of the outflow tracts should be attempted as part of the cardiac screening examination.

### *Abdomen*

- Stomach (presence, size, and situs)
- Kidneys
- Bladder
- Umbilical cord insertion site into the fetal abdomen
- Umbilical cord vessel number.

### *Spine*

Cervical, thoracic, lumbar, and sacral spine.

### *Extremities*

*Legs and arms*: Presence or absence.

### *Sex*

Medically indicated in low-risk pregnancies only for evaluation of multiple gestations.

## International Society of Ultrasound in Obstetrics and Gynecology

*Minimum requirements for the basic fetal anatomic survey during the midtrimester of pregnancy according to the guidelines of the International Society of Ultrasound in Obstetrics and Gynecology (ISUOG)[5] are the following as described here.*

### *Head*

*Skull*: Size, shape, integrity, and bone density of the skull are visualized at the time of the head measurements and when the brain is evaluated for anatomic integrity.

*Brain*: Two axial planes permit visualization of the cerebral structures relevant to the anatomic integrity of the brain. These planes are commonly referred to as the transventricular and transthalamic planes. A third axial transcerebellar plane can be added to evaluate the posterior fossa. The following brain structures should be evaluated:

- Lateral ventricles (including choroid plexi)
- Cavum septi pellucidi
- Thalami
- Cerebellum
- Cisterna magna.

### *Face*

Suggested views for minimum evaluation of the fetal face include the presence of both orbits, evaluation of the nose/nostrils, and presence of the mouth. If technically feasible, a median facial profile view can be obtained.

### *Neck*

Detailed neck anatomy is not part of the screening examination although this region can be evaluated in transverse and sagittal planes. This structure should be cylindrical with no protuberances, masses, or fluid collections.

### *Thorax*

The shape should be regular with a smooth transition to the abdomen. The ribs should have normal curvature without deformities. Both lungs should appear homogenous and without evidence for mediastinal shift or the presence of masses. The diaphragmatic interface can often be visualized as a hypoechoic dividing line between the thoracic and abdominal content (e.g., liver and stomach).

### *Heart*

*"Basic cardiac" examination*: The basic cardiac screening examination is interpreted from a four-chamber view of the fetal heart. A normal regular rate ranges from 120 to 160 beats/min. The heart should be located in the left chest (same side as the fetal stomach) if the situs is normal. A normal heart is usually no larger than one-third the area of the chest and without pericardial effusion. The heart is normally deviated about 45 ± 20 degrees (2 SD) toward the left side of the fetus.

*"Extended basic" cardiac examination*: This includes the aortic and pulmonary outflow tracts and can increase the detection rate for major cardiac malformations above those achievable by the four-chamber view alone. These additional views to the basic examination are more likely to identify conotruncal anomalies. Normal great vessels are approximately equal in size and should cross each other as they exit from their respective ventricular chambers.

Some investigators have described an optional "three-vessels and trachea view" that may also be useful for evaluating the pulmonary artery, ascending aorta, and right superior vena cava in terms of their relative sizes and anatomic relationships.

JAYPEE BROTHERS

### *Abdomen*

The situs of abdominal organs should be determined. The fetal stomach should be identified in its normal position on the left side.

The following should be routinely imaged:

- Stomach
- Bowel
- Umbilical cord insertion and intact abdominal wall
- Three-vessel cord.

### *Kidneys and Bladder*

The fetal bladder and both kidneys should be identified. If either the bladder or renal pelvis appear enlarged, a measurement should be documented. Persistent failure to visualize the bladder should prompt a referral for a more detailed assessment.

### *Spine*

The detailed examination of the fetal spine requires expertise and meticulous scanning, and the results are heavily dependent upon the fetal position. Therefore, a full-detailed evaluation of the fetal spine from every projection is not a part of the basic examination. The most frequent of the severe spinal abnormalities, open spina bifida, is usually associated with abnormal intracranial anatomy such as a no visualized cisterna magna. However, a longitudinal section of the fetal spine should always be obtained because it may reveal at least in some cases other spinal malformations including vertebral abnormalities and sacral agenesis.

### *Limbs and Extremities*

The presence or absence of both arms/hands and both legs/feet should be documented using a systematic approach. Counting fingers or toes is not required as part of the basic scan.

### *Genitalia*

Characterization of external genitalia, to determine fetal gender, is not considered mandatory in the context of a mid-trimester routine scan. Reporting of gender should be considered only with parental consent and in the context of local practices.

## CONCLUSION

Although many countries have already developed local guidelines for the practice of fetal ultrasonography, there are still many areas of the world where they have not been implemented. This can be related to the availability of qualified examiners and equipment, local practices, legal considerations, and costs related to reimbursement. Nonetheless, a WHO Study Group[6] stated: "Worldwide, it is likely that much of the ultrasonography currently performed is carried out by individuals with in fact little or no formal training". It is desirable, therefore, that the use of guidelines in performing mid-trimester anomaly scan becomes a common worldwide practice. It in fact allows the performance of a good level basic examination with the correct selection of patients, which should be referred to a second level center.

## REFERENCES

1. Kalousek DK, Lau AE. Development of the embryo, fetus and placenta. In: Dimmick JE, Kalousek DK (Eds). Developmental Pathology of the Embryo and Fetus. New York: JB Lippincott Co. 1992;1-25.
2. Staudach A. Fetal Echo-anatomy. Berlin: Springer-Verlag; 1989.
3. SIEOG. (2010). Linee Guida 2010. Available from: www.sieog.it [Last accessed April 2022].
4. AIUM (2007). Practice guidelines for the performance of obstetric ultrasound examination. Available from: www.aium.org [Last accessed April 2022].
5. ISUOG practice guidelines for performance of the routine mid-trimester fetal ultrasound examination (2010). Available from: www.isuog.org. [Last accessed April 2022].
6. World Health Organization (1998). Training in diagnostic ultrasound: essentials, practice, and standards. Geneva: World Health Organization (WHO Technical report Series, No. 875). [online] Available from: https://apps.who.int/iris/handle/10665/42093 [Last accessed April, 2022].

JAYPEE BROTHERS

for detailed information on obstetrics & gynecology books, visit our website www.jaypeebrothers.com, for detailed information on obstetrics & gy

*Donald School*

# Basic Textbook of Ultrasound in Obstetrics and Gynecology

***Salient Features***

- Serves as a basic understanding of the wide diagnostic capability of ultrasonography in obstetrics and gynecology
- Several new chapters have been added in order to cover in a simple and basic way all aspects of ultrasound in obstetrics and gynecology
- An essential educational tool not only for physicians involved in fetal medicine, gynecology and infertility, but also for ultrasound technicians and midwifes
- The basic knowledge of ultrasonography in obstetrics and gynecology following the reading of this book can be expanded by reading the more specialized books of the rich Donald School Library.

**Vincenzo D'Addario** is an Associate Professor, Department of Obstetrics and Gynecology, University Medical School, Bari, Italy. He is teaching at the Ian Donald School since its foundation in 1982 and was Director of the Italian Branch of the School. He is the Past President of the Italian Society of Ultrasound in Obstetrics and Gynecology, Honorary Member of several international ultrasound societies and Fellow of the International Academy of Perinatal Medicine.



**Asim Kurjak** is a Professor, Department of Obstetrics and Gynecology, Medical School Universities of Zagreb, Zagreb, Croatia and Professor Emeritus, University Sarajevo School of Science and Technology, Sarajevo, Bosnia and Herzegovina. He published 1,175 papers which have been cited more than 15,000 times (Google Scholar bases) and authored, co-authored or co-edited 123 books. He is the President of International Academy of Perinatal Medicine, President of International Academy of Science and Art in Bosnia and Herzegovina, and the Director of Ian Donald Inter-University School of Medical Ultrasound. He received doctorum honoris causa from Universities in Banja Luka, Budapest, Barcelona, Bucharest, Athens, Montevideo, Tomsk, Buenos Aires, St Petersburg, Moscow, Tirana, and Khartoum.



**Giuseppe Rizzo** is Full Professor of Obstetrics and Gynecology at Tor Vergata University, Rome, Italy and Chairman of the Department of Obstetrics and Gynecology, Fondazione Policlinico Tor Vergata, Rome. He is the Past President of the Italian Society of Ultrasound in Obstetrics and Gynecology, Honorary Member of several International Ultrasound Societies, Fellow of the International Academy or Perinatal Medicine.



*Printed in India*

**Available at all medical bookstores or buy online at www.jaypeebrothers.com**

**JAYPEE BROTHERS**
**Medical Publishers (P) Ltd.**
**EMCA House, 23/23-B, Ansari Road,**
**Daryaganj, New Delhi - 110 002, INDIA**
**www.jaypeebrothers.com**

Join us on facebook.com/JaypeeMedicalPublishers

Shelving Recommendation
**OBSTETRICS & GYNECOLOGY**

ISBN 978-93-5465-578-4