isit our website www.jaypeebrothers.com, for detailed information on surgery books, visit our website www.jaypeebrothers.com

diginerve
A Jaypee Initiative
Your Guide at Every Step
Video Lectures | Notes | Self-Assessment
Scan code to check out courses

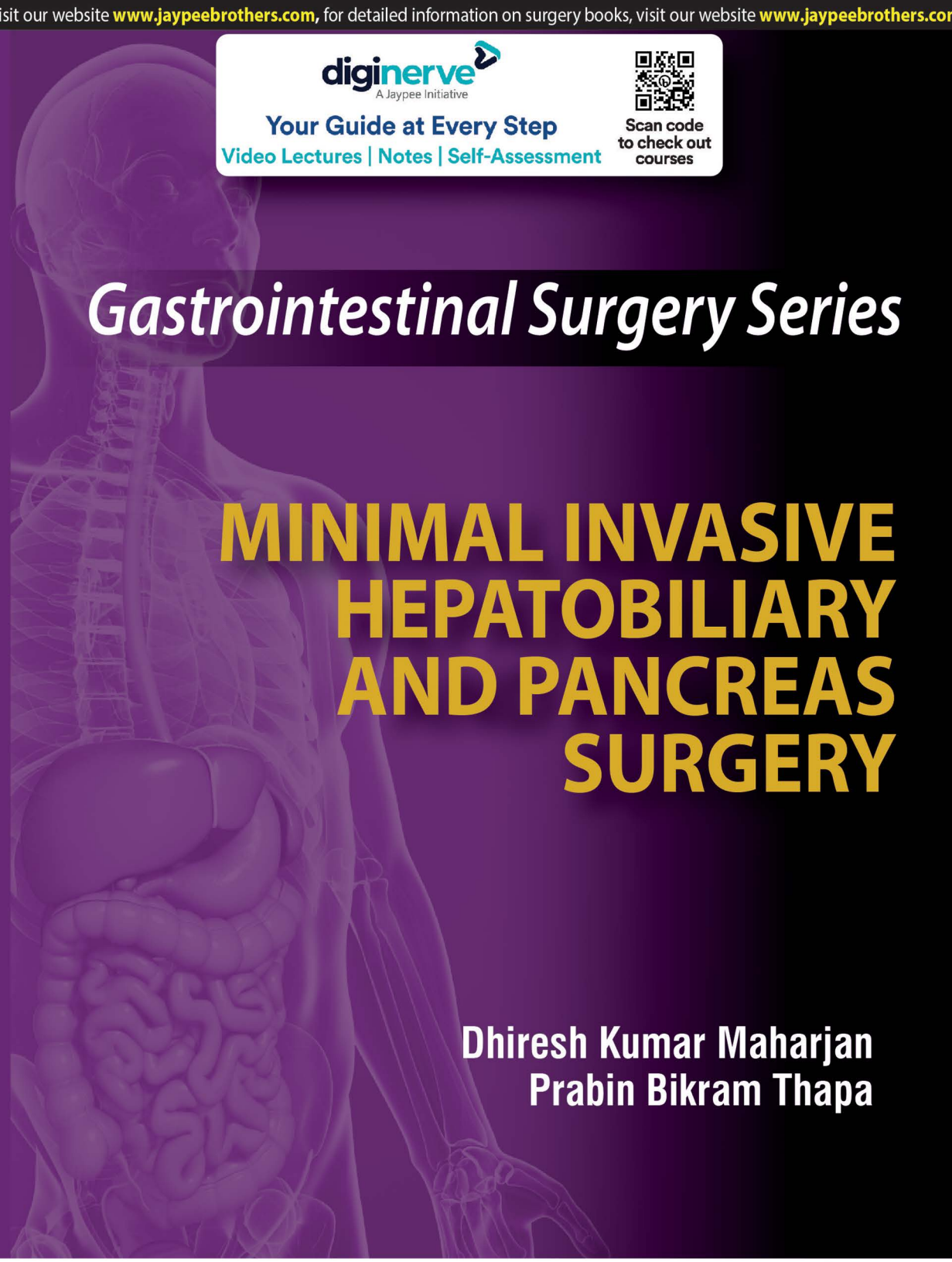

## Gastrointestinal Surgery Series

# MINIMAL INVASIVE HEPATOBILIARY AND PANCREAS SURGERY

Dhiresh Kumar Maharjan
Prabin Bikram Thapa

*Foreword*
**Samiran Nundy**

JAYPEE

# Contents


1. **Anesthetic Viewpoints in Laparoscopic Liver Resection ..... 1**
   *Babu Raja Shrestha, Sushila Lama Moktan*

2. **Intraoperative Bleeding Control during Laparoscopic Liver Resections ..... 6**
   *Ioannis Triantafyllidis, Maud Neuberg, Yoshikuni Kawaguchi, Marc Beaussier, Brice Gayet, David Fuks*

3. **Initiating Laparoscopic Hepatectomy in Low-volume Center ..... 14**
   *Saseem Poudel, Naoto Senmaru, Satoshi Hirano*

4. **Role of Indocyanine Green in Laparoscopic Liver Surgery .... 20**
   *Katherine M Panganiban, Catherine SC Teh*

5. **Laparoscopic Right Hepatectomy ..... 32**
   *Fumiaki Tokito, Yusuke Ome, Goro Honda, Masakazu Yamamoto*

6. **Minimal Invasive Treatment for Colorectal Liver Metastases ..... 37**
   *Giovanni M Garbarino, Giammauro Berardi*

7. **Minimally Invasive Surgery in Gallbladder Carcinoma ..... 50**
   *Yugal Limbu, Sujan Regmee, Roshan Ghimire*

8. **Changing Trends in Minimal Invasive Pancreatic Surgery ..... 57**
   *Savio George Barreto*

9. **Laparoscopic Pancreaticoduodenectomy ..... 65**
   *Siddhartha Mishra, Rajesh Bhojwani*

10. **Initiating Robotic Pancreaticoduodenectomy ..... 78**
    *Ruchit H Kansaria, Manish S Bhandare, Vikram Chaudhari, Ammiel Arra, Shailesh V Shrikhande*

11. **Minimally Invasive Distal Pancreatectomy ..... 105**
    *Christoph Berchtold, Thilo Hackert*

12. **Minimally Invasive Approach to Chronic Pancreatitis ..... 115**
    *Shreeyash Modak, GV Rao*

*Index* ..... **123**

CHAPTER

# 3 Initiating Laparoscopic Hepatectomy in Low-volume Center

*Saseem Poudel, Naoto Senmaru, Satoshi Hirano*

## INTRODUCTION

Reich et al.[1] reported the first laparoscopic partial hepatectomy in 1991 and laparoscopic left lateral sectionectomy was reported independently by Azagras et al.[2] and Kaneko et al.[3] in 1996. Since then, laparoscopic hepatectomy has been widely adopted in developed countries especially for partial hepatectomies and left lateral sectionectomy. Meta-analyses have shown laparoscopic hepatectomies to have less blood loss and complications, shorter hospital stay with similar or longer operation time compared to open hepatectomies.[4,5] It allows for magnified view of various anatomy, especially for the liver inside the ribcage. Pneumoperitoneum helps reduce the intraoperative bleeding. However, it should be noted that the studies published are from high-volume centers with expertise in both laparoscopic surgery and hepatobiliary surgery. There are concerns of cost, technical difficulty, and lack of overview that need to be addressed while adopting laparoscopic hepatectomies in low-volume centers, especially in context of developing countries.

## COST

Laparoscopic hepatectomy requires many energy devices to maintain hemostasis. It is not unusual for both the surgeon and assistant using as many as three energy devices at the same time. Energy devices commonly used are: Laparoscopic Clarity Ultrasonic Surgical Aspirator System (CUSA®), laparoscopic ultrasonic sears (Harmonic Scarpel®), advanced bipolar vessel sealing device (Ligasure®), and advanced coagulation modes in cautery. All of these have initial setup cost as well as the cost of disposable units used in each operation. Laparoscopic hepatectomy also requires laparoscopic ultrasound device to locate the tumor and vessels as well as staplers to divide major vessels in major hepatectomies.

A study by Cipriani et al.[6] showed that these costs are however offset by shorter hospital stay, lower rate of transfusion, less investigation, and lower severe complications and readmission. However, it should be noted that the study is from western scenario where the cost of hospital stay and instrument differ from the cost in Nepal. Also, the study has reported that the cost becomes higher with conversion cases. So, it is important to first select the cases with a less probability of conversion.

JAYPEE BROTHERS

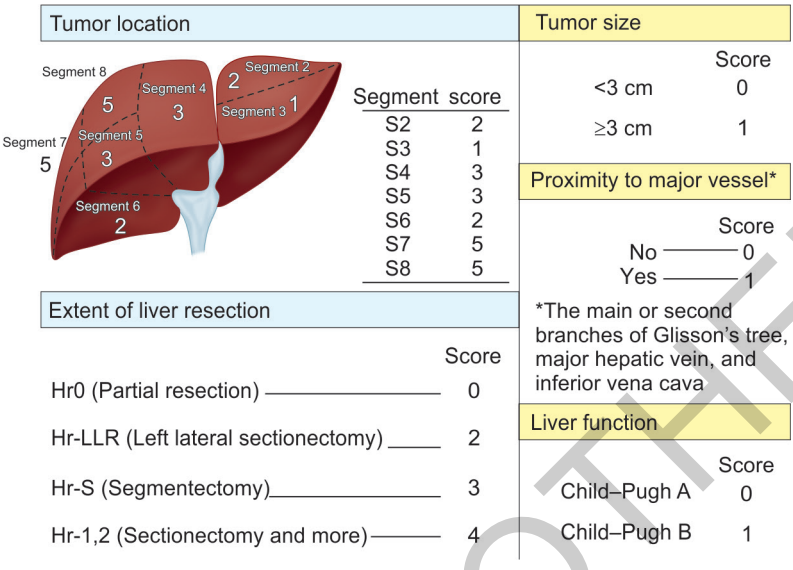


**Fig. 1:** Technical difficulty scoring system by Ban et al.[7]

## TECHNICAL DIFFICULTY

All segments of the liver are not equally accessible and suited for laparoscopic hepatectomy. Ban et al.[7] came up with the technical difficulty scoring system based on the location of the tumor, extent of liver resection, size of the tumor, proximity to major vessels, and liver function **(Fig. 1)**. For the surgeons starting laparoscopic liver resections and with the experience of <10 cases of laparoscopic liver resection, it is recommended to start with liver resection with low difficulty such as simple and small partial hepatectomies in Section 3. Anterior and lateral segments are more accessible laparoscopically than posterior and superior segments. Lesions in these regions can be a good starting point for surgeons starting with laparoscopic hepatectomy.

As the surgeon who can consistently perform "low difficulty" liver resection cases with experience of 10–50 liver resections can move to intermediate difficulty liver resection cases such as left lateral sectionectomy. This has relatively a small transection plane which lies caudal to cranial direction making it easily accessible with traditional laparoscopic port placement. For surgeons who can consistently perform intermediate difficulty level laparoscopic liver resection cases and with the experience of >50 laparoscopic liver resection cases can attempt high difficulty cases such as simple hemihepatectomy. The study also recognizes difficulty score of 10 as the technical limitation of current laparoscopic surgery.

Laparoscopic hepatectomy has a long learning curve of 45–75 cases for major hepatectomy.[8-10] It is recommended to be attempted in high-volume centers with dedicated teams. Even with the dedicated team complications can occur if the technical limitations are not taken into consideration. In one

JAYPEE BROTHERS

case series in Japan, which has defined the adaptation of laparoscopic liver resection in the country, a team performed 92 cases in three and a half year. However, 58 cases were complex cases and they had eight mortality including four mortality in the first year itself. This led to an external investigation which found that they had not performed adequate preoperative evaluations on liver function. Discussions among the groups were inadequate and external evaluations were also inadequate. The investigation panel recommended adequate preoperative evaluation for every case: Discussion within the group on the operative indication and surgical plan, adequate informed consent with the patient and the family, and to have a national registry for all the cases. Following the recommendation, Japanese Society of Gastroenterological Surgery has started an online registry where all the cases of laparoscopic hepatectomy, except for partial hepatectomy and left lateral sectionectomy, must be registered preoperatively with the intended surgical plan to maintain external evaluation of the surgical indication. Surgical data and complications must be registered once the surgery is completed and the patient is discharged. This type of national registry system maintains the quality of the surgery performed in the country.

## LACK OF OVERVIEW

One of the major concerns of laparoscopic surgery compared to open surgery is a lack of overview. While we get magnified views of the several small vessels, it is often easy to lose track of the anatomy. Especially in hepatectomy, losing track of anatomy and deviating from the intended line of resection can result into injuring major vessels or tumor. Several technologies can help the surgeon to keep track of the anatomy during resection. Laparoscopic ultrasound should be routinely performed to check for the location of tumor, major vessels, and their relationship with the intended line of resection. Preoperative simulation with three-dimensional (3D) computed tomography (CT) can help surgeons to understand the anatomy and what to expect in the line of resection **(Fig. 2)**. In recent years, an advancement in fluoroscopy has made it possible to use indocyanine green (ICG) preoperatively to check the location of the tumor during resection or use it after clamping the Glisson to check for the demarcation line.

## OUR EXPERIENCE

Steel Memorial Muroran Hospital is a small community-based hospital with around 600 gastrointestinal surgeries every year with nearly 80% of them being laparoscopic surgery. We are a low-volume center and perform roughly 10–15 laparoscopic liver resections every year.

Our approach to laparoscopic hepatectomy has been pure laparoscopic from the beginning. While with hand-assisted methods and hybrid approach can help compensate for the technical aspects of laparoscopic hepatectomy,

JAYPEE BROTHERS

it loses the benefits of laparoscopic surgery such as reduced blood loss and complications. It is important to become technically proficient in laparoscopic surgery before attempting laparoscopic liver resections. Animal training are highly useful in mastering new techniques and are highly recommended even for the experienced laparoscopic surgeons before they attempt new advanced surgeries.

Cadaver training is another way to get accustomed to the anatomy; however, in liver resection, one of the major concerns is hemostasis, which cannot be replicated in cadaver trainings. As laparoscopic hepatectomy is a team surgery, training with the team is important. Visiting high-volume centers and observing their techniques, management of instruments and complications can also be very educational for the centers looking forward to introducing laparoscopic hepatectomies.

For all liver resections, our preoperative evaluations include contrast CT scans and magnetic resonance imaging (MRI) scans, ultrasonography, blood work up, and liver function is tested using ICG 15 minutes retention test. This is a simple test where the patient is injected with 0.5 mg/kg of ICG into peripheral blood vessel and blood sample taken exactly 15 minutes after the injection from another site is tested for the level of ICG. The result of ICG determines resection limitation of the patients according to the Makuuchi criteria (**Flowchart 1**).[11] We use Synapse Vincent™ software by FUJIFILM to create a 3D image of the liver and its vessels and simulate the plane of

**Flowchart 1:** Makuuchi criteria for liver resection.[11]

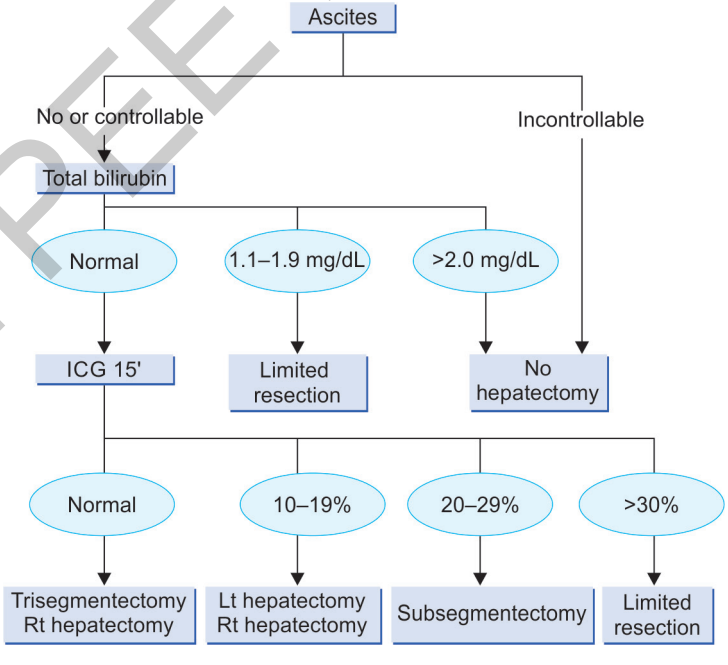


JAYPEE BROTHERS

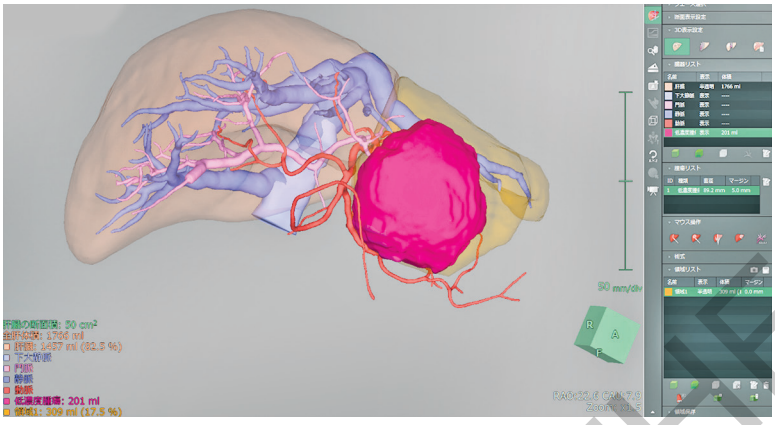

**Fig. 2:** Three-dimensional (3D) computed tomography (CT) using SYNAPSE Vincent Software™.

resection preoperatively **(Fig. 2)**. This image helps us navigate during the surgery. This software also helps us calculate the liver volume and the expected volume of remaining liver after the resection. We can do simulation with various lines of resections and surgical technique and check for the volume of the remnant liver. This along with the liver function tests helps us determine the best possible surgery for the patient and minimizing the risk of posthepatectomy hepatic failure.

As in open resections, we employ Pringle maneuver in almost all of laparoscopic hepatectomies. Avascular plane of lesser omentum is first divided, then a rubber vessel tape is passed through the Winslow foramen to tape the hepatoduodenal ligament. This tape is pulled out of one of the 5 mm ports and the port is removed. The tape is passed through a rubber tube which is then introduced into to the abdomen. Pulling the vessel tape and pushing the rubber tube is used to clamp the hepatoduodenal ligament **(Fig. 3)**.

For liver resections, we employ the combinations of clamp crush technique using Biclamps® or Ligasure® or using CUSA®. With Biclamps® and CUSA®, the assistant uses Harmonic scalpel® to divide the small vessels and soft coagulation mode for hemostasis. Medium vessels are clipped and divided. Larger vessels such as main branches of Glisson and main hepatic veins are divided using staplers. Navigation using 3D CT and laparoscopic ultrasound is done regularly to check for the location of the tumor and vessels and our line of resection.

## CONCLUSION

Laparoscopic hepatectomy has many advantages over open hepatectomy. However, before starting with laparoscopic hepatectomy, we need to consider the case volume of the center, the difficulty of the case we are attempting, the experience and laparoscopic technical expertise of the surgeon and the

JAYPEE BROTHERS

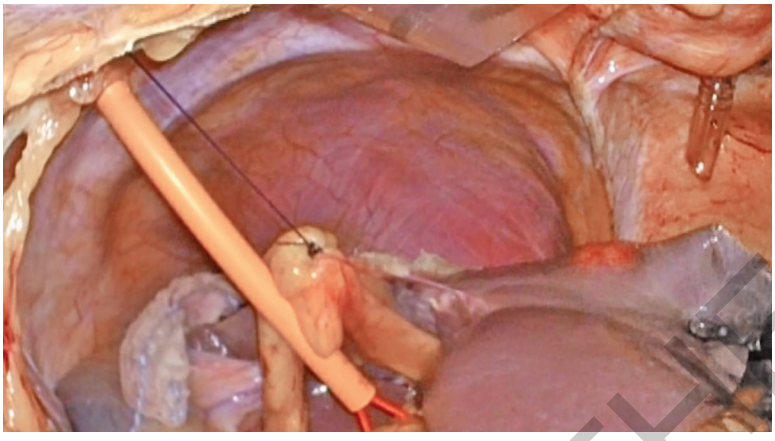

**Fig. 3:** Pringle maneuver.

surgical team involved in the surgery and the bailout method when things do not work out.

## REFERENCES


1. Reich H, McGlynn F, DeCaprio J, Budin R. Laparoscopic excision of benign liver lesions. Obstet Gynecol. 1991;78(5 Pt 2):956-8.
2. Azagra JS, Goergen M, Gilbart E, Jacobs D. Laparoscopic anatomical (hepatic) left lateral segmentectomy-technical aspects. Surg Endosc. 1996;10(7):758-61.
3. Kaneko H, Takagi S, Shiba T. Laparoscopic partial hepatectomy and left lateral segmentectomy: technique and results of a clinical series. Surgery. 1996;120(3):468-75.
4. Xu H, Liu F, Li H, Wei Y, Li B. Outcomes following laparoscopic versus open major hepatectomy: a meta-analysis. Scand J Gastroenterol. 2017;52(12):1307-14.
5. Jin B, Chen MT, Fei YT, Du SD, Mao YL. Safety and efficacy for laparoscopic versus open hepatectomy: a meta-analysis. Surg Oncol. 2018;27(2):A26-34.
6. Cipriani F, Ratti F, Cardella A, Catena M, Paganelli M, Aldrighetti L. Laparoscopic versus open major hepatectomy: analysis of clinical outcomes and cost effectiveness in a high-volume center. J Gastrointest Surg. 2019;23(11):2163-73.
7. Ban D, Kudo A, Ito H, Mitsunori Y, Matsumura S, Aihara A, et al. The difficulty of laparoscopic liver resection. Updates Surg. 2015;67(2):123-8.
8. Brown KM, Geller DA. What is the learning curve for laparoscopic major hepatectomy? J Gastrointest Surg. 2016;20(5):1065-71.
9. Hong SK, Suh KS, Yoon KC, Lee JM, Cho JH, Yi NJ, et al. The learning curve in pure laparoscopic donor right hepatectomy: a cumulative sum analysis. Surg Endosc. 2019;33(11):3741-8.
10. Nomi T, Fuks D, Kawaguchi Y, Mal F, Nakajima Y, Gayet B. Learning curve for laparoscopic major hepatectomy. Br J Surg. 2015;102(7):796-804.
11. Makuuchi M, Kosuge T, Takayama T, Yamazaki S, Kakazu T, Miyagawa S, et al. Surgery for small liver cancers. Semin Surg Oncol. 1993;9(4):298-304.


JAYPEE BROTHERS

for detailed information on surgery books, visit our website **www.jaypeebrothers.com,** for detailed information on surgery

*Gastrointestinal Surgery Series*

# MINIMAL INVASIVE HEPATOBILIARY AND PANCREAS SURGERY

*Gastrointestinal Surgery Series: Minimal Invasive Hepatobiliary and Pancreas Surgery* is a book covering extensive technical issue during laparoscopic HPB (Hepato-Pancreatico-Biliary) surgery including anesthesiologist viewpoint along with managing bleeding during laparoscopic liver resection which is nightmare for laparoscopic HPB surgeons. It has well-descriptive pictorial approach discussed about robotic and laparoscopic Whipple's operation along with laparoscopic extended cholecystectomy for carcinoma of gallbladder targeting for postgraduate students and young aspiring HPB surgeons.

**Dhiresh Kumar Maharjan** MRCS (Ed) FCPS is an Associate Professor affiliated to Department of General and GI Surgery, Kathmandu Medical College and Teaching Hospital, Sinamangal, Kathmandu, Nepal. He has been involved with various academic as well as clinical research activities with key publishing articles about laparoscopic extended cholecystectomy for early gallbladder cancer (one of the few papers from South-East Asia) and importance of Apical Tissue in Triangle Surgery during Whipple's Operation. He has been key personal to start genetic research in carcinoma of gallbladder and pancreas in collaboration with national and international scientific organization along with propagating minimal invasive pancreatic surgery for malignancy and chronic pancreatitis. He has been a part of BMJ Awards South Asia as a Jury member.

**Prabin Bikram Thapa** MS is a Professor of Department of General and GI Surgery, Kathmandu Medical College and Teaching Hospital, Sinamangal, Kathmandu, Nepal. His extensive clinical research encircles exclusively in the field of hepatobiliary and pancreatic surgery with introduction of many noble techniques in surgical fraternity of Nepal including laparoscopic Whipple's operation, use of ICG during laparoscopic liver resection, single incision laparoscopic surgery and enhanced recovery after surgery (ERAS) in gastrointestinal surgery. In Nepal, he has the distinction of pioneering advance laparoscopic surgery and for this achievement, he has been awarded Young Scientist Award by Nepal Academy of Science and Technology (NAST). Besides he has been invited as guest speaker in different national and international conference.

*Printed in India*

**Available at all medical bookstores**
**or buy online at www.jaypeebrothers.com**




**JAYPEE BROTHERS**
**Medical Publishers (P) Ltd.**
**EMCA House, 23/23-B, Ansari Road,**
**Daryaganj, New Delhi - 110 002, INDIA**
**www.jaypeebrothers.com**

Join us on facebook.com/JaypeeMedicalPublishers

Shelving Recommendation
**SURGERY**

