ypeebrothers.com, for detailed information on medicine books, visit our website www.jaypeebrothers.com, for detailed information on medicine books

Manual of Lab Investigations *in* Rheumatic Diseases

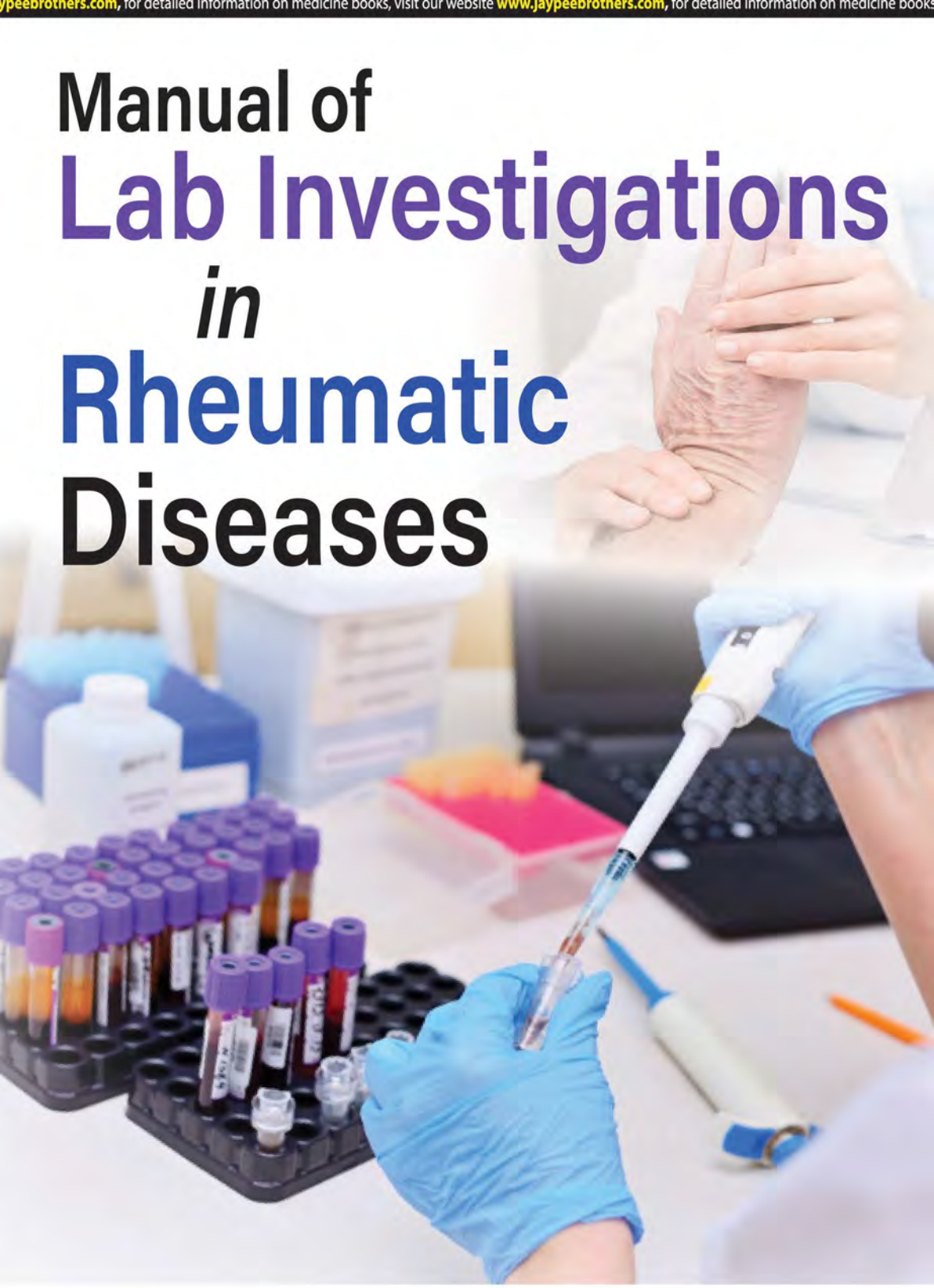

Sham Santhanam

Foreword
S Rajeswari

JAYPEE

Contents

Chapter 1: Laboratory Investigations in Rheumatic Diseases: Choosing Wisely **1**

Vijaya Prasanna Parimi, Vinod Ravindran

- Choosing the Initial Investigations *1*
- Types of Tests *1*
- Choosing Wisely *1*
- Performance of Diagnostic Tests *2*
- Interpretation of Serological Tests *3*
- Factors Responsible for Random Investigations without Careful Judgment *4*

Chapter 2: Autoantibodies in Rheumatoid Arthritis **7**

Raja Natarajan

- Rheumatoid Factor *7*
- Anticitrullinated Protein Antibody *9*
- Other Autoantibodies and their Clinical Significance *12*

Chapter 3: Antinuclear Antibody (ANA) **15**

Kavitha Mohanasundaram, Pooja Nair

- Indications for Antinuclear Antibody Testing *15*
- Detection of Antinuclear Antibodies: Indirect Immunofluorescence Assay *16*
- Patterns of ANA and Association with Various Diseases *17*

Chapter 4: Antinuclear Antibody (ANA)/Extractable Nuclear Antigen (ENA) Profile **30**

Sowndhariya V Annamalai, Sujatha Narayanan

- Indications for Specific ANA Testing *30*
- Methods of Detection of ENA Antibodies *31*
- Method of Choice for ANA/ENA Profile *33*
- Limitations of ENA Profile *34*

Chapter 5: Antineutrophil Cytoplasmic Antibodies (ANCA) **37**

Karthikeyan Subbian, Sham Santhanam

- ANCA Pattern and Antigenic Targets *37*
- Concept Behind ANCA IIF Patterns *40*
- Pitfalls of ANCA IIF Test *40*
- Method of Choice in ANCA Testing (IIF versus ELISA) *40*
- Recommendations to do ANCA Testing *41*
- Clinical Importance of ANCA Titers *42*

Chapter 6: Immunofluorescence and Autoantibodies in Rheumatic Diseases: Tips and Traps 45

Sunitha KG

- Indirect Immunofluorescence *46*
- Antinuclear Antibodies *47*
- Antineutrophil Cytoplasmic Antibodies *50*
- Troubleshooting of Indirect Immunofluorescence *51*
- Antiglomerular Basement Membrane Antibodies *59*

Chapter 7: Evaluation of Antiphospholipid Syndrome 63

Vignesh Mantharam

- Classification Criteria *63*
- Diagnostic Testing for Antiphospholipid Syndrome *63*
- Clinical Significance of Antiphospholipid Antibodies *68*
- Other Laboratory Investigations *69*

Chapter 8: Human Leukocyte Antigen-B27 (HLA-B27) 72

Bhuvanesh M, Rajesh S

- Structure *72*
- Prevalence *72*
- Pathogenic Mechanisms in Disease *72*
- Role in Health *74*
- Testing Methods *74*
- Diagnostic Implications *76*
- Prognostic Utility *78*
- Busting Myths *79*

Chapter 9: Acute-Phase Reactants—Part 1 81

Pranav Raman Chickermane, Mithun CB *81*

- Erythrocyte Sedimentation Rate *81*
- C-reactive Protein *83*
- Complement Proteins: C3 and C4 *85*

Chapter 10: Acute-Phase Reactants—Part 2 91

Pratyusha Rajavarapu, Keerthi Talari

- Serum Ferritin *91*
- Interleukin-6 *92*
- Serum Amyloid A Protein *93*
- Haptoglobin *93*

- Fibrinogen *94*
- Calprotectin *94*

Chapter 11: Miscellaneous—Part 1 **99**

Parthajit Das

- Hemogram (Hemoglobin, Red Blood Cell Indices, White Blood Cell Count, Platelets) *99*
- Peripheral Smear *102*
- Uric Acid *105*
- Liver Enzymes (Alanine Aminotransferase, Aspartate Aminotransferase, Lactate Dehydrogenase) *106*
- Creatine Kinase *108*
- Antistreptolysin O Titer *110*

Chapter 12: Miscellaneous—Part 2 **112**

Balaji Chilukuri, Saranya Chinnadurai

- Serum Cryoglobulins *112*
- Coombs' Test *115*
- Peripheral Smear *117*
- Serum ACE Levels *117*

Chapter 13: Synovial Fluid Analysis **121**

Hema Murugesan, Nishita Manivannan *121*

- Synovial Membrane *121*
- Dynamics of the Synovial Fluid *121*
- Arthrocentesis *122*
- Examination of Synovial Fluid *123*

Chapter 14: Laboratory Investigations in Metabolic Bone Diseases **129**

Sruti Chandrasekaran

- Serum Calcium *129*
- Urinary Calcium *130*
- Phosphorus *130*
- Magnesium *131*
- Bone-specific Alkaline Phosphatase *131*
- 25-Hydroxyvitamin D *132*
- 1,25-Hydroxyvitamin D *132*
- Parathyroid Hormone *132*
- Parathyroid Hormone-related Protein *133*
- Fibroblast Growth Factor 23 *133*
- Bone Turnover Markers *134*

Chapter 15: Risk Assessment Before Initiating Biological and Targeted Synthetic Disease-Modifying Antirheumatic Drugs **137**
Meha Sharma, Bimlesh Dhar Pandey, Mohit Goyal
❖ Approach to Investigations *137*

Index *145*

CHAPTER 3

Antinuclear Antibody (ANA)

Kavitha Mohanasundaram, Pooja Nair

INTRODUCTION

Antinuclear antibody (ANA) testing remains as one of the cornerstones in the diagnosis of autoimmune connective tissue disorders (AICTDs).[1] The testing methodology has evolved over the period of time from enzyme-linked immunosorbent assay (ELISA) to indirect immunofluorescence (IIF) and now on to individual antibodies by line immunoassays (LIAs). ANA testing by IIF remains the basic screening test and gold standard methodology.[1] ANA by itself is not diagnostic of any of the AICTDs and at best is a screening test. A panel of investigations like ANA profile, anti-dsDNA, and complement levels in the background of clinical suspicion are needed for an effective diagnosis. Considering the above fact, ANA should not be ordered upfront when the pretest probability is low. It increases false positivity leading on to further immunological panel testing thereby increasing the cost of health care. ANA is a preclinical antibody, which might predict the onset of a disease even years before the first manifestation. Presence of ANA is of prognostic significance in certain diseases like juvenile idiopathic arthritis (JIA) where its presence increases the risk of uveitis.[1]

This chapter deals with indications for ANA testing, its methodology, patterns of ANA, association of antibodies with patterns and their clinical significance.

INDICATIONS FOR ANTINUCLEAR ANTIBODY TESTING[2]

Conditions where positive ANA helps in diagnosis:

- Systemic lupus erythematosus (SLE) including drug-induced lupus, systemic sclerosis, Sjögren's syndrome, mixed connective tissue disorder, and idiopathic inflammatory myositis
- Pyrexia of unknown origin (PUO)—particularly in young females with pancytopenia
- Raynaud's phenomenon
- Unexplained nephritic and nephrotic syndrome

Conditions where positive ANA aids in prognosis rather than diagnosis:

- Juvenile idiopathic arthritis (ANA positivity confers an additional risk toward uveitis)
- Antiphospholipid syndrome (APS)

JAYPEE BROTHERS

Conditions where ANA forms part of diagnostic criteria (close to 100% positivity):

- Mixed connective tissue disease (MCTD)
- Autoimmune hepatitis
- Drug-induced lupus

Conditions where ANA may be positive but does not add to the prognosis or diagnosis of the disease:

- Rheumatoid arthritis
- Psoriatic arthritis
- Hashimoto's thyroiditis
- Multiple myeloma
- Fibromyalgia

In none of the AICTDs, ANA is used for assessment of disease progression; i.e., once the disease is diagnosed, serial ANA testing during flare of disease or as part of routine periodic investigations is not indicated, whatever the AICTD may be.[2]

DETECTION OF ANTINUCLEAR ANTIBODIES: INDIRECT IMMUNOFLUORESCENCE ASSAY

The indirect immunofluorescence assay (IFA) is the classical technique used for the detection of ANAs since 1957 when George Friou introduced it. It is generally used as a primary screening test for ANA as it enables the detection of a wide range of autoantibodies. Different types of ANA give rise to characteristic staining patterns, depending on the cellular location and properties of the antigenic target.[3] A wide array of substrates were used from time to time such as tissue sections of stomach, liver or kidney cells of murine models, chick red blood cells (RBCs), and HeLa cell. Introduction of HEp-2 cells (squamous cells from human laryngeal carcinoma) or its variant (HEp-2000) further increased the sensitivity of the test. As HEp-2 cells are rapidly dividing, many mitotic cells are present in the prepared slides, allowing detection of antibodies against structures unique to mitotic cells.[3,4] Sometimes, even in case of presence of high titers of autoantibodies such as those directed to SS-A/Ro 60kD, SS-A/Ro 52kD, Jo1, etc., there are chances of yielding false-negative results. This issue was solved to an extent by HEp-2000 cells, which are transfected with information to hyperexpress the 60kD-SS-A/Ro antigen; resulting in more sensitivity over standard HEp-2 substrate.[5]

Another better advanced modality of Biochip-titerplane technique (by Euroimmun) can also be used to detect ANA in patient's serum by IFA. The kit is comprised of slides that are embedded with HEp-20-10 cell and primate liver (monkey hepatocytes) tissue sections. The monospecific substrates can be analyzed in parallel with the HEp-2 cells as Biochip mosaics, thus no additional incubation period is required. The fluorescence patterns of the two

JAYPEE BROTHERS

substrates can be compared and results can be verified reciprocally giving an additional diagnostic security. The primate liver also allows identification of additional autoantibodies, thus aiding in unexpected diagnoses.[6]

As per the manufacturer's protocol, serum is diluted as 1/100 in phosphate buffered saline (PBS)—Tween 20 and is overlaid onto fixed cells (Euroimmun) at room temperature for 30 minutes. Slides are then washed for 10 minutes with PBS—Tween 20 wash buffer, and then overlaid with fluorescence labeled conjugate, which is antihuman immunoglobulin G (IgG), and incubated for another 30 minutes in dark. After washing, a coverslip is placed over the slide, and the slides are read using a fluorescence microscope at 40x objective.[6] The fluorescence intensity is scored semiquantitatively from 1+ to 4+ relative to the intensity of a negative and a positive (3+) control that are supplied in the kit.[7]

In ANA reporting, three parameters have to be taken into consideration: (1) the pattern of the fluorescence, (2) titer of the positive test, and (3) the substrate used. A discernible fluorescence staining pattern indicates ANA positivity but does not allow specific identification of the antibodies. For further identification of fine reactivity (testing for individual antibodies like anti-ds-DNA, anti-Ro, etc.) of the antibodies, additional testing like IIF on Crithidia luciliae (for the detection of anti-dsDNA antibodies), ELISA, immunodiffusion, or LIA (for the detection of extractable nuclear antigens) is required.[7-10] In **Table 3.1**, the advantages and disadvantages of IFA and ELISA techniques have been discussed.

Dilution: ANA screening dilution universally stands at 1:80, some centers do it at 1:100. End dilution titers of ANA testing are reported by certain laboratories (e.g., ANA is positive, speckled pattern, 3+ intensity at a titer of 1:640—here end dilution is 640). In diseases like MCTD where ANA positivity at high dilution is a part of major criteria in the classification of disease, dilution could be useful. When ANA is positive at a higher dilution, the chances that the positivity is associated with an AICTD is high.[1]

PATTERNS OF ANA AND ASSOCIATION WITH VARIOUS DISEASES

For the ease of understanding, the naming nomenclatures are adopted from the consensus guidelines of the International Consensus on ANA Patterns (ICAP) and the alpha-numeric code [referred to as anti cell (AC) followed by a number from 0 to 29] is mentioned for each pattern.[13] The nuclear and cytoplasmic patterns are discussed in the consensus separately. The utility of dense fine speckled (DFS) pattern has been discussed too. In the following segment, we have discussed what are the ANA patterns observed in major rheumatological diseases, their antibody association, and their clinical significance.

JAYPEE BROTHERS

TABLE 3.1: Comparison between immunofluorescence and ELISA techniques.[3,4,7,9-12]

	Advantages	*Disadvantages*
Indirect immunofluorescence (IFA)	• Cost-effective • Easy to perform • High sensitivity • Classical method using HEp-2 cells, which contain several hundred different antigens. Hence, it is the standard multiplexing screening assay • It is generally reported with both a titer and a pattern. Hence, its semiquantitative determination	• Time-consuming • Low specificity. Can give false-positive results • Requires trained personnel, more expensive equipment and expertise to read the results • Interobserver variability. The IFA method is influenced by variables like cell type, fixation procedure, dilution of patient serum, inspection time, experience level of the laboratory personnel and the microscope used • Extractable nuclear antigen (ENA) categorization is difficult. The fluorescence pattern itself does not disclose the fine reactivity of the detected antibodies (except for anticentromere antibodies)
Enzyme-linked immunosorbent assay (ELISA)	*Advantages*	*Disadvantages*
	• Automated • Most enzyme immunoassays (EIAs) are reported as a numeric value with unit of measurement. EIAs' quantitation is based on light absorbance. The enzyme linked to the detection antibody converts a colorless substrate to a colored product, the absorbance of which is compared to a standard curve. Manufacturers will provide a recommended cutoff, which is the unit value above which a sample would be considered "ANA-positive" • High sensitivity; the presence or absence of antibody to a specific antigen can be better assessed • Potential for identifying the fine reactivity of the antibodies with higher reproducibility and low cost	• Less specific • Potential for false positives • Requires purified antigen • The reactivity of EIA methods is limited to the relatively few individual antigens included in the assays

Systemic Lupus Erythematosus[14]

Systemic lupus erythematosus, which is the prototype of AICTDs, is characterized by a wide variety of antibodies. There is no specific ANA pattern that can define SLE. A cytoplasmic pattern which is often ignored by many personnel interpreting ANA can be associated with antiribosomal P

JAYPEE BROTHERS

TABLE 3.2: Antinuclear antibody (ANA) patterns associated with systemic lupus erythematosus (SLE).

Pattern observed in ANA immunofluorescence	***Antibodies associated***	***Clinical significance***
Nuclear patterns		
Homogeneous (AC-1)	• Anti-dsDNA • Antinucleosome • Antihistone	• Specific, renal lupus • Neuropsychiatric lupus • Drug-induced lupus
Speckled—fine speckled (AC-4)	• Anti-SSA • Anti-SSB	• Serositis, subacute cutaneous lupus, photosensitivity • Sicca
Speckled—coarse speckled (AC-5)	• Anti-Sm • Anti-U1RNP	• Specific • Associated with arthritis, pulmonary hypertension, negative association with lupus nephritis
Proliferating cell nuclear antigen (PCNA) (AC-13)	• Anti-PCNA	• Was considered to be specific for SLE but debatable
Cytoplasmic ANA patterns		
Dense fine speckled (AC-19)	• Antiribosomal P (anti-P0, P1, P2)	• Neuropsychiatric lupus
Golgi pattern (AC-22)	• Anti-Golgi	• Rare in general population • Very few in SLE • Debatable importance

protein which is a specific antibody associated with neuropsychiatric lupus. Patterns of ANA and antibodies that can be observed in SLE is represented in **Table 3.2**.

Homogeneous pattern, though considered to be specific for SLE, can also be observed in chronic autoimmune hepatitis and JIA. There is no clear association with an autoantibody in JIA. The ANA positivity here carries a prognostic value (risk of uveitis). Follow-up testing is not recommended in such patients.

Sjögren's Syndrome

Sjögren's syndrome is characterized by sicca symptoms evidenced by xerostomia, xerophthalmia, and presence of antibodies-anti-SSA and anti-SSB. In ANA HEp-2, they show a fine speckled pattern (AC-4). Underrepresentation of SSA in HEp-2 cells could be a major diagnostic difficulty in Sjögren's syndrome, which might lead to a negative ANA in HEp-2 IIF. A patented modification in ANA HEp-2, called as ANA HEp-2000 in which HEp-2 cells are transfected with SSA Ro60 cDNA results in over

JAYPEE BROTHERS

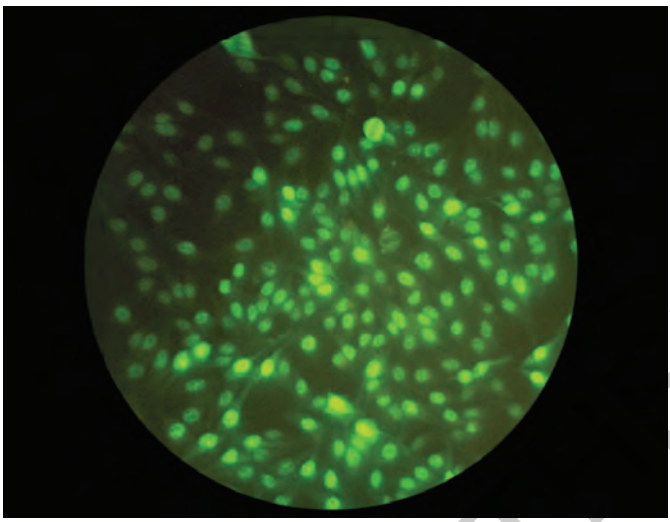

Fig. 3.1: Transfected SSA showing brightly stained fluorescence. HEp-2000—SSA pattern.

expression of SSA, thereby bridging the gap in diagnosis[14] **(Fig. 3.1)**. When the clinical suspicion of Sjögren's syndrome is strong, it is always better to employ at least two different laboratory testing (IFA and LIA or IFA and ELISA). The presence of anti-SSA can also be associated with neonatal lupus and congenital heart blocks in fetus of mothers harboring these antibodies.

Systemic Sclerosis

Systemic sclerosis is classified into two broad subtypes: (1) diffuse cutaneous and (2) limited cutaneous based on the extent of skin involvement. Current classification system, the ACR/EULAR 2013, for systemic sclerosis includes anti-Scl-70 (antitopoisomerase 1), anticentromere, and anti-RNA polymerase III antibodies, the presence of one or all of which carries 3 points.[15] In addition, we have anti-Th/T0, antifibrillarin as other antibodies. Systemic sclerosis can be associated with autoimmune myositis frequently and the antibodies expressed by this group are discussed under myositis.

The ANA patterns exhibited by the above antibodies are listed in **Table 3.3**.[13]

Mixed Connective Tissue Disease

The disease is characterized by ANA positivity at higher dilution, coarse speckled (AC-5) pattern and U1RNP positivity in ELISA or LIA. The presence of U1RNP is associated with Raynaud's phenomenon, arthritis, pulmonary hypertension, interstitial lung disease, and muscle involvement; less likely to cause proliferative glomerulonephritis with good prognosis.

JAYPEE BROTHERS

TABLE 3.3: Antinuclear antibody (ANA) patterns associated with systemic sclerosis.

Pattern observed in ANA IFA	***Antibodies associated***	***Clinical significance***
Nuclear patterns		
• Homogeneous (AC-1)	• Anti-Scl-70 (previously reported as nuclear homogeneous—however it has a special pattern AC-29 which is composite and a pattern by its own)	See below
• Centromere • (AC-3)	• Anticentromere (anti-CENP-B)	• Limited cutaneous systemic sclerosis • Pulmonary hypertension • Digital ischemia • Calcinosis • Primary biliary cirrhosis subset
• Coarse speckled (AC-5)	• Anti-RNA polymerase III	• Specific for systemic sclerosis, poor prognosis • Scleroderma renal crisis (SRC) • Tendon friction rubs, gastric antral vascular ectasia (GAVE)
• Homogeneous nucleolar (AC-8)	• Anti-Th/T0 • Anti-PM-Scl	• Limited cutaneous scleroderma • Less SRC and dysmotility • Overlap with myositis
• Clumpy nucleolar • (AC-9)	• Antifibrillarin/U3 RNP	• Diffuse cutaneous systemic sclerosis • Associated manifestations: – Pulmonary arterial hypertension – Skeletal muscle disease – Cardiac involvement – Gastrointestinal dysmotility
• Punctate nucleolar (AC-10)	• Anti-RNA polymerase I	• Always coexist with anti-RNA polymerase III
• TOPOI-like (AC-29) • highly specific pattern	• Anti-Scl-70 (antitopoisomerase 1)	• Diffuse cutaneous • Interstitial lung disease (ILD) • Cardiac involvement

Idiopathic Inflammatory Myositis

The diagnostic utility of antibodies in idiopathic inflammatory myositis has grown up in proportions over the past decade. The time tested Bohan and Peter's classification does not include antibodies in the classification criteria. As we move towards comprehensive antibody testing in myositis, we

JAYPEE BROTHERS

also understand the association of certain antibodies to prognosis or organ involvement (anti-SRP to heart, anti-Jo to lungs). Broadly the antibodies associated with myositis are termed as myositis-specific antibodies (which are mutually exclusive—anti-Jo1, anti-SRP, anti-MDA5, etc.) and myositis-associated antibodies (can also be seen in other AICTDs like anti-U1RNP, anti-SSA). ANA patterns and their clinical association are described in detail in **Table 3.4**.

TABLE 3.4: Antinuclear antibody (ANA) patterns associated with inflammatory myositis.[13,16,18-20]

	Antibodies associated	***Pattern in ANA immunofluorescence***	***Clinical significance***
Myositis-specific antibodies	Antisynthetase antibodies • Anti-Jo1 • EJ, KS, OJ, PL-7 • PL-12 • Anti-Ha/Zo	• Cytoplasmic pattern—fine speckled (AC-20) • Cytoplasmic pattern (AC-19—dense fine speckled in cytoplasm) • No defined pattern	Common in inflammatory myositis • Arthritis, mechanic hands, fever, interstitial lung disease (ILD) • ILD is severe and occurs early
	• Anti-Mi-2	• Fine speckled (AC-4)	• Classical dermatomyositis • Good prognosis • Negative association with malignancy
	• Anti-TIF-γ	• Fine speckled (AC-4)	• Associated with malignancy • Telangiectatic "red on white patch", skin manifestations like psoriasis
	• Anti-MDA5	• Usually, ANA by IIF in HEp-2—negative • Other nonspecific patterns can be present	• Other association: Rapidly progressive ILD may be present
	• Anti-SAE	• Fine speckled in IIF • Usually by ELISA/Immunoprecipitation • IF shows nuclear speckled pattern	• Amyopathic DM—progression to myositis
	• Anti-SRP	• Cytoplasmic pattern (AC-19—dense fine speckled in cytoplasm)	• Immune-mediated necrotizing myopathy

Contd...

JAYPEE BROTHERS

Contd...

	Antibodies associated	***Pattern in ANA immunofluorescence***	***Clinical significance***
	• Anti-MJ/NXP2	• Multiple nuclear dots (AC-6)	• Specific for autoimmune myositis • Associated with: – Juvenile dermatomyositis – Adult myositis—its presence is associated with malignancy
	• Anti-HMGCR	• Only by immunoprecipitation • Proposed: Rat hepatocytes in IIF—studies	• Immune-mediated necrotizing myopathy
Myositis-associated antibodies	• Anti-PM-Scl	• Homogeneous nucleolar (AC-8) • Additionally, can have diffuse nuclear fine speckled pattern	• Associated with systemic sclerosis (SSc) myositis overlap • Associated features: Arthritis, Raynaud's
	• Anti-Ro/SSA	• Fine speckled (AC-4)	• Polymyositis, dermatomyositis, overlap myositis • Other features: ILD, sicca
	• Anti-La/SSB	• Fine speckled (AC-4)	• Polymyositis, dermatomyositis • Other features: Sicca symptoms
	• Anti-Ku	• Fine speckled (AC-4) and coarse speckled (AC-5)	• Associated with overlap myositis (SLE/SSc/myositis overlap or SSc/myositis overlap) • Other features: ILD association
	• Anti-U1snRNP	• Coarse speckled (AC-5)	• Overlap myositis (SSc/myositis) • Other features: Raynaud's, sclerodactyly, fever

The clinical subtypes of inflammatory myositis have now expanded to five.[16]

1. Polymyositis
2. Dermatomyositis
3. Sporadic inclusion body myositis
4. Immune-mediated necrotizing myopathy
5. Overlap syndrome with myositis [that includes antisynthetase syndrome—(ASS)]

JAYPEE BROTHERS

Muscle biopsy has been considered the gold standard test for myositis especially polymyositis and inclusion body myositis. With the advent of newer antibodies and increased accessibility to immunological diagnostics, it is not long before we have a classification criteria for myositis with antibodies in the forefront (current EULAR/ACR classification criteria has included only anti-Jo1).[17]

Some of the common antinuclear antibody immunofluorescence patterns, seen in various connective tissue disorders are depicted in the images **(Figs. 3.2A to F)** below:

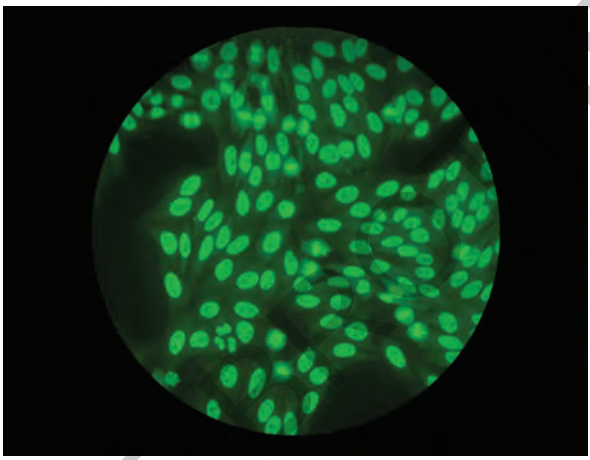

Fig. 3.2A: Nuclear homogenous pattern.
(*Courtesy:* Pooja Nair)

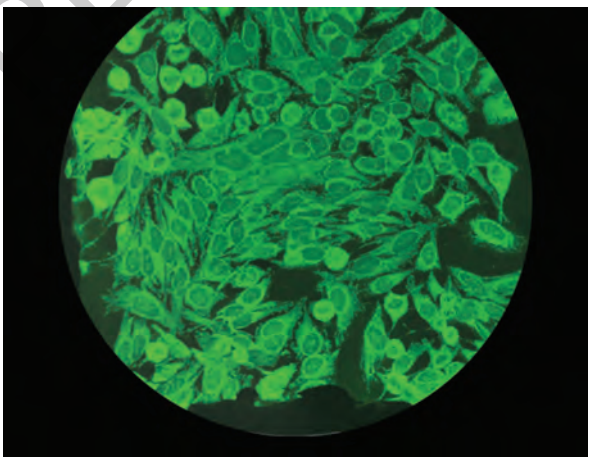

Fig. 3.2B: Cytoplasmic pattern.
(*Courtesy:* Pooja Nair)

JAYPEE BROTHERS

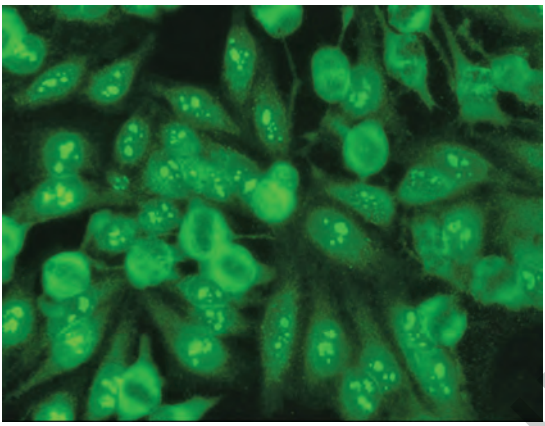

Fig. 3.2C: Nucleolar.
(*Courtesy:* Sunitha KG)

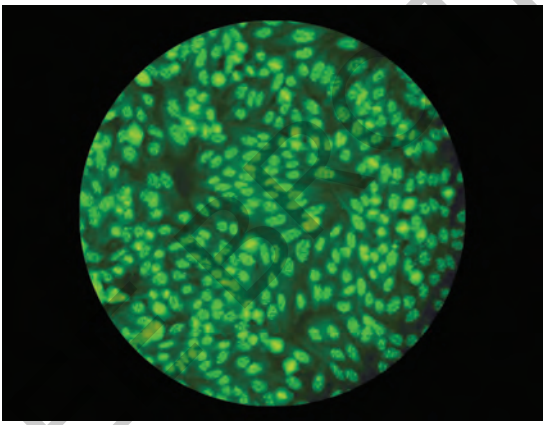

Fig. 3.2D: Centromere pattern.
(*Courtesy:* Sunitha KG)

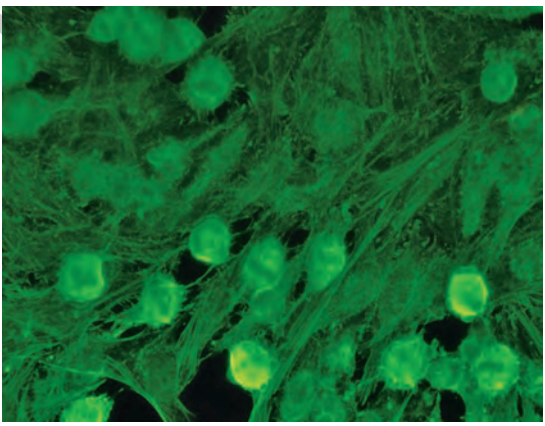

Fig. 3.2E: Cytoplasmic filamentous.
(*Courtesy:* Sunitha KG)

JAYPEE BROTHERS

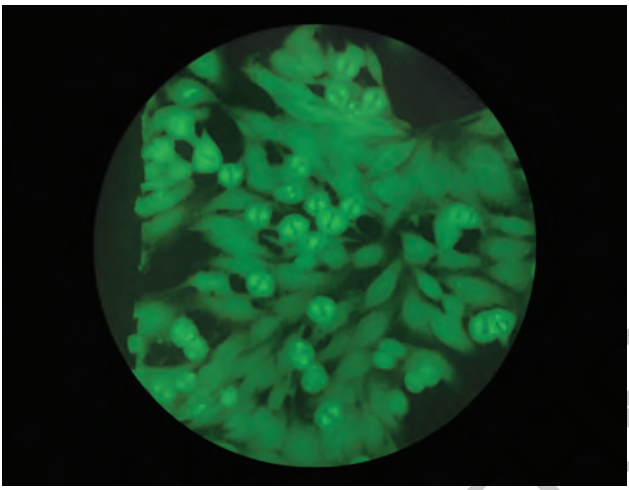

Fig. 3.2F: Mitotic pattern.
(*Courtesy:* Pooja Nair)

Nuclear Dense Fine Speckled (AC-2)

Autoantibodies that produce a nuclear DFS pattern/lens epithelium-derived growth factor in IIF has been more prevalent in healthy controls.[13] Current LIAs have included anti-DFS in their panel. The major differentiating feature between anti-DFS in healthy individuals and in AICTDs is anti-DFS occurs alone/isolated in healthy individuals whereas anti-DFS can be one of the autoantibodies in SLE, rheumatoid arthritis, Hashimoto's thyroiditis and other autoimmune diseases.[21] Current evidence states that high titer of isolated anti-DFS is useful in excluding an AICTD. It could also be useful in identifying the group of UCTDs which will not progress to a well-differentiated AICTD.[22]

The striking feature of anti-DFS is intensely stained chromatin in metaphase along with speckled pattern in nucleus. The speckled pattern in anti-DFS is heterogeneous in size and fluorescence intensity[13] **(Fig. 3.3)**.

Current update on anti-DFS, also talks about anti-MeCP2 which produces an exact pattern on HEp-2-IIF undistinguishable from DFS, the LIA is negative though. MeCP2 is less represented in human sera. Others which cause similar findings are c-MYC-binding protein JPO2/CDCA7L and mixed-lineage leukemia protein MLL1.[22]

JAYPEE BROTHERS

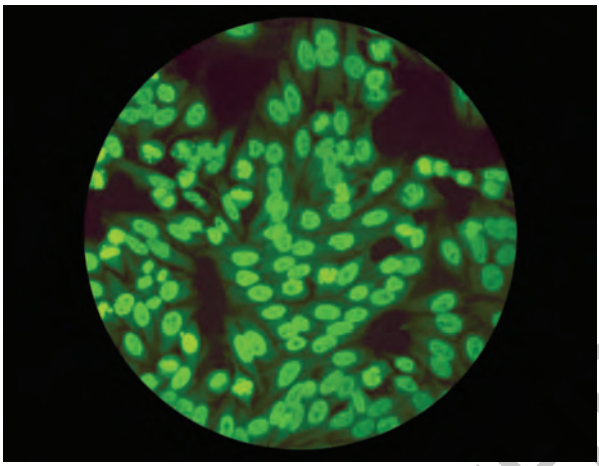

Fig. 3.3: Dense fine speckled pattern where metaphase chromatin is brightly stained with surrounding speckled pattern.

CONCLUSION

To conclude, ANA testing is the cornerstone in the diagnosis of AICTD provided the test is requested in the background of a strong clinical suspicion for a connective tissue disorder.

Key Points

- ANA by IIF using HEp-2 cells is the gold standard screening test for AICTDs.
- ANA can be used in classification, as a prognostic feature and as a predictor depending on the disease.
- Judicious use of ANA testing along with diligent clinical examination ensures early and appropriate diagnosis and lessens the economic burden on the patient.
- Individual autoantibodies against cellular targets have clinical significance and associated with specific organ involvement.
- Myositis-specific and myositis-associated antibodies are the newest entrants into the everexpanding panel of autoantibodies and have the potential to replace muscle biopsy in near future.
- Identification of isolated nuclear DFS pattern is useful in classifying a normal healthy individual from a patient with AICTD.

REFERENCES

1. Agmon-Levin N, Damoiseaux J, Kallenberg C, Sack U, Witte T, Herold M, et al. International recommendations for the assessment of autoantibodies to cellular antigens referred to as anti-nuclear antibodies. Ann Rheum Dis. 2014;73:17-23.

JAYPEE BROTHERS

2. Solomon DH, Kavanaugh AJ, Schur PH, American College of Rheumatology Ad Hoc Committee on Immunologic Testing Guidelines. Evidence-based guidelines for the use of immunologic tests: antinuclear antibody testing. Arthritis Rheum. 2002:47:434-44.
3. Kumar Y, Bhatia A, Minz RW. Antinuclear antibodies and their detection methods in diagnosis of connective tissue diseases: a journey revisited. Diagn Pathol. 2009;4:1.
4. Gautam K. Anti-nuclear antibodies: current concepts and future direction for diagnosing connective tissue disease. J Pathol Nepal. 2015;5:766-73.
5. Karumanchi D, Oommen S. Evaluation of diagnostic significance and cost effectiveness of ELISA and IFA for the diagnosis of autoimmune disorders. Immunome Res. 2018;14:155.
6. Mosaic HEp-20-10/Liver (Monkey): Instruction Manual for the Indirect Immunofluorescence Test. EUROIMMUN AG, Germany. [online] Available from http://www.euroimmun.com [Last accessed November, 2021].
7. Santhosh P, Ajithkumar K. Anti-nuclear antibodies: a practical approach to testing and interpretation. J Skin Sex Transm Dis. 2021;3:175-9.
8. Peene I, Meheus L, Veys EM, De Keyser F. Detection and identification of antinuclear antibodies (ANA) in a large and consecutive cohort of serum samples referred for ANA testing. Ann Rheum Dis. 2001;60:1131-6.
9. Baronaite R, Engelhart M, Hansen TM, Thamsborg G, Jensen HS, Stender S, et al. A comparison of anti-nuclear antibody quantification using automated enzyme immunoassays and immunofluorescence assays. Autoimmune Dis. 2014:1-8.
10. Mahler M, Meroni PL, Bossuyt X, Fritzler MJ. Current concepts and future directions for the assessment of autoantibodies to cellular antigens referred to as anti-nuclear antibodies. J Immunol Res. 2014;2014:315179.
11. Copple SS, Sawitzke AD, Wilson AM, Tebo AE, Hill HR. Enzyme-linked immunosorbent assay screening then indirect immunofluorescence confirmation of antinuclear antibodies: a statistical analysis. Am J Clin Pathol. 2011;135:678-84.
12. Kamel NA, Hassaballa AA, Hasan YM. Detection of antinuclear antibody in autoimmune connective tissue diseases: a comparison between immunofluorescence and solid-phase assay. Al-Azhar Assiut Med J. 2018; 16(3):223-8.
13. Damoiseaux J, Andrade LE, Carballo OG, Conrad K, Francescantonio PL, Fritzler MJ, et al. Clinical relevance of HEp-2 indirect immunofluorescent patterns: the International Consensus on ANA patterns (ICAP) perspective. Ann Rheum Dis. 2019;78:879-89.
14. Lee AY, Beroukas D, Roberts-Thomson PJ. Utility of the HEp-2000 antinuclear antibody substrate. Ann Rheum Dis. 2020:79:e68.
15. van den Hoogen F, Khanna D, Fransen J, Johnson SR, Baron M, Tyndall A, et al. 2013 classification criteria for systemic sclerosis: an American College of Rheumatology/European League against Rheumatism collaborative initiative. Arthritis Rheum. 2013;65:2737-47.
16. Stuhlmüller B, Schneider U, González-González JB, Feist E. Disease specific autoantibodies in idiopathic inflammatory myopathies. Front Neurol. 2019; 10:438.

JAYPEE BROTHERS

17. Lundberg IE, Tjärnlund A, Bottai M, Werth VP, Pilkington C, de Visser M, et al. 2017 European League against Rheumatism/American College of Rheumatology classification criteria for adult and juvenile idiopathic inflammatory myopathies and their major subgroups. Ann Rheum Dis. 2017;76(12):1955-64.
18. Selva-O'Callaghan A, Pinal-Fernandez I, Trallero-Araguás E, Milisenda JC, Grau-Junyent JM, Mammen AL. Classification and management of adult inflammatory myopathies. Lancet Neurol. 2018;17(9):816-28.
19. Damoiseaux J, Vulsteke JB, Tseng CW, Platteel AC, Piette Y, Shovman O, et al. Autoantibodies in idiopathic inflammatory myopathies: clinical associations and laboratory evaluation by mono- and multispecific immunoassays. Autoimmun Rev. 2019;18:293-305.
20. Palterer B, Vitiello G, Carraresi A, Giudizi MG, Cammelli D, Parronchi P. Bench to bedside review of myositis autoantibodies. Clin Mol Allergy. 2018;16:5.
21. Mahler M, Parker T, Peebles CL, Andrade LE, Swart A, Carbone Y, et al. Anti-DFS70/LEDGF antibodies are more prevalent in healthy individuals compared to patients with systemic autoimmune rheumatic diseases. J Rheumatol. 2012;39(11):2104-10.
22. Mahler M, Andrade LE, Casiano CA, Malyavantham K, Fritzler MJ. Anti-DFS70 antibodies: an update on our current understanding and their clinical usefulness. Expert Rev Clin Immunol. 2019;15(3):241-50.

JAYPEE BROTHERS

for detailed information on medicine books, visit our website www.jaypeebrothers.com, for detailed information on medicine books, visit our web

Manual of Lab Investigations *in* Rheumatic Diseases

Salient Features

- Chapters written by experienced clinicians with a focus on the practical applications of laboratory investigations used in clinical rheumatology practice.
- Chapters with disease-wise discussions of immunological investigations for common rheumatic diseases, with discussion focusing on their clinical indications and practical application.
- Chapters covering the common hematological and biochemical tests used mainly in the evaluation of rheumatic diseases and also metabolic bone diseases.
- Chapter on immunofluorescence and the technicalities authored by an expert.
- Illustrative figures, tables and flowcharts to emphasize the important information.
- Chapters written with postgraduate medical students, rheumatologists, physicians and other clinicians involved in the management of rheumatic diseases as the target readership.

Sham Santhanam MD (General Medicine) DM (Rheumatology) MRCP (UK) MRCPE SCE Rheumatology (RCP UK) European Certificate of Rheumatology is a Consultant in Department of Rheumatology at Gleneagles Global Health City and Vijaya Hospital, Chennai, Tamil Nadu, India; and is the Director of Sham's Rheumatic Care Centre, Chennai. He got trained in rheumatology at the prestigious Madras Medical College, Chennai. He has cleared the MRCP (UK), Specialty Certificate Examinations (RCP UK) and the European (EULAR) Certification Examination for Rheumatology. He was the recipient of the Indo-UK travelling fellowship in 2016. He serves as an Associate Editor of the Indian Journal of Rheumatology. He has also edited the special issue of the journal on *Interstitial Lung Disease in Rheumatic Diseases*. He has been the Editor for a monograph on *Rheumatic Rarities*, another on *Osteoarthritis* and has published several articles on a broad range of topics within rheumatology.

Printed in India

Available at all medical bookstores or buy online at www.jaypeebrothers.com



JAYPEE BROTHERS
Medical Publishers (P) Ltd.
EMCA House, 23/23-B, Ansari Road, Daryaganj, New Delhi - 110 002, INDIA
www.jaypeebrothers.com

Join us on facebook.com/JaypeeMedicalPublishers

Shelving Recommendations
MEDICINE, RHEUMATOLOGY

