d information on pediatric books, visit our website www.jaypeebrothers.com, for detailed information on pediatric books, visit our website www.jaypeebrothers.com

Essential Pediatric Pulmonology

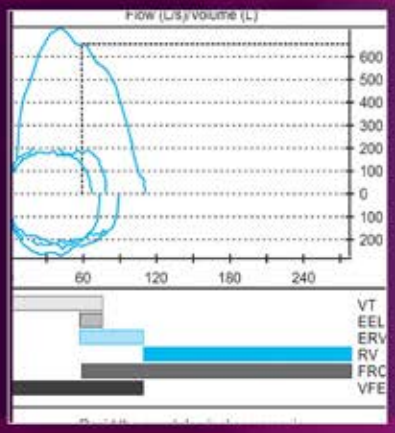





Editors
Rakesh Lodha
Sushil K Kabra

4TH EDITION

JAYPEE

Contents

SECTION 1: General Considerations

1. **Introductory Anatomy: Respiratory System** 3
   Samriti Gupta
2. **Physiology of the Respiratory System** 9
   Lokesh Guglani
3. **History Taking and Physical Examination** 18
   Krishna Mohan Gulla, Sushil K Kabra

SECTION 2: Investigations in Pulmonology

4. **Investigations in Pulmonology** 27

   4.1. Diagnostic Imaging 27

   4.1.1. **Role of Chest Radiograph and Ultrasound in Respiratory Disorders in Children** 27
   Manisha Jana, Ashu Seith Bhalla, Priyanka Naranje, Arun Kumar Gupta

   4.1.2. **Role of Computed Tomography and Magnetic Resonance Imaging in the Evaluation of Pediatric Chest** 37
   Ashu Seith Bhalla, Priyanka Naranje, Manisha Jana, Arun Kumar Gupta

   4.2. Microbiological Investigations 49
   Nitin Dhochak, Sushil K Kabra

   4.3. Thoracocentesis 52
   Jagat Jeevan Ghimire, Sushil K Kabra

   4.4. Lung Puncture and Lung Biopsy 54
   Nitin Dhochak, Sushil K Kabra

   4.5. Pulmonary Function Test 56
   Nitin Dhochak, Sushil K Kabra, Rakesh Lodha

   4.6. Bronchoscopy and Bronchoalveolar Lavage in Children 65
   Prawin Kumar, Sushil K Kabra

   4.7. Endobronchial Ultrasound-guided Transbronchial Needle Aspiration and Endoscopic Ultrasound with an Echobronchoscope-guided Fine Needle Aspiration, and Transthoracic Needle Aspiration 77
   Krishna Mohan Gulla, Sushil K Kabra

   4.8. Arterial Blood Gas Analysis 82
   Rakesh Lodha

   4.9. Sweat Chloride Estimation 85
   Arvind Kumar, Sushil K Kabra

   4.10. Fractional Exhaled Nitric Oxide, Nasal Nitric Oxide, Nasal Brush, and High-speed Video Microscopy 89
   Shishir Jindal, Sushil K Kabra

   4.11. Pleural Biopsy 91
   Anshula Tayal

4.12. **Esophageal pH Monitoring** 95
Nikhil Rajvanshi, Prawin Kumar

4.13. **Diffusion Capacity** 99
Nitin Dhochak, Sushil K Kabra

SECTION 3: Respiratory Infections

5. **Upper Respiratory Tract Infection** 103
Hardeep Kaur, Sushil K Kabra

6. **Acute Laryngotracheobronchitis** 111
Kana Ram Jat

7. **Acute Bronchiolitis** 117
Sagar Tungal, Rakesh Lodha

8. **Community-acquired Pneumonia** 128
Swati Dublish, Rakesh Lodha, Sushil K Kabra

9. **Respiratory Viruses** 141
Lokesh Guglani

10. **Fungal Pneumonia** 161
Aparna Mukherjee, Sushil K Kabra

11. **Allergic Bronchopulmonary Aspergillosis** 168
Kana Ram Jat, Jyoti Kumari

12. **Recurrent/Persistent Pneumonia** 175
Sagar Tungal, Rakesh Lodha, Sushil K Kabra

13. **Suppurative Lung Diseases** 182
Rashmi Hooda, Sushil K Kabra

14. **Pulmonary Complications in Immunocompromised Children** 188
Saurav Jain, Sushil K Kabra

15. **Tuberculosis** 201
Anshula Tayal, Sushil K Kabra

16. **Eosinophilic Lung Diseases** 222
Hardeep Kaur, Sushil K Kabra

SECTION 4: Asthma

17. **Epidemiology, Risk Factors, and Natural History of Asthma** 233
Snehal Vala, Lokesh Guglani

18. **Clinical Presentation and Diagnosis of Asthma** 253
Jagdish Prasad Goyal, Chirag Thakur

19. **Assessment of Airway Inflammation** 261
Anirban Maitra

20. **Acute Exacerbation of Asthma** 270
Kiran Kumar, Jhuma Sankar

21. **Long-term Treatment of Asthma** 281
Jagat Jeevan Ghimire, Sushil K Kabra

22. **Difficult Asthma** 295
Sheetal Agarwal, Sushil K Kabra

23. **Preschool Wheezing** 301
Vijaya Kumar U, Kana Ram Jat

24. **Asthma and Obesity** 310
Samriti Gupta

SECTION 5: Noninfectious Diseases

25. **Cystic Fibrosis** 321
Nitin Dhochak, Sushil K Kabra

26. **Interstitial Lung Diseases** 339
Parul Sehgal, Sushil K Kabra

27. **Hypersensitivity Pneumonitis** 348
Nitin Dhochak, Sushil K Kabra

28. **Pediatric Sarcoidosis** 353
Ganganath Gunathilaka, Sushil K Kabra

29. **Pulmonary Manifestations of Rheumatological Disorders** 357
Lesa Dawman, Sushil K Kabra

30. **Asthma and Gastroesophageal Reflux** 362
Priyanka Gupta, Sushil K Kabra

31. **Foreign Body Aspiration** 371
Sandeep Agarwala, Anjan Dhua

32. **Hydrocarbon Aspiration** 376
Jhuma Sankar, Samriti Gupta

33. **Pulmonary Hemorrhage** 382
Channa de Silva, Sushil K Kabra

34. **Sleep-disordered Breathing and Pediatric Obstructive Sleep Apnea** 390
Kana Ram Jat, Neethu Rajeev

35. **Primary Ciliary Dyskinesia** 396
Anshula Tayal, Kana Ram Jat

36. **Bronchopulmonary Dysplasia** 402
Mayank Priyadarshi, Akash Sharma, M Jeeva Sankar

37. **Environment and Lung Disease** 414
Vinod H Ratageri

38. **Central Hypoventilation Syndromes** 419
Wai Wong, Umakanth A Katwa

39. **Assessment and Management of Patients with Neuromuscular Weakness** 434
Sumit Verma, Lokesh Guglani

40. **Pediatric Pulmonary Arterial Hypertension** 445
Vijaya Kumar U, Jhuma Sankar

41. **Pulmonary Injury due to Pharmacological Agents** 457
Sneha Varkki

42. **Sudden Infant Death Syndrome** 464
Samiya Razvi

43. **Genetics and Pulmonary Diseases** 473
Neerja Gupta, Amit Satapathy, Madhulika Kabra

44. Lung Complications in Children with Congenital Heart Diseases 485
B Arvind

45. Airway Malacias 491
Amit Pathania, Kana Ram Jat

SECTION 6: Congenital Malformations

46. Congenital Lung Malformations 499
Vishesh Jain, Sandeep Agarwala

SECTION 7: Pleural Diseases

47. Pleural Effusion 509
Dinesh Raj, Rakesh Lodha

48. Empyema Thoracis 513
Isha Saini, Sushil K Kabra, Rakesh Lodha

49. Pneumothorax 521
Namita Ravi Kumar, Rakesh Lodha

SECTION 8: Neoplasms

50. Neoplasms of Mediastinum and Respiratory Tract 527
Sandeep Agarwala, Alisha Gupta

SECTION 9: Intensive Care in Pulmonology

51. Acute Lung Injury and Acute Respiratory Distress Syndrome 539
Arpita Chattopadhyay, Rakesh Lodha

52. Basics of Mechanical Ventilation 551
Namita Ravi Kumar, Rakesh Lodha

53. Chronic Care of Respiratory Illnesses at Home 567
Jagat Jeevan Ghimire, Rakesh Lodha

SECTION 10: Therapeutics

54. Airway Clearance Techniques 579
Sumita Gupta

55. Oxygen Therapy 588
Satya Prakash, Jhuma Sankar

56. Aerosol Therapy 595
Kana Ram Jat, Aravindhan Manoharan

57. Whole Lung Lavage 601
Krishna Mohan Gulla

58. Pharmacology of Pediatric Pulmonary Disorders 606
Kana Ram Jat

Index 615

4

CHAPTER

Investigations in Pulmonology

4.1 Diagnostic Imaging

4.1.1 Role of Chest Radiograph and Ultrasound in Respiratory Disorders in Children

Manisha Jana, Ashu Seith Bhalla, Priyanka Naranje, Arun Kumar Gupta

◇ KEY POINTS

- Chest radiograph, due to its low monetary and radiation cost as well as easy availability remains the workhorse of chest imaging despite the myriad advances in cross-sectional imaging.
- The advances in digital imaging have significantly improved the quality of chest radiographs while reducing the "repeat rates" critical to interpretation of chest radiographs, especially in chronic disorders in the evaluation of serial imaging.
- Hence, the need to save digital records cannot be over emphasized.
- Ultrasonography (USG) has emerged as an invaluable complementary modality and should be used increasingly.

◇ INTRODUCTION

Chest radiograph has remained the initial and the most commonly utilized imaging modality in all spheres of pediatric radiological practices since its inception; owing to the ease of performance, low cost, and radiation burden. Chest USG is a relatively newer modality; but with immense importance as an adjunct; especially in the evaluation of pleural pathologies and critically ill children. This chapter summarizes the important indications for chest radiographs and USG.

◇ RADIOGRAPHIC VIEWS

The commonly used radiographic views in children include anteroposterior (AP) and posteroanterior (PA). In infants and small children who are unable to stand upright; or for very sick children in the ward or intensive care units (ICUs), AP radiograph is performed **(Fig. 1)**. While interpreting AP radiograph, a few pitfalls should be kept in mind **(Box 1)**.

Posteroanterior view is the most commonly performed one. It remains the mainstay of diagnosis in a wide range of chest disorders in children. In an adequately performed PA chest radiograph, the anterior end of five ribs, and posterior end of eight ribs should be clearly visible above the dome of diaphragm.

Lateral radiograph **(Fig. 2)** is performed less commonly nowadays, due to the availability of superior cross-sectional imaging modalities such as computed tomography (CT)/ magnetic resonance imaging (MRI). However, in children where CT cannot be performed (as in the ICUs); lateral

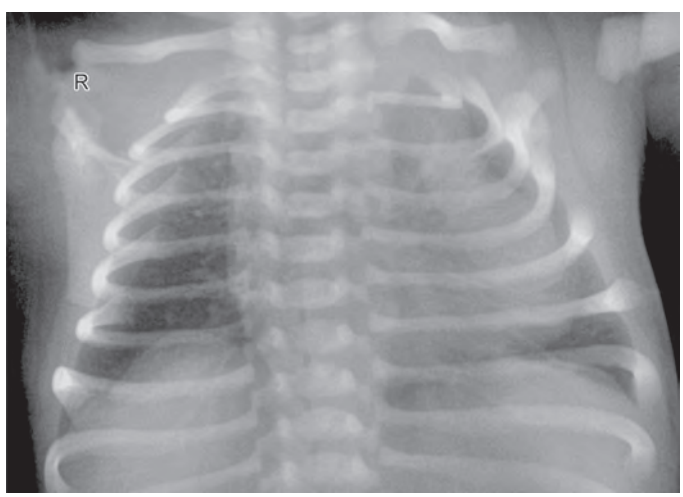

Fig. 1: Supine anteroposterior (AP) radiograph of an infant showing abnormal horizontal orientation of the ribs, cardiomegaly, and small lung volume.

JAYPEE BROTHERS

radiograph can be helpful in localizing a lesion visible on frontal radiograph. Another use of lateral radiograph is in cases with equivocal hilar adenopathy on a PA view. Lateral view helps in differentiating normal, from enlarged vessels or enlarged nodes, thus obviating a CT scan.

BOX 1: Normal findings on anteroposterior (AP) radiograph which may mimic disease.

- Small volume lungs (due to restricted diaphragm movement)
- Prominent vessels/apparent plethora
- Apparent cardiomegaly
- Abnormal orientation of the ribs

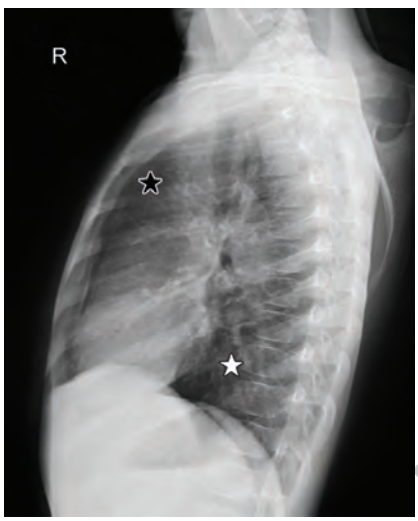

Fig. 2: Normal lateral chest radiograph. Normal retrosternal (Black asterisk) and retrocardiac (white asterisk) spaces should show lucency. Any increase in density in these two locations are to be considered abnormal (except for large thymus in infancy).

Expiratory view is another useful radiograph in pediatric practice. It has additional utility in diagnosing airway obstruction. Normal lung shows reduction of volume on expiratory view. In case of suspected tracheobronchial foreign body, the lung with airway obstruction shows no reduction of volume on expiratory film **(Figs. 3A and B)**.

Other views such as lordotic views, apical view, and decubitus views are no longer used in clinical practice.

◇ UTILITY OF RADIOGRAPHS IN SPECIFIC CLINICAL SITUATIONS

Infections

Chest radiograph is often the only imaging required in the initial evaluation and follow-up of patients with suspected pulmonary infections with an acute/subacute presentation. While a chest radiograph cannot predict the organism responsible for the infection; in conjunction with the clinical presentation, a reasonable differential diagnosis can be arrived at this regard.[1,2] Chest ultrasound can be useful as an adjunct tool in appropriate settings.[2,3] A radiographic pattern approach is useful classifying the appearance predominantly as consolidation, bronchopneumonia, interstitial pneumonia, or nodules.

Consolidation/Lobar Pneumonia

Consolidation presents with ill-defined, inhomogeneous opacity with or without air bronchogram. Air space opacities (those arising from alveolar filling) can also appear as nodules, but these nodules have ill-defined, fluffy borders, and tend to coalesce **(Fig. 4)**. When coalescent these result

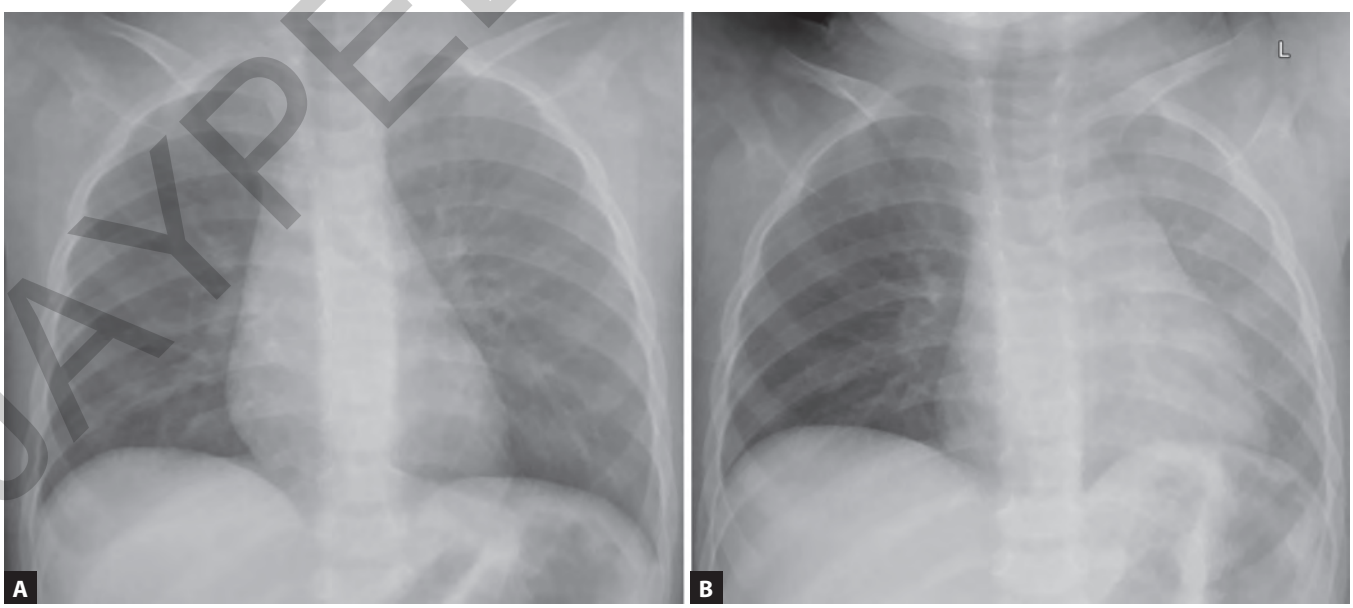

Figs. 3A and B: Value of expiratory radiograph on expiratory film. Suspected foreign body aspiration in a 6-year-old girl. Inspiratory image; (A) shows mildly hyperlucent right hemithorax. Expiratory radiograph; (B) shows accentuated hyperlucency of the abnormal side (right). The normal side (left) shows an increase in density.

JAYPEE BROTHERS

in radiographic appearance of "consolidation", or lobar pneumonia. Consolidation is often limited by fissures **(Figs. 5 and 6)**. The common causative organisms of this pattern are bacterial **(Table 1)**, and usually no accompanying volume loss is seen. Over a period of time areas of low density (lucent areas or cavitation) may appear within representing breakdown **(Fig. 7)**. The clearance of radiographic opacities lags behind clinical response and takes 2–3 weeks' time.

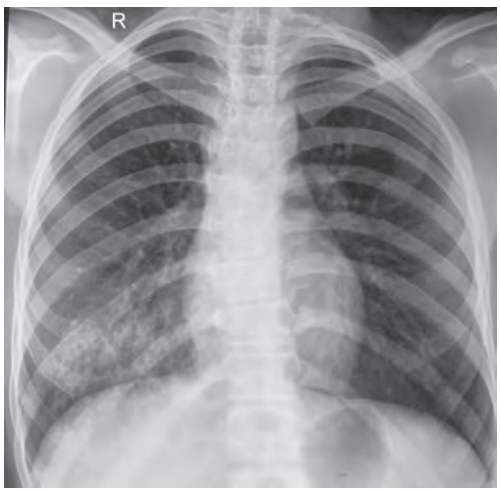

Fig. 4: Airspace opacities. The chest radiograph in an adolescent male with cough and fever reveals nodules with ill-defined fluffy borders in the right lower zone.

In a patient showing expected clinical response, frequent radiographs should not be performed. Lobar pneumonia may heal without sequelae or leave behind few fibrotic sequelae.

Bronchopneumonia

Bronchopneumonia is the radiographic pattern which results from infection that is centered in the terminal and respiratory bronchioles with subsequent spread to the surrounding alveoli. The chest radiographic appearance is of bilateral ill-defined nodules, which may subsequently evolve into consolidation. Accompanying pleural effusion or empyema is commoner in this form. This pattern is also seen in bacterial pneumonia. Staphylococcal pneumonia can also result in a pattern of cavitating nodules (septic emboli) which evolve into pneumatoceles.

Interstitial Pneumonia

In cases of viral pneumonia, "*interstitial pneumonia*" pattern or "*bronchiolitis*" is seen on radiographs **(Fig. 8)**. This pattern is characterized by perihilar symmetric infiltrates which are often bilateral and symmetrical. These are accompanied by hyperinflation of lung fields **(Fig. 9)** and areas of atelectasis.

- *Complications of pneumonia* such as parapneumonic effusion, empyema, and lung abscesses formation can be

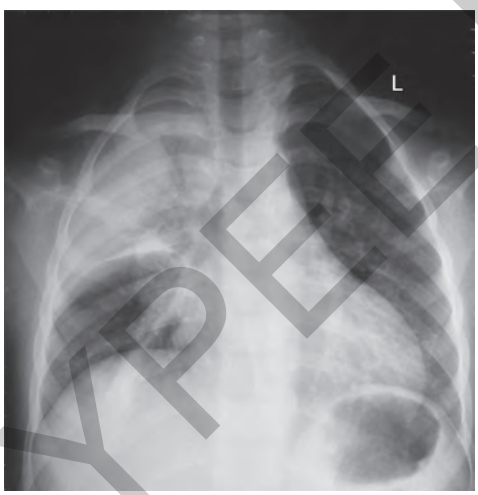

Fig. 5: Lobar consolidation involving the right upper lobe, outlined by the minor fissure.



Fig. 6: Consolidation with a "bulging fissure"; and multifocal airspace nodules; suggestive of Gram-negative bacterial infection (*Klebsiella* sp.).

TABLE 1: Bacterial versus viral pneumonia: Pattern wise recognition on chest X-ray (CXR).

	Bacterial	*Viral*
Lobar/segmental consolidation	More common	Less commonly seen
Bronchiolitis pattern/widely distributed airspace nodules	Can be seen but less common	More common pattern
Bilateral involvement	Uncommon	More commonly seen
Hyperinflated lung fields	Less common	More common
Pleural effusion/empyema	Relatively common	Very uncommon

JAYPEE BROTHERS

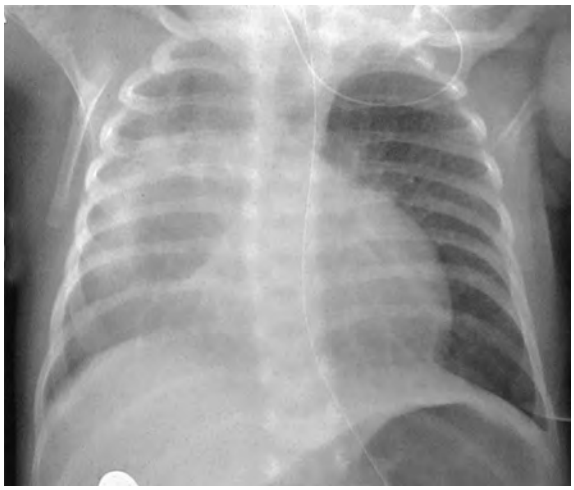

Fig. 7: Consolidation with area of breakdown.

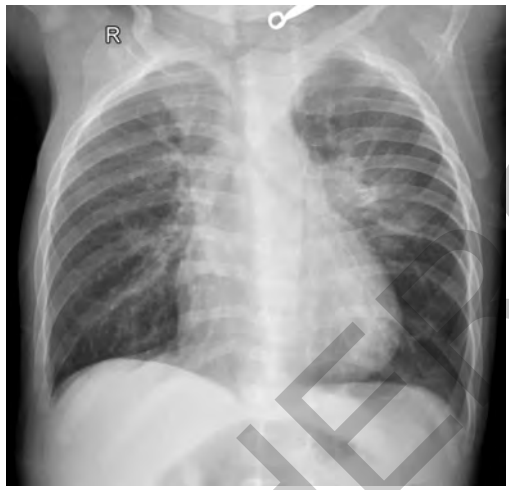

Fig. 8: Viral pneumonia, characterized on this chest radiograph by bilateral symmetrical reticular opacities and hyperinflated lung fields.



Fig. 9: Viral pneumonia, characterized on this chest radiograph by bilateral symmetrical reticular opacities and hyperinflated lung fields.



Fig. 10: Loculated hydropneumothorax of the left lower hemithorax and adjacent consolidation.

diagnosed on a chest radiograph. The appearance of an air-fluid level in a previous area of consolidation suggests lung abscess formation. Hydropneumothorax **(Fig. 10)** can result from rupture of a pneumatocele or following aspiration of an effusion.

Differentiation of lung abscess from loculated hydropneumothorax is aided by a lateral radiograph. On a lateral radiograph, the length of the air-fluid level remains the same as on a PA view; while in case of hydropneumothorax, it appears longer occupying the entire AP diameter.

However, CT may be required for evaluation of complications, especially when an intervention is planned.

Similarly, CT is performed in immunocompromised patients (especially those with malignancies on chemotherapy with febrile neutropenia) for early detection of infections.

Amongst the parasitic infections, *hydatid cyst* **(Figs. 11 to 13)** is the most common and appears as a well-defined round mass lesion on chest radiograph **(Fig. 11)**. On

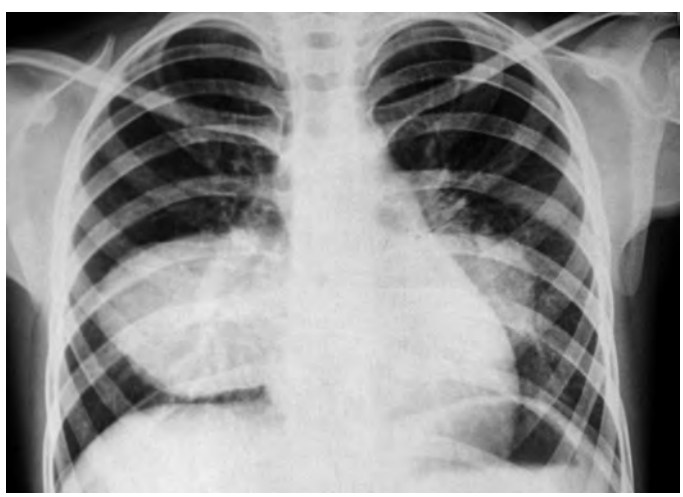

Fig. 11: Multiple hydatid cysts in a child, seen as masses on both lung fields in a frontal chest radiograph.

JAYPEE BROTHERS

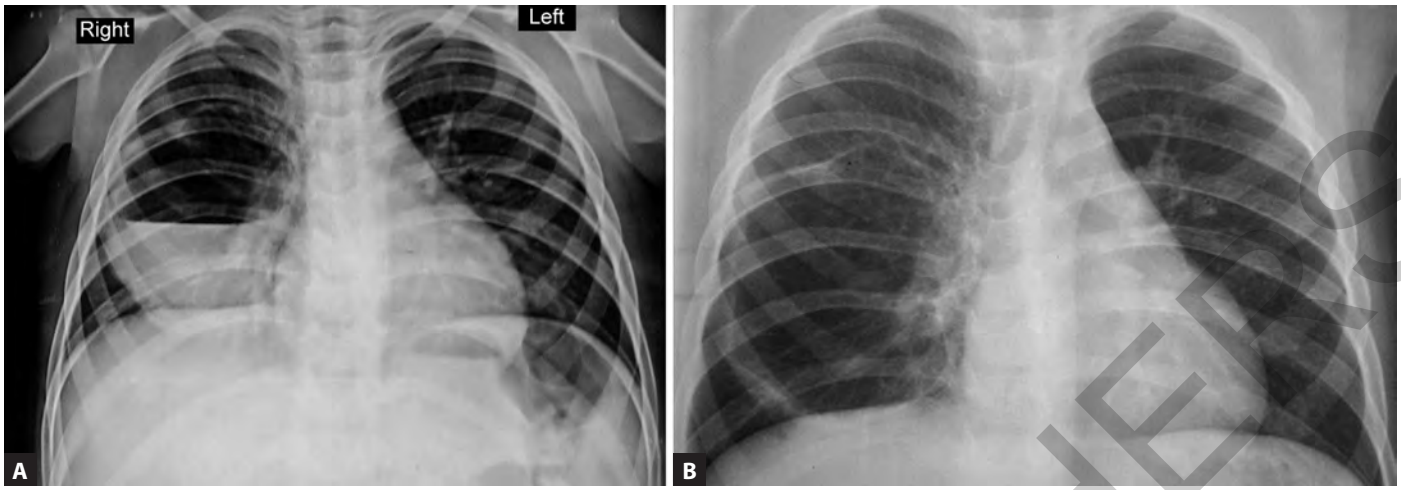

Figs. 12A and B: Ruptured hydatid cyst at various stages (A and B) in a patient. Depending on the contents of the cyst, either air-fluid level; (A) or an air-filled cyst; (B) can be seen.

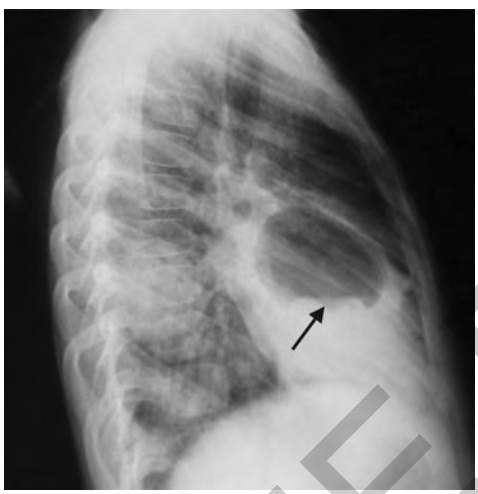

Fig. 13: Water lily sign (arrow) in a case of ruptured hydatid cyst on a chest radiograph.

rupture/secondary infection, they show either air-fluid levels **(Figs. 12A and B)**, "crescent sign" or even the characteristic "water-lily" sign **(Fig. 13)** due to floating membranes.

Terms Defined by World Health Organization

While interpreting a pediatric chest radiograph, it should be kept in mind that the definition of "pneumonia" with respect to public health, epidemiology, and vaccination strategies is different. The World Health Organization (WHO) vaccine trial group defined the findings on chest radiograph[4] into three broad categories: "End point consolidation", other infiltrates, and pleural effusion. End-point consolidation refers to dense/fluffy opacity large enough to involve a part or whole of a lobe or a lung. Presence of an air bronchogram is not essential for its diagnosis. Infiltrates not large enough to qualify as end-point consolidation, reticular opacities, and linear opacities are termed as "other infiltrates".

Primary end point pneumonia (PEPP) is the radiological conclusion when there is an "end point consolidation", pleural effusion associated with lung infiltrates, or pleural effusion large enough to obscure any parenchymal abnormality.[4]

COVID-19 Pneumonia in Children

The SARS CoV-2 infection in children behaved in a different way than its presentation in adults. Children, unlike adults, were more commonly asymptomatic. When presenting with symptomatic diseases, the radiographic patterns did not necessarily follow those in adults. Typical peripheral bilateral ground glass opacities (GGOs) or consolidations were less commonly seen in children.[5] Although GGO remained the common imaging finding, unilateral, or asymmetric lung involvement was also seen (**Figs. 14A to C**). Compared to the usual viral pneumonia caused by respiratory syncytial virus (RSV), hyperinflation was less common imaging manifestation.[5]

Recurrent Infections

Recurrent infections occurring in a single lobe raise the possibility of an endobronchial obstruction or compression and should be evaluated with bronchoscopy/contrast-enhanced computed tomography (CECT). Areas of consolidation which are transitory and have "waxing and waning" tendency are likely to be noninfective and patients should be investigated for vasculitis or allergic bronchopulmonary aspergillosis (ABPA) **(Fig. 15)**.

Recurrent infections especially in the lower lobes raise the suspicion of aspiration and further evaluation with endoscopy or barium studies can be done. On the other hand, recurrence of infections in different lobes/multisystem such as sinonasal infection warrants investigation for systemic disorders.

JAYPEE BROTHERS



Figs. 14A to C: *Radiographs in pediatric COVID-19.* Bilateral hyperinflation and segmental atelectasis; (A) bilateral diffuse bronchopneumonic pattern; (B) and asymmetric consolidation in right upper and midzone (C).

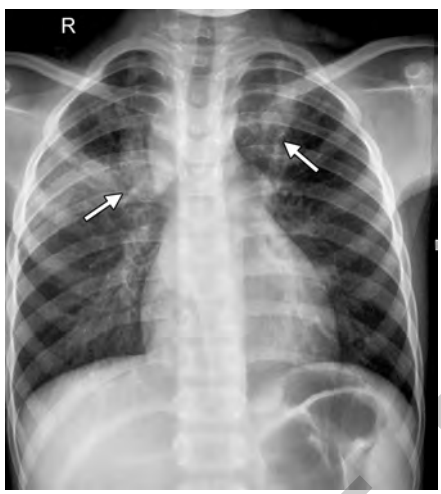

Fig. 15: Allergic bronchopulmonary aspergillosis (ABPA) in an adolescent male. The chest radiograph reveals bilateral upper zone bronchoceles evident as linear finger-like densities (arrows), and a patch of consolidation in the right mid zone.

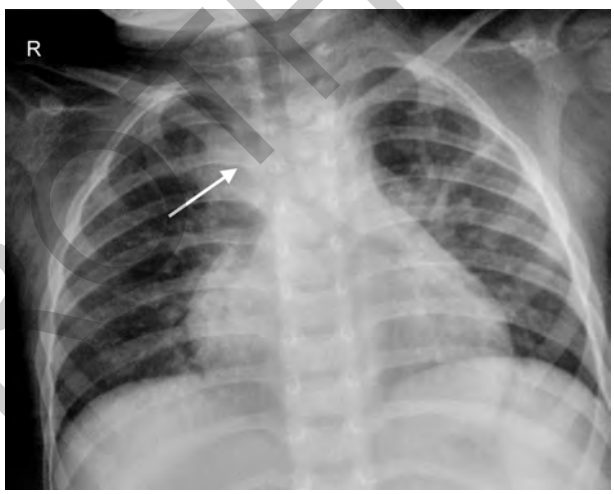

Fig. 16: Tuberculosis. The chest radiographic findings include widened right paratracheal stripe (arrow) and left parahilar consolidation.

◇ MEDIASTINAL AND HILAR LYMPHADENOPATHY

On radiographs, enlarged lymph nodes are seen as mediastinal widening and/or hilar enlargement. Hilar enlargement in association with paratracheal nodes (right > left) and an ipsilateral consolidation, in a concordant clinical setting, are highly suggestive of tuberculosis **(Fig. 16)**. If the mediastinal widening is bilateral, especially if the hilar enlargement or consolidation are not present **(Fig. 17)**, lymphoma is an important differential and a CT scan becomes essential. Presence of bilateral symmetric hilar enlargement with or without paratracheal adenopathy raises the suspicion of sarcoidosis.

◇ EMERGENCY SETTINGS

In emergency/casualty set ups, the chest radiograph is the only imaging modality performed due to its easy availability

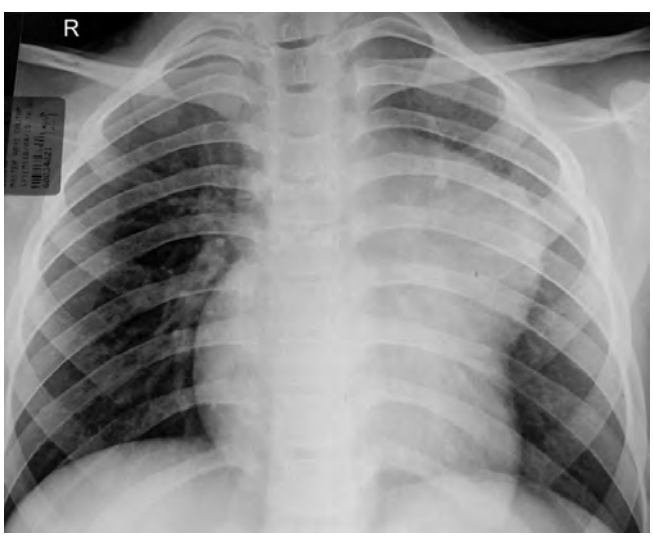

Fig. 17: Anterior mediastinal mass. The mediastinal enlargement is asymmetric, broad based toward the mediastinum and has a sharp margin at the interface with the lung.

JAYPEE BROTHERS

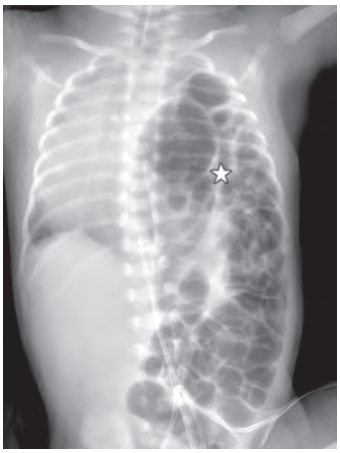

Fig. 18: Congenital diaphragmatic hernia. Note the displacement of bowel loops in the left hemithorax (asterisk); causing contralateral mediastinal shift.

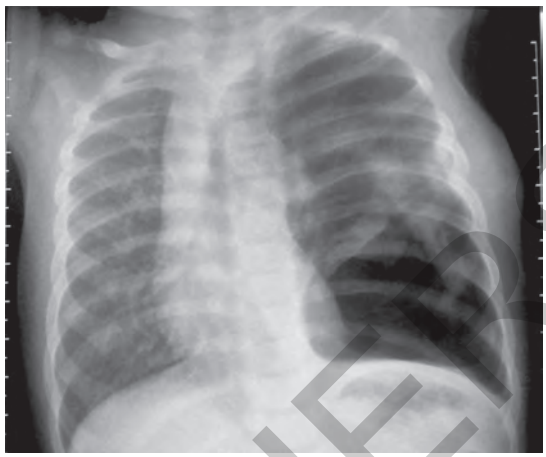

Fig. 19: Pneumothorax on left side.

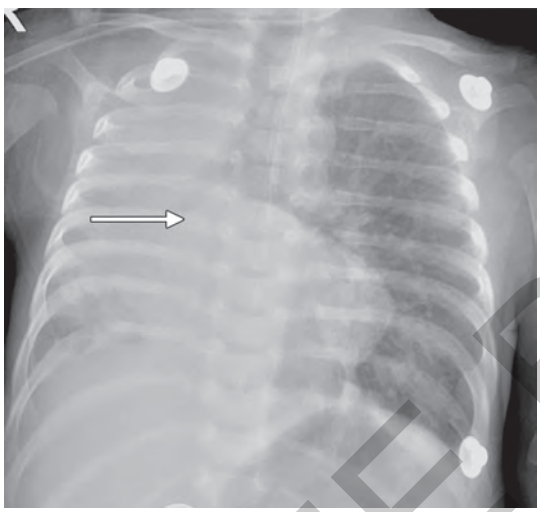

Fig. 20: Opaque right hemithorax with ipsilateral mediastinal shift; secondary to lung collapse caused by mucus plug. Note the abrupt occlusion of the right main bronchus (arrow).

TABLE 2: Clinicoradiographic situations where chest radiograph will suffice.

Acute/subacute settings	• Pulmonary infections • Suspected foreign body aspiration • Pneumothorax
Intensive care settings	Congenital diaphragmatic hernia **(Fig. 18)**
Chronic disorders	• Pleural effusion • Follow-up imaging in bronchiectasis, immunodeficiency, ILDs
Mediastinal/hilar adenopathy	Clinical and radiographic picture concordant with tuberculosis

(ILD: interstitial lung disease)

and short imaging time. In several situations such as a pneumothorax **(Fig. 19)**, pleural effusion or febrile illness with respiratory complaints, the findings are concordant/characteristic and no further imaging is required. In case of pleural effusion especially those which are loculated or large presenting with an opaque hemithorax, USG has an additive value as it can aid in differentiation between mass and effusion in those with contralateral mediastinal shift. In case of suspected foreign body, the chest radiograph may be normal, reveal a radiopaque foreign body, or air trapping or collapsed lung **(Fig. 20)**. In case a radiograph reveals a radiopaque foreign body, its further localization can be done with a lateral view. Other causes such as pulmonary edema and pericardial effusion can also be diagnosed with reasonable certainty on a chest radiograph. Addition of screening USG in the later situation is immensely useful.

There are emergencies such as acute onset respiratory symptoms, febrile illnesses, foreign body inhalation, a chest radiograph in conjunction with clinical findings may suffice **(Table 2)**. In cases of hemoptysis, findings of tuberculosis, bronchiectasis, or diffuse pulmonary hemorrhage may be seen on chest radiograph. However, a CT is often required while evaluating chest radiograph, basic medical examination should never be omitted.

◇ INTENSIVE CARE UNITS/CRITICAL CARE SETTINGS

In ICU settings, pulmonary involvement in patients is frequent, and chest radiograph is often the only imaging modality used.[6-8] Chest radiograph is invaluable in the assessment of position of the tubes and lines **(Fig. 21)**, and also of any complications arising from their insertion **(Fig. 22)**. Bilateral extensive consolidation is frequently encountered in this clinical scenario; and would result from pulmonary edema, diffuse pulmonary hemorrhage, or even extensive infection. Parahilar and mid/lower zone predominance along with pleural effusion and septal

JAYPEE BROTHERS

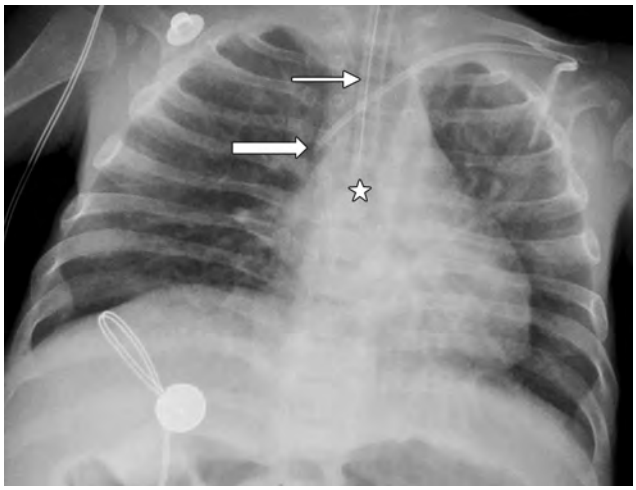

Fig. 21: Normal position of endotracheal (ET) tube (arrow), and central venous line. The tip of ET tube should be well above the carina (asterisk); and the tip of the central venous catheter should be in the cavoatrial junction (block arrow).

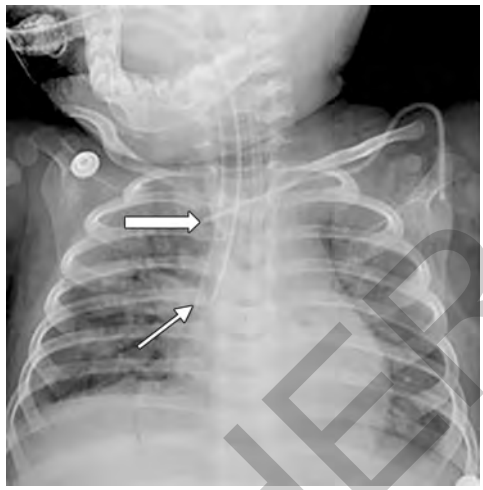

Fig. 22: Malposition of endotracheal (ET) tube, located more distally in the right main bronchus (arrow). Also, the central venous catheter tip is directed toward right brachiocephalic vein (block arrow).

lines suggest pulmonary edema/fluid overload. Upper lobe pulmonary veins and the vascular pedicle (superior mediastinum) may also be widened. The diagnosis of diffuse alveolar hemorrhage requires clinical correlation of drop in hematocrit and has no specific differentiating features. Amongst infections, *Pneumocystis jirovecii* pneumonia characteristically produces this picture, although the consolidation is often not as dense as pulmonary edema and gives a more "ground glass" type appearance.

◇ CHRONIC DISORDERS

In the management of chronic disorders such as bronchiectasis, immunodeficiencies, congenital abnormalities being managed conservatively (e.g., pulmonary hypoplasia), chest radiograph again remains the cornerstone of imaging. This is because of the need for repeated imaging in these patients in the event of worsening/new symptoms. However, a CT is often required for a complete diagnosis initially; and for taking a decision regarding surgical versus nonsurgical management. For instance, bronchiectasis which may appear confined to a single lobe on chest radiograph may be bilateral and more diffuse on CT, thus precluding surgery and initiating work up for secondary causes.

◇ THORACIC MASSES

Thoracic masses **(Fig. 23)** invariably need some form of cross-sectional imaging (CT/MR). CECT is performed most often. However, in case the chest radiograph suggests a posterior mediastinal location, MRI is the preferred modality for demonstrating intraspinal extension.

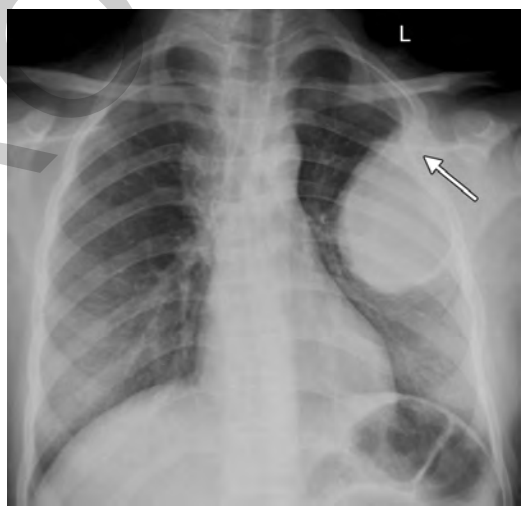

Fig. 23: Left chest wall mass. The chest radiograph reveals the mass, and left third rib destruction erosion (arrow), but a computed tomography (CT) scan is needed prior for definitive extent assessment.

◇ UTILITY OF ULTRASOUND

Over the last few years, there has been a significant expansion of the role of USG in thoracic pathologies. Conventionally, ultrasound has remained the imaging modality of choice for differentiation of solid/cystic nature of any lesion anywhere in the body. In thoracic imaging, characterization and quantification of pleural fluids remain the most common use of USG.[9,10] However, lung ultrasound (LUS) has expanded the scope of USG in several other pulmonary parenchymal pathologies.[11] Amongst the other emerging uses of USG, detection and characterization of mediastinal adenopathy is worth mentioning. Upper mediastinal nodes accessible to USG can be visualized using proper imaging

JAYPEE BROTHERS

TABLE 3: Indications of ultrasonography (USG).[9-12]

Pleural/extrapleural	• Pleural effusion and empyema detection, quantification (**Figs. 24A and B**) • Guided aspiration/drainage/biopsies • Pneumothorax detection
Pulmonary	• Neonatal respiratory distress (RDS/TTN) (**Fig. 25**) • Characterization of peripheral pulmonary pathologies • Monitoring of fluid replacement in the ICU
Mediastinal	• Characterization of anterior mediastinal mass • Normal thymus confirmation (**Fig. 26**) • Posterior mediastinal mass characterization (selective situations) • Detection and characterization of mediastinal lymphadenopathy
Evaluation of opaque hemithorax	
Evaluation of upper airway	

(ICU: intensive care unit; RDS: respiratory distress syndrome; TTN: transient tachypnea of the newborn)

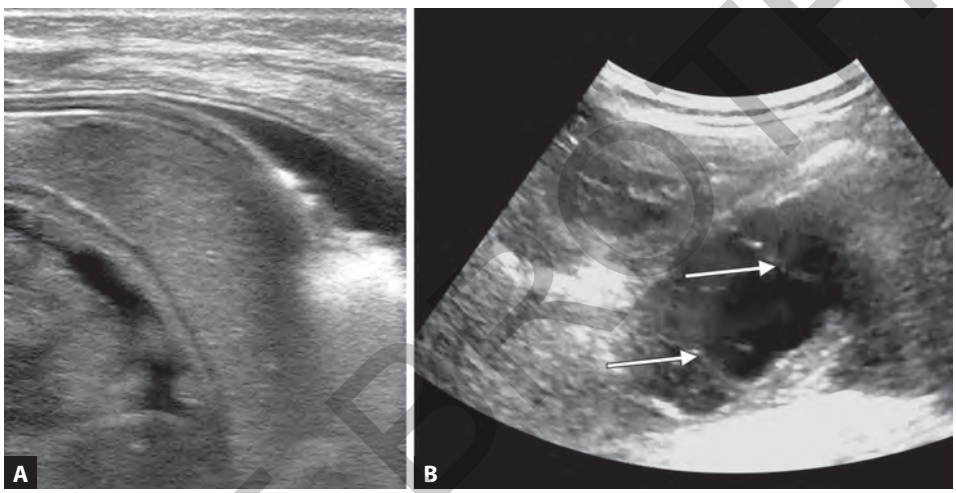

Figs. 24A and B: Free pleural effusion (A) and empyema (B) on chest ultrasound. Note the septae in B (arrows).

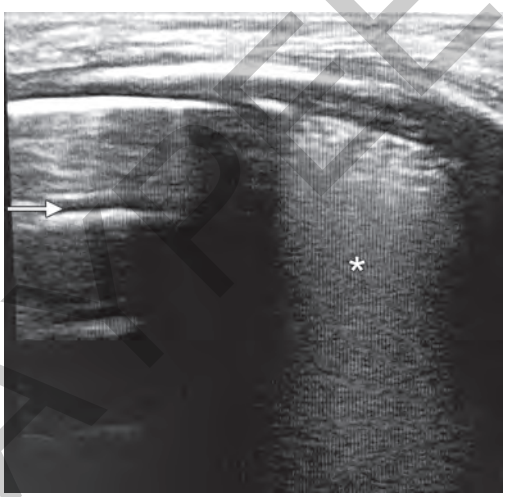

Fig. 25: Lung ultrasound (LUS) in transient tachypnea of newborn (TTN). Image obtained in a longitudinal plane shows dependent areas of confluent B lines (asterisk). The nondependent areas appear normal, showing "A lines" (arrows).

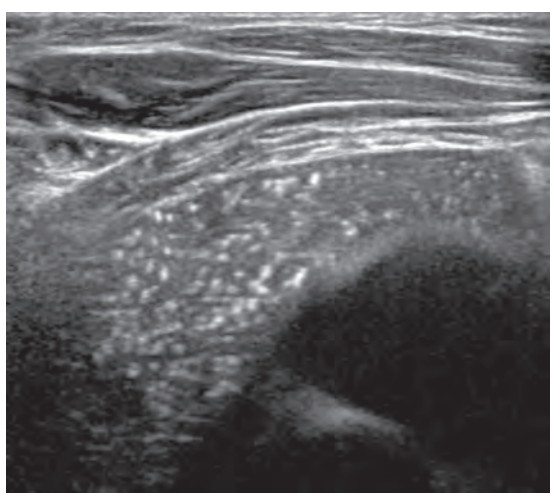

Fig. 26: Ultrasonography (USG) appearance of normal thymus, showing a characteristic speckled or "starry sky" appearance.

technique; thereby complementing radiograph in follow-up of mediastinal lymphadenopathies.[12] **Table 3** enlists the indications of thoracic ultrasound in children.

◇ PLEURAL EFFUSION AND EMPYEMA

Pleural effusion is best diagnosed and managed with a combination of chest radiograph and USG. USG is

JAYPEE BROTHERS

invaluable for septae/loculi and in guiding drainage. CECT is required in nonresolving effusions and when contemplating surgery.

Quantification of pleural fluid can also be performed quite accurately on USG using the Goecke 2 formula. It is measured in erect position, with the transducer placed longitudinally oriented along the dorsolateral/posterolateral aspect of chest wall. The craniocaudal extent (X) and the lung base to mid diaphragm distance (LDD)/subpulmonary height is measured. Volume of effusion is measured using formula "estimated volume (EV) mL = (X + LDD) × 70".[9,10] In conclusion, a combination of chest radiograph and ultrasound can suffice in several settings, not only in emergency and critical care settings but also in elective situations, thus obviating the need of CT scan.

◇ REFERENCES

1. Guo W, Wang J, Sheng M, Zhou M, Fang L. Radiological findings in 210 paediatric patients with viral pneumonia: a retrospective case study. BJR. 2012;85:1385-9.
2. Jana M, Bhalla AS, Gupta AK. Approach to pediatric chest radiograph. Indian J Pediatr. 2016;83:533-42.
3. Balesa J, Rathi V, Kumar S, Tandon A. Chest sonography in the diagnosis of pneumothorax. Indian J Chest Dis Allied Sci. 2015;57:7-11.
4. World Health Organization. Pneumonia Vaccine Trial Investigators Group. Standardization of interpretation of chest radiographs for the diagnosis of pneumonia in children. Geneva, WHO; 2001.
5. Nino G, Zember J, Sanchez-Jacob R, Gutierrez MJ, Sharma K, Linguraru MG. Pediatric lung imaging features of COVID-19: A systematic review and meta-analysis. Pediatr Pulmonol. 2021;56:252-63.
6. Goodman LR, Conrardy PA, Laing F, Singer MM. Radiographic evaluation of endotracheal tube position. AJR. 1976;127:433-4.
7. Godoy MCB, Leitman BS, de Groot PM, Vlahos I, Naidich DP. Chest radiography in the ICU: Part 1, Evaluation of airway, enteric, and pleural tubes. Am J Roentgenol. 2012;198:563-71.
8. Amorosa JK, Bramwit MP, Mohammed TL, Reddy GP, Brown K, Dyer DS, et al. ACR appropriateness criteria routine chest radiographs in intensive care unit patients. J Am Coll Radiol. 2013;10:170-4.
9. Ibitoye BO, Idowu BM, Ogunrombi AB, Afolabi BI. Ultrasonographic quantification of pleural effusion: comparison of four formulae. Ultrasonography. 2018;37:254-60.
10. Bhalla AS, Jana M, Naranje P, Singh SK, Banday I. Challenges in image-guided drainage of infected pleural fluid collections: A review. J Clin Interv Radiol. 2022;6:131-140.
11. Lichtenstein DA. Lung ultrasound in the critically ill. Ann Intensive Care. 2014;4:1.
12. Jana M, Mittal D, Bhalla AS, Naranje P, Kandasamy D, Gupta AK. High resolution transthoracic ultrasound in evaluation of pediatric mediastinal lymphadenopathy. Indian J Pediatr. 2021;88:105.

JAYPEE BROTHERS

for detailed information on pediatric books, visit our website www.jaypeebrothers.com, for detailed information on pediatric books, visit our website www.jaypeebrothe

Essential
Pediatric Pulmonology

Salient Features

- Covering various aspects of respiratory diseases in children
- Multiauthored book, extensively updated by experts
- Provides the key details of anatomy and applied physiology. The section on investigations has been expanded to include advanced lab investigations, pulmonary functions, and molecular tests.
- Common as well as rare infections, include COVID-19 infection have been covered in the section on respiratory infections. The section on noninfectious diseases covers various aspects of asthma, sarcoidosis, eosinophilic lung diseases, hydrocarbon aspirations, central hypoventilation, pulmonary hemorrhage, etc.
- The emerging illnesses such as primary ciliary dyskinesia, cystic fibrosis, interstitial lung diseases, etc. described in detail. These will be useful for India and other resource-limited countries.
- The section on acute pulmonary care including acute lung injury, mechanical ventilation monitoring and airway clearance technique that may be of immense help to practicing pediatricians who provide care for pediatric respiratory illnesses.
- Surgical issues that are essential for pediatricians including foreign body aspirations, intrathoracic tumors and malformations have been included.
- There are chapters on genetics of lung diseases, sudden infant deaths syndrome, drug and environmental diseases of lung.
- Useful for all physicians, who treat children with acute- as well as chronic-respiratory illnesses, and for the postgraduate students and fellows.

Printed in India

Available at all medical bookstores
or buy online at www.jaypeebrothers.com



JAYPEE BROTHERS
Medical Publishers (P) Ltd.
EMCA House, 23/23-B, Ansari Road,
Daryaganj, New Delhi - 110 002, INDIA
www.jaypeebrothers.com

Join us on facebook.com/JaypeeMedicalPublishers

Shelving Recommendation
PEDIATRIC

ISBN 978-93-5465-615-6