others.com, for detailed information on anatomy books, visit our website www.jaypeebrothers.com, for detailed information on anatomy book

diginerve
A Jaypee Initiative
Your Guide at Every Step
Video Lectures | Notes | Self-Assessment
Scan to download the App

Uniquest Series

ANATOMY

A Compilation of All India University Questions 2003–2021

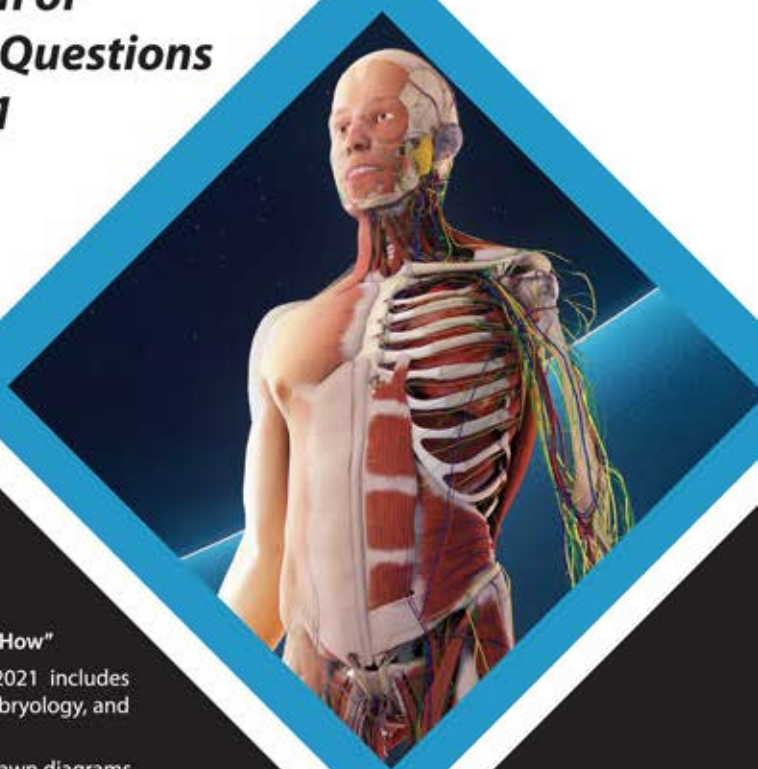

2nd Edition

Anatomy is not just "Where", but also "Why" and "How"

- Decoding of 19 years question papers 2003–2021 includes General Anatomy, Gross Anatomy, Histology, Embryology, and Genetics
- All answers are provided with appropriate self-drawn diagrams
- Answers are in reference to all the anatomy referral books
- More than 80% of the portions of anatomy are covered in these question answers

Sheela Grace Jeevamani
T Preethi Ramya

JAYPEE

CONTENTS

1.	MBBS Examination 2003	1
2.	MBBS Examination 2004	43
3.	MBBS Examination 2005	88
4.	MBBS Examination 2006	143
5.	MBBS Examination 2007	186
6.	MBBS Examination 2008	227
7.	MBBS Examination 2009	271
8.	MBBS Examination 2010	306
9.	MBBS Examination 2011	339
10.	MBBS Examination 2012	381
11.	MBBS Examination 2013	409
12.	MBBS Examination 2014	443
13.	MBBS Examination 2015	476
14.	MBBS Examination 2016	503
15.	MBBS Examination 2017	522
16.	MBBS Examination 2018	533
17.	MBBS Examination 2019	545
18.	MBBS Examination 2020	554
19.	MBBS Examination 2021	562
	Topic-wise University Questions	593

MBBS Examination 2006

ANSWER ALL QUESTIONS

I. Essay questions (15/10 Marks)

1. Describe the pancreas under the following headings: (a) Morphology, (b) Relations, (c) Microscopic anatomy, (d) Development, and (e) Clinical anatomy.
2. Describe the shoulder joint under the following headings: Definition, articular surfaces, ligaments, movements and muscles causing the movements and applied anatomy.
3. Describe the uterus under the following headings: Position, parts, supports, structure, arterial supply, and applied anatomy.
4. Describe the extension, the bed, blood supply and lymphatic drainage of mammary gland. Add a note on its clinical importance.
5. Describe the formation, termination, course, tributaries and relations of portal vein.
6. Describe the internal capsule of brain under the following heading: Position, divisions, constituent fibers, blood supply and applied anatomy.
7. Describe the heart under the following headings: Position, coverings, internal features, conducting and skeletal systems and applied anatomy.
8. Describe the pharynx under the following headings: Extent, divisions, internal features, musculature, structures related and applied anatomy.
9. Define a typical intercostal nerve. Describe the course and distribution. Add a note on its clinical importance.
10. Describe the parotid gland under the following headings: (i) Extension, (ii) Features, (iii) Relations, (iv) Innervations, and (v) Applied aspects.

II. Short notes (5/3/2 Marks)

1. Microscopic structure of hyaline cartilage.
2. Prostatic part of urethra.
3. Adductor canal.
4. Paramesonephric duct.
5. Clavipectoral fascia.
6. Deep peroneal nerve.
7. Microscopic anatomy of fundus of stomach.
8. Anastomosis around elbow.
9. Femoral sheath.
10. Congenital anomalies of kidney.
11. Histology of compact bone.
12. Triceps brachii.
13. Second part of duodenum.
14. Trigone of urinary bladder.
15. Great saphenous vein.
16. Yolk sac.
17. Bronchopulmonary segments.
18. Fate of aortic arches.
19. Hyoglossus muscle.
20. Cerebellar peduncles.
21. Lateral wall of nose.
22. Microscopic structure of ganglions (spinal and sympathetic).
23. Blood supply and nerve supply of scalp.
24. Histology of palatine tonsil.
25. Development of interatrial septum.
26. Circle of Willis.
27. Lacrimal apparatus.

JAYPEE BROTHERS

28. Turner's syndrome.
29. External jugular vein.
30. Histology of cerebellum.
31. Sternocleidomastoid.
32. Development of tongue.

I. ESSAY QUESTIONS

1. Describe the pancreas under the following headings: (a) Morphology, (b) Relations, (c) Microscopic anatomy, (d) Development and (e) Clinical anatomy.

Morphology

Type of Gland

- It is a compound acinar type of gland—majority exocrine and small part of endocrine.
- Ducts
  - Main duct (duct of Wirsung)
  - Accessory duct (duct of Santorini).
- Main duct **(Fig. 1)**
  - Lies near the posterior surface. It begins at the tail, runs left to right
  - Receives tributaries at right angles like a pattern of Herring bone appearance
  - It joins with the bile duct to form the hepato—pancreatic duct/ampulla of Vater which opens on the summit of the major duodenal papilla, along the posteromedial wall of 2nd part of duodenum. It is 8 – 10 cm distal to the pylorus of stomach.
- **Accessory duct**
  - Receives secretion from upper part of head of pancreas
  - Crosses in front of the main duct and communicates with it
  - Opens into the duodenum at minor duodenal papilla. It is 2 cm proximal to major duodenal papilla
  - The opening of the accessory duct lies medial and ventral to that of main duct.

Gross Features

It is lobulated, elongated, J-shaped gland.

- **Parts:** It has head, neck, body, tail and uncinate process **(Fig. 2).**
  - **Head:**
    - Enlarged, lies within the concavity of the duodenum
    - It is flattened
    - 4 borders—superior, inferior, right and left
    - 2 surfaces—anterior and posterior
    - 1 process—uncinate process.
  - **Neck:**
    - Constricted part, directed forwards, upwards and to the left
    - Two surfaces—anterior and posterior.
  - **Body:**
    - Elongated, directed upwards, backwards and to the left
    - Triangular in cross-section
    - 3 borders—superior, inferior and anterior.

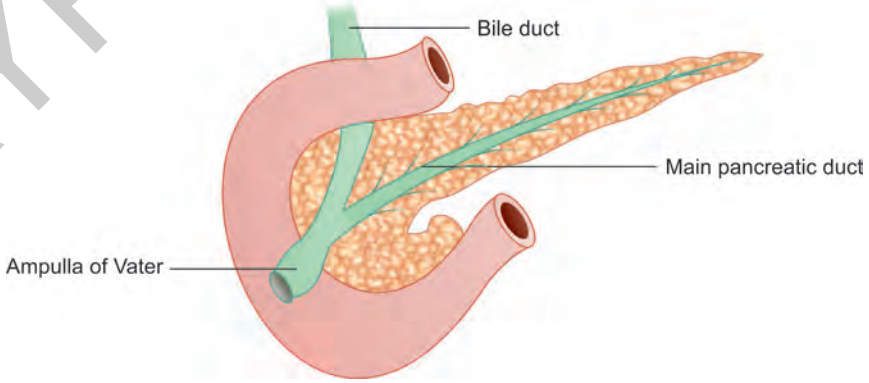

Fig. 1: Ducts of pancreas.

JAYPEE BROTHERS

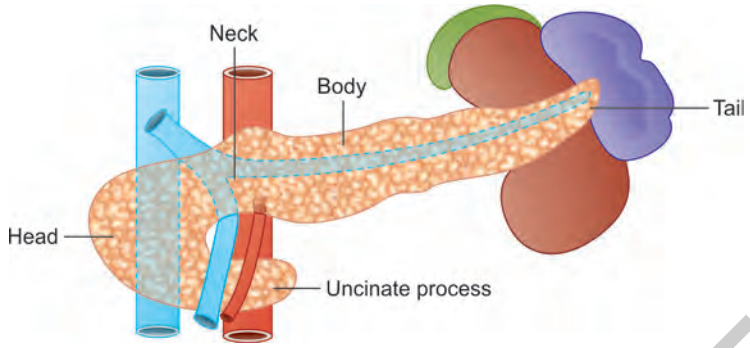

Fig. 2: Parts.

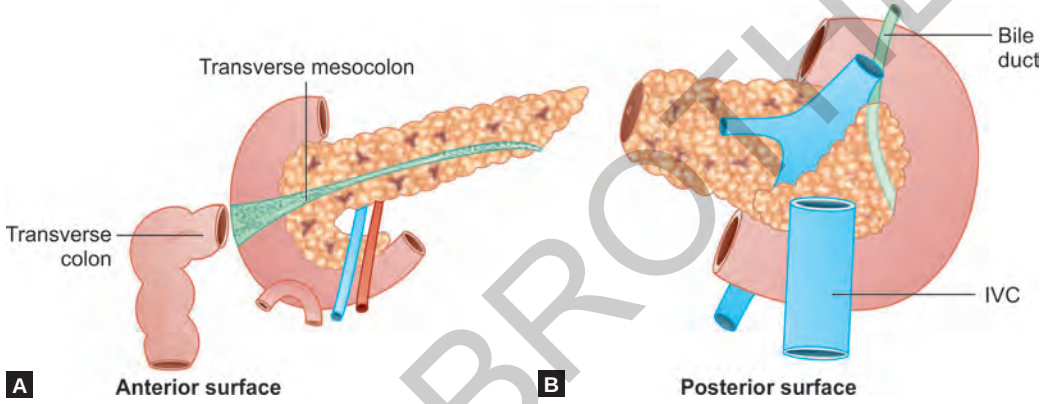

Figs. 3A and B: Relations of head.

- 3 surfaces—anterior, inferior and posterior.

– **Tail:** Left end, lies in the splenorenal ligament along with splenic vessels.

Relations

- **Head (Fig. 3)**
  - Anterior surface
    - First part of duodenum
    - Transverse colon
    - Transverse mesocolon
    - Jejunum.
  - Posterior surface
    - Inferior vena cava (IVC)
    - Terminal parts of renal veins
    - Right crus of diaphragm
    - Bile duct—embedded nearer to the posterior surface.
- **Uncinate process (Fig. 4)**
  - Anterior—superior mesenteric vessels
  - Posterior—aorta.

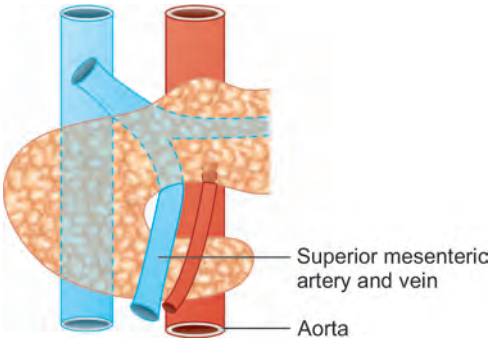

Fig. 4: Uncinate process.

- **Neck**
  - Anterior—lesser sac and pylorus
  - Posterior—superior mesenteric vein and portal vein.
- **Body (Figs. 5 and 6)**
  - Anterior border—gives attachment to transverse mesocolon

JAYPEE BROTHERS

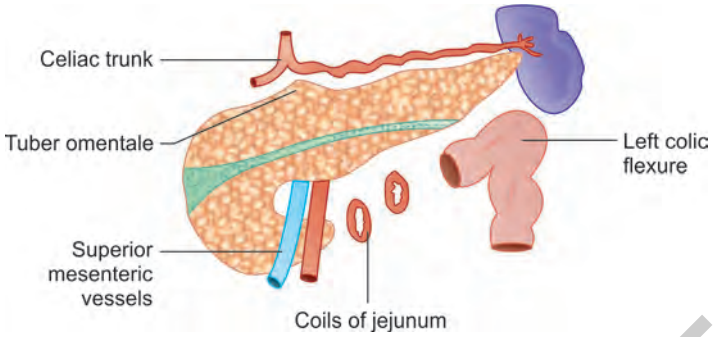

Fig. 5: Relations of body of pancreas.

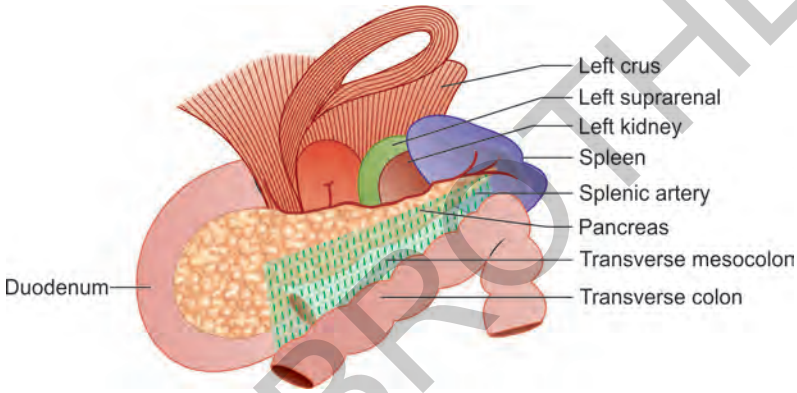

Fig. 6: Posterior relations.

  - Superior border—a projection known as **tuber omentale** is present. It is related to coeliac trunk, hepatic artery and splenic artery
  - Inferior border—superior mesenteric vessels.
- **Anterior surface**
  - Lesser sac
  - Stomach.
- **Posterior surface (Fig. 6)**
  - Aorta
  - Origin of superior mesenteric artery
  - Left crus of diaphragm
  - Left kidney across hilum
  - Left suprarenal gland
  - Left renal vessels
  - Splenic vein.
- **Inferior surface**
  - Duodenal flexure
  - Coils of jejunum
  - Left colic flexure.
- **Tail**
  - Lienorenal ligament
  - Splenic vessels
  - Spleen.

Microscopic Anatomy

Refer short notes 10 – 2003.

Development

Refer short notes 6 – 2005.

Applied Anatomy

- Carcinoma of head of pancreas is common. It results in jaundice, ascites
- Annular pancreas—obstructs the 2nd part of duodenum
- Pancreatitis—inflammation of pancreas presents with symptoms of fever and pain at the back
- Endoscopic retrograde cholangio pancreatography (ERCP), Magnetic

JAYPEE BROTHERS

retrograde cholangiopancreatography (MRCP) are radiological procedures to out pattern of duct system.

2. Describe the shoulder joint under the following headings: Definition, articular surfaces, ligaments, movements and muscles causing the movements and applied anatomy.

Type (Definition)

Synovial, multi axial, and ball and socket variety.

Articulating Parts (Fig. 7)

- Glenoid cavity of scapula and the head of humerus
- **Glenoid cavity of scapula**: Pear shaped, concave, directed upwards, forwards and laterally. Anterior border is notched and the cavity is lined by articular cartilage which is thin at the centre and thick at the periphery. The cavity is deepened by the glenoidal labrum
- **Head of humerus:** Hemispherical, directed upwards, backwards and medially, lined by articular cartilage which is thick at the centre and thin at the periphery. It forms one-third of sphere.

Ligaments

- **Fibrous Capsule (Fig. 8):**
  - Medially attached to the margin of glenoid cavity beyond glenoidal labrum and encloses the origin of long head of biceps
  - Laterally to the anatomical neck of humerus

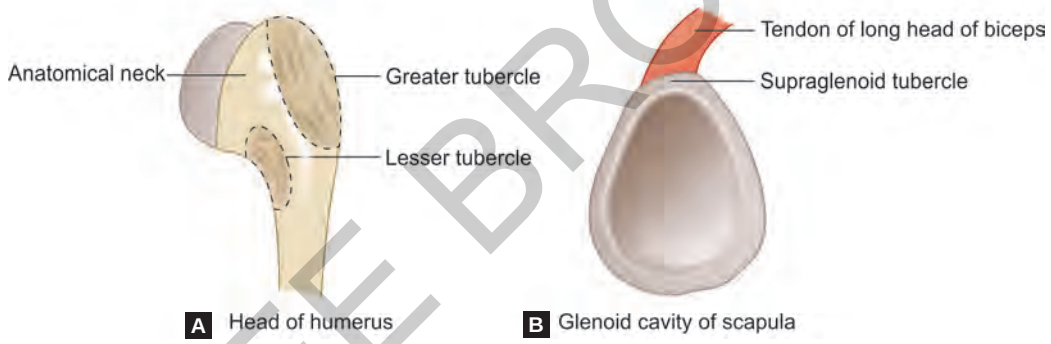

Figs. 7A and B: Articulating parts.

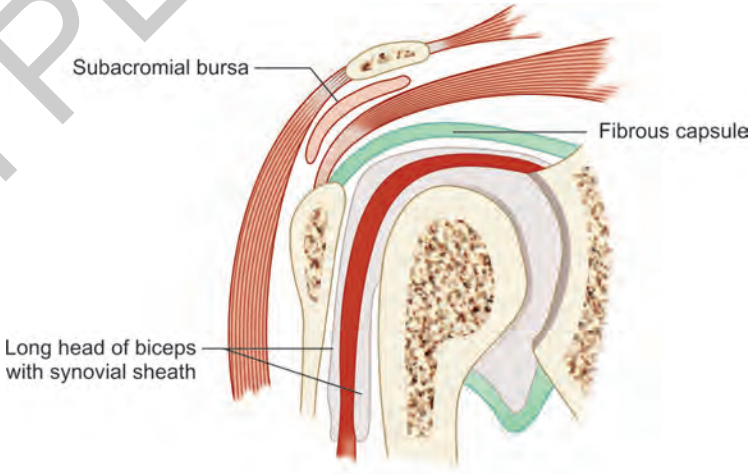

Fig. 8: Fibrous capsule.

JAYPEE BROTHERS

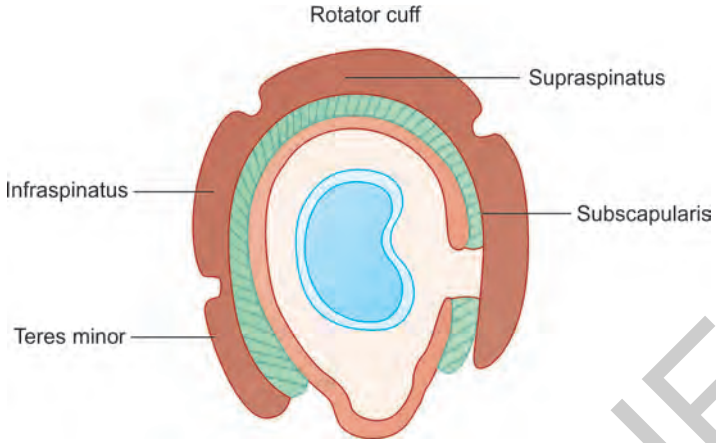

Fig. 9: Rotator cuff.

- Inferiorly extends for 1 cm below the anatomical neck
- The capsule is least supported inferiorly
- It is strengthened by the **rotator cuff** The muscles fuse with the capsule of the shoulder joint and is called as **musculotendinous cuff/rotator cuff of Codmann (Fig. 9)**
- The cuff usually collide against the coracoacromial arch when the humerus is abducted, flexed and internally rotated.
- Components of rotator cuff
  - Anteriorly—subscapularis
  - Superiorly—supraspinatus
  - Posteriorly—infraspinatus and teres minor
  - These tendons merge with lateral part of articular capsule to form the cuff
- It is supported inferiorly by the long head of triceps. The axillary nerve and posterior circumflex vessels intervene between triceps and the capsule
- The synovial membrane lines the capsule
- Three **openings** are present in the capsule. 1. Opening anteriorly communicating with subscapular bursa. 2. Opening for the passage of long head of biceps. 3. Posteriorly an inconstant opening communicating with infraspinatus bursa.

- **Transverse humeral ligament (Fig. 10)** Between lesser tubercle and greater tubercle of humerus. It acts as a retinaculum and holds the tendon of long head of biceps brachii in position.

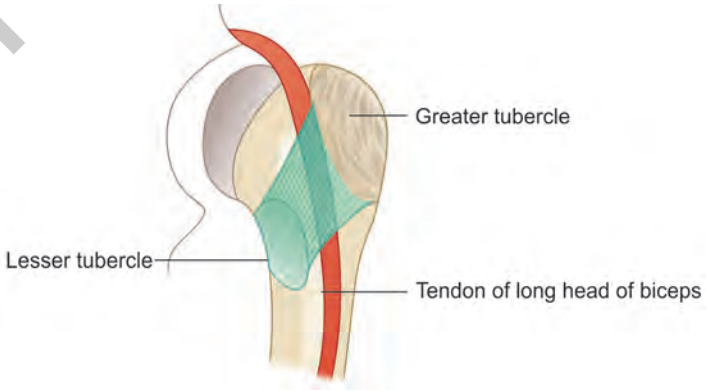

Fig. 10: Transverse humeral ligament.

JAYPEE BROTHERS

- **Glenohumeral ligament (Fig. 11)**
  - It is seen inside the capsule
  - It is seen as 3 bands—superior, middle and inferior bands
  - These are thickening of the anterior aspect of the capsule
  - Extends between the anterior border of glenoid cavity to the anatomical neck of humerus and lesser tubercle
  - It is taut during abduction and rotation of humerus.
- **Coracohumeral ligament**: Extends from the base of coracoid process to the capsule between greater and lesser tubercles. Checks the lateral rotation of humerus.
- **Glenoidal labrum**
  - It is made of fibro cartilage, triangular in section
  - Attached to the margin of glenoid cavity
  - Helps to deepen the cavity.
- **Synovial sheath and bursae around the joint:**
  - The synovial membrane lines the fibrous capsule
  - A sheath envelops the tendon of the long head of biceps brachii and extends up to the surgical neck of humerus
  - Subacromial bursa—between supraspinatus below and coracoacromial arch and deltoid above. It is the largest bursa. It is also called as the sub deltoid bursa when it extends deep to deltoid
  - Subscapular bursa – between subscapularis and fibrous capsule. It communicates with the joint cavity

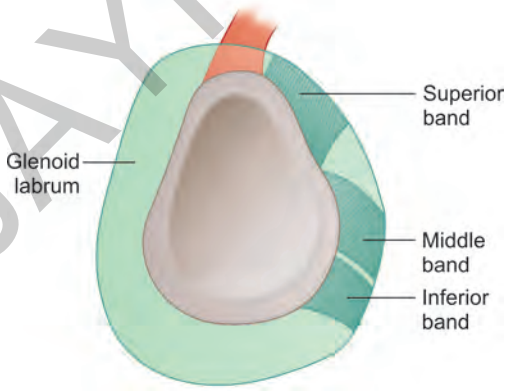

Fig. 11: Glenohumeral ligament.

  - Infraspinatus bursa – occasionally present
  - Supraacromial bursa lies above the acromion process.

Movements and Muscles Producing

- **Flexion:**
  - Carrying the arm anteromedially
  - It is along horizontal plane
  - Muscles producing are: Clavicular head of pectoralis major, anterior fibers of deltoid, coracobrachialis, short head of biceps brachii.
- **Extension**: Muscles producing are—posterior fibers of deltoid, teres major, latissimus dorsi, sterno-costal fibers of pectoralis major.
- **Abduction**:
  - The arm is carried away from the trunk laterally till it comes in horizontal position
  - The abduction is further continued to raise the arm above the head and the arm moves a total of 180 degrees (overhead abduction)
    - 0 – 15 degrees: By supraspinatus
    - 15 – 90 degrees: By middle fibers of deltoid
    - Above 90 degrees: By trapezius and serratus anterior.
  - Up to 90 degrees, the movement is confined to the shoulder joint
  - For next 30 degrees, there is lateral rotation of humerus
  - Above 120 degrees the abduction is done by scapular movement along with the shoulder joint movement
  - For every 15 degrees of movement 10 degree is contributed by shoulder and 5 degrees by the scapular movement in the ratio of 2:1.
- **Adduction**: Muscles producing are Latissimus dorsi, subscapularis, infraspinatus, teres major and minor, pectoralis major, short head of biceps brachii, long head of triceps brachii
- **Medial rotation**: Pectoralis major, anterior fibers of deltoid, latissimus dorsi, teres major, subscapularis.

JAYPEE BROTHERS

- **Lateral rotation**:
  - Posterior fibers of deltoid, infraspinatus, teres minor
  - **Circumduction**: Successive movements as above.

Applied Anatomy

- **Subacromial bursitis**: Inflammatory reaction may be due to calcium deposition in the tendon of supraspinatus leading to irritation of the subacromial bursa
- **Calcified scapulohumeral bursitis**: Inflammation and calcification of the subacromial bursa results in pain, tenderness, and reduction in movements of shoulder joint
  - Rotator cuff disease
  - (Refer Short 4 – 2003)
  - **Dislocation:** It is the commonest joint to dislocate. Usually the dislocation is anteroinferior which lacks support. Posterior dislocation is usually due to violent movement as in epileptic seizures or electric shock
  - **Tear of glenoid labrum** commonly occur in the baseball players. The tear is due to sudden contraction of biceps
  - **Rupture of tendon of supraspinatus** leads to difficulty in initiation of abduction of shoulder.

3. Describe the uterus under the following headings: Position, parts, supports, structure, arterial supply, and applied anatomy.

Position, Parts, Supports, Applied anatomy-Refer Essay Q. No. 2 – Aug 2004.

- **Microstructure of uterus (Fig. 12):** It is made up of 3 layers—endometrium, myometrium, perimetrium
- **Endometrium** is mucous layer
  - Lined by columnar epithelium, and before puberty by ciliated columnar
  - Deep to epithelium the stroma contains numerous simple tubular glands lined by columnar epithelium
  - The endometrium undergoes cyclic changes according to the menstrual cycle
  - Glands are straight in postmenstrual phase, in proliferative phase elongates, and secretary phase become twisted.
- **Myometrium is** muscular layer
  - Bundles of smooth muscles in various direction
  - Arranged as three layers—outer longitudinal, middle circular, inner oblique
  - Middle circular layer contains blood vessels and hence called **stratum vasculare**
  - The inner oblique layer contraction helps to arrest the uterine bleeding

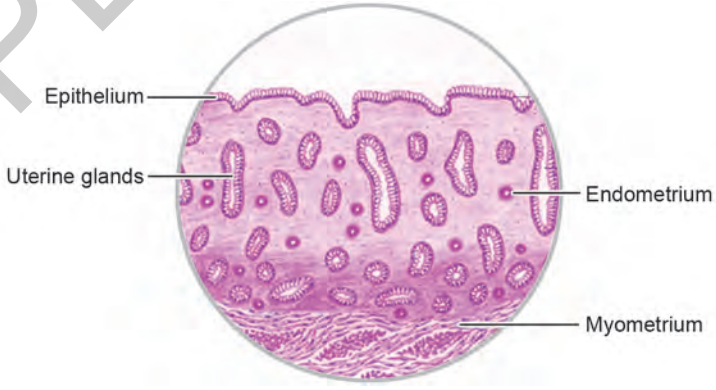

Fig. 12: Histology of uterus.

JAYPEE BROTHERS

II. SHORT NOTES

1. Microscopic structure of hyaline cartilage.

- Hyaline cartilage is so called because it has ground glass appearance
- It is covered by fibrous membrane called the **perichondrium**
- It is made of cells and matrix
- The **cells**—chondrocytes are round in the deeper part and flat towards perichondrium
- **Chondrocytes** are present in groups.
- Groups of cartilage cells are called cell-nests (isogenous cell groups).
- They are formed by division of a single parent cell, and separation is prevented by dense matrix
- The cells are surrounded by lacunae.
- The **matrix** contains fibers and ground substance
- The matrix is homogenous because the refractive index of fibers and ground substance are same.
- **Fibers:** Many collagen fibers type I are present in the matrix.
- Around cell nests, the matrix stains deeply called **territorial matrix** or lacunar capsule.
- The matrix lying in between the cell nests is called **interterritorial matrix**.
  - An isogenous cell group, together with the pericellular matrix, is referred to as a **chondron**.
- **Property**: As age advances the hyaline cartilage can get ossified
- **Distribution:**
  - Costal cartilages
  - Articular cartilage
  - Skeletal framework of the larynx: Thyroid cartilage, cricoid cartilage and part of arytenoid cartilage
  - Trachea and large bronchi
  - Parts of the nasal septum and lateral wall of the nose
  - In growing bone epiphyseal plate
- **Function**: Resists tensional forces.

2. Prostatic part of urethra.

- It is a part of male urethra lying within the prostate gland
- **Commencement:** The preprostatic part is continued as prostatic part. It pierces the base of prostate at the junction of anterior one third and posterior two-third
- **Course:** Runs closer to the anterior surface of the gland, within the substance of the prostate
- **Termination:** Emerges from the prostate in front of apex, and continued as membranous part of urethra

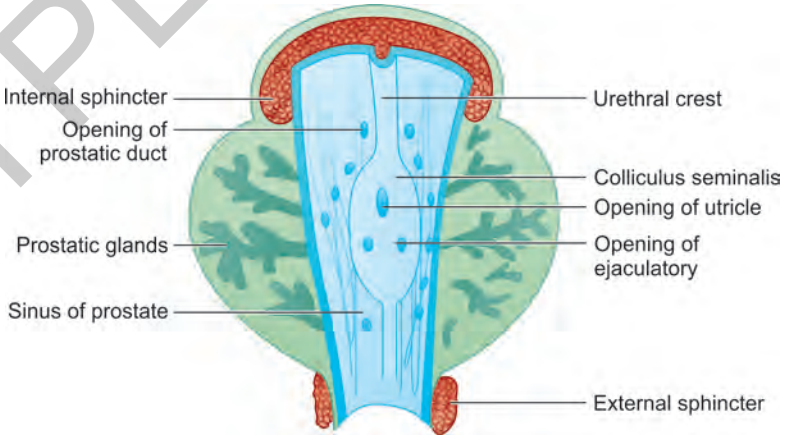

Fig. 28: Prostatic urethra.

JAYPEE BROTHERS

- **Features in the posterior wall:**
  - A midline ridge is seen known as **urethral crest**
  - Hence the lumen of the prostatic urethra is crescent shaped in cross section
  - There is an elevation at the middle of the crest called **verumontanum (colliculus seminalis)**
  - In the middle of verumontanum a slit like opening is the orifice of **Prostatic utricle**
  - On each side of this orifice are the **openings of the ejaculatory ducts** which is formed by the union of vas deferens and duct of seminal vesicle
  - A shallow depression is present on each side of the crest—called **prostatic/ urethral sinus**
  - Into the sinus about 15 – 20 ducts of prostate gland open.
- **Prostatic utricle:**
  - It is a blind sac 6 mm long; directed upwards and backwards
  - Its wall is made of fibrous tissue, muscle fibers and mucous membrane with glands
  - It is developmentally **remnant** of para-mesophrenic duct (Mullerian duct)
  - It is **homologous** with the vagina of female; hence the name **vagina masculina**
  - According to some it is similar to uterus hence called as utricle.
- **Lining epithelium:** Up to colliculus seminalis it is lined by transitional epithelium, below it is lined by pseudostratified or stratified columnar epithelium
- **Applied anatomy:** Hypertrophy of median lobe can compress the prostatic part of the urethra resulting in symptoms of urinary retention.

3. Adductor canal.

It is an intermuscular tunnel in the thigh region

- **Other names:** Subsartorial canal or Hunter's canal named after John Hunter for treating popliteal aneurysm
- **Situation:** In distal two-third of medial side of thigh
- **Extent:** From apex of femoral triangle to tendinous opening in adductor magnus
- **Shape:** Triangular in section
- **Boundaries:**
  - **Posterior wall:** Adductor longus above and adductor magnus below
  - **Anterolateral wall:** Vastus medialis
  - **Roof:** Subsartorial fascia extending from anterior to posterior wall covering the femoral vessels, sartorius and the subsartorial plexus of nerves lie on the fascia.

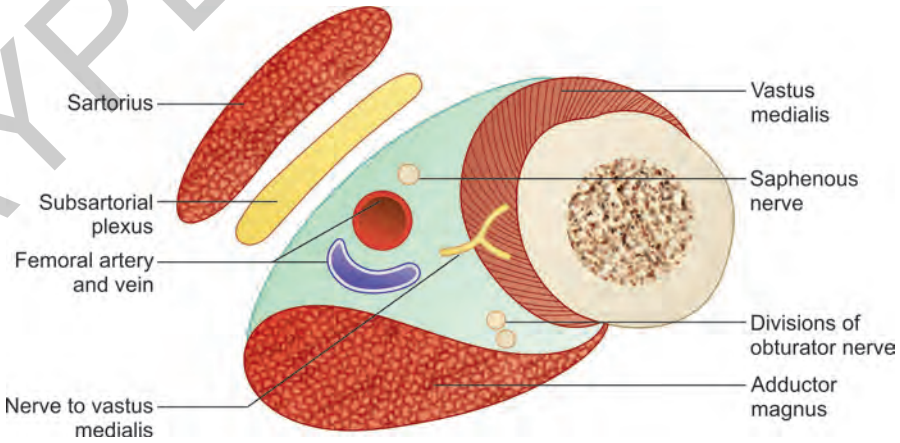

Fig. 29: Adductor canal.

JAYPEE BROTHERS

- **Contents:** Femoral artery
  - Femoral vein is posterior to artery in the upper part and then it becomes lateral
  - Saphenous nerve crosses the artery from lateral to medial side
  - Nerve to vastus medialis
  - Descending genicular artery
  - Posterior division of obturator nerve.

Applied Anatomy

- Ligation of femoral artery to prevent bleeding from a distal cut end
- Ligation of femoral artery in popliteal artery aneurysm is done in subsartorial canal.

4. Paramesonephric duct.

- The paramesonephric ducts are developed in both sexes
- But it is the main genital duct in female
- It is also known as the **Mullerian duct**
- It is from intermediate mesoderm
- In the 6th week coelomic epithelium invaginates and appear like a longitudinal groove
- **Situation:**
  - Lateral to the mesonephric ridge
  - The margins of the groove gradually fuse to convert the groove into a duct
  - The cranial end of the duct opens into the coelomic cavity
  - Its caudal end is seen as a solid tube and later lumen is acquired as it descends to reach the definitive urogenital sinus.
- **Parts:** Each paramesonephric duct consists of three parts:
  i. Cephalic vertical part
  ii. Intermediate horizontal part
  iii. Caudal vertical part.
- **Derivatives in female**
  - The **cephalic vertical part** and most of the **intermediate horizontal parts** of each paramesonephric duct form the respective **uterine tube**
  - The commencement of the duct persists as the abdominal opening of the uterine tube through which it communicates with the coelomic cavity
  - Due the descent of the ovaries, the uterine tubes are pulled to the pelvic cavity and undergo a horizontal course
  - The **caudal vertical parts** of both paramesonephric ducts fuse in caudo-cranial direction
  - The partition between them completely disappears by the 3rd month
  - The single duct thus formed is the **uterovaginal canal**
  - The cranial part of this canal forms the entire **uterus**
  - The most cephalic point of fusion of the two ducts represents the site of the future fundus.
  - The caudal part of the uterovaginal canal is for the development of **vagina.**
- **Derivatives in male**
  - The paramesonephric duct disappears

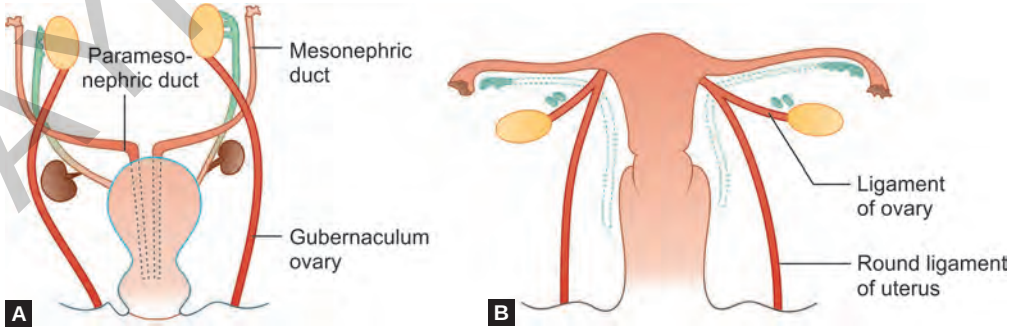

Figs. 30A and B: Paramesonephric duct.

JAYPEE BROTHERS

for detailed information on anatomy books, visit our website www.jaypeebrothers.com, for detailed information on anatomy books, visit our webs

Uniquest Series
ANATOMY

Salient Features

- Presented in a simple and lucid language, student-friendly, easy to understand
- The answers are precise with bullet points
- To make learning easier, illustrations are added to correlate with theory
- Clinical/applied anatomy is dealt with for all the answers
- Few mnemonics are given to remember easily
- Muscle attachments are given as tables along with diagrams
- Helpful for students preparing for their anatomy examinations
- Multiple Choice Questions are included, decoded and explanation with references.

Sheela Grace Jeevamani MBBS MS (Anatomy) is Formerly, Professor and Head, Department of Anatomy, Karpagam Faculty of Medical Sciences and Research, Coimbatore, Tamil Nadu, India. She has three decades of teaching experience. She retired from government service as Additional Director of Medical Education/Secretary Selection Committee, Tamil Nadu and served as Dean, Theni Government Medical College and Hospital, Theni, Tamil Nadu. She is recipient of Best Administrator Award from The Tamil Nadu Dr MGR Medical University, Best Doctor Award—Indian Medical Association, Best Teacher Letter of Appreciation—Health Secretary.

T Preethi Ramya MBBS MD (Anatomy) is Senior Lecturer, Clinical Anatomy Coordinator, School of Medicine, University of Notre Dame, Australia and Casual Academic Tutor, Discipline of Anatomy and Histology, University of Sydney and University of Technology Sydney, Australia and Formerly, she served as an Associate Professor, Kilpauk Medical College, Chennai, Tamil Nadu, India.

Printed in India

Available at all medical bookstores
or buy online at www.jaypeebrothers.com



JAYPEE BROTHERS
Medical Publishers (P) Ltd.
EMCA House, 23/23-B, Ansari Road,
Daryaganj, New Delhi - 110 002, INDIA
www.jaypeebrothers.com

Join us on facebook.com/JaypeeMedicalPublishers

Shelving Recommendation
ANATOMY

