peebrothers.com, for detailed information on obstetrics & gynecology books, visit our website www.jaypeebrothers.com, for detailed information on obstetrics & gynecology

SAQ in Gynecologic Cancers

(Part I) with Model Answers

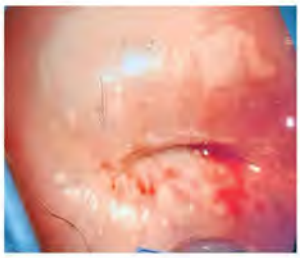

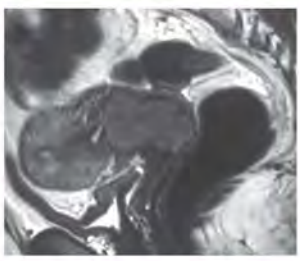

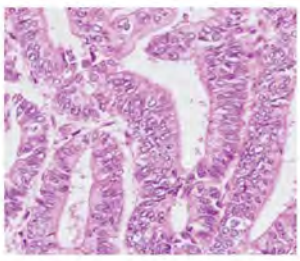



Editor
Professor Farhat Hussain

Forewords
TA Chowdhury
Abdul Bayes Bhuiyan

JAYPEE

Contents

1. Cervical Cancer Screening and Abnormal Cervical Cytology 1
2. Cervical Intraepithelial Neoplasia 24
3. Cervical Carcinoma 42
4. Endometrial Carcinoma 69
5. Gestational Trophoblastic Neoplasia 93
6. Epithelial Ovarian Cancer 112
7. Adnexal Mass, Germ Cell, and Sex Cord Ovarian Tumor 141

3

CHAPTER

Cervical Carcinoma

Question 1

A woman with cervical cancer (CC) stage IB1 with cervical growth 1.5 × 1.5 cm **(Fig. 1)** was admitted in the hospital for surgical management. The patient had squamous cell carcinoma, grade 2 in cervical biopsy.

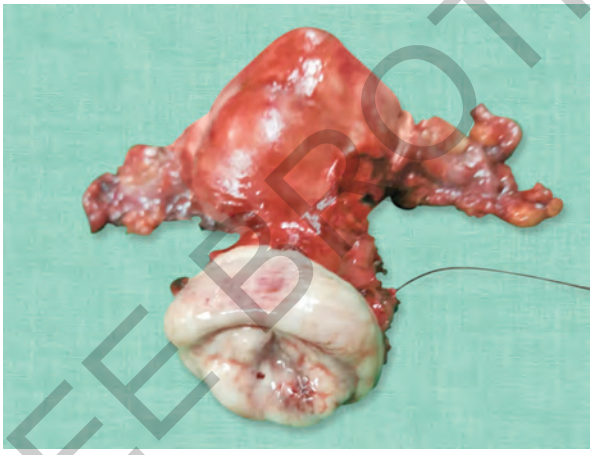

Fig. 1: Resected uterus with cervical growth.

1.1. Which surgical management is appropriate for the patient? (1)

1.2. Justify the role of pelvic lymphadenectomy here. (0.5 × 4 = 2)

1.3. Is laparoscopic-assisted procedure feasible in this case? What are the advantages? (1 + 0.25 × 4 = 2)

Answer 1.1

Radical hysterectomy, type III with pelvic lymphadenectomy.

Answer 1.2

In stage IB1 CC, approximately >15% have positive lymph nodes. So systematic pelvic lymphadenectomy in such cases is helpful to:

- Accurately stage the disease
- Provide therapeutic benefit by resecting bulky positive lymph node

JAYPEE BROTHERS

- Stratify patient for adjuvant treatment
- Provide prognostic information

Answer 1.3

Laparoscopic radical hysterectomy with pelvic lymphadenectomy is feasible as the tumor is small in sizes (1.5 × 1.5 cm).

Advantages:

- Less morbidity
- Few blood transfusions due to decreases in blood loss
- Faster recovery
- Shorter hospital stays

Question 2

A 46-year-old lady was diagnosed as stage IIA1 CC, histology subtype—squamous cell carcinoma. She was offered to choose any modality of treatment—surgery or radiotherapy assuring her that both have similar outcomes and efficacy. The patient was convinced to select surgery as the primary treatment.

2.1. Enlist the advantages of surgical treatment. (0.5 × 4 = 2)

2.2. Name the surgery that will be offered to the patient. Specify the sites of division of cardinal and uterosacral ligament. (1 + 0.5 × 2 = 2)

2.3. Outline the extent of pelvic lymph nodes removal. (0.25 × 4 = 1)

Answer 2.1

The surgical treatment provides advantages as follows:

- Accurate staging of disease is possible based on histopathologic findings.
- Individualization of adjuvant treatment.
- Preservation of ovarian function.
- Psychological relief of patient as the disease organ is removed.

Answer 2.2

- Type III radical hysterectomy with pelvic lymphadenectomy
- In type III radical hysterectomy, the division of ligaments is as follows:
  - Cardinal ligament is divided at the pelvic side wall.
  - Uterosacral ligament is divided near sacral attachment.

Answer 2.3

Pelvic lymph nodes which are removed include:

- Parametrial nodes
- Obturator nodes

JAYPEE BROTHERS

- External iliac nodes
- Internal iliac nodes
- Common iliac nodes

Question 3

A 43-year-old woman presented with postcoital and intermenstrual bleeding for the last 8 months. On clinical evaluation, there was a barrel-shaped cervix with free fornices and parametrium. Cervical biopsy and endocervical curettage (ECC) revealed adenocarcinoma of cervix, grade 2.

3.1. What is the preferred treatment in this case? Justify. (1 + 2 = 3)

3.3. Mention the schedule of post-treatment surveillance of this patient. (0.5 × 4 = 2)

Answer 3.1

- The preferred treatment is radical hysterectomy **(Fig. 2)** with pelvic lymphadenectomy.
- In adenocarcinoma histologic type of cancer cervix, radiotherapy is discouraged as primary treatment because adenocarcinoma is generally regarded as radio-resistant in comparison to squamous cell carcinoma. Because of the above concept, as the patient is in early stage, surgery is selected as preferred treatment.

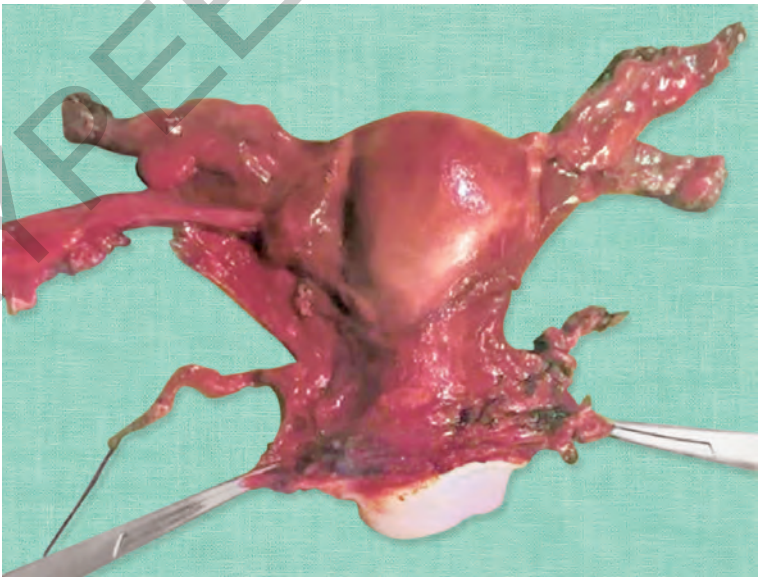

Fig. 2: Radical hysterectomy specimen depicting endocervical adenocarcinoma.

JAYPEE BROTHERS

- Moreover, since the patient is young, sexual function can be well maintained following surgery by:
  - Conserving the ovaries
  - Excising shorter length (1.5 cm) of vagina

Answer 3.2

Patient is monitored after treatment to detect early recurrence. The schedule of follow-up is:

- Monthly for first 3 months
- 3 monthly for the next 2 years
- 6 monthly for the next 5 years
- Annually for the rest of life

Question 4

A 42-year-old multiparous lady is diagnosed as invasive CC—squamous cell type, FIGO stage 1B2. She got admitted for treatment.

4.1. What will be the primary treatment for her? (2)

4.2. Mention four important points to differentiate modified radical hysterectomy from radical hysterectomy. (0.75 × 4 = 3)

Answer 4.1

- Either surgery or radiotherapy anyone can be chosen as primary treatment as both have similar outcomes.
- Because of the advantages in young patient, surgery will be preferred.

Type III radical hysterectomy with pelvic lymphadenectomy will be the choice of surgery.

Answer 4.2

TABLE 1: Differentiation between type II and type III radical hysterectomy.

Points	***Type II radical hysterectomy***	***Type III radical hysterectomy***
Indication	• Stage 1A1 with LVSI • Stage 1A2	Stage IB1, IB2, IIA
Uterine artery	Ligated just medial to the point at which it crosses the ureter	Ligated at its origin where it branches off the hypogastric artery
Vagina removed	1–2 cm of upper vagina is removed	2–3 cm of upper vagina is removed
Cardinal ligament **(Fig. 3)**	Divided at the medial half	Divided at pelvic side wall
Uterosacral ligament **(Fig. 3)**	Medial half is removed	Divided near sacral attachment

(LVSI: lymphovascular space invasion)

JAYPEE BROTHERS

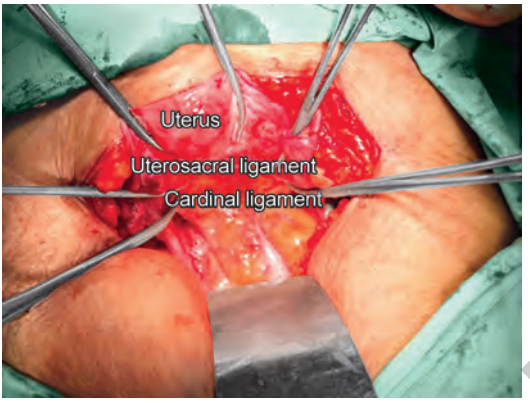

Fig. 3: Division of uterosacral and cardinal ligaments in type II, type III radical hysterectomy.

Question 5

A patient was diagnosed as cervical carcinoma, squamous cell subtype, grade 2. Clinical evaluation revealed a cauliflower tumor (3 × 4.5) cm in the anterior lip of cervix but the fornices and both parametrium were free. Magnetic resonance imaging (MRI) of abdomen showed pelvic lymph nodes enlarged with unilateral hydronephrosis.

5.1. What is the stage of the disease? Specify the probable reason for unilateral hydronephrosis in this case. (0.5 + 1 = 1.5)

5.2. What is the standard treatment here? (1.5)

5.3. If the patient has bilateral hydronephrosis, what treatment should be given? (2)

Answer 5.1

- Stage IIIC1
- The ureter is probably compressed externally by enlarged pelvic lymph nodes causing unilateral hydronephrosis **(Fig. 4)**.



Fig. 4: Magnetic resonance imaging (MRI) urogram showing hydroureter and hydronephrosis.

JAYPEE BROTHERS

Answer 5.2

The standard treatment is concurrent chemoradiation (CCRT) but before radiotherapy, resection of bulky lymph nodes via extraperitoneal approach if done will significantly improve the survival of the patient.

Answer 5.3

Renal status should be assessed by creatinine clearance.

If creatinine clearance is <50 mL/min, bilateral ureteric stenting should be done followed by chemoradiation.

Question 6

A 40-year-old woman underwent simple hysterectomy for abnormal uterine bleeding. Invasive CC was found during pathologic evaluation of specimen of uterus.

6.1. How should the woman be evaluated now? (1 + 1 = 2)

6.2. Mention the treatment options for such patient. (1 + 1 = 2)

6.3. If repeat surgery is done, what are the challenges faced by the surgeon? (1)

Answer 6.1

For evaluation:

- The extent of disease should be assessed by:
  - Positron emission tomography (PET)/computed tomography (CT) scan if available
  - If not available, then chest X-ray
  - CT or MRI scan of pelvis and abdomen
- Hysterectomy specimen should be assessed for high-risk features:
  - Positive surgical margins
  - Deep infiltrating tumor
  - Lymphovascular space invasion (LVSI)

Answer 6.2

The treatment option is CCRT provided:

- No evidence of metastatic disease is found
- No high-risk features in hysterectomy specimens

If any of the above is found, the treatment option is repeat laparotomy followed by:

- Radical parametrectomy
- Upper vaginectomy
- Pelvic lymphadenectomy with or without adjuvant CCRT.

JAYPEE BROTHERS

Answer 6.3

Repeat surgery is difficult due to previous scarring, adhesions, and distortion of anatomy.

It must be done in centers where experienced surgeons are available.

Question 7

A woman who is clinically diagnosed as early staged CC was subjected to imaging for accurate staging.

7.1. Which imaging is preferable for determining accurate staging of cancer cervix? Give reasons. (1)

7.2. Enlist five information obtained from the imaging tool for accurate staging. (0.5 × 5 = 2.5)

7.3. When PET scan use is indicated? (1 + 0.5 = 1.5)

Answer 7.1

Magnetic resonance imaging having high soft-tissue resolution is the preferred imaging tool to accurately determine the staging.

Answer 7.2

Information that are obtained from MRI include:

- Primary tumor diameter
- Extension to parametrium
- Extension to vagina
- Status of lymph nodes
- Depth of cervical stromal invasion

Thus, accurate preoperative staging can be determined.

Answer 7.3

Positron emission tomography scan has the ability to determine more accurately the extent of disease, particularly status of lymph nodes when they are not enlarged.

Distant site metastasis can be detected by PET scan when they are undetectable by conventional imaging.

Thus, if available and affordable, PET inclusion preoperatively will more accurately assign staging.

Question 8

A woman who was diagnosed as stage IB3 cervical carcinoma with histology of squamous cell carcinoma grade II, reported to hospital for management.

JAYPEE BROTHERS

8.1. Which treatment option is most preferred and why? (0.75 × 2 = 1.5)

8.2. What extra benefit is gained by such treatment? (1.5)

8.3. Which imaging is used for treatment planning? What are the other imaging methods which will provide accurate information on local tumor extent? (1 + 0.5 × 2 = 2)

Answer 8.1

Primary chemoradiation therapy is the preferred treatment option.

The reason behind it is as follows:

- When the tumor is bulky like stage 1B3, there is increased probability of lymph node metastasis and early recurrence. This consequence is prevented by giving radiotherapy following surgery. Thus, dual treatment increases morbidity like lymph edema, radiation proctitis, cystitis, colitis, and sexual dysfunction and is discouraged.

Answer 8.2

Since chemotherapy is added with radiotherapy, there is significant improvement in local control of the disease and overall survival (OS) when chemotherapy is added with radiation because chemotherapy acts as a sensitizer of radiation, thereby increasing its efficacy.

Answer 8.3

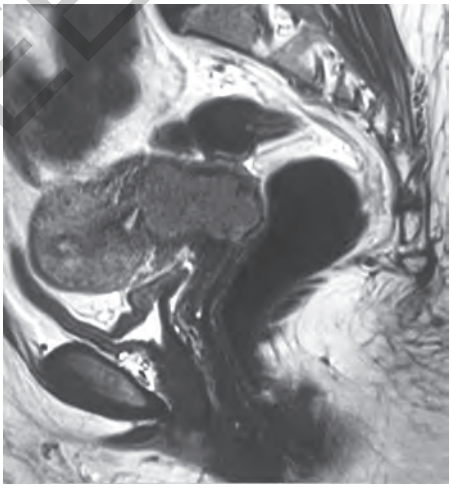

Fig. 5: Magnetic resonance imaging (MRI) showing bulky tumor.

- Magnetic resonance imaging in bulky tumors **(Fig. 5)** like stage IB3 is used in treatment planning.

JAYPEE BROTHERS

- The other imaging methods which provide accurate information on local tumor extent in CC are:
  - Transvaginal ultrasound (TVS)
  - Transrectal ultrasound (TRUS)

Question 9

A 56-year-old woman was diagnosed as cervical carcinoma. On clinical evaluation and MRI, she was staged as IIA2.

9.1. Enlist four high-risk factors which are likely to be present in such a stage. (0.5 × 4 = 2)

9.2. Which modality of treatment is preferred here? Give reasons for such preference. (1 + 1 = 2)

9.3. Why is CCRT more favorable than radiotherapy alone in the treatment of cancer cervix? (1)

Answer 9.1

Since the tumor is bulky in stage IIA2, the likelihood of high-risk factors are:

- Positive pelvic lymph nodes
- Positive parametrium
- Invasion of more than half of cervical stroma
- LVSI

The presence of such high-risk factors increases the risk of recurrence.

Answer 9.2

Concurrent chemoradiation is preferred here.

Reasons of preference:
It avoids the severe morbidity associated with dual modality of treatment, i.e., surgery followed by adjuvant radiotherapy.

Answer 9.3

Chemotherapy sensitizes the tissue to the effect of radiotherapy, thereby increasing the efficacy. As a result, patient getting CCRT shows improved OS, progression free survival (PFS), and decreased local and distant recurrences.

Question 10

A 37-year-old married woman with recent history of (H/O) kidney transplantation and on immunosuppressive medications reports with heavy menstrual bleeding. She also complains of bleeding in between menstruation

JAYPEE BROTHERS

for the last 4 months. She is worried about CC and wants to have a checkup.

10.1. Mention four important other symptoms you want to obtain from her which will suggest cancer cervix. (0.5 × 4 = 2)

10.2. Which examination and investigations suggest parametrial involvement in such cancer? (0.5 × 2 = 1)

10.3. Name four investigations recommended by International Federation of Gynaecology and Obstetrics (FIGO) to be included with clinical examination to assign the stage of disease. (0.5 × 4 = 2)

Answer 10.1

1. Vaginal discharge which may be foul smelling
2. Postcoital bleeding
3. Pain in lumbosacral or gluteal region
4. Pervaginal bleeding on straining

Answer 10.2

- Rectovaginal examination **(Fig. 6)**
- *Imaging studies:*
  - High-resolution ultrasonography (USG)
  - MRI/CT scan

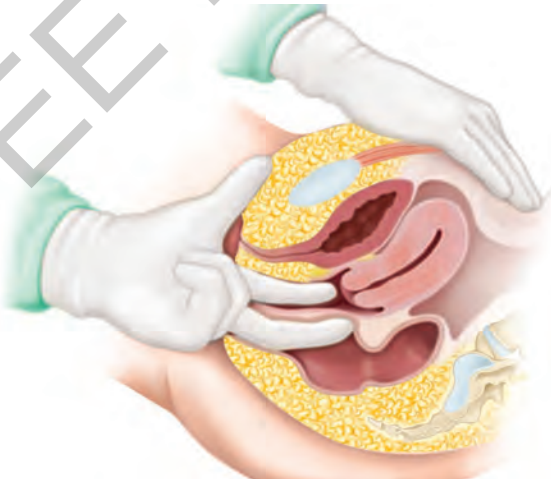

Fig. 6: Rectovaginal examination.

Answer 10.3

- Cervical biopsy
- Chest X-ray

JAYPEE BROTHERS

- *Imaging:* USG/intravenous urogram (IVU)/CT/MRI/PET
- If relevant symptoms are present, cystoscopy and proctoscopy.

Question 11

Lymph node status should be meticulously assessed preoperatively in patients with CC.

11.1. Why is reliable information on lymph node status necessary once diagnosis of cancer cervix is confirmed? (0.5 × 3 = 1.5)

11.2. Compare the different imaging tools in the assessment of metastatic lymph node. (2.5)

11.3. How PET-CT assesses lymph node status? (1)

Answer 11.1

Lymph node status is an independent predictor of prognosis, thus preoperatively reliable information about it must be known to:

- Accurately determine staging
- Plan treatment
- Predict the prognosis of disease

Answer 11.2

- Both MRI and CT have low sensitivity in detecting metastatic lymph node. The reasons are:
  - Nonbulky metastatic lymph node may remain unrecognized.
  - Bulky lymph nodes are detected but differentiations between metastatic and hyperplastic enlarged lymph node are not possible.
- PET-CT has better sensitivity in diagnosing metastatic bulky lymph node but may miss the diagnosis in small/microscopic metastasis.

Answer 11.3

F18-deoxyglucose is injected in PET-CT which is taken up by tumor cells in lymph nodes because of increased glucose metabolism.

This results in increased tracer uptake which is then detected by PET-CT.

Question 12

A woman underwent radical hysterectomy with pelvic lymphadenectomy for cancer cervix stage IB1. She was counseled about the procedure.

12.1. Outline the boundary within which pelvic lymphadenectomy should be performed to ensure its completeness. (2)

JAYPEE BROTHERS

12.2. If 1 cm of external iliac vein is injured during surgery, what will be the principle of repair? (2)

12.3. Which postoperative treatment should be ensured prophylactically to prevent deep vein thrombosis (DVT) following repair? (1)

Answer 12.1

The boundaries for pelvic lymphadenectomy **(Fig. 7)** are:

- *Cranially:* Bifurcation of common iliac artery
- *Caudally:* Deep circumflex iliac vein
- *Inferiorly:* Obturator nerve
- *Medially:* Obliterated umbilical artery
- *Laterally:* Genitofemoral nerve

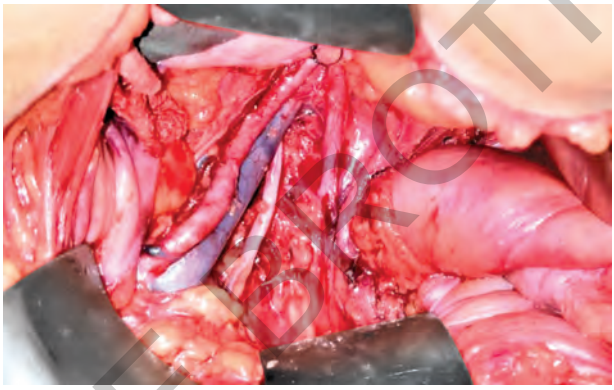

Fig. 7: Boundaries of pelvic lymph node dissection.

Answer 12.2

Principal of Repair

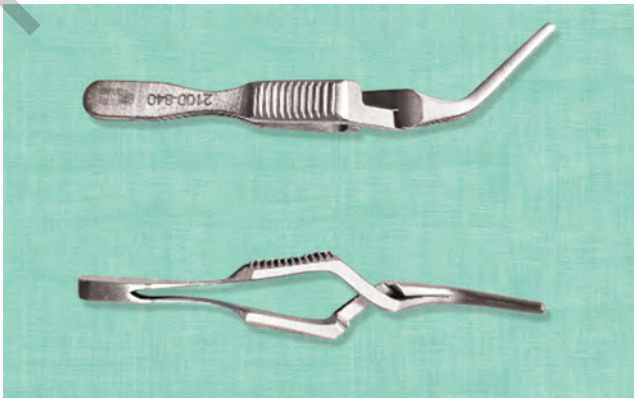

Fig. 8: Bulldog artery clamps.

JAYPEE BROTHERS

- Compression over vein by mop till instruments and ligature are arranged.
- Clamping the ends of injured rent by vascular clamp: Bulldog clamp **(Fig. 8)**
- Repair the rent by continuous suture using 4-0 prolene.

Answer 12.3

In order to prevent DVT, LMWH 60 unit should be given daily subcutaneously arround the umbilicus in the immediate postoperative period for 5 days.

Question 13

A patient with stage IB2 CC, underwent radical hysterectomy with pelvic lymphadenectomy. Postoperatively, the histopathology report revealed the following:

- *Histology subtype:* Squamous cell carcinoma
- *Histology grade:* Grade II
- *Primary tumor diameter:* 2 × 3.2 cm
- *LVSI:* (+)
- *Surgical margin:* (+)
- *Two (right) and one (left) pelvic lymph nodes:* Metastatic
- *Parametrium:* Free of tumor
- *Cervical thickness:* >⅔ involved

13.1. Enlist intermediate and high-risk factors, two for each from the above histopathology report. (0.5 × 4 = 2)

13.2. Which adjuvant treatment should the patient receive postoperatively? (1)

13.3. Is vaginal brachytherapy indicated in such a case? Give reasons. (1 + 0.5 × 2 = 2)

Answer 13.1

Intermediate risk factors:

- LVSI (+)
- Deep stromal invasion

High risk factors:

- Surgical margin (+) for malignancy
- Pelvic lymph nodes metastatic

Answer 13.2

Concurrent chemoradiation because there are two high-risk factors.

JAYPEE BROTHERS

Answer 13.3

Vaginal brachytherapy **(Fig. 9)** is indicated here.

This is because the patient has:

- Positive surgical margin
- Deep stromal invasion



Fig. 9: Tandem, ovoid, and catheter tube for brachytherapy.

Question 14

An elderly woman was diagnosed with stage IIB CC. She was offered CCRT which is considered as the standard treatment. The patient wanted to know the details of treatment.

14.1. What is meant by CCRT? (1 × 2 = 2)

14.2. Specify the targeted coverage area in external beam radiotherapy (EBRT) and intracavitary brachytherapy (ICRT). (1 × 2 = 2)

14.3. If it is not feasible to give ICRT because of distorted anatomy, what is the next option? (1)

Answer 14.1

Concurrent chemoradiation means to administer chemotherapy and radiotherapy simultaneously.

- Chemotherapy regimen is once weekly intravenous (IV) cisplatin along with EBRT for 5 weeks.
- Radiotherapy includes EBRT 25 fractions in 5 weeks and ICRT three to five applications. The overall treatment time (OTT) is 55–56 days. ICRT is given within this time and thus is started during the last 2 weeks of EBRT.

JAYPEE BROTHERS

Answer 14.2

External beam radiotherapy ***(Fig. 10A)****:* It covers the cervix (tumor bed) and draining pelvic lymph node area. A dose of 40–50 Gy is usually given over abdomen in 5 weeks.

Intracavitary brachytherapy ***(Fig. 10B)****:* It delivers high central dose to cervix (primary tumor) and reduced doses to the parametrium. A dose of 30–40 Gy is given in three to five fractions through vaginal route.



Fig. 10A: Linear accelerator machine for external beam radiotherapy (EBRT).



Fig. 10B: High dose rate (HDR) brachytherapy used for intracavitary brachytherapy.

JAYPEE BROTHERS

Answer 14.3

Interstitial brachytherapy should be considered where multiple needles are inserted into the primary tumor and parametrium in situations where ICRT application is not possible due to vaginal stenosis.

Question 15

A 67-year-old lady underwent radical hysterectomy with pelvic lymphadenectomy for stage IB1 CC. Postoperatively histopathological evaluation revealed.

- *Surgical margin:* Negative.
- *Pelvic lymph nodes:* Reactive
- *PTD*: (2 × 3.5) cm
- *LVSI*: Positive
- *Cervical stromal invasion:* >⅔

15.1. Which adjunct treatment is suitable in this situation? Give reasons for such selection. (1 + 1 = 2)

15.2. What are the components of postoperative radiotherapy (PORT)? What benefit will be achieved? (0.5 × 2 + 1 = 2)

15.3. If no further treatment after radical hysterectomy is given in the above patient, mention two common sites of recurrence. (1)

Answer 15.1

Postoperative radiotherapy is the only suitable adjunct treatment.

Reasons for selection are:

Patient is node negative but intermediate risk features are present in primary tumor like:

- *LVSI:* Positive
- *Cervical stromal invasion:* >⅔

Answer 15.2

- PORT includes EBRT as standard protocol. In some situations, brachytherapy is added with EBRT.

  In the above scenario, there is deep cervical stromal invasion. ICRT in the form of brachytherapy can be added with EBRT.
- There will be significant reduction in risk of recurrence causing improvement in disease-free survival and OS.

Answer 15.3

80–90% of recurrences are seen in the central pelvis which includes vaginal vault and paravaginal soft tissue.

JAYPEE BROTHERS

Question 16

A patient who is diagnosed as cancer cervix stage IIB is scheduled for CCRT. She is thoroughly counseled about the details of CCRT.

16.1. What are the preventable morbidities of conventional radiotherapy about which the patient should be counseled? (1.5)

16.2. Which new technique can reduce the morbidities and how? (1 + 1.5 = 2.5)

16.3. What is the ultimate goal of this new technique? (1)

Answer 16.1

There is late morbidity to the small bowel, rectum, urinary bladder, and vagina in the form of:

- Radiation proctitis
- Urgency of urine
- Sexual dysfunction

The patient should be informed about these complications before radiotherapy is started.

Answer 16.2

Intensity modulated radiotherapy (IMRT) **(Fig. 11)** use can reduce the above morbidities by undergoing 360° rotation and intensity modulation of radiation to organ at risk (OAR). In other words, IMRT distributes high radiation doses to the target organs evenly with better dose sparing of small bowel, rectum, and urinary bladder, thus reducing the toxicities.

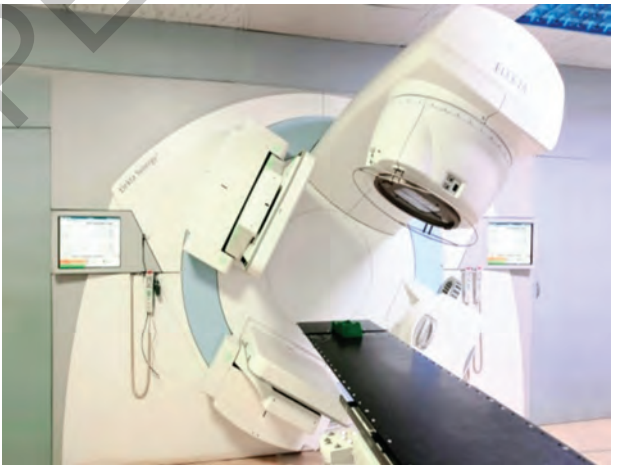

Fig. 11: Linear accelerator machine with intensity-modulated radiotherapy (IMRT) facility.

JAYPEE BROTHERS

Answer 16.3

The ultimate goal of IMRT is to provide high-radiation dose to primary tumor with minimum toxicity and achieve prolong PFS and OS.

Question 17

A 27-year-old lady desiring fertility reported with cancer cervix which was clinically staged as stage IA1. The histopathology of cervical biopsy revealed squamous cell carcinoma, grade II with no LVSI and depth of invasion is 1.5 mm. In MRI of the abdomen, there was no involvement of endocervix, parametrium, and neither metastasis of pelvic lymph nodes were evident.

17.1 Justify the feasibility of fertility sparing treatment (FST) in this patient. Outline the different FST options. (2 + 1 = 3)

17.2. Is laparoscopy feasible in such situation? Enumerate the stepwise approach in such option. (0.5 + 1.5 = 2)

Answer 17.1

Justification for FST:

- The stage is IA1, grade II.
- No involvement of endocervix, para-aortic, and pelvic lymph nodes.
- No LVSI.
- Cervical stromal invasion is only 1.5 cm.

Fertility sparing treatment options are:

- Radical trachelectomy with pelvic lymphadenectomy
- Cone biopsy with pelvic lymphadenectomy

Answer 17.2

Laparoscopy is feasible in such situation.

Stepwise approach includes:

- Laparoscopic pelvic lymphadenectomy is done first followed by
- Radical vaginal trachelectomy which is done by open method.

Question 18

A young woman desiring fertility, reported with a histopathology report of loop electrodiathermy excisional procedure (LEEP) specimen revealing squamous cell carcinoma which has invaded <3 mm depth of cervical stroma. She is worried and wants standard treatment.

JAYPEE BROTHERS

18.1. What is the stage of the disease? If LVSI is positive, what will be the treatment plan? (1 + 0.75 × 2 = 2.5)

18.2. Why pelvic lymphadenectomy is essential here? (1)

18.3. Enlist the components of specimen that should be included in cone biopsy. (0.5 × 3 = 1.5)

Answer 18.1

- The stage is IA1.
- Since the woman desires fertility, she may be offered any one of the following:
  - Cervical conization with pelvic lymphadenectomy
  - Radical trachelectomy with pelvic lymphadenectomy

Answer 18.2

Lymphovascular space invasion is an important prognostic indicator. When LVSI is positive, the likelihood of lymph node metastasis increases. As such, pelvic lymphadenectomy should be done.

Answer 18.3

Cone biopsy **(Fig. 12)** should include:

- Portion of ectocervix
- External os with entire transformation zone
- Endocervical canal with varying amount of deep tissues

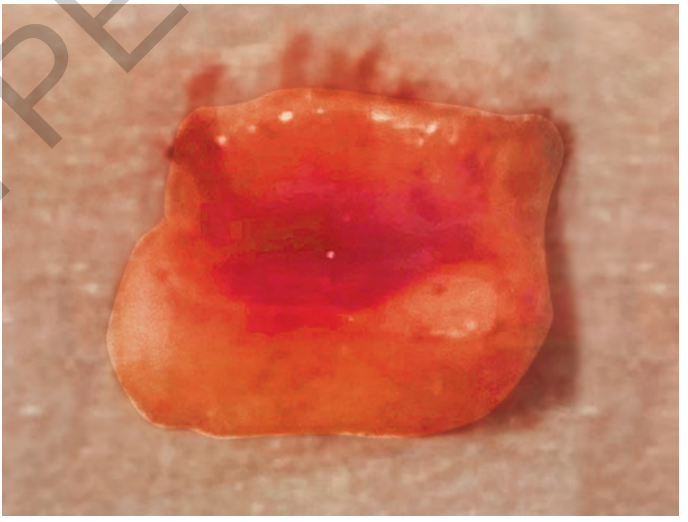

Fig. 12: Cone biopsy specimen of cervix.

JAYPEE BROTHERS

Question 19

A 28-year-old lady was diagnosed with squamous cell carcinoma of cervix, stage IA1 by colposcopy-guided biopsy. She opted for fertility preservation surgery and came to cancer center for treatment.

19.1. What will be the next step for evaluation? Justify. (0.5 × 3 = 1.5)

19.2. What are the treatment options for the patient? (1 × 3 = 3)

19.3. Enumerate the follow up procedure if the patient is kept under observation. (0.5)

Answer 19.1

- Next step for evaluation is cold knife conization (CKC).
- The rationality of doing CKC is to:
  - Confirm the stage from depth of invasion
  - Determine histologic subtype, grade, margin status, and LVSI.

Answer 19.2

Fertility preservation treatment options for this patient includes:

- Only observation when surgical margins are negative and there in no LVSI. CKC will serve the therapeutic purpose then.
- Radical trachelectomy and pelvic lymphadenectomy if surgical margins are negative but LVSI is positive.
- If surgical margins are positive but LVSI is absent, repeat conization or radical trachelectomy.

Answer 19.3

Follow-up procedure in observation includes:

- Cytology
- Colposcopy
- ECC

Question 20

A 40-year-old lady was diagnosed as squamous cell carcinoma of cervix at 28 weeks of gestation. The stage at diagnosis was stage IB1. She consulted with her obstetrician and expressed her desire for continuation of pregnancy.

20.1. What will be its impact on prognosis if treatment is delayed? When should she deliver? (1 + 0.5 = 1.5)

20.2. Justify which mode of delivery is preferred. (0.5 + 1 = 1.5)

20.3. When definitive treatment will be planned? What complications will be encountered? (1 + 1 = 2)

JAYPEE BROTHERS

Answer 20.1

There is no negative impact on prognosis compared with nonpregnant controls as found in evidence.

Pregnancy is continued up to 34 weeks of gestation until fetal lung maturity is achieved and then terminated.

Answer 20.2

The preferred mode of delivery is cesarean section because vaginal delivery is considered as the most significant predictor of recurrence as evident in literature.

Answer 20.3

Definite treatment is done at the same time when cesarean section is performed.

The complications that will be encountered are:

- Excessive blood loss during surgery
- Postoperative fever

Question 21

A 36-year-old lady was diagnosed as stage IIB squamous cell carcinoma at 16 weeks of gestation. The patient visited the hospital to get information about the impact of pregnancy on disease and treatment.

21.1. What specific information should be delivered to the patient during counseling? (1.5)

21.2. Enumerate the plan of treatment. (1.5)

21.3. Explain the role of neoadjuvant chemotherapy here. (1 + 1 = 2)

Answer 21.1

In this situation, definitive treatment for CC should be done without delay to avoid risk of progression because there will be a long waiting period of minimum 18 weeks (16 + 18 = 34 weeks) for the fetus to attain lung maturity and during this time, the disease will progress rapidly and thus treatment should be started immediately.

This information must be delivered to the patient during counseling.

Answer 21.2

The standard of treatment for stage IIB is to give chemoradiation with the fetus in situ.

JAYPEE BROTHERS

During the first few fractions of radiation, there will be spontaneous abortion of conceptus following which the remaining fractions can be given smoothly.

Answer 21.3

- Neoadjuvant chemotherapy (NACT) is planned to prevent disease progression in woman with locally advanced CC if she desires pregnancy continuation.
- The standard regimen is platinum-based chemotherapy which is given from 14 weeks gestational age onward and is safe both for the mother and the fetus, but the impact of treatment delay on survival is not well studied.

Question 22

A 47-year-old multiparous lady was diagnosed as stage IB3 CC. She was admitted in a tertiary care center for treatment.

22.1. Which one is the preferred treatment option among the following? Give reason for such preference. (1 + 2 = 3)
- Primary chemoradiation
- NACT followed by radical hysterectomy
- Radical hysterectomy followed by adjuvant radiation
- Chemoradiation followed by extrafascial hysterectomy

22.2. Can IMRT replace traditional radiation in such situation if lymph nodes are unresectable? (2)

Answer 22.1

The preferred treatment option is primary chemoradiation.

The standard protocol is cisplatin once weekly along with EBRT: 45–50 Gy for rest of the 5 days in a week for 5 weeks.

ICRT is given in three to five applications: 30–35 Gy anytime from last 2 weeks of EBRT at an interval of 7–10 days.

Reasons of preference:

- Carcinoma cervix IB3 means bulky tumor which is associated with high incidence of central recurrence, pelvic, and para-aortic lymph node metastasis and distant metastasis.
- Primary chemoradiation will effectively control such predicted outcome and simultaneously will avoid adverse morbidity associated with dual modality of treatment that is surgery followed by radiotherapy.
- The ultimate outcome will be improved PFS and OS.

JAYPEE BROTHERS

Answer 22.2

Conventional radiation is associated with increased toxicity. In such situation, IMRT is able to safely deliver high doses of radiation to tumor site and lymph node area while limiting the dose of radiation to highly proliferating normal tissue such as bowel, bladder, and vagina.

There is higher rate of tumor response and at the same time, lower gastrointestinal tract (GIT) and vaginal toxicities.

Thus, there is improvement in PFD and OS.

Question 23

A woman who underwent radical hysterectomy for carcinoma cervix IB1 is found to have no urine in the urine bag 6 hours after the surgery.

23.1. Enumerate four measures that should be taken immediately. $(0.5 \times 4 = 2)$

23.2. Which imaging can detect ureteric injury accurately? (1)

23.3. If the left ureter is injured at its distal third producing a rent of 0.5 cm, what will be the management? (2)

Answer 23.1

- Enquire whether the urine bag was emptied without keeping record.
- Assess vital parameters, level of dehydration, and urine color.
- Assess whether the urinary bladder is distended or not.
- Flush the catheter with distilled water to remove blood clot.
- Hydrate the patient with 200–300 mL IV fluid in 1 hour and observe the urine output.

Answer 23.2

A CT urogram (CT of the abdomen and the pelvis with IV contrast and delayed image) can accurately identify ureteral injury.

Answer 23.3

- Since the rent in the ureter is small, ureteral double J stent insertion and keeping it in situ for 21 days is the first line treatment.
- If spontaneous healing fails to occur, repair the ureteric rent by open method keeping the stent in situ.

Question 24

A 48-year-old obese woman is scheduled for radical hysterectomy for CC stage IB1. The woman's family is concerned about surgical site

JAYPEE BROTHERS

infection (SSI) and have requested to take all protective measures to minimize the risk.

24.1. Define surgical site infection. Enlist the causative agents responsible for SSI. (1 + 1 = 2)

24.2. Enlist six best practices you will adopt to reduce SSI. (0.5 × 6 = 3)

Answer 24.1

Definition: Surgical site infection is defined as infection occurring up to 30 days after surgery and affecting either the incision or deep tissue at the operation site.

Causative agents: The responsible pathogens originate from patients endogenous flora.

Commonly seen pathogens are:

- *Staphylococcus*
- Coagulase-negative *Staphylococcus*
- *Enterococcus* spp.
- *Escherichia coli*

Answer 24.2

Six best practices to reduce SSI

1. IV antibiotics should be administered 60 minutes before skin incision.
2. The antibiotic should have a longer half-life and broad spectrum coverage such as cefazolin and cefoxitin.
3. The dose should be repeated if the operation time is prolonged beyond 3 hours or when blood loss is >1,000 mL.
4. The dose should be doubled for woman >70 kg weight.
5. Hair clipping is preferred for hair removal before surgery if it is mandatory.
6. Chlorhexidine-alcohol is preferred over povidone-iodine.

Question 25

An obese elderly woman who is a known case of hypertension and diabetes mellitus underwent radical hysterectomy. On the 4th postoperative day, the patient complained of throbbing pain at the wound area with mild fever. On inspection, there was redness, swelling, and discharge from one end of the wound.

25.1. What immediate action should be undertaken? (0.5 × 3 = 1.5)

25.2. Identify three factors which contributed in the impairment of wound healing. (0.5 × 3 = 1.5)

25.3. When will wound closure be done if wound disruption has occurred? How wound healing will now take place? (1 + 1 = 2)

JAYPEE BROTHERS

Answer 25.1

- Two or three stitches at the red, swollen area of the wound should be cut and pus is drained out.
- The pus is sent for culture sensitivity.
- Antibiotic should be changed according to the culture sensitivity report.

Answer 25.2

Three factors which contributed in the impairment of wound healing:

1. Old age
2. Obesity
3. Diabetes mellitus

Answer 25.3

- Secondary closure will be done when:
  - Infection subsides
  - Wound is filled up from the base
- Wound healing will take place by formation of granulation tissue from the base.

Question 26

A 43-year-old lady underwent primary radical hysterectomy for early-stage CC. 8 months after surgery, the patient reported sexual dysfunction.

26.1. What is the prevalence of sexual dysfunction following radical hysterectomy? Why it happens? $(1 + 0.5 \times 2 = 2)$

26.2. What prophylactic measures can overcome the sexual dysfunction problem? $(1 + 1 = 2)$

26.3. Which modality of treatment causes more sexual dysfunction and why? $(0.5 \times 2 = 1)$

Answer 26.1

- Among CC survivors, sexual dysfunction is reported in 55% patients treated by radical hysterectomy.
- Sexual dysfunction following surgery is due to any of the following: They may remain alone or in combination:
  - Insufficient lubrication or dry vagina
  - Reduced vaginal length and elasticity

Answer 26.2

- In premenopausal women, resection of vagina in radical hysterectomy should be limited within 1.5 cm.
- Nerve sparing radical hysterectomy should be practiced frequently.

JAYPEE BROTHERS

Answer 26.3

Sexual dysfunction is more pronounced following primary radiotherapy than primary surgery because of:

- Vaginal atrophy
- Fibrosis
- Stenosis

Question 27

A 67-year-old lady with CC underwent radical hysterectomy 8 hours back. Her left calf was found to be swollen with tenderness and pitting edema.

27.1. Enlist the clinical features in the scenario that goes in favor of DVT. $(0.5 \times 5 = 2.5)$

27.2. Which two investigatory tools are needed to confirm the diagnosis? $(0.5 \times 2 = 1)$

27.3. What specific treatment should be offered to the patient? (1.5)

Answer 27.1

TABLE 2: Clinical features suggesting deep vein thrombosis (DVT) with scoring.

Clinical features	***Score***
Malignancy—cervical cancer	1
Radical hysterectomy (major surgery)	1
<12 hours back	1
Calf swollen	1
Local tenderness	1
Pitting edema	1
Total Score	**6**

The score between 3 and 8 indicates the high probability of DVT.

Answer 27.2

Two investigatory tools to confirm diagnosis are:

1. Compression USG showing blood clot in ileo-saphenous-popliteal vein
2. Age-adjusted D-dimer positive in blood

JAYPEE BROTHERS

Answer 27.3

Low molecular weight heparin (LMWH) **(Fig. 13)** subcutaneously is given for 5 days followed by oral anticoagulant or warfarin for minimum 3 months.



Fig. 13: Low molecular weight heparin.

Question 28

Conventional radiation therapy is usually given in a fractionated course with daily doses of 180–200 CGy per fraction in cancer cervix.

28.1. Why is fractionated irradiation important? (1)

28.2. When are the cells most sensitive and resistant to radiation in fractionated course? (1 + 1 = 2)

28.3. How hyperfractionated strategy is helpful in advanced stage CC? (2)

Answer 28.1

Fractionated irradiation permits recovery or maximum repair of sublethal injury of normal tissue and tumor.

Answer 28.2

- Cells are most sensitive to radiation in late G2 phase and during mitosis of cell cycle.
- Cells are most resistant to radiation in mid to late S phase and early G1 phase of cell cycle.

Answer 28.3

In advanced stage CC, primary radiation therapy in the form of EBRT with brachytherapy is the gold standard. Hyperfractionated strategy here decreases the expected late morbidity to the bowel, bladder, and vaginal vault.

JAYPEE BROTHERS

For detailed information on obstetrics & gynecology books, visit our website www.jaypeebrothers.com, for detailed information on obstetrics & gynecology books, visit our web

SAQ in Gynecologic Cancers
(Part I) with Model Answers

The book offers a complete coverage of cognitive knowledge and practical issues of common gynecological cancers. Recent, evidence-based diagnostic and therapeutic approaches are present with explanations in the book to help the readers to select the most ethical, social, and medicolegal approaches for dealing patients with problems. The information are well laid out in contemporary format using high-quality colored illustrations, flowcharts, tables and photographs from recent operations, resected specimens and histopathology for effective visual impact in readers' brain which will retain the fact with clarity and lucidity. The information are in accordance with guidelines of NCCN, FIGO, ACS, ASCCP, WHO and is suitable for students in many countries around the world. The book will be a good guide for postgraduate students, trainee residents and practicing gynecologists. It will fill the long-staining need of students for a comprehensive compilation of standard knowledge and accurate stepwise approach for managing patients with common gynecological oncology problems. Since the questions describe clinical scenarios with answers giving appropriate management, it will be a helpful guide for students in preparation for written, OSCE and practical clinical examination. Moreover, it can be useful for self-assessment as it contains large number of questions and also as revision guide before examination as it summarizes the syllabus in a compact manner.



Professor Farhat Hussain MBBS FCPS (Obs & Gyne) is a Professor and former Head, Department of Obstetrics and Gynecology in Sir Salimullah Medical College, Mitford Hospital, Dhaka, Bangladesh. She has been teaching medical students for the final MBBS examination and trainee postgraduate students for Fellowship of College of Physicians and Surgeons (FCPS) in Obstetrics and Gynecology and Gynecological Oncology for long time. She has a profound passion in the field of gynecologic oncology and this book is a reflection of her vast clinical experience, surgical expertise and dedication towards improving cancer care for women. She is an active clinician and academician who is always devoted in helping students to enlighten their higher cognitive thinking.

Printed in India

Available at all medical bookstores
or buy online at www.jaypeebrothers.com

JAYPEE BROTHERS
Medical Publishers (P) Ltd.
EMCA House, 23/23-B, Ansari Road,
Daryaganj, New Delhi - 110 002, INDIA
www.jaypeebrothers.com

Join us on facebook.com/JaypeeMedicalPublishers

Shelving Recommendation
OBSTETRICS & GYNECOLOGY

ISBN 978-93-5465-645-3