detailed information on obstetrics & gynecology books, visit our website www.jaypeebrothers.com, for detailed information on obstetrics & gynecology books

An Official Publication of
Federation of Obstetric and Gynaecological Societies of India

Look Inside the Book

FOGSI's POSTGRADUATE GYNAECOLOGY

Volume 2 A TEXTBOOK



Alpesh Gandhi
Parikshit Tank
Ameya Purandare

diginerve
A Jaypee Initiative
Your Guide at Every Step
Video Lectures | Notes | Self-Assessment
Scan to Know More

JAYPEE

Contents

Volume 1

PART 1: Obstetrics and Perinatology

Section 1: Introduction to Obstetrics

1.1. **A Brief History of Women's Health** 3
Parikshit Tank

1.2. **Communication and Counseling** 10
Tripti Nagaria

1.3. **Evidence-Based Medicine and Medical Informatics** 22
Anahita Chauhan, Madhva Prasad S

1.4. **Good Clinical Practice and Research Methodology for Obstetricians** 31
Ramalingappa C Antaratani, Sanjana K

1.5. **Pelvic Anatomy for the Obstetrician and Gynaecologist** 37
Bhavik Doshi, Ashvin Vachhani

1.6. **Violence against Healthcare Professionals** 46
MC Patel, Dilip Walke

Section 2: Normal Pregnancy

2.1. **Fertilization, Implantation, and Placental Development** 53
Milind R Shah, Rajesh V Darade

2.2. **Fetal Physiology: Growth and Development** 61
Halvi Ediger Ramaraju, Surya Malik

2.3. **Clinically Relevant Embryology for Obstetricians** ... 65
Madhuri Arvind Patel, Hemraj R Narkhede, Navin Srinivasan

2.4. **Maternal Adaptations in Normal Pregnancy** 80
Sadhana Gupta, Hema J Shobhane

2.5. **Preconception and Routine Antenatal Care** 88
Vanita Suri, Bharti Sharma

2.6. **Minor Ailments in Pregnancy and Care** 98
Aswath Kumar

2.7. **Normal Laboratory Values in Pregnancy** 104
Sumitra Yadav, Shraddha Paliwal

Section 3: Fetal Evaluation

3.1. **Genetics and Genomics for the Obstetrician** 113
Pragya Mishra Choudhary, Manisha Madhai Beck

3.2. **Fetal Abnormalities: Definitions, Etiology, and Pathophysiology** 122
Mandakini Pradhan

3.3. **Ultrasound in First Trimester: Milestones and Pathology** 126
PK Shah, Pooja Lodha

3.4. **Biochemical Test for Fetal Screening** 133
Vinita Das, Smriti Agrawal

3.5. **Second-trimester Anatomy Scan** 138
Narendra Malhotra, Neharika Malhotra, Jaideep Malhotra, Rahul Gupta, Nitin Agrawal

3.6. **Invasive Tests for Fetal Diagnosis** 149
Purnima Satoskar, Shilpa Agrawal

3.7. **Antepartum Fetal Surveillance Tests in Third Trimester** 157
Shailesh Kore, Mansi Medhekar

3.8. **Color Doppler in Obstetrics** 165
Chinmayee Ratha

3.9. **Fetal Echocardiography** 174
Jayprakash Shah, Parth Shah

3.10. **Noninvasive Prenatal Test** 186
Hemant Deshpande, Monika Maan Sharma

Section 4: Early Pregnancy Complications

4.1. **Abortion** 193
Ranjana Desai

4.2. **Ectopic Pregnancy** 202
K Aparna Sharma, Archana Kumari

4.3. **Gestational Trophoblastic Disease** 210
VP Radhadevi, PK Sekharan

4.4. **Pregnancy after Previous Fetal Loss** 227
Sudha Gandhi, Savitri Verma

Section 5: Pregnancy with Pre-existing Morbidities

5.1. **Chronic Hypertension in Pregnancy** 233
Ragini Verma, Vijeta Jagtap

5.2. **Heart Disease in Pregnancy** 243
Vanita Raut, Shruti Panchbudhe, Anahita Chauhan

5.3. **Diabetes Mellitus** 258
Sujata Misra

5.4. **Thyroid Disorders in Pregnancy** 266
Kanan Yelikar, Sonali Deshpande, Ashwini Kale

5.5. **Anemia** 273
Hema Divakar, Arulmozhi Ramarajan

JAYPEE BROTHERS

5.6. Other Anemias in Pregnancy....279
Jyothika Desai, Megha Chauhan

5.7. Renal Disease and Pregnancy....291
Pralhad Kushtagi

5.8. Liver and Gastrointestinal Disease: Abnormal Pregnancy with Pre-existing Conditions....301
Sujata A Dalvi

5.9. Autoimmune Disorders of Pregnancy....308
Vinita Salvi, Ami Surti

5.10. Respiratory Conditions, the Lung and Pregnancy....318
Ravindra Rupwate, Sonal Kumta

5.11. Neurological Conditions....327
Jyoti Bindal

5.12. Dermatological Disorders in Pregnancy....335
Bharathi KR, Pooja Bhat

5.13. Mental Health Issues and Substance Use in Pregnancy and Puerperium....340
Parul P Tank

5.14. Obesity....347
Ashis Kumar Mukhopadhyay, Maya Mukhopadhyay

5.15. Cancer in Pregnancy....356
Amita Maheshwari, Vikash K Chatrani, Sudeep Gupta

5.16. HIV/AIDS and Other Sexually Transmitted Infections....367
Archana Kumari, Monika Anant

5.17. Infections in Pregnancy....378
Prakash K Mehta, Aparna Setia

5.18. Covid–19 in Pregnancy....393
Ajith S, Kasturi Donimath, Sabnam Nambiar

Section 6: Maternal Complications Arising in Pregnancy

6.1. Hypertensive Disorders in Pregnancy (Gestosis)....398
Sanjay Gupte, Arati Shah

6.2. Liver Diseases in Pregnancy: (HELLP, IHCP, AFLP, HELLP and Infective Hepatitis)....408
Suyajna Joshi D, Manjula Patil

6.3. Gestational Diabetes....420
Girija Wagh

6.4. The Surgical Abdomen in Pregnancy....428
Shashank Parulekar

6.5. Trauma in Pregnancy....434
Alok Sharma, Aanya Sharma

6.6. Poisoning in Pregnancy....442
Sujata Sharma, Amarjeet Kaur

Section 7: Fetal Complications

7.1. Fetal Infections....450
Geetha Balsarkar

7.2. Multiple Pregnancy....457
Sanjay Singh, Parag Biniwale

7.3. Abnormalities of Amniotic Fluid Volume....470
Sasikala Kola, Vidya M Ranga Rao

7.4. Abnormalities of the Placenta and Cord....478
Tamkin Khan, Ayesha Ahmad

7.5. Fetal Growth Restriction....485
Pratik Tambe, Sarita Bhalerao, Usha Krishna

7.6. Fetal Hydrops....495
Muralidhar V Pai, Krishnendu Gupta

Section 8: Late Pregnancy Complications

8.1. Antenatal Care: Malpresentations....499
N Palaniappan

8.2. Preterm Labor....503
MB Bellad, Bhawna Garg

8.3. Preterm Premature Rupture of Membranes....512
Shyam V Desai, Gaurav S Desai

8.4. Antepartum Hemorrhage....518
Madhuri Chandra

8.5. Placenta Accreta Spectrum Disorders....528
Shrinivas N Gadappa, Ankita Rajesh Shah

8.6. Post-term Pregnancy....535
Mala Srivastava, Ankita Srivastava

8.7. Intrauterine Fetal Demise....539
Vandana Bansal, Kaizad R Damania

Section 9: Labor

9.1. Mechanism of Labor....550
Shirish N Daftary, Gaurav S Desai

9.2. Labor in Malposition and Malpresentations....555
Sareena Gilvaz

9.3. Routine Intrapartum Care and Intrapartum Tests..567
Ganpat Sawant, Sachin Ajmera

9.4. Induction of Labor....577
Uday Thanawala, Manasi Venkatraman, Saloni Suchak, Nanak Bhagat

9.5. Labor in Special Situations (Previous Cesarean Birth, Poor Progress in Labor, Fetal Compromise in Labor, Meconium Stained Amniotic Fluid)....585
BS Jodha, Sudhakshi Kinger

9.6. Instrumental Vaginal Delivery....595
Haresh Doshi

9.7. Shoulder Dystocia....604
Abha Rani Sinha, Bhawana Tiwary

9.8. Cesarean Section....609
Suchitra N Pandit, Rakhee R Sahu

9.9. Rupture Uterus....616
Vidya Thobbi, Priyanka S Deshpande

9.10. Obstetric Analgesia and Anesthesia....621
Siddesh Iyer, Shanthakumari S, M Krishna Kumari

JAYPEE BROTHERS

Section 10: Postpartum Issues: Maternal and Neonatal

10.1. Normal Puerperium....628
Indrani Roy

10.2. Episiotomy and Perineal Trauma....635
Picklu Chaudhuri, Arindam Halder, Hiralal Konar

10.3. Postpartum Hemorrhage and its Management....641
Parul J Kotdawala, Sapana Shah, Sunil Shah

10.4. Obstetric Hysterectomy....652
Ajit C Rawal, Janki Pandya

10.5. Postpartum Pyrexia....663
Indranil Dutta, Dilip Kumar Dutta

10.6. Problems with Breastfeeding....670
Sarita Agrawal, Rajeshwari G

10.7. Neonatal Adaption to Extrauterine Life....682
Ruchi Nimish Nanavati, Suman Rao PN

10.8. Neonatal Resuscitation....688
Sonali Tank

10.9. Perinatal Asphyxia....696
Ashish Mehta

10.10. Birth Injuries....704
Upendra Kinjawadekar, Anjali Otiv

10.11. Common Neonatal Problems....710
Bakul Jayant Parekh

Section 11: Social Obstetrics

11.1. Perinatal Mortality, Surveillance and Response....720
Manju Puri, Kanika Chopra

11.2. Safe Motherhood Initiative....725
Alka Pandey

11.3. Maternal Death: Surveillance and Response....733
Jayam Kannan

11.4. Role of Midwifery in Obstetrics....736
Evita Fernandez

Section 12: Critical Care in Obstetrics

12.1. Role of HDU/ICU in Obstetrics....743
Pratima Mittal, Rekha Bharti

12.2. Monitoring in Obstetric HDU and ICU....749
Nuzhat Aziz, Siri Yerubandi, Ananth K

12.3. Fluid and Blood Therapy in Obstetric Shock....762
Jyotsna Suri, Divya Pandey

12.4. Sudden Obstetric Collapse....770
Alpesh Gandhi, Amita Gandhi

Index....783

Volume 2

PART 1: Contraception and Termination of Pregnancy

Section 1: General

1.1. Population Dynamics: The Indian Perspective....3
Anita Soni, Seeru Garg, Ruchi Shah

1.2. Government Policies and Population Stabilization....7
Mandakini Megh, Bhumika Kotecha Mundhe

1.3. Legal Aspects in Medical Termination of Pregnancy and Contraception....12
Nikhil Datar, Meghana Shedge

Section 2: Contraception: Spacing Methods

2.1. Natural and Behavioral Methods of Contraception....16
Vijyalakshmi Pillai

2.2. Male Barrier Methods....22
Rujuta Fuke

2.3. Female Barrier Methods....27
Shobha Gudi

2.4. Vaginal Spermicides....31
Gorakh Mandrupkar

2.5. Combined Oral Contraceptive Pills....33
Poonam Varma Shivkumar, Darshana Legha

2.6. Progesterone-only Pills....38
Nalini Anand

2.7. Injectable Contraceptives....41
Mukta Jain

2.8. Newer Routes for Contraceptions: Implants, Rings and Patches....47
Ashwini Bhalerao-Gandhi, Sanket Pisat, Minal Dhanvij

2.9. Intrauterine Contraception (Including PPIUCD): Copper Devices....54
Pushpa Junghare, Sayali Jahagirdar

2.10. Levonorgestrel Intrauterine System....60
Priya Ballal K, Nikhil Shetty

2.11. Emergency Contraception....68
Lila Vyas, Preeti Sharma

JAYPEE BROTHERS

Section 3: Termination of Pregnancy

3.1. Termination of Pregnancy: Counseling and Evaluation 75
Chandravati, Priti Kumar, Bhawna Khera

3.2. Choices and Methods of Procedures in Pregnancy Termination in First and Second Trimesters 81
Suma Natarajan, Gayathri V, Jayashree Natarajan

3.3. Difficult Situations in Pregnancy Termination 90
Jaydeep Tank, Kunal Doshi

3.4. Complications of Termination of Pregnancy 96
Bharti Maheshwari

3.5. Counseling after Pregnancy Termination 104
Basab Mukherjee

3.6. Access to Safe Pregnancy Termination 107
Atul Ganatra, Freni Shah

Section 4: Permanent Contraception

4.1. Male Sterlization including Nonscalpel Vasectomy: Methods and Strategies to Improve Acceptance 112
Phiroze Soonawala

4.2. Female Sterilization: Standards, Surgical Approaches, and Techniques 116
Madhuri Mehendale, Shraddha Mevada

4.3. Sterilization Failure 121
Kiran Pandey, Pavika Lal

4.4. Reversal of Sterilization 126
Abha Singh, Prabha Lal

Section 5: Contraception and Pregnancy Termination for Special Groups

5.1. Contraception in Adolescents 136
Sucheta Kinjawadekar, Unmesh Santpur

5.2. Perimenopausal Women 143
Nisha Rani, Shikha Sachan

5.3. Contraception and Pregnancy Termination for Women with Medical Disorders 150
Ashok Kumar, Sai Charisma

5.4. Contraception and Pregnancy Termination in the Postabortal Period 157
Trupti Nadkarni

5.5. Contraception in Postdelivery and Lactation 161
Kavita Singh, Deepti Gupta

PART 2: Gynaecology

Section 6: Reproductive Physiology and Basic Sciences

6.1. Embryonic Development and Sexual Differentiation 171
Madhu Nagpal, Manjitkaur Mohi

6.2. Neuroendocrinology and Reproductive Cycle 193
Kamini A Rao, Vyshnavi A Rao

6.3. Normal Menstrual Cycle: Physiology and Care 213
Ameya Purandare, Ritu Hinduja

6.4. Normal Puberty and Adolescence: Physiology and Care 221
Maya Padhi, Lucy Das

Section 7: Basic Aspects of Gynaecological Care

7.1. Eliciting History and Examining Gynaecological Patients 229
S Sampathkumari

7.2. Cytology: Cervicovaginal Smear and Endometrial Biopsy 236
Anita Singh, Richa Jha

7.3. Ultrasound in Gynaecology: Uterine Disease 251
Sonal Panchal, Chaitanya Nagori

7.4. Ultrasound in Gynaecology: Adnexal Disease 267
Archana Baser, Anshu Baser

7.5. CT and MRI in Gynaecology 276
Jyoti Jaiswal, Anand Kumar Jaiswal

7.6. Hormone Assays: Indications, Techniques, and Interpretation 295
Anuradha Ridhorkar

7.7. Preoperative Care and Preparation 304
Gokul Das, Shehla Jamal

7.8. Postoperative Care in Obstetrics and Gynaecology 311
Kavita V Kapadia, Vaibhav V Kapadia

Section 8: Puberty and Adolescence

8.1. Amenorrhea: Evaluation and Management 320
Rajrani Sharma, Ameya Purandare, Parikshit Tank

8.2. PCOS in Adolescence 329
Ameet Patki, Mrinmayi Dharmadhikari

8.3. Developmental Abnormalities of Genital Tract 337
Ragini Agrawal, KV Divya

8.4. Disorder of Sex Development in an Adolescent Girl 342
Kunal Thakkar, Vijaya Sarthi, Nalini Shah

8.5. Body Issue Images in Adolescents 351
Reeti Dutta Mehra

8.6. Eating Disorders in Adolescence 357
Nirmala Sharma, Anand Sharma, Neha Seehara

8.7. Precocious Puberty 364
Surveen Ghumman, Rajal Thaker

Section 9: General Gynaecology

9.1. Premenstrual Syndrome 371
Abha Singh

JAYPEE BROTHERS

9.2. Dysmenorrhea....377
PB Hiremath

9.3. Chronic Pelvic Pain....380
Anupam Gupta, Shikha Singh

9.4. Heavy Menstrual Bleeding: Approach to Evaluation and Treatment....387
Amala Khopkar Nazareth, Gillian Ryan, Alka Kriplani, CN Purandare

9.5. Heavy Menstrual Bleeding: Uterine Conservative Surgery....404
Anuradha Khanna, Shikha Sachan

9.6. Fibroid Uterus....413
PC Mahapatra, Nitin Raithatha

9.7. Adenomyosis....427
N Sanjeeva Reddy, Radha Vembu

9.8. Endometriosis....437
Kanthi Bansal, Anu Agarwal, Shweta Shah

9.9. Hysterectomy: Choice of Surgical Approach....450
Shirish S Sheth, Kurush P Paghdiwalla

9.10. Technical Aspects of Abdominal and Vaginal Hysterectomy....457
VP Paily, Raji Raj

9.11. Technical Aspects of Laparoscopic Hysterectomy....465
PG Paul, George Paul, Sanghamitra Thakur

Section 10: Benign Gynaecological Conditions

10.1. Vaginal Discharge....473
Sheela Mane

10.2. Sexually Transmitted Infections and HIV in Women....489
Atul Munshi, Munjal Pandya

10.3. Pelvic Inflammatory Disease....497
Kusum Lata Singhal, Uma Jain

10.4. Female Genital Tuberculosis....510
Jai Bhagwan Sharma, Eshani Sharma, Sona Dharmendra

10.5. Benign Diseases of Ovary and Fallopian Tube....516
Shobhana Mohandas, Haritha C

10.6. Benign Lesions of Vulva and Vagina....525
Rajashree Dayanand Katke, Deepti Prasad

10.7. Genital Tract Trauma and Sexual Assault....529
Saroj Singh, Neha Agarwal

10.8. Dyspareunia and Vaginismus....537
Shantanu Abhyankar

10.9. Premature Ovarian Insufficiency....545
Duru Shah, Vishesha Yadav

10.10. Menopause: Physiology and Adaptations....554
Sheela HS, Ashwini Neelakanthi

10.11. Implications of Menopause on Cardiovascular and Bone Health....561
Revathy Janakiram, Krithika Meenakshi

10.12. Hormone Therapy in Menopause....568
Suvarna Khadilkar, Madhva Prasad S

10.13. Non-hormonal Therapy at Menopause....576
Meeta, Akanshi Madan, Tanvir

Section 11: Endoscopy

11.1. Laparoscopy: Safe Entry Technique and Instrumentation....584
Rajendra Sankpal, Damodar Rao

11.2. Hysteroscopy: Instrumentation and Distension Media....592
Subash Mallya

11.3. Robotic Surgery in Gynaecology....596
Seema Singhal, Alka Kriplani

11.4. Complications of Gynaecological Laparoscopy....603
Sunita Tandulwadkar, Abhishek Chandavarkar, Rohan Krishnakumar

11.5. Surgical Training in Gynaecological Endoscopic Surgery....613
Pragnesh Shah, Foram Vora

11.6. Energy Sources in Endoscopic Surgery....623
Prakash Trivedi, Soumil Trivedi

Section 12: Reproductive Endocrinology and Infertility

12.1. Infertility: Etiology and Clinical Evaluation....631
Charmila Ayyavoo, Sunil Shah

12.2. Investigations for the Male Partner....638
Fessy Louis T, Parvathy T

12.3. Investigations for the Female Partner....645
Rishma Dhillon Pai, Meenu Handa

12.4. Male Infertility: Etiology and Management....652
Ajay S Shetty, Rupin Shah

12.5. Anovulation: Etiology and Management....662
Manish Banker, Jwal Banker

12.6. Hormonal Issues and Infertility: Thyroid, Prolactin and Androgens....669
Krishnendu Gupta, Muralidhar V Pai

12.7. Tubal Factor Infertility: Etiology and Management....672
Pratap Kumar, Aswathy Kumaran

12.8. Uterine Factor in Infertility: Etiology and Management....682
Laxmi Shrikhande

12.9. Unexplained Infertility: Treatment Approach....690
Rohan Palshetkar, Nandita Palshetkar

JAYPEE BROTHERS

12.10. **Intrauterine Insemination** 693
Sudha Prasad, Aswathy Kumaran, Saumya Prasad

12.11. **Assisted Reproductive Technology** 699
Jaideep Malhotra, Shally Gupta, Neharika Malhotra, Neerja Sachdev, Narendra Malhotra, Keshav Malhotra

12.12. **Assisted Reproductive Technologies: New Techniques and Research** 712
Hrishikesh Pai, Sunita Arora, Nandan Roongta, Rishma Dhillon Pai, Nandita Palshetkar

12.13. **Recurrent Pregnancy Loss** 721
Mala Arora

12.14. **Third Party Reproduction** 727
Nayana Patel, Molina Patel, Niket Patel, Yuvraj Jadeja, Harmi Thakkar

12.15. **Adoption** 735
T Ramani Devi, D Gayathri

PART 3: Urogynaecology and Gynaecological Oncology

Section 13: Urogynaecology

13.1. **Assessment of Lower Urinary Tract Complaints and Function** 743
Achla Batra, Karishma Thariani

13.2. **Nonsurgical and Surgical Treatment of Stress Urinary Incontinence** 747
N Rajamaheswari, Vaishnavy

13.3. **Overactive Bladder** 755
Subhash Ch Biswas, Ramprasad Dey

13.4. **Urinary Tract infections** 760
Susheela Rani BS

13.5. **Urogenital Prolapse: Assessment and Treatment Approaches** 767
RM Saraogi, Chirag Patel

13.6. **Posthysterectomy Vaginal Vault Prolapse** 780
L Krishna, N Shailaja

13.7. **Anal Incontinence** 785
Pranav Mandovra, Roy Patankar

13.8. **Fistulas in Obstetrics and Gynaecology** 791
Manu Sobti

Section 14: Gynaecological Oncology

14.1. **Neoplastic Diseases of Vulva** 796
Niranjan Chavan, Dinesh Wade, Prathamesh Kane, Richa Deshmukh

14.2. **Vulval Carcinoma** 799
SP Somashekhar

14.3. **Intraepithelial Disease of the Cervix** 810
Nikhil Parwate, Sabina Hasan Ali Moman

14.4. **Malignant Diseases of Vagina** 829
Shalini Rajaram, Bindiya Gupta

14.5. **Malignant Disease of Vagina** 834
Saritha Shamsunder

14.6. **Premalignant and Malignant Diseases of the Uterus** 844
SK Giri, BL Nayak

14.7. **Benign Ovarian Neoplasia** 861
Neerja Bhatla, Anju Singh, Seema Singhal

14.8. **Malignant Ovarian Neoplasia** 872
Harshad Parasnis, Suchita Dabhadkar

14.9. **Neoplastic Diseases of Fallopian Tube** 883
Uma Singh, Manjulata Verma

14.10. **Principles of Radiation Therapy** 889
Umesh Mahantshetty, Gargee Mulye, Lavanya Gurram

14.11. **Principles of Chemotherapy** 902
Anant Ramaswamy, Sudeep Gupta

14.12. **Palliative Care in Gynaecologic Oncology** 909
Jayaraman Nambiar M, Thiencherry Rema

14.13. **Screening for Ovarian Cancer Current Perspective** 914
Usha B Saraiya, Nidhi Shah Gandhi

Index *921*

JAYPEE BROTHERS

a. Investigations should be initiated when the hemoglobin is lower than a defined value for a population
b. The definition of HMB is a loss of more than 30 mL per day
c. A woman's perception of blood loss is the main determinant of starting treatment
d. HMB is a physiological event

2. The following is true about endometrial polyps:
   a. Intermenstrual or postcoital bleeding is a typical feature
   b. They are malignant in 75% of women
   c. They are associated with endometrial atrophy
   d. All women with endometrial polyps should undergo hysterectomy
3. The following is included in AUB-N:
   a. Endometrial polyp b. Adenomyosis
   c. Endometrial cancer d. Myometrial hyperplasia
4. The following is true about endometrial ablation techniques:
   a. The depth of endometrial destruction is 15 mm
   b. First generation techniques are hysteroscopy-based techniques
   c. Second generation techniques have a longer learning curve than first generation techniques
   d. Hysterectomy provides a faster recovery than endometrial ablation techniques
5. Regarding transcervical resection of the endometrium (TCRE), the following is true:
   a. It is a second generation ablation technique
   b. Destruction of endometrium is to a depth of 4 to 6 mm
   c. After the procedure, fertility is not affected
   d. Monopolar current is used with normal saline distension
6. The following are types of thermal balloon ablation techniques, except:
   a. Hydrothermal ablation b. Cavaterm
   c. Thermachoice d. Thermablate
7. The following second generation endometrial ablation technique requires hysteroscopy:
   a. Therablate b. Cavaterm
   c. Novasure d. Hydrothermal ablation

Answers

1. c 2. a 3. d 4. b 5. b 6. a 7. d

9.6 FIBROID UTERUS

PC Mahapatra, Nitin Raithatha

INTRODUCTION

The uterine muscle is prone to forming benign neoplasms. This extremely common condition has been given various names such as fibroids, myomas, leiomyomas, solid uterine tumor, and many others over the years.[1] The prevalence of fibroids varies with age and ethnicity and depending on the population studied, varies from 5 to 65%. Women in the reproductive age group and of African ethnicity have a high prevalence of fibroids. Most, if not all, fibroids will regress after menopause.[2] The study of fibroids is a vast subject. Recent advances are mind-boggling when it comes to refinements in imaging, medications, minimally invasive surgery, and conventional surgery. The challenge for the clinician is to select the right approach of care for the woman that suits her medical condition and affords her choice.

ETIOLOGY

Fibroids are benign, estrogen-dependent tumors. They arise from the myometrial smooth muscles as monoclonal tumors. Over the last five decades, a number of theories have been proposed to expain their origin. In modern times, molecular studies have shown the importance of specific driver mutations and substantial changes in the microenvironment of the extracellular matrix (ECM). This is accompanied by changes in growth factors, cytokine signaling, and other biochemical and molecular variations which enhance fibroid growth.[3, 4] The etiopathogenesis is illustrated in **Figure 1**.

FIBROID GROWTH

The origin, growth rate, and symptomatology of fibroids vary from woman to woman and also from fibroid to fibroid in the same woman. Growth is hormone dependent and women in the reproductive age group will show some fibroid growth. In a majority of women, the growth is slow and most tumors remain indolent over long periods of time. Relatively rapid growth is seen in about one third of fibroids. When hormone levels decline, fibroids shrink. This occurs after delivery and after menopause. 7–40% of fibroids will regress in 3–36 months after delivery. After menopause, fibroids are expected to shrink. When the growth pattern varies (i.e., rapid growth of fibroids or a fibroid that grows after menopause), the clinician should keep the possibility of malignant change in mind. This is an extremely rare event.[4-6]

JAYPEE BROTHERS

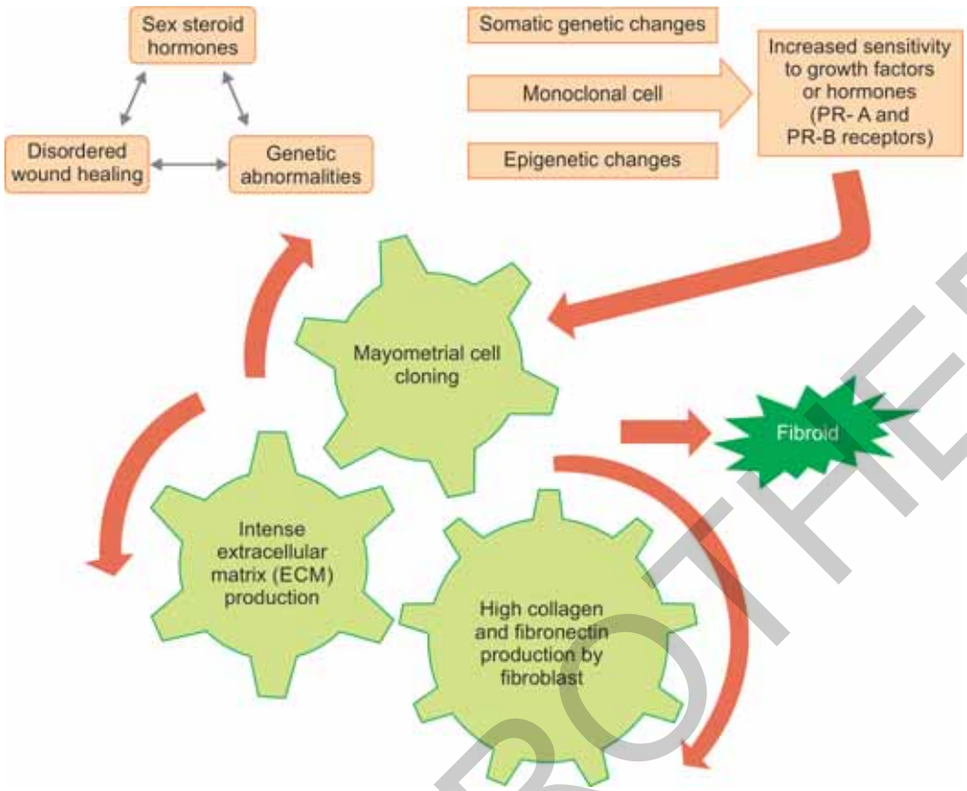

Fig. 1: Etiopathogenesis of fibroid.

The growth of the fibroid leads to an increase in volume. The available blood supply is then lower than the tissue requirement and this leads to some degenerative changes. An acute degenerative change may be seen in the form of red degeneration, necrosis, infection, and hemorrhage. Chronic degenerations are cystic, hyaline, atrophy, calcifications, fatty, or myxomatous in nature.[7,8]

EPIDEMIOLOGY AND RISK FACTORS

The prevalence of fibroids has increased over the years. This could be due to a number of factors such as:

- More estrogen exposure in the lifetime of a woman due to fewer pregnancies and childbirths
- Higher environmental estrogen exposure in modern times
- Health awareness
- Better imaging allowing higher rates of detection

It is difficult to determine the exact prevalence of a condition as ubiquitious as fibroids. Studies on epidemiology have cohorts of varying natures. Prevalence rates differ by population. These populations could be asymptomatic women undergoing health screening, symptomatic women, different diagnostic criteria and modalities, histopathological studies, or event autopsy reports.[3]

Age and race have the biggest role to play in prevalence rates. Fibroids are tumors of the reproductive age group. They are uncommon in adolescence or after menopause. Women of African origin have a higher prevalence of fibroids. They also have more and larger fibroids and the age of onset is earlier than Caucasian, Asian, or women from Latin America. First-degree relatives have a risk 2.5 times higher than the general population.[1-3] The major risk factors have been outlined in **Table 1**.[1-3, 9-12]

CLASSIFICATION

Fibroids are classified by their location in the uterus. A number of studies have been done to optimize such classification, with significant variation. The European Society of Gynecological Endoscopy (ESGE) and the Canadian Task Force have more specific classifications which directly impact management. However, they are limited in their scopes. In recent times, the FIGO (2011) classification is well-accepted globally. It is based on location, penetration of the myometrium, and encroachment of the uterine cavity. It allows for fibroid mapping and description of multiple fibroids in the same uterus. The types of fibroids are illustrated in **Figures 2A and B**.[1,3,9]

CLINICAL PROFILE

A large majority of women remain asymptomatic with myomas. They may be incidental findings on health screening or "well-woman check ups". The range of symptoms attributable to fibroids is vast, can be severe, and can affect the woman's quality of life. The symptomatology seems to depend more on location, the relationship of the fibroid to the endometrium,

JAYPEE BROTHERS

TABLE 1: Risk factors for fibroids.

Age	• Higher prevalence in reproductive age group • Women younger than 35 years have faster growth of fibroids compare to those older than 45 years
Race	• African women have greater prevalence, larger fibroids, and more numerous fibroids • African women have faster growth and higher recurrence rates
Menstrual pattern	Early menarche and late menopause are associated with higher prevalence of fibroid
Obstetric history	• Late conception is associated with higher incidence • Higher the parity lower, the incidence as postpartum remodeling leads to apoptosis of small lesion
Anthropometry	Obesity—high BMI associated with increase risk of fibroid
Lifestyle	Women with sedentary lifestyles have higher prevalence than those with regular physical activity
Smoking	Reduces the risk in some studies , while other studies find no difference
Aelchohol and Caffeine	• Alchohol—particularly beer increases risk of fibroids • High consuption in younger age have minor increased risk
Diet	• Red meat increases in dietary glycemic index, porducts with marine omega 3 fatty acid increase chances of fibroids • Green vegetables, citrus food, dairy products, vitamin D-rich food reduces risk of fibroid
Endocrine abnormalities	• Prenatal exposure of DES can increase fibroid risk • Environmental estrogen exposures (phtalates, polychlorinated biphenyl, and bisphenol A) are associated with increased risk of fibroids
Contraception	• COC pills do not increase risk of fibroid if started after adulthood. Earlier consumption of COC may be associated with higher prevalence of fibroids. • Progesterone only depot preparation reducess fibroid growth
Infection	Do not play a role
Genetics	Familial tendency is associated with chromosomal mutations called chromothripsis.

(BMI: body mass index; COC: combined oral contraceptive; DES: diethylstilbestrol)

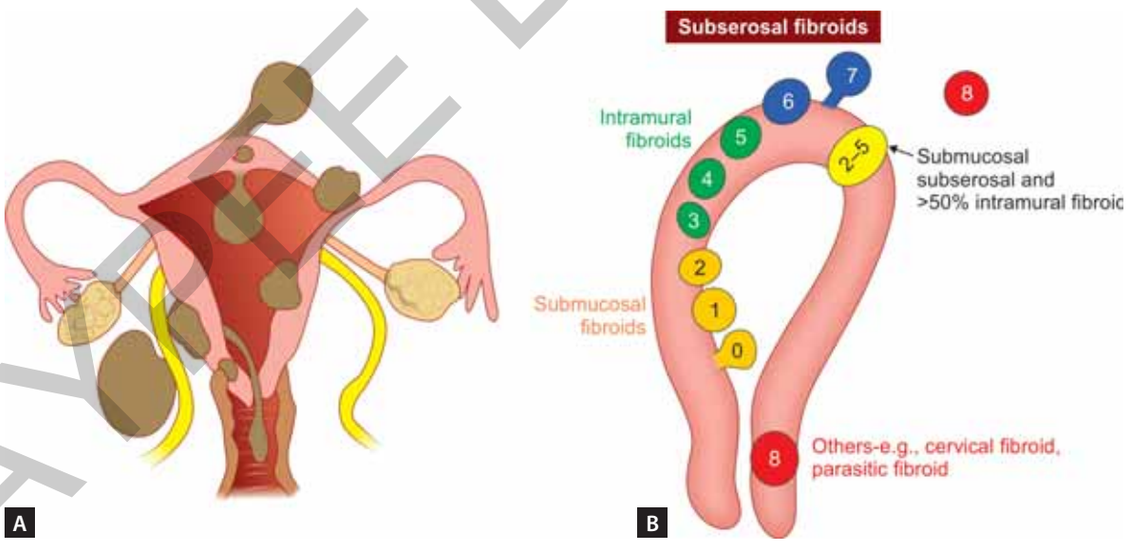

Figs. 2A and B: Types of fibroids and FIGO (2011) classification of leiomyoma.
(FIGO: International Federation of Gynecology and Obstetrics)

and growth rather than size. The symptoms and their salient features are enumerated here:

- *Menstrual disturbances:* In general, these occur when the endometrium is disturbed by an endometrial polyp, submucus fibroid, or an intramural fibroid distorting the cavity. Heavy menstrual bleeding (HMB) is due to increase in vascularity and surface area as well as altered uterine contractility. Submucus fibroids may cause intermenstrual bleeding. Fibroids that are emerging out of the cervix can cause postcoital bleeding. Postmenopausal bleeding may

JAYPEE BROTHERS

be a presenting feature of a submucus fibroid; however, it merits investigation to rule out malignancy.

- *Lump in abdomen:* Women may present with a sense of fullness, heaviness in the pelvis, palpable mass, or bloating. This is usually seen with large subserous fibroids. Cervical and broad ligament fibroids also tend to grow to a large size.
- *Pain:* Usually, fibroids are not a painful pathology. However, a woman may experience spasmodic dysmenorrhea. The pain is cramping and of a colicky nature. Chronic pain can be due to a large fibroid, compression of other organs, or associated adenomyosis or endometriosis.
- *Pressure effects:* Large fibroids may compress the viscera, nerves, and vessels in the pelvis. Anterior fibroids may cause urinary complaints including dysuria, retention of urine, or incontinence. Posterior fibroids may occasionally cause constipation. Compression of vessels and lymphatics may result in pedal edema. Nerve compression is unusual, but may present with sharp, shooting pelvic pain.
- *Infertility:* Fibroids are an unusual cause of infertility. Unless the fibroid is very large, or distorts the endometrial cavity significantly, or is located largely in the cavity, infertility should be regarded as unrelated to the fibroid.
- *Reproductive events and fibroids:* **Table 2** shows the various effects of fibroid on pregnancy. Most fibroids do not affect the pregnancy outcome. Some complications may arise as outlined. Pregnancy may also demonstrate fibroids. Most fibroids show some initial enlargement and then stabilize through pregnancy. By far and large, the postpartum period is associated with regression. Occasionally, pregnant women with fibroids may present with an emergency when there is a red degeneration, rapid cystic degeneration, torsion or rarely, rupture of a capsular vein leading to intraperitoneal bleeding and hemoperitoneum. A submucus lower segment fibroid, especially a pedunculated one, may get expelled.
- *Associated conditions:* The woman presenting with fibroids may also have associated gynecological conditions such as adenomyosis and endometriosis. She may also have comorbidity as a result of the effects of the fibroid in the form of anemia. There is a higher prevalence of obesity and depression in these women.[10-12]

NATURAL HISTORY

The natural history of fibroids varies. Just as the symptomatology, the natural history depends to a large extent on the fibroid location.

- Submucus fibroids are more likely to be symptomatic and detected at a small size. Women present early in the course of the pathology with menstrual complaints. They are also likely to affect reproductive life. A long-standing submucus fibroid in a postmenopausal woman can cause chronic inversion. This is an uncommon event.
- Intramural fibroids usually grow to a significant size (5 cm or more) before they cause symptoms. The symptoms are usually of heavy bleeding or pain.
- Subserous fibroids usually do not cause symptoms unless they are large in size. They remain undetected and asymptomatic. for a long time.

DIAGNOSIS

Clinical examination (abdominal and pelvic) will reveal an enlarged uterus that feels knobby and irregular. Usually, the uterus is mobile and there is no tenderness unless there is significant endometriosis associated with the fibroid. The consistency is firm to hard. It may be soft when there is significant degeneration in the fibroid mass. The most common differential diagnosis of a fibroid uterus on clinical examination is adenomyosis.

TABLE 2: Effects of fibroid on reproductive life of a woman.[3,5,8]

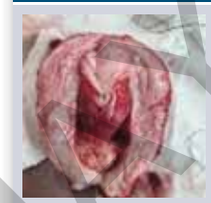		
Pregnancy • Infertility • Implantation failure • Abortion • Pressure symptoms • Malpresentation • Torsion • Ectopic pregnancy • Placenta previa	**Labor** • Preterm Labor • Malpresentation • Uterine inertia • Dystocia • Obstruction • PPH • Increased operative intervention • MRP	**Puerperium** • Secondary PPH • Inversion • Subinvolusion • Puerperal sepsis

(MRP: manual removal of the placenta; PPH: postpartum hemorrhage)

MYPEEBROTHERS

Imaging is widely available today and is routinely used to confirm the diagnosis. The standard imaging of choice is a pelvic ultrasound, preferably by the transvaginal route. High-end ultrasound machines are excellent tools to diagnose and characterize the fibroid. The fibroid appears as a well-defined, circumscribed, variegated mass. Depending on the type and degree of degeneration, appearances may vary. Fibroid mapping is a crucial element of planning treatment, especially surgical interventions. Characteristics that should be reported are the size, number, location, extension outside the uterus and compression of viscera, and relation to the endometrium.

There can be significant interobserver variations. Guidelines, such as the International Society of Ultrasound in Obstetrics and Gynecology endorsed the Morphological Uterus Sonographic Assessment (MUSA) consensus statement (2015), are useful to standardize reporting, improving the quality of diagnosis and enhancing counseling and surgical planning.[13] Reporting should include the above-mentioned characteristics and assessment of the size of the uterus and junctional zone are also desirable. The guideline suggests a Doppler evaluation and 3D mapping if facilities are available. Reporting with a diagrammatic representation is a useful adjunct.[14] There may be a learning curve and such detailed reporting may be tedious. However, it has an important part to play in surgical planning and preventing surprises on the operation table.

Other ultrasound-based modalities such as saline infusion sonography are simple procedures which can enhance visualization and characterization of the uterine cavity. New modalities such as strain ratio elastography (SE) may have value in understanding fibroid degeneration.[15]

In some situations, ultrasound falls short of the diagnostic standard. There may be confusion in the diagnosis. Magnetic Resonance Imaging (MRI) is useful in these circumstances. It helps to clarify the pathology when there is a difficulty in differentiating between a fibroid and an adenomyoma. Unusual tumors such as smooth muscle tumors of uncertain malignant potential (STUMP), leiomyosarcomas, and ovarian fibromas are better characterized by MRI. These tumors may be mistaken as degenerative changes in a fibroid. MRI is useful to study the relationship of the fibroid to other pelvic viscera.[16]

Hysteroscopy is the gold standard to treat endometrial and submucus fibroids. However, in modern gynecology, there is no role for only diagnostic hysteroscopy. These lesions are amenable to correction by hysteroscopic surgery and interventions should be planned accordingly.[17]

MANAGEMENT OF FIBROIDS

The management of fibroids is a complex subject due to the vast number of options available. It is useful for the practitioner to have a logical and generally conservative approach when managing this situation. There are a number of factors to be considered when treatment plans are made in the management of a fibroid **(Table 3)**.

The arrays of choices are mentioned in **Table 4**. It is unreasonable to discuss every management option with every woman with fibroids. However, the clinician should be aware of the various options. These choices should be offered with clinical judgment and with an understanding of the infrastructure and expertise at hand. In offering treatment to a symptomatic woman, it should be reasonably ascertained that the symptom is due to the fibroid and that the fibroid is not an incidental finding which may drain resources and time with no therapeutic benefit to the woman.

EXPECTANT MANAGEMENT OF FIBROIDS

It is desirable and reasonable to manage most fibroids without intervention. This is especially true for fibroids that are incidentally diagnosed. The ideal fibroids for expectant management are:

- Which do not cause symptoms or minimal symptoms that do not disrupt quality of life
- Those which are small to moderate sized
- Mural or subserous in location
- In perimenopausal women

Periodic assessment of symptoms, associated comorbidities (anemia), and fibroid characteristics (volume, location) should be done. Other modalities should be offered when there is a change in circumstances such as new-onset symptoms or significant change in fibroid size or nature.

TABLE 3: Factors to be considered in planning management of fibroids

Factors related to the woman	*Factors related to the fibroid*	*Factors related to healthcare settings*
Age	Location of the fibroid	Availability of different modalities
Desire to retain menstrual and/or reproductive function	Other characteristics such as number, degenerative changes	Surgical training and expertise
Symptoms, extent to which quality of life is affected	Associated gynecological conditions such as enometriosis	Financial considerations
General health status		
Personal choice and belief		

JAYPEE BROTHERS

TABLE 4: Available options for fibroid management.[18]

Expectant management	• Suitable for a significant proportion of fibroids • Fibroids should be kept under surveillance
Medical magnagement for symptoms	• Correction of anemia • Management of pain by appropriate analgesics • Management of heavy bleeding by non hormonal medications (NSAIDs, and antifibrinolytic such astranexamic acid) or hormonal medications (progesteone, combined oral contraceptive pills, LNG IUS)
Medical magnagement that reduce fibroid size	• Androgens (danazol) • GnRH agonist depots • SPRM—selective progesteron receptor modulator- mifepristone, ulipristal acetate • SERM—selective estrogen receptor modulator • Aromatase inhibitors— letrozole and anastrazole
Interventional radiology	• Uterine artery embolization • MRgFUs/HIFU • Radiofrequency volumetric thermal ablation (RFVTA)
Surgical management	• Vaginal occlusion of uterine artery • Myomectomy—conventional, laparoscopic, hysteroscopic , robotic • Hysterectomy—conventional, laparoscopic, robotic • Laparoscopic radiofrequency volumetric thermal ablation (RFVTA) • Endometrial ablaton

(GnRH: gonadotropin-releasing hormone; HIFU: high-intensity focused ultrasound; LNG-IUS: levonorgestrel-intrauterine system; MRgFU: magnetic resonance-guided focused ultrasound; NSAIDs: nonsteroidal anti-inflammatory drugs; SERM: selective estrogen receptor modulator; SPRM: selective progesterone receptor modulator)

MEDICAL MANAGEMENT OF FIBROIDS

Fibroids can be managed medically but are usually cured only surgically. This dictum should be kept in mind when counseling and setting expectations at the initial stages of fibroid management. The rationale for medical management of fibroids to provide symptom relief is as follows:

- Fibroids are benign tumors in general and rarely cause emergency situations.
- Surgery may need to be scheduled at a later date if the woman is unfit and her medical condition needs to be optimized (treatment of anemia that results from fibroid-related bleeding or control of medical conditions that may co-exist such as hypertension or diabetes).
- Surgery may not be the optimal choice for women who have recurrent fibroids or are close to menopause.
- Some women may not want to be operated for personal reasons.

The following selection criteria are desirable in selecting women for medical therapy:

- There is a need to treat the fibroid and the symptoms are ascribable to the fibroid.
- Small to moderate sized.
- Mural or subserous location.
- The woman is counseled about the process, is compliant and can accept a failure of medical therapy as a possible outcome.

Medical Therapy to Control Heavy Bleeding

Heavy bleeding can be controlled by a number of non hormonal and hormonal medications. Each have their pros and cons. Hormonal medications can be used after ruling out contraindications for their use, particularly if the preparation contains estrogen. Most oral preparations are meant for acute control of bleeding. The usual horizon for therapy is 3–6 months. It is not possible to sustain oral medical therapy for longer periods for most women. Long-term control of bleeding can be achieved by non oral routes such as injectables [Gonadotropin-releasing hormone (GnRH analog depots, depot medroxy progesterone – DMPA depots, and levonorgestrel intrauterine systems – (LNG IUS)].

Nonsteroidal Anti-inflammatory Drug

Nonsteroidal anti-inflammatory drugs (NSAIDs) can be looked upon as sole therapy for control of pain and bleeding or as adjuvant to other medical treatment options. They inhibit the cycloxygenase enzyme and reduce prostaglandin reduction. These in turn, will reduce pain and bleeding. NSAIDs are easily available, cheap, and have a good safety profile for short-term use. Some options are mefenamic acid, ibuprofen, and naproxen. They are less effective than hormonal medications in control of bleeding. Gastrointestinal side effects are a limitation of this therapy.

Tranexamic Acid

It is nonhormonal option to control heavy bleeding related to fibroid by virtue of its antifibrinolytic activity and procoagulation property. It reduces blood loss and prevents fibrin destruction at plasminogen receptor site. According to the Cochrane review, there is a 40–50% reduction in blood loss.[19] Tranexamic

JAYPEE BROTHERS

acid has minimal side effects. Bleeding control effect increases when used with other medical management.

Combined Estrogen + Progesterone Therapy

It was most commonly used option to control heavy bleeding with fibroids.[20,21] Oral contraceptive pills are easily available and affordable. They also function as effective contraception if the couple so desires. Other options of route for delivering combined estrogen and progesterone are the transdermal patch and vaginal ring. Contraindications to the use of estrogen should be ruled out before embarking on treatment with this option.

Progesterone-only Therapy

Progesterone therapy is a logical step in treating an estrogen-dependent tumor such as fibroid. There is a downregulation of both estrogen and progesterone receptors in the fibroid and this leads to remodulation. Overall, there is a reduction in the endometrial thickness and reduction in blood loss, but no significant change in fibroid size. In general, progesterone has a better safety profile than combined hormonal preparations. Progesterone can be delivered orally in the form of medroxyprogesterone acetate tablets (20–30 mg/day in dividend doses) or norethisterone acetae tablets (5–15 mg/day in divided doses). It can be also administered as a depot injection of medroxyprogesterone acetate, which also provides contraception. There may be breakthrough bleeding with progesterone therapy and the woman should be duly counseled.

Levonorgestrel Intrauterine System

If there is no significant cavity distortion, the LNG IUS is a suitable choice to deliver progesterone to the uterus. The effects are mainly local in the endometrium and to some extent on the myometrium and there is negligible systemic absorption. It is very effective for the management of bleeding related to fibroids.[22] It also functions as a long-acting reversible contraceptive (LARC). Some studies show small reductions in uterine volume and fibroid size, but this is not consistent. It is a minimally invasive, long-term symptom-based solution and is a popular method.

Medical Therapy for Symptom Control and to Reduce Fibroid Size

Some medical therapy options have been studied which reduce fibroid size and control symptoms. Many authorities look upon them as a "cure" for fibroids. However, the reduction in size is usually temporary. The fibroid tends to grow back sooner or later and symptoms also return when the life of the drug runs out.

Androgens (Danazol)

Danazol is a 17-alpha ethinyl testosterone molecule. It inhibits gonadotropin release and occupies the androgen receptors. It causes a 20% shrinkage in fibroid size. It is moderately effective in symptom control. However, this option is no longer popular due to the side effects of androgenization in the woman.

Gonadotropin-releasing Hormone Analogs

Gonadotropin-releasing hormone analogs may be agonists or antagonists. The GnRH agonists are typically used in depot form for the management of fibroids. GnRH antagonists are less studied and are available only as daily preparations.

The main benefits of GnRH analogs is symptom control, improvement in quality of life, and rise in hemoglobin level. They reduce fibroid size temporarily and relieve pressure symptosm and can favorably affect the route of surgery, taking it to a less invasive option.[18, 20, 21]

They act by desensitization and downregulation of GnRH receptors. They inhibit cell proliferation and induce apoptosis. The fibroid shrinks as a result of this. The shrinkage is to the extent of 30–50%, but is temporary. Fibroids return to their earlier size within 6 months of cessation of treatment.

Gonadotropin-releasing hormone analogs are limited by their cost, side effects, and duration of usage. Side effects include sudden onset of menopause, like symptoms such as hot flushes, sweating, dizziness, and headaches. Duration is limited to 3–6 months. Long-term usage can result in bone loss. To manage side effects and avoid bone loss, add-back therapy with estrogens may be considered.

The GnRH agonist molecules are goserelin, triptorelin, and leuprolide acetate for injectable depot forms. Nasal sprays such as nafarelin and buserilin are also available for daily use but may not be practical. GnRH antagonists are used in daily injectable form of cetrorelix and ganirelix. Recently, oral GnRH antagonists have been studied. These are elagolix and relugolix. They are under research and can be options in the future with estrogen add-back therapy for long term use.

Selective Progesterone Receptor Modulators

A number of agents which block progesterone receptors are available. The ones which have been studied widely in the management of fibroids are mifepristone (RU-486, the abortion pill), ulipristal acetate (UPA), and asoprisnil.

These drugs block the estrogen and progesterone receptors in the tumor. There is a loss of cellularity and deceleration of growth. The result is a shrinkage of the fibroid and control of symptoms. There is a 30–50% shrinkage of the fibroid volume over a course of treatment of 3–6 months. The shrinkage is more sustained than that observed with GnRH agonists.[23]

The side effect profile is generally favorable and menopausal symptoms are uncommon. There is no significant reduction in bone density. The commonly reported side effects are gastrointestinal upset and bloating. Ulipristal has potential for liver toxicity. It is a rare event but may be severe enough to need a liver transplant.[24] There may be endometrial

JAYPEE BROTHERS

hyperplasia with long-term selective progesterone receptor modulator (SPRM) use.

Ulipristal is used in a dose of 5–10 mg. Recent studies have looked at intermittent therapy over a long term and there is a significant number of women who can avoid a hysterectomy with this approach.[23] Mifepristone is used in a daily dose of 10–25 mg for 3–6 months. The formulation has recently become available in India.

Selective Estrogen Receptor Modulators

Estrogen receptor modulation can also result in fibroid shrinkage. The options available are fulvestrant, ormeloxifene and raloxifen. Fulvestrant is less effective than GnRH agonists.[25] Most studies show some effectiveness in fibroid shrinkage and symptom control. Ormeloxifene can cause ovarian cyst formation, which are temporary and benign.

Aromatase Inhibitors

Aromatase inhibitors such as letrozole, anastrazole, and fadrazole act on aromatase P450 enzyme and prevent conversion of androgens to estrogen. This results in a hypoestrogenic environment. This could lead to fibroid shrinkage. Some trials have reported such results.[26] They may be options for medical management after more research and comparative studies.

INTERVENTIONAL RADIOLOGY FOR FIBROID MANAGEMENT

Interventional radiology has opened up a new vista in the management of fibroids. It can be looked upon as a minimally invasive option between medical and surgical therapy. The purpose of radiological interventions is to reduce or block the blood supply to the fibroid (uterine artery embolization – UAE or uterine fibroid embolization – UFE) or to ablate the fibroid tissue by delivery of focused energy to the tumor (magnetic resonance-guided high-intensity focused ultrasound – MRgHIFU or myolysis by radiofrequency volumetric thermal ablation – RFVTA). UAE has been the most studied technique in interventional radiology for fibroids. Other techniques are relatively new. They offer the advantage of minimal invasion and are suitable for women who are:

- Not fit for surgery
- Not responding to medical management
- Not agreeable to have surgery

Uterine Artery Embolization (UAE) or Uterine Fibroid Embolization (UFE)

This is a minimally invasive procedure done under light sedation. It does not require anesthesia. The procedure is conducted in a cath lab. The femoral artery is entered by percutaneous route in the groin and under radiological guidance, a catheter is passed to the uterine artery. Polyvinyl occluding particles or gel are then injected to occlude the uterine artery (UAE) or selected branches going to the fibroid (UFE). The result is an ischemia and necrosis of the fibroid. Consequently, the size decreases, cellular content reduces, and symptoms should abate.[18, 27]

Compared to a myomectomy, the procedure is less invasive and has a shorter hospital stay, pain, and blood loss. The overall procedure related risk is lower. However, pregnancy rates, fertility, and abortion rates compare adversely to myomectomy. Recurrence rates and need for repeat procedures are also higher for UAE/UFE as compared to myomectomy.

The procedure has a risk of permanent impairment of uterine and ovarian function. Postembonlization syndrome with severe pain, fever, and acute abdomen are known complications. Selective distal vessel embolization and avoiding cervicovaginal and ovarian vessels may reduce these problems. Patient selection and informed decision become crucial steps before UAE/UFE.

Focused Energy Delivery Systems

Various energy sources such as radiofrequency, laser, electricity, crayon probes, and high-frequency ultrasound waves have been used to deliver ablative focused energy to the fibroid. The advantages listed are non invasive approach, no scar, daycare procedure, short hospital stay, and early resumption of activities. However, their scope is limited by the strict inclusion and exclusion criteria, need for repeat procedures, limited availability, and questionable efficacy. Long-term outcomes have not been studied in most of these methods.

Magnetic resonance-guided high-frequency focused ultrasound delivers high-intensity ultrasound waves to the fibroid under precise MR guidance. This results in protein denaturation and irreversible cell damage. This targets the center of the fibroid, but peripheral, faster growing cells are not adequately treated. Multiple sittings are need to allow adequate tissue to be treated to become clinically significant. Only one fibroid can be treated at a time. Surrounding myometrium may be damaged. Skin, bowel, and bone injury have been reported. Recently, high-end ultrasound machines have also been used to deliver the same energy.

Originally, radiofrequency myolysis was a combination of interventional radiology with laparoscopy. At laparoscopy, a radiofrequency probe is inserted into the center of the fibroid. Recently, the probe placement has been done through a 2-mm incision using imaging to direct it to the center of the fibroid. Acessa radiofrequency volumetric thermal ablation (RFVTA) system is the Food and Drug Administration (FDA)-approved one for treatment of fibroid. Studies have shown favorable results and up to 75% reduction in volume with effective control of symptoms in daycare settings. However, failure of treatment and reintervention may be required in

JAYPEE BROTHERS

significant number of patients. Postprocedure pregnancy had been reported but data is limited. At presnt, it should not be recommended for patients planning for pregnancy.

SURGICAL MANAGEMENT OF FIBROIDS

The mainstay of surgical treatment options for fibroids are myomectomy (removal of the fibroids only) and hysterectomy (removal of the uterus) **(Figs. 3A and B)**. The surgical options may be required in more than half of the cases of symptomatic fibroids. The choice of procedure and surgical technique depends upon the location of fibroids, the number of fibroids, the need of fertility preservation (uterus sparing), the expertise of the surgeon, the available equipment, associated gynecological or medical comorbidities, fitness for anesthesia, and the patient's desire to undergo surgery.

Myomectomy

This is an uterus- and fertility-preserving surgery where only fibroids are surgically removed. It is most suitable for single or a less number of fibroids which are symptomatic and future fertility is desired.

The various types of myomectomy are:

- Hysteroscopic
- Laparoscopic
- Open (laparotomy)
- Vaginal
- Robotic.

Hysteroscopic Myomectomy

It is recommended for submucous fibroids distorting uterine cavity. Performed under anesthesia, an operative hysteroscope is introduced in to the uterine cavity and the fibroids are identified and removed by one of the following different approaches:

- Cutting the pedicle with electrocautery or scissor or laser with retrieval of specimen by hook or resectoscope or loop. This is most suitable for pedunculated fibroids.
- Slicing the myoma in single sitting, where with using monopolar or bipolar-embedded electrocautery, the myoma is removed in strips. It has been observed that once protruding myoma is excised in bits, there is thickening of myometrium above it and contraction pushes the remaining myoma into the cavity. Piece meal removal should be continued till the fibers of myometrium are visualized and it is considered as completion of the process. The use of the intrauterine morcellator has made this process easier especially in fibroids <3 cm.
- Two-step approach may be needed at time, where piece meal resection of the protruding part of the fibroid in the cavity is done in first step. Post procedure, the remaining fibroid is pushed out in cavity by surrounding myometrium and simultaneous thickness of myometrium also increases. This facilitates complete and safe myoma excision in second step.

Distention media-related complications such as hyponatremia, fluid overload, or embolism are known to occur in hysteroscopic myomectomy. These can be minimized by using bipolar current instead of monopolar current and changing the distention medium. If available, laser knife may also help in minimizing complications. Other complications include perforation, intraoperative hemorrhage, incomplete removal, and infection. Recurrence of symptomatic fibroids may be encountered in about 10–15% patients. The overall failure rates at 5 years range from 14.5 to 30%. Coexisting adenomyosis or endometriosis may at times contribute to treatment failure.

Myomectomy with endometrial ablation can also be done when fertility is not the question and severe HMB is presenting complain. This combined approach allows better control of symptoms.

Correct selection of patient, appropriate mapping of fibroid, expertise and experience of surgeon, upgraded equipment, good visualization, and careful selection of safe

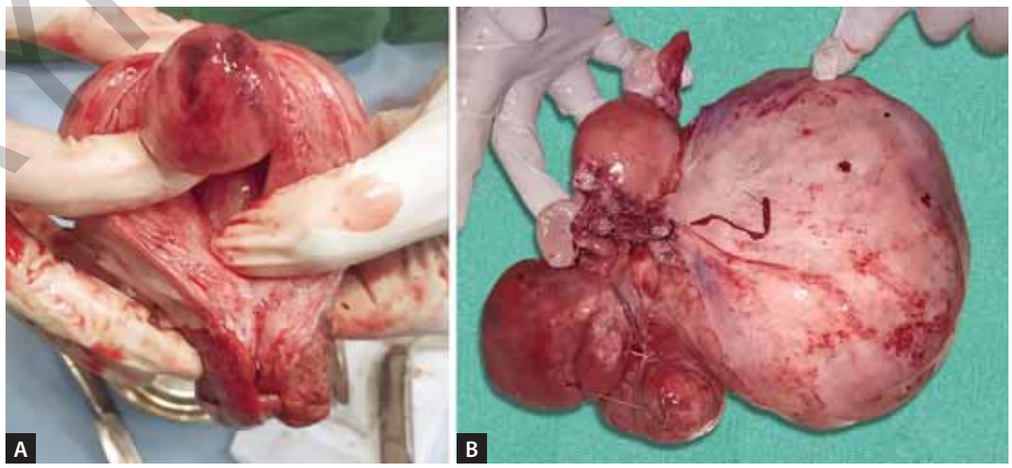

Figs. 3A and B: Post-hysterectomy specimens of the uterus showing a solitary submucus fibroid (A) and multiple fibroids (B).

JAYPEE BROTHERS

distention medium and lowest distention pressure used are some of the key factors responsible for success of the treatment.[28-30]

Laparoscopic Myomectomy

Undoubtedly laparoscopic myomectomy is associated with lesser postoperative pain, faster recovery, less hospital stay, less blood loss, cosmetic advantages, and overall less morbidity compared to open myomectomy with laparotomy. The laparoscope with the attached camera is introduced via the central port and additional ports for hand instruments are placed depending on as the site and size of the fibroid as well as operative surgeon's expertise. Currently, usage of 3D cameras offer the added advantage of depth assessment during surgery.

Subserous fibroids with a pedicle are easy to handle by just coagulating and then cutting the pedicle followed by specimen retrieval. For other types of subserous fibroids, incision over uterus is first placed after infiltration with vasopressin or using vaso-occlusive methods such as clamps, clips or torniquets. A transverse incision is preferred but if required, the incision is be made depending on the position of the fibroid. The myoma is the enucleated totally as the pseudocapsule helps in easy dissection once the correct plane is identifed. The feeding vessels are coagulated. The fibroid is the removed with due care taken not to enter endometrial cavity. Hemostasis is checked and confirmed. Multilayer or single-layer suturing of the myoma bed is done. Care must be taken to avoid hematoma formation and ensuring optimum suturing with good approximation. Polyglactin (vicryl), polydioxanone (PDS), or barbed sutures can be used.

Important key surgical points:

- Patients with fibroids with size preferably <10–12 cm, number of fibroids not more than 4 and uteri of size <16 weeks are generally to be selected .
- Avoid entry in the endometrial cavity which may affect future reproductive outcome.
- Care to be taken as to not to compromise tubal patency at any stage of dissection or suturing.
- Preventive steps to minimize blood loss and operative time same as used in open myomectomy to be employed.
- Optimal suturing neither too tight to cause necrosis nor loose to cause hematoma is to be performed.
- Retrieval of specimen can be done via colpotomy or extension of one of the port
- In-bag morcellation should be considered on case to case basis.

Overall results of lap myomectomy are comparable to open myomectomy with respect to recurrence, postsurgical pregnancy as well as the risk of rupture in pregnancy and labor. In appropriately selected cases, laparoscopic myomectomy seems to be superior to open myomectomy as it is associated less operative morbidity. However entry-related complications, long learning curve, availability of upgraded equipment, identification of small fibroids, difficult excision of fibroids at abnormal locations, and finally retrieval of specimen are remain key challenges.[31]

Concerns Related to the Retrieval of the Myoma Specimen

As postoperative histopathologic evaluation may reveal occasionally an undiagnosed or unsuspected leiomyosarcoma following routine myomectomy, hence inadvertent tissue spread after morcellation has raised alarm. The FDA issued a warning for the same, particularly following the use of a power morcellator. Nevertheless, incidence of the specimen reported to have malignant potential in various studies is quite low, only about < 0.03–0.6%. Endobag morcellation and through lavage with the patient placed in Trendelenburg and anti-Trendelenburg position at the end of surgery helps in removal of most leftover pieces, which further reduces likelihood of inadvertent spread of the disease.[32-34]

Conventional Myomectomy (Figs. 4A to C)

This conventional surgical procedure has evolved and refined over time. Conventionally, myomectomy was considered lethal but with improved surgical techniques, availability of blood and blood products, preoperative fibroid mapping due to improved imaging, availability of hemostatic agents, better suture material, and better anesthesia, it is now comparatively a safer and effective surgery. Principles are similar to those discussed in laparoscopic myomectomy but advantages are open access to the myoma and quicker and easier suturing. The only probable drawbacks compared to laparoscopy are larger incisions and slower recovery. Open myomectomy can be done for fibroids of any size, any number, any location, i.e., both intramural and subserous fibroids.

Prevention of Hemorrhage in Myomectomy[27]

Several mechanical and pharmacological measures have been used for preventing or reducing hemorrhage open or laparoscopic myomectomy myomectomy and have been found to be variably beneficial as reported in literature and so may be used alone or in combination as per the need in the particular case.

Preoperatively:

- Preoperatively ensure that the hemoglobin is at least 10 g/dL and the patient is fit for anesthesia.
- Preoperative medical management with a GnRH analog for 3–6 months may reduce fibroid size and hence smaller incision may be needed and lesser blood loss may occur because of reduced vascularity and additionally the operative time is also reduced. However, few studies suggest that the its use may result in difficulties to easily

JAYPEE BROTHERS

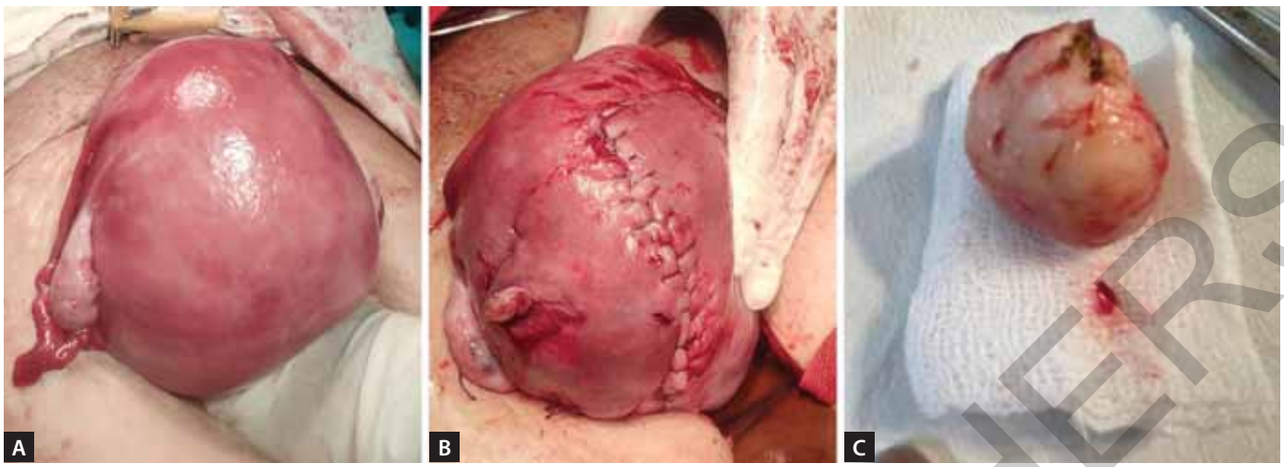

Figs. 4A to C: Conventional myomectomy. (A) Enlarged uterus with myoma; (B) Uterine incision sutured after enucleation of the myoma; (C) Myoma specimen.

obtain a plane of cleavage during enucleating the myoma from myometrium. It has also not shown any advantage for hysteroscopic myomectomy.

- Preoperative use of SPRMs such as UPA that are known to shrink the fibroid size and reduce blood loss have been proposed. However, more studies are required to demonstrate significant benefits justifying routine use.

Intraoperatively:

- Tourniquet application or uterine artery occlusion (UAO) at level of uterine isthmus results in occlusion uterine arteries and at infundibulopelvic ligament for ovarian collateral circulation with help of Bonney's myomectomy clamp, red rubber catheter through a hole in broad ligament, and specialized vascular clamp on uterine. Important point to note is that the occlusion is to be released every 15–20 minutes for some time to avoid tissue ischemia and necrosis.
- Vasopressin diluted in a dose of 10 units in 10 mL or 20 units in 20 mL of saline is to be infiltrated in fibroid boundaries or just medial to feeding vessel or uterine artery thereby reducing the blood loss by 40–50%
- Misoprostol 400 µg per rectally 30 minutes prior to surgery and oxytocin 10 units infusion pre- and intraoperatively decreases blood flow and increases myometrial contraction thereby reducing overall blood loss. This is also helpful in hysteroscopy as it causes softening of cervix for easy dilatation and minimizes the risk of perforation.
- Antifibrinolytics such as tranexamic acid 1 g IV just before onset of surgery reduce blood loss and need for blood transfusion significantly.
- Gelatin–thrombin matrix for local application as hemostatic plug over the bleeding site acts as sealant causing rapid hemostasis and reduces need of blood.

Myomectomy and Pregnancy

Postmyomectomy, different studies have described variable pregnancy rates depending on the type and methodology of the study; however, overall, a pregnancy rate of 49–57% has been documented in literature. Myomectomy is known to reduce the abortion rate, particularly in submucous fibroids. There is statistically no significant difference observed between laparoscopy versus open myomectomy in subsequent obstetric and perinatal outcomes including cumulative pregnancy rate.[35-37]

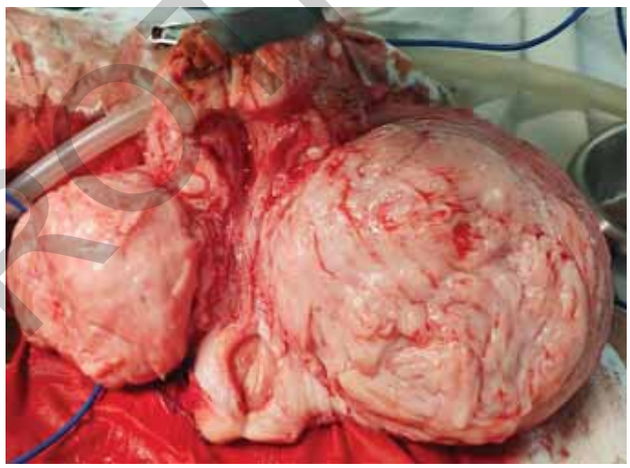

Fig. 5: Hysterectomy specimen of an enlarged uterus with multiple fibroids.

Hysterectomy (Fig. 5)

Fibroids are the one of the top three indications for hysterectomies performed worldwide. The common indications for offering an hysterectomy in symptomatic fibroids are:

- Symptomatic fibroids refractory to medical management
- Age > 40 years
- Child bearing completed and future fertility/uterus preservation not desired by patient
- Anticipated difficult compliance and follow-up

Hysterectomy is known to provide relief of symptoms and drastically improve quality of life.

JAYPEE BROTHERS

TABLE 5: Treatment options of fibroids.

Type of myoma as per FIGO[39]	*First line*	*Supportive interventions*	*Remarks*
0	Hysteroscopic myomectomy		
1	• <3 cm hysteroscopic myomectomy (1 step) • >3 cm hysteroscopic myomectomy (2 steps)	• Preoperative patient fitness with anemia correction and reduction of fibroid volume with SPRMs or GnRH analogs	• 1–3 month medical therapy may convert two-step procedure to single step due to reduction in size or • No further treatment may be needed if no further symptoms
2 desiring pregnancy	• Long-term intermittent SPRM therapy	• Volume reduction > 50% and uterine cavity normal—no further treatment • Volume reduction > 25–50% and HMB controlled—no further treatment or hysteroscopic myomectomy if cavity is uneven with the possibility of interfering with pregnancy • No response or insufficient response or no relief of symptoms then consider hysteroscopic myomectomy	• Natural conception • Natural conception • If other indications or no pregnancy after initial efforts then consider IUI or IVF • Natural conception • If other indications or no pregnancy after initial efforts then consider IUI or IVF
2 not desiring pregnancy	• Myomectomy • Long-term intermittent SPRM (3-4 courses of 3 months) • If 40+ or not interested in uterine conservation and poor compliance to medical management- Hysterectomy	• Preoperative anemia correction • If good response • If inadequate symptomatic relief • Preoperative fitness and anemia correction	• No further treatment • If symptomatic or if recurrence consider myomectomy
Type 2–5 single or multiple fibroid	• Same as above	• Same as above	• Same as above
Type 6–7	• No pressure symptoms , size < 6 tcm—no treatment • If pressure symptoms or possible torsion—myomectomy • Size > 8 cm with minimal symptoms but high risk group—myomectomy	• Counselling regarding prognosis and follow up is particularly important in high risk group • If no desire for uterine preservation consider hysterectomy	
Type 8	• Asymptomatic < 6 cm—no treatment • Pressure symptoms or pain – Myomectomy / hysterectomy	• Follow-up advised • If childbearing completed or difficult myomectomy anticipated then consider hysterectomy	

(GnRH: gonadotropin-releasing hormone; HMB: heavy menstrual bleeding; IUI: intrauterine insemination; IVF: in vitro fertilization; SPRM: selective progesterone receptor modulator)

Route of hysterectomy:[38]

- Laparoscopic hysterectomy
- Vaginal hysterectomy
- Abdominal hysterectomy
- Robotic surgery.

Laparoscopy had been proved to be an effective mode of hysterectomy in fibroids with less perioperative complications and a faster recovery. However, Donnez et al. have reported statistically no significant difference between any type and route of hysterectomy.

Important key surgical points: All steps are same as any other hysterectomy; however, certain important points should be always remembered.

- Always firstly identify round ligaments to get orientation of the uterus and its relations with other organs.
- After clamping and transfixing upper pedicles, identify uterine artery and vessels feeding the fibroids. Camp and double ligate these vascular pedicles separately.
- If space is restricted, enucleation of the fibroid like in myomectomy can be done so as to allow more space and provide better orientation. After ligating the uterine and feeding vessels, subsequent myomectomy will not cause bleeding.
- Always try to restore normal anatomy, avoid torsion while handling specimen.
- When in doubt, identify the ureter and trace it down before clamping.

Generally, most patients seem satisfied postoperatively due to symptom relief and improvement in quality of life and are usually back to their normal lifestyle within 6–8 weeks postoperatively.

JAYPEE BROTHERS

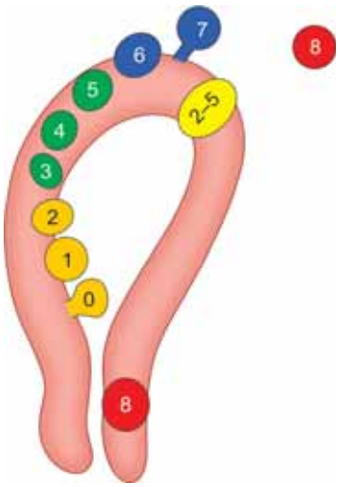

Fig. 6: FIGO classification based on location of fibroids.
(FIGO: International Federation of Gynecology and Obstetrics)

Vaginal Occlusion of Uterine arteries

By using a specialized clamp which can be applied on the uterine arteries through vagina and occlusion of both the uterine arteries is achieved which leads to ischemia of the uterus and primarily the myoma. Postprocedure pregnancy outcome needs further study and hence at present is not recommended in patients a planning pregnancy. Published medical literature has shown efficacy in reduction in menstrual blood loss and shrinkage of fibroid.[27]

SUMMARY OF TREATMENT PLAN

As there are several treatment options are available, a simplified approach can be adopted using the different guidelines and FIGO classification based on location of fibroids **(Fig. 6 and Table 5)**.

CONCLUSION

An individualized approach in each patient of fibroids should be offered with the aim to provide relieve the symptoms of HMB, pelvic pressure, subfertility, and pain. Detailed evaluation of the clinical presentation, examination, and imaging are the first steps in management of fibroids. Planning of treatment offering a expectant, medical, surgical, or endoscopic option using an evidence base approach is to done after an informed decision-making session explaining the pros, cons, and limitations of all treatment options and respecting patient choices will usually lead to desired positive outcomes.

KEY MESSAGES

- Fibroids are benign tumors of the uterus.
- Clinical presentations are variable ranging from being asymptomatic to symptoms such as HMB, pain, pressure, and infertility.
- Imaging using ultrasound and MRI have greatly helped in precise fibroid mapping.
- Spectrum of treatment options is available ranging from expectant, medical, open surgery, to minimally invasive surgery.
- If selected appropriately, they result in favorable outcomes providing symptom relief and improving quality of life.

REFERENCES

1. Donnez J, Dolmans MM. Uterine Fibroid management: from present the future. Hum Reprod Update. 2016;22(6):665-86.
2. Berek JS. Uterine Fibroids. In: Berek JS (Ed). Berek & Novak; Gynecology essential, 1st Edition. Netherlands: Wolters Kluwer; 2020. pp. 138-53.
3. Giuliani E, As-Sanie S, Marsh EE. Epidemiology and management of uterine fibroids. Int J Gynecol Obstet. 2020;149:3-9.
4. Vergara D, Catherino WH, Trojano G, Tinelli A. Vitamin D: Mechanism of action and biological effects in uterine fibroids. Nutrients. 2021;13:597.
5. Tochie JN, Badjang GT, Ayissi G, Dohbit JS. Physiopathology and management of uterine fibroids. Intech Open. 2020;94162.
6. Peddada SD, Laughlin SK, Miner K, Guyon JP, Haneke K, Vahdat HL, et al. Growth of uterine leiomyomata among premenopausal black and white women. Proc Natl Acad Sci USA. 2008;105:19887-92.
7. DeWaay DJ, Syrop CH, Nygaard IE, Davis WA, Voorhis VJV. Natural history of uterine polyps and leiomyomata. Obstet Gynecol. 2002;100:3.
8. Baird DD, Garrett TA, Laughlin SK, Davis B, Semelka RC, Peddada SD. Short-term change in growth of uterine leiomyoma: Tumor growth spurts. Fertil Sterill. 2011;95:242.
9. Lasmar RB, Barrozo PRM, Dias R, de Oliveira MAP. Submucous mayoma: A new presurgical classification to evaluate viability of hysteroscopic surgical treatment–preliminary report. J Minim Invasive Gynecol. 2005;12(4):308-11.
10. Borah BJ, Nicholson WK, Bradley L, Stewar EA. The impact of uterine leiomyomas: a national survey of affected women. Am J Obstet Gynecol. 2013;209:319.e.1.
11. Stewart EA, Laughlin-Tommaso SK. (2021). Uterine fibroids (leiomyomas): Epidemiology, clinical features, diagnosis, and natural history. [online] Available from https://www.uptodate.com/contents/uterine-fibroids-leiomyomas-epidemiology-clinical-features-diagnosis-and-natural-history [Last accessed December, 2021].
12. Bonine NG, Banks E, Harrington A, Vlahiotis A, Moore-Schiltz L, Gillard P. Contemporary treatment utilization among women diagnosed with symptomatic uterine fibroids in united states. BMC women's Health. 2020;20:174.
13. Bell SW, Kempson RL, Hendrickson MR. Problematic uterine smooth muscle neoplasms: A clinicopathologic study of 213 cases. Am J Surg Pathol. 1994;18:535.
14. Daga SR, Phatak SV. Ultrasound evaluation of uterine leiomyoma in perimenopausal females with histopathological correlation. J. Evolution Med Dent Sci. 2020;9(08):562-5.
15. Van den Bosch T, Dueholm M, Leone FP, Valentin L, Rasmussen CK, Votino A, et al. Terms, definitions and measurements to describe sonographic features of myometrium and uterine masses: a consensus opinion from the Morphological Uterus

JAYPEE BROTHERS

Sonographic Assessment (MUSA) group. Ultrasound Obstet Gynecol. 2015;46:284-98.
16. Bougie O, Bedaiwy MA, Laberge P, Lebovic G, Leyland N, Atri M, et al. Quality of ultrasonography reporting and factors associated with selection of imaging modality for uterine fibroids in Canada: results from a prospective cohort registry. CAMJ Open. 2020;8(3):E506-13.
17. Sasaran V, Turdean S, Gliga M, Ilyes L, Grama O, Muntean M, et al. Value of strain-ratio elastography in the diagnosis and differentiation of uterine fibroids and adenomyosis. J Pers Med. 2021;11;824.
18. Hartmann KE, Fonnesbeck C, Surawicz T, Krishnaswami S, Andrews JC, Wilson JE, et al. Management of Uterine Fibroids. Comparative Effectiveness Review No. 195; AHRQ Publication No. 17(18)-EHC028-EF. Rockville, MD: Agency for Healthcare Research and Quality. 2017.
19. Bryant-smith AC, Lethaby A, Farguhar C, Hickey M, Antifibrinolytics for heavy menstrual bleeding. Cochrane Database Syst Rev. 2018;4:CD000249.
20. Yao X, Sewart EA, Laughlin-Tommaso SK, Heien HC, Borah BJ. Medical therapies for heavy menstrual bleeding in women with uterine fibroids: a retrospective analysis of a large commercially insured population in the USA. BJOG. 2017;124:322.
21. Marsh EE, Galitsky A, Stewart EA, Kerolous M. Burden, prevalence and treatment of uterine fibroids: A survey of US women. J Women's Health. 2018;27(11)::1359-67.
22. Sayed GH, Zakherah MS, El-Nashar SA, Shaaban MM. A randomized clinical trial of a levonorgestrel-releasing intrauterine system and a low-dose combined oral contraceptive for fibroid-related menorrhagia. Int J Gynaecol Obstet. 2011;112:126-30.
23. Mahase E. Uterine fibroid drug is recalled after case of liver failure requiring transplantprompts EU review. BMJ. 2020;368:m1112.
24. Murji A, Whitaker L, Chow TL, Sobel ML. Selective progesterone receptor modulators(SPRMs) for uterine fibroids. Cochrane Database Syst Rev. 2017;4:CD010770.
25. Donnez J, Hervais Vivancos B, Kudela M, Audebert A, Jadoul P. A randomized, placebo-controlled, dose-ranging trial comparing fulvestrant with goserelin in premenopausal patients with uterine fibroids awaiting hysterectomy. Fertil Steril. 2003;79:1380-9.
26. Song H, Lu D, Navaratnam K, Shi G. Aromatase inhibitors for uterine fibroids. Cochrane Database Syst Rev. 2013;(10):CD009505.
27. Vilos GA, Allaire C, Laberge PY, Leyland N Vilos AG, Murji A, et al. The management of uterine leiomyomas. J Obstet Gynaecol Can. 2015;37:157-78.
28. Munro MG. Abnormal uterine bleeding: surgical management–part 3. J Am Assoc Gynecol Laparosc. 2001;8:18-47.
29. Loffer FD. Improving results of hysteroscopic submucusal myomectomy for menorrhagia by concomitant endometrial ablation. J Min Invas Gynecol. 2005;12:254-60.
30. AAGL Advancing Minimally Invasive Gynecology Worldwide, Munro MG, Storz K, Abbott JA, Falcone T, Jacobs VR, et al. AAGL practice report. Practice guidelines for the management of hysteroscopic distendng media. J Minim Invasive Gynecol. 2013;20:137-48.
31. Donnez O, Donnez J, Dolmans MM, Dethy A, Baeyens M, Mitchell J. Low pain score after total laparoscopic hysterectomy and same-day discharge within less than 5 hours: Results of a prospective observational study. J Minim Invasive Gynecol. 2015;22:1293-9.
32. Donnez O, Jadoul P, Squifflet J, Donnez J. Iatrogenic peritoneal adenomyoma after laparoscopic subtotal hysterectomy and uterine morcellation. Fertil Steril. 2006;86:1511-2.
33. Bojahr B, De Wilde RL, Tchartchian G. Malignancy rate of 10,731 uteri morcellated during laparoscopic supracervical hysterectomy (LASH). Arch Gynecol Obstet. 2015;292:665-72.
34. Parker WH, Kaunitz AM, Pritts EA, Olive DL, Chalas E, Clarke-Pearson DL, et al. Leiomyoma Morcellation Review Group. US Food and Drug Administration's Guidance regarding morcellation of leiomyomas: well-intentioned, but is it harmful for women? Obstet Gynecol. 2016;127:18-22.
35. Galliano D, Bellver J, Días-Garcia C, Simón C, Pellicer A. ART and uterine pathology: how revelant is the maternal side for implantation? Hum Reprod Update. 2015;21:13-38.
36. Metwally M, Farquhar CM, Li TC. Is another meta-analysis on the effects of intramural fibroids on reproductive outcomes needed? Reprod Biomed Online. 2011;23:2-14.
37. Tian YC, Long TF, Dai YM. Pregnancy outcomes following different surgical approaches of myomectomy. J Obstet Gynaecol Res. 2015;41:350-7.
38. Aarts JW, Nieboer TE, Johnson N, Tavender E, Garry R, Mol BW, et al. Surgical approach to hysterectomy for benign gynaecological disease. Cochrane Database Syst Rev. 2015;8:CD003677.
39. Munro MG, Critchley HO, Broder MS, Fraser IS. FIGO Working Group on Menstrual Disorders. FIGO classification system (PALM-COEIN) for causes of abnormal uterine bleeding in nongravid women of reproductive age. Int J Gynaecol Obstet. 2011;113:1-2.

LONG QUESTIONS

1. Discuss the management approach to a primigravida at 6-week pregnancy who presents to the clinic with an 8-cm intramural fibroid. What are the difficulties anticipated in labor and delivery with such a fibroid?
2. Discuss the pharmacological management of fibroids.
3. What is the role of radiology in the management of fibroids? Discuss the various diagnostic and therapeutic modalities.
4. What impact do fibroids have on fertility? Discuss the possible mechanisms and possible interventions.

SHORT QUESTIONS

1. What is the FIGO classification of fibroids? Why is it useful?
2. Name the indications and contraindications for myomectomy.
3. What are the pros and cons of ulipristal acetate in treating fibroids?

MULTIPLE CHOICE QUESTIONS

1. Heavy menstrual bleeding is typically associated with:
   a. Cervical fibroid
   b. Subserosal fibroid
   c. Submucosal fibroid
   d. Intramural fibroid

JAYPEE BROTHERS

2. Which of the following is not a risk factor for fibroid uterus?
   a. Nulliparity b. African-American race
   c. Menopause d. Obesity
3. Which of the following options are correct? Fibroids lead to heavy menstrual bleeding because fibroids alter myometrial contractility:
   a. Both statements are true and causally related
   b. Both statements are true but not causally related
   c. First statement is true and second is false
   d. Both statements are false
4. Which is/are true about red degeneration of fibroids?
   i. Occurs in pregnancy
   ii. Occurs in menopause
   iii. Managed conservatively
   iv. Surgery is the definitive management
   a. Only i, ii and iii are correct
   b. Only i and iii are correct
   c. Only ii and iv are correct
   d. Only iv is correct
5. The most common site for fibroids is:
   a. Cervical fibroid b. Subserosal fibroid
   c. Submucosal fibroid d. Intramural fibroid
6. Which of the following fibroid is /are associated with pressure symptoms ?
   i. Cervical fibroid
   ii. Subserosal fibroid
   iii. Broad ligament fibroid
   iv. Intramural fibroid
   a. Only i, ii and iii are correct
   b. Only i and iii are correct
   c. Only ii and iv are correct
   d. Only iv is correct
7. Which type of fibroid has been associated with adverse pregnancy outcomes?
   a. Submucous Fibroid b. Intramural fibroid
   c. Subseroal fibroid d. Seedling fibroid
8. Which of the following is/are true about use of GnRH in treatment of fibroids?
   i. Reduces fibroid volume
   ii. To change the initially decided route of surgery
   iii. To improve pre operative hemoglobin
   iv. To postpone surgery and manage symptoms
   a. Only i and iii are correct
   b. Only ii and iv are correct
   c. Only iv is correct
   d. All four are correct

Answers

1. c 2. c 3. a 4. b 5. d 6. b
7. a 8. d

9.7 ADENOMYOSIS

N Sanjeeva Reddy, Radha Vembu

INTRODUCTION

Adenomyosis of the uterus is a benign disorder with pathologically demonstrated endometrial glands and stroma in the uterine myometrium. It is one of the specific entities in PALM-COEIN FIGO classification of abnormal uterine bleeding (AUB). Even though this condition was considered as a disease of multiparous women over 40 years, it is more commonly diagnosed in younger women with the advancement of imaging techniques. However, there is no clear consensus in the diagnosis and classification of adenomyotic lesion.

DEFINITION

According to histological classification, focal adenomyosis is defined as circumscribed nodular aggregates of endometrial glands and stroma surrounded by normal myometrium. Within the myometrium, when the ectopic endometrial tissue is surrounded by hypertropic myometrium, it is called adenomyoma. In diffuse adenomyosis, endometrial glands and stroma are recognized throughout the myometrium.[1]

PREVALENCE

Adenomyosis was a disease of elderly, multiparous women, but now, it is commonly diagnosed in young women, infertile patients, and women with pain or AUB or both.[2] It often coexists with other uterine lesions like fibroid and endometriosis and hence it is difficult to estimate. In women less than 45 years, it is around 31.2% and increases to 65.6% over the age of 45 years. However, among the general population, it is estimated to be present in 20–35% of women[3, 4] with majority of women being postmenopausal. But age is not consistently associated with the disease. It is diagnosed in 24.4% of infertile women, especially in those with endometriosis, recurrent miscarriage, and recurrent implantation failure, and in older women seeking IVF treatment.[5] Cystic adenomyosis is seen in adult form in 5–7% of hysterectomy specimen with fibroid uterus. The juvenile form is seen in nulliparous women between 13 and 20 years of age where the true incidence is not known with only few case reports. Even though adenomyosis is rare before 20 years of age, cystic forms are reported in young women, till now less than 10 cases are reported.

JAYPEE BROTHERS

For detailed information on obstetrics & gynecology books, visit our website www.jaypeebrothers.com, for detailed information on obstetrics & gynecology

FOGSI's POSTGRADUATE GYNAECOLOGY A TEXTBOOK

Training in obstetrics and gynaecology is based on clinical exposure and a strong foundation of knowledge. There are some immutable aspects related to basic sciences in every field, but knowledge is constantly evolving. There is a surfeit of information, and there is a felt-need to distill this into a practical and useful manner.

FOGSI's Postgraduate Gynaecology: A Textbook is an authoritative compendium on the subject suitable for trainees and practitioners. The important highlights of the book are mentioned here:

- Complete coverage of the subject with due attention to the subspecialties including fetal medicine, endoscopy, fertility care, uro-gynaecology and oncology
- Chapters are compiled into two volumes for quick reference
- Contributing authors are experts in their fields and represent a broad geographic distribution as well as representing the public and private healthcare settings
- Key messages, diagrams, photographs and tables have been provided to adequately illustrate the subject matter
- Multiple choice questions, short and long questions with every chapter to facilitate self-assessment and preparation for examinations.

Hope that the book is useful for every trainee and practitioner in their endeavor to lay a foundation, and constantly endeavor to evolve to a higher clinical standard of care.



Alpesh Gandhi
MBBS DGO FICOG FRCOG Post PG (Hospital Management)
Senior Consultant, Obstetrics and Gynecology
Critical Care in Obstetrics and
High-risk Pregnancy Expert
Arihant Women's Hospital, Ahmedabad, Gujarat
President, The Federation of Obstetric and Gynaecological Societies of India (FOGSI), 2020



Parikshit Tank
MD DNB DGO DFP MNAMS FICOG FRCOG
Senior Consultant Obstetrician and Gynecologist
Ashwini Maternity and Surgical Hospital
Jupiter Hospital, Mumbai, Maharashtra, India
Honorary Professor, Assisted Reproduction
Pacific Medical College and Hospital
Udaipur, Rajasthan, India
Treasurer, The Federation of Obstetric and Gynaecological
Societies of India (FOGSI), 2021-2024
Joint Secretary, FOGSI, 2012
Joint Treasurer, FOGSI, 2018-2020
Chairperson, Safe Motherhood, FOGSI, 2014-2017



Ameya Purandare
MD DNB FCPS DGO DFP MNAMS FICMCH FICOG Fellowship in Gyne Endoscopy (Germany)
Senior Consultant Obstetrician and Gynecologist
Purandare Hospital, KJ Somaiya Medical College and Hospital
Sir HN Reliance Foundation Hospital and Research Centre
Bhatia Hospital, Masina Hospital, Mumbai Police Hospital
Mumbai, Maharashtra, India
2nd Vice President Elect, The Association of Maharashtra Obstetric and Gynaecological Societies (AMOGS), 2022-2024
Joint Secretary, FOGSI, 2019
Chairperson, Food, Drugs and Medical and Surgical Equipments Committee, FOGSI, 2015-2017
Assistant Administrator, FOGSI Manyata Project

Printed in India

Available at all medical bookstores or buy online at www.jaypeebrothers.com

JAYPEE BROTHERS
Medical Publishers (P) Ltd.
EMCA House, 23/23-B, Ansari Road,
Daryaganj, New Delhi - 110 002, INDIA
www.jaypeebrothers.com

Join us on facebook.com/JaypeeMedicalPublishers

Shelving Recommendation
GYNECOLOGY

ISBN 978-93-5465-662-0