AICOG 2022 Indore
Quality care within her reach

FOGSI FOR ALL, ALWAYS
DHEERA
STOP VIOLENCE AGAINST WOMEN

AICOG

Manual of

Endoscopy

Cutting Edge

64th All India Congress of
Obstetrics & Gynaecology
04–08 April 2022

Editors
Asha Baxi
Dhaval Baxi

Co-Editors
Archana Dubey
Astha Jain Mathur

Organized by:
The Indore Obstetric and Gynaecological Society
Under the Aegis of FOGSI

EVERY MEMBER MATTERS
IOGS

JAYPEE

Contents

1. **Ergonomics in Gynecological Laparoscopy.....1**
   Dhaval Baxi, Asha Baxi
2. **Energy Sources in Laparoscopy.....7**
   Manjula Anagani, R Sindura Ganga, Swathi HV
3. **Safe Abdominal Port Entry Techniques in Laparoscopic Gynecologic Surgery.....14**
   Vivek Salunke
4. **Diagnostic Laparoscopy.....21**
   Yashodhan Deka
5. **Laparoscopic Anatomy of the Pelvis.....24**
   Damodar Rao
6. **Diagnostic Hysteroscopy.....34**
   Anshu Baser, Archana Baser
7. **Complications in Laparoscopy.....42**
   B Ramesh, Jasmine S Abraham
8. **Complications in Hysteroscopy.....46**
   S Krishnakumar, Aditi Abhade
9. **Sterilization and Disinfection in Endoscopy.....55**
   Subash Mallya
10. **Myoma Specimen Retrieval Methods.....60**
    Pandit Palaskar

CHAPTER 3

Safe Abdominal Port Entry Techniques in Laparoscopic Gynecologic Surgery

Vivek Salunke

INTRODUCTION

Laparoscopy has gradually become popular in gynecological practices due to its many benefits and has less surgical complications compared to laparotomy such as pain and hospitalization. Complications related to gynecological laparoscopy are relatively rare but mostly related with abdominal port entry. It is a challenging procedure in laparoscopy because of its serious complications such as gastrointestinal tract and major blood vessel injuries that account for 50% cases prior to the commencement of the intended surgery. Most injuries are caused by the insertion of the primary umbilical trocar, so it is important to learn the safe techniques in creating pneumoperitoneum in gynecologic laparoscopy.

The main abdominal access techniques used in laparoscopic surgery include:

1. Classic or closed entry
2. Open (Hasson) technique
3. Direct trocar insertion without prior pneumoperitoneum

CLOSED ENTRY (CLASSIC) LAPAROSCOPY

The classic, or closed entry, laparoscopic technique requires cutting of the abdominal skin with a scalpel, insufflation of air or gas into the abdomen (establishment of pneumoperitoneum), and insertion of a sharp trocar/cannula system into the abdomen. Following removal of the sharp trocar, the abdominal cavity is examined by an illuminated telescope through the cannula.

Veress Needle Insertion Sites (Fig. 1)

1. *Umbilical point:* Here there is risk of injury to abdominal viscera, inferior vena cava (IVC) and abdominal aorta.
2. *Palmer's point* is most preferred site for port entry. It lies in left upper quadrant 3 cm below left subcostal margin in mid-clavicular line and is preferred in obese, very thin females or previously operated for abdominal surgeries. In Palmer's point, one must be careful of inflated stomach so must deflate it using nasogastric tube, in cases of hepatosplenomegaly,

JAYPEE BROTHERS

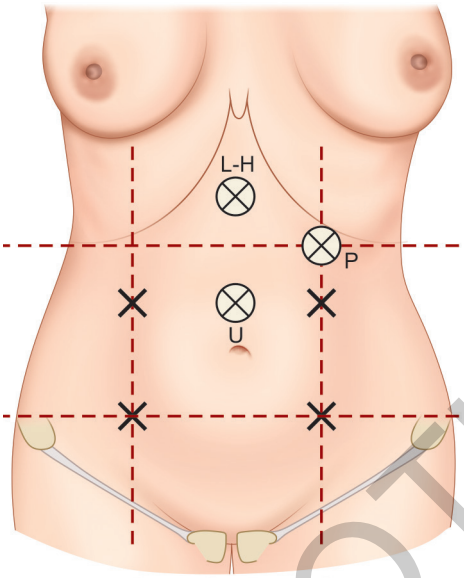

Fig. 1: The access points for abdominal entry in laparoscopic surgery.
(L-H = Lee-Huang point; P = Palmer's point; U = umbilical point)

previous gastric or splenic surgery and careful of splenic flexure of colon in case of tuberculosis.

3. *Jain point* lies in the left paraumbilical region in a straight line of 10–13 cm depending on patient's body mass index (BMI) and body type drawn vertically upward from a point of 2.5 cm medial and 1 cm above anterior-superior iliac spine. It avoids sudden catastrophic injury to major retroperitoneal vessels, viscera, adhesions and bowel.
4. *Lee-Huang point* lies at the middle upper abdomen centrally between the xiphoid process and the umbilicus and preferred in large pelvic pathology like fibroids, gynecological malignancy or failed Palmer's or umbilical approach, umbilical hernia.
5. *Latif's point* is in the right angle between the xiphoid process and the right costal margin but there is risk of injury to liver and must be avoided in previous right upper abdominal operated or mass cases.
6. *Transuterine Veress CO_2 insufflation:* Using a long Veress needle, pneumoperitoneum has been established through the fundus of the uterus transvaginally. This technique has been especially helpful in obese women.
7. *Trans cul-de-sac CO_2 insufflation:* The posterior vaginal fornix has been reported as another site through which to establish pneumoperitoneum especially in obese women.
8. *Ninth or tenth intercostal space CO_2 insufflation:* If the parietal peritoneum is adhered to the undersurface of the ribs at the costal margin, Veress needle

JAYPEE BROTHERS

can be inserted through the ninth or tenth intercostal space at the anterior axillary line along the superior surface of the lower rib to avoid injury to the underlying neurovascular bundle. Following pneumoperitoneum, established at 20–25 mm Hg pressure, 5 mm laparoscopes are introduced at Palmer's point for inspection, followed by additional trocars, inserted under direct vision, to facilitate the required surgery and/or perform adhesiolysis when indicated.

Angle of Veress Needle Insertion

The position of the umbilicus was found, on average, 0.4 cm, 2.4 cm, and 2.9 cm caudally to the aortic bifurcation in normal weight (BMI <25 kg/m^2), overweight (BMI 25–30 kg/m^2), and obese (BMI >30 kg/m^2) women, respectively. Therefore, the angle of the Veress needle insertion should vary accordingly from 45° in non-obese women to 90° in very obese women.

Veress Needle Safety Tests

- The double click sound of the Veress needle
- The aspiration test
- The hanging drop of saline test
- The "hiss" sound test
- The syringe test

Veress Needle Modifications

To reduce entry-related injuries several instruments have been introduced like—shielded disposable trocars, optical Veress needle, optical trocars, radially expanding trocars, and a trocarless reusable, visual access cannula.

- *Pressure-sensor-equipped Veress needle:* A modified pressure-sensor-equipped Veress needle to provide the surgeon immediate feedback the moment the tip enters the peritoneal cavity has been described.
- *Optical Veress needle (minilaparoscopy):* The Veress needle has been modified to a 2.1 mm diameter and cannula 10.5 cm long to allow insertion of a thin zero degree, semirigid fiberoptic minilaparoscope. During insertion of the assembled unit (Veress cannula and telescope) the surgeon observes a cascade of monitor color sequences that represent different abdominal wall layers: subcutaneous fat appears yellow, fascia white, anterior rectus muscle red, and peritoneum translucent or shiny bright.

Veress Intraperitoneal (VIP) Pressure

Several investigators have reported initial intraperitoneal insufflation pressures <10 mm Hg indicating correct Veress needle placement. Adequate pneumoperitoneum traditionally has been defined by an arbitrary

JAYPEE BROTHERS

volume of 1 L to 4 L of CO_2 or an arbitrary intraperitoneal pressure of 10–15 mm Hg.

High Pressure Entry (The HIP Entry)

The pressure technique has been adopted by many surgeons worldwide, but the appropriate volume to establish an appropriate intra-abdominal pressure remains controversial. Final pressures up to 10 mm Hg, 15 mm Hg, 14–18 mm Hg, 20 mm Hg, and even 25–30 mm have been advocated.

The rationale for the higher pressure entry technique is that it produces greater splinting of the anterior abdominal wall and a deeper intra-abdominal CO_2 bubble than the traditional volume-limited pneumoperitoneum of 2–4 L.

It has been determined that trocar insertion requires 4–6 kg of force, and shielded disposable trocars require half the force of reusable trocars.

It has been demonstrated that the use of transient high-pressure pneumoperitoneum causes minor hemodynamic alterations of no clinical significance.

OPEN LAPAROSCOPIC ENTRY OR HASSON TECHNIQUE

Hasson first described the open entry technique in 1971. The suggested benefits are prevention of gas embolism, of preperitoneal insufflation, and possibly of visceral and major vascular injury.

The technique involves using a cannula fitted with a cone-shaped sleeve, a blunt obturator, and possibly a second sleeve to which stay sutures can be attached. A small incision is made transversely or longitudinally at the umbilicus. The cannula is inserted into the peritoneal cavity with the blunt obturator in place. Sutures are placed on either side of the cannula in the fascia and attached to the cannula or purse-stringed around the cannula to seal the abdominal wall incision to the cone-shaped sleeve. The laparoscope is then introduced and insufflation is commenced.

The open technique is favored by general surgeons and considered by some to be indicated in patients with previous abdominal surgery, especially those with longitudinal abdominal wall incisions.

Most common of the major complications associated with access were bowel injuries. The risk of bowel injury was higher with the open technique than with closed technique, technique (0.09%).

DIRECT TROCAR ENTRY

The suggested advantages of this method of entry are the avoidance of complications related to the use of the Veress needle: failed pneumoperitoneum, preperitoneal insufflation, intestinal insufflation, or the more serious CO_2 embolism.

JAYPEE BROTHERS

Laparoscopic entry is initiated with only one blind step (trocar) instead of three (Veress needle, insufflation, trocar). The direct entry method is faster than any other method of entry however, it is the least performed laparoscopic technique in clinical practice today.

The technique begins with an infra-umbilical skin incision wide enough to accommodate the diameter of a sharp trocar/cannula system. The anterior abdominal wall must be adequately elevated by hand, and the trocar is inserted directly into the cavity, aiming towards the pelvic hollow. On removal of the sharp trocar, the laparoscope is inserted to confirm the presence of omentum or bowel in the visual field. A history of abdominal surgery was not associated with an increased risk of complications.

Sharp trocars are recommended for a direct insertion technique.

Direct insertion of the trocar is associated with less insufflation-related complications such as gas embolism, and it is a faster technique than the Veress needle technique.

Disposable-shielded Trocars

Disposable shielded "safety" trocars were introduced in 1984. These trocars are designed with a shield that partially retracts and exposes the sharp tip as it encounters resistance through the abdominal wall. As the shield enters the abdominal cavity, it springs forward and covers the sharp tip of the trocar. These trocars were intended to prevent the sharp tip from injuring intra-abdominal contents. Shielded trocars may be used in an effort to decrease entry injuries, however, there is no evidence that they result in fewer visceral and vascular injuries during laparoscopic access.

Radially Expanding Access System

Advantages of this system include elimination of sharp trocars, application of radial force, stabilization of the cannula's position (cannula does not slide in and out), avoidance of injury to abdominal wall vessels, and elimination of the need for suturing of fascial defects. Radially expanding trocars are not recommended as being superior to the traditional trocars. They do have blunt tips that may provide some protection from injuries, but the force required for entry is significantly greater than with disposable trocars.

Visual Entry Systems

Disposable Optical Trocars Optical/access trocars were introduced in 1949 and are popular among urologists. Two disposable visual entry systems are available that retain the conventional trocar and cannula push-through design: the Endopath Optiview optical trocar (Ethicon Endo-Surgery, Inc., Cincinnati, OH) and the VisiPort™ optical trocar (Tyco-United States Surgical, Norwalk, CT). These single-use visual trocars trade blind sharp trocars for

JAYPEE BROTHERS

a hollow trocar, in which a zero-degree laparoscope is loaded for the distal crystal tip to transmit real-time monitor images while transecting abdominal wall tissue layers.

Endopath Optiview Optical Trocar

This comprises a hollowed trocar and a cannula. When insufflation is complete, the Veress needle is withdrawn, and the subcutaneous fatty tissue is dissected off, using peanut sponges, to expose the white anterior rectus fascia. A 5-mm incision is then made with a scalpel to accommodate the visual trocar's pointed tip. The fascia is then divided between the stay sutures over a length of approximately 5 mm. During insertion, the stay sutures are pulled to lift the abdominal wall against the advancing trajectory and facilitate proper port site closure at the end of the operation. The cascade of generated entry images displayed on the monitor demonstrates level of penetration.

VisiPort™ Optical Trocars

The VisiPort™ optical trocar is a disposable visual entry instrument that comprises a hollow trocar and a cannula. When insufflation is complete, the Veress needle is withdrawn, and subcutaneous fatty tissue is dissected off, downward axial pressure is applied while activating the trigger. Then downward pressure is relieved, the trigger released, and the trocar tip position verified on the monitor again. This entry sequence is repeated until the peritoneal cavity is entered. The trigger is not fired until the exact anatomical position of the trocar tip is known. The push-through entry design requires significant perpendicular force to drive a trajectory across tissue planes with no means of avoiding trocar overshoot.

The VisiPort™ optical trocar comes in only one diameter and accommodates only a 10-mm laparoscope.

EndoTIP Visual Cannula

The endoscopic threaded imaging port, EndoTIP (Karl STORZ Endoscopy, Tuttlingen, Germany), is a reusable visual cannula system that allows real-time interactive port creation, when port-dynamics are archived, for recall and analysis.

The visual entry cannula system may represent an advantage over traditional trocars, as it allows a clear optical entry, but this advantage has not been fully explored. The visual entry cannula trocars have the advantage of minimizing the size of the entry wound and reducing the force necessary for insertion. Visual entry trocars are non-superior to other trocars since they do not avoid visceral and vascular injury.

In 2019, Cochrane review authors evaluated the benefits and risks of different laparoscopic entry techniques in gynecological and

JAYPEE BROTHERS

non-gynecological surgery. Systematic review authors included 57 randomized controlled trials with a total of 9865 individuals undergoing laparoscopy. There was insufficient evidence to show whether there were differences between groups in the rate of failed entry, vascular injury, or visceral injury, or in other major complications with the use of an open-entry technique in comparison to a closed-entry technique. Overall conclusion was that the evidence was insufficient to support the use of one laparoscopic entry technique over another. Researchers noted an advantage of direct trocar entry over Veress needle entry for failed entry. Most evidence was of very low quality; the main limitations were imprecision (due to small sample sizes and very low event rates) and risk of bias associated with poor reporting of study methods.

CONCLUSION

Many techniques have been introduced to eliminate laparoscopic entry complications; however, not a single technique has been proven to eliminate this complication. On comparing open and closed techniques, there is no difference in the incidence of visceral or vascular injury. Thus, to prevent and decrease complications of port entry, surgeons should continue to increase their knowledge of anatomy, their training, and their experience.

SUGGESTED READING

1. Ellison E, Zollinger RM, Jr (Eds.). Hasson open technique for laparoscopic access. Zollinger's Atlas of Surgical Operations, 10th edition. McGraw Hill. 2016. [online] Available from https://accesssurgery.mhmedical.com/content.aspx?bookid= 1755&sectionid=119128026 [Last accessed March, 2022]
2. Jain N, Sareen S, Kanawa S, Jain V, Gupta S, Mann S. Jain point: A new safe portal for laparoscopic entry in previous surgery cases. J Hum Reprod Sci. 2016;9(1):9-17.
3. Lee CL, Huang KG, Jain S, Wang CJ, Yen CF, Soong YK. A new portal for gynecologic laparoscopy. J Am Assoc Gynecol Laparosc. 2001 Feb 1;8(1):147-50.
4. Palmer R. Safety in laparoscopy. J Reprod Med. 1974;13:1-5.

JAYPEE BROTHERS

Printed in India

Available at all medical bookstores
or buy online at www.jaypeebrothers.com



JAYPEE BROTHERS
Medical Publishers (P) Ltd.
EMCA House, 23/23-B, Ansari Road,
Daryaganj, New Delhi - 110 002, INDIA
www.jaypeebrothers.com

Join us on facebook.com/JaypeeMedicalPublishers

Shelving Recommendation
OBSTETRICS & GYNECOLOGY

