rs.com, for detailed information on obstetrics & gynecology books, visit our website www.jaypeebrothers.com, for detailed information on obstetrics & gynecology boo

diginerve
A Jaypee Initiative
Your Guide at Every Step
Video Lectures | Notes | Self-Assessment
Scan to Know More

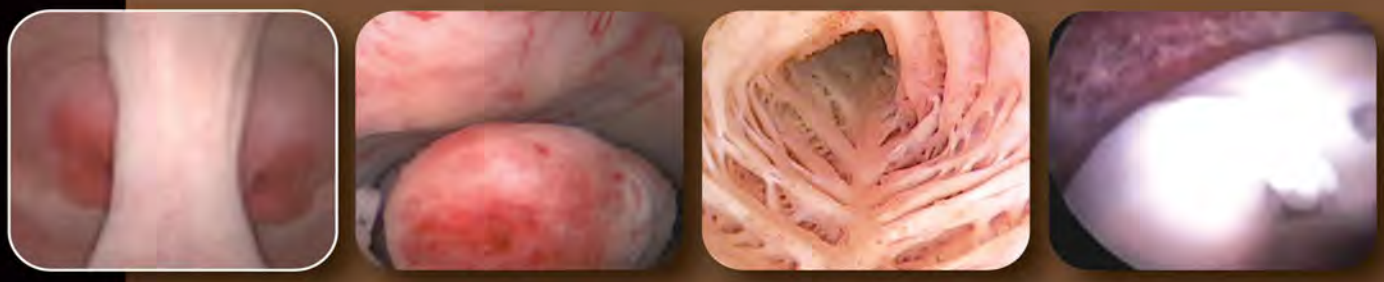

Mastering the Techniques in HYSTEROSCOPY

Access the videos by Scanning the **QR code** Inside.

Editors
Osama Shawki
Sushma Deshmukh
Luis Alonso Pacheco

2nd Edition

JAYPEE

Contents

Section 1: The Beginning with Hysteroscopy

1. Introduction: Hysteroscopy and Its Philosophy 3
Sushma Deshmukh
- Knowing about Hysteroscopy *3*
- Philosophy of Uterus and Hysteroscope *4*
- Let us Begin *4*
- Knowing Indications and Contraindications *5*
- What Facilities We Should Provide *7*
- Mastering the Technique *7*

2. History and Evolution of Hysteroscopy 8
Adam Magos
- The Foundations of Endoscopy *8*
- The Beginning of Endoscopy *9*
- The First Hysteroscopy *10*
- The Era of Modern Hysteroscopy *16*
- Final Words *18*

Section 2: Knowing the Uterus

3. Anatomy, Embryology and Hysteroscopy 25
Swati Shiradkar
- Anatomy of Uterus and Tubes *25*
- Changes in Uterus with Age and Parity *30*
- Positions of the Uterus *30*
- Embryology of Uterus and Tubes *31*

4. Physiology: The Uterus, Cervix and Practical Aspect 34
Manju P Jilla
- Hypothalamic-Pituitary-Ovarian Axis *34*
- Cervico-Uterine Changes at Birth, Puberty and Adult *35*
- Uterine Endometrial Histology *35*
- Receptors in the Uterus *37*
- Uterine Contractions *37*
- Cervix *38*
- Color Doppler Ultrasound and Utero-Ovarian Physiology *39*
- Applied Aspects *40*
- Cervix: Applied Aspects *41*

5. Histology and Hysteroscopic View of Normal Endometrium **44**
Rujuta Ayachit, Anuja Kulkarni
- Cyclic Histological Changes *44*
- Endometrial Dating *45*
- Atrophic Endometrium *45*
- Hysteroscopic Assessment of Endometrium *46*
- Traditional Classification of Hysteroscopic Appearance of Normal Endometrium *47*
- Atrophic (Postmenopausal) Endometrium *47*

6. Abnormal Endometrium and Hysteroscopy **50**
Suprita Nayak, Sushma Deshmukh
- Abnormal Endometrium *50*
- Endometrial Hyperplasia *50*
- Endometrial Polyp *52*
- Well-Differentiated Endometrial Carcinoma *53*
- Evaluation of Endometrium *54*

7. Effects of Drugs on the Uterus **60**
Sanjeev Khurd, Sadhana Khurd, Aditya Khurd
- Pharmacologic Principles in Hormone Action *60*
- Oral Contraceptive Pills *61*
- Hormone Replacement Therapy *61*
- Androgens *63*
- Gonadotropin-Releasing Hormone Analogs *64*
- Misoprostol *65*

8. How to Date Endometrium through Hysteroscopy without the Need of Biopsy **66**
Alicia Ubeda Hernandez
- Place of Endoscopic Techniques: Hysteroscopy *66*
- Endometrium Through Hysteroscopy *67*

Section 3: Imaging Technologies for Intrauterine Diagnosis

9. Hysterosalpingography for Intrauterine Diagnosis and Hysteroscopy **73**
Veerendra Kumar CM
- Scope of Hysterosalpingography *73*
- Techniques *73*
- Procedure *74*
- Intrauterine Diagnosis *76*
- Hysterosalpingography and Hysteroscopy—Diagnostic Fallacies and Comparative Studies *80*

10. Imaging Modalities for Assessment of Uterine Abnormalities **85**
Sonal Panchal, Chaitanya B Nagori
- Congenital Uterine Abnormalities *85*
- Acquired Uterine Abnormalities *91*

11. Ultrasonography 2D, 3D and Sonohysterography in Abnormal Uterine Bleeding and Correlation with Hysteroscopy **102**
Neema Acharya, Narendra Malhotra, Neharika Malhotra *102*
- Transvaginal Sonography *102*
- Role of 3D Ultrasound and 3D Saline Infusion Sonohysterography *102*
- Role of Hysteroscopy *104*

12. Beyond Ultrasound—Role of MRI in Uterine Imaging 106
Nilay S Nimbalkar, Parimal V Fuke, Prashant S Nimbalkar, Ravi Rajdeo, Rohit Gadewar
- Normal Uterine Anatomy *106*
- Uterine Leiomyomas *109*
- Intrauterine Synechiae *110*
- Adenomyosis *110*
- Carcinoma Endometrium *112*
- Uterine Anomalies *114*

Section 4: Hysteroscope and Its Gadgets

13. Instrumentation in Hysteroscopy 123
Sushma Deshmukh, Nagendra Sardeshpande, Jainesh Doctor
- Instrumentation *123*
- Hysteroscopes *123*
- Mechanical Instruments *126*
- Electrical Instruments *126*
- Delivery Systems for Fluid Medium in Hysteroscopy *129*
- Other Gynecological Instrumentation *130*
- Choice of Instrumentation *130*
- Maintenance and Sterilization of Instruments *131*

14. Optical Principles and Camera for Hysteroscope 133
Vasudeo Ridhorkar, Anuradha Ridhorkar
- Optical Principles for the Hysteroscope *133*
- Which Equipment to Buy? *138*

15. Distension Media and Fluid Management Machines 139
Rajesh Gajbhiye, Rakhi Gajbhiye
- Gaseous Media *139*
- Liquid Media *139*
- Mechanisms of Systemic Absorption *140*
- Managing Fluid Media *141*
- Recommendations *144*

16. Basics of Electrosurgery for Intrauterine Procedures: Monopolar and Bipolar 147
Atul Ganatra
- History *147*
- Basic Principles of Electrosurgery *147*
- Hysteroscopy *149*
- Managing Fluid Media in Electrosurgery *149*

17. Laser in Office Hysteroscopy 157
Sergio Haimovich
- Diode Laser *157*
- Hysteroscopic Findings and Technique Used *159*
- Septum *175*

18. How to Run Hi-Tech Hysteroscopy Unit 181
B Ramesh, Shraddha Daksha
- Operating Room Setup *181*
- Technique *182*

- Patient Selection and Preparation *182*
- Patient Positioning *182*
- Choice of Anesthesia *182*
- Instrumentation *183*
- Optical System *186*
- Office Hysteroscopy *187*
- Advanced Bipolar Versapoint (Gynecare Ethicon) *188*
- Diagnostic Hysteroscopy (The Standard Technique) *188*
- Operative Hysteroscopy *189*
- Distention Media and Delivery System *189*
- Energy Sources *191*
- Data Recording System *191*
- Complications *191*
- Updating and Maintaining *193*

Section 5: Hysteroscopy—Start with Basics

19. Diagnostic Hysteroscopy **197**
Nagendra Sardeshpande
- Indications *197*
- Contraindications *202*
- Types of Diagnostic Hysteroscopy *203*
- Instrumentation *203*
- Technique *205*
- Pathological Findings in Diagnostic Hysteroscopy *206*
- Difficulties *210*
- Complications *211*

Section 6: Office Hysteroscopy

20. Office Hysteroscopy: An Approach to Modern Gynecology **215**
Linda D Bradley
- Anatomic Considerations *223*

21. Ambulatory Hysteroscopy for All **225**
S Krishnakumar, Rohan Krishnakumar, P Kulkarni
- Indications for Ambulatory Hysteroscopy *225*
- Contraindications *225*
- Instrumentation *226*
- Ambulatory Hysteroscopy Room *230*
- Preparation and Positioning of the Patient (Including Consent) *231*
- Technique of Ambulatory Hysteroscopy *232*
- Anesthesia and Ambulatory Hysteroscopy *234*
- Ambulatory Operative Hysteroscopy (See and Treat Clinics) *235*
- Hysteroscopically Targeted Biopsy *235*
- Synechiae and Septae *235*
- Removal of Foreign Bodies *235*

- Polypectomy *236*
- Myomectomy *236*
- Complications in Ambulatory Hysteroscopy *237*

22. Hysteroscopy in Adolescents **239**
Milind A Telang, Ridhi Desai
- Developmental Changes of the Uterus and Cervix in Adolescents *239*
- Procedure of Vaginoscopic Method of Hysteroscopy *242*
- Technique of Diagnostic Hysteroscopy *243*

23. Office Hysteroscopy in Climacteric Women **245**
Carlos Gerardo Salazar Lopez Ortiz, Gonzalo de Jesús Siu Moguel, José Carlos Salazar Trujillo, Ana Paula Vázquez Alvarado
- Atrophy *248*

24. Hysteroscopy in the Diagnosis and Treatment of Cervical Lesions **251**
Attilio Di Spiezio Sardo, Gloria Calagna, Linda Tebache, Brunella Zizolfi, Ursula Catena, Carmine Nappi
- Nabothian Cysts *251*
- Cervical Polyps *251*
- Cervical Synechiae *254*
- Rare Lesions *255*
- Congenital Anomalies *258*
- Ectopic Cervical Pregnancy *260*
- Precancerous Lesions *261*
- Cervical Adenocarcinoma *264*

Section 7: Hysteroscopy and Congenital Uterovaginal Anomalies

25. Uterine Malformations—General Review **273**
Marco Gergolet
- Embryology *273*
- Classification *273*
- Epidemiology *275*
- Clinical Behavior Before and After Surgery *276*
- Diagnosis *276*
- Treatment *277*

26. Uterine Septum **279**
Luis Alonso, Miguel Rodrigo, Raquel Duarte
- Embryology *279*
- Incidence *279*
- Structure *280*
- Classification *281*
- Reproductive Impact of Septate Uterus *281*

27. Lateral Metroplasty **294**
Kedar N Ganla, Sanket Pisat, Rana Choudhary
- Incidence and Prevalence *294*
- Classification of Uterine Anomalies and the Place of T-Shaped Uterus *294*
- Diagnosis of T-Shaped Uterus *295*
- Management of T-Shaped Uterus—Hysteroscopic Diagnosis and Correction *297*

- Diagnostic Hysteroscopy and Primary Assessment *298*
- Hysteroscopic Outpatient Metroplasty to Expand Dysmorphic Uteri Technique *299*

28. Uncommon Malformations—A Rare Case of Robert's Uterus and Its Surgical Management **303**
Vivek Salunke, Shinjini Pande
- Case Review and Our Surgical Management *303*

29. Role of Endoscopy in Vaginal Septum **310**
Pankaj Mate
- Prevalence *312*
- Clinical Presentation *312*
- Diagnosis *313*
- Management *314*
- Postoperative Care *316*
- Complications *316*

Section 8: Polyps, Fibroids and Hysteroscopy

30. Hysteroscopy and Polyps **321**
Rohini S Deshpande
- Polyps Prevalence, Predisposing Factors *321*
- Clinical Presentation *321*
- Role of Transvaginal Ultrasound in the Diagnosis of Intracavitary Polyps *321*
- Hysteroscopic Diagnosis of Polyps and Its Management *322*
- Endometrial Polyps and Infertility *324*
- Polyps and Abnormal Uterine Bleeding *325*
- Hysteroscopy in Polyps: Technical Details *325*
- Take Home Message *327*

31. Dealing with Submucous Myoma **329**
Rakesh Sinha, Shweta Raje, Gayatri Rao
- History *329*
- Myoma Classification *329*
- Diagnosis of Submucous Leiomyomas *330*
- Preprocedural Preparation: Suppressive Medical Therapy Before Hysteroscopic Myomectomy *331*
- Surgical Techniques for Removal of Submucous Myomas *331*
- Laparoscopic Management of Large Submucous Myomas *334*
- Fluid Overload During Hysteroscopy *334*
- Other Complications *336*
- Surgical Outcome *337*

32. Hysteroscopic Myomectomy—Impact of Size of Submucous Myoma and MyoSure **339**
Candice P Holliday, Rajesh Paladugu, Botros Rizk
- Pathophysiology *339*
- Classification *340*
- Clinical Presentation *340*
- Diagnostic/Presurgical Evaluation *342*
- Indications for Hysteroscopic Myomectomy *344*
- Treatment *344*

- Outcomes *346*
- Complications *347*

33. Management of Submucous Myomas with the Intrauterine Bigatti Shaver **349**
Giuseppe Bigatti
- History of the Equipment *349*
- Results *352*
- Discussion *352*
- Future Development *358*

34. Cold Loop Hysteroscopic Intracapsular Myomectomy: A Safe and Effective Myometrial Sparing Treatment **361**
Mazzon Ivan, Favilli Alessandro, Sandro Gerli
- Rationale *361*
- Instruments *362*
- Preoperative Assessment and Treatment *362*
- Technique *363*
- Intraoperative Complications *364*
- Postsurgical Outcome and Intracavitary Adhesions Rate—The Role of Diagnostic Hysteroscopy Follow-Up *365*
- Feasibility *366*
- Pregnancy Outcomes *366*

Section 9: Hysteroscopy in Abnormal Bleeding

35. Hysteroscopy and Dysfunctional Uterine Bleeding **371**
PG Paul, Aditya S Khurd, Radhika KT, Saumya Bulusu, George Paul
- Palm-Coein Classification for Abnormal Uterine Bleeding *371*
- Diagnosis of Dub *371*
- Management of Dysfunctional Uterine Bleeding *372*

36. Hysteroscopy in Adenomyosis **376**
Alejandro M Gonzalez
- Basic Structure and Function of Endometrium *377*
- Pathogenesis-Physiopathology *378*
- Epidemiology *379*
- Risk Factors *379*
- Pathological Anatomy *380*
- Clinical Presentation *381*
- Forms of Presentation *381*
- Diagnosis *382*
- Treatment *385*
- Role of Hysteroscopy *389*

37. Hysteroscopy in Acute Uterine Bleeding **395**
Alejandro M Gonzalez
- Scientific Evidence *396*
- Medical Treatment in Acute Uterine Bleeding *397*
- Role of Hysteroscopy *398*
- Surgical Technique *398*

38. Transcervical Resection of the Endometrium with Hysteroscopy 405
Neeta Warty, Parul Shah, Rajkishor Sawant
- Patient Selection *405*
- Indications *405*
- Contraindications *405*
- Set-up *405*
- Preoperative Investigations *406*
- Instrumentation *406*
- Procedure *406*
- Complications *408*
- Postoperative Care and Follow-Up *409*
- Evidence *409*

39. Classification of Microhysteroscopic Images 410
Jorge E Dotto, Miguel A Bigozzi
- Hysteroscopy Techniques *410*
- Classification of Hysteroscopic Images *410*

40. Endometrial Metaplasias 422
Luis Alonso Pacheco
- Epithelial Metaplasias *422*
- Stromal Metaplasias *424*

Section 10: Intrauterine Adhesions

41. Uterine Synechiae 431
Ricardo Bassil Lasmar, Bernardo Portugal Lasmar, Daniela Baltar da Rosa Zagury
- Etiology *431*
- Diagnosis and Clinical Correlation *432*
- Investigations *433*
- Classification *434*
- Management *435*
- Postoperative Prevention of Relapse *436*

42. Innovative Alternatives in the Postoperative Management of Asherman Syndrome 438
Jaime Ferro, Pedro Montoya
- Preventing the Recurrence of Adhesions *439*
- Restoring the Normal Endometrium *444*
- Postoperative Assessment *444*

Section 11: Hysteroscopy and Infertility

43. Hysteroscopy and Infertility 449
José Metello, José Jiménez
- Normal Endometrium and Window of Implantation *449*
- Polyps *450*
- Fibroids *459*

- Uterine Septum *462*
- Intrauterine Adhesions *468*
- Prevention *476*
- Tubal Ligation *477*
- Diagnostic Hysteroscopy *479*
- Chronic Endometritis *479*
- Hysteroscopic Proximal Tubal Catheterization *481*
- Adenomyosis *482*
- Cesarean Scar *484*

44. Hysteroscopy Guided Transuterine Cannulation for Treatment of Proximal Tubal Blocks Using an Innovative Technique **500**
Gautam Nand Allahbadia, Swati Gautam Allahbadia, Akanksha Gautam Allahbadia
- Clinical Discussion *500*

45. Hysteroscopic Embryo Transfer **508**
Parul Kotdawala, Shalini Gainder
- Technique for Hysteroscopic Subendometrial Embryo Delivery (Kamrava M) *509*
- Technique of Hysteroscopic Embryo Delivery (Kamrava M) *509*
- Advantages of Hysteroscopic Embryo Transfer *510*
- Disadvantages *510*

Section 12: Intrauterine Foreign Bodies and Hysteroscopy

46. Intrauterine Foreign Bodies Other than Cu-T and Hysteroscopy **515**
E Cayuela Font, Ayuso Thorell, L Acín, P Zarco, M del Río
- Intrauterine Devices *515*
- Chinese Intrauterine Devices or Stainless Steel Ring Intrauterine Device *516*
- Pregnancy with Intrauterine Devices *517*
- Laminaria *518*
- Osseous Metaplasia *519*
- Suture Material *520*
- Unknown Material *520*

47. Hysteroscopic Retrieval of Lost Intrauterine Devices **522**
Kedar Padte
- Levels of Lost Intrauterine Contraceptive Device *522*
- Methods of Retrieval of Lost Cu-T Device *523*
- Instrumentation *523*
- Complications *526*

Section 13: Hysteroscopy in Obstetrics and Gynecology in Different Situations

48. Hysteroscopic Management of Cervical Ectopic Pregnancy **531**
Nozer Sheriar
- Historical Antecedents *531*
- Predisposing Factors *531*
- Diagnosis of Cervical Ectopic Pregnancy *531*

- Management Modalities *531*
- Hysteroscopic Management *532*
- Personal Experience *533*
- The Potential of Hysteroscopic Management *534*
- Fertility After Cervical Ectopic Pregnancy *536*

49. Diagnostic and Operative Hysteroscopy for Pelvic Pain **538**
Nash S Moawad, Estefania Santamaria
- Hysteroscopic Management of Common Conditions Implicated in Pelvic Pain *538*
- Vaginoscopy for Conditions Implicated in Pelvic Pain *544*

50. Hysteroscopic Guidance in Obstetric Procedures **547**
Charles E Miller, Courtney Steller
- First Trimester Missed Abortion and Embryoscopy *547*
- Retained Products of Conception *549*
- Cesarean Section Scar or Isthmocele *551*
- Cesarean Section Scar Ectopic Pregnancy *552*
- Other Uses of Hysteroscopy in Obstetrics *553*

51. Uterine Scar after Cesarean Section: A Multimodal Evaluation and Treatment **558**
Malvasi Antonio, Resta Leonardo, Sparić Radmila, Kadija Sasa, Ospan A Mynbaev, Imperatore Alberto, Tinelli Andrea
- Importance of Evaluation *558*
- An Appraisal on Various Modalities to Evaluate the Postcesarean Scar *563*
- The Role of Hysteroscopy *566*

52. Hysteroscopic Correction of Isthmocele **572**
Giampietro Gubbini, Lorenzo Goglia, Pasquale Florio
- Reason to Treat Isthmocele *572*
- Results *573*
- Repair of Isthmocele: Isthmoplasty *574*
- Hysteroscopic Complications *576*

Section 14: Hysteroscopy and Tubal Sterilization

53. Scope of Hysteroscopy in Family Planning **581**
Laura Nieto Pascual, José Eduardo Arjona Berral
- Advantages of Female Hysteroscopic Sterilization *581*
- Historical Use of Hysteroscopy in Family Planning *582*
- Confirmation of Obstruction After Occlusion Tubal Hysteroscopic *584*

54. Hysteroscopic Methods of Sterilization Nowadays: Essure Device **587**
Laura Nieto Pascual, José Eduardo Arjona Berral
- Device and Mechanism of Action *587*
- Contraindications *587*
- Preparation of the Patient Prior to Procedure *587*
- Procedure Description *588*
- Tips for Placement of the Essure Device *589*
- Confirmation Test after Placement *593*
- Complications During the Procedure *593*
- Complications after the Procedure *596*

- Our Experience with Essure Device *597*
- Current Status of Essure *597*
- Removing Essure Devices *598*
- Female Hysteroscopic Sterilization in the Future *598*

Section 15: Endometrial TB and Hysteroscopy

55. Hysteroscopic Markers in Endometrial Tuberculosis and Chronic Endometritis **603**
Alka Kumar, Atul Kumar
- Hysteroscopic Markers in Endometrial Tuberculosis *603*
- Hysteroscopic Markers for Chronic Endometritis *605*

56. Role of Hysteroscopy in Endometrial Infections **608**
Sandhya Saoji, Nitin Shinde
- Etiological Agents *608*
- Diagnosis *608*
- Diagnosis of Organisms Not Transmitted Through Sexual Route *610*
- Diagnosis of Tuberculosis in Endometrial Infections *610*

Section 16: Hysteroscopy as a Complimentary

57. Hysteroscopy as a Complimentary to Laparoscopy **615**
Ibrahim Alkatout, Liselotte Mettler
- Hysteroscopy *617*
- Laparoscopy *619*
- Hysteroscopic Training Models *638*

58. Hysteroscopy as a Complimentary with Falloposcopy **649**
Haresh Vaghasia
- Instrumentation and Technique *649*
- Procedure *649*
- Indications *650*
- Findings and Interventions *650*
- Complications *651*
- Limitations *651*

59. Hysteroscopic Embryoscopy **652**
Tirso Perez-Medina, Mar Rios, Laura Calles
- Development of the Technique *652*
- Material and Methods *653*
- Findings *653*
- Indications for Transcervical Embryoscopy *658*

Section 17: All about Difficulties in Hysteroscopy

60. Complications of Hysteroscopy **663**
Aswath Kumar, Hambal Ahmed
- Classification of Hysteroscopic Complications *663*
- Immediate Complications *663*

- Vasovagal Syndrome *664*
- Gas Embolism *664*
- Media-Related Complication *664*
- Late/Delayed Complication *665*

61. Difficulties in Negotiating Hysteroscope to Reach Uterine Cavity **666**
Rahul Manchanda
- External Cervical Orifice *666*
- Cervical Canal *666*
- Internal Cervical Orifice *666*
- External Cervical Orifice *666*
- Cervical Canal *667*
- Internal Cervical Orifice *668*

Section 18: Anesthesia in Hysteroscopy

62. Nerve Supply to the Uterus and Methods of Anesthesia **673**
Vinod Kumar, Janesh Gupta, Akanksha Sood
- Nerve Supply to the Uterus *673*
- Methods of Anesthesia *673*

63. Precautions for Hysteroscopy from Anesthesiologist's Point of View and Management of Crisis **677**
BM Rajurkar, Archana Munishwar
- Preoperative Evaluation *677*
- Complications of Operative Hysteroscopy *679*

64. Pain Management for In-Office Hysteroscopy **684**
Gray B, Jose Tony Carugno
- Anatomy and Pain Physiology *684*
- Factors Affecting Pain *685*
- Pain Management Options *687*

Section 19: Hysteroscope—An Expanding Scope

65. What is New in Hysteroscopy? **697**
Mykhailo V Medvediev, Julia Davydova
- Office Hysteroscopy *698*
- New Energies in Hysteroscopy *701*
- Hysteroscopic Mechanical Morcellation *702*
- Hysteroscopic Tubal Sterilization *703*
- Endometrial Ablation "Without" Hysteroscopy *705*

Section 20: Hysteroscopy, You and Other Aspects

66. Maintenance and Sterilization of Hysteroscopic Instruments **713**
Rajesh V Darade, Manoj S Parbat
- Maintenance of Hysteroscopic Instruments *713*
- Maintenance after Surgery *716*

67. Controversies and Misleading Facts in Hysteroscopy **718**
Rajendra Tiwari, Sanjay B Patil, Mausami Parpillewar
- Indications of Hysteroscopy *718*
- Where and Why Controversy? *719*
- Dysfunctional Uterine Bleeding *721*
- Role of Hysteroscopy and Its Controversies in Endometrial Carcinoma *721*
- Does Hysteroscopy Disseminate Endometrial Cancer Cells? *722*
- Are Disseminated Cancer Cells Viable? *722*
- Studies and Discussions *723*
- Few Studies on Ablation Techniques *723*
- Studies on Endometrial Carcinoma and Hysteroscopy *723*
- Conclusion *723*
- Misleading Facts in Hysteroscopy *724*
- Pitfalls in Uterine Cavity Assessment *724*
- Pitfalls in Lesions in Endometrial Cavity *725*
- Pitfalls in Congenital Malformation of Uterus *725*

68. Medicolegal Aspects of Hysteroscopy **726**
Girish Kumthekar
- Hysteroscopy *726*
- Consent *726*
- Procedure *726*
- Complications *727*
- Possibility of Litigation *727*

Section 21: Tips and Tricks

69. Technical Tricks in Dealing with Hysteroscope **733**
Sanjay Makwana
- Preprocedure Setting *733*
- Miniaturized Rigid and Flexible Hysteroscopes *733*
- Oval Profile Rigid Hysteroscopes *733*
- Saline Solution as a Distension Medium *733*
- Vaginoscopy *734*
- Tricks for Overpassing Cervical Stenosis *734*
- Distension Media *734*
- Intravasation *735*
- Guidelines to Reduce Complications While using Electrosurgery *735*
- Tips to Reduce Complications While Septum Resection *736*

70. Tips and Tricks to Revolutionize the Hidden Art of Intrauterine Surgery **738**
Osama Shawki
- Set-up and General Considerations *738*
- Diagnostic Procedures *739*
- Additional Thoughts *743*

Index *745*

SECTION 2

Knowing the Uterus

3. Anatomy, Embryology and Hysteroscopy
4. Physiology: The Uterus, Cervix and Practical Aspect
5. Histology and Hysteroscopic View of Normal Endometrium
6. Abnormal Endometrium and Hysteroscopy
7. Effects of Drugs on the Uterus
8. How to Date Endometrium through Hysteroscopy without the Need of Biopsy

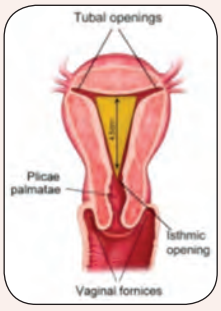

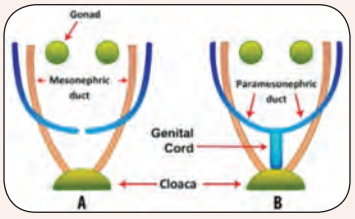

To know hysteroscopy

Understand uterus thoroughly

Learn embryology, anatomy

Remember practical aspects of physiology

Study normal/abnormal endometrial histology

Dating of endometrium, one should study.

Then get ready to apply.

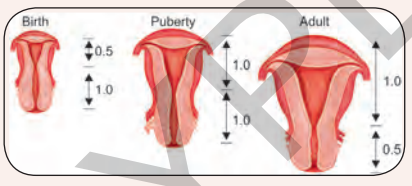



Sushma Deshmukh

JAYPEE BROTHERS

CHAPTER 03

Anatomy, Embryology and Hysteroscopy

Swati Shiradkar

INTRODUCTION

Female reproductive system comprises of gonads (ovaries), reproductive tract (fallopian tubes, uterus, and vagina), and external genitalia. External genitalia, vagina, and vaginal portion of cervix can be directly examined during physical examination for any abnormality. On the other hand, ovaries, tubes, and uterus are situated deep inside pelvis. Therefore, finger of examining doctor was the only way to inspect their abnormalities without opening the abdomen, before the noninvasive imaging techniques or laparoscopy were invented. Ultrasonography, aptly known as third eye of obstetrician and gynecologist along with other imaging techniques are noninvasive indirect ways which can help in diagnosis. Laparoscopy is direct way for diagnosis and treatment as well, but unlike hysteroscopy, it cannot visualize inside of uterus. Hence, hysteroscopy has a special place in diagnosis and treatment of uterine and to some extent tubal disorders in association with imaging and laparoscopy. It uses natural opening, i.e. cervix to enter, making diagnostic hysteroscopy an office procedure unlike diagnostic laparoscopy.

Uterus is very important functioning end-organ in female reproductive system. When one wants to start the journey of uterine cavity with the help of hysteroscope, it is mandatory that one should know the organ, its origin, its relation with adjacent organs and possible deviations from normal path in detail so as to make use of this journey for diagnosis and treatment fruitful. Purpose of this topic is to go through anatomy and embryology of female internal genitalia, mainly uterus and fallopian tubes as prerequisite to be a hysteroscopy expert. This chapter provides an overview of clinically significant issues in structure of uterus and tubes, how they develop and the developmental abnormalities.

ANATOMY OF UTERUS AND TUBES

Uterus is a pear-shaped muscular organ with cavity situated in female pelvis between bladder anteriorly and rectum posteriorly. Its size changes depending on the phase of female's life, such as before and after puberty, during and after pregnancy, in nulliparous and multiparous, before and after menopause. Typical size of nonpregnant uterus during reproductive years is 7–8 cm in length, 5 cm in width in upper part and 2.5 cm in lower part and 4 cm in thickness. It weighs 30–40 g and the volume is 80–200 mL. It communicates with peritoneum through tubes and to vagina through cervix.

It is divided into three parts (1) fundus, (2) body, and (3) cervix (Fig. 1). The part above the openings of fallopian tubes is called as fundus. The part below is body of uterus till a constriction on outer surface (called isthmus) which corresponds to internal os. Below that level till opening in vagina is cervix. It is suspended with the help of ligaments making angle between body and cervix (flexion) and with vagina (version) (Fig. 1). More commonly fundus is pointing anteriorly (anteverted, anteflexed), sometimes posteriorly (retroverted, retroflexed). This position can change physiologically because of full bladder or rectum and pathologically because of infection, tumors or weakness of ligaments. It is important to know the position before entering the cavity to avoid injury.

The anterior surface of uterus is in relation with bladder, posterior with sigmoid colon. There are coils of small

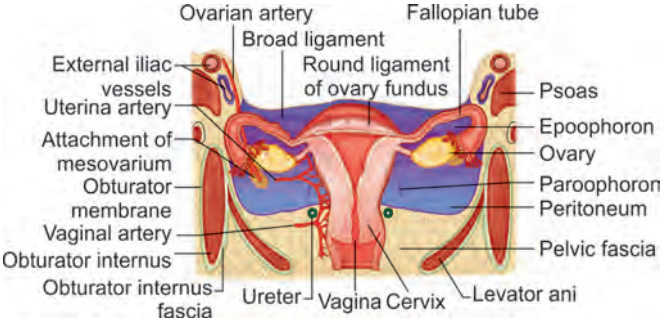

Fig. 1: Parts of uterus.

JAYPEE BROTHERS

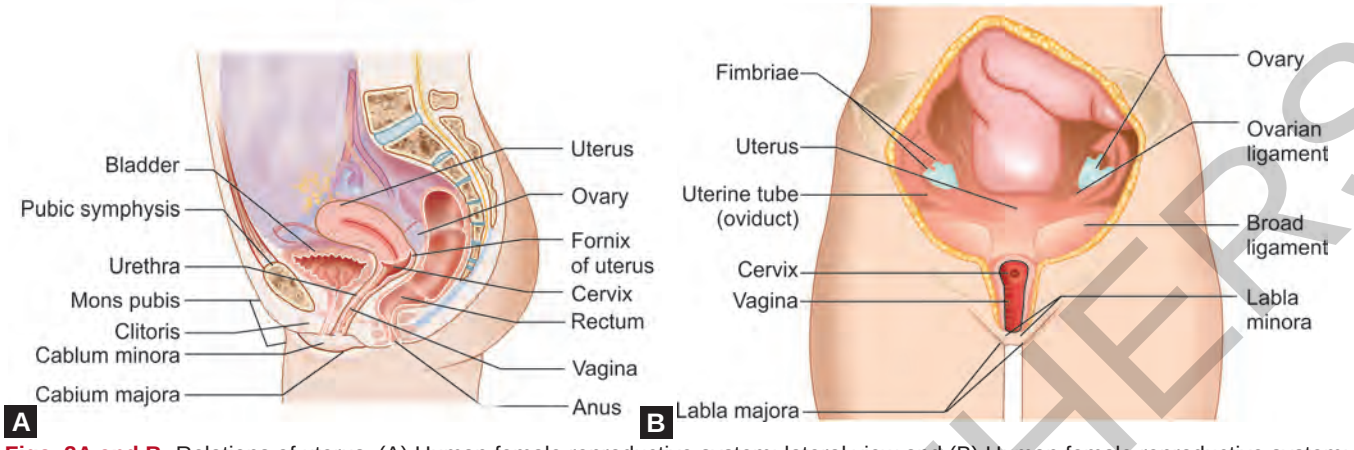

Figs. 2A and B: Relations of uterus. (A) Human female reproductive system: lateral view and (B) Human female reproductive system: anterior view.

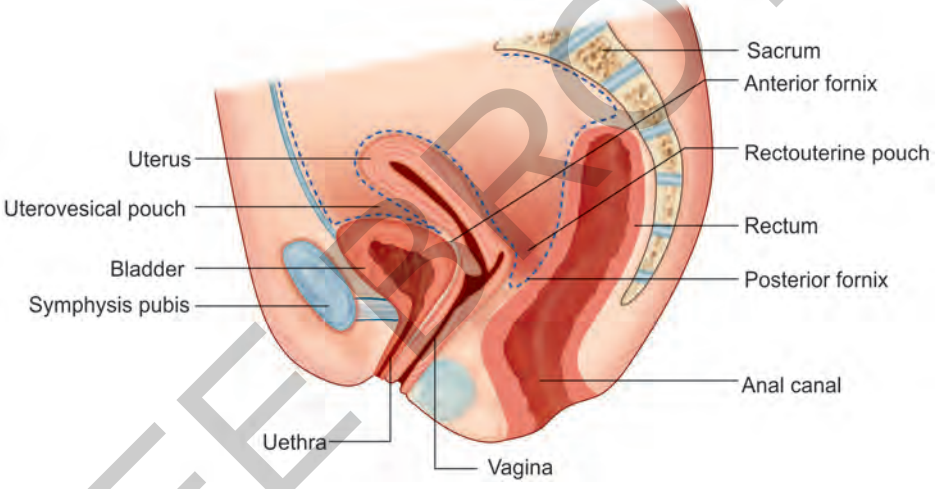

Fig. 3: Peritoneal covering.

intestine in relation to fundus. Laterally there are tubes, round ligaments, and ovaries on either sides (Figs. 2A and B).

The organ is having three layers: (1) serosa, (2) myometrium (muscle), and (3) endometrium (internal lining).

Serosal Layer

Serosa is visceral peritoneum forming outermost coat. It completely covers fundus, body, and cervix posteriorly while reflects on posterior surface of bladder from level of isthmus anteriorly making cervix devoid of it. On the fundus and body, this layer is firmly attached while on post aspect of cervix it is loosely attached. These twofolds of peritoneum (broad ligaments) cover tubes and round ligaments on both sides and then reflect on pelvic walls (Fig. 3).

Muscular Layer

Muscle mass of uterus is unique. It has three layers of smooth muscles. The outermost is longitudinal in nature. It covers isthmus, body, and fundus. In intermediate layer, the fibers are arranged in crisscross manner. They are predominant in body and fundus. They act as living ligatures around blood vessels traversing through them, controlling blood loss during menstruation and delivery. The innermost layer is made of circular muscle fibers, which

JAYPEE BROTHERS

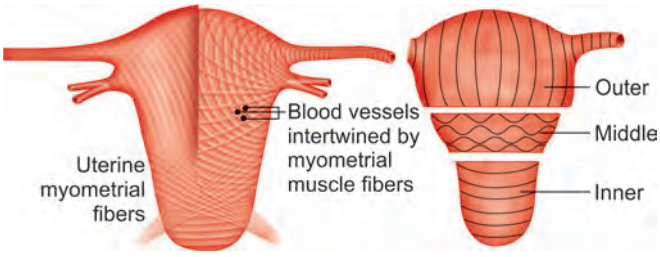

Fig. 4: Muscular layer.

is predominant in cervix and cornual portion of fallopian tubes (Fig. 4). The muscle cells increase in number and size during pregnancy so as to accommodate the growing fetus. During labor and puerperium, along with contraction, there is retraction, i.e. permanent shortening of muscle cells leading to expulsion of products of conception and decrease in size of uterus. Cervical muscle fibers also work in such a way that the canal is closed during pregnancy to retain the fetus. It opens because of upward and outward pull of longitudinal fibers attached to circular fibers of cervix. The canal again closes after uterus is empty. Just imagine if these properties were absent, the life of females would have been so miserable carrying uterus of full term size throughout her life after first delivery without a second chance! Nature has created such a wonderful organ. Let us understand its wonders further.

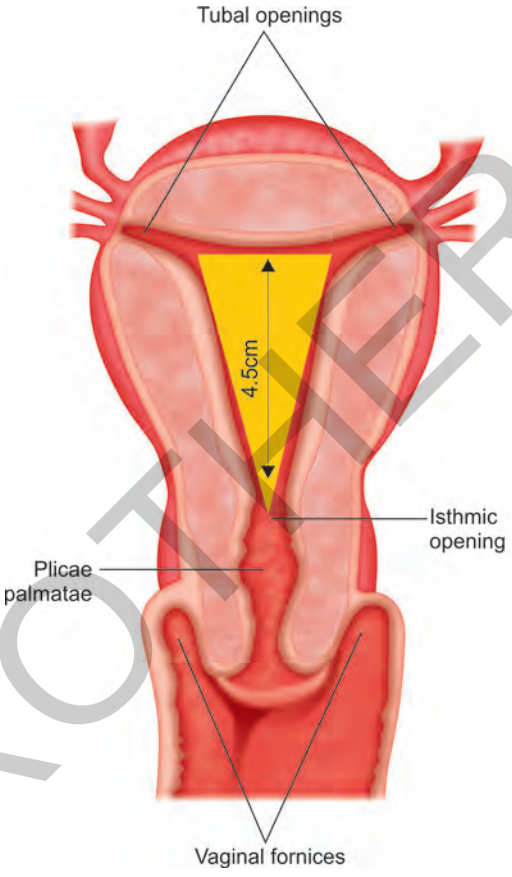

Fig. 5: Uterine cavity seen as inverted triangle.

Endometrium Layer

Cavity of nonpregnant uterus is anteroposteriorly flat making shape "H" in cross section, indicating need to instil fluid while doing various procedures like hysteroscopy to visualize it. The uterine cavity is triangular in shape, when seen from the front, the length is approximately 4–5 cm and the lumen communicates with the lumina of the two fallopian tubes at the two cornua and with the vagina through endocervical canal at the internal os. Uterine cavity is no more than a slit when seen from side (Fig. 5).

The lining of cavity, i.e. endometrium is a specialized lining having two layers, basal and functional. Basal layer is responsible for regeneration of endometrium after each menstruation. Damage to this layer by infection or instrumentation can lead to impaired formation of functional layer. The raw surface then may lead to adhesion between surfaces of cavity, a condition known as Asherman's syndrome. Functional layer is having capacity to undergo various changes in response to estrogen and progesterone hormones during reproductive phase of life (Figs. 6A to C). It is lined by ciliated columnar epithelium which looks pale red having orifices of tubular endometrial glands when seen under magnification. These tubular glands are arranged perpendicular to surface and supported by specialized stroma, which is also responsive to the hormones. These glands synthesize and secrete substances essential for survival and development of fetus. The functional layer of endometrium along with stroma is responsible for successful implantation and continuation of pregnancy. Cervical epithelium is cylindrical ciliated with numerous ridges in upper two-thirds. This epithelium is also having effect of hormones on its secretion. The epithelium lower down loses cilia and gradually changes to stratified squamous. This change is also affected by estrogen.

Isthmus

The isthmus is an annular zone which lies between the cervix and body of uterus also called the lower uterine

JAYPEE BROTHERS

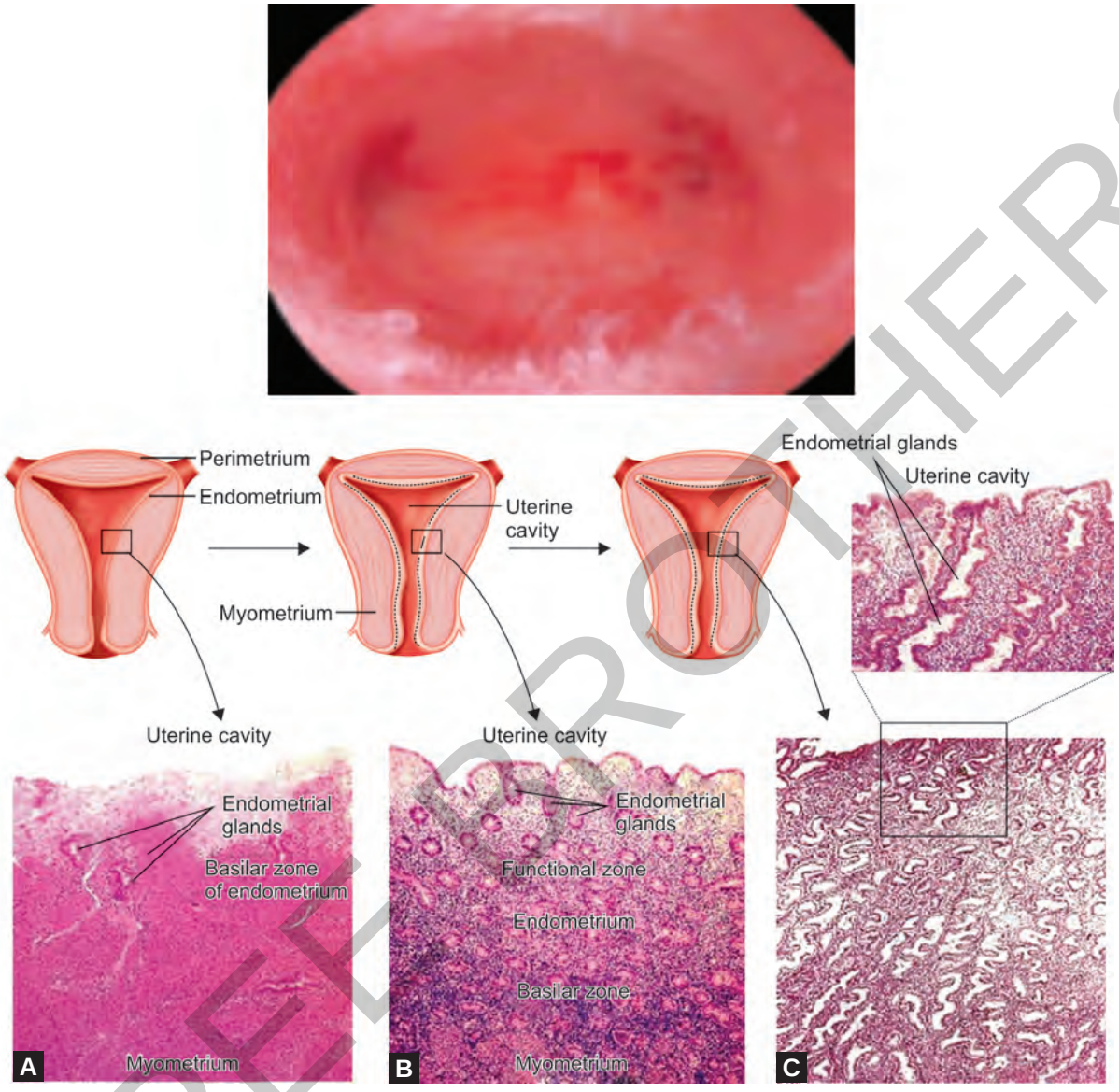

Figs. 6A to C: Cyclical endometrial changes: (A) Menses (B) Proliferative phase (C) Secretory phase.

segment. It corresponds to the level of the internal os of the cervix. It is around 0.5–1 cm in length and very narrow in nulliparous woman. The mucosa is smooth compared to the highly folded endocervix.

Cervix

The cervix is cylindrical in shape measuring 2.5–3.5 cm in height and 2 cm in diameter. Half of the cervix projects into the vagina (portio vaginalis) while half is above vaginal attachment (supravaginal cervix). The terminus of the cervix is round and has a circular or transverse opening; the external os. There are two lips, the anterior shorter and thicker and posterior which is longer and thinner.

The upper part of the cervix is composed mainly of involuntary muscle, many of the fibers being continuous with those in the corpus. The lower half has a thin peripheral layer of muscle (the external cervical muscle) is otherwise entirely composed of fibrous and collagenous tissues.

The mucous membrane lining the canal (endocervix) is thrown into folds which consist of anterior and posterior columns from which radiate circumferential folds to give the appearance of tree trunk and branches, hence the

JAYPEE BROTHERS

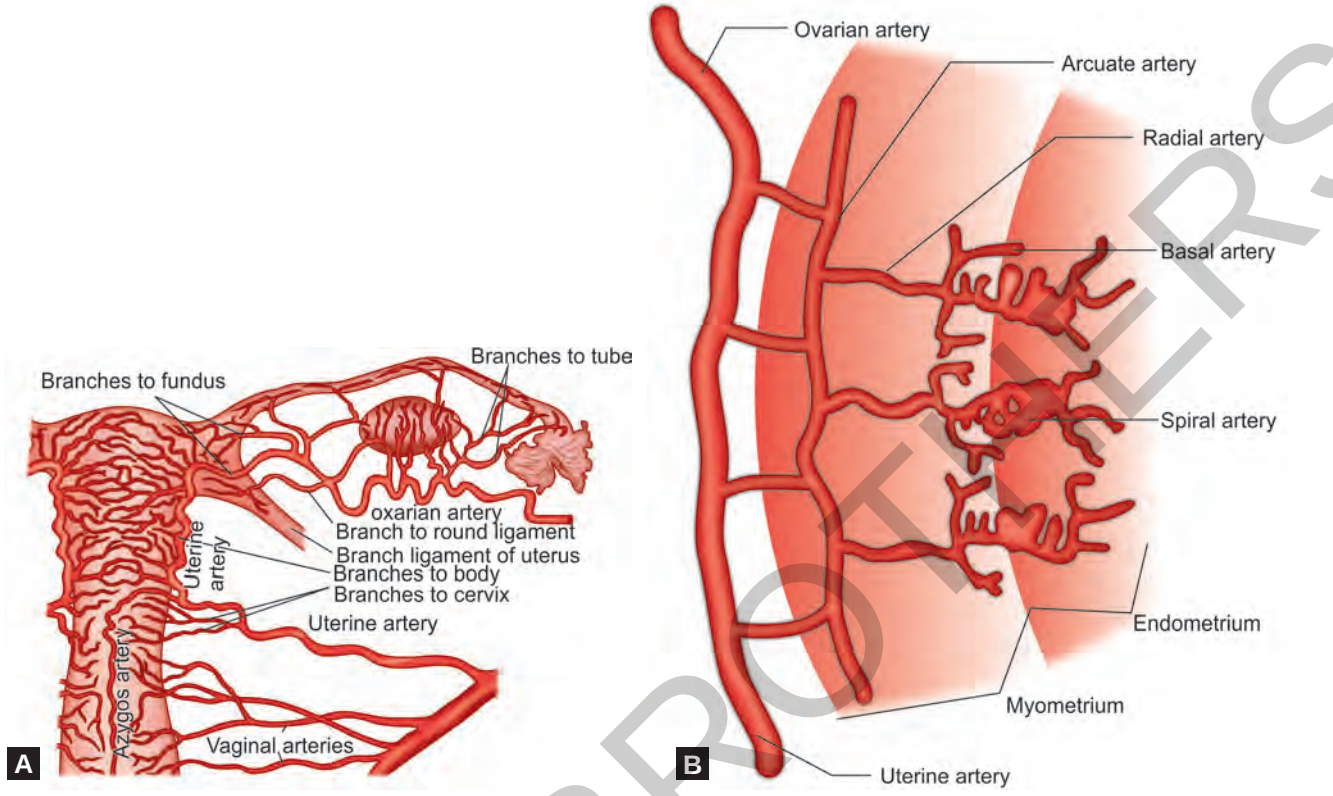

Figs. 7A and B: Blood supply.

name arborvitae (Fig. 3). The irregularity of surface can make the passage of sound difficult in young nulliparous women. The endocervix is covered by a single layer of tall columnar epithelium. The mucosa is whitish pink and deeply clefted to form the plicae palmatae. Retention cysts are frequently visible within the canal. The vaginal part of cervix is covered with the squamous epithelium continuous with that of the vagina.

Blood Supply

Main blood supply to uterus is through uterine arteries, branches of internal iliac. The ovarian arteries, after supplying ovaries and tubes also anastomose with uterine artery. After traversing through base of broad ligament across the ureter, uterine artery enters uterus laterally near isthmus. It gives circumferential branches throughout body of uterus called as arcuate arteries. They give branches called as radial arteries as they travel perpendicular to muscles. Radial arteries give two types of branches: (1) basal, supplying basal layer of endometrium and (2) spiral, supplying functional layer. Spiral arterioles are responsive to hormones (Figs. 7A and B). For example, they proliferate because of estrogen and dilate, coil because of progesterone.

Nerve Supply

Sympathetic supply is through T5, T6 (motor), and T10, T11, T12, and L1 (sensory). Parasympathetic is via S3 and S4. Both reach uterus through branches of inferior hypogastric plexus. We should remember that cervix and body is relatively insensitive to touch, cut and burn, but holding and dilating cervix as well as distending cavity while doing hysteroscopy causes pain.

Lymphatics

Primary drainage is in parametrial nodes, after which cervix drains in obturator, internal iliac and external iliac nodes. Body drains in sacral and external iliac nodes. External genitalia drain in inguinal group of nodes. All lymphatics from pelvis then goes to common iliac nodes to reach lumbar group of aortic nodes (Fig. 8).

JAYPEE BROTHERS

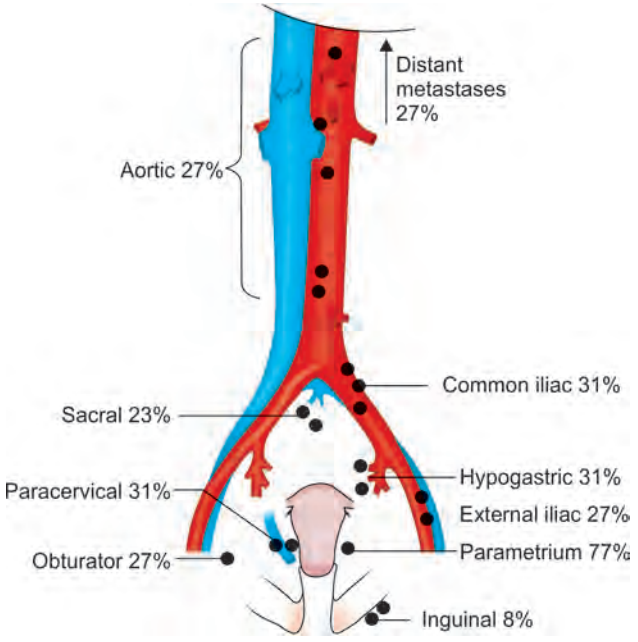

Fig. 8: Lymphatics.

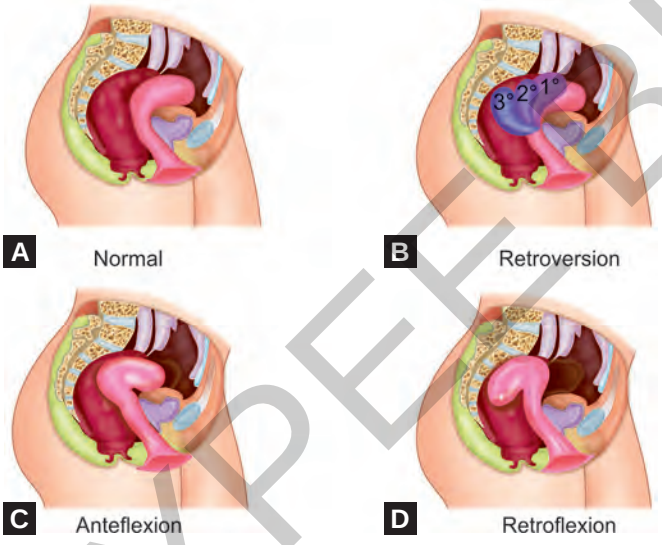

Figs. 10A to D: Positions of uterus: normal position of the uterus is anteverted on the bladder. Other variations are retroversion, anteflexion, and retroflexion.

Fallopian Tubes

Fallopian tubes are two in number, one each at superior angle of uterus, in upper margin of broad ligament. The average length is 10 cm which is divided into three parts. Near uterine cornu is isthmus, which is having narrow diameter, then is wider part infundibulum which turns in

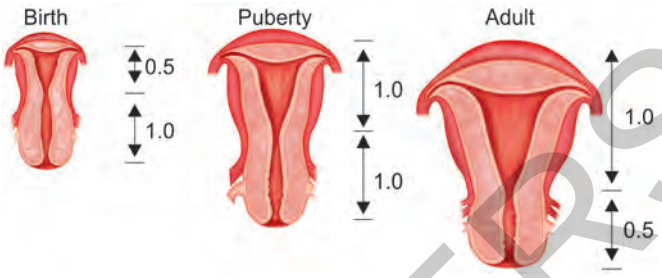

Fig. 9: Schematic representation of the change in uterine length and cervix/corpus ratios at birth, puberty, and adulthood.

funnel-like part ampulla. There are fimbriae at ampullary end of tube, one of them keeps tube in contact with ovary to facilitate entry of ovum in tube at the time of ovulation.

There are three coats like uterus: (1) serous, (2) muscular, and (3) mucous. Serous layer is apex of broad ligament, i.e. visceral peritoneum. Muscular layer has two parts, external longitudinal and internal circular. Endothelium is ciliary columnar having folds. It is continuous with endometrium at cornual end and peritoneum at ampullary end. The blood supply is through branches of ovarian artery.

Once we are familiar with normal structure, we can immediately pick up abnormalities which can be congenital or acquired. Scope of this topic is to understand embryology and the congenital anomalies that are typically encountered.

CHANGES IN UTERUS WITH AGE AND PARITY

In childhood the cervix is longer than the corpus uteri, the proportion being 2:1. At one stage in intrauterine development the proportions are 5:1 or 6:1. At and after puberty, the corpus grows faster than the cervix, and later represents only one-third of the total length of the mature uterus, sometimes only one-quarter of the parous uterus (Fig. 9). After climacteric the uterus atrophies, its overall length is reduced and its walls become thinner, less muscular more fibrous. The cervix shrinks so that the vaginal portion no longer projects and the external os becomes more or less flushed with the vaginal walls.

POSITIONS OF THE UTERUS

When viewed from side, the adult uterus is seen to bend on itself (anteflexed/retroflexed) or at cervix (anteverted/retroverted). The normal position of the uterus is anteverted on the bladder (Figs. 10A to D).

JAYPEE BROTHERS

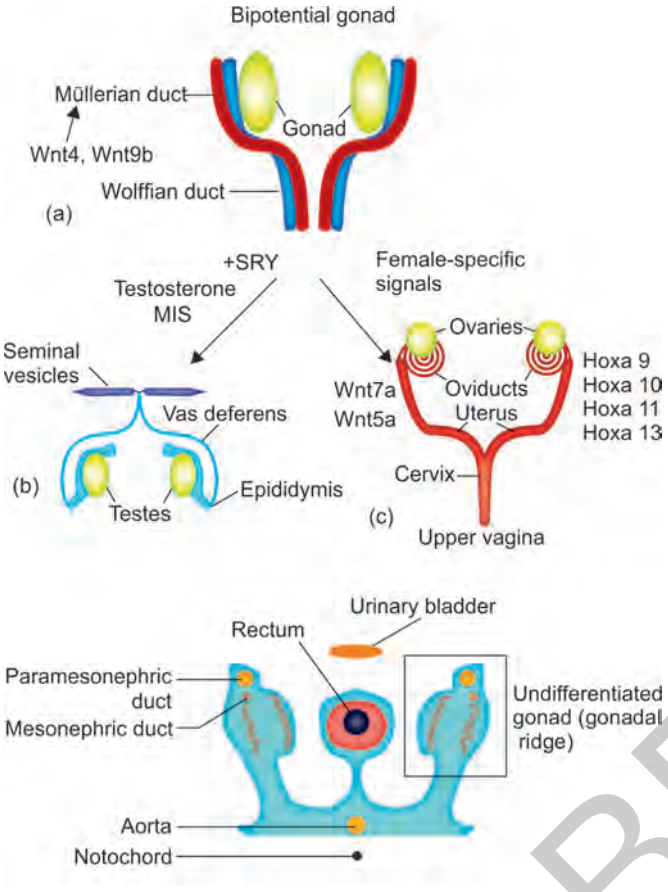

Fig. 11: Differentiation in male and female gonads.

Characteristically, the uterus is anteverted over the urinary bladder. As a result of childbearing and stretching of main ligamentous supports, the uterus may be displaced backwards toward the sacrum (retroversion). Occasionally, uterus is flexed posteriorly on itself (retroflexion). At the time of examination of patient, it is important to know accurate anterior or posterior displacement of uterus as it helps in performing a successful hysteroscopic examination.

EMBRYOLOGY OF UTERUS AND TUBES

Genotype of the fetus is decided at the time of fertilization but phenotype depends on prevailing biochemical and hormonal influence initiated because of expression of concerned genes. Precursors of both, male and female genitalia (mesonephric and paramesonephric duct, respectively) coexist in fetus in early weeks of intrauterine life. After 6 weeks differentiation starts which depends on presence or absence of "Y" chromosome, expression of

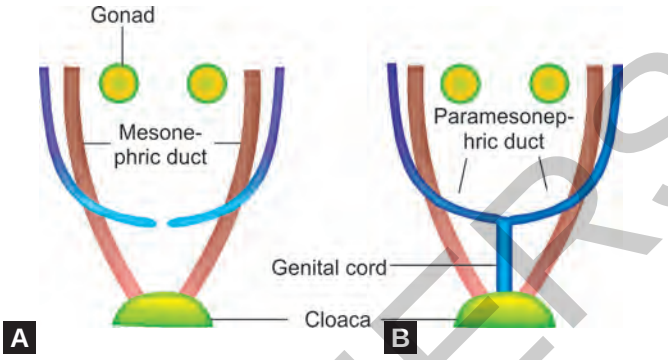

Figs. 12A and B: (A) Course of the Müllerian ducts and (B) Formation of genital cord at 7 weeks.

genes on "X" chromosome, and release or non-release of growth specific factors and hormones (Fig. 11).

In female fetus, there is absence of "Y" chromosome, lack of anti-Müllerian factor and as developing gonad is ovary, testosterone is not secreted so there is regression of mesonephric duct (It is interesting to note here that anti-Müllerian hormone levels go on decreasing in male fetus after birth and it is found in rising levels in female fetus after birth till adolescence and again decrease after menopause). In presence of two "X" chromosomes, development of paramesonephric duct takes place, from which develop tubes, uterus, and upper two-thirds of vagina. There are three stages in this development:

1. Organogenesis or formation of Müllerian duct
2. Fusion of both ducts in center
3. Resorption of septum within two ducts.

At 6 weeks of embryonic development a groove appears on the lateral surface of metanephros. This groove indents the superficial epithelium and advances caudally, originally named as a Müllerian duct but officially as a paramesonephric duct. Near the cloaca of the embryo the two ducts swing towards the midplane and fuse into a cylindrical mass called the genital cord (at 7 weeks) (Figs. 12A and B).

By 10th week this duct descends up to urogenital sinus (precursor of lower third of vagina and external genitalia). The cranial segments of both ducts persist as uterine tubes. Middle segments of both the ducts merge and form the fundus of the uterus. The caudal segments of the ducts which are already fused forms corpus, cervix and upper part of vagina. This caudal end presses against the urogenital subdivision of the cloaca, the joint membrane that represents the future hymen.

By 12th week development of external genitalia and fusion of ducts is complete. Resorption of septum is

JAYPEE BROTHERS

completed by 20th week, but uterine horn and fimbrial development continues even after birth.

Initially, early uterus is bicornuate. After a period the cranial walls of the slanting segments bulge in a cranial direction, so the original angular junction becomes flat and finally dome is formed (Figs. 13A to C).

In 7th prenatal month, the uterine epithelium, i.e. endometrium is formed. But it is in dormant state till puberty. The myometrium formed at 3 months by mesenchyme of the genital cord condensing into smooth muscle tubes that invests the endometrium. The parametrium differentiates from the exterior of the genital cord into a peritoneal covering.

Abnormalities in this process results in congenital anomalies of reproductive tract Müllerian duct anomalies (MDA). There are no risk factors identified except intrauterine exposure to diethylstilbestrol (DES), which was previously used during pregnancy to prevent abortion.

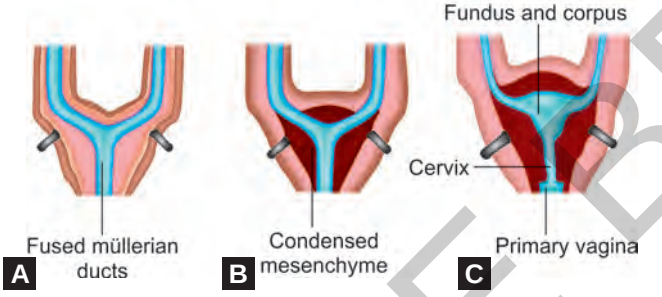

Figs. 13A to C: The later progress of the transverse limbs and fused Müllerian ducts.

Because of developmental proximity, these anomalies may be associated with renal anomalies. Most of the times they remain asymptomatic till puberty. The manifestations vary depending upon type and severity of abnormality. MDA should be ruled out when patient is presented with any of following:

- Cryptomenorrhea
- Pelvic mass
- Dysmenorrhea
- Infertility
- Recurrent pregnancy loss
- Continuation of pregnancy after suction evacuation
- Intrauterine growth restriction
- Preterm labor
- Malpresentation
- Obstructed labor
- Retained placenta
- Failure of tubectomy

Incidence of MDA varies from 4% to 7%. It is more common in women with infertility and abortions than in general population. Because of its effect on reproductive life, exact diagnosis is very important to choose treatment options and predict prognosis.

There are two main classification schemes suggested for these anomalies such as the American Society for Reproductive Medicine (ASRM) and the European Society of Human Reproduction and Embryology (ESHRE) and the European Society for Gynecological Endoscopy (ESGE) classifications.

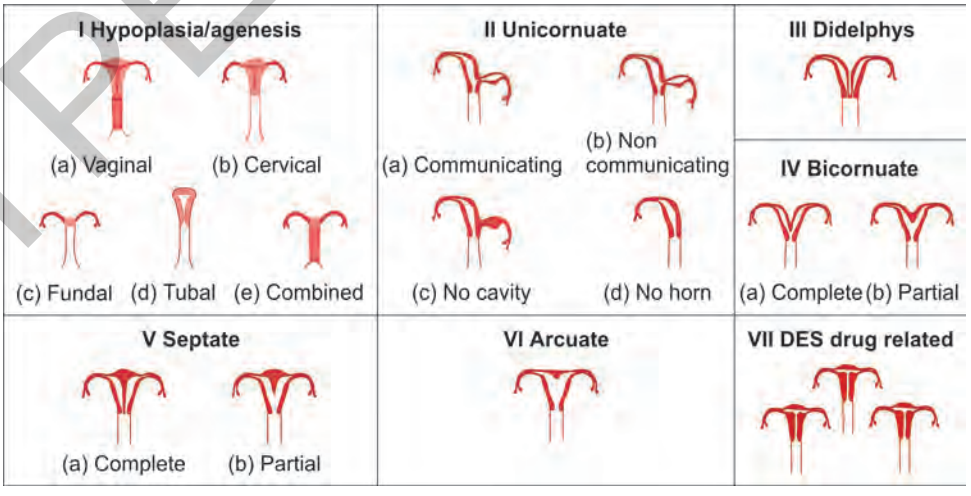

Fig. 14: American Society for Reproductive Medicine (ASRM) classification.
(DES: Diethylstilbesterol).

JAYPEE BROTHERS

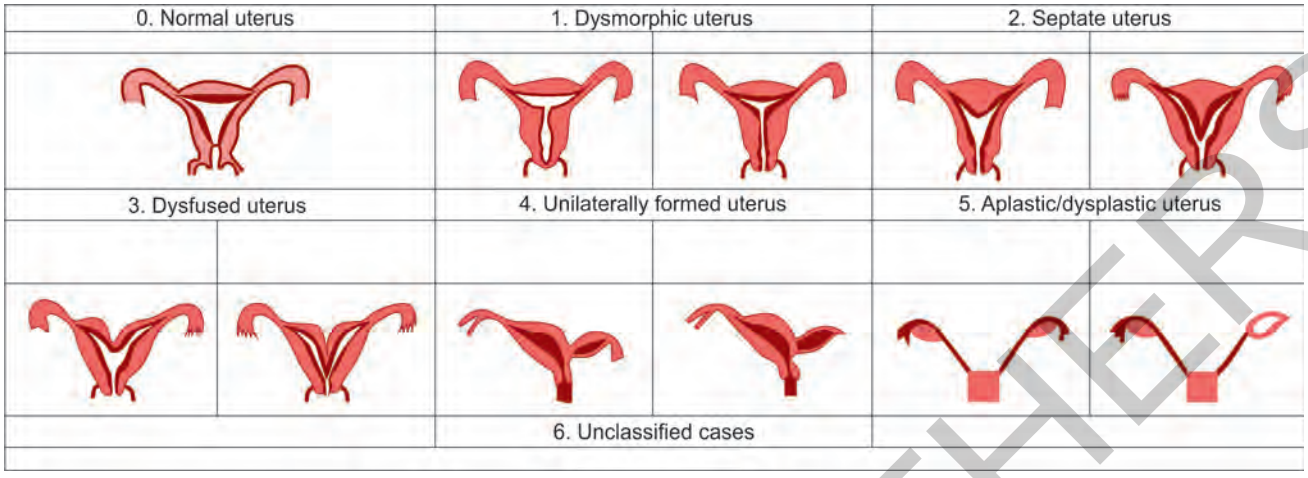

Fig. 15: The European Society of Human Reproduction and Embryology (ESHRE) or the European Society for Gynecological Endoscopy (ESGE) classification.

American Society for Reproductive Medicine

In practice since 1988 (Fig. 14), based on clinical findings:

- Hypoplasia
- Unicornuate uterus
- Uterus didelphys
- Bicornuate uterus
- Septate uterus
- Arcuate uterus
- DES drug related.

European Society of Human Reproduction and Embryology (ESHRE)/the European Society for Gynecological Endoscopy (ESGE) Classification

Revised to consider defect in formation, fusion or resorption as basis (Fig. 15). Consideration is given to normal variations in size instead of absolute figures while diagnosing partial or complete septum. Severity increases with number of group.

0. Normal
1. Dysmorphic—"T" shaped and infantalis—outline normal, shape of cavity abnormal
2. Septate—partial or complete—less than or more than half of myometrial thickness
3. Dysfused—outline and cavity both abnormal—partial or complete
4. Unilaterally formed uterus— rudimentary horn with or without cavity on other side
5. Apastic or dysplastic uterus
6. Unclassified.

Whatever may be the classification used, along with imaging technique and laparoscopy, hysteroscopy is very important diagnostic tool and in few conditions the only treatment option.

SUMMARY

- Understanding of *anatomy* and *embryology* is important for *hysteroscopy.*
- Three parts of female reproductive system are*: (1) gonads, (2) reproductive tract,* and *(3) external genitalia.*
- Three parts of reproductive tract are: *(1) fallopian tubes, (2) uterus,* and *(3) vagina.*
- Hysteroscopy is useful to study *interior of cervix, body of uterus,* and *fallopian tubes.*
- Three parts of uterus are: *(1) fundus, (2) body,* and *(3) cervix.*
- Three layers of uterus are: *(1) serosa, (2) myometrium,* and *(3) endometrium.*
- Three layers of musculature of uterus are: *(1) longitudinal, (2) crisscross, (3)* and *circular.*
- Three types of branching of uterine artery are: *(1) arcuate, (2) radial,* and *(3) spiral.*
- Three things required for development of female reproductive system are: *(1) two "X" chromosomes, (2) absent anti-Müllerian factor,* and *(3) absent testosterone.*
- Three types of developmental defects are: *(1) formation, (2) fusion,* and *(3) resorption defect.*

JAYPEE BROTHERS

for detailed information on obstetrics & gynecology books, visit our website www.jaypeebrothers.com, for detailed information on obstetrics & gynecology books, visit ou

Mastering the Techniques in HYSTEROSCOPY

Salient Features

- Times are changing in the World of the Hysteroscopy. A technique that has been usually labeled as 'simply' or 'minor' has finally exceeded all expectations, and everyday more and more procedures are done by hysteroscopy
- In the recent years, we have witnessed the remarkable progress that has happened in the field of gynecological endoscopy. Technological development has led to a huge improvement in image quality and miniaturization of surgical devices. New techniques and methods have emerged. This process is consistently advancing, very dynamically, and still has quite a way to go
- Within the field of gynecological endoscopy, hysteroscopy is booming. More and more gynecologists want to learn and develop this technique in order to include it in their daily clinical practice. As a result, you can also see a simultaneous increase in the practice of hysteroscopy carried out in all hospitals in the world
- Courses and conferences about hysteroscopy play a crucial role in implementing and promoting our hysteroscopy approach as an available technique in every gynecologic practice
- The objective of teaching is to enable others to get along without teachers.



Osama Shawki MD was born and raised in Cairo, Egypt, where he graduated from Cairo University, Giza, Egypt with highest honours. He is currently Professor of Gynecologic Surgery in Cairo University, School of Medicine, Cairo, Egypt. A ground-breaker in the field of endoscopic surgery, Dr Shawki has not only advanced the potential of minimally invasive surgery, but also pioneered the subtle art of hysteroscopy. The pharaonic maestro not only possesses the Midas touch, but also bestows it onto his pupils as evidenced by hundreds of successful live-surgery workshops in over 40 countries worldwide. Indeed, all who have entered his circle have been left in awe, having been guided through both the microcosm of the uterus to the macrocosm of his philosophical, visionary ideals. A true icon in the ever-evolving world of endoscopy, Dr Shawki's popularity grows with each colossal step forward in his miniaturized world of the womb.



Sushma Deshmukh MD DGO has a special interest in infertility and hysteroscopy. She is Director of Central India Test Tube Baby Centre, Nagpur, Maharashtra, India. She is Head, Department of Obstetrics and Gynecology, Getwell Superspeciality Hospital, Nagpur. She is In-Charge of Deshmukh Hospital, Nagpur. She had organized Nagpur Hysteroscopy Carnival in 2014 and 2016—a national event. She has written the following four academic books: *Infertility Management Made Easy (in 2007), Mini-Atlas in Infertility (in 2008), Tubal Function Tests (in 2010)* and *Fine Art of Hysteroscopy (in 2014)*. Dr Deshmukh has written eight books and one drama book for public awareness in regional language for infertile couple, for adolescents, reproductive and above-40 women going through IVF and sonography. She has also written Sakhi Arogya Sanvad (compilation of 10 dramas on all phases of a woman's life). Dr Deshmukh has prepared a CD on Garbha-Sanskar. She is Director, PCOS Club of Central India, Nagpur for education and awareness. Her main interest is to update the newer technologies and advances. Hysteroscopy is an emerging rewarding specialty and has taken great strides to solve many problems in Obstetrics and Gynecology. She also has great love for public awareness.



Luis Alonso Pacheco MD is board certified and fellowship trained in the area of hysteroscopy. He received his medical degree from the University of Valladolid, Valladolid, Spain, and his title of specialist in obstetrics and gynecology from the Universitary Regional Hospital "Carlos Haya" Málaga, Málaga, Spain. After finishing his specialization, Dr Pacheco worked in Hospital Materno-Infantil de Málaga until 2002. He had been Endoscopic Surgery Consultant of Hospital Xanit Internacional, Málaga from 2006 until 2009. Dr Pacheco was also Professor of Andalusian Endoscopic School, Jerez de la Fronter, Spain from 2006 to 2009. Currently, he is Director of Endoscopy Unit at Centro Gutenberg, where he works from 2002. Dr Pacheco is Co-owner of the reproductive center Clínica Victoria, San Pedro, Costa Rica, and Coordinator of hysteroscopic unit from 2010. He is also Endoscopic Surgery Consultant of Fertility Center, Quirónsalud Hospital, Madrid, Spain from 2010. Dr Pacheco is Chief Editor of 'Hysteroscopy Newsletter'.

Printed in India

Available at all medical bookstores or buy online at www.jaypeebrothers.com

JAYPEE

JAYPEE BROTHERS
Medical Publishers (P) Ltd.
EMCA House, 23/23-B, Ansari Road,
Daryaganj, New Delhi - 110 002, INDIA
www.jaypeebrothers.com

Join us on facebook.com/JaypeeMedicalPublishers

Shelving Recommendation
HYSTEROSCOPY

ISBN 978-93-5465-755-9