d information on medicine books, visit our website www.jaypeebrothers.com, for detailed information on medicine books, visit our website www.jaypeebrothers.com





Interesting Clinical Cases in Medicine

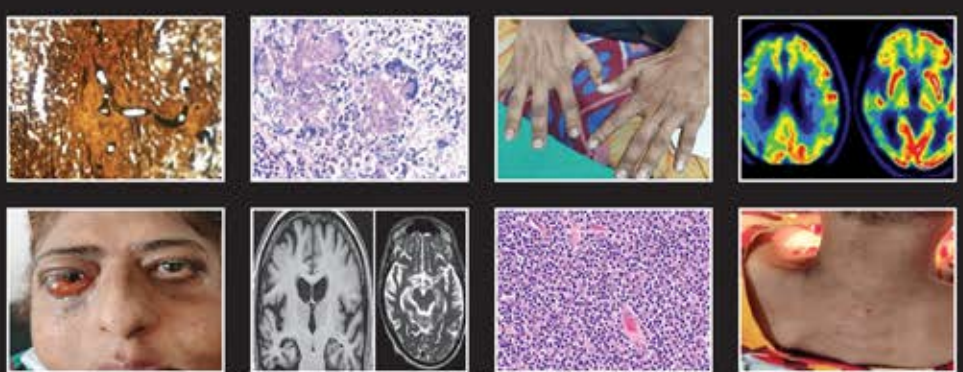

Editors-in-Chief
KK Pareek
Girish Mathur

JAYPEE



Interesting Clinical Cases in Medicine

Editors-in-Chief

KK Pareek MD FICP FFIACM FACP
FRCP (Glasg, Edin, Lond) FGSI FRSSDI
Senior Consultant in Medicine
Head of the Department of Medicine and Director
SN Pareek Memorial Hospital, Kota, Rajasthan, India
Past President – Association of Physicians of India

Girish Mathur MD FICP FRCP (Edin, Glasg, Lond)
FACP FRSSDI FIACM Fellow Diabetes, India
Senior Consultant in Medicine
Alka Diagnostic Centre, Kota, Rajasthan, India
President Elect – Association of Physicians of India

Foreword

Yash Pal Munjal



JAYPEE BROTHERS MEDICAL PUBLISHERS
The Health Sciences Publisher
New Delhi | London

JAYPEE BROTHERS

CONTENTS

CHAPTER 1	**Massive Hematemesis in a Middle-aged Man** *Varun Teja, Soumya Jagannath Mahapatra, Govind K Makharia*	**1**
CHAPTER 2	**A Young Patient with Chronic Diarrhea** *Randeep Rana, Mahendra Singh Rajput, Govind K Makharia*	**7**
CHAPTER 3	**Purple Urine Bag Syndrome: A Case Report and Literature Review** *Sanjiv Maheshwari, Rishab Sharma, Pragya Maheshwari*	**14**
CHAPTER 4	**Allergic Reaction to Human Insulin and its Management: A Case Report** *A Sindhu, Varalakshmi M, K Kavya, Nadiminty Ganapathi Sastry, Prasanna Kumar Gupta, Viswanathan Mohan*	**18**
CHAPTER 5	**An Unusual Case of Delayed Insulin Allergy (Type IV Hypersensitivity)** *Lovelena Munawar, Viswanathan Mohan*	**24**
CHAPTER 6	**Follicular Thyroid Carcinoma in Graves' Disease: A Rare Association** *Choudhary Chandrakanta Jha, Ranjit Unnikrishnan, Viswanathan Mohan*	**27**
CHAPTER 7	**Insulin Autoimmune Syndrome: A Case Report** *K Madhavi, Vidya Jayadeep, Vamsi Krishna, Ranjit Unnikrishnan, Viswanathan Mohan*	**30**
CHAPTER 8	**Wilson's Disease with Diabetes: A Case Report** *Prakash Priya Sandhya, Prasanna Kumar Gupta, Nadiminty Ganapathi Sastry, Viswanathan Mohan*	**34**
CHAPTER 9	**IgA Vasculitis with Predominant Skin Manifestations in a Patient with Diabetes: A Case Report** *M Varalakshmi, M Sravani, Viswanathan Mohan*	**36**
CHAPTER 10	**Workup of a Diabetic Patient with Suspected Ischemic Heart Disease** *Vinod K Abichandani*	**40**
CHAPTER 11	**Intriguing Infections** *Soumyadip Chatterji, Bibhuti Saha*	**48**
CHAPTER 12	**Hirayama Disease: A Rare Neurological Disease** *Jyotirmoy Pal, Purbasha Biswas, Kaushik Samanta*	**55**

JAYPEE BROTHERS

CHAPTER 13	**Rheumatological Symptoms to Leprosy: A Journey of Exclusions** *Nandini Chatterjee*	**60**
CHAPTER 14	**Venoarterial Extracorporeal Membrane Oxygenation in Aluminium Phosphide Poisoning: Bridge to Early Recovery!!** *Rajesh Mishra, Kanwalpreet Sodhi, Ruchira Khasne*	**65**
CHAPTER 15	**Hypokalemic Quadriparesis as the Presenting Manifestation of Sjögren's Syndrome** *Atanu Chandra, Moni Sankar Bhattacharjee, Arkapravo Hati, Partha S Karmakar*	**69**
CHAPTER 16	**Untangling Web of Human Immunodeficiency Virus Management** *Priyanka Ojha, Bharat Bhushan Rewari*	**79**
CHAPTER 17	**A Diagnostic Journey of Monogenic Diabetes** *Banshi Saboo, Mahira Saiyed, Kaumudi Chennamsetti, Tarjani Vyas*	**86**
CHAPTER 18	**Discrepancy between GeneXpert MTB/RIF and Line-probe Assay in Detection of Rifampicin Resistance: A Case Report and Literature Review** *Alok Gupta, Deepak Kumar, Subhashree Samantaray*	**90**
CHAPTER 19	**Challenging Status Epilepticus** *S Arulrhaj, Aarathy Kannan, Chandrakumar*	**98**
CHAPTER 20	**Interesting Gastric Outlet Obstruction** *S Arulrhaj, Ramasubramaniyan, Manikandan*	**102**
CHAPTER 21	**Lateral Chest Pain in Emergency Room** *S Arulrhaj, Aarathy Kannan, Manikandan*	**106**
CHAPTER 22	**Orthopnea for Diagnosis** *S Arulrhaj, Aarathy Kannan, Faizur Rahman*	**109**
CHAPTER 23	**The Forgotten Lead in ECG** *S Arulrhaj, Neelambujan, Chandrakumar*	**113**
CHAPTER 24	**COVID-19** *R Rajasekar, Packiamary Jerome, M Ananthi*	**117**
CHAPTER 25	**Rhabdomyolysis** *R Rajasekar, Packiamary Jerome, M Ananthi*	**119**
CHAPTER 26	**Morvan's Syndrome** *Pooja Yadav, RP Agrawal*	**122**
CHAPTER 27	**Peripheral Arterial Thromboembolism: A Rare Complication of Severe Sepsis and Septic Shock** *RP Agrawal, Kapil Dev Chahar*	**125**

JAYPEE BROTHERS

CHAPTER 28 **Senescent Jaccoud's Arthropathy: Uncommonly Encountered, Rarely Discussed** 129
Deepak Ramchandra Malgutte, Srujana Budumuru, Rohini Handa

CHAPTER 29 **Takayasu Arteritis** 132
Sriram Easwaran, Milind Phadke, Sadanand R Shetty

CHAPTER 30 **Are Hematology Autoanalyzers Always Reliable Enough to Diagnose Thrombocytopenia? An Enigmatic Case Report** 141
Sudhir Mehta, Laxmi Kant Goyal, Shaurya Mehta

CHAPTER 31 **Secondary Hemophagocytic Lymphohistiocytosis: When to Suspect in Tropical Fever?** 143
Sudhir Mehta, Laxmi Kant Goyal, Shaurya Mehta

CHAPTER 32 **Von Willebrand Disease: Why is it Missed in Clinical Practice?** 146
Sudhir Mehta, Laxmi Kant Goyal, Shaurya Mehta

CHAPTER 33 **Hirata's Disease: A Cause of Endogenous Hyperinsulinemia** 148
Swati Srivastava, Vishal Kalwaan, Rakesh Sahu

CHAPTER 34 **Takayasu Arteritis with Antiphospholipid Antibody Syndrome** 151
Vijaya Prasanna, Gumdal Narsimulu

CHAPTER 35 **Secondary Hypertension** 153
Meenaxi Sharda, Preeti Chaudhary

CHAPTER 36 **A Road Less Travelled** 156
Mukesh K Sarna, Pallaavi Goel, Kishore Moolrajani

CHAPTER 37 **A Case of Dementia** 162
Mrinal Kanti Roy

CHAPTER 38 **From Fatigue to Fungus: Bilateral Adrenal Mass with Paravertebral Abscess in an Immunocompetent Elderly Male** 168
Anish Kar, Pankaj Singhania, Aditya Deshpande, Vijay Budhwar, Arunava Ghosh, Sreejith Babu, Piyas Gargari, Yogiraj Ray, Pradip Mukhopadhyay, Sujoy Ghosh

CHAPTER 39 **Thalidomide Induced Primary Amenorrhea in a Patient with HbE/Beta Thalassemia** 172
Arijit Singha, Pradip Mukhopadhyay, Sujoy Ghosh

CHAPTER 40 **Ectopic Cushing's Syndrome due to Thymic Neuroendocrine Tumor** 175
Pankaj Singhania, Anish Kar, Arunava Ghosh, Sreejith Babu, Aditya Deshpande, Vijay Budhwar, Pradip Mukhopadhyay, Sujoy Ghosh

CHAPTER 41 **Mauriac Syndrome in T1DM: Rare Occurrence** 182
Sattik Siddhanta, Nilanjan Sengupta

CHAPTER 42 **Refractory Heart Failure** 187
Meenaxi Sharda, Prateek Jain

JAYPEE BROTHERS

CHAPTER 43	**Panhypopituitarism-Hypothyroidism Unusual Presentation of Myxedema Coma** *Sudhir Bhandari*	**190**
CHAPTER 44	**Multiple Pathologies and Polypharmacy in Elderly** *OP Sharma, Amarnath Jena, Sundeep Upadhyaya*	**193**
CHAPTER 45	**An Unusual Presentation of Tuberculosis as Splenic and Hepatic Abscesses in a Patient of Type 2 Diabetes Mellitus** *Rajeev Chawla, Ashwin Kumar Panda, Hitesh Punyani*	**199**
CHAPTER 46	**Spontaneous Nonclostridial Gas Gangrene in a Diabetic Patient** *A Muruganathan, M Gowri Sankar, P Vishnuram*	**202**
CHAPTER 47	**Hyperthyroidism: A Differential Diagnosis for Pyrexia of Unknown Origin** *M Sabir, Mansoor Ahmed*	**204**
CHAPTER 48	**Systemic Lupus Erythematosus with Sjögren's Syndrome Manifesting as Multiple Cranial Nerve Palsies** *Narinder Pal Singh, Anish Kumar Gupta, Saurabh Puri*	**207**
CHAPTER 49	**Scrub Infection with Peripheral Demyelination: A Case Report** *Akanksha Srivastava, Sintu Kumar, Jamuna Pandey, Sudhir Kumar, BB Thakur*	**212**
CHAPTER 50	**Neuroleptic Malignant Syndrome: A Case Report** *Akanksha Srivastava, Sintu Kumar, Amit Kumar Mishra, Sudhir Kumar, BB Thakur*	**215**
CHAPTER 51	**Methylenetetrahydrofolate Reductase (MTHFR) Mutation in a Young Stroke** *Puneet Rijhwani, Kanika Suri, Anchin Kalia*	**218**
CHAPTER 52	**Uncontrolled Type 2 Diabetes Mellitus with Comorbidities for Insulin Initiation and Titration** *Jugal Kishor Sharma*	**223**
CHAPTER 53	**Association of Neuropsychiatric Systemic Lupus Erythematosus with Type 1 Renal Tubular Acidosis: An Extremely Rare Association** *Biva Bhakat, Sukdeb Das*	**229**
CHAPTER 54	**Fish Gallbladder Ingestion: Bane or Boon** *Koushik Mukherjee, Subhra Sankar Sen, Sourav Sen, Krishnendu Roy*	**235**
CHAPTER 55	**Tubercular Meningitis in an Elderly: Atypical Presentation** *Meenaxi Sharda, Maneesh Gadhwal*	**241**

JAYPEE BROTHERS

CHAPTER 56 **Clinical Pharmacological Review in a Case of Iatrogenesis and Therapeutic Conundrum** **243**
Shambo S Samajdar, Shatavisa Mukherjee, Sougata Sarkar, Gaurab Bhaduri, Jyotirmoy Pal, Saibal Moitra, Santanu K Tripathi

CHAPTER 57 **Hypokalemic Paralysis in a Patient of Dengue Fever** **248**
Puneet Rijhwani, Kanika Suri, Manish Pahadia, Mukesh K Sarna, Pradeep Agarwal, Shrikant Choudhary

CHAPTER 58 **Artery of Percheron Infarction** **252**
Shikha Yadav, Deepak Gupta, Anchin Kalia, Yudhishthir Kuntal, Naveen Yadav, Naveen Chhaba, Pushpendra Chauhan, Manjeet, Pruthvi Patel, Vaishali Sharai, Piyush Batra

CHAPTER 59 **Primary Hyperparathyroidism Presenting as Acute Necrotizing Pancreatitis** **257**
Sudhir Bhandari

CHAPTER 60 **An Important Cause of Secondary Hypertension: Primary Hyperaldosteronism** **260**
Vinay Malhotra, Shiv Chadha

CHAPTER 61 **Abdominal Epilepsy: An Often Misdiagnosed Disorder** **265**
Samir Sahu, Siba Prasad Dalai

CHAPTER 62 **Acute Paracetamol Poisoning with Uncommon Complication** **269**
Atanu Chandra, Sisir Chakraborty, Poulami Karmakar, Koustav Ali Shah, Partha S Karmakar

CHAPTER 63 **Acute Hemiparesis: A Primary Presentation of Neuro-Behçet's Disease** **274**
Mukesh K Sarna, Sana Parvez, Amit Agarwal, Ishank Goel

INDEX ***279***

JAYPEE BROTHERS

CHAPTER 12

Hirayama Disease: A Rare Neurological Disease

Jyotirmoy Pal, Purbasha Biswas, Kaushik Samanta

JAYPEE BROTHERS

INTRODUCTION

Monomelic amyotrophy, also known as Hirayama Disease, is a rare cervical myelopathy that manifests itself as slowly progressive asymmetrical, atrophic, and weakness of the forearms and hands predominantly in young males.

The characteristic clinical features include insidious onset with gradual progression of unilateral (more common) or bilateral asymmetrical muscular atrophy with weakness of the forearms and hands muscles. Autonomic nervous system involvement, sensory system impairment, and upper motor neuron (UMN) signs are rare. This disease is mostly seen in Asian countries but cases have been reported from other parts of the world as well.

A very close differential diagnosis of "Hirayama Disease" is motor neuron disease (MND) but unlike MND, the disease progresses initially and is followed by spontaneous stabilization years after the onset.

CASE PRESENTATION

- A 20-year-old male, mechanic by occupation, presented with history of slowly progressive asymmetric weakness of forearms and hands (right more than left) for 6 months.
- He also noticed loss of muscle bulk of the aforementioned regions which initially started with poor hand grip and difficulty in buttoning and unbuttoning his shirt [right more than left].
- There was no associated history of muscle pain or muscle cramps or contractures.
- There was no difficulty in reaching for higher objects or combing hair.
- No evidence of prolonged or heavy exercises, fever, heat stroke, or toxin exposure.
- No involuntary muscle movements of the affected limbs, no associated stiffness or heaviness.
- There was no associated weakness of his lower limbs, trunk or neck muscles, no dysfunction or history suggestive of autonomic dysfunction.
- No history of difficulty in walking, dysphagia, diplopia, or bowel or bladder involvement. His past medical history was noncontributory and there was no history of trauma or prior hospitalization, and no history of a similar complaint in any of his family members.

CLINICAL EXAMINATION

Neurological examination showed features of lower motor neuron (LMN) lesions. There was bilaterally asymmetrical wasting of the small



Figs. 1A and B: Both forearms and hands appear weak and wasted with preservation of the brachioradialis muscle.

muscles of hand with associated clawing with mild hypotonia in right upper limb. Both forearms and hands were weak and wasted with preservation of the brachioradialis muscle (**Figs. 1A** and **B**). Full abduction, adduction of the digits, and opposition of thumbs of both hands were grossly impaired with poor hand grip. No postural hypotension, excessive sweating, or trophic changes were noted in any limbs. Both superficial and deep tendon reflexes were within normal limits. The power of the proximal muscles of upper limbs and both proximal and distal muscles of lower limbs were within normal limits. There was no evidence of cranial nerve, cerebellum, or sensory system involvement.

DIFFERENTIAL DIAGNOSIS

- *Poliomyelitis*—rapid atrophy, weakness later, preceded by a prodromal stage having headache, sore throat and other constitutional symptoms, acute stage having muscle tenderness, predominantly lower limb involvement with flexion contractures, and inability to swallow if associated with bulbar paralysis.
- *Type IV spinal muscular atrophy (SMA) (Adult form)*—autosomal recessive inheritance, areflexia of lower limbs, hand tremor, tongue fasciculations, and mainly proximal muscle weakness and wasting.
- *Nonprogressive juvenile SMA of distal upper limbs (Hirayama disease)*—*Hirayama disease,* also known as monomelic amyotrophy (MMA), is a rare cervical myelopathy that manifests itself as a self-limited, asymmetrical, slowly progressive atrophic weakness of the forearms and hands predominantly in young males.
- *Amyotrophic lateral sclerosis (ALS)*—Cognitive and behavioral changes. ALS often starts in the hands, feet or limbs, and then spreads to other parts of your body. As the disease advances and nerve cells are destroyed, muscles get weaker. This eventually affects chewing, swallowing, speaking, and breathing.
- *X-linked adult onset bulbospinal muscular atrophy*—signs of androgen insensitivity, e.g., gynecomastia, muscle cramps, fasciculations of tongue, lips, perioral region, dysphagia and dysarthria, strong

JAYPEE BROTHERS

family history, caused by expansion of a CAG trinucleotide repeat (>35), begins between 30 and 50 years.

- *Postpolio syndrome*—progressive muscle and joint weakness and pain, general fatigue, and exhaustion with minimal activity, breathing or swallowing problems, sleep apnea, and decreased tolerance of cold exposure.

CASE MANAGEMENT

Investigations

Nerve Conduction Studies

- *Motor*

Right and left median and ulnar nerve	Normal distal latencies and conduction velocities
Right C-MAP of all nerves	Relatively lower
The right ulnar short segmental study over a 12-cm segment across the elbow	Focal demyelination

- *Sensory*

Right median and ulnar nerve conduction studies	• Normal onset latencies • Normal sensory nerve action potentials (SNAP) amplitudes, and • Normal conduction studies

- *Electromyography*

Type of damage	*Areas affected*
Chronic axonal neurogenic injury	• Bilateral C8-T1 more than C7 innervated musculature • Bilaterally along with the mild active denervation in some of the C8-T1 innervated muscles • More severe on the right side

- *Magnetic resonance imaging*
  - Loss of cervical lordosis with C5–C6
  - MRI on flexion of the neck shows anterior displacement of the posterior dural sac
  - C5–C7 thecal sac indentation
  - Crescent-shaped mass in the posterior epidural space of the lower cervical canal (**Figs. 2A** and **B**).
- X-rays ruled out any osteophytes or bony deformity (**Fig. 3**).

Diagnosis

Overall, the clinical, nerve conduction studies (NCS), and MR imaging features were consistent with the diagnosis of Hirayama disease.

Treatment

Hirayama disease is a self-limiting condition without definitive treatment. Cervical

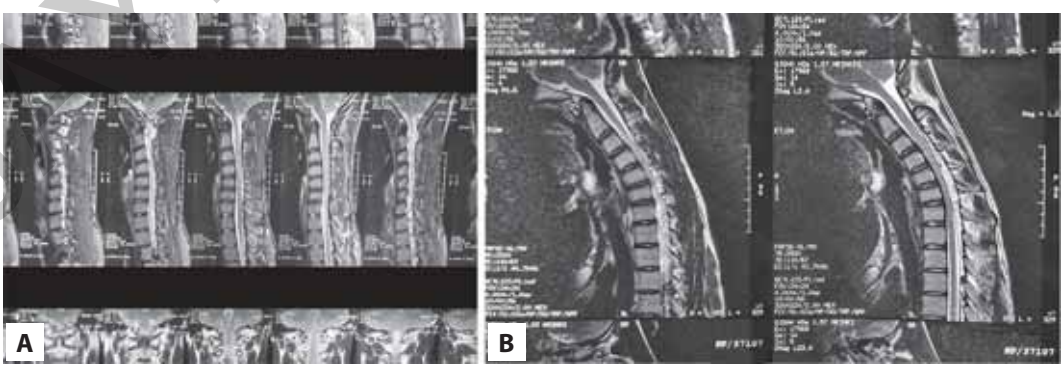

Figs. 2A and B: Crescent-shaped mass in the posterior epidural space of the lower cervical canal.

JAYPEE BROTHERS



Fig. 3: X-rays ruled out any osteophytes or bony deformity.

collars can be used to prevent the neck flexion, compression, and mitigate symptom exacerbation. Apart from permanent cervical fixation, posterior cervical decompression with coagulation of epidural venous plexus is a technique that seems to be effective.

CASE DISCUSSION

- *Hirayama disease* is a neurological condition with asymmetrical weakness and wasting of muscles of upper limb involving the lower cervical cord C7, C8, and T1 myotomes with normal sensory and reflex examination.

According to Tashiro et al., the following criteria are important for diagnosis:

- Predominantly distal muscle weakness with atrophy of forearm and hand muscles
- Involvement of the unilateral upper limbs mostly
- No lower limbs involvement
- Insidious onset with gradual progression initially, followed by stabilization
- Onset between the first and second decades
- No sensory involvement or reflex abnormalities; and
- Exclusion of other neurological diseases

All of these points were fulfilled by our case, which helped to make the diagnosis.

- While pathogenesis is not clearly understood, it is believed that dysfunction of anterior horn cells (AHC) due to pressure atrophy at C5–T1 level may play a role. The imbalance between spinal canal content growth and the vertebral column makes the dural sac thicker, and these cause displacement of the posterior dural sac anteriorly on neck flexion, resulting in compression. Prolonged flexion and repeated compression lead to ischemic damage of AHC, which are vulnerable. Cervical X-ray usually shows no changes. MRI on flexion of the neck shows anterior displacement of the posterior part of the dural sac along with a crescent-shaped mass in the posterior epidural space of the lower cervical canal.

JAYPEE BROTHERS

SUGGESTED READINGS

1. Anuradha S, Fanai V, Fee DB. Hirayama Disease: A Rare Disease with Unusual Features. Case Rep Neurol Med. 2016;5839761.
2. Gourie-Devi M, Suresh TG, Shankar SK. Monomelic amyotrophy. Arch Neurol. 1984;41(4):388-94.
3. Kikuchi S, Tashiro K, Kitagawa M, Iwasaki Y, Abe H. A mechanism of juvenile muscular atrophy localized in the hand and forearm (Hirayama's disease)—flexion myelopathy with tight dural canal in flexion. Clin Neurol. 1987;27(4):412-9.
4. Hirayama K, Toyokura Y, Tsubaki T. Juvenile muscular atrophy of unilateral upper extremity: a new clinical entity. Japanese J Psychiatry Neurol. 1959;61:2190-7.
5. Tayade AT, Kale SK, Pandey A, Kalantri S. Hirayama disease. J Neurosci Rural Pract. 2010;1(1):46-8.
6. Pradhan S, Gupta RK. Magnetic resonance imaging in juvenile asymmetric segmental spinal muscular atrophy. J Neurol Sci. 1997;146:133-8.
7. Kira J, Ochi H. Juvenile muscular atrophy of the distal upper limb (Hirayama disease) associated with atrophy. J Neurol Neurosurg Psychiatry. 2001;70:798-801.
8. Kumar M, Athwal PSS, Rhandhawa S, Kahlon S, Shiv Kumar J. Hirayama's Disease in a Young Male: A Rare Case Report. Cureus. 2019;11(11): e6204.
9. Hassan KM, Sahni H, Jha A. Clinical and radiological profile of Hirayama disease: a flexion myelopathy due to tight cervical dural canal amenable to collar therapy. Ann Indian Acad Neurol. 2012;15:106-12.
10. Gourie-Devi M, Suresh TG, Shankar SK. Monomelic amyotrophy. Arch Neurol. 1984;41:388-94.

JAYPEE BROTHERS

For detailed information on medicine books, visit our website www.jaypeebrothers.com, for detailed information on medicine books, visit our website www.jaype

Interesting Clinical Cases in Medicine

Salient Feature

- The book "Interesting Clinical Cases in Medicine" is published with the aim to give insight of clinical medicine through case-based discussion.
- This book can prove to be of special interest for postgraduate students of medicine and practicing physicians.
- Book comprises—case reports covering all specialties of medicine contributed by eminent authors.
- Contributors of the case reports are experts of great repute who have original work in their field.

KK Pareek MD FICP FFIACM FACP FRCP (Glasgow, Edinburg, London) FGSI FRSSDI is a Senior Consultant in Medicine, Head of the Department of Medicine, and Director, SN Pareek Memorial Hospital (A Multispecialty 100-bedded Hospital), Kota, Rajasthan, India. He is Past President of API, President Elect Indian Association of Clinical Medicine, Founder Chairman—RSSDI—Rajasthan Chapter, Past Dean ICP, Honorary Secretary API, Rajasthan Chapter, Past Chairman—API Rajasthan Chapter, and Organizing Chairman APICON 2022, Jaipur. His areas of interest are diabetes, infectious disease, and tropical medicine. He is the Chief Editor of Medicine Update, Volumes 1 and 2—2019 and Progress in Medicine (2016). He was the Editor of Monograph on Pyrexia of unknown origin. He has published numerous articles in Textbook of Medicine and delivered guest lecture in CMEs and National Conference for last 35 years. He is a very popular physician in Rajasthan and is instrumental in starting and progression of API in this region.

Girish Mathur MD FICP FRCP (Edinburg, Glasgow, London) FACP FRSSDI FIACM Fellow of Diabetes India is a Senior Consultant in Medicine at Kota, Rajasthan, India. His areas of interest are diabetes, cardiology, infectious diseases, and tropical medicine. He is the President Elect—Association of Physicians of India, Chairman Elect RSSDI Rajasthan Chapter, Past Vice Dean—Indian College of Physicians, Past Vice President, Association of Physicians of India (2015–2018), Past Member Governing Body, Association of Physicians of India (2009–2012, 2012–2015), Co-Chair Scientific Committee APICON 2019, Member National Governing Council of Indian Forum for adult immunization. He is an Associate Editor—Journal of Association of Physicians of India (JAPI), Editor of Monograph on Pyrexia of unknown origin, Medicine Update, Volumes 1 and 2—2019, Progress in Medicine, and Medicine Update, Volumes 1 and 2—2016, Member Editorial Board—Medicine Update, Volumes 1 and 2—2013, 2014, and 2015, Journal of Indian Academy of Clinical Medicine, and Indian Journal of Medical Specialization. He has presented many papers in International and National Journals, given guest lectures, and chaired many sessions in state and national conference. He is Co-organizing Chairman APICON 2022, Jaipur, India.

Printed in India

Available at all medical bookstores or buy online at www.jaypeebrothers.com

JAYPEE BROTHERS
Medical Publishers (P) Ltd.
EMCA House, 23/23-B, Ansari Road, Daryaganj, New Delhi - 110 002, INDIA
www.jaypeebrothers.com

Join us on facebook.com/JaypeeMedicalPublishers

Shelving Recommendation
MEDICINE

ISBN 978-93-5465-779-5