ooks, visit our website www.jaypeebrothers.com, for detailed information on dental books, visit our website www.jaypeebrothers.com, for detailed information on dental book

Essentials of
Prosthodontics

- Complete Dentures (CD)
- Removable Partial Dentures (RPD)
- Maxillofacial Prosthetics (MFP)
- Fixed Partial Dentures (FPD)
- Implant Dentistry (ID)



Deepak Nallaswamy Veeraiyan

JAYPEE

CONTENTS

CHAPTER 1: Introduction 1

- Components of a Complete Denture 1

CHAPTER 2: Diagnosis and Treatment Planning 4

- Diagnosis 4
- Patient Evaluation 4
- Clinical History Taking 6
- Contraindications for Complete Denture 7
- Dental History 7
- Clinical Examination of the Patient 8
- Radiographic Examination 16
- Treatment Plan 17
- Adjunctive Care 20
- Prosthodontic Care 20

CHAPTER 3: Diagnostic Impression in Complete Denture 21

- Diagnostic Impression 21
- Making the Diagnostic Cast 22
- Analyzing the Diagnostic Cast 23
- Surveying 23

Chapter 4: Mouth Preparation for CD 25

- Objectives of Mouth Preparation 25
- Non-surgical Methods 25
- Surgical 25
- Ridge Augmentation 27

Chapter 5: Primary Impressions in Complete Denture 29

- Introduction and Classification of Impressions 29
- Anatomical Landmarks 31
- Anatomical Landmarks in Maxilla 31
- Anatomical Landmarks in Mandible 35
- Principles of Impression Making 38
- Objectives of Impression Making 38
- Recording the Primary Impression 42
- Relining the Primary Impression 44
- Alternative Method 44

CHAPTER 6: Lab Procedures Prior to Master Impression Making 45

- Finishing the Primary Cast 45
- Fabrication of a Special Tray 45

CHAPTER 7: Secondary Impressions in Complete Dentures 52

- Techniques for Making the Master Impression 52
- Making a Secondary Impression Using a Special Tray 52

- Inspecting the Impression 58
- Disinfecting the Impression 58
- Remaking the Impression 58

CHAPTER 8: Lab Procedures Prior to Jaw Relation 59
- Preparing the Master Cast 59
- Indexing the Master Cast 61
- Fabricating the Temporary Denture Base 62
- Stabilizing the Base Plates 66
- Fabrication of Occlusal Rims 67

CHAPTER 9: Maxillomandibular Relations 70
- Mandibular Movements 70
- Customizing the Occlusal Rims 77
- Orientation of the Plane of the Occlusal Rim 77
- Jaw Relation 77
- Vertical Jaw Relation 80
- Horizontal Jaw Relation 85
- Other Methods of Recording the Centric-jaw Relation 93

CHAPTER 10: Lab Procedures Prior to Try-in 94
- Articulators and Articulation 94
- Classification 94
- Structure of an Articulator 98
- Mounting Procedure 101
- Teeth Selection 101
- Occlusion 112
- Arrangement of Artificial Teeth 120
- Wax Up 124

CHAPTER 11: Try-in 126
- Definition 126
- Procedure 126
- Speech 127

CHAPTER 12: Lab Procedures Prior to Insertion 129
- Denture Processing 129
- Compression Moulding Technique 129
- Injection-Moulding System 133
- Microwave Processing 135
- Finishing and Polishing the Denture 135

CHAPTER 13: Complete Denture Insertion 137
- Checking for Fit and Function 137
- Checking for the Fit of the Prosthesis 137
- Patient Instructions 139
- Tissue Conditioners 139
- Use of Denture Adhesives 141
- Sequelae of Wearing Complete Dentures 143
- Direct Sequelae of Wearing Complete Dentures 144
- Indirect Sequelae of Wearing Complete Dentures 150
- General Precautions to Prevent and/or Control of Sequelae from Complete Dentures 151

CHAPTER 14: Relining and Rebasing in Complete Dentures **152**
- Relining 152
- Rebasing 158

CHAPTER 15: Special Complete Denture **160**
- Conventional Complete Dentures with Mechanical Retentive Components 160
- Single Complete Dentures 160
- Immediate Dentures 163
- Tooth-supported Overdentures 166
- Cu-sil Denture 168
- Implant-supported Overdentures 168
- Obturators 168

CHAPTER 16: Introduction and Classification **169**
- Common Terminologies Used in Removable Partial Denture 169
- Indications for Removable Partial Dentures 169
- Classification of Partially Edentulous Arches 170
- Steps in the Fabrication of a Removable Partial Denture 174
- Parts of a Removable Partial Denture 175

CHAPTER 17: Diagnosis, Treatment Planning and Mouth Preparation **177**
- Clinical Diagnosis 177
- Clinical Evaluation of the Existing Teeth 177
- Derived Diagnosis or Postclinical Diagnosis 178
- Treatment Planning 180
- Pre-prosthetic Mouth Preparation 180
- Common Problems Faced During Treatment Planning 181
- Making the Primary Cast 184

CHAPTER 18A: Surveying **185**
- Surveying 185

CHAPTER 18B: Path of Insertion **193**
- Determining the Path of Insertion and Guiding Planes 193

CHAPTER 18C: Major Connectors **196**
- Major Connector 196

CHAPTER 18D: Minor Connector **205**
- Minor Connectors 205

CHAPTER 18E: Rest and Rest Seats **208**
- Rest and Rest Seats 208

CHAPTER 18F: Direct Retainers **211**
- Direct Retainer 211

CHAPTER 18G: Attachments **221**
- Internal Attachment 221

CHAPTER 18H: Indirect Retainers **226**
- Indirect Retainers 226

CHAPTER 18I: Denture Base and Teeth **230**
- Denture Base 230

CHAPTER 18J: Principles of a Removable Partial Denture Design **233**
- Principles of a Removable Artial Denture 233
- Principles of Design/Philosophy of Design 239
- Essentials of Design 240
- Laboratory Design Procedure 241

CHAPTER 19: Prosthetic Mouth Preparation **243**
- Preparation of Retentive Undercuts 243
- Guide Plane Preparation 244
- Rest Seat Preparation 245

CHAPTER 20: Secondary Impression and Master Cast for RPD **247**
- Impression Making for Kennedy's Tooth Supported Partial Denture 247
- Impression Making for Distal Extension Denture Bases 247
- Dual Impression Procedures 249
- Preparing the Master Cast 254

CHAPTER 21: Fabrication of a Removable Partial Denture **257**
- Framework Fabrication 257
- Framework Try-in 262
- Fabrication of the Temporary Denture Base and Occlusal Rims 263
- Jaw Relation 263
- Mounting the Casts 263
- Denture Base Selection 263
- Teeth Selection 264
- Arranging the Artificial Teeth 265
- Processing 266
- Insertion 266

CHAPTER 22: Types of Removable Partial Dentures **269**
- Unilateral RPD 269
- Implants Supported RPD 269
- Removable Partial Over-denture 270
- Guide Plane Removable Partial Denture 271
- I-bar Removable Partial Dentures 271
- Swing-lock Removable Partial Dentures 274
- Temporary Partial Dentures 276
- Immediate Partial Dentures 280
- Spoon Dentures 280
- Avery Dentures 281
- Two-part Dentures 281
- Claspless Dentures 281
- Disjunct Dentures 282
- Tooth-borne Nesbit Dentures 283
- Sectional Denture Attachments 283

CHAPTER 23: Correction of Removable Partial Dentures **285**
- Relining 285
- Rebasing of Removable Partial Dentures 286

- Reconstruction of Removable Partial Dentures 286
- Repair of Removable Partial Dentures 287
- Glass Fibre Reinforcement Repair in Acrylic Removable Dentures 288

CHAPTER 24: Introduction to Fixed Partial Dentures 290
- Common Terms Used in Fixed Prosthodontics 290
- Indications for FPD 290
- Contraindications for FPD 290
- Diagnosis and Treatment Planning 290
- Classification of FPD 293
- Smile Designing 296

CHAPTER 25: Parts of a Fixed Partial Denture 300
- Retainers 300
- Pontics 301
- Special Pontics 308
- Connectors 309

CHAPTER 26: Design of a Fixed Partial Denture 311
- Design Considerations for Individual Conditions 311
- Material Selection 312
- Biomechanical Considerations 312
- Abutment Selection 313
- Special Cases 316
- Condition of the Residual Ridge 317
- Occlusion with the Opposing Teeth 317

CHAPTER 27: Types of Abutments 318
- Healthy/Ideal Abutments 318
- Cantilever Abutments 318
- Pier Abutments 318
- Tilted Abutments 318
- Extensively Damaged Abutments 319
- Implant Abutments 323

CHAPTER 28: Tooth Preparation 327
- Principles of Tooth Preparation 327
- Preparations for Full Veneer Crowns 331
- Preparations for Partial Veneer Crowns 338

CHAPTER 29: Types of Fixed Partial Dentures 347
- Based on Design 347
- Based on Materials 348
- Based on Length 350
- Based on Duration of Use 350
- Fixed Partial Denture Splints 350
- Fibre-reinforced Composite Resin Bridges 351
- Resin-bonded Fixed Partial Dentures 352
- Laminate Veneers 357

CHAPTER 30: Impression Making in Fixed Partial Dentures **364**
- Fluid Control and Soft Tissue Management 364
- Impression-making for Fixed Partial Dentures 371
- Other Equipment for FPD Impressions 374

CHAPTER 31: Temporization or Provisional Restoration **375**
- Ideal Requirements of Provisional Restorations 375
- Types of Provisional Restorations 375
- Limitations of Provisional Restorations 377
- Recent Advances and New Materials 378

CHAPTER 32: Lab Procedures Involved in the Fabrication of FPD **380**
- Dies and Working Casts 380
- Wax Pattern Fabrication 382
- Casting 387
- Soldering 389
- Welding 391
- Recent Advancements Fabrication in Metal Framework 391
- Ceramic/Acrylic Veneering 393

CHAPTER 33: Cementation of Fixed Partial Dentures **395**
- Finishing and Polishing 395
- Luting Agents 395
- Try-in 398
- Cementation 399

CHAPTER 34: Maxillofacial Prosthetics **404**
- Materials in Maxillofacial Prosthetics 404
- Colour Matching 407
- Extrinsic and Intrinsic Methods of Colouring 408
- Adhesives in Maxillofacial Prosthesis 408

CHAPTER 35: Implant Dentistry **409**
- Indications and Contraindications 409
- Classification of Implants by Design 409
- Classification of Implants by Material Used 412
- Classification of Implants Based on Biocompatibility 414
- Osseointegration 415
- Implant Surgical Components 422
- Implant Prosthetic Components 427
- Prosthetic Management of Dental Implants 432
- Implant Maintenance 448

Index 459

CHAPTER 4: Mouth Preparation for CD

Mouth preparation includes all the measures taken to correct tissue discrepancies that pose a difficulty in the placement of a denture. Mouth rehabilitation is defined as a "*Restoration of the form and function of the masticatory apparatus to as nearly normal as possible*"—GPT.

Mouth preparation for receiving complete denture (CD).

- Non-surgical method
- Surgical method pre-prosthetic surgery.

1. OBJECTIVES OF MOUTH PREPARATION

- Improves denture foundation.
- Improves ridge relations.
- Enhances support.
- Restoration of form and function of stomatognathic system.
- Improves aesthetics.

2. NON-SURGICAL METHODS

- Rest for denture bearing areas 48–72 hours before final impression made.
- Correcting occlusion [optimum vertical dimension of occlusion (VDO) should be restored using interim resilient lining material].
- Good nutrition.
- Conditioning patients' musculature jaw exercises can be advised to help relax muscles of mastication and strengthen coordination.

2.A. Tissue Conditioners

These can be used to reline areas with tissue damage. They are composed of polyethylene methacrylate and an aromatic ester ethyl alcohol mixture. It should be changed every 72 hours to 3 weeks depending on the extent of tissue damage.

2.B. Adjunctive Care

Ulcers, lesions and abscesses, etc. require immediate attention. The lesion should be cured and the tissue should be given adequate rest for sufficient healing. During the healing period adjunctive therapies like the tissue massage, use of mouthwashes, etc. should be carried out. For patients with normal tissues, 48-hour rest with frequent tissue massage is sufficient. The patient should be advised to stop wearing the existing dentures. Tissue-conditioning materials can be used to reline the existing dentures to reduce tissue inflammation and thus facilitate in subsequent surgical procedures.

2.C. Removal of Retained Dentition

The decision to remove or preserve the tooth is planned during treatment planning. An orthopantomogram (OPG) gives a clear idea about the status of remaining dentition.

2.D. Removal of Unerupted Teeth

- The unerupted teeth lying close the ridge should be removed.
- Deeply submerged, non-symptomatic teeth with normal bony trabeculae can be left untouched.

2.E. Removal of Retained Roots

- All retained roots should be removed especially if there is any sign of pathology.
- Asymptomatic roots, which are present deep in the bone, whose removal can result in a large bony defect, can be cautiously left untouched.

2.F. Correction of Hypermobile Ridge Tissue

Hypermobile tissues result due to excessive residual ridge resorption.

- Small areas of hypermobile tissue, which may not affect the functioning of the denture, can be left untouched. These mobile tissues should be recorded carefully using a mucostatic impression.
- Large pendulous hypermobile tissues should be removed.

2.G. Removal of Soft Tissue Interferences

- Firm soft tissue interferences, which do not affect the stability of the denture, can be left intact.
- In case of a maxillary tuberosity with excessive fibrous tissue the need for surgical removal is evaluated by articulating the diagnostic casts.

3. SURGICAL

3.A. Soft Tissue Procedures

3.A.1. Removal of Hypertrophic Maxillary Labial Frenum

- If the frenal attachment is high, but not close to the crest of the ridge, it is not mandatory to do any surgical procedure. Additional relief in the labial notch of the denture may be sufficient.
- In case of a highly attached frenum where relief of the labial notch can break the peripheral seal of the denture, surgical treatment is recommended. Technique used-diamond excision.
- Other techniques of frenectomy include Z-plasty technique V-Y advancement technique.

3.A.2. Removal of a Hypertrophic Lingual Frenum

Frenectomy is indicated for cases with a hypertrophic lingual frenum. In case of a hypertrophic tongue-tie, surgical management should be done. Tongue-tie test should be done to determine the need for surgical correction. The patient is asked to touch his upper lip with his tongue. If the lingual frenum produces displacement of the denture, then frenectomy should be done (Fig. 4.1A).

3.A.3. Correction of Prominent Buccal Frenum

- Usually, they never present themselves large enough to warrant surgical correction.
- The buccal frenum is soft and hence it can be easily displaced by the denture without producing any injury.

3.A.4. Removal of Papillary Hyperplasia

- These are hyperplastic lesions, which occur in localized areas due to some form of irritation.
- The lesions may be either small or large and if the lesion is small it is treated by curettage. Large lesions are treated by split thickness supraperiosteal excision (Fig. 4.1B).
- It may occur due to poorly adapted dentures or *Candida albicans* worsened by poor oral hygiene or wearing dentures at night.

JAYPEE BROTHERS

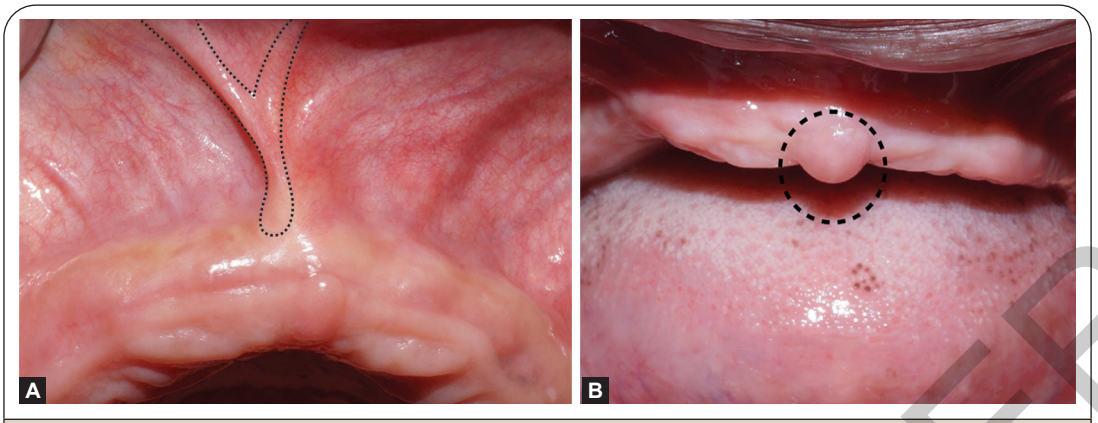

Figs. 4.1A and B: (A) Hypertrophic frenum; (B) Papillary hyperplasia.

- If associated with *Candida albicans* antifungal nystatin mouth wash should be adviced followed by surgical excision. Composition of nystatin mouthwash.
  - Nystatin oral—100,000 use units/mL
  - Alcohol—<1% v/v
  - Sucrose—49.8% w/v
  - Purified water, glycerine, magnesium aluminium silicate flavouring agents, benzaldehyde, methylparaben, propylparaben.

3.A.5. Treatment of Epulis Fissuratum

- It is a soft tissue reaction that appears in the sulcular region due to overextension of the denture flanges. It is commonly seen in immediate denture cases where rapid ridge resorption occurs (Fig. 4.2).
- It does not require any special treatment. Shortening and smoothening the denture border is sufficient.
- Once the tissues heal, the borders of the denture should be refined.
- Carbon dioxide lasers and Nd:YAG lasers are now being used to remove large lesions that occur in the vestibule and are considered as the "GOLD STANDARD".

3.A.6. Vestibuloplasty

It is a surgical procedure to increase the vestibular depth. It can be done using one of the following techniques:

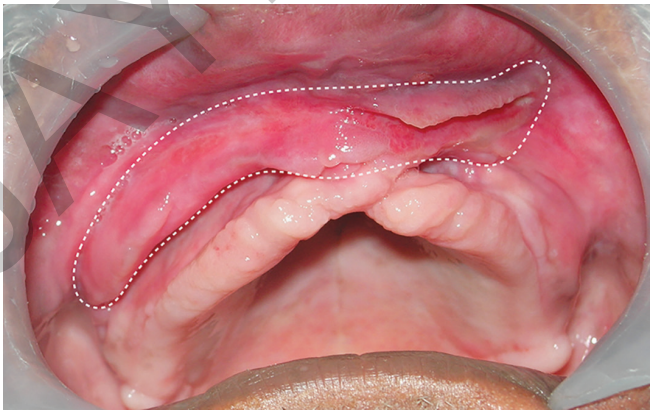

Fig. 4.2: Epulis fissuratum.

Indications

- When conservative procedures fail.
- Healthy, motivated, cooperative patient.

Mucosal advancement

It involves the dissection and apical repositioning of the sulcular mucosa using a surgical stent.

- McIntosh and Obwegeser (1967).
- This procedure is indicated when maxillary denture is unstable due to shallow vestibular depth or high frenal attachment.
- Mouth mirror test: To determine the amount of tissue available for vestibuloplasty.

This is done by placing the mouth mirror under the lip and elevating it to the deserved vestibular depth. Absence of shortening or inversion of the lip indicates adequate tissue availability for vestibuloplasty.

Secondary epithelialization

A full thickness flap is reflected, apically repositioned and sutured with the periosteum at a lower level. The exposed area is allowed to heal by secondary intention.

- It used for hypermobile and hyperplastic ridges present.
- In this technique, over correction is adviced because the relapse is high.

Epithelial graft vestibuloplasty

It is similar to secondary epithelialization except that a full thickness graft is placed over the exposed region allowing it to heal by primary intention.

- Esser (1917) first described this technique. It was later developed by Obwegeser (1967).
- It enhances retention, stability, support of a denture in highly resorbed maxilla/mandibular ridge.
- Most preferred and predictable.

Lip switch procedure (transitional flap vestibuloplasty)

- This technique was introduced by Kazanjian in 1935.
- Indicated-insufficient vestibular depth owing to mandibular atrophy and high muscle and soft tissue attachments.
- Effective in patients with bone height >15 mm.
- If <15 mm, ridge augmentation advised.
- Submucosal dissection from inner lower lip to mucogingival junction.

JAYPEE BROTHERS

- Periosteal flap dissected from bone and sutured to raw lip bed.
- Raised mucosal flap is adapted to reposed bone to the depth of new vestibule and fixed with sutures or stent.

3.B. Hard Tissue Procedures

3.B.1. Removal of Ridge Undercuts

- Small undercuts, which do not pose much difficulty in the insertion of the prosthesis, can be left untouched.
- Moderate single-sided undercuts also do not require any surgical treatment because the path of insertion of denture can be altered parallel to the direction of the undercut (Figs. 4.3A and B).
- Severe undercuts or bilateral (double-sided) moderate undercuts require surgical correction (alveoloplasty, ridge augmentation).
- Alveoloplasty procedure: A mucoperiosteal flap is reflected and bone is reduced using rongeurs forceps or a rotary bur. This procedure helps remove undercuts and smoothen saw tooth or knife edged ridges.

3.B.2. Management of Prominent Mylohyoid and Internal Oblique Ridges

- Internal oblique and mylohyoid ridges are seen in the lingual surfaces of the mandible. Sometimes they become very prominent due to ridge resorption.
- They should be surgically reduced when there is repeated ulceration, loss of peripheral seal, etc.
- Mucoperiosteal flap is neglected and the prominence is removed with rotary bur or bone file.
- It limits extension of the lingual flange of a lower denture.

3.B.3. Reduction of Maxillary Tuberosity

- A wide tuberosity is easier to reduce compared to vertically large tuberosity.
- The maxillary sinus tends to expand into the tuberosity. Hence, radiological evaluation is mandatory before surgical reduction.
- The interarch distance should be evaluated and the thickness of denture flange should also be reduced accordingly.
- Hyperplastic tuberosity may be due to combination syndrome or due to super eruption of unopposed molars.
- Upon extraction, the bone associated with the tuberosity is untrimmed.

3.B.4. Treatment of Sharp Tiny Ridges

- These ridges usually occur in the lower anterior region due to resorption of the labial and lingual cortical plates.

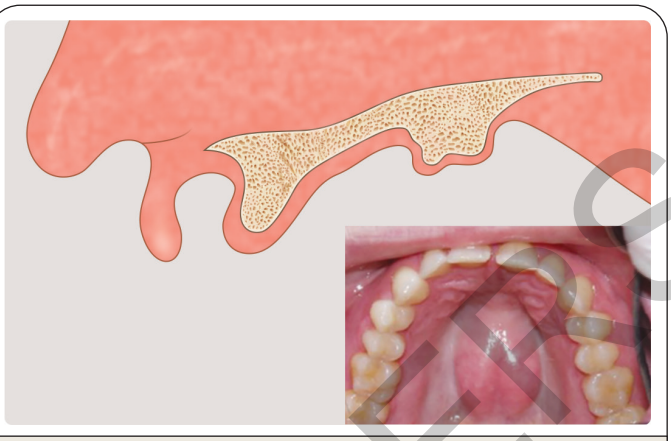

Fig. 4.4: Tori.

Courtesy: Dr William J Moorehead, Flemigsburg, KY, USA.

- Ridge augmentation can be done. Usually dentures with large flanges are constructed to avoid load on the crest of the ridge.
- Meyer classified knife edge ridges into three types:
  1. Saw-tooth
  2. Razor-like
  3. Ridge with discrete spiny projections.

All three ridges have a sensitive mucosal lining. Care should be taken to protect the mucosa.

3.B.5. Excision of Tori

- These are small bony projections of unknown aetiology, which grow to their maximum size by the end of third decade of life.
- Indications for removal of maxillary tori (Fig. 4.4):
  - Interference of speech
  - Loss of posterior palatal seal
  - Poor denture stability
- Tori are more common in females and is composed of cortical bone.
- All mandibular tori should be excised because the mucosa over the tori is more prone to irritation due to constant movement of the denture during mastication.

4. RIDGE AUGMENTATION

- Bone grafts or alloplastic materials are used to increased the size of an atrophic alveolar ridge.
- Commonly used techniques for ridge augmentation include:
  - **Visor osteotomy:** Buccolingual dimension of the mandible is split and lingual cortical bone is repositioned superiorly.

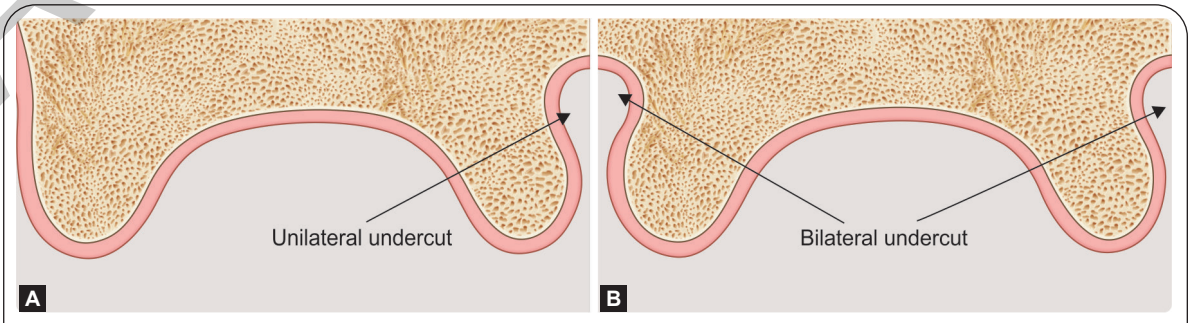

Figs. 4.3A and B: (A) Unilateral ridge undercut; (B) Bilateral ridge undercut.

JAYPEE BROTHERS

❑ **Onlay bone grafting**
- ♦ When bone to bone support in maxilla and mandible is inadequate.
- ♦ Residual vertical bone height between mental foramen is greater than 7 mm.
- ♦ Autogenous bone from iliac crest used.
- ♦ However onlay bone grafts cannot be used for increasing the height, thus distraction osteogenesis is the only option in such cases.

4.A. Interpositional Bone Grafts

- The superior-interior dimension of the residual jaw is split and bone grafted.
- Allogeneic bone graft can be used.
- It is the procedure of choice for mandibular ridge augmentation.

4.B. Inferior Bone Grafts

- Supralaryngeal
- Autogenous cancellous graft from ileac crest, hydroxyapatite or allogeneic particulate can be used as graft expander.

4.C. Distraction Osteogenesis

Distraction osteogenesis, also termed Callotasis, Callus distraction, and osteo-distraction, is a surgical technique of generating new bone by progressive stretching of the divided bone segments.

It was invented by a Russian surgeon, Dr Gavril Ilizarov who used the procedure to treat the problems of the leg. This procedure is used to increase the height of the bone in resorbed ridges. In maxillofacial procedures, both external and internal devices may be used to distract the bone. Normal rate of distraction is 1 mm/day. Distraction rates of more than 1.5 mm/day may cause delayed healing.

Distraction osteogenesis decreases the need for bone grafting for large (>10 mm) mandibular advancements; one can achieve 20 mm or more of advancement without a bone graft and the associated donor site morbidity, scarring, and potential for infection.

This procedure also has certain disadvantages:
- Relative difficulty in performing osteotomies owing to potential damage to lingual mucoperiosteum or vascular plexuses of the floor of the mouth.
- Difficulty in obtaining correct vector of distraction.
- Patient discomfort and psychological burden due to the retained distractor device.

JAYPEE BROTHERS

or detailed information on dental books, visit our website www.jaypeebrothers.com, for detailed information on dental books, visit our website www.jaypeebrothers.com, for d

Essentials of Prosthodontics

Salient Features

The *Essentials of Prosthodontics* by Deepak Nallaswamy Veeraiyan is a comprehensive resource designed to meet the needs of dental students, practitioners, and educators. Here are some salient features that make the book standout:

- **Comprehensive coverage:** This book provides a thorough examination of all aspects of prosthodontics, including fixed, removable, maxillofacial, and implant prosthodontics.
- **Up-to-date content:** It includes the latest advancements and technologies in the field, keeping readers at the forefront of modern dental practice.
- **Clear and concise writing:** Written in an accessible language, the book makes complex topics understandable for readers at all levels of expertise.
- **Rich visual aids:** Featuring high-quality images, diagrams, and illustrations, this book offers a visual learning experience that complements the written content.
- **Step-by-step procedures:** Detailed procedural guides, including step-by-step instructions for various techniques, aid in learning and applying skills in a clinical setting.
- **Multidisciplinary approach:** This book integrates insights from related disciplines, offering a well-rounded perspective on prosthodontics.
- **Global perspective:** By incorporating international standards and practices, this book serves as a valuable resource for readers around the world.
- **Hands-on laboratory manual:** In some editions, a hands-on laboratory manual might be provided, offering practical exercises and simulations for skill development.

In summary, Deepak Nallaswamy Veeraiyan's *Essentials of Prosthodontics* sets a benchmark in dental education, offering a complete, accessible, and state-of-the-art guide to prosthodontics. Its combination of breadth, clarity, and practicality makes it an indispensable resource for anyone involved in the study or practice of this specialized field of dentistry.

Deepak Nallaswamy Veeraiyan BDS MDS MS MDP is an eminent figure in the field of prosthodontics, with a distinguished career spanning several decades. A renowned author, educator, and clinician, he has made significant contributions to dental science and education, particularly in the specialized field of prosthodontics. Born and raised in a family deeply ingrained in the world of medicine and education, his passion for dental care was nurtured from a young age. He pursued his studies with dedication and excelled in his academic pursuits, earning degrees from prestigious institutions. His *Essentials of Prosthodontics* has become a seminal work in dental education, appreciated by students, educators, and practitioners alike. Comprehensive in scope yet accessible in language, this book offers a deep and thorough exploration of prosthodontics, covering essential concepts, innovative techniques, and the latest developments in the field. What sets his book apart is his unique approach to blending theory with practical application. Through clear explanations, detailed illustrations, and real-world examples, he demystifies complex subjects, making them accessible to undergraduate students and seasoned professionals alike. This book reflects his philosophy of patient-centered care, emphasizing the importance of understanding individual needs, preferences, and anatomical considerations. He believes in a holistic approach to prosthodontics, considering not just the technical aspects but also the psychological and social dimensions of patient care. In addition to his writing, he is an esteemed faculty member at Saveetha Dental College, where he inspires future generations of dental professionals. His lectures are known for their clarity, depth, and engaging style, a reflection of his commitment to excellence in education. His impact on the field of prosthodontics goes beyond academia. He has been actively involved in various professional organizations, contributing to policy-making, research, and advocacy. His research work has been published in top-tier dental journals, further cementing his reputation as a thought leader in the field.

In conclusion, his *Essentials of Prosthodontics* is more than a reference guide; it's a testament to his passion for dental care, his mastery of the subject, and his dedication to fostering the next generation of dental professionals. It stands as an essential resource for anyone looking to delve into the fascinating and essential world of prosthodontics.

Printed in India

Available at all medical bookstores
or buy online at www.jaypeebrothers.com



JAYPEE BROTHERS
Medical Publishers (P) Ltd.
EMCA House, 23/23-B, Ansari Road,
Daryaganj, New Delhi - 110 002, INDIA
www.jaypeebrothers.com

Join us on facebook.com/JaypeeMedicalPublishers

Shelving Recommendation
DENTISTRY

ISBN 978-93-5465-819-8

9 789354 658198