ooks, visit our website www.jaypeebrothers.com, for detailed information on medicine books, visit our website www.jaypeebrothers.com, for detailed information on medicine books

Under the aegis of
Indian Association of Clinical Medicine

SCIENTIFIC COMMITTEE SOCIETY
SINCE-2019

BLENDING TECHNOLOGY AND CLINICAL MEDICINE

IACM
Clinical Medicine Update 2022

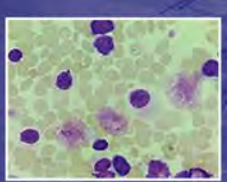



Editor-in-Chief
KK Pareek

JAYPEE

CONTENTS

SECTION 1: CARDIOLOGY

1. **Advances in Management of Heart Failure** 1
   Debaprasad Chakrabarti, Anirban Bhowmik

2. **Microalbuminuria: A Risk Marker for CAD** 9
   AN Rai

3. **Cardiomyopathy: Diagnosis and Management** 16
   Subhash Chandra

4. **Echocardiography and Lung Ultrasound in the Emergency Room** 41
   Rohit Tandon, Priyanka, Sidhant Sachdeva

5. **Electrocardiogram in Routine Practice** 81
   Abhishek Goyal

SECTION 2: CLINICAL MEDICINE

6. **Hand Palmistry in Medicine** 93
   Subhash Chandra, SN Yadav, Prakhar Gupta, Shweta Yadav

7. **General Physical Examination: A Window to Systemic Disease** 107
   Y Sathyanarayana Raju, Rahul Yadati, Sairam Yadati

8. **Superior Vena Cava Syndrome: A Forgotten Clinical Entity** 111
   Madhuchanda Kar, Amit K Adhikary

9. **Tongue is a Mirror of Systemic Diseases** 117
   Smarajit Banik, Shankar Dutta

SECTION 3: CRITICAL CARE

10. **Metabolic Acidosis: Diagnosis and Management** 125
    Subhash Chandra

11. **Hyponatremia** 144
    Mukesh K Sarna, Pallaavi Goel

12. **Rational for Antibiotics: Guidelines** 156
    Mangesh Tiwaskar, Tanuja Manohar

SECTION 4: DIABETOLOGY

13. Surgery and Diabetes: Current Concepts 173
BK Singh

14. How Often Estimation of Urinary Albumin to Creatinine Ratio do Help to Identify Early DM Nephropathy? 178
Dipankar Prakas Bhaumik, Mukut Roy, Soma Saha

15. Difficult Case Scenarios in Diabetes Mellitus Management 184
Anil Kumar Virmani

16. Type 2 Diabetes Mellitus: Asian Indian Phenotype 191
GD Ramchandani, Sugandha Sharma, Rahul Ramchandani, Divyansh Mathur

17. Interpretation of Urine of a Diabetic Patient 194
Prabhat Agrawal, Mudit Khurana, Nikhil Pursnani, Kanika Agarwal, Ashish Gautam

18. Sulfonylureas in 2022: Are They Still Relevant? 201
Abhishek Kumar, Sudhir Kumar, Niharika Sinha

19. Remission and Reversal in Diabetes 206
Navneet Agrawal

20. Protecting the Diabetic Target Organs: Kidneys/ Heart/Retina and the Liver 213
Daya Kishore Hazra, Padmamalika Khanna nee Hazra, Gaurav Ashish Khanna, Srishta Hazra

21. Gestational Diabetes Mellitus: A Window of Opportunity for Noncommunicable Disease Prevention 219
Saurabh Srivastava

22. Diabetes and Vaccination: The Need and Guideline 225
Puneet Saxena, Aradhana Sharma, Suresh Yadav

23. Prediabetes 230
Vijay Garg, Himanshu Jain, Vimlesh Patidar, Sukrati Maheshwari

24. Insulin: Initiation, Intensification, and Barriers 238
Arvind Gupta, Rajeev Gupta, NK Singh

25. Technology Transforming Diabetes Care 242
Ajay Kumar

26. Selection of Footwear in Patient with Diabetic Foot **249**
Vaibhav Saxena, Rajnish Saxena, SS Dariya

27. Interplay between T2DM, Dyslipidemia and NASH **255**
Anuj Maheshwari, Naman Shukla, Ajoy Tewari

28. Early Detections and Therapeutic Interventions in Diabetes Kidney Disease **259**
SK Sharma, Niharikaa Sharma

29. Diabetes in Young: Current Concepts **269**
BK Singh

30. Prediabetes: A Synopsis **275**
Sarita Bajaj

SECTION 5: ENDOCRINOLOGY

31. Addison Disease, Clinical Challenges, and Treatment **282**
Gursaran K Sidhu

32. Treatment Issues in Hypothyroidism **293**
Rahin Mahata, Partha Pratim Chakraborty

33. Subclinical Hypothyroidism **300**
AK Gupta, Ajit Singh Chahar, Ashutosh Kumar

SECTION 6: EXERCISE AND GOOD HEALTH

34. Physical Activity and Exercise Plan in a Patient with Type 2 Diabetes Mellitus **314**
Sirshendu Pal

35. Physiology of Yoga and Its Effect on Body **319**
Arun Chaturvedi

36. Enjoy Your Exercise **323**
KK Pareek

SECTION 7: GASTROENTEROLOGY

37. Approach to a Patient of Dyspepsia **334**
Avik Chakraborty

38. Recent Advances in Management of Acute Pancreatitis **340**
Gurinder Mohan, Arvinder Pal Singh, Jagga Sankalp Harish

39. Chronic Pancreatitis: Newer Concepts in Management **348**
Rajesh Gopalakrishna

40. Clinicopathological Approach in a Case of Chronic Diarrhea **354**
Ashis Kumar Saha

41. Ascites: Diagnostic and Management Issues **363**
Rajesh Upadhyay, Amrit Yog Datley, VS Gaurav Narayan

SECTION 8: HEMATOLOGY

42. Peripheral Blood Smear: Clues to Diagnosis **371**
Nandini Chatterjee, Nabanita De

43. Approach to Lymphadenopathy **379**
Alladi Mohan, Srishti Ahluwalia, Saumya Ahluwalia, G Bindhu Madhavi

44. Approach to Pancytopenia **384**
BL Bhardwaj

SECTION 9: HIV MEDICINE

45. Updated Antiretroviral Therapy Guidelines: 2022 and Beyond **391**
BB Rewari

46. Pre- and Post-exposure HIV Prophylaxis **399**
Naval Chandra

SECTION 10: HYPERTENSION

47. What is New in Current Guidelines of Management of Hypertension? **403**
Hem Shanker Sharma, Reeja Antony

48. Calcium Channel Blockers and Angiotensin Receptor Blockers: A Friendly Duo **407**
Kamlesh Tewary

49. Management of Hypertension in Chronic Kidney Disease **414**
Mritunjay Kumar Singh

SECTION 11: INFECTIOUS DISEASE

50. Antimicrobial Stewardship Program 423
Amit Aggarwal

51. Systemic Fungal Infections 430
Vipin Mediratta

52. Approach to Tropical Fever 434
Anusha Singhania, Vikas Loomba

53. Sepsis Management: Current Update 440
Shankha S Sen

SECTION 12: METABOLIC MEDICINE

54. Nonalcoholic Fatty Liver Disease: Current Understanding 454
Pradip Bhaumik

55. Metabolic Syndrome: An Overview 462
KK Lohani

56. Erectile Dysfunction 467
MPS Chawla

SECTION 13: NEUROLOGY

57. The Untold Story of Acute Encephalitis Syndrome 481
Jitendra Singh, Anju Dinkar

58. Management of Acute Ischemic Stroke: What is New? 494
TP Singh, Akansha

59. Advances in Epilepsy Management and Current Perspectives 505
Man Mohan Mehndiratta, Vasundhara Aggarwal

SECTION 14: PULMONOLOGY

60. Changing the Course of Allergic March 518
Pradyumn Sharma

61. Recent Advances in Management of Interstitial Lung Disease 527
Prashant Prakash, SK Kushwaha

62. Approach to Undiagnosed Pleural Effusion 538
DP Singh

SECTION 15: RHEUMATOLOGY

63. A Clinical Approach to Patient with Joint Pain **544**
Tarun Satija, Samarth Loomba

64. New Concepts in Systemic Lupus Erythematosus **550**
S Bhavana, RN Tejaswini, Vijaya Prasanna, G Narsimulu

65. Changing Landscape of Rheumatoid Arthritis Management **554**
Uma Kumar, Israrul Haque

SECTION 16: MISCELLANEOUS

66. Familial Hypercholesterolemia **558**
Raman Puri, Rashmi Nanda

67. Antimicrobial Resistance: What the Clinician Should Know? **566**
Dipanjan Bandyopadhyay, Santanu Hazra, Samarth Loomba

Index **575**

CHAPTER

4

Echocardiography and Lung Ultrasound in the Emergency Room

Rohit Tandon, Priyanka, Sidhant Sachdeva

JAYPEE BROTHERS

INTRODUCTION

- Echocardiography has emerged as an important noninvasive tool for improving the efficiency in the diagnosis of serious conditions in the medical emergency department.
- Lung ultrasonography allows for rapid assessment of numerous conditions, including pulmonary edema, pleural effusion, and pneumothorax.
- Over-reliance of traditional clinical findings and symptoms can cause potential delay in various cardiac and noncardiac emergencies.
- The use of echocardiography and lung ultrasonography can help to improve diagnostic accuracy and monitor responses to interventions in these patients.

CONSIDERATIONS PRIOR TO SCANNING

Setting

Preparation

- Appropriate transducer selection
- Appropriate preset selection

Ultrasound Protocol

- Focused examination
- Diagnostic examination

CARDIAC PROBE SELECTION

- Small round footprint for scan between ribs
- 2.5 MHz: Above average sized patient
- 3.5 MHz: Average sized patient
- 5.0 MHz: Below average sized patient or child

VASCULAR PROBE FOR LUNG USG

- Long foot print
- 3–12 MHz range
- Good resolution

CLINICAL INDICATION

- *Hemodynamic instability and/or hypoxemia of unclear etiology*
  - Suspected tamponade
  - Pulseless electrical activity (PEA) can be the presenting symptom for:
    - Tamponade
    - Massive pulmonary embolism
    - Acute massive internal hemorrhage
    - Tension pneumothorax



FIG. 1: Sector probe for echocardiography.



FIG. 2: Vascular probe for lung USG.

TABLE 1: Major causes of cardiac and cardiac like emergencies and their common clinical presentation in emergency.

	ACS	AoD	PE	P	Ptx	ADHF	T	AVR/PVD
Acute chest pain	+++	+++	++	+++	+++	+	+	+
Acute dyspnea	++	+	+++	0	++	++++	++++	++++
Hemodynamic instability/shock	++	++	+++	+	+	++++	++++	++++
New murmur	+	+	+	+	0	+	0	++++
Cardiac sources of embolism/syncope	+	+	+	0	0	+	0	+
Chest trauma	+	+++	0	+	++	0	+++	+
Cardiac arrest/CPR	++++	+	+++	+	+	+	+++	+

JAYPEE BROTHERS

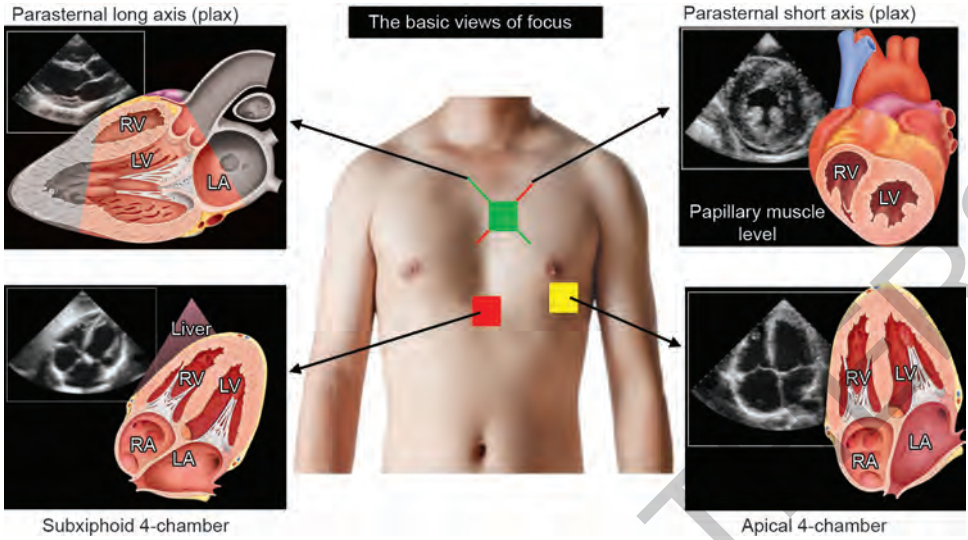

FIG. 3: Focus-assessed transthoracic echocardiography (FATE).

- Aortic dissection
- Acute coronary syndromes
- Acute valvular pathology, prosthetic valve malfunction
- Infective endocarditis
- Massive pulmonary embolism
- Acute embolic event
- Critically ill patients due to noncardiac illness: Cardiac function and left ventricular (LV) filling may be crucial to guide fluid-resuscitation:
  (a) Septic shock, and (b) Diabetic ketoacidosis

Major causes of cardiac and cardiac like emergencies and their common initial clinical presentation in the emergency room.

PARASTERNAL LONG AXIS VIEW

- Most echocardiography studies begin with this view.
- Transducer position: Left sternal edge; 3rd–4th intercostal space.
- Marker dot direction: Points toward right shoulder.

Purpose

- Overview of LV inflow, outflow, aortic root
- LV dimensions
- Perimembranous ventricular septal defect (VSD)
- Measurements:
  - Mandatory: LV systolic and diastolic diameters; interventricular septal and posterior wall thickness.

JAYPEE BROTHERS

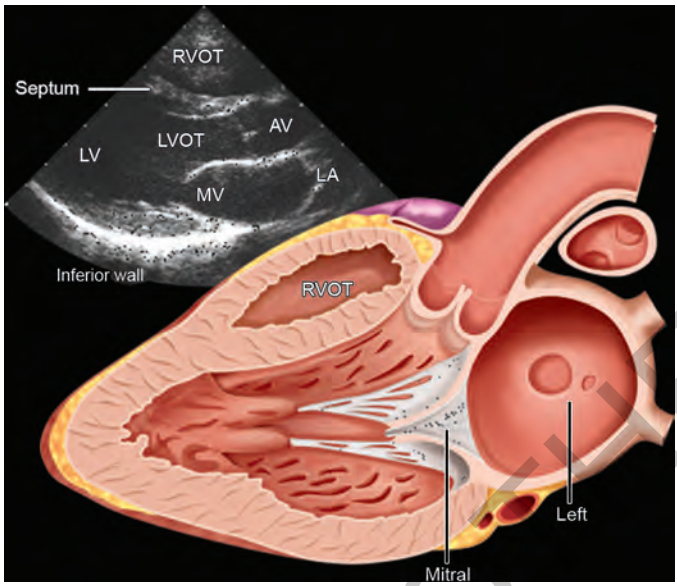

FIG. 4: Parasternal long-axis view.

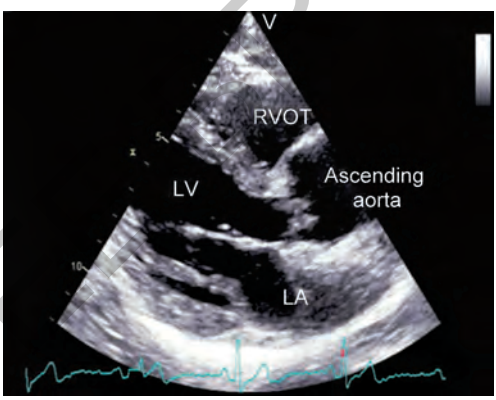

FIG. 5: Parasternal long-axis view.

PARASTERNAL LONG-AXIS MITRAL VALVE ZOOM TWO-DIMENSIONAL AND COLOR

- *Purpose:*
  - 2D: Mitral leaflet motion and pathology
  - Color: Detection of mitral regurgitation (MR), measurement of MR jet vena contracta
- *Measurements:*
  - 2D: Mitral annulus anteroposterior diameter
  - Color: Vena contracta, proximal isovelocity surface area (PISA)

JAYPEE BROTHERS

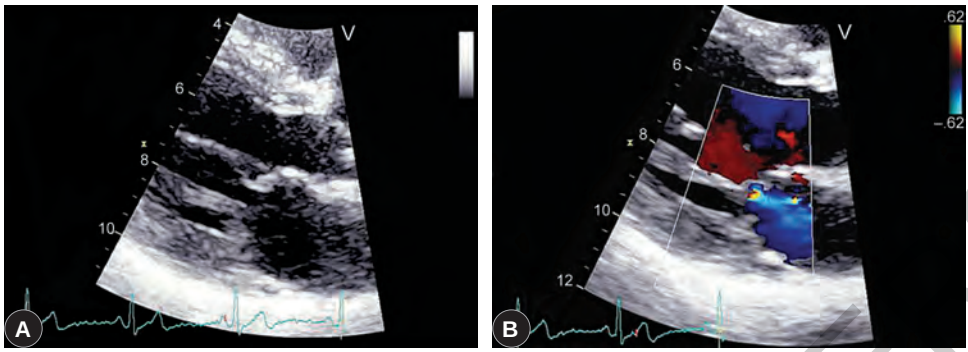

FIGS. 6A AND B: PLAX mitral valve zoom 2D and color.

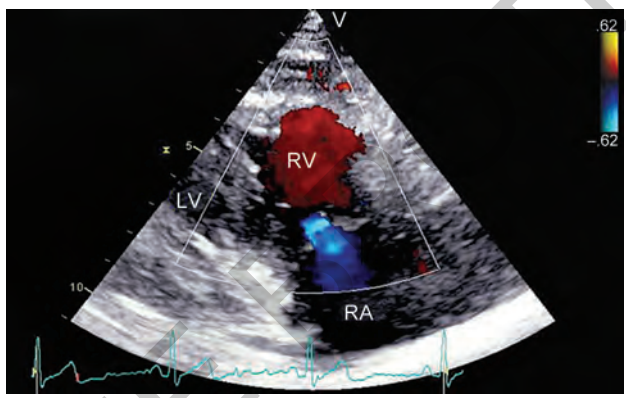

FIG. 7: Right ventricular (RV) inflow view.

RIGHT VENTRICULAR INFLOW VIEW

- Obtained by angling the transducer medially, toward the right hip
- RA, TV, and RV can be visualized.
- Ostium of the inferior vena cava, including Eustachian valve, is seen draining into the RA.
- *Purpose:*
  - Tricuspid leaflet pathology
  - Tricuspid regurgitation (TR) mechanism and severity
- *Measurements:*
  - Qualitative for TR, also CW for estimation of TR gradient

PARASTERNAL SHORT AXIS VIEW (SEMILUNAR VALVES)

- Obtained from the PLAX view by rotating the transducer orientation mark by 90° in the clockwise direction, such that it points to the patient's left shoulder.

JAYPEE BROTHERS

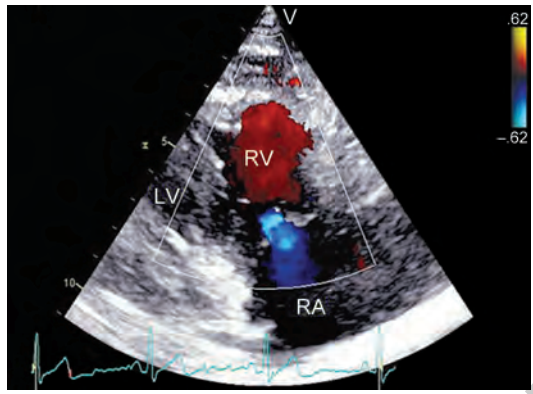

FIG. 8: Right ventricular (RV) inflow view.

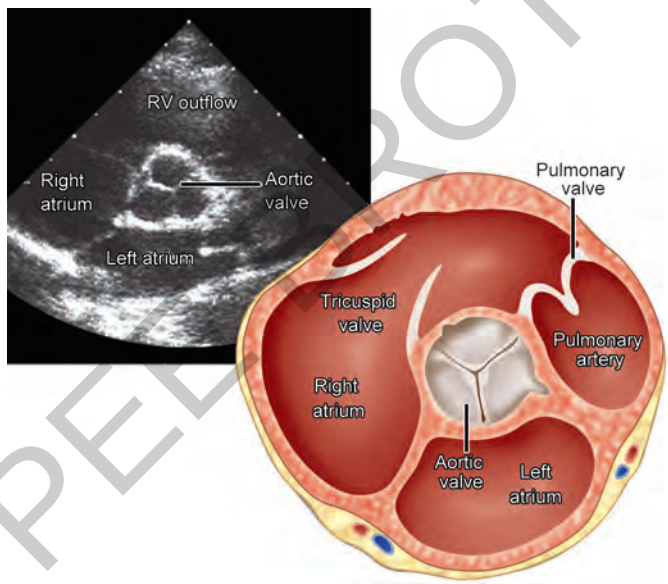

FIG. 9: Parasternal short-axis view aortic valve level.

JAYPEE BROTHERS

- Moving the transducer superiorly with a slight cranial angulation provides a cross-section of the aortic root (commonly referred to "circle and sausage" view)
- Coronary arteries are best visualized using a higher transducer frequency.
- *Purpose:*
  - 2D: Aortic valve, RVOT, pulmonary valve pathology
  - Color: To detect perimembranous/supracristal VSD, RVOT stenosis, TR
- *Measurements:*
  - Pulmonary valve annulus size

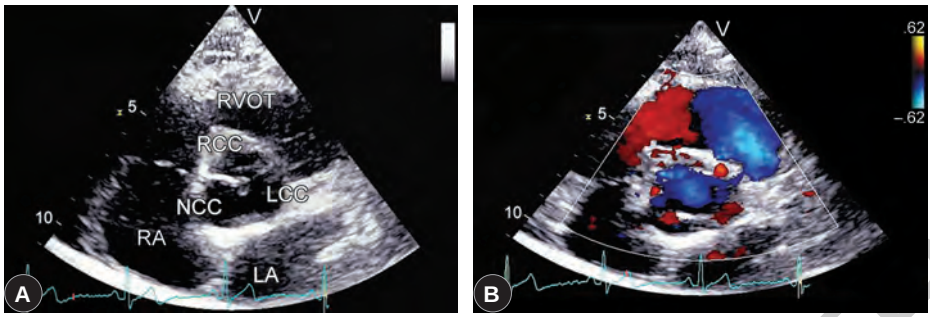

FIGS. 10A AND B: Parasternal short-axis view (semilunar valves).

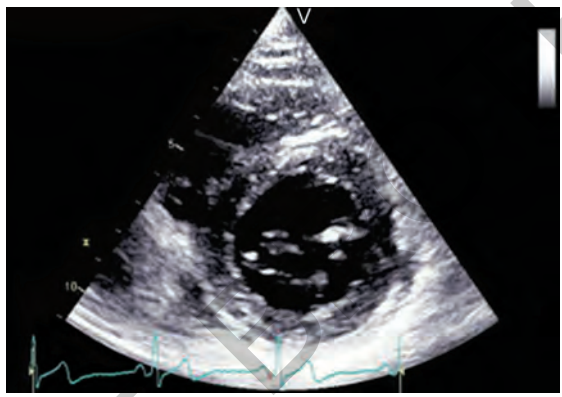

FIG. 11: Parasternal short-axis view (mitral valve level).

PARASTERNAL SHORT AXIS VIEW (MITRAL VALVE LEVEL)

- Characterized by a "fish mouth" appearance of the anterior and posterior mitral leaflets
- *Purpose:*
  - RWMA
  - Mitral valve end-on view for the assessment of mitral valve pathologies such as prolapse, MS (planimetry, commissures, etc.)
- *Measurements:*
  - Mitral valve area in those with MS
  - Optional: 2D circumferential and radial strain, basal rotation

PARASTERNAL SHORT AXIS VIEW (PAPILLARY MUSCLE LEVEL)

- *Purpose:*
  - Assessment of LVEF
  - RWMA-LV mass estimation
  - Papillary muscle geometry and morphology

JAYPEE BROTHERS

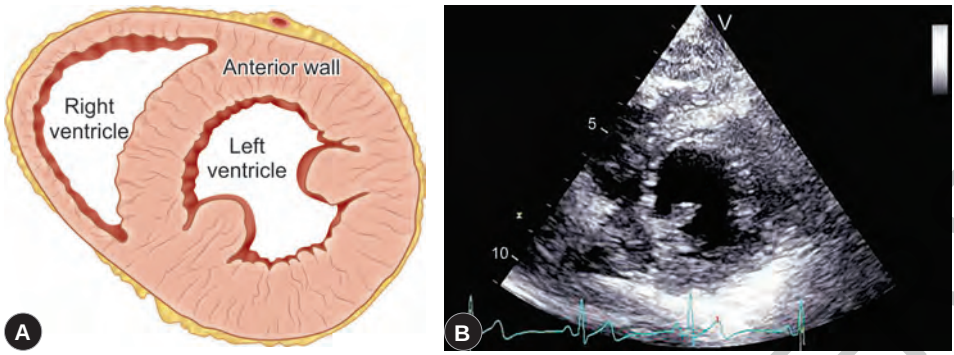

FIGS. 12A AND B: Parasternal short-axis view (papillary muscle level).

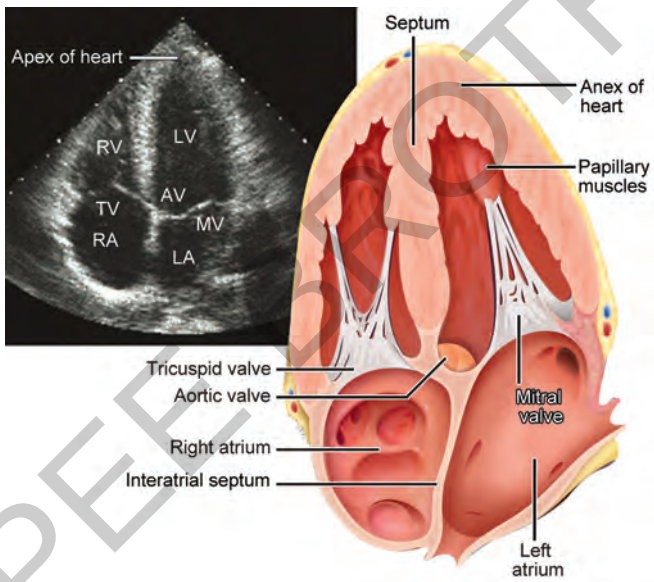

FIG. 13: Apical four-chamber view.

- *Measurements:*
  - Optional: LV mass calculation
  - 2D circumferential and radial strain, basal rotation

APICAL FOUR-CHAMBER VIEW

- Acquired with the patient positioned in the steep left lateral decubitus position.
- Apical pulse is palpated and the probe positioned slightly lateral to this position.
- Orientation marker is positioned at the 5 o'clock position to image the four chambers of the heart.
- Patient may be requested to suspend respiration at end-expiration to reduce translational disturbances.

JAYPEE BROTHERS

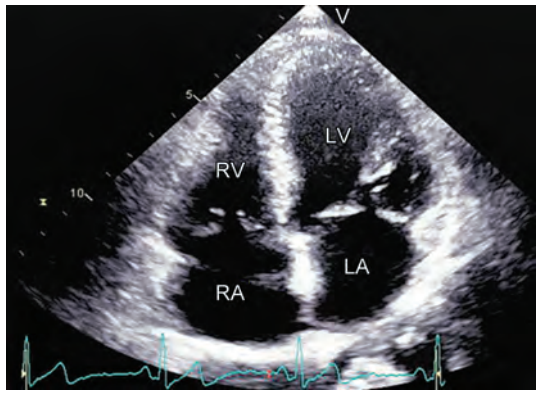

FIG. 14: Apical four-chamber view.

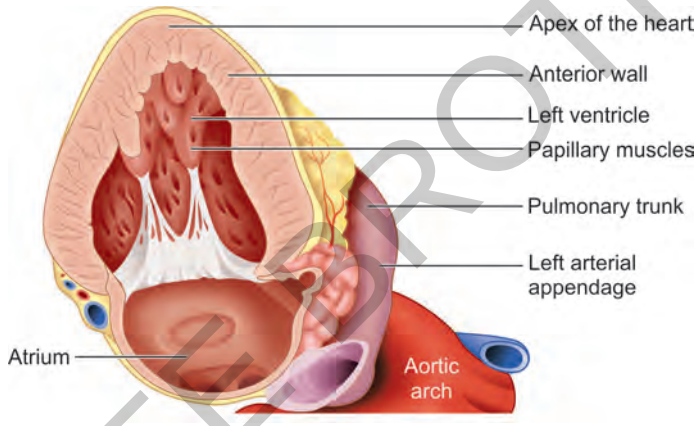

FIG. 15: Apical four-chamber view.

- *Purpose:*
  - Overview of chambers
  - Pericardial or extracardiac pathology
  - ASD
- *Measurements:*
  - Mandatory: LV volume and EF by Simpson's method
  - LA, RA, RV diameters; LA area
  - Optional: RA area, RV fractional shortening; LV length; 2D longitudinal strain

APICAL TWO-CHAMBER VIEW

- Obtained from the focused four-chamber view by rotating the transducer counterclockwise by approximately 60°.
- Provides a complete visualization of the anterior wall to the right of the display and the inferior wall to the left.
- *Purpose:*
  - RWMA in anterior and inferior wall

JAYPEE BROTHERS

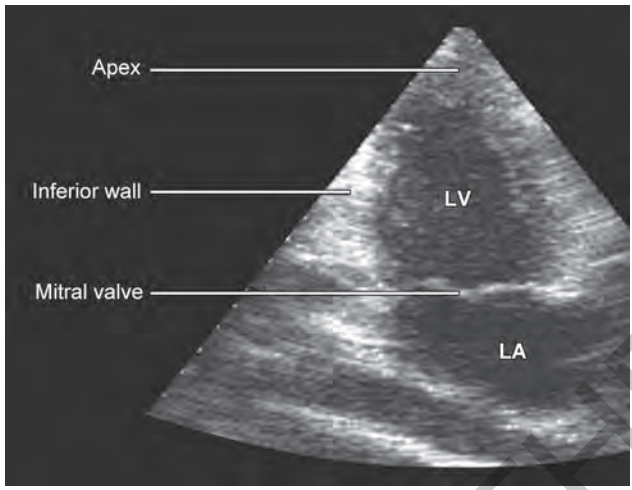

FIG. 16: Apical two-chamber view.

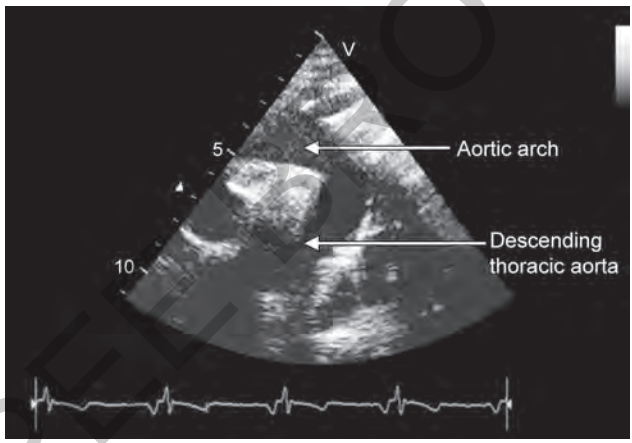

FIG. 17: Suprasternal view.

- *Measurements:*
  - Mandatory: LV volume and EF by Simpson's method
  - Optional: 2D longitudinal strain

SUPRASTERNAL VIEW

- Obtained by placing the transducer in the suprasternal notch with the orientation marker pointing toward the patient's left shoulder.
- With a slight anterior angulation, the aortic arch and branch vessels are seen.
- Moving from proximal to distal arch, the aortic arch first gives rise to the brachiocephalic artery, followed by the common carotid and the left subclavian artery, respectively.
- *Purpose:*
  - Linear measurements of aortic arch and isthmus

JAYPEE BROTHERS

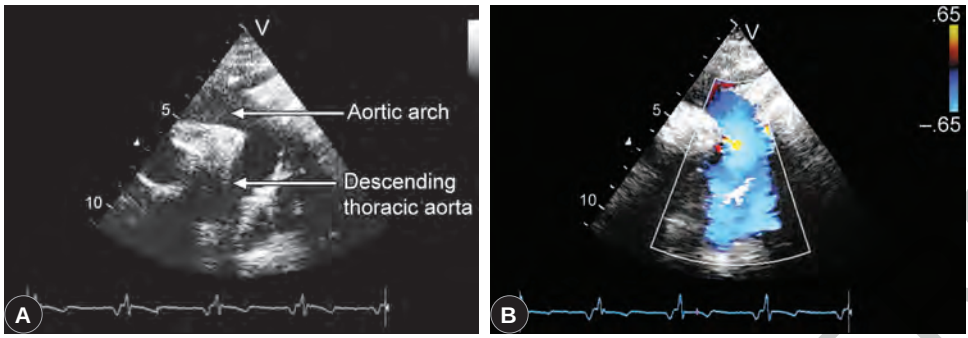

FIGS. 18A AND B: Suprasternal view.

BOX 1: Frequent causes of acute chest pain in patients presenting in the emergency room.

- Acute coronary syndrome
- Aortic dissection
- Pulmonary embolism
- Pericarditis
- Myocarditis
- Pneumothorax
- Aortic stenosis
- Hypertrophic cardiomyopathy
- Takotsubo cardiomyopathy
- Mitral valve prolapse

- *Color:*
  - Color M-mode for qualitative assessment of diastolic flow reversal in case of AR
  - Descending aorta PW for diastolic flow reversal
  - CW Doppler for coarctation gradient

ROLE OF ECHOCARDIOGRAPHY IN ACUTE CHEST PAIN SYNDROMES

- Chest pain accounts for about 8% of all emergency room visits. The major life-threatening cardiovascular emergencies presenting as chest pain are:
  - Acute coronary syndrome
  - Aortic dissection
  - Acute pulmonary embolism

REGIONAL WALL MOTION ABNORMALITY

- Normal left ventricular wall motion consists of simultaneous myocardial thickening and endocardial excursion so as the cavity size decreases in a symmetrical manner.

JAYPEE BROTHERS

TABLE 2: Regional wall motion abnormality scoring.			
Score	**Wall motion**	**Endocardial motion**	**Wall thickening**
1	Normal	Normal	Normal (>30%)
2	Hypokinesis	Reduced	Reduced (<30%)
3	Akinesis	Absent	Absent
4	Dyskinesis	Outward	Thinning
5	Aneurysmal	Diastolic deformity	Absent or thinning

BOX 2: Conditions other than coronary artery disease presenting with regional wall motion abnormalities on the resting echocardiographic study.

- Acute myocarditis
- Cardiomyopathies
- Left bundle branch block
- Pacemaker
- Right ventricular pressure or volume overload
- Takotsubo cardiomyopathy

- Interruption of normal myocardial contraction due to ischemia (reduced blood supply) or infarction (complete cessation of blood supply) results in abnormality in systolic endocardial thickening termed as "wall motion abnormality".

DEFINITIONS

COMPLICATION OF ACUTE MYOCARDIAL INFARCTION

- Hemodynamic states:
  - Globally reduced LV contractility
  - Right ventricular infarction
  - Hypovolemia
  - Ischemic MR
- Mechanical complications:
  - Papillary muscle rupture
  - Ventricular septal rupture
  - Free wall rupture and tamponade
  - Left ventricular aneurysm
  - Mural thrombus

JAYPEE BROTHERS

for detailed information on medicine books, visit our website www.jaypeebrothers.com, for detailed information on medicine books, visit our website www.jaypeebrothers.com, for d

IACM
Clinical Medicine Update 2022

Salient Features

- The book *IACM Clinical Medicine Update 2022* is published with the aim to give insight of the clinical medicine to the readers as we are losing with the time and depending more on technologies but we have to remember that technologies are as important as clinical medicine and are inseparable part of the clinical medicine.
- The chapters of this book are written by the eminent physicians of the country of great repute who have applied the principles and theme of this conference, "blending technology and clinical medicine" and accordingly written the chapters with their expertise on the subject to ensure to meet the needs of a practising physician in their daily practice.
- This book can prove to be of special interest for the postgraduate students in medicine and practising physicians to update their knowledge and transforming this knowledge into their day-to-day practice for the benefit of patients.



KK Pareek MD FICP FRCP (Glasg, Edin, Lond) FFIACM FGSI FRSSDI FACP is a Senior Consultant in Medicine, Head of the Department of Medicine and Director SN Pareek Memorial Hospital (A multispeciality 100-bedded hospital) Kota, Rajasthan, and is a Past President of Association of Physicians of India, Past Dean—Indian College of Physicians, President Elect—Indian Association of Clinical Medicine, Founder Chairman, RSSDI—Rajasthan Chapter, Past Chairman and Honorary Secretary API—Rajasthan Chapter, Past President IMA Kota. Organized many conferences at national level and CME programs at the district level. Organizing Chairman, National Annual Conference of RSSDI at Jaipur (2019). Also hosted National APICON 2022 in Jaipur as Organizing Chairman. His areas of interest are diabetes, infectious disease, and tropical medicine. He has contributed many chapters in Medicine Updates. He was the Chief Editor of Medicine Update, and Progress of Medicine, 2016 and Chief Editor of Medicine Update, Volume I and II in 2019. Edited Monograph on Pyrexia of unknown origin, book on "interesting Clinical Cases in Medicine" and "IACM Clinical Medicine Update 2022". Also delivered many guest lectures and he has been awarded many "Orations and Guest" lectures in different National Conferences in last 35 years. He is a very popular physician in Rajasthan and instrumental in forming the state chapters of Rajasthan API and RSSDI.

Printed in India

Available at all medical bookstores
or buy online at www.jaypeebrothers.com

JAYPEE BROTHERS
Medical Publishers (P) Ltd.
EMCA House, 23/23-B, Ansari Road,
Daryaganj, New Delhi - 110 002, INDIA
www.jaypeebrothers.com

Join us on facebook.com/JaypeeMedicalPublishers

Shelving Recommendation
MEDICINE

ISBN 978-93-5465-869-3