ur website www.jaypeebrothers.com, for detailed information on anatomy books, visit our website www.jaypeebrothers.com

diginerve
A Jaypee Initiative
Your Guide at Every Step
Video Lectures | Notes | Self-Assessment
Scan to download the App

Asterion
The Practical Handbook of
ANATOMY

As per the Competency-based Medical Education Curriculum (NMC)



3rd Edition

Harishanker JS
Ajai Sasi
Aswathy BI

Forewords
Kanchan Kapoor
VS Akbar Sherif

JAYPEE

Contents

1. Histology 1

Microscope 2
- Parts of microscope 2
- Slide preparation and staining 2

Epithelium 3
- General functions of epithelial cells 3
- Simple squamous epithelium 4
- Simple cuboidal epithelium 4
- Simple columnar epithelium 7
- Surface specializations of the epithelial cells 7
- Pseudostratified columnar epithelium 8
- Stratified epithelium 8
- Transitional epithelium 8

Cartilage 11
- General aspects 11
- Hyaline cartilage 12
- Elastic cartilage 15
- Fibrocartilage 16

Bone 19
- General aspects 19
- Bone transverse section 19
- Bone longitudinal section 20

Muscle 23
- General aspects 23
- Skeletal muscle 23
- Smooth muscle 24
- Cardiac muscle 27

Blood Vessels 28
- General aspects 28
- Arteries 28
- Large artery or elastic artery 28
- Medium-sized artery 31
- Veins 32
- Large vein 32
- Medium-sized vein 35

Lymphoreticular System 36
- Lymph node 36
- Palatine tonsil 39
- Spleen 40
- Thymus 43

Nervous Tissue 44
- Nerve fiber 44
- Spinal ganglion 47
- Sympathetic ganglion 48

Oral Cavity 51
- Serous salivary gland 51
- Mucous salivary gland 52
- Mixed salivary gland 55
- Tongue 56

Alimentary System 59
- General aspects 59
- Esophagus 59
- Stomach fundus 60
- Stomach pylorus 63
- Small intestine 64
- Duodenum 64
- Jejunum 67
- Ileum 68
- Colon 71
- Appendix 72

Liver and Pancreas 75
- Liver 75
- Gallbladder 76
- Pancreas 79

Respiratory System 80
- Trachea 80
- Lung 83

Renal System 84
- Kidney 84
- Ureter 87
- Urinary bladder 88

Skin 91
- General aspect 91
- Thick skin 91
- Thin skin 92

Special Senses 95
- Cornea 95
- Retina 96
- Optic nerve 99

Female Reproductive System 100
- Mammary gland 100
- Ovary 103
- Fallopian tube 104
- Uterus 107
- Placenta 108
- Umbilical cord 111

Male Reproductive System 112
- Testis 112
- Epididymis 115
- Vas deferens 116
- Prostate gland 119

Endocrine System 120
- Adrenal gland 120
- Thyroid gland 123

JAYPEE BROTHERS

- Parathyroid gland 123
- Pituitary gland 124

Central Nervous System 127
- Spinal cord 127
- Cerebellum 128
- Cerebrum 131

2. Embryology 133

General Embryology 134
- Embryogenesis 134
- Implantation 134
- Decidua 135
- Embryonic disc and germ layers 135
- Intraembryonic mesoderm 135
- Somites 136
- Notochord 136
- Neurulation 136
- Neural crest 137
- Lamina terminalis 137
- Placenta 137

Systemic Embryology 138
- Pharyngeal arches 138
- Palate 138
- Face 140
- Upper lip 140
- Tongue 141
- Thyroid gland 141
- Lungs 141
- Heart tube 142
- Right atrium 142
- Interatrial septum 142
- Fallot's tetralogy 143
- Diaphragm 143
- Gut 143
- Esophagus 143
- Stomach 143
- Meckel's diverticulum 144
- Pancreas 144
- Liver and gallbladder 144
- Kidney 144
- Urinary bladder 145
- Uterus 145
- Uterine tube 145
- Development of gonads (testis and ovaries) 146
- Rectum and anal canal 147
- Prostate 147
- Amniocentesis 147

Genetics 149
- Barr body (sex chromatin) 149
- Chromosome banding 149
- Karyotyping 149
- Nondisjunction 150
- Klinefelter syndrome 150
- Turner's syndrome 150
- Down syndrome 151

3. Radiology 153

Basics 154
- Imaging modalities 154

Imaging Modalities with Ionizing Radiations 154
- Concept of radio-opacity 154
- Plane radiography 154
- How to read a chest radiograph (PA view)? 155
- Contrast radiography 156
- Barium studies 156
- Barium swallow 156
- Barium meal 157
- Barium enema 157
- Iodine studies 157
- Intravenous pyelography 158
- Water-soluble contrast study 158
- Hysterosalpingography 158
- Computed tomography 158
- Positron emission tomography scan 159

Imaging Modalities with Nonionizing Radiations 159
- Ultrasonography 159
- Doppler studies 159
- Magnetic resonance imaging 159

4. Osteology 177
- Introduction to bones 178
- Markings on the bones 178
- Age and sex determination with bones 179
- Clinical aspects of osteology 179

5. Surface Marking 203

Upper Limb 204
- Axillary artery 204
- Brachial artery 204
- Radial artery 204
- Ulnar artery 204
- Axillary nerve 204
- Median nerve 204
- Musculocutaneous nerve 205
- Radial nerve 205
- Ulnar nerve 205
- Flexor retinaculum 205
- Extensor retinaculum 205
- Superficial palmar arch 206
- Deep palmar arch 206

Lower Limb 206
- Femoral artery 206
- Popliteal artery 206
- Posterior tibial artery 206
- Dorsalis pedis artery 206
- Saphenous opening 206
- Great saphenous vein 206
- Sciatic nerve 207
- Superior extensor retinaculum 207
- Inferior extensor retinaculum 207
- Flexor retinaculum 207

JAYPEE BROTHERS

Thorax 208
- Heart 208
- Arch of aorta 208
- Lungs 208
- Pleural reflection 209
- Esophagus 209
- Thoracic duct 210

Abdomen and Pelvis 210
- Abdomen planes and quadrants 210
- Inguinal canal 210
- Stomach 211
- Liver 211
- Fundus of gallbladder 211
- Abdominal aorta 212
- Spleen 212
- Root of mesentery 212
- Mcburney's point 212
- Kidney 212
- Ureter 212

Head and neck 213
- Common carotid artery 213
- External carotid artery 213
- Facial artery 213
- Facial vein 213
- Internal jugular vein 213
- External jugular vein 213
- Facial nerve 214
- Parotid gland 214
- Parotid duct 214

6. Spotters and Discussion Topics 215

Spotters 216
- Upper limb 216
- Lower limb 216
- Thorax 217
- Abdomen and pelvis 218
- Head and neck 218
- Brain 220

Discussion Topics 220
- Discussion topics 220

7. Red Alert 221

Anatomy Examination Paper 1—

Important Topics 222
- Upper limb 222
- Lower limb 222
- Thorax 223
- General histology 223
- General embryology 223
- General anatomy 223

Anatomy Examination Paper 2—

Important Topics 224
- Head and neck 224
- Neuroanatomy 224
- Abdomen and pelvis 225
- Histology 225
- Systemic embryology 226

Important Diagrams 227
- Upper limb 227
- Thorax 227
- Lower limb 227
- Abdomen and pelvis 227
- Head and neck 228

Index *229*

JAYPEE BROTHERS

4 CHAPTER Osteology

OUTLINE

- Introduction to Bones
- Markings on the Bones
- Age and Sex Determination with Bones
- Clinical Aspects of Osteology
- Atlas of Bones

JAYPEE BROTHERS

INTRODUCTION TO BONES

- An adult's skeleton contains 206 bones.
- Babies have more bones than adults. When a baby grows up, some of the bones fuse together to form one bone.
- A matured adult skeleton can be divided into axial and the appendicular skeleton.

Axial Skeleton

It consists of the bones that form the vertical axis of the body. Axial skeleton has 80 bones.

- Skull bones—22
- Auditory ossilcles—malleous, incus and stapes one each in both ears—6
- Hyoid bone
- Vertebral column—cervical, thoracic and lumbar vertebrae, sacrum and coccyx.
- 12 pairs of ribs and sternum.

Appendicular Skeleton

It consists of all the bones of the arms and legs and those bones that attach them to the axial skeleton.

- Appendicular skeleton has 126 bones.
- Each upper limb have 30 bones: Humerus, radius, ulna, carpals—8, metacarpals—5, phalanges—14
- Each lower limb have 30 bones: Femur, patella, tibia, fibula, tarsals—7, metatarsals—5, phalanges—14
- Pectoral girdle has both scapula and clavicle each side.
- Pelvic girdle is made of two hip bones from both sides. Each pelvic bone is made of ilium, ischium and pubis.

MARKINGS ON THE BONES

Parts of a Bone

Long bones are composed of four distinct parts:

1. Head—epiphysis
2. Neck—metaphysis
3. Body—diaphysis
4. Articular surface—making joints

Projections and Parts

- *Condyle* is a rounded knob that form articulation with other bones.
- *Epicondyle* is a bony area on or above a condyle. It provides area for a muscle or ligament to attach.
- *Process* is a bulging bony outgrowth of a larger bone.
- *Protuberances* are similar to processes. Appears as swelling, bulging or protruding parts of bone.
- *Tubercle* is a small rounded prominence, usually give site for tendon or ligament to attach.
- *Tuberosity* is larger comapred to tubercle. They are found in varying shapes and texture.
- *Trochanter* is a very large, blunt, irregularly shaped process of the femur that serves as an attachment point for a couple of muscles and ligaments.
- S*pine/spinous process* is a sharp, slender projection of the bone in which muscles or ligaments attach.
- *Linea* refers to a subtle, long, and narrow marking which distinguishes itself in elevation, color or texture from surrounding tissues.
- *Facet* is a flat smooth area which serves as an articular surface.
- *Crests* are prominent, raised edges of a bone.
- *Ridges* are linear elevations, margins or borders.

Depressions and Openings

- *Foramina* are holes or openings in a bone through which nerves and blood vessels pass.
- *Fissures* are open slits/grooves/depressions in a bone, housing nerves and blood vessels.
- *Meatus* is a short, tube-like passage extending into the bone.
- *Fossa* is a depression on a bone surface which is often broad and shallow. It is seen supporting brain structures or receiving another bone for articulation.
- *Fovea* refers to a pit or depression on bone. Compared with fossa, it is much smaller.
- *Notch* is an indentation at the edge of a bone.
- *Sulci* are groove-like areas and can be traced through the bone where nerves or vessels runs safely from outside compression forces.
- A *sinus* is a cavity or hollow space.

JAYPEE BROTHERS

SKULL

SKULL: ANTERIOR VIEW

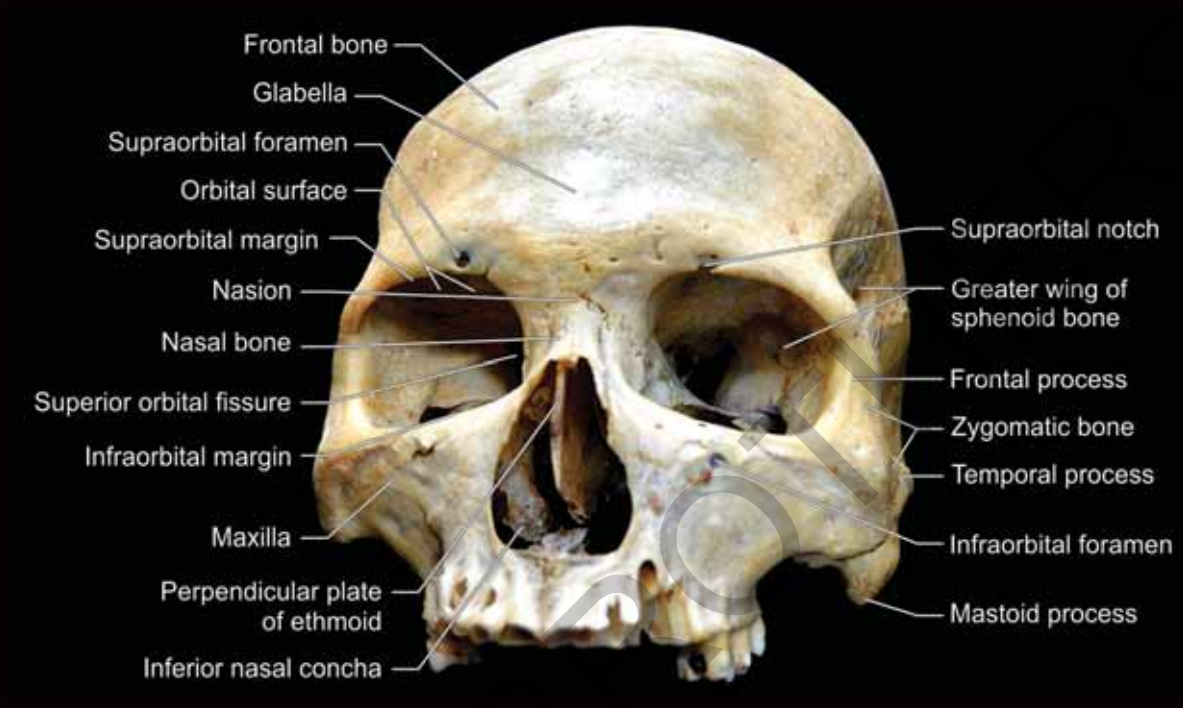

SKULL: POSTERIOR VIEW

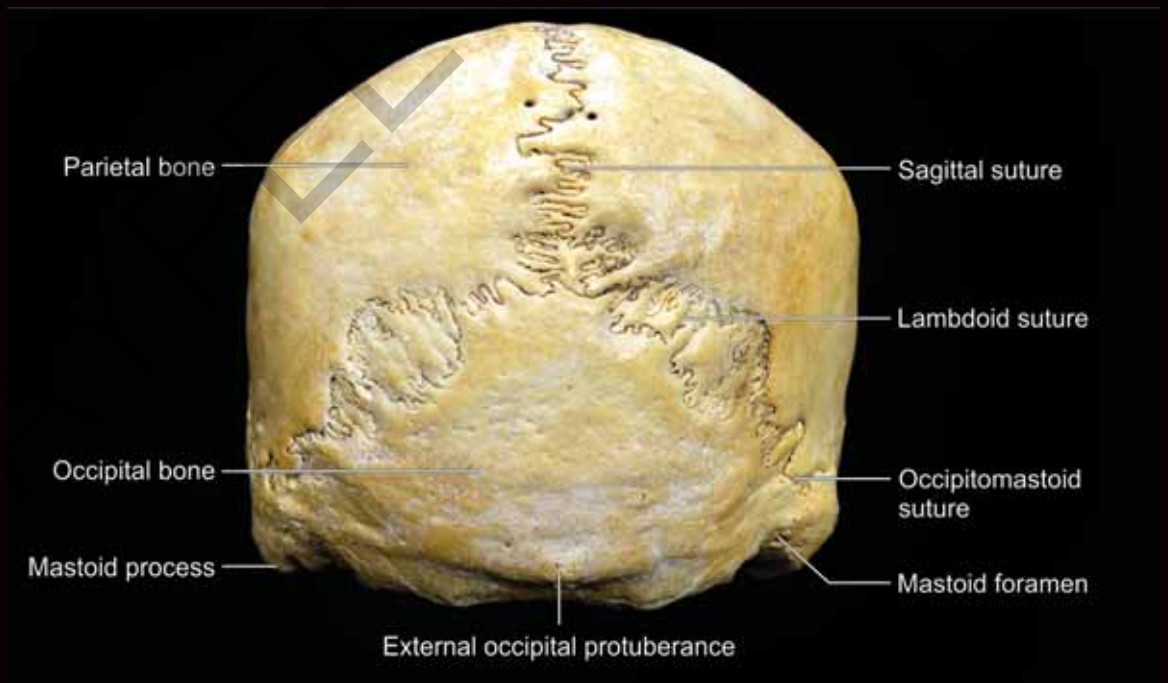

Structures Passing Through Foramina

- *Incisive fossa*: Nasopalatine nerve, sphenopalatine vessels
- *Greater palatine foramen*: Greater palatine nerve and vessels
- *Lesser palatine foramen*: Lesser palatine nerve and vessels
- *Foramen lacerum*: Greater petrosal nerve
- *Foramen ovale*: Lesser petrosal nerve, mandibular nerve, accessory meningeal artery
- *Foramen spinosum*: Middle meningeal vessels, meningeal branch of mandibular nerve
- *Carotid canal*: Internal carotid artery, carotid autonomic plexus
- *Petrotympanic fissure*: Chorda tympani of facial nerve
- *Tympanic canaliculus*: Tympanic branch of glossopharyngeal nerve
- *Mastoid canaliculus*: Auricular branch of vagus nerve
- *Stylomastoid foramen*: Facial nerve
- *Jugular fossa*: Glossopharyngeal nerve, vagus nerve, accessory nerve, superior bulb, internal jugular vein
- *Mastoid foramen*: Mastoid emisary vein, posterior meningeal artey
- *Hypoglossal canal*: Hypoglossal nerve
- *Foramen magnum*: Medulla oblongata, vertebral arteries and venous plexus, spinal accessory nerves.

FLOOR OF CRANIAL CAVITY: POSTEROSUPERIOR VIEW

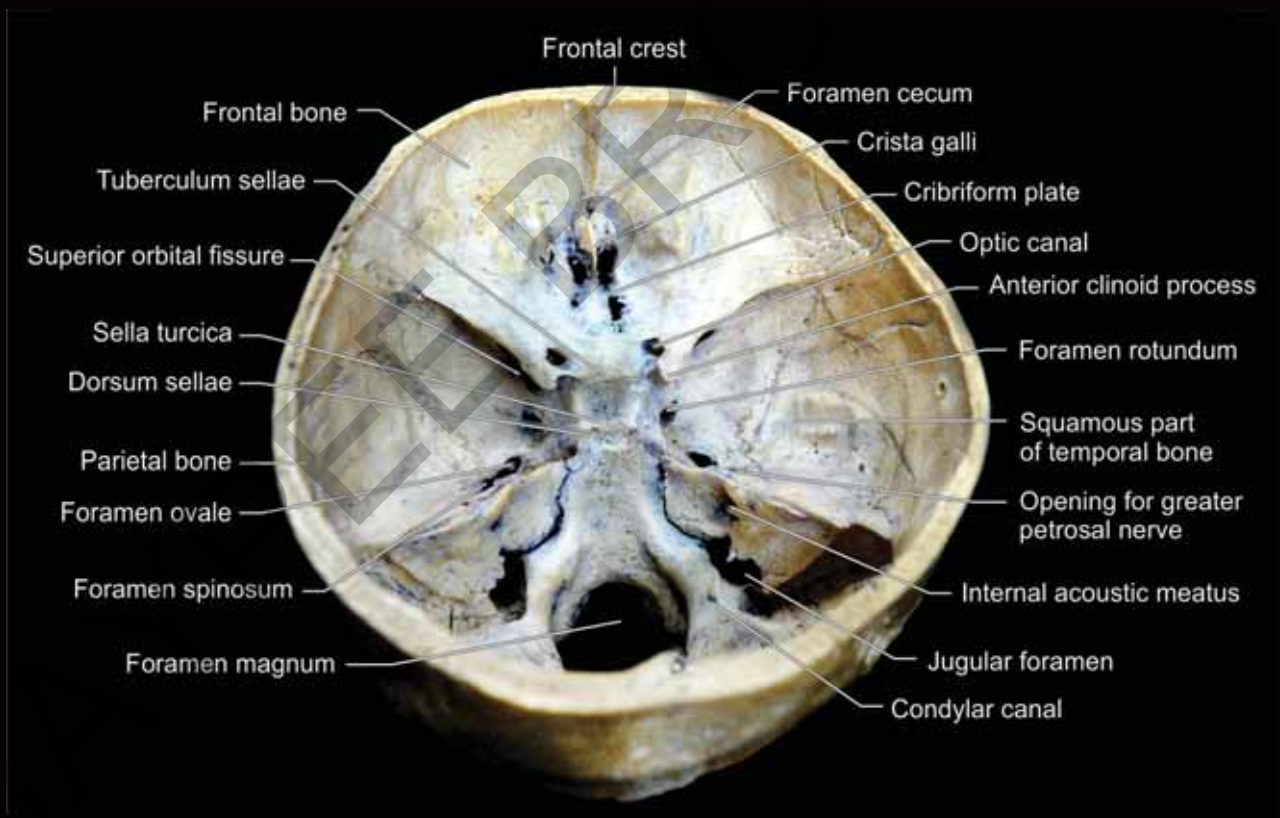

MANDIBLE: ANTERIOR VIEW

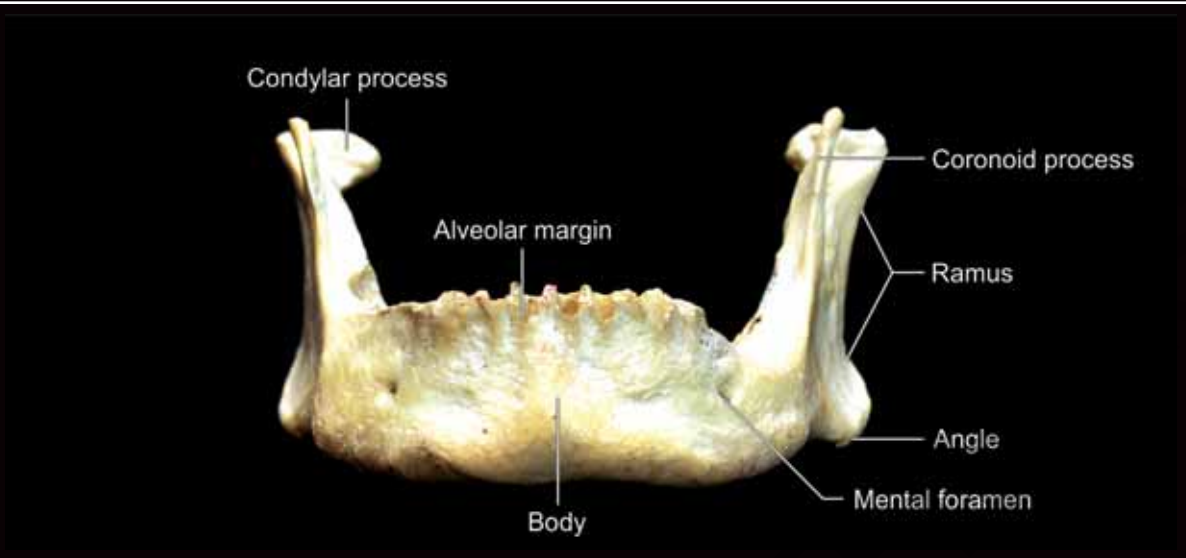

MANDIBLE: LATERAL VIEW

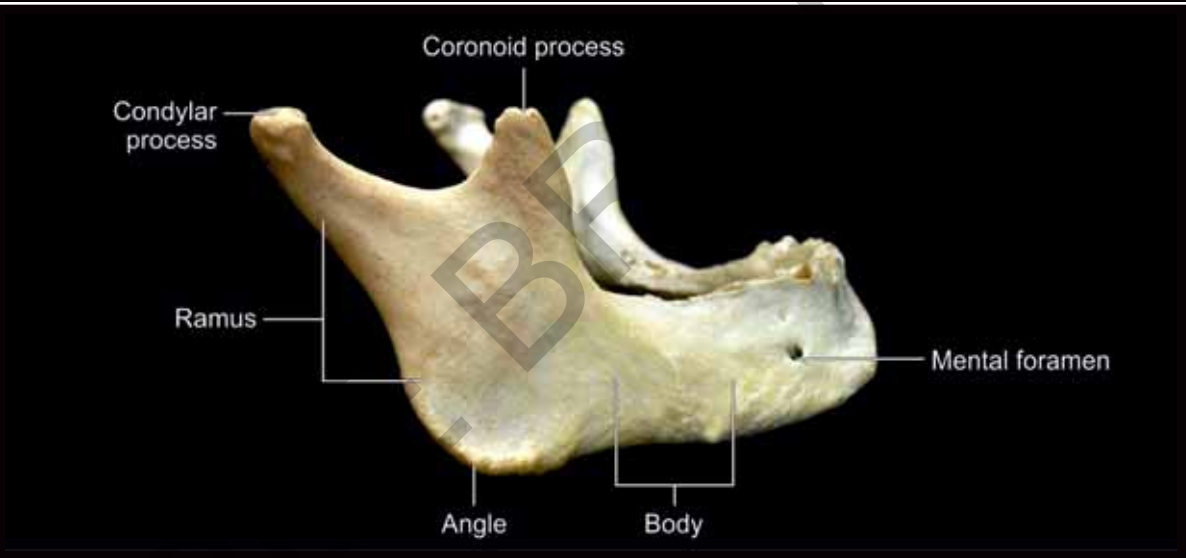

MANDIBLE: POSTERIOR VIEW

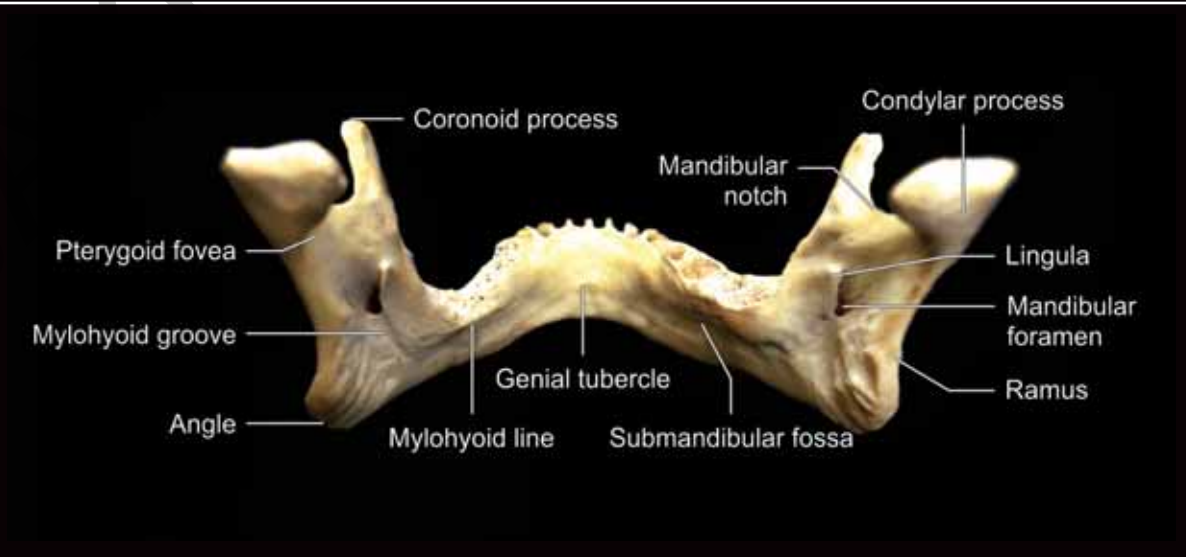

UPPER LIMB

CLAVICLE: SUPERIOR VIEW

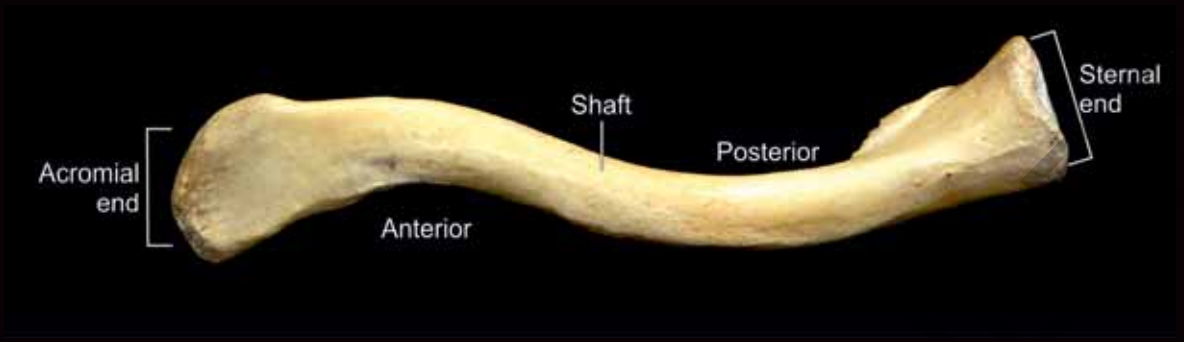

CLAVICLE: INFERIOR VIEW

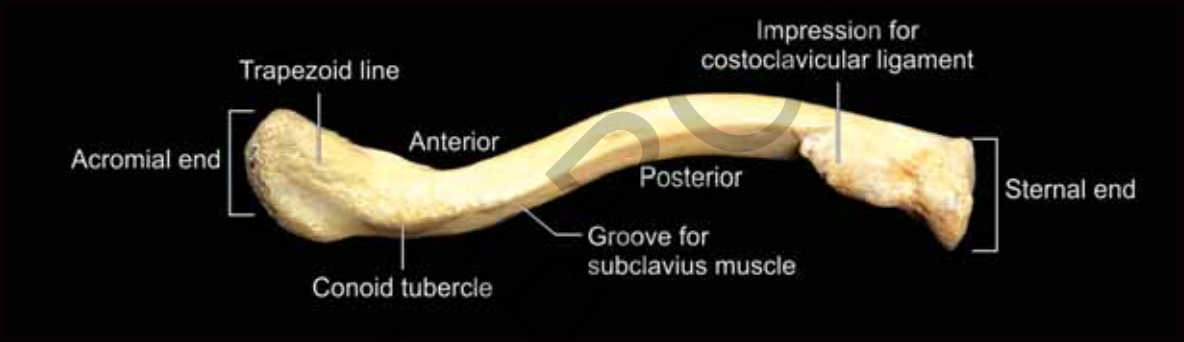

SCAPULA: ANTERIOR VIEW

Left Scapula Anterior View

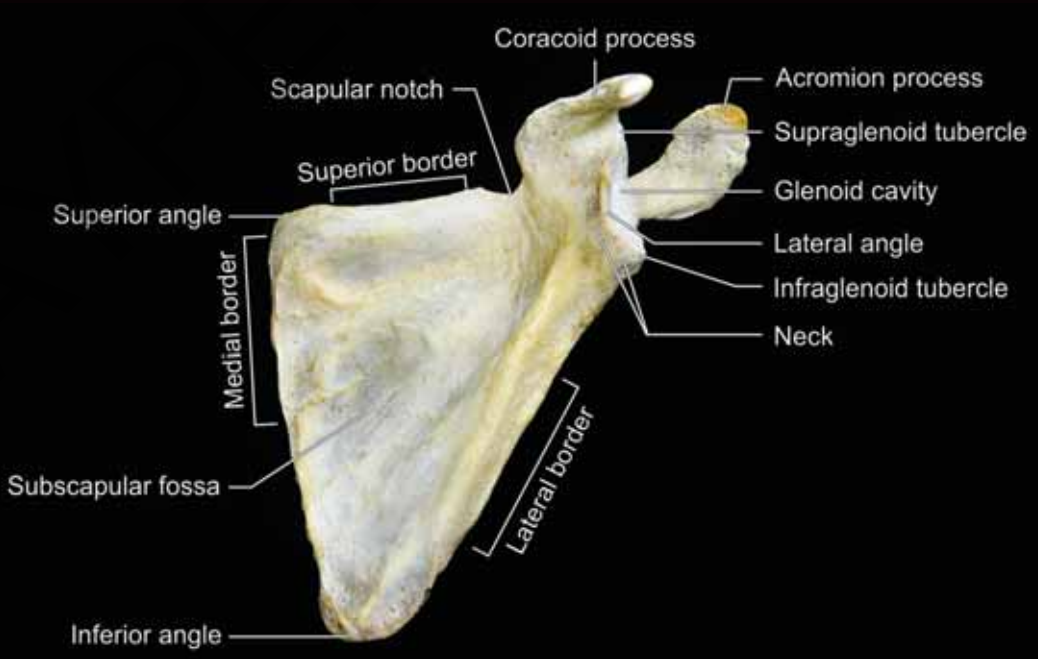

SCAPULA: POSTERIOR VIEW

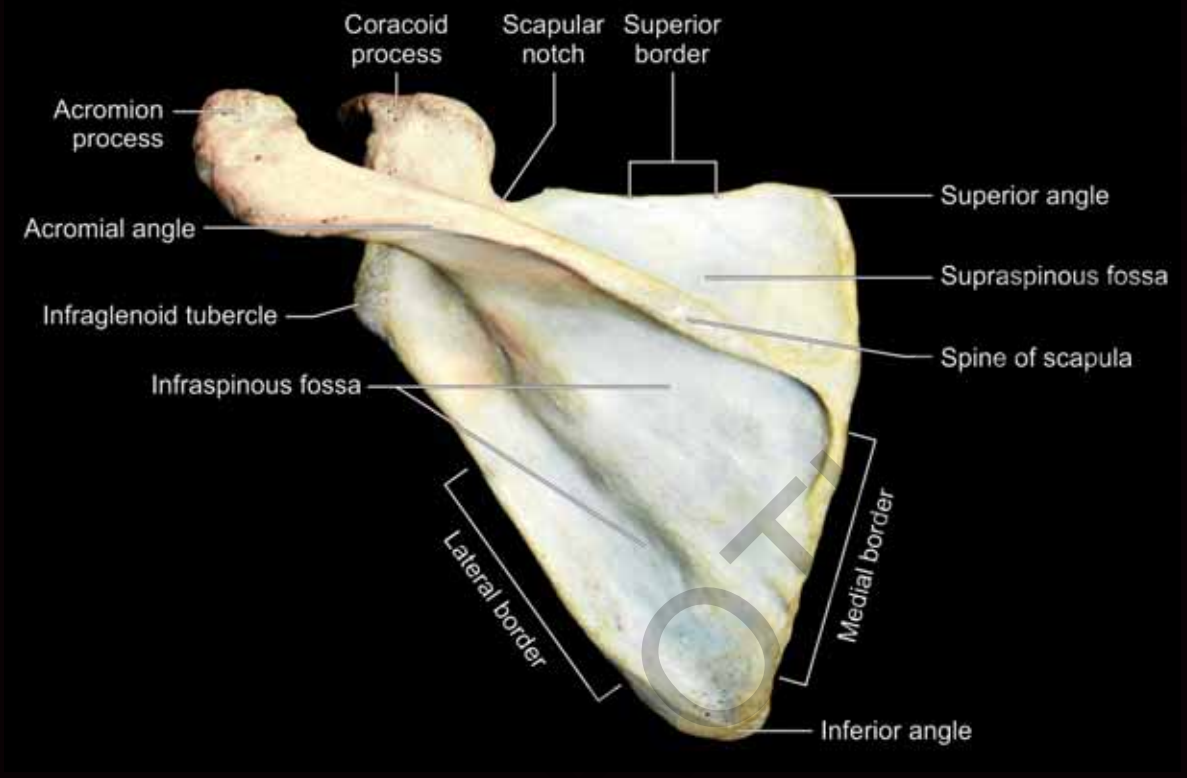

SCAPULA: LATERAL VIEW

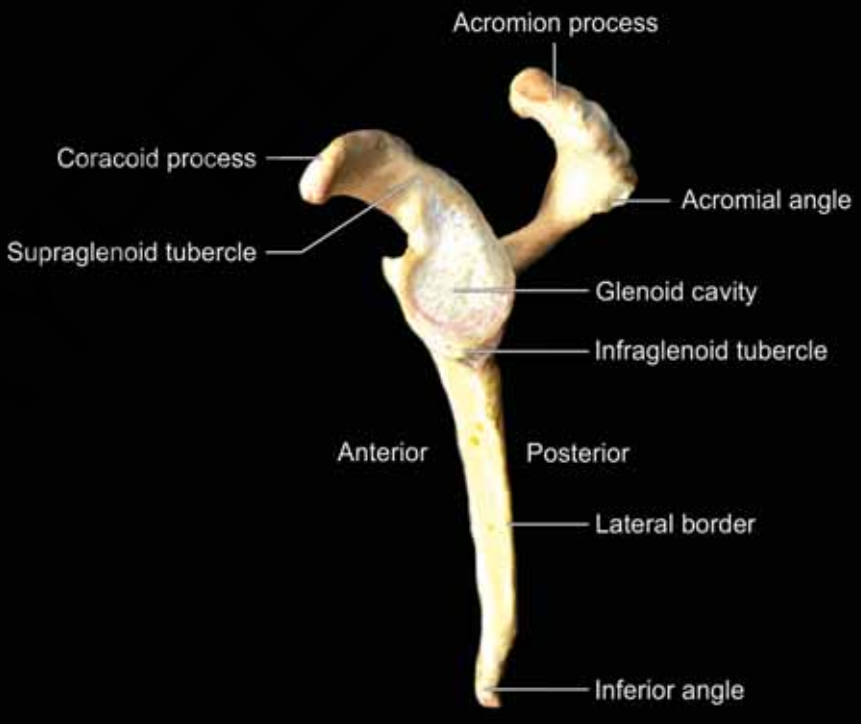

HAND: DORSAL VIEW



LEFT HAND DORSAL VIEW

LOWER LIMB

PELVIS: ANTERIOR VIEW

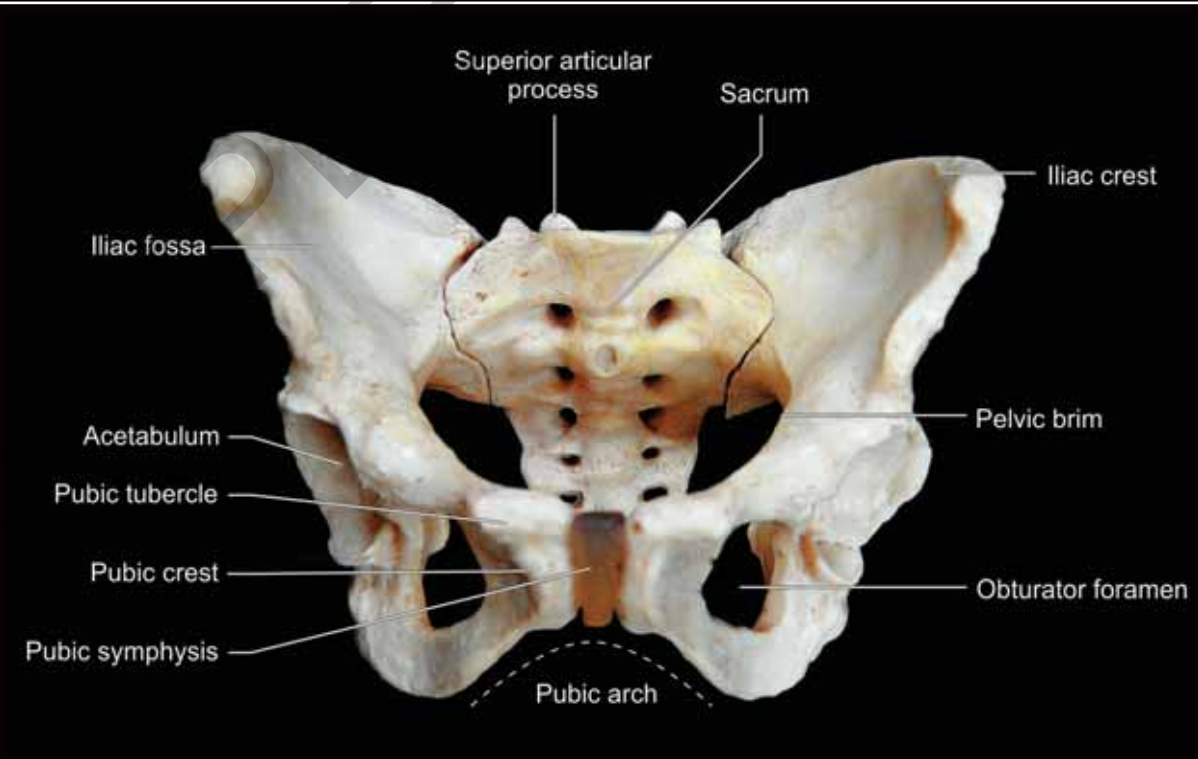

for detailed information on anatomy books, visit our website www.jaypeebrothers.com, for detailed information on anatomy b

Asterion
The Practical Handbook of
ANATOMY

Salient Features

- Concise and thoroughly revised chapters
- The entire book has been made CBME curriculum compliant
- New and better images, diagrams and flowcharts are included for better understanding of the concepts
- Crisp, updated and easier to follow content
- Updated and new hand drawn diagrams and other contents in histology chapter
- Routinely used imaging modalities pictures are included in Radiology chapter other than plain radiographs
- Clinical anatomy aspects are added and updated to the Osteology chapter
- Embryology chapter updated with required topics and flowcharts
- New topics and diagrams are added to Surface Marking chapter

About the Authors

Harishanker JS, Ajai Sasi and **Aswathy BI** completed their MBBS from Malabar Medical College, Kozhikode, Kerala, India. Harishanker JS is currently pursuing MBA. Ajai Sasi is pursuing MD in pediatrics from KMCT Medical College, Kozhikode, Kerala. Awasthy BI is currently pursuing MPH from Sree Chitra Tirunal Institute for Medical Sciences and Technology (SCTIMST), Thiruvananthapuram, Kerala. Harishanker JS and Ajai Sasi with Avinash N had authored other title *Exam Preparatory Manual for Undergraduates in Anatomy* with Jaypee Brothers Medical Publishers (P) Ltd.



Harishanker JS



Ajai Sasi



Aswathy BI

Printed in India

Available at all medical bookstores
or buy online at www.jaypeebrothers.com

JAYPEE BROTHERS
Medical Publishers (P) Ltd.
EMCA House, 23/23-B, Ansari Road,
Daryaganj, New Delhi - 110 002, INDIA
www.jaypeebrothers.com

Join us on facebook.com/JaypeeMedicalPublishers

Shelving Recommendation
ANATOMY

ISBN 978-93-5465-920-1