nformation on orthopaedics books, visit our website www.jaypeebrothers.com, for detailed information on orthopaedics books, visit our website www.jaypeebrothers.com

Scan to Download the App

diginerve
A Jaypee Initiative
Your Guide at Every Step
Video Lectures | Notes | Self-Assessment

Digital Content

Clinical Examination Videos



Musculoskeletal Examination
for Undergraduates

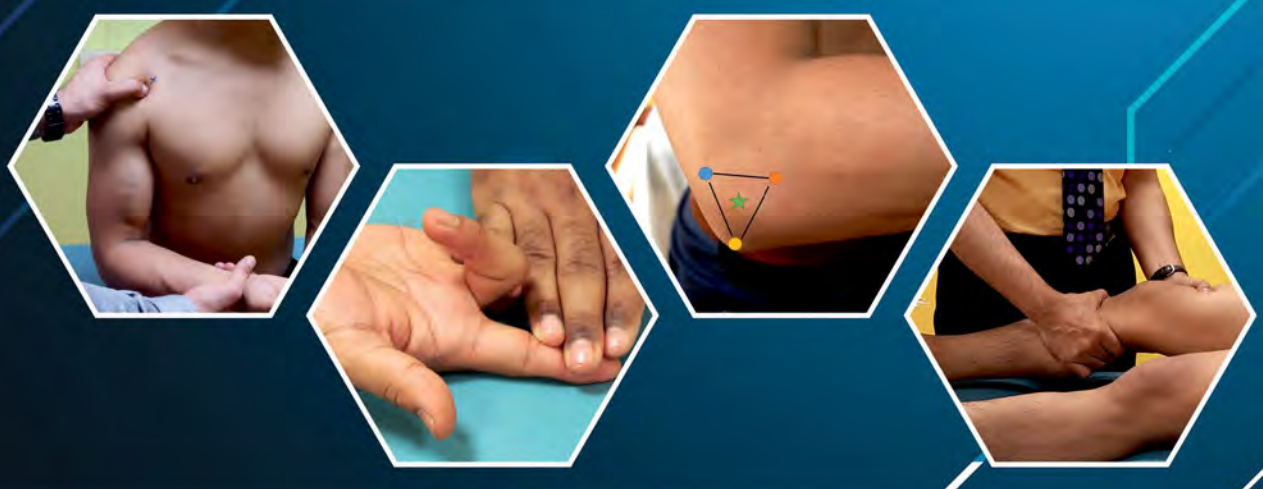

Vivek Pandey
Saktthi Shanmuganathan

Foreword
Sharath K Rao

JAYPEE

Contents

1. Basics of History Taking and Examination in Orthopaedics 1
- History Assessment in Orthopaedics 1
- Examination 10

2. Clinical Evaluation of Polytrauma and Acute Injury of Bones and Joints 18
- Polytrauma 18
- History 20
- General Assessment 22
- Local Examination 23
- Trauma-related Orthopaedic Emergencies 28

3. Clinical Evaluation of Diseased Long Bones and Joints 30
- History Taking in Long Bone Disease 30
- General and Systemic Examination 32
- Local Examination 32
- Differential Diagnosis 34
- Clinical Evaluation of Pathological Joints 39

4. Clinical Evaluation of the Shoulder Joint 50
- Surgical Anatomy and its Clinical Significance 50
- History and its Evaluation 51
- Examination 55
- Shoulder Examination Proforma 71
- Common Conditions Affecting Shoulder and their Salient Features 71

5. Clinical Evaluation of the Elbow Joint 76
- Relevant Surgical Anatomy and its Clinical Significance 76
- History and its Evaluation 79
- Examination 81
- Elbow Examination Proforma 92
- Common Conditions Affecting Elbow and their Salient Features 92

6. Clinical Evaluation of the Wrist and Hand 95
- Surgical Anatomy of the Wrist Joint and its Clinical Significance 95
- Surgical Anatomy of the Hand and its Clinical Significance 97
- History and its Evaluation 98
- Examination 103
- Wrist and Hand Examination Proforma 114
- Common Conditions Affecting Wrist-hand and their Salient Features 115

7. Clinical Evaluation of the Hip Joint 120
- Surgical Anatomy and its Clinical Significance 120
- History and its Evaluation 120
- Examination 125
- A Note on Abductor Mechanism and Trendelenburg Test 140
- Use of Cane in Hip Diseases 141
- Hip Examination Proforma 142
- Common Conditions Affecting Hip and their Salient Features 143

8. Clinical Evaluation of the Knee Joint 146
- Surgical Anatomy and Function of the Knee Joint 146
- History and its Evaluation 152
- Examination 155
- Knee Examination Proforma 173
- Common Conditions Affecting Knee and their Salient Features 174

9. Clinical Evaluation of the Foot and Ankle Joint 178
- Surgical Anatomy of Foot-ankle and its Clinical Significance 178
- History and its Evaluation 180
- Examination 184
- Foot-ankle Examination Proforma 196
- Common Conditions Affecting Foot-ankle and their Salient Features 197

10. Clinical Evaluation of the Spine 200
- Surgical Anatomy of Spine-spinal Cord and its Clinical Significance 200
- History and its Evaluation 205
- Examination 209
- Spine Examination Proforma 229
- Common Conditions Affecting Spine and their Salient Features 230

11. Clinical Evaluation of the Peripheral Nerves 236
- Surgical Anatomy of the Peripheral Nerve and its Clinical Significance 236
- History and its Evaluation 239
- Examination 241
- Peripheral Nerve Examination Proforma 270
- Common Deformities following Specific Nerve Injuries and Other Conditions 270

12. Clinical Evaluation of the Bone Tumors 272
- Classification of Bone Tumors 272
- History Taking in Bone Tumors 272
- Examination 276
- Bone Tumor Examination Proforma 279
- Important Bone Tumors (in Brief) 280

13. Clinical Evaluation of the Amputation Stump **283**
- Indications for Amputation 283
- The Scheme of History Taking in a Patient with Amputation Stump 283
- Examination 285
- Amputation Stump Examination Proforma 289

14. Clinical Evaluation of Gait and Various Patterns of Gait **290**
- Definition of Gait 290
- Phases of Gait 290
- Etiology of Gait Disturbance 290
- Commonly Encountered Gait Patterns 292

15. Clinical Evaluation of the Swelling, Scar, Sinus, and Ulcer **296**
- History and Examination of a Swelling 296
- Examination 298
- History and Examination of a Scar 305
- History and Examination of a Sinus 307
- History and Examination of an Ulcer 309

Index *315*

CHAPTER

2 Clinical Evaluation of Polytrauma and Acute Injury of Bones and Joints

INTRODUCTION

Trauma is the leading cause of death and disability in the first four decades and the third most common cause of death overall. This chapter will briefly focus on the concepts of polytrauma, triaging, advanced trauma life support (ATLS) protocol followed by assessment of acute injury of bone and joint in a stable patient.

POLYTRAUMA

Polytrauma does not merely imply fracture of multiple bones. These patients have involvement of multiple systems and are hemodynamically unstable.

Definition of Polytrauma

There are multiple definitions of polytrauma, such as:

1. When injury severity score is >18
2. There is hemodynamic instability or coagulopathy on admission
3. Involvement of more than one systems of the body

Polytrauma is both a surgical and a medical emergency. Not only will the patient require surgical interventions to stabilize the traumatized systems, but also a close monitoring of the general conditions to counter the systemic effects of trauma. The management of a polytrauma patient requires a holistic multidisciplinary approach. The orthopedic surgeons carry the responsibility of stabilizing the musculoskeletal system, using principles of either damage control orthopaedics (external fixator application) or early total care (emergency internal fixation). The management is dictated by various pathophysiological factors and scoring systems that have been developed to aid in decision-making. These scoring systems help the team to communicate better and provide prognosis for a given patient. The ISS is an anatomical scoring system that utilizes the abbreviated injury scale (AIS)—a standardized system of classification for the severity of individual injuries. The ISS is calculated from the sum of the squares of the three worst regional values and ranges from 1 to 75. ISS>15 carries a mortality of more than 10%.

Importance of Time in a Polytrauma Patient

Time is of utmost importance in a polytrauma patient. Mortality and morbidity can be significantly reduced if that patient is given due attention within the "**golden hour**," which is the ***1st hour*** after the injury. **Figure 2.1** summarizes the quick timeline in a polytrauma patient right from the site of accident to the medical intervention.

The management of a patient with trauma should begin at the field of injury and should include:

- Immediate call for help
- In-line immobilization of the cervical spine

JAYPEE BROTHERS

- Jaw-thrust and chin lift to clear the airway
- Splinting the limb with a firm, linear object such as an umbrella, folded newspaper, stick, etc.
- Applying compression over an actively bleeding injury
- Arranging for safe transport to a trauma center at the earliest.

Triaging in Trauma

- Triaging in trauma refers to the process by which emergency medical personnel *sort and prioritize victims of mass casualty incidents at the scene*. It is intended to *identify those victims most in need of immediate care*, in order to make the best use of limited treatment and transport resources. In the descending order for priority of attention, the patients are triaged into four categories: RED, YELLOW, GREEN, and BLACK, respectively.

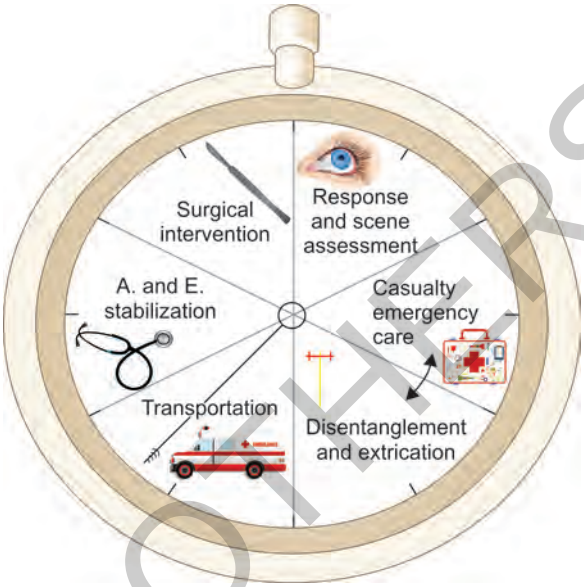

Fig. 2.1: Timeline in a polytrauma patient.

- Triaging in trauma center of the hospital also refers to the process used in the *emergency departments* to determine the order in which the presenting patients will be seen. **Table 2.1** describes the triaging sequence and examples.

Once in the hospital, triaged, the patient should be managed according to the principles laid down by ATLS. The detailed workflow of ATLS is beyond the scope of this chapter. Nevertheless, each patient must be quickly assessed for ***Airway, Breathing, Circulation, Disability*** (to assess neurological status of patient), and ***Exposure*** (bearing the dignity of patient in mind,

TABLE 2.1: Triaging of patient in trauma.

Color	*Triage priority*	*Type of injury*	*Examples*
	Red—Immediate	Life threatening	• Tension hemopneumothorax • Fracture pelvis with uncontrolled bleeding and hypotension • Convulsions
	Yellow—Urgent	Serious, but stable patient and not in any danger Requires observation	• Fracture femur • Stable liver laceration
	Green—Minor	Patient who will require treatment at some point	Fracture distal radius
	Black—Deceased/ Un-survivable	Deceased or patients with extensive injuries that they will not be able to survive given the care available	• Massive open head injury with GCS 3 • 95% third degree burns

JAYPEE BROTHERS

TABLE 2.2: Glasgow come scale.

Feature	*Response*	*Score*
Best eye response	Open spontaneously	4
	Open to verbal command	3
	Open to pain	2
	No eye opening	1
Best verbal response	Oriented	5
	Confused	4
	Inappropriate words	3
	Incomprehensible sound	2
	No verbal response	1
Best motor response	Obeys command	6
	Localizes pain	5
	Withdraws from pain	4
	Flexion from pain	3
	Extension to pain	2
	No motor response	1

BOX 2.1: AMPLE history.

A: Allergies
M: Medications
P: Past medical history
L: Time since last meal
E: Events surrounding the injury

completely undress to assess other injuries especially spine, chest, abdomen, and pelvis) approach. Glasgow coma scale helps in assessing the conscious level in a patient with a head injury **(Table 2.2)**. After a quick primary survey, a brief history is taken along with AMPLE (**Box 2.1**). Other adjuncts are relevant investigations like X-rays (trauma series [spine, pelvis, chest] and other limb X-ray, if applicable), FAST (Focused Assessment with Sonography in Trauma) abdominal four quadrant scan to look for free fluid/blood in abdomen, blood tests [hemoglobin, packed cell volume (PCV), renal and liver function tests], pulse oximetry, arterial blood gas analysis, and electrocardiogram (ECG).

Once the patient is hemodynamically stable, secondary survey can be conducted. **Flowchart 2.1** summarizes the management of a polytrauma patient.

This chapter will focus only on a stable patient with orthopedic injuries.

HISTORY

The appropriate relevant history must be directly taken from the patient who is hemodynamically stable, conscious and oriented. In a situation where patient is unable to provide history, it should be taken from bystanders. However, it should be corroborated once patient is stable, conscious and oriented.

Age

- **Pediatric age group:** Common injuries seen in young children are greenstick fracture, epiphyseal injury or a pulled elbow. One must always keep a note of battered baby syndrome in kids where history and pattern of fracture(s) do not match.

JAYPEE BROTHERS

Flowchart 2.1: Summary of polytrauma—advanced trauma life support (ATLS) care.

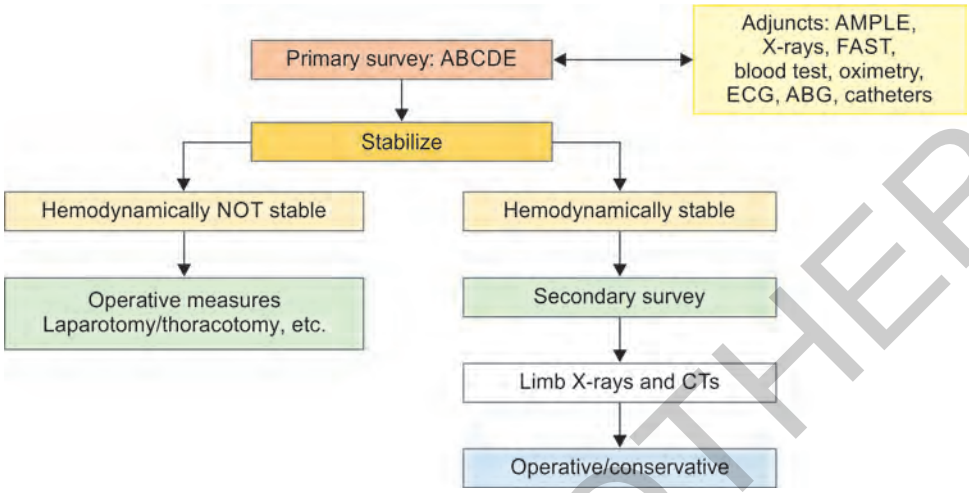

(ABG: arterial blood gas; CT: computed tomography; ECG: electrocardiogram; FAST: focused assessment with sonography in trauma)

- **Young adults:** Young adult patients are more prone to high-velocity road traffic accidents.
- **Elderly:** Elderly patients are more prone to falls and subsequent fragility fractures (fracture distal radius, proximal humerus, neck of femur, intertrochanteric femur fracture, or vertebral fracture) due to osteoporosis.

Mechanism and Force of Trauma

- The **mechanism of trauma** entails how the patient sustained the injury. This can give a clue to the structures injured. For example, a fall from a height can cause a fracture of the calcaneum, tibia, pelvis, and spine, whereas a fall from a bike onto the tip of the shoulder with facial abrasions could result in brachial plexus injury.

  In a setting of acute trauma, the mechanism of injury could be *direct or indirect*. Direct injury means fracture/dislocation at the site of impact, whereas indirect trauma results in fracture/dislocation at a site away from the point of impact. Indirect injury can also result from a forceful muscle contraction resulting in a fracture of the bone onto which it is attached. Further, the type of fracture varies in both mechanisms. Several examples of both mechanisms are mentioned below.
  - ***Direct injury:*** It could result in transverse fracture, comminuted fracture, open fracture, or a crush injury of the limb.
  - ***Indirect injury:*** Spiral/oblique fracture due to twisting force distal to the site of fracture; dashboard injury to the knee can cause posterior dislocation of the hip; forceful quadriceps contraction over a flexed knee results in a transverse fracture patella, whereas peroneus brevis contraction over an inverted foot results in fracture of the base of the fifth metatarsal.
- The **force/velocity of trauma** must be probed as significant trauma or force can undoubtedly cause a fracture. However, if an insignificant force results in the fracture, this indicates that the bone was diseased before the trauma (osteoporosis, infection, and tumor), and such fractures are known as *pathological fractures*.

  Certain common terminologies used in an injured patient are mentioned in **Box 2.2**.

JAYPEE BROTHERS

BOX 2.2: Pertinent terminologies in an injured patient.

- **Sprain:** Stretch and or tear of a ligament
- **Strain:** An injury to a muscle and/or tendons
- **Fracture:** Discontinuity or break in the anatomical continuity of the bone
- **Subluxation:** When two articular surfaces of joint are only in partial contact with each other
- **Dislocation:** When two articular surfaces of joint are no more in contact with each other

Presenting Complaints

An injured patient will have one or more complaints such as:

1. **Pain**
2. **Swelling**
3. **Deformity:** A deformed limb indicates fracture or dislocation.
4. **Inability or difficulty to use limb/weight bear:** Any such difficulty or inability to use the limb indicates severe soft tissue injury (ligament/muscle/nerve or combination), bony injury (fracture or dislocation), or both.
5. **Open wound:** Any open wound around the fracture site must be considered "open fracture" unless proved otherwise. In open fractures, enquiring specific history is mentioned in **Box 2.3**.

BOX 2.3: In case of an open fracture, specific history has to be taken.

- ***Time since injury:*** Time is of utmost importance in the management of open injuries. The longer the duration of the open wound which remained unclosed/not debrided (>8 hours), the higher is the chance of local infection and morbidity! Another important aspect of time is impending damage to the limb if there is an injury to neurovascular structure, which should be attended as early as possible to salvage the limb as the warm ischemia time is considered to be less than 8 hours.
- ***High- or low-velocity of trauma accidents:*** High-velocity injuries could lead to severe bone and soft tissue damage.
- ***Site of the accident:*** To understand the possible type of contamination. Organic contamination is more detrimental than industrial contamination because *farm accidents where there is* contamination with mud, grass or organic fertilizers could lead to anaerobic infection due to *Clostridium welchii*.

Other History

Relevant (past, personal, family, and treatment) history should be taken in standard fashion. Occupation of the patient is quite important in deciding the treatment and rehabilitation.

GENERAL ASSESSMENT

Apart from the history to evaluate the local injuries, one must assess the rest of the body's other systems (head and maxillofacial, chest, spine and spinal cord, abdomen, and pelvis) as per ATLS protocol. Glasgow coma scale helps in assessing the conscious level in a patient with a head injury **(Table 2.2)**. A polytrauma patient or patient with multiple long bone fracture and/or pelvis fracture may be hemodynamically unstable due to profound blood loss. Quick assessment of vital parameters and appropriate resuscitative measures should be initiated in form of oxygen supplement (nasal prongs/intubation), catheterization, intravenous fluid (normal saline/ringer lactate) via a 16- or 18-gauge cannula followed by blood transfusion. One must also keep **"massive transfusion protocol" (MTP)** in mind if transfusion of multiple

JAYPEE BROTHERS

packed red blood cells (PRBC) in a short period is foreseeable (>4 units of PRBC in one hour) due to significant blood loss. MTP involves transfusion of PRBC, plasma, and platelets in a ratio of 1:1:1 to avoid the perils of mere PRBC transfusion (hypothermia, acidosis, and coagulopathy).

After the quick general and systemic evaluation, focus is shifted to the local examination. ***This chapter will refrain from the detailed systemic evaluation of a trauma patient as that is out of the scope of this chapter****. However, it is imperative to note that while the injured limb is being examined, the cervical spine should be immobilized with a Philadelphia collar until a suspected cervical spine injury is ruled out with adequate imaging.*

LOCAL EXAMINATION

Attitude

The presenting attitude of the injured limb may suggest a specific diagnosis. For example, a patient presenting with posterior hip dislocation, the index hip assumes flexion, adduction, and internal rotation. In patients with fracture neck of the femur or intertrochanteric femur, the lower limb appears short and externally rotated.

However, in most cases, making a diagnosis merely by the attitude of the limb is not possible. An abnormal attitude merely indicates that the limb is injured.

Inspection

1. **Swelling:** It is a sign of an injury either to a bone/joint/soft tissue.
2. **Deformity:** A deformity always suggests displaced fracture or a dislocation.
3. **Limb length discrepancy:** Typically, a displaced fracture with over-riding of fracture ends or a dislocated joint presents as a shortening of the limb. However, in certain situations, the injured limb may appear longer, e.g., anterior dislocation of the hip.
4. **Condition of overlying skin and the presence of a wound (if any):** The skin may look stretched and shiny in case of compartment syndrome. The overlying skin at the site of injury must be thoroughly inspected for any of the following:
   i. ***Fracture blisters:*** It indicates severe injury to the soft tissue envelope and possibly compromised circulation to the soft tissue **(Fig. 2.2)**. The presence of blisters is a contraindication to "acute" open reduction and internal fixation (ORIF).
   ii. ***Ecchymosis/bruise/contusion:*** It is characterized by discoloured intact skin (bluish or red) which indicates bleeding under the skin **(Fig. 2.3)**.
   iii. ***Abrasion:*** Abrasions are superficial injuries of the skin resulting in a break in the continuity of epidermal tissue **(Fig. 2.4)**. As abrasions are confined to the epidermis, they result in minimal bleeding and heal uneventfully without permanent scar.
   iv. ***Laceration:*** Both skin and underlying tissues are cut with irregular wound margins **(Fig. 2.5A)**. It heals by scarring. One must always examine the integrity of structures which are lying deep to the lacerated wound such as nerves, tendons, and vessels. For example, a laceration over cubital fossa **(Fig. 2.5B)** may result in injury to median nerve, brachial vessels, and underlying muscle tendon.
   v. ***Puncture wound:*** A small wound that occurs due to a sharp, penetrating object either from outside or inside **(Fig. 2.6)**. A puncture wound associated with a fracture should never be taken lightly as these 'innocuous-looking' puncture wounds almost always occur due to sharp ends of fracture, making it an inside-out open fracture. Hence, a puncture wound must be adequately explored and debrided.

JAYPEE BROTHERS



Fig. 2.2: Fracture blisters.



Fig. 2.3: Ecchymotic contuse skin over medial aspect of the knee.

vi. ***Degloving injury:*** It is a type of soft tissue injury wherein skin and underlying soft tissues are ripped off the underlying muscle/fascia/bone secondary to a sudden shearing force applied to the skin surface. Degloving could be open and closed. *Open degloving injuries* are associated with a large irregular wound with the degloved skin like a flap, which is detached from underlying fascia and muscle, and can be everted **(Fig. 2.7A)**. A *closed degloving injury* is identified by a large fluctuant swelling under an intact skin. However, the overlying skin might be contused **(Fig. 2.7B)**. It is known as *Morel-Lavallée lesion* in the hip and thigh.

vii. ***Skin loss:*** There may be a skin loss around the site of injury **(Fig. 2.8)**.

viii. ***Mangled extremity:*** A mangled extremity is defined as an injury to a limb resulting from a high-energy or crush mechanism involving at least three out of four structures (soft tissue, bone, nerves, and vessels) **(Fig. 2.9)**. Dr Johansen (1990) developed the mangled extremity severity score (MESS) with components of skeletel/soft tissue injury, limb ischemia,



Fig. 2.4: Multiple abrasions over arm and forearm.



Figs. 2.5A and B: (A) Lacerated wound over forefoot; (B) Lacerated wound over the cubital fossa and proximal forearm.

JAYPEE BROTHERS

shock and age to predict the viability of a limb. MESS score ≥ 7 indicates almost 100% possibility of amputation. However, modern orthopedic techniques have given a possibility of limb survival even up to MESS scores of 8 or 9.

ix. ***Total or near-total amputation:*** Total amputation refers to a complete detachment of a body part (surgical/traumatic) with separation of all structures with no connection between the two parts. Near-total (subtotal) amputation is defined as an incomplete detachment of a body part with a definite separation of the blood vessels with a tag of soft tissue (skin, tendon, or muscle) still remains intact and attached **(Fig. 2.10)**.

Various soft tissue injuries can be graded according to the Tscherne classification. However, details of Tscherne classification are out of the scope of the chapter.



Fig. 2.6: Puncture wound.



Figs. 2.7A and B: (A) Open degloving with skin loss; (B) Morel-Lavallée lesion (Closed degloving injury) in a patient with pelvis fracture.

5. **Open fracture:** An open fracture is defined as an injury where the fracture fragment/bone/fracture hematoma are communicating with the external environment through the soft tissue injury. Open fracture are classified based on Gustilo–Anderson classification **(Table 2.3)**.

Palpation

Before the palpation is initiated, the clinician should ask the patient about the site of maximum tenderness. *The traumatized limb should be palpated and moved with utmost care* as it causes severe pain.

A limb with fracture has certain specific signs:

1. **Bony tenderness:** The fracture site is tender when palpated through the overlying soft tissue.
2. **Bony crepitus:** A grating sensation is felt when the two ends of the fractured bone are moved. *However, bony crepitus is a very painful maneuver; hence, it is never deliberately elicited*. Note that the bony crepitus is absent in undisplaced fractures.
3. **Palpation of a gap** between two ends of the fracture is a certain sign of a fracture.
4. **Abnormal mobility:** When two ends of the fracture are held together, the abnormal mobility at the fracture site can be elicited. *However, abnormal mobility is not deliberately elicited as it is quite a painful maneuver.*

JAYPEE BROTHERS



Fig. 2.8: Skin loss over the lower end of thigh, knee and upper end of tibia with associated fracture of distal femur and proximal tibia.



Fig. 2.9: Mangled lower limb.

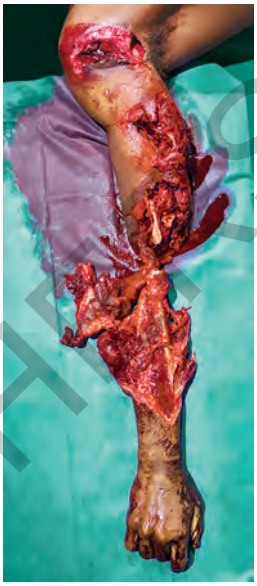

Fig. 2.10: Near-total upper amputation of right limb at the level of mid-forearm.

Note about penetrating injury with offending object in situ: It is crucial to understand that if there is a penetrating injury to any part of the body with penetrating object in situ (rod/pin/knife/bullet, etc.), one must never remove these objects either at the place of accident or in triage/casualty. These objects should be removed only in an operation room as these objects may lie next to a vessel, and sudden removal might result in dislodgement of the hematoma/clot causing torrential bleeding and hypotension. In operation room, bleeding can be controlled and vessel can be immediately repaired. However, outside the operating room, there might be no facility to effectively control the bleeding and repair the vessel resulting in potential complications. Moreover, the fingerprints over these object might be of medicolegal value which needs be preserved in standard fashion to aid the legal system.

TABLE 2.3: Gustilo–Anderson classification of open fracture.

Type	*Description*
1	An open fracture with wound <1 cm long, simple fracture (#) pattern
2	An open fracture with a wound 1–10 cm long without extensive soft tissue damage, flaps or avulsion, simple # pattern
3	High-energy injury involving extensive soft tissue damage OR multifragmentary # OR bone loss irrespective of wound size OR severe crush injuries OR severe farmland contamination. Usually wound size >10 cm
3A	Adequate soft tissue coverage of a fractured bone is possible without any additional procedure despite extensive soft tissue laceration or flaps, or high-energy trauma (multifragmentary or segmental #) irrespective of the size of the wound
3B	Extensive soft tissue injury with periosteal stripping and bony exposure with massive contamination, *requiring additional soft tissue reconstructive procedure to cover the wound*
3C	Open fracture with *arterial injury* requiring a repair

JAYPEE BROTHERS

5. **Compression test:** This is an indirect tenderness test wherein the pressure is exerted over a group of normal bone(s), leading to tenderness over the fracture. Compression or squeeze elsewhere along the length of the bone other than injured site would result in the force of compression to propagate via bones rather than soft tissue and would cause pain at the fracture site.

   This test is performed where there is a suspicion of a fracture in a region with two or more parallel bones (ribs, metatarsal or metacarpals, forearm, and leg). For example, if the ribs are fractured (one or more), gentle pressure over the sternum with one hand and other hand over the dorsal spine or gentle side-to-side squeezing the rib cage in the axilla with both hands causes pain over the fractured rib. Another example, gentle side- to-side squeezing of the forearm, hand, leg or foot causes a painful response in radius-ulna, metacarpal, tibia-fibula or metatarsal fracture.
6. **Loss of transmitted movements:** The fractured limb fails to transmit the movements performed at the distal segment. For example, if the ankle is manually rotated in a patient with a tibia shaft fracture, the proximal tibia will not rotate as there is a break in the continuity of the bone.
7. **Passive stretch pain, a red flag sign!** Severe pain on a passive stretch of fingers and toes in injury to forearm or leg respectively could indicate underlying compartment syndrome. One must suspect compartment syndrome, if there is unrelenting pain in body parts, especially in the forearm, leg, hand, and foot, which fails to subside with appropriate analgesics and splintage.
8. **Soft tissue crepitus in case of gas in soft tissue planes:** Surgical emphysema in case of fracture ribs and gas gangrene.
9. **Palpation of all other bones, contralateral limb, spine and pelvis**.

Movements

It is always difficult to assess the movement at the joint near the fracture site due to pain and discontinuity in the lever (fracture). Nevertheless, after stabilizing the limb in a splint, one should ask the patient to move adjacent joints actively, especially the ones which are free and distal to the injured area to get an idea of integrity of nerves and tendon.

Measurement

- *Measurement of the limb length is not performed in acute fractures, as maneuvering would be very painful.* A mere visual assessment of the limb length is fair enough! However, sequential girth assessment may be of some value in patients with impending compartment syndrome who are kept under observation. Any sequential increase in the girth with unrelenting pain may require urgent fasciotomy.
- Muscle wasting is not a feature of acute trauma unless there were a pre-existing one such as pre-existing poliomyelitis in the limb.

Auscultation

It is relevant in patients with fractured ribs. One must try to record the breath sounds on both sides of the chest.

Neurovascular Examination

A thorough systematic neurovascular examination of the extremity is mandatory to rule out any neurovascular deficit. *A handheld Doppler may be used to supplement the examination of*

JAYPEE BROTHERS

peripheral pulses, especially if there is a significant limb edema obscuring the palpation of artery. If a detailed neurological assessment is not possible in the presence of multiple injuries or an uncooperative patient, it should be recorded to avoid litigation. Later, neurological examination must be performed once the patient is conscious and cooperative.

Joint Above and Below

Careful assessment of the joint above and below is essential to rule out any transmitted injury to the neighboring joints. For example, after a fall from height, the foot, knee, hip, pelvis, and spine should be examined as axial force can be transmitted from the 'lower' point of impact (calcaneum) to higher levels (ankle, knee, pelvis, spine).

Special Tests

The special tests especially pertaining to the ligament injury are often difficult to perform in primary survey due to other priorities and painful local conditions (fracture, dislocation, wounds). Hence, it should be preformed with care only when patient is stable as a part of secondary or tertiary survey.

A Note on Relevant Investigations in Stable Trauma Patients

- **X-rays:** Plain radiograph with relevant views must be asked for to *assess or rule out bony injuries*. Trauma series X-rays (chest, spine, and pelvis) are asked for patients with polytrauma.
- **FAST scan:** It is a rapid bedside ultrasound examination performed by emergency physicians, surgeons, or paramedics as a *screening test for blood around the heart* (pericardial effusion) and *abdominal organs* (hemoperitoneum) after trauma. The four classic areas that are examined for free fluid are the perihepatic space (including Morison's pouch or the hepatorenal recess), perisplenic space, pericardium, and the pelvis. The presence of free fluid will usually be due to bleeding.
- **Computed tomography (CT) scan:** It is requested in patients with specific situations such as:
  - *Intra-articular or periarticular fractures.*
  - *Areas where the anatomy is complex*: Spine, pelvis, scapula, or joints.
- **Arterial Doppler:** It is requested to *rule out any arterial injury* if there is a vascular injury (arterial). For example, pulse is not palpable/feeble/pulse not palpable due to swelling, cold extremity, poor capillary filling.
- **CT angiogram:** It is requested when there is *suspicion of vascular injury* to the limb. It is superior to Doppler imaging in terms of sensitivity and specificity.
- **Magnetic resonance imaging (MRI):** It is usually requested *if there is suspicion of soft tissue injury involving ligament, muscle–tendon, or nerves*. It is also valuable for *undisplaced fractures wherein one can visualize fractures and associated bone marrow edema*. However, unless really required for an emergency management of a patient, MRI is conducted once patient has been completely stable for a day or two and all other major emergency managements are over.

TRAUMA-RELATED ORTHOPEDIC EMERGENCIES

Open Fractures

The wound of open fracture can vary from a puncture wound at the fracture site to composite soft tissue loss along with severe contamination. These fractures require emergency

JAYPEE BROTHERS

intervention in the form of thorough debridement preferably within 8 hours, empirical antibiotics to minimize the risk of infection followed by stabilization of fracture with appropriate method (external/internal).

Compartment Syndrome

Compartment syndrome is defined as an increase in the pressure of a closed osteomyofascial compartment to levels high enough to cause ischemia. Compartment syndrome is usually seen in the leg and forearm, where there are two long bones connected by an interosseous membrane and surrounded by different groups of muscles enclosed in tight fascial structures. Compartment syndrome may also happen in the hand, foot, and thigh. Stretched shiny skin, unrelenting pain after fracture that fails to subside with regular analgesics, and pain on the passive stretch of the finger/toes are clinical signs of compartment syndrome. A quick clinical assessment may help to establish the diagnosis and may require urgent fasciotomy and fracture fixation.

Dislocations

A dislocation is an emergency as dislocated part often lies next to the neurovascular bundle, which can compress the neurovascular bundle. For example, in anterior dislocation of the shoulder, the head lies next to the axillary nerve/brachial plexus. Further, the vascularity of the dislocated part is under stress, which may result in avascular necrosis if the part is not reduced early. For example, dislocation of the hip tents the retinacular vessels. Therefore, a dislocation must be reduced as early as possible.

Major Vascular Injury of the Limb/Traumatic Amputation of a Limb

The *re-implantation of a traumatically amputated part or repair of a major vascular injury of the limb* compromising the circulation must be tackled as an utmost priority. Both (re-implantation/re-vascularization) should be undertaken within 8–12 hours of the injury as the warm ischemia time of the limb is less than 12 hours. Associated fracture/dislocation should be managed on standard lines.

Absolute contraindications for re-implantation include severely crushed or mangled parts, amputations at multiple levels, and prolonged warm ischemia more than 12 hours. The amputated limb/part should not transported from the site of accident to the hospital with direct contact of ice. It should be kept in a plastic bag and this bag should be kept in another plastic bag with ice so that the limb/part is not in the direct contact with the ice. This will aid in retaining the viability of the limb when re-vascularization is attempted.

Notes

JAYPEE BROTHERS

for detailed information on orthopaedics books, visit our website www.jaypeebrothers.com, for detailed information on orthopaedics books, visit our website www.jaypee

Musculoskeletal Examination
for Undergraduates

Salient Features

- Compendium of Orthopaedic examination for easy retention with videos of almost all the essential clinical tests included on the Diginerve platform
- The first chapter provides a thorough understanding of the art of history taking
- Every major joint has been exhaustively explained with possible maladies and relevant findings using pictorial representations for lucidity
- The methodology to elicit examination findings has been explained in a comprehensible, concise manner to encourage further reading
- Every chapter ends with a brief proforma on history and examination for quick revision before the exam.

Vivek Pandey is Professor and Unit Head of the Sports Medicine and Arthroscopy Division, Department of Orthopaedic Surgery, Kasturba Medical College, Manipal, Karnataka, India. He received his undergraduate degree (MBBS) from Kasturba Medical College, Manipal and his postgraduate degree (MS Orthopaedics) from KGMC, Lucknow, Uttar Pradesh, India. He won numerous accolades in academia and research, including a Gold Medal for MBBS. He is passionate about his clinical work, research, and teaching. His more than 70 indexed papers in several national and international journals and his chapters in numerous textbooks, demonstrate his love for academics and research. His original studies on platelet-rich plasma, rotator cuff repair, shoulder instability and stem cells in osteoarthritis have received many citations in the literature. He is a guide to postgraduates and PhD candidates. In addition to the *Musculoskeletal Examination for Undergraduates*, he has written three more books that are well-liked by medical students and orthopaedic residents both in India and abroad: *Musculoskeletal Examination for Postgraduates, Manipal Manual of Orthopaedics,* and *Manipal Practical Orthopaedics.* Furthermore, students from all over the world heavily subscribe to the online digital version of 'orthopaedics for undergraduates' at the Diginerve platform (Jaypee Brothers), which aids in their preparation of fundamentals of orthopaedics. Numerous 'Excellence in Teaching' awards at KMC Manipal and Sikkim Manipal Institute of Medical Sciences (SMIMS), Gangtok, Sikkim, India, highlight his love of instructing undergraduate and postgraduate students. His passion for clinical work is primarily managing sports injuries, especially knee and shoulder injuries. By giving guest lectures, carrying out live surgeries, fellowship programs, and training orthopaedic surgeons in sports injuries and arthroscopy, he has contributed significantly to advancing the science and art of arthroscopy.

Saktthi Shanmuganathan is an Assistant Professor, Department of Orthopaedics, Kasturba Medical College, Manipal, Karnataka, India. She finished her graduation and pursued postgraduation in the field of Orthopaedics from Sri Ramachandra Institute of Higher Education and Research (SRIHER), Chennai, Tamil Nadu. She had received the Gold Medal award for Research during her postgraduation residency. She is currently pursuing her passion for research in Hand and Spine.

Printed in India

Available at all medical bookstores
or buy online at www.jaypeebrothers.com



JAYPEE BROTHERS
Medical Publishers (P) Ltd.
EMCA House, 23/23-B, Ansari Road,
Daryaganj, New Delhi - 110 002, INDIA
www.jaypeebrothers.com

Join us on facebook.com/JaypeeMedicalPublishers

Shelving Recommendation
ORTHOPAEDICS

