others.com, for detailed information on PGMEE books, visit our website www.jaypeebrothers.com, for detailed information on PGMEE books



The Next Level of Preparation

NEET PG

CRYSTAL CLEAR

NEET PG

Thameem Saif • Apurv Mehra

Akhil Monga • Kavan Parikh

4th Edition

JAYPEE

CONTENTS

Latest NEET 2022 ..... *p1 – p75*

Recent NEET 2021 ..... *p76 – p169*

1. Anatomy 1
2. Physiology 59
3. Biochemistry 96
4. Pathology 138
5. Pharmacology 239
6. Microbiology 288
7. Forensic Medicine 360
8. Orthopedics 381
9. Ophthalmology 414
10. ENT 437
11. Preventive and Social Medicine 459
12. Medicine 523
13. Surgery 588
14. Obstetrics and Gynecology 633
15. Dermatology 705
16. Anesthesia 720
17. Radiology 728
18. Psychiatry 749
19. Pediatrics 759

Recent NEET 2021

ANATOMY

NEET PG September 2021

1. Identify the type of papillae shown in the microscopic picture of tongue:



For colour version see Plate 1

a. Circumvallate
b. Fungiform
c. Filiform
d. Foliate

Ans. is 'a' Circumvallate

❖ Lingual papillae are projections of mucosa covering the dorsal surface of tongue producing roughness (friction) and increasing area of contact. They are limited to (present only in) upper surface of presulcal part (anterior 2/3rd) of tongue.

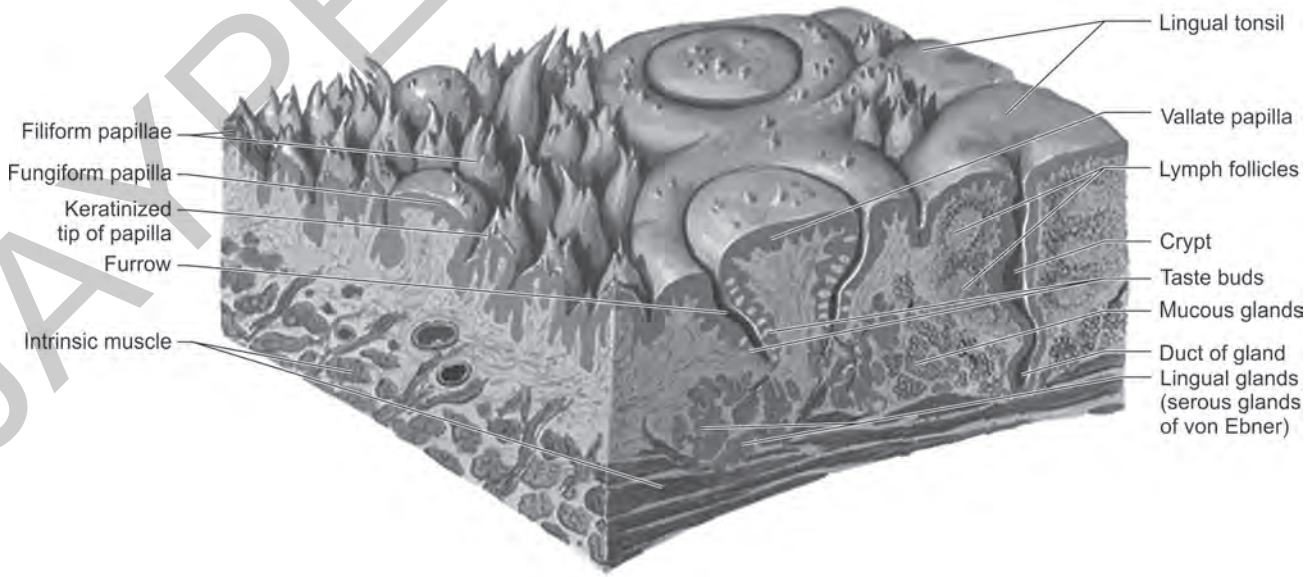

JAYPEE BROTHERS

- Lingual papillae are of 4 types, named filiform, fungiform, foliate and circumvallate papillae, all except the filiform papillae bear the taste buds. All except circumvallate are innervated by chorda tympani (facial) nerve (for taste) and lingual nerve (general). Circumvallate papillae is innervated by glossopharyngeal nerve (both taste and general sensation). Foliate papillae are least developed in humans.
- Taste buds are numerous on all types of lingual papillae (except filiform papillae), particularly on their lateral aspects. However, tastes buds are not restricted to papillae and are scattered over almost the entire dorsal and lateral surfaces of tongue and rarely on epiglottis and soft palate (lingual aspect). Each taste bud (a paraneurone) is linked to one of three cranial nerve which carry taste i.e., facial glossopharyngeal or vagus.

2. A 30-year-old patient complaints of diminishing vision of right halves of both eyes. Where is the most probable lesion?

a. Right optic nerve
b. Optic chiasma
c. Left optic tract
d. Right occipital lobe

Ans. is 'c' Left optic tract

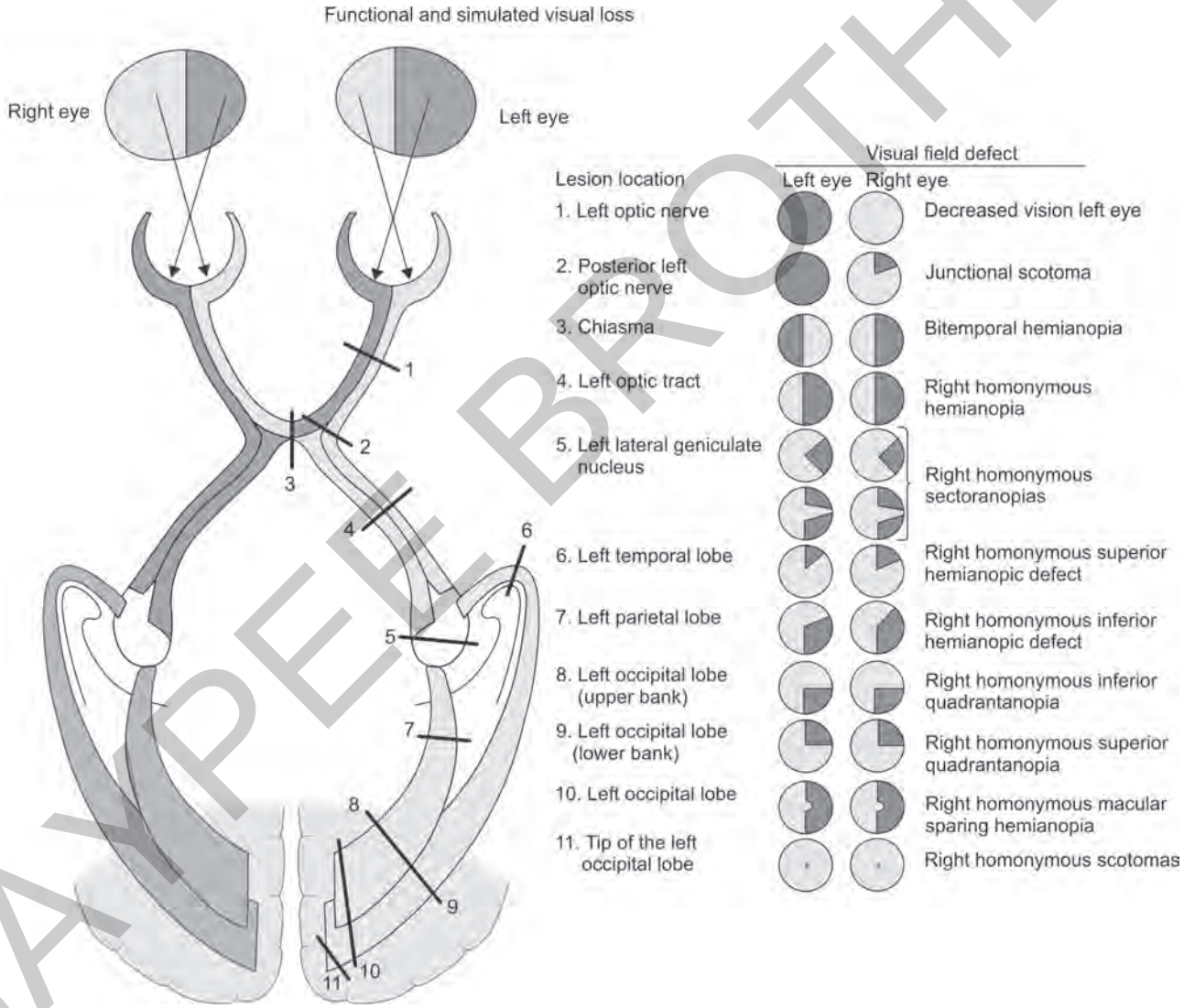

3. A patient presented with history of vision loss. On investigation an aneurysm was identified causing compression on the optic chiasma. Which of the following artery is most likely involved?

a. Anterior choroidal artery
b. Anterior communicating artery
c. Middle cerebral artery
d. Anterior cerebral artery

Ans. is 'b' Anterior communicating artery

JAYPEE BROTHERS

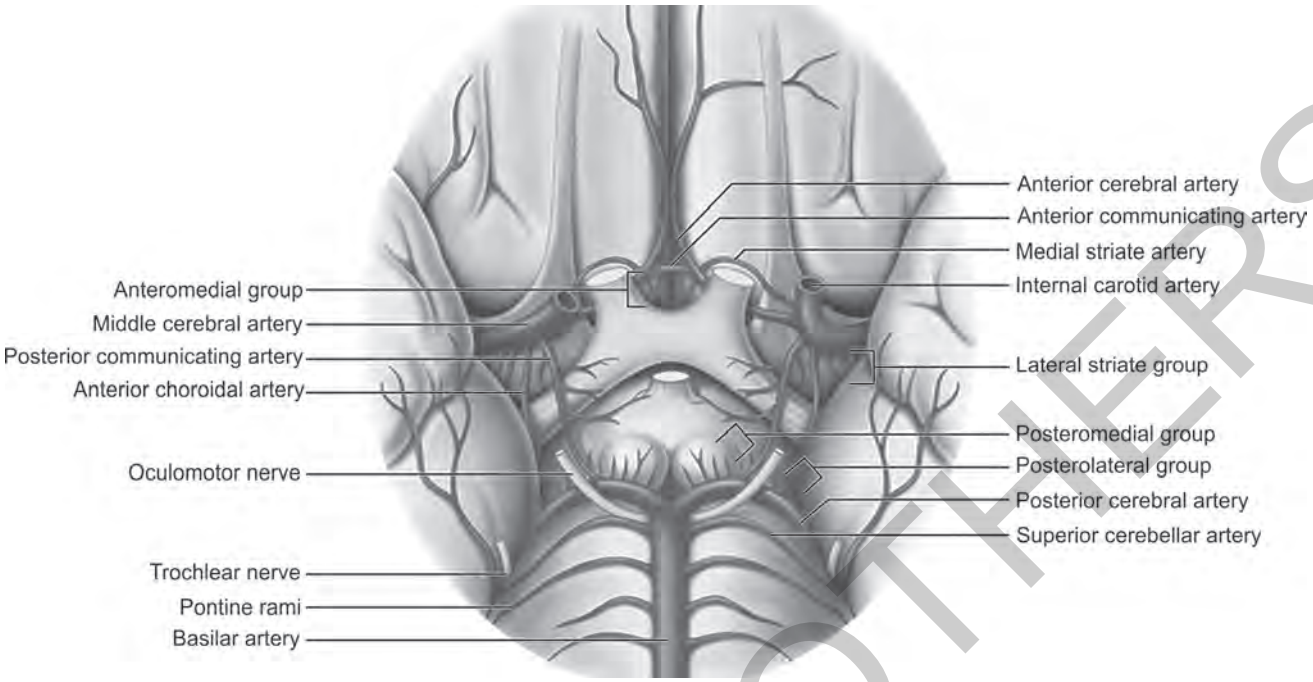

❖ **Bitemporal hemianopia:** Can be best understood by anatomic relations of optic chiasma

Relation	*Structure*	*Cause*
Inferiorly	Pituitary gland in sella turcica	Pituitary, macro adenoma (>10 mm) suprasellar extension (Never Microadenoma)
	Earliest visual field defect seen in cases of pituitary adenoma Pituitary adenoma first compresses the inferior binasal fibers ↓ Thus, lesions of binasal inferior fibres ↓ Bitemporal superior heteronymous Quadrantanopia	
Superiorly	Remnant of Rathke's Pouch	Craniopharyngioma
	Earliest visual field defect seen in cases of craniopharyngioma Superior binasal fibers ↓ Thus, lesion of binasal superior fibers ↓ Bitemporal inferior heteronymous Quadrantanopia	
Anteriorly	Anterior cerebral artery and anterior communicating artery	Aneurysm of anterior communicating artery > anterior cerebral artery
Inferolaterally	Cavernous sinus	Aneurysm of cavernous sinus
Superiolaterally	3rd Ventricle	3rd Ventricle Glioma

4. A patient has undergone submandibular gland excision and the Wharton's duct was ligated in the process. Which of the following nerve is most likely to be damaged during the process of ligating the duct?

a. Inferior alveolar nerve
b. Lingual nerve
c. Hypoglossal nerve
d. Marginal mandibular branch of facial nerve

Ans. is 'b' Lingual nerve

JAYPEE BROTHERS

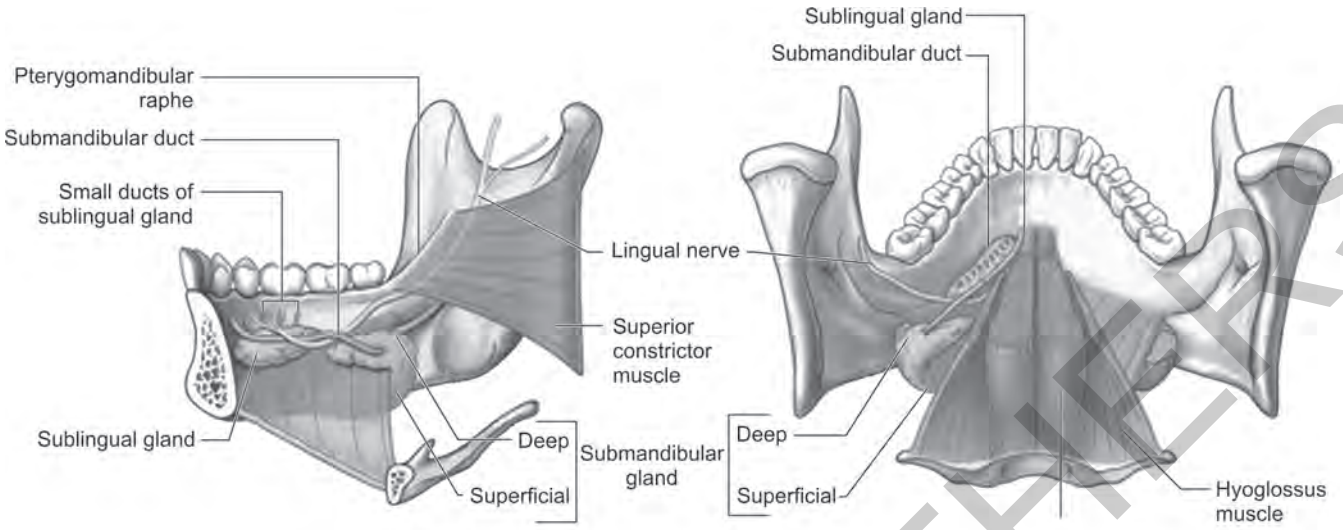

The **submandibular duct** emerges from the medial side of the deep part of the gland in the oral cavity and passes forward to open on the summit of a small **sublingual caruncle** (papilla) beside the base of frenulum of the tongue.

The lingual nerve loops under the submandibular duct, crossing first the lateral side and then the medial side of the duct, as the nerve descends anteromedially through the floor of the oral cavity and then ascends into the tongue.

5. A patient was admitted with skull base trauma and difficulty in swallowing. The doctor was touching the marked structure. Which of the following cranial nerve is being tested?



For colour version see Plate 1

a. X
b. IX
c. VII
d. V

Ans. is 'a' X

Motor and most sensory innervation (except for the nasal region) of the pharynx is mainly through branches of the vagus (X) and glossopharyngeal (IX) nerves, which form a plexus in the outer fascia of the pharyngeal wall.

The pharyngeal plexus is formed by:

- The pharyngeal branch of the vagus nerve (X);
- Branches from the external laryngeal nerve from the superior laryngeal branch of the vagus nerve (X);
- Pharyngeal branches of the glossopharyngeal nerve (IX).

The pharyngeal branch of the vagus nerve (X) originates from the upper part of its inferior ganglion above the origin of the superior laryngeal nerve and is the major motor nerve of the pharynx, in addition to carrying sensory information from the laryngopharynx.

JAYPEE BROTHERS

All muscles of the pharynx are innervated by the vagus nerve (X) mainly through the pharyngeal plexus, except for the stylopharyngeus, which is innervated directly by a branch of the glossopharyngeal nerve (IX).

6. Which structure prevents the vertical and downward descent of the spleen?

a. Lienophrenic ligament
b. Lienorenal ligament
c. Gastrosplenic ligament
d. Phrenicocolic ligament

Ans. is 'd' Phrenicocolic ligament

Spleen hypertrophy causes the enlargement to move downwards and obliquely towards right iliac fossa. It is prevented from descending to left side by phrenicocolic ligament.

The anterior aspect of the gastrosplenic ligament continues below the inferior pole of the spleen as fan-shaped fold of peritoneum and blends with the phrenicocolic ligament. The phrenicocolic ligament extends from the splenic flexure of the colon to the diaphragm at about the level of the eleventh rib. It is continuous inferiorly, with the peritoneum of the transverse mesocolon near the pancreatic tail, and the splenorenal ligament at the hilum of the spleen.

PHYSIOLOGY

NEET PG September 2021

7. Following are the levels of various ions in a body fluid. Identify the fluid ~Na^+ = 10 mEq/L, K^+ = 140 mEq/L, Cl^- = 15 mEq/L, HCO_3^- = 12 mEq/L:

a. ICF
b. Plasma
c. Interstitial fluid
d. CSF

Ans. is 'a' ICF

Ion	*Cell (ICF) in mOsm/L*	*ISF in mOsm/L*	*Blood (ECF) in mOsm/L*
K^+	140 (max cation)	4	4.2
Na^+	14	139	145 (max cation)
Cl^-	4	108	108 (max anion)
HCO_3^-	10	28	24
HPO_4, H_2PO_4	11/max anion	2	2
Protein	4	0.2	1.2
Ca^{2+}	<0.0002	1.2	1.8
Mg^{2+}	20	0.7	1.5
Corrected osmolar activity (mOsm/L)	281	281	282
Total osmotic pressure at 37° C (mmHg)	5423	5423	5443

8. Tetany will result from which of the following disorder?

a. Metabolic acidosis
b. Respiratory alkalosis
c. Hyperoxemia
d. Hypercalcemia

Ans. is 'b' Respiratory alkalosis

Alkalosis, by promoting the binding of calcium to albumin, can reduce the fraction of ionized calcium in blood, causing tetany. Symptomatic hypocalcemia is more common with respiratory alkalosis than with metabolic alkalosis.

9. Cardiovascular findings in a patient were as follows: large 'a' wave on JVP, mid-diastolic murmur. Pedal edema+. The most probable diagnosis is:

a. MS
b. MR
c. TS
d. TR

Ans. is 'c' TS

JAYPEE BROTHERS

Types

Name	*Diagram*	*Causes*
I. Systolic Murmurs		
1. Ejection Systolic/ Mid-systolic/ Crescendo-Murmurs	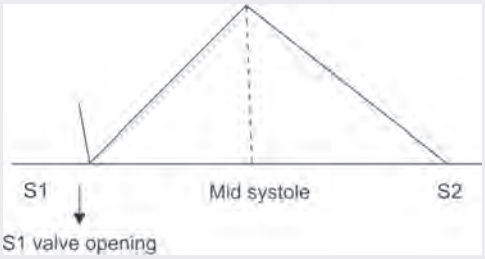	Turbulence during ejection phase ↓ AS, PS High CO states HOCM CoA
2. Pan systolic Murmur	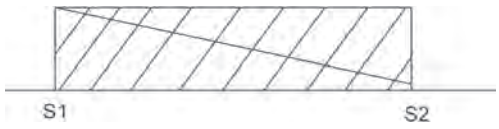	Ventricular septal defect (LV pressure >> RV pressure) Throughout systole • Chronic mitral regurgitation on LV pressure >> LA pressure throughout systole (cooing/seagull like) • Chronic TR to RV pressure >> RA pressure throughout systole. (intensified on inspiration – Carvallo sign)
3. Early systolic [Will stop ≤ Mid systole]	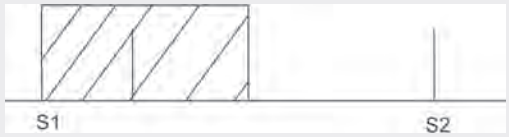 or 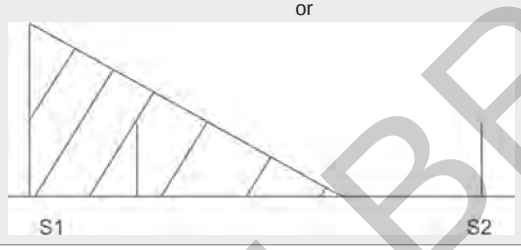	If defect closes ≤ mid systole • Small muscular VSD If pressure gradient becomes zero ≤ mid systole • Acute mitral regurgitation or acute TR (LA/RA not dilated) [Unlike chronic] During early systole → LV blood enters LA and LA pressure rises rapidly During mid systole → LA pressure = LV pressure [Murmur will stop]
4. Late systolic starts ≥ mid systole		Mitral valve prolapsed [whooping/konking type heard best @apex]
II. Diastolic Murmurs		
1. Early Diastolic = decrescendo	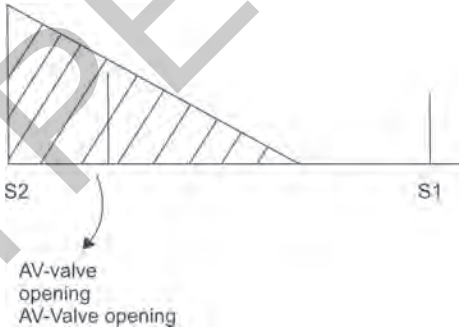 AV-Valve opening	Aortic regurgitation Pulmonary regurgitation
2. Mid Diastolic	Presystolic accentuation (atrial contraction) 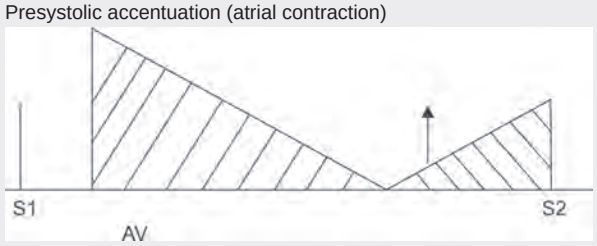	Turbulence of blood flow across AV valve ↓ MS, TS

JAYPEE BROTHERS

The *a* wave reflects right atrial presystolic contraction and occurs just after the electrocardiographic P wave, preceding the first heart sound (S1).

A prominent *a* wave is seen in patients with reduced right ventricular compliance; a cannon *a* wave occurs with atrioventricular (AV) dissociation and right atrial contraction against a closed tricuspid valve.

In a patient with a wide complex tachycardia, the appreciation of cannon *a* waves in the jugular venous waveform identifies the rhythm as ventricular in origin.

The *a* wave is not present with atrial fibrillation.

10. Neurologic examination of a patient revealed the following ~ diplopia and suspected involvement of other cranial nerves, tingling and numbness in the lower extremities. Symptoms were getting worse upon taking hot both. Defect of which of the following cells is the most likely causes?

a. Oligodendrocyte
b. Ependymal cell
c. Astrocyte
d. Microglia

Ans. is 'a' Oligodendrocyte

Normal conduction of action potentials relies on the insulating properties of **myelin.** Thus, defects in myelin can have major adverse neurological consequences. One example is **multiple sclerosis (MS),** an autoimmune disease.

The cause of MS appears to include both genetic and environmental factors.

In MS, antibodies and white blood cells in the immune system attack myelin, causing inflammation and injury to the sheath and eventually the nerves that it surrounds. Loss of myelin leads to leakage of K^+ through voltage gated channels, hyperpolarization, and failure to conduct action potentials. Typical physiological deficits range from muscle weakness, fatigue, diminished coordination, slurred speech, blurred or hazy vision, bladder dysfunction, and sensory disturbances.

Symptoms are often exasperated by increased body temperature or ambient temperature. Progression of the disease is quite variable. In the most common form, transient episodes appear suddenly, last a few weeks or months, and then gradually disappear.

Oligodendrocytes and **Schwann cells** are involved in myelin formation around axons in the CNS and peripheral nervous system, respectively.

BIOCHEMISTRY

NEET PG September 2021

11. A person had a meal at 8 pm and records blood glucose at 7 am on the next day which was 180 mg/dL. What is the source of glucose in this patient?

a. Dietary glucose
b. Hepatic gluconeogenesis
c. Hepatic glycogenolysis
d. Muscle glycogenolysis

Ans. is 'c' Hepatic glycogenolysis

Compensatory mechanisms during starvation

Process	*Provides energy up to*
Glycogenolysis	12–24 (avg. 18 hrs)
Gluconeogenesis (from glutamine and alanine from skeletal muscles)	Up to 72 hrs
FA oxidation and KB synthesis	Up to 2 weeks
Proteolysis of structural proteins	Till death

12. A patient who is diagnosed case of HNPCC, which of the following is the most common repair associated with it?

a. Mismatch repair
b. Base excision repair
c. Nucleotide excision repair
d. Homologus recombinant repair

Ans. is 'a' Mismatch repair

For detail see explanation on page 124 Table

JAYPEE BROTHERS

13. This multienzyme complex converts Pyruvate to Acetyl CoA. Identify E1 and E2:

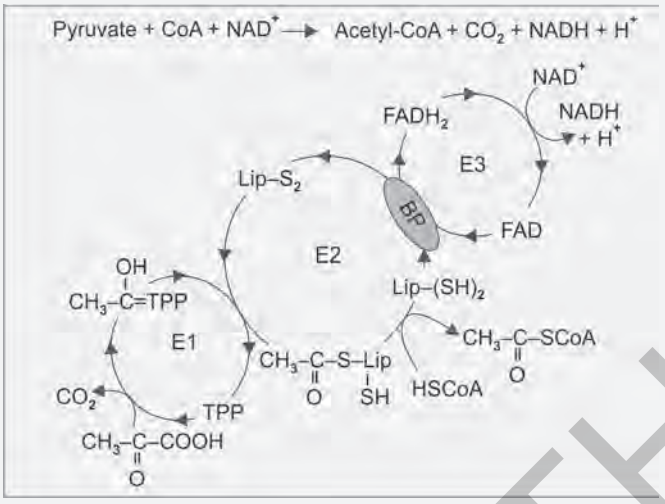

a. E1: Pyruvate dehydrogenase E2: Dihydrolipoyl transacetylase
b. E1: Pyruvate decarboxylase E2: Dihydrolipoyl dehydrogenase
c. E1: Pyruvate carboxylase E2: Dihydrolipoyl transacetylase
d. E1: Pyruvate dehydrogenase E2: Dihydrolipoyl dehydrogenase

Ans. is 'a' E1: Pyruvate dehydrogenase E2: Dihydrolipoyl transacetylase

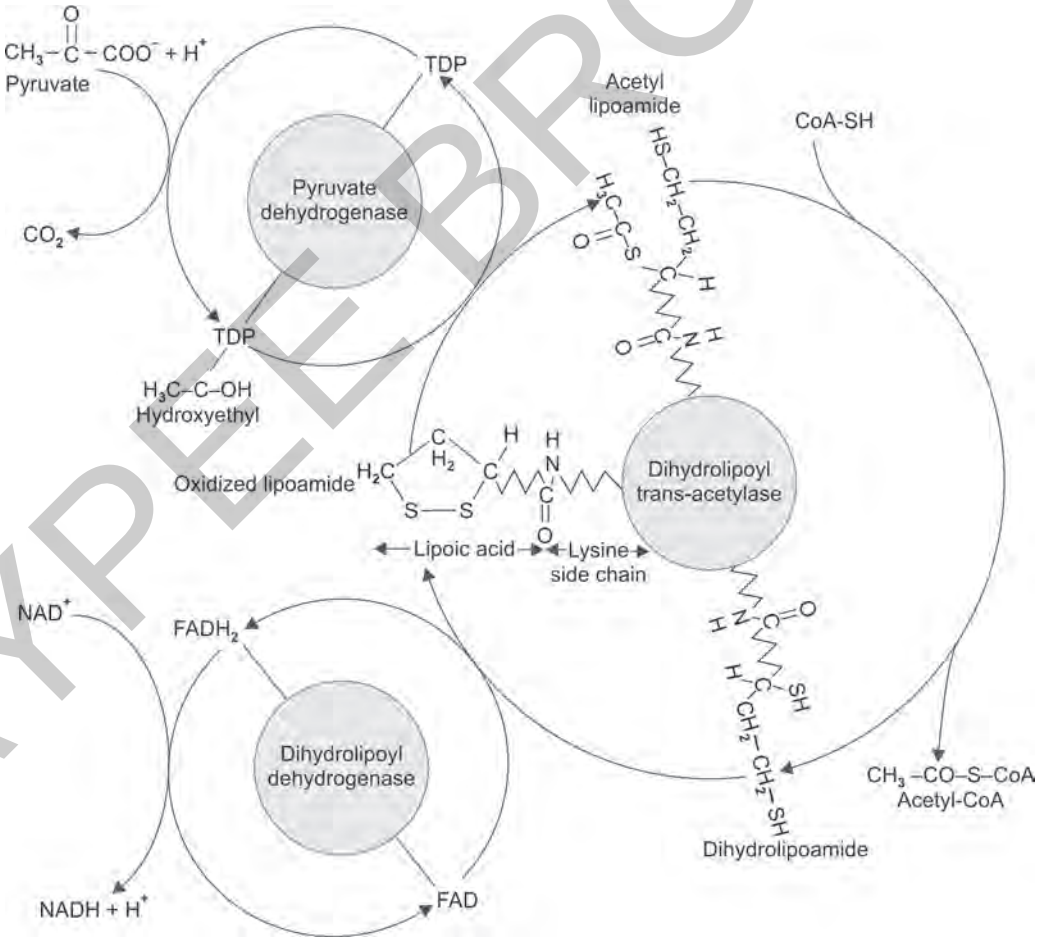

Oxidative decarboxylation of pyruvate by the pyruvate dehydrogenase complex. Lipoic acid is joined by amide link to a lysine residue of the transacetylase component of the enzyme complex. It forms a long flexible arm, allowing the lipoic acid prosthetic group to rotate sequentially between the active sites of each of the enzymes of the complex. (FAD, Flavin adenine dinucleotide; NAD^+, nicotinamide adenine dinucleotide; TDP, thiamin diphosphate)

JAYPEE BROTHERS

PDH is Mitochondrial enzyme complex linking glycolysis and TCA cycle.

Differentially regulated in fed/fasting states (active in fed state).

Components

- Pyruvate dehydrogenase (remove CO_2)
- Dihydrolipoyl Transacetylase (add CoA)
- Dihydrolipoyl Dehydrogenase (NAD→NADH)

Reaction

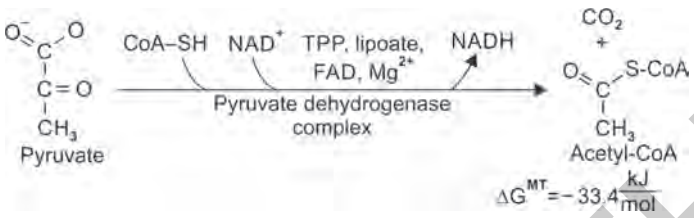

The complex contains 3 enzymes that require 5 cofactors:

- Thiamine pyrophosphate (B1)
- Lipoic acid
- CoA (B5, pantothenic acid)
- FAD (B2, riboflavin)
- NAD+ (B3, niacin)

Lipoic acid dependant enzymes:

- PDH
- αKG DH
- Branched chain α ketoacid DH

Lipoic acid → inhibited by ARSENITE

14. A 35-year-old farmer on maize diet with diarrhea, dementia and dermatitis. Which Vitamin is deficient in this patient?

a. Thiamine
b. Riboflavin
c. Niacin
d. Pyridoxine

Ans. is 'c' Niacin

For detail see explanation on page 130

15. Which of the following vitamin needs to be supplies in the diet of patients with Cystathionine beta synthase defect?

a. Cysteine
b. Methionine
c. Serine
d. Homocysteine

Ans. is 'a' Cysteine

Methionine metabolism (1 carbon transfer)

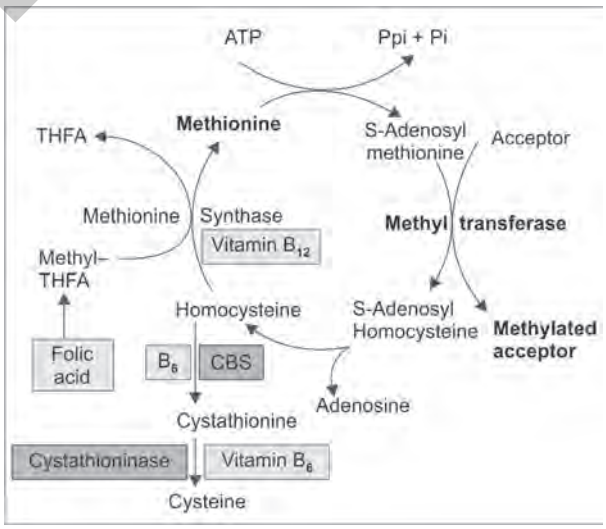

(CBS- cystathionine β synthase)

JAYPEE BROTHERS

Disease	Defect/deficiency	Features
Homocysteinemia type 1	Cystathionine β synthase	• MR • Charlie Chaplin gait • Inferomedial ectopia lentis • IV thrombosis (due to thiolactone adducts)
Homocysteinemia type 2	Methyl THFA reductase	
Homocysteinemia type 3	Methionine synthase	
Homocysteinemia type 4	Dietary B12 deficiency	

16. A patient has multiple tendon xanthomas. Serum cholesterol (398 mg/dL) and LDL (220 mg/dL) were found to be raised. Statins were given to this patient. What is the diagnosis?

a. Lipoprotein lipase deficiency
b. Familial hypercholesterolemia
c. Tangier's disease
d. Huntington's disease

Ans. is 'b' Familial hypercholesterolemia

For detail see explanation on page 115 Table

17. A patient presented with weakness, anemia, bony pain and hepatosplenomegaly. Which of the following enzyme is deficient?

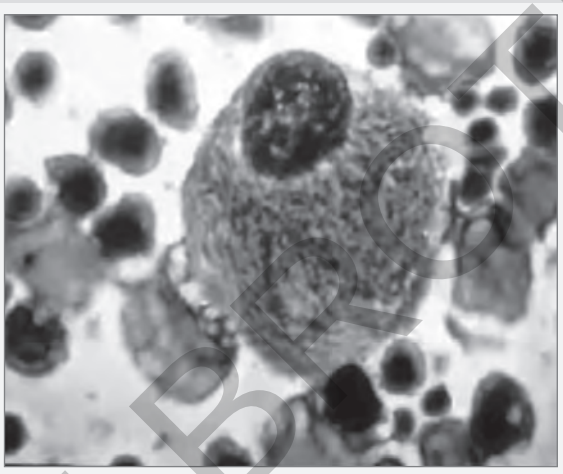

For colour version see Plate 1

a. Glucose 6 phosphatase
b. Gluco-cerebrosidase
c. Hexosaminidase A
d. Alpha galactosidase

Ans. is 'b' Gluco-cerebrosidase

Sphingolipidoses for lipid storage diseases

No	Disease	Enzyme defect	Lipid accumulating	Salient features
1.	Gaucher's disease	β-glucosidase	Glucocerebroside	3 types—adult, infantile, juvenile hepatosplenomegaly, erosion of bone, moderate anemia
2.	Niemann-Pick disease	Sphingomyelinase	Sphingomyelin	Severe CNS damage, mental retardation, hepatosplenomegaly, Cherry red spot in macula. Death occurs by 2 years of age
3.	Krabbes leukodystrophy	β-galactosidase	Galactocerebroside	Severe mental retardation. Total absence of myelin in CNS Globoid bodies in white matter
4.	Metachromatic leukodystrophy	Sulfatidesulfatase	Sulfogalactocerebroside	Accumulates in most tissues. Neurological deficit, difficult in speech and optic atrophy. Demyelination is also seen
5.	Fabry's disease	α-galactosidase	Ceramide trihexoside	Kidney is the site of accumulation. Progressive renal failure, death by 5 years of age. Purplish papules appear. 'X' linked inheritance
6.	Tay Sach's disease	Hexosaminidase A	Ganglioside (GM2)	Incidence 1 in 6000 births. Mental retardation. Cherry red spot in the macula. Progressive deterioration. Death by 3–4 years
7.	Generalized gangliosidoses	β-galactosidase	Ganglioside (GM1)	Mental retardation, hepatomegaly, skeletal deformities. Foam cells in bone marrow. Cherry red spot in the retina
8.	Lactosyl ceramidoses	β-galactosidase	Lactosyl ceramide	Mainly CNS and reticuloendothelia system affected
9.	Sandhoff's disease	Hexosaminidase A and B	Globoside	Neurological deficit, mental retardation

JAYPEE BROTHERS

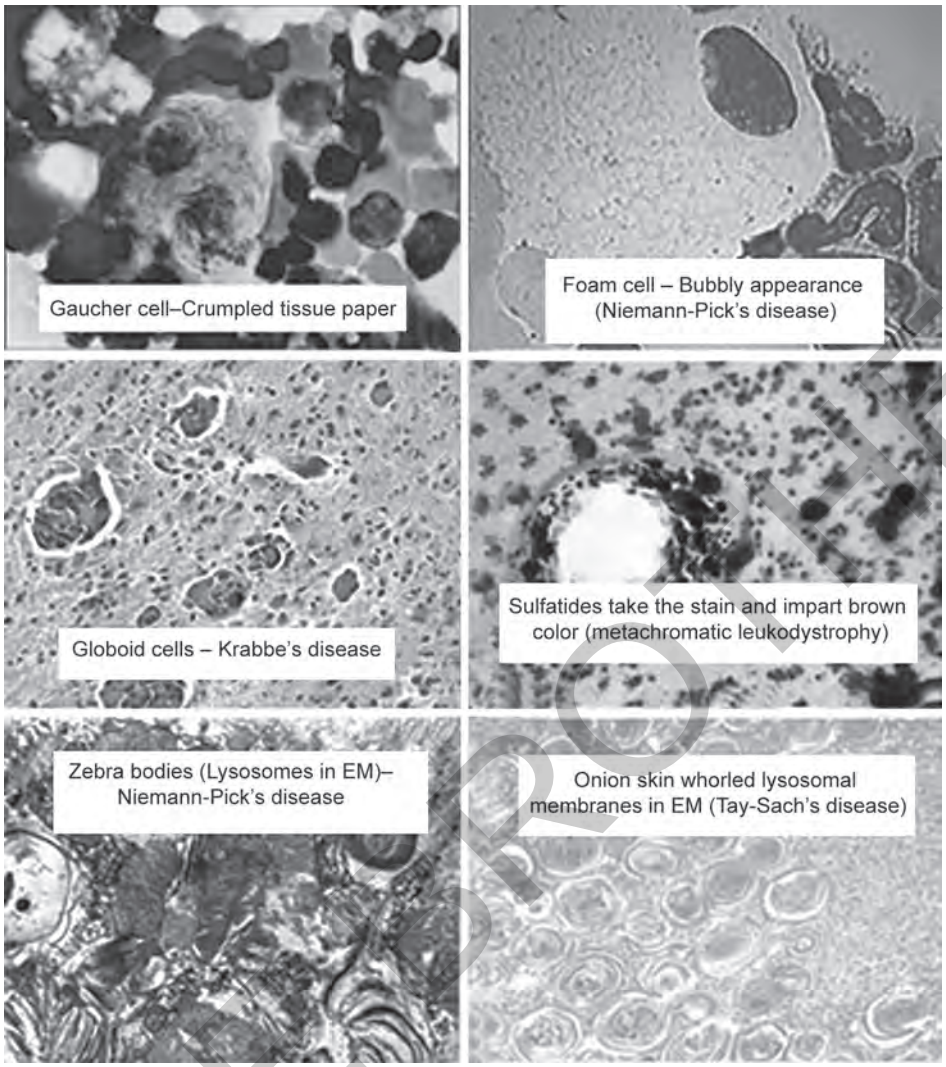

For colour version see Plate 2

18. Transparency of corneal endothelium is maintained by:

a. Heparan sulphate
b. Keratan sulphate
c. Chondroitin sulphate
d. Hyaluronic acid

Ans. is 'b' Keratan sulphate

Glycosaminoglycans

Proteoglycan	*Repeated units*	*Location*
Hyaluronic acid	Glucuronic acid + NAG	Only GAG that is NON-SULFATED Synovial fluid, vitreous Role in cell migration
Chondroitin sulfate	Glucuronic acid + NAGal	Commonest GAG Cartilages, tendons
Heparan sulfate	Glucuronic acid + sulfoglucosamine	ECM
Heparin	Iduronic acid + sulfoglucosamine	Only intracellular within organs and monocytes
Dermatan sulfate	Iduronic acid + NAGal	Skin, heart valves Blood vessels Sclera—gives shape to eye
Keratan sulfate	Galactose + NAG	Only GAG with NO URONIC ACID Type-1: Cornea, hair nails, horns, claws Type-2: Cartilage

JAYPEE BROTHERS

19. Which vitamin deficiency causes this?



a. Thiamine
b. Niacin
c. Zinc
d. Pyridoxine

Ans. is 'b' Niacin

For detail see explanation on page 130

20. A 25-year-old patient presented with dark urine, which further blackens on exposure to air. What is the enzyme defect in this case?

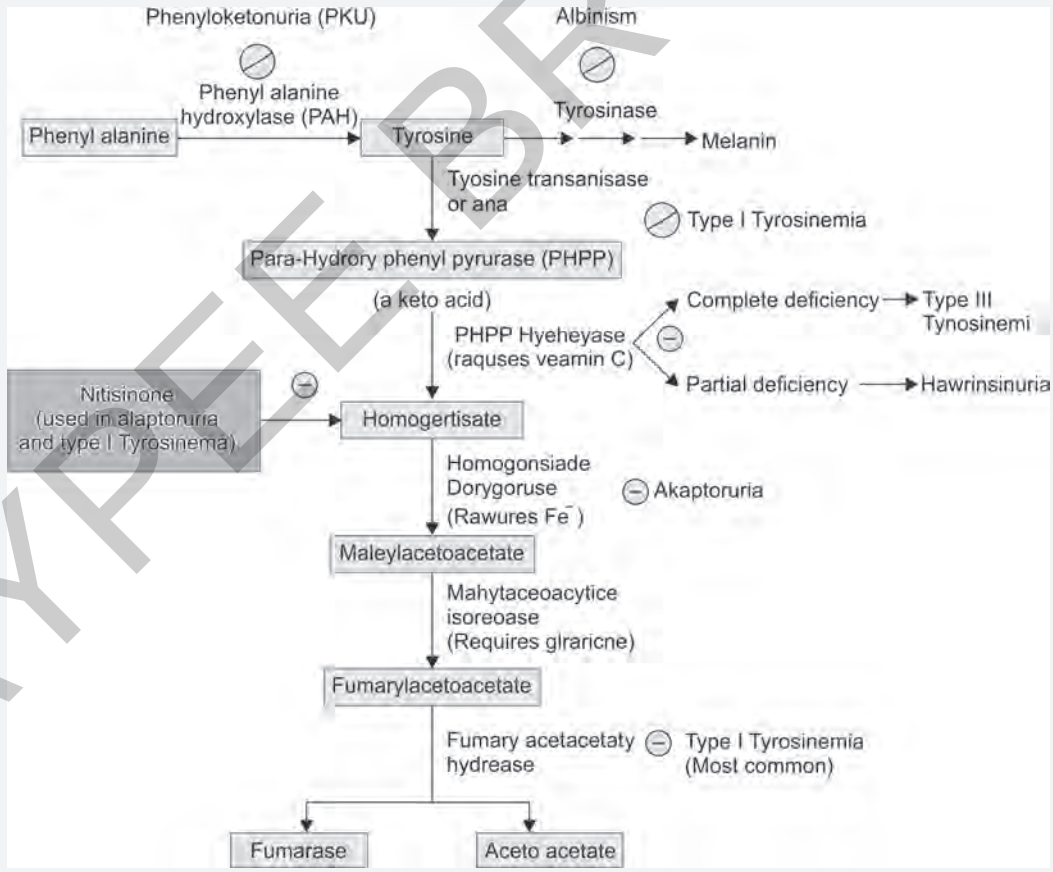

a. Fumaryl acetoacetate hydrolase
b. Dihydroxy phenyl acetate dioxygenase
c. Homogentisate dehydrogenase
d. Phenyl alanine hydroxylase

Ans. is 'b' Dihydroxy phenyl acetate dioxygenase

JAYPEE BROTHERS

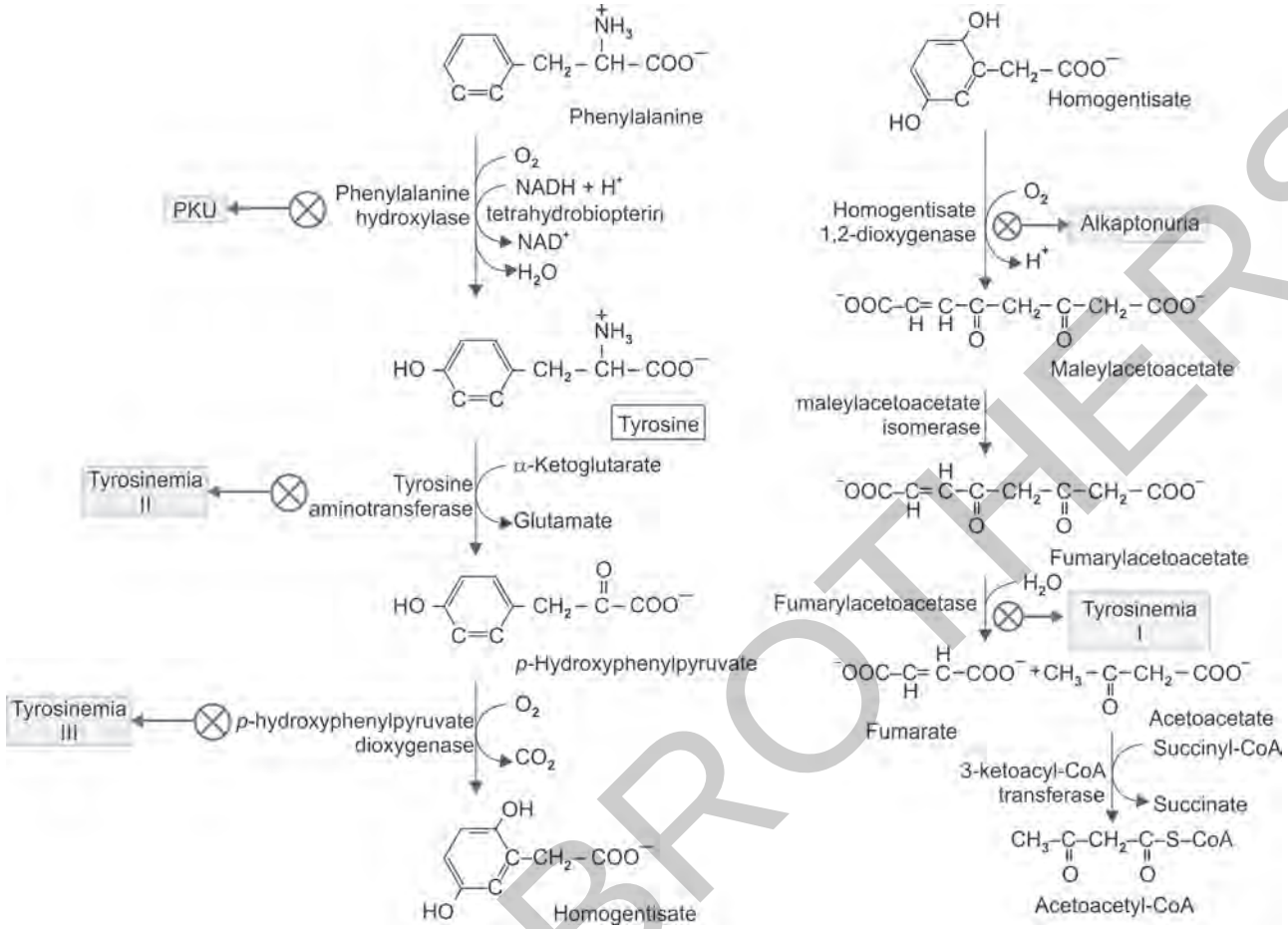

21. In an isolated mitochondria, in a medium containing Succinate, Fumarate, ADP and Pi, ATP were produced. Later a compound was added, and oxidative phosphorylation was decreased. What is that compound?

a. Oligomycin b. 2,4 dinitrophenol
c. Antimycin d. Rotenone

Ans. is 'a' Oligomycin

Compounds which affect electron transport chain and oxidative phosphorylation	
1.	Complex I to Co-Q specific inhibitors
	i. Alkylguanides (guanethide), hypotensive drug ii. Rotenone, insecticide and fish poison iii. Barbiturates (amobarbital), sedative iv. Chlorpromazine, tranquilizer v. Piericidin, antibiotic
2.	Complex II to Co-Q I. Carboxin
3.	Complex II to cytochrome c inhibitors i. Bal (British anti-lewisite), antidote of war gas ii. Naphthoquinone iii. Antimycin
4.	Complex IV inhibitors i. Carbon monoxide, inhibits cellular respiration ii. Cyanide (CN^-) iii. Azide (N_3^-) iv. Hydrogen sulfide (H_2S)

Contd…

JAYPEE BROTHERS

for detailed information on PGMEE books, visit our website **www.jaypeebrothers.com**, for detailed information on PGMEE books, visit our

The Next Level of Preparation

NEET PG

CRYSTAL CLEAR



Dr Thameem Saif

MD Medicine is a renowned teacher head in very high regard by medicos both in India and the US. He is an intellect of high order with brilliant teaching skills. His input have been found to be very valuable by his students across the country and he has helped lots of students achieve their dreams of clearing the tough Indian Medical PG Entrance Exam and the USMLE. Most of the toppers in the country today thank him in their heart for playing an important role in their success. He is well known for solving MCQs in an organised approach to reach towards the answer. His orientation about how to approach MCQs with latest patterns proposed for National Eligibility Entrance Test is an important aspect of his session.



Dr Apurv Mehra

MBBS (MAMC) MS ORTHO (UCMS) DNB ORTHO DIP SICOT (BELGIUM) FELLOWSHIP JOINT REPLACEMENTS GERMANY, AUSTRALIA, MALAYSIA

Dr Apurv Mehra is the Leading Faculty of Orthopedics & is recognized Nationally & Internationally as an outstanding teacher, world class scholar & dedicated mentor. He is best known for his stupendous efforts in teaching, motivating and inspiring budding doctors. The quality that sets him apart is his unique style of teaching with fun & passion. Dr Apurv Mehra is also co-founder of Cerebellum Academy – An Institute By The Top Most Educators Online To Guide Students Preparing for Medical Entrance Exams. Dr Apurv Mehra is a youth icon, guide, mentor and role model for aspiring doctors. He is known for his highly inspirational and motivational speeches. Inspired from his lectures, students not only "learn" but actually follow Dr Apurv Mehra and also implement his advice & guidance in their day to day lives.



Dr Akhil Monga

MD Radiodiagnosis, AIIMS, New Delhi cleared his AIIMS PGMEE in November 2015. It was the exam that saw the introduction of the image-based questions. He proved then, that as long as you have strong concepts and have strong hold on the commonly asked topics, you shall not be surprised by any new element in the exam. He along with Dr Kavan Parikh has come up with this book to emphasize that though practising new MCQs and understanding the scoring pattern of these questions is important, the subject matter needed to do a focussed revision is still similar. The goal is to reduce the "last month anxiety" of revising 19 subjects before the exam.



Dr Kavan Parikh

MBBS MD Radiodiagnosis, BJMC, Ahmedabad, Gujarat cleared NEET PG 2019 in his first attempt along with internship with an AIR 18 and state rank of 3. But it seemed destiny demanded more from him. He eventually appeared for AIIMS Nov-2019 and secured AIR 106 followed by NEET PG 2020 AIR of 21. However, NEET 2020 turned out to be a difficult exam with a lot of clinical and intersubjective integration, but amidst all adversities, he managed to maintain his position and improve his score. Getting a great rank 1st time is difficult, but getting it once again is even more difficult. With all his experience and insight about NEET, AIIMS and NEXT exams, he actively mentors PG aspirants.

Printed in India

Available at all medical bookstores or buy online at www.ejaypee.com

JAYPEE BROTHERS
Medical Publishers (P) Ltd.
EMCA House, 23/23-B, Ansari Road,
Daryaganj, New Delhi - 110 002, INDIA
www.jaypeebrothers.com

Join us on facebook.com/JaypeeMedicalPublishers
Follow us on instagram.com/JaypeeMedicalPublishers

ISBN 978-93-5465-999-7