, visit our website www.jaypeebrothers.com, for detailed information on obstetrics & gynecology books, visit our website www.jaypeebrothers.com

Clinical Focus on

Male and Female Infertility

Series Editors
Neharika Malhotra
Jaideep Malhotra
Narendra Malhotra

Editors
Shaheen Anjum
Keshav Malhotra

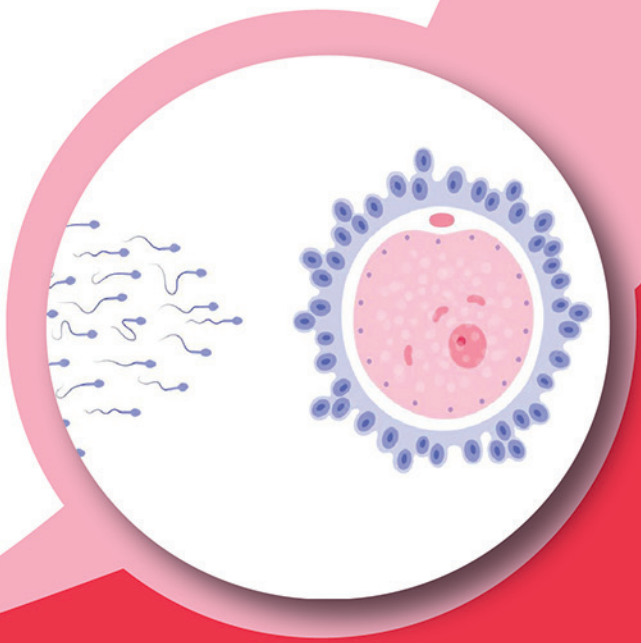

Foreword
Jatin P Shah

JAYPEE

Contents

1. **Evaluation of Infertile Couple** **1**
   Shikha Seth, Narendra Malhotra

2. **Male Infertility** **10**
   Deeba Khanam, Shaheen Anjum, Keshav Malhotra

3. **The Environment and Infertility** **16**
   Jaya Sharma, Jaideep Malhotra, Divya Yadav

4. **Genetics and Infertility** **22**
   Ruchika Garg, Rekha Rani

5. **Nutrition and Infertility** **25**
   Sufia Naseem, Shaheen Anjum

6. **Ultrasound Evaluation of Infertility** **33**
   Maneesha Jain, Narendra Malhotra

7. **Management of Tubal Factor in Fertility** **46**
   Anu Agarwal, Shikha Sachan

8. **Anovulatory Infertility** **52**
   Rehana Najam, Jaideep Malhotra

9. **Unexplained Infertility** **61**
   Neharika Malhotra, Narendra Malhotra

10. **Assisted Reproductive Techniques: When to Refer** **68**
    Saeeda Wasim, Sharique Ahmad

Index *77*

CHAPTER 2

Male Infertility

Deeba Khanam, Shaheen Anjum, Keshav Malhotra

INTRODUCTION

Infertility is defined as inability to conceive after 1 year of regular sexual intercourse without using any contraception.[1] Various bodies like World Health Organization (WHO), the American Society for Reproductive Medicine and American Medical Association (AMA) have labeled it as a disease which requires evaluation and treatment.[2] The couples, who could not conceive in the first year of married life contribute to approximately 15% and majority of them conceive in second year of regular unprotected sexual intercourse. A male factor as an isolated cause for infertility is present in 20% of infertile couples and may exist along with other causes of infertility in approximately 30-40%[3] of infertile population. Infertility evaluation is recommended after 1 year of failed attempt to conceive, however it should be proposed after 6 months when the age of female partner is greater than 35 years of age.[4]

MALE INFERTILITY

Definition

Primary male infertility is defined as a condition where male has never been able to contribute to a clinical pregnancy, whereas secondary male infertility refers to a condition where the male partner is unable to impregnate her sexual partner, but who had procreated a clinical pregnancy previously.[2]

Causes

The causes of male infertility can be identified as factors acting at pre-testicular, testicular or post-testicular level.[5] However, despite advancements 50% causes cannot be clinically identified and labeled as idiopathic infertility.

Pretesticular Causes

They are known as extra-gonadal endocrine disorders originating in the pituitary, hypothalamus or adrenals. A systemic problem could progress from hormonal imbalances, genetic disorders, poor health, obesity, dietary and age patterns.

Hypogonadotropic hypogonadism:

- Idiopathic
- Kallmann syndrome, Prader-Willi syndrome, Laurence-Moon-Biedl syndrome

Pitutary causes:

- Prolactinoma
- Isolated LH deficiency
- Isolated FSH deficiency
- Craniopharyngioma
- Pituitary tumors
- Infiltrative diseases
- Trauma
- Critical and chronic diseases

Coital disorders:

- Erectile dysfunction
- Ejaculatory disorder

JAYPEE BROTHERS

Testicular disorders:
- Varicocele
- Cryptorchidism
- Noonan syndrome
- Vanishing testicular disease
- Myotonic dystrophy
- Y-chromosome microdeletion
- XX male (sex reversal syndrome)
- XYY male
- Noonan syndrome (male Turner syndrome)
- Androgen receptor defect

Testicular injury:
- Trauma
- Torsion

Systemic diseases:
- Liver diseases
- Renal diseases
- Congenital adrenal hyperplasia (CAH) Alcoholism
- HIV
- Orchitis
- Obesity
- Chronic gastroenteritis
- Hematological diseases

Gonadotoxins:
- Radiotherapy
- Drugs
- Toxins.

Post-testicular Causes
- Obstruction
- Transportation and ductal system defects
- *Congenital:* Diethylstilbestrol (DES) exposure, cystic fibrosis
- *Acquired:* Infections, surgery, stone, prostatic cyst, antisperm antibodies
- Immotile cilia syndrome
  Ejaculation defects
- Diabetes, bladder neck surgery, colon, rectal, prostate surgery, spinal cord injury
- Infections.

Evaluation

Evaluation of infertility requires simultaneous assessment of both male and female partners. The American Urological Association (AUA) and American Society of Reproductive Medicine (ASRM) recommends that at a minimum, the infertility work-up includes a detailed history, physical examination and two separate semen analyses to identify risk factors for male infertility.[6] The consistent presence of abnormal semen parameters supports meticulous evaluation of male partner furthermore. Semen parameters are assessed according to WHO 5th edition recommendations[1] as mentioned in **Table 1**.

TABLE 1: Semen parameters (WHO 5th Edition recommendations).

Semen Parameter	***One-sided lower reference limit (Fifth centiles with 95% confidence intervals)***
Semen volume	1.5 mL (1.4–1.7)
Total sperm number	39 million per ejaculate (33–46)
Sperm concentration	15 million/mL (12–16 million/mL)
Vitality	58% Live (55–63%)
Progressive motility	32% (31–34%)
Total motility (Progressive + Non-progressive)	40%
Morphologically normal forms	4.0% (3.0–4.0)

JAYPEE BROTHERS

The evaluation of men with abnormal SAs and/or abnormal reproductive history, including physical examination and selected laboratory and radiologic assessment, should be done by expert in male infertility.

History

While evaluating the male partner with detailed history (reproductive, sexual, past, personal and family) and meticulous physical examination[7] of male reproductive organs existing or newly diagnosed comorbid conditions are identified, e.g. diabetes, endocrinopathies, hypertension, etc., and treatment is offered as increasing number of studies report increased medical comorbidities associated with abnormal SA.[8]

Physical Examination

- It includes general and local examinations.
- Body habitus—eunuchoid body, infantile hair, poor muscular development, longer lower body—endocrinal disorders
- Truncal obesity, striae, Moon facies—Cushing syndrome
- Thyroid swelling
- Hepatomegaly, lymph nodes for lymphomas.

Local Examination

- *Phallus:* Meatal location as hypospadias/epispadias, penile lesions/ulcers/discharge
- *Scrotum/testes:* Examination for previous scars, position, size and consistency of the testes and palpation of testicular masses.
- *Epididymides:* Size, shape and consistency to be evaluated. Exclusion of induration/dilation which suggests obstruction.
- *Vas deferens:* Examination of its presence, shape/consistency as its abnormality may be suggestive of CFTR mutation.
- *Digital rectal examination:* Evaluation of prostatic cysts or dilated seminal vesicles to rule out EDO (epididymal obstruction).

Semen Analysis (SA)

Individual semen parameters measured in the SA are not diagnostic of male infertility, however isolated parameters like azoospermia, necrozoospermia or specific type of morphological pattern like globozoospermia may raise fertility concerns.[6] ASRM states that an endocrine evaluation is not indicated as first line investigation but is vindicated with clinical findings suggestive of endocrinopathy, sexual dysfunction (decreased libido, erectile dysfunction) and abnormal laboratory parameters such as oligozoospermia or azoospermia are obtained.[8] Endocrinal evaluation includes testing for free testosterone, LH, FSH, and prolactin levels in men evaluated for male sexual dysfunction.

Oligozoospermia/Oligospermia (Decreased Sperm Count)

Oligospermia (<10 million sperm/mL) in semen analysis requires hormonal evaluation of the male partner (FSH, testosterone and luteinizing hormone) and is also indicated in men with sexual dysfunction. Low serum testosterone (<300 ng/dL) warrants PRL levels evaluation to exclude hypo- gonadotropic hypogonadism in men.[9]

Azoospermia (Absence of Sperm in Ejaculate)

This finding warrants classifying azoospermia into obstructive and non-obstructive type. On the basis of history, physical examination and hormonal studies this differentiation can be made. Men with azoospermia and normal semen volume, smaller testes on

JAYPEE BROTHERS

examination and elevated FSH levels are suggestive of testicular failure and will have NOA (azoospermia due to impaired sperm production). Men with azoospermia with decreased semen volume (<0.5 or 1.0 mL), normal testicular size (e.g., testis length >4.6 cm), and normal FSH levels (<7.6) suffer from obstructive azoospermia, especially when supported by physical examination of proximal epididymis enlargement and absent vas deferens.[9]

Severe Oligospermia (Less than 5 Million Count) and Non-obstructive Azoospermia

Men with severe oligospermia (<5 M/mL) including NOA should be evaluated with karyotyping and Y-microdeletion studies.[10] The most common chromosomal abnormality is Klinefelter syndrome (47 XXY), and second most common genetic cause is Y-chromosome microdeletions of azoospermic genes. Sperms may be retrieved through microsurgical sperm extraction in the former and may not be retrieved at all in specific Y- chromosome microdeletions.

Obstructive Azoospermia

Diagnosis is suggested by azoospermia, normal FSH and testosterone levels and physical examinations confirming absence of vas deferens, epididymal obstruction or ejaculatory duct obstruction. If congenital absence of vas deferens is suspected, unilateral or bilateral, then *CFTR* gene mutation evaluation should be advised in the male partner and if found to be positive female partner should be screened for the presence of carrier gene which may possibly affect the transmission of the defect to the offspring.[11,12] These mutations are also associated with renal abnormalities and therefore transrectal ultrasound is advised for confirmation of diagnosis and proper counseling. Treatment incudes extraction of sperm through different microsurgical techniques. Reversible causes of obstructive azoospermia should be treated as per the norms.

Asthenozoospermia (Decreased Sperm Motility)

Specific movement attributes (average path velocity, moving straight, and amplitude of lateral sperm head displacement) of spermatozoa are considered features of semen quality that can facilitate cervical barrier penetration.[13] The causes of asthenozoospermia include varicocele, genetic abnormalities, lifestyle, radiations, infections, psychological stress, and environmental factors. Assessing the factors responsible and preventing or regulating them may affect the motility. Researchers have proposed certain novel motility enhancing proteins derived from caprine serum which are known to enhance sperm motility in vitro.[14,15] However, ART has been proposed for abnormalities in sperm motility for now.

Sperm Vitality

It is an important predictor of sperm viability and is estimated by percentage of live spermatozoa with intact membranes. WHO 2010 guidelines states that 42% dead sperm is the cut-off for necrospermia (dead sperm) and 58% should be live (viable). DNA fragmentation is the last step of sperm death and is linked to poor sperm viability. Both increased DNA fragmentation and poor viability have positive correlation with male infertility and the parameters are influenced by number of systemic and local conditions

JAYPEE BROTHERS

associated with males[16] and that needs identification. However DNA fragmentation studies are not proposed as first line in initial evaluation of male infertility but may be used in RPL and for sperm selection in ART.[9]

Pyospermia

If the round cells on SA are increased in number (>1 million/mL), then attempts should be made to further to differentiate white blood cells (pyospermia) from germ cells. Semen culture is recommended in patients with pyospermia.[9]

Postejaculatory Urine Analysis

This test should be considered to identify retrograde ejaculation and differentiate it from obstructive causes of oligo/azoospermia. When the volume of ejaculate is less (<2 mL), condition is known as hypospermia or if there is no ejaculate at all, known as aspermia.[1] Abstinence of 1 day or less or loss of sample can be the contributory factor. To evaluate urine sample, it should be centrifuged for 10 minutes at 300 rpm and seen at 400 magnification.[17] Any sperm in urine is diagnostic of retrograde ejaculation.

Imaging

Imaging is not used as initial investigating modality in male infertility evaluation.[9] The main role of imaging is to identify the cause of infertility and help categorize it into Obstructive and non-obstructive causes. When the examination of scrotum is difficult to, especially in obesity and then scrotal ultrasound may be advised. Testicular atrophy, varicocele, absence of vas deferens and dysplastic seminal vesicles may be identified through sonography,[18,19] when examination findings are unable to determine the pathology. Ejaculatory duct anomalies require TRUS (Transrectal ultrasonography) for diagnosis.[20]

Management

Successful pregnancy requires a sperm which is morphologically and functionally normal and therefore male infertility requires assiduous evaluation. ART has opened opportunities for infertile couples with subtle and apparent male factor infertility. Treatment offered is case based and depends on the pathology including systemic and local causes.

Pharmacological treatment like aromatase inhibitors, SERMs, and hCG injections are prescribed for males with testosterone deficiency. Gonadotropins are recommended for males with hypogonadotropic hypogonadism with low levels of LH and FSH. For primary testicular failure, microsurgical procedures for sperm aspiration and extraction are preferred. Novel technologies such as stem cell implants for spermatogenesis and its maintenance are under research to provide hope to patients with testicular failure. Idiopathic male infertility is not benefitted by pharmacological therapy but gonadotropins may be offered to improve pregnancy rates.[9]

CONCLUSION

Male infertility evaluation requires a combination of detail history, physical examination, semen analysis, hormonal profile, and imaging and is advised when required. Genetic testing and testicular biopsy requires definite recommendation. Newer research into evaluation of these genetic, genomic, epigenetic, metabolomic defects is suggested for better understanding of male infertility.

JAYPEE BROTHERS

REFERENCES

1. World Health Organization. WHO Laboratory Manual for the Examination and Processing of Human Semen, 5 edition. Geneva, Switzerland: WHO Press. 2010. p. 287.
2. Practice Committee of the American Society for Reproductive Medicine. Definitions of infertility and recurrent pregnancy loss: a committee opinion. Fertil Steril. 2020; 113:533-5.
3. Thonneau P, Marchand S, Tallec A, et al. Incidence and main causes of infertility in a resident population (1,850,000) of three French regions (1988–1989). Hum Reprod. 1991;6:811.
4. Rowe T. Fertility and a woman's age. J Reprod Med. 2006;51:157.
5. Dimitriadis F, Adonakis G, Kaponis A, Mamoulakis C, Takenaka A, et al. Pre-testicular, testicular, and post-testicular causes of male infertility. In: Simoni M, Huhtaniemi I (Eds). Endocrinology of the Testis and Male Reproduction. Cham: Springer; 2017. p1364.
6. Guzick DS, Overstreet JW, Factor-Litvak P, et al. Sperm morphology, motility, and concentration in fertile and infertile men. N Engl J Med. 2001; 345:1388.
7. Practice Committee of the American Society for Reproductive Medicine. Diagnostic evaluation of the infertile male: a committee opinion. Fertil Steril. 2015;103:e18.
8. Oliva A and Multigner L. Chronic epididymitis and grade III varicocele and their associations with semen characteristics in men consulting for couple infertility. Asian J Androl. 2018;20:360.
9. Schlegel PN, Sigman M, Collura B, De Jonge CJ, Eisenberg ML, Lamb DJ, Mulhall JP, Niederberger C, Sandlow JI, Sokol RZ, Spandorfer SD, Tanrikut C, Treadwell JR, Oristaglio JT, Zini A. Diagnosis and treatment of infertility in men: AUA/ASRM Guideline Part I. J Urol. 2021;205(1):36-43. doi: 10.1097/JU.0000000000001521. Epub 2020 Dec 9. PMID: 33295257.
10. Behre HM, Bergmann M, Simoni M, et al. Primary testicular failure. [updated 2015 Aug 30]. South Dartmouth, MA: MDText.com, Inc., 2000.
11. Chillon M, Casals T, Mercier B, et al. Mutations in the cystic fibrosis gene in patients with congenital absence of the vas deferens. N Engl J Med. 1995;332:1475.
12. Yu J, Chen Z, Ni Y, et al. CFTR mutations in men with congenital bilateral absence of the vas deferens (CBAVD): a systemic review and meta-analysis. Hum Reprod. 2012;27:25-35.
13. Aitken RJ, Sutton M, Warner P, Richardson DW. Relationship between the movement characteristics of human spermatozoa and their ability to penetrate cervical mucus and zona-free hamster oocytes. J Reprod Fertil. 1985;73:441-9.
14. Mandal M, Saha S, Ghosh AK, Majumder GC. Identification and characterization of a sperm motility promoting glycoprotein from buffalo blood serum. J Cell Physiol. 2006;209:353-62.
15. Dey S, Roy D, Majumder GC, Bhattacharyya D. Extracellular regulation of sperm transmembrane adenylyl cyclase by a forward motility stimulating protein. PLoS One. 2014;9:e110669.
16. Brahem S, Jellad S, Ibala S, Saad A, Mehdi M. DNA fragmentation status in patients with necrozoospermia. Syst Biol Reprod Med. 2012;58(6):319-23.
17. McMahon CG. Disorders of male orgasm and ejaculation. In: Wein AJ, Kavoussi LR, Partin AW, et al (Eds). Campbell-Walsh Urology. Philadelphia: Elsevier, 2016;692-708.
18. Ammar T, Sidhu PS, Wilkins CJ. Male infertility: the role of imaging in diagnosis and management. Br J Radiol. 2012;85 (special_issue_1):59-68.
19. Brugh VM, III, Matschke HM, Lipshultz LI. Male factor infertility. Endocrinol Metab Clin North Am. 2003;32(3):689-707.
20. Jarow JP, Espeland MA, Lipshultz LI. Evaluation of the azoospermic patient. J Urol. 1989;142(1):62-5. doi: 10.1016/S0022-5347(17)38662-7.

JAYPEE BROTHERS

for detailed information on obstetrics & gynecology books, visit our website www.jaypeebrothers.com, for detailed information on obstetrics & gyne

Clinical Focus on
Male and Female Infertility


Neharika Malhotra


Jaideep Malhotra


Narendra Malhotra


Shaheen Anjum


Keshav Malhotra


Jatin P Shah

Infertility is seen in almost 15 % of our population. The concept of managing infertility is change today to active management. This book addresses all the issues of male and female infertility.

Printed in India

Available at all medical bookstores
or buy online at www.jaypeebrothers.com

JAYPEE BROTHERS
Medical Publishers (P) Ltd.
EMCA House, 23/23-B, Ansari Road,
Daryaganj, New Delhi - 110 002, INDIA
www.jaypeebrothers.com

Join us on facebook.com/JaypeeMedicalPublishers

Shelving Recommendation
OBSTETRICS & GYNECOLOGY

ISBN 978-93-5696-095-4