ers.com, for detailed information on obstetrics & gynecology books, visit our website www.jaypeebrothers.com, for detailed information on obstetrics & gynecology books

Look Inside the Book

Bedside Clinics in Gynecology

Clinics to Care with Illustrations

- History Taking & Examinations
- Clinical Cases
- Instruments, Operations, Specimens & Imagings
- Research Questions
- Examination of a Rape Victim
- Pelvic Inflammatory Disease & STDs

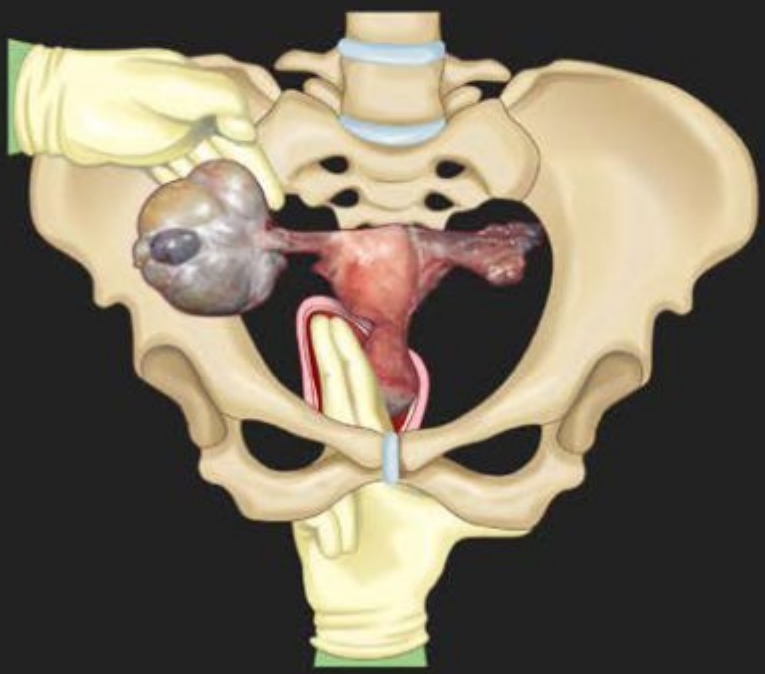

Arup Kumar Majhi

2nd Edition

JAYPEE

CONTENTS

SECTION 1: GYNECOLOGICAL HISTORY TAKING, EXAMINATION AND INVESTIGATIONS

1. Writing a Gynecology Case 3

- Structure of History Writing 3
- Detailed Parameters Under the Broad Headings 3
- Discussion of the Points Essential for Proper Case Taking and Writing 5
- Investigations Supplied or Required 33
- Summary of the Case 33
- Example of Writing a Summary (Sample Summary) 33
- Provisional Diagnosis 33
- Differential Diagnosis 33

2. Investigative Procedures in Gynecology and Imaging in Gynecology 34

- Investigations 34
- Imaging in Gynecology 37
- Role of Ultrasonography in Gynecology 37
- Role of USG According to Symptomatology 38
- Procedures Under Ultrasonography Guidance 38
- Computed Tomography Scan (CT Scan) 40
- Magnetic Resonance Imaging (MRI) in Gynecology 40
- Positron Emission Tomography (PET) 41
- X-ray—its Role in Gynecology 41
- Pipelle Biopsy 41

SECTION 2: CLINICAL CASES

3. A Case of Lump Abdomen (Ovarian Tumor) 45

- History Taking 45
- Physical Examination 46
- Gynecological Examination 46
- Summary of the Case (Sample Summary) 46
- Investigations Supplied or Required 46
- Provisional Diagnosis 47
- Differential Diagnosis 47
- Diagnosis of a Case of Benign Ovarian Tumor 48
- USG Features of Malignant Ovarian Tumor 50
- Tumor Markers in Ovarian Malignancy 51
- Classification of Ovarian Tumor 52
- Epithelial-Stromal Tumors 53
- Sex Cord—Stromal Tumors 53
- Germ Cell Tumors 53
- Secondary (Metastatic) Tumors 53
- Functional Cyst 53
- Follicular Cyst 54
- Corpus Luteum Cyst 54
- Theca Lutein Cyst 54
- Classification of Ovarian Tumor 54
- Benign Serous Cystadenoma 55
- Benign Mucinous Cystadenoma 55
- Brenner (Transitional) Tumor 56
- Dermoid Cyst of Ovary (Synonym: Benign Cystic Teratoma) 56
- Complications of Ovarian Tumor 58
- Pseudomyxoma Peritonei 59
- Management of a Case of Benign Ovarian Cyst and Tumor 59
- Steps of Laparotomy in a Case of Ovarian Tumor 60

Ovarian Cancer 62

- Screening of Ovarian Cancer 62
- Genetic Testing in Ovarian Cancer and its Utility 63
- Types and Pathology of Ovarian Cancer 63
- Diagnosis and Investigations of Ovarian Cancer 64
- Route of Spread of Epithelial Ovarian Cancers 66
- Stages of Ovarian Cancer 67
- Gradings of Ovarian Malignancy 68
- Management of Early-stage and Advanced Ovarian Cancer 68
- Steps of Surgical Staging 69
- Chemotherapeutic Agents Used in Ovarian Malignancy 71
- Recurrent Ovarian Cancer 71
- Borderline Ovarian Tumor (Synonym: Low Malignant Potential Tumor) 72

Fallopian Tube (FT) Cancer 73

- Germ Cell Tumors 74
- Sex Cord Stromal Tumors 77
- Management of a Case of Ovarian Tumor in Pregnancy 81

4. A Case of Uterine Leiomyoma (Uterine Fibroid) 82

- Patient's Particulars 82
- History 82
- Physical Examination 83
- Systemic Examination 83
- Gynecological Examination 83
- Summary of the Case (Sample) 83
- Investigations Supplied or Required 84

JAYPEE BROTHERS

- Provisional Diagnosis 84
- Differential Diagnosis 84
- Diagnosis of Fibroid Uterus 84
- Wandering and Parasitic Fibroid 90
- Broad Ligament Fibroids 90
- Microscopical Features 92
- Degenerations of Uterine Fibroid 92
- Details of Management of Fibroid Uterus 94
- Surgery 97
- Hysteroscopic Myomectomy 97
- Laparoscopic Myomectomy 97
- Open Myomectomy 98
- Cervical Fibroid 102
- Broad Ligament Cysts and Tumors 105
- Uterine Polyp 107

5. A Case of Abnormal Uterine Bleeding (Endometrial Hyperplasia) 110

- Patient's Particulars 110
- History 110
- Physical Examination 111
- Gynecological Examination 111
- Summary of the Case 111
- Definition of AUB 112
- Causes of Reproductive Tract Bleeding 113
- Structural and Nonstructural Causes of AUB as Defined in PALM-COEIN Classifications by FIGO 2011 113
- Dysfunctional Uterine Bleeding (DUB) 117
- Postcoital Bleeding 117
- Diagnosis of AUB 117
- Case of AUB 118
- Endometrial Biopsy—Different Methods 120
- Management 121
- Uterine Procedures 126
- Heavy Menstrual Bleeding in Adolescents (Puberty Menorrhagia) 128
- Metropathia Hemorrhagica 129
- Isthmocele 130
- Arteriovenous Malformation (AVM) 130
- Myometrial Hypertrophy 130
- Endometrial Hyperplasia 130
- Classification 131

6. A Case of Endometrial Carcinoma (Including Postmenopausal Bleeding) and Uterine Sarcoma 133

- Patient's Particulars 133
- History 133
- Physical Examination 134
- Gynecological Examination 134
- Investigations Supplied or Required 134
- Summary of the Case (Sample) 134
- Provisional Diagnosis 134
- Differential Diagnosis 134
- History 136
- Management of Endometrial Carcinoma 140
- Pyometra 144
- Postmenopausal Bleeding (PMB) 144
- Sarcoma of the Uterus 146

7. A Case of Choriocarcinoma (Gestational Trophoblastic Neoplasia) 149

- Patient's Particulars 149
- History 149
- Physical Examination 150
- Gynecological Examination 150
- Summary of the Case (Sample) 150
- Investigations Supplied or Required 150
- Provisional Diagnosis 151
- Differential Diagnosis 151

8. A Case of Carcinoma Cervix and Premalignant Lesions of Cervix 157

- Patient's Particulars 157
- History 157
- Physical Examination 158
- Stages of Cancer Cervix 161
- Lymphatic Drainage of Cancer Cervix 165
- Management of Cancer Cervix 166
- Radical Hysterectomy 167
- Premalignant Lesions of Cervix 170
- Cervical Carcinogenesis 173
- Colposcopy 177
- Human Papilloma Virus Vaccine 183

9. A Case of Carcinoma Vulva, Preinvasive Lesion of Vulva, and Vaginal Cancer 185

- Patient's Particulars 185
- History 185
- Physical Examination 186
- Systemic Examination 186
- Gynecological Examination 186
- Summary of the Case (Sample) 186
- Investigations Supplied or Required 187
- Provisional Diagnosis 187
- Differential Diagnosis (If H/P Not Available) 187
- Diagnosis of Vulvar Carcinoma 187
- Staging of Vulvar Cancer 190
- Key Changes in FIGO Staging for Vulvar Cancer 2021 191
- Management of Vulvar Cancer 191
- Prognosis of Vulvar Cancer 195
- Preinvasive Lesions of Vulva 196
- Vulvar Intraepithelial Disease 198
- Vaginal Cancer 199

JAYPEE BROTHERS

10. Pelvic Organ Prolapse (Genital Prolapse) 202

- Genital Prolapse 202
- History Taking 202
- Physical Examination 203
- Gynecological Examination 204
- Summary of the Case (Sample Summary) 204
- Investigations Supplied or Required 205
- Provisional Diagnosis 205
- Differential Diagnosis 205
- Supports of Uterus and Vagina 207
- Etiologies of Pelvic Organ Prolapse 209
- Anatomical Classification of Pelvic Organ Prolapse 210
- Grading Systems of Pelvic Organ Prolapse 212
- Pelvic Organ Prolapse Quantification System (POP-Q) 214
- Surgicopathological Changes in Pelvic Organ Prolapse 216
- Diagnosis of Pelvic Organ Prolapse 217
- Demonstration of POP-Q Staging 220
- Demonstration of Enterocele 222
- Demonstration of Stress Incontinence 222
- Management of Pelvic Organ Prolapse 223
- Conservative Management 223
- Vaginal Pessary 223
- Surgery in Pelvic Organ Prolapse 225
- Surgeries Done in POP 225

Operative Details of Pelvic Organ Prolapse 226

- Anterior Colporrhaphy 226
- Posterior Colpoperineorrhaphy 231
- Fothergill's Operation (Manchester Operation) 233
- Ward Mayo's Operation (Vaginal Hysterectomy with Pelvic Floor Repair) 236
- Le Fort's Operation (Colpocleisis) 241
- Purandare's Abdominal Sling Operation (1956) 241
- Shirodkar's Abdominal Sling Operation (1960) 241
- Khanna's Abdominal Sling Operation 241
- Abdominal Sacrocolpopexy, Sacrocolpohysteropexy 241
- Sacrospinous Ligament Fixation 243
- McCall Culdoplasty 244
- Prevention of Pelvic Organ Prolapse 245
- Pregnancy with Pelvic Organ Prolapse 245

11. A Case of Infertility 247

- Patient's Particular 247
- History 247
- Physical Examination 248
- Gynecological Examination 248
- Investigations Supplied or Required 249
- Summary of the Case (Sample) 249
- Provisional Diagnosis 249
- Differential Diagnosis 249
- Contribution of Male and Female Partners 249
- Causes of Female Factor Infertility 249
- Etiologies of Male Factor Infertility 250
- Investigation (Evaluation) of a Case of Infertility 250
- History and Examination of Female Partner 250
- History and Examination of Male Partner 251
- Diagnosis or Detection of Ovulation 251
- Ovarian Reserve 257
- Tubal Patency Test 258
- Anovulation 261
- Cervical Factor Causing Infertility 261
- Causes of Tubal Block 262
- Causes of Infertility in Endometriosis 262
- History and Examination of Male Partner 262
- Semen Analysis 264
- Hormones Profile in Assessment of Male Infertility 266
- Reactive Oxygen Species 267
- Management of Female Infertility 268
- Management of Ovulatory Dysfunction 268
- Management of Diminished Ovarian Reserve 271
- Ovarian Hyperstimulation Syndrome 271
- Surgical Management in Anovulation/Oligoovulation 272
- Tubal Factor Infertility 272
- Assisted Reproductive Technology 275
- In Vitro Fertilization and Embryo Transfer 275
- Surrogacy (Gestational Carrier Surrogacy) 279
- Management of Male Factor Infertility 280
- Intrauterine Insemination (IUI) 280
- Intracytoplasmic Sperm Injection 283
- Treatment of Erectile and Ejaculatory Dysfunction 285
- Azoospermia 286
- Klinefelter Syndrome (47 XXY) 287
- Vaginismus 287
- Unexplained Infertility 287

12. A Case of Polycystic Ovarian Syndrome and Hirsutism 288

A Case of Polycystic Ovary Syndrome 288

- Patient's Particular 288
- History 288
- Physical Examination 289
- Gynecological Examination 289
- Investigations Supplied or Required 289
- Summary of the Case (Sample) 289
- Diagnosis of PCOS 290
- Clinical Presentations of PCOS 292
- Complications of PCOS 292
- Etiology of PCOS 292
- Endocrine Profile and Other Investigations in PCOS 293
- Diagnosis of Adolescent PCOS 293
- Management Outline in a Case of PCOS 294
- Outline the Management of Adolescent PCOS 294
- Management of PCOS in Elderly 295
- Discuss the Pathophysiology of PCOS 295

JAYPEE BROTHERS

Hirsutism 297
- Exogenous Pharmacological Agents Causing Hirsutism 300
- Medications Causing Hirsutism and Hypertrichosis 300
- Idiopathic Hirsutism 300
- Androgen Synthesis in Female 300
- Different Androgens and their Sources 300
- Evaluation of Hirsutism 301
- Laboratory Investigations 302
- Further Investigations 302
- Imaging 302
- Summary of Recommendation for Evaluation of Hirsutism 303
- Outline the Management of Hirsutism 303
- Summary of Recommendation of Treatment 305
- Physiology of Hair 305
- Differential Diagnosis of PCOS 307

13. A Case of Primary Amenorrhea and Disorder of Sexual Development 308
- Writing a Case of Primary Amenorrhea 311
- Definition 312
- Etiologies of Primary Amenorrhea 313
- Common Causes of Primary Amenorrhea 313
- Diagnosis a Case of Primary Amenorrhea 314
- Discussion of Individual Cases 319
- Turner Syndrome 319
- Anatomical Defects Leading to Amenorrhea 321
- Creation of Neovagina 322
- Reifenstein Syndrome 325
- Swyer Syndrome 325
- Congenital Adrenal Hyperplasia (Adrenogenital Syndrome) 327

Disorder of Sexual Development (Intersex) 328
- Definition of DSD 328
- Gender Identity 328
- Sexual Differentiation: Mechanism 328
- Classification of Disorder of Sexual Differentiation 329
- Hermaphrodite 330
- Transgender 330
- New Nomenclature 330
- Gonads in Different DSDs 331
- Approach in a Case of Ambiguous Genitalia 331
- Diagnosis of a Case of Ambiguous Genitalia 331
- Management of a Case of DSD 332
- Gender Assignment 332
- Surgeries in DSDs 333
- Medical Management in DSDs 334

14. A Case of Secondary Amenorrhea 335

Case Taking in a Case of Secondary Amenorrhea 335
- Patient's Particular 335
- History 335
- Physical Examination 336
- Gynecological Examination 336
- Investigations Supplied or Required 336
- Summary of the Case (Sample Summary) 336
- Provisional Diagnosis 337
- Differential Diagnosis 337
- Definition of Secondary Amenorrhea 337
- Causes of Secondary Amenorrhea 337
- Diagnosis of Secondary Amenorrhea 338
- Approach to Diagnose a Case of Secondary Amenorrhea 339
- Hyperprolactinemia and Amenorrhea 339
- Thyroid Disorder and Amenorrhea 341
- Polycystic Ovarian Syndrome 342
- Obesity and Menstrual Abnormality 342
- Asherman Syndrome (Uterine Synechiae) 342
- Premature Ovarian Failure (Also Called Primary Ovarian Insufficiency) 342
- Late-onset Congenital Adrenal Hyperplasia 343
- Functional Hypothalamic Amenorrhea 343
- Amenorrhea in Androgen-producing Tumor 343

15. A Case of Precocious Puberty (Pediatrics and Adolescent Gynecological Problem) 345

A Case of Precocious Puberty 345
- Patient's Particulars 345
- History 345
- Detailed General Survey are Done and Noted 346
- Systemic Examination 346
- Gynecological Examination 346
- Investigations Supplied or Required 346
- Summary of the Case 346
- Provisional Diagnosis 346
- Differential Diagnosis (D/D) 346
- Evaluation of a Case of Precocious Puberty 348
- Onset of Puberty 350

Pediatric and Adolescent Gynecology (PAG) 351
- Common Gynecological Problems in Pediatric and Adolescent Group 351
- Labial Adhesion 352
- Vulvovaginitis 352
- Vaginal Bleeding in Prepubertal Girl 353
- Ovarian Neoplasms in Adolescents and Children 353
- Endometriosis in Adolescent 354
- Disorder of Sexual Differentiation (DSD) 354
- Adolescent Polycystic Ovary Syndrome 355
- Preventive Gynecology in Pediatrics and Adolescent 355

16. A Case of Endometriosis Adenomyosis 356
- Patient's Particulars 356
- History 356
- Physical Examination 357
- Gynecological Examination 357
- Investigations Supplied or Required 357
- Summary of the Case (Sample) 357

JAYPEE BROTHERS

- Provisional Diagnosis 358
- Differential Diagnosis 358
- Adenomyosis 369
- Dysmenorrhea 373
- Chronic Pelvic Pain 375
- Ovarian Remnant Syndrome and Ovarian Retention Syndrome 376

17. A Case of Vesicovaginal Fistula and Urinary Incontinence 377

- History Taking 377
- Physical Examination 378
- Gynecological Examination 378
- Summary of the Case (Sample Summary) 378
- Investigations Supplied or Required 378
- Provisional Diagnosis 378
- Differential Diagnosis 378
- Summary of Diagnosis 380
- Ureterovaginal Fistula 385
- Urinary Incontinence 389

18. A Case of Old Complete Perineal Tear 400

- Patient's Particulars 400
- History 400
- Physical Examination 401
- Gynecological Examination 401
- Summary of the Case (Sample) 401
- Complete Perineal Tear 402
- Anatomy of Anal Canal and Anal Sphincter 402
- Anal Incontinence 403
- Diagnosis of Old Complete Perineal Tear 403
- Steps of Surgery for Repair of CPT 405

Rectovaginal Fistula (RVF) 408

SECTION 3: REPRODUCTIVE PHYSIOLOGY

19. Physiology of Ovulation, Menstruation, Spermatogenesis and Implantation 413

- Physiology of Ovulation 413
- Two-Cell, Two-Gonadotropin Theory 415
- Ovulation Phase 417
- Physiology of Menstruation 418
- Normal Composition of Semen 421
- Physiology of Spermatogenesis 422
- Implantation 426
- Premenstrual Syndrome (PMS) or Premenstrual Tension (PMT) 429

20. Menopause and its Management 431

Menopause 431

- Physiology of Menopause 432
- Management of Menopause 435

21. Development of Genital Organs and Müllerian Anomaly 438

- Development of Male Genital System 438
- Development of Female Genital System 438
- Müllerian Anomaly Classification 439
- ASRM Müllerian Anomaly Classification 2021 (MAC, 2021) 441
- Unicornuate Uterus 443
- Uterine Didelphys 445
- Bicornuate Uterus 446
- Septate Uterus 448
- Arcuate Uterus 449
- Transverse Vaginal Septum 449
- Longitudinal Vaginal Septum 450
- Cervical Agenesis 451
- Vaginal Agenesis 451
- Mayer-Rokitansky-Küster-Hauser Syndrome 451
- Surgical Methods in Müllerian Anomaly 453
- Uterine Transplantation 455

SECTION 4: BIRTH CONTROL AND POPULATION DEMOGRAPHY

22. Family Planning and Contraception 459

- Common Viva Questions on Contraceptives 459
- History of Birth Control 461
- Criteria of an Ideal Contraceptive 462
- Classification of Birth Control Methods 462
- WHO Tier Method (Groups) Classification 462
- Expression of Failure Rate 463
- Classification of Steroidal Contraceptives 464
- Combined Oral Contraceptives Pills 464
- Noncontraceptive Benefits of Combined Oral Pills 467
- Noncontraceptive Uses of COCs 467
- Medical Eligibility Criteria (MEC) Wheel for Contraceptive Use 468
- Missing Pill 468
- Progesterone-only Pill 471
- Centchroman 472
- Injectable Contraceptives 472
- Subdermal Implants 474
- Combined Hormonal Transdermal Patches 476
- Transvaginal Combined Hormonal Ring 476
- Progesterone Vaginal Ring 476
- Emergency Contraceptives (Synonyms: Morning After Pill, Postcoital Contraception) 476
- Intrauterine Contraceptive Devices (IUDs or IUCDs) 478
- Contraindications of Copper-containing IUDs 481

Postpartum IUCD 488

- Long-acting Reversible Contraceptive (LARC) 490
- Barrier Methods of Contraceptive 491

JAYPEE BROTHERS

Permanent Contraception 495
- Pomeroy Technique 496
- Other Techniques of Tubal Sterilization 498
- Laparoscopic Sterilization 499
- Eligibility of Male Sterilization 506
- Other Male Contraceptives 507
- Antifertility Vaccine 508

23. Demography and Family Planning Programs in India—Present Scenario 509
- Magnitude of the Problem 509
- Fertility Indicators 509
- Current Use of Family Planning Methods (Currently Married Women Age 15–49 Years) as Per NFHS-5 (2019-21) Data 510
- Unmet Need in India 510
- Milestones of Family Planning Program in India 510
- Contraceptives Available at Present Through Government of India 511

SECTION 5: INSTRUMENTS AND OPERATION

24. Identify the Instruments—Know Your Instruments 515
- Instruments at a Glance 515
- Sponge Holding Forceps (Also Called Swab Holding or Ring Forceps) 528
- Ovum Forceps 528
- Female Metallic Catheter 528
- Foley Catheter 529
- Sims' Double-Bladed Posterior Vaginal Speculum 529
- Single-Bladed (Universal) Posterior Vaginal Speculum 530
- Cusco's Bivalve Self-retaining Speculum 530
- Auvard's Self-retaining Speculum 531
- Anterior Vaginal Wall Retractor 531
- Allis Tissue Forceps 531
- Multiple Teeth Vulsellum 531
- Single Tooth Vulsellum 532
- Uterine Sound 532
- Cervical Dilators 533
- Uterine Curette 534
- Uterine Dressing Forceps 534
- Lane's Tissue Forceps 534
- Hysterectomy Clamp (Straight/Curve) 535
- Babcock's Tissue Forceps 535
- Myoma Screw 535
- Bonney's Myomectomy Clamp 536
- Landon's Bladder Retractor 536
- Aneurysm Needle with Thread 536
- Ring Pessary 536
- Hodge–Smith Pessary 537
- Hysterosalpingography Cannula 537
- Ayre's Spatula 538
- Cytobrush 538

25. Operative Gynecology 539
- Hysterectomy 539
- Classification of Hysterectomy in Relevance to Surgery of Cancer Cervix 540
- Steps of Abdominal Approach of Total Hysterectomy 540
- Indications of Hysterectomy 544
- Justification of Salpingectomy During Hysterectomy 544
- Nondescent Vaginal Hysterectomy (NDVH) 544
- Wertheim's Operation (Abdominal Radical Hysterectomy) 545
- Dilatation and Curettage 546
- Surgery for Chronic Uterine Inversion 550
- Surgery for Making Uterus Anteversion 551
- Other Gynecological Surgeries are Described in the Respective Chapters as Below 551
- Preoperative Assessment of a Patient Undergoing Gynecological Surgery 551

26. Endoscopic Surgery: Laparoscopic/Hysteroscopic/Robotic Surgery 553
- Laparoscopic Surgery 553
- Hysteroscope 559
- Robotic Surgery 562

27. Routine Postoperative Management in a Gynecological Surgery 563
- Postoperative Round in First Postoperative Day 563
- Postoperative Round in Second Postoperative Day 564
- Complications Anticipated in Postoperative Period 564
- Alarming Signs in Postoperative Period 564
- ERAS 566

SECTION 6: SPECIMENS

28. Specimens 569
- Specimen 1: Submucous Fibroid 569
- Specimen 2: Submucous Fibroid 570
- Specimen 3: Multiple Fibroid 570
- Specimen 4: Subserous Fibroid 570
- Specimen 5: Large Cervical Fibroid 571
- Specimen 6: Large Cervical Fibroid 571
- Specimen 7: Pseudobroad Ligament Fibroid 571
- Specimen 8: Simple Serous Cyst Ovary 572
- Specimen 9: Benign Tumor 572
- Specimen 10: Ovarian Cyst 572
- Specimen 11: Dermoid Cyst of Ovary 572
- Specimen 12: Benign Ovarian Tumor (TAH with BSO) 573
- Specimen 13: Malignant Ovarian Tumor 573
- Specimen 14A and 14B: Krukenberg Tumor 574
- Specimen 15 and 15A: Cancer Cervix 574

JAYPEE BROTHERS

- Specimen 16: Cancer Cervix 575
- Specimen 17: Endometrial Cancer 575
- Specimen 18: Cancer Vulva 576

SECTION 7: IMAGING

29. Hysterosalpingography Plates, X-ray Plates with IUCD and Other Imaging 579

Hysterosalpingography Plates 579
- Normal Scan 579
- Bilateral Tubal Block 580
- Left Side Tube Block 581
- Bicornuate Uterus 581
- Septate Uterus 582
- Unicornuate Uterus 582
- Arcuate Uterus 583
- Bicornuate Uterus 583

X-ray Plates 583
- Cu-T Intrauterine Contraceptive Device 583
- Inert IUCD 584

Sonography Plates 584
- IUCD in Uterine Cavity 584
- Displaced Cu-T 584
- 3D USG 585
- Chocolate Cyst Ovary 585

MRI Plates 585
- Fibroid Uterus 585

SECTION 8: MISCELLANEOUS

30. Research Questions for Students 589
- Types of Study 592
- Clinical Trials 592
- Randomized Control Trial (RCT) 592
- CONSORT 594
- Levels of Evidence 595
- Clinical Trials Registry–India 596

31. Examination of a Rape Victim: Procedures and Protocols 597
- Rape and Function of a Doctor 597
- Purpose of Medical Examination in Female Rape Victim 597
- Prerequisites for Examination of Victim 597
- Examination and Note of Findings 598
- Acknowledgments 599

32. Swellings of Vulva: Bartholin's Cyst and Abscess 600
- Classifications of Swellings 600
- Bartholin's Cyst and Abscess 601

33. Pelvic Inflammatory Disease, Sexually Transmitted Infections and Female Genital Tuberculosis 605
- Pelvic Inflammatory Disease (PID) 605
- Criteria Developed and Recommended (2015) by CDC for Initiation of Treatment of PID 607
- Sexually Transmitted Infections (STIs) 608
- Female Genital Tuberculosis (FGT) 612

Index 617

JAYPEE BROTHERS

24 CHAPTER

Identify the Instruments—Know Your Instruments

JAYPEE BROTHERS

Chapter Outline

- **Instruments at a Glance—Identify All**
- **Questions on common instruments asked in viva:**
  Sponge Holding Forceps, Ovum Forceps, Female Metallic Catheter, Foley Catheter, Sims' Speculum, Cusco's Speculum, Anterior Vaginal Wall Retractor, Allis Tissue Forceps, Multiple Teeth and Single Tooth Vulsellum, Uterine Sound, Cervical Dilator, Uterine Curette (All Types), Uterine Dressing Forceps, Lane's Tissue Forceps, Hysterectomy Clamp, Babcock's Tissue Forceps, Myoma Screw, Bonney's Myomectomy Clamp, Landon's Bladder Retractor, Aneurism Needle, Hodge-Smith Pessary and Ring Pessary

INSTRUMENTS AT A GLANCE

All the instruments have been shown in **Figures 1 to 68**.

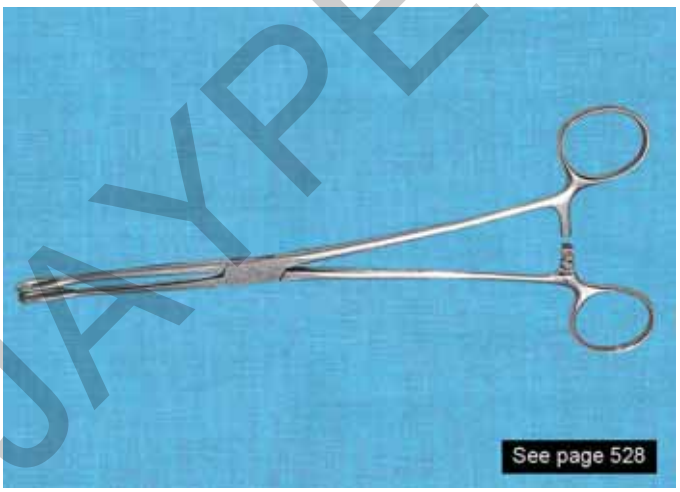
See page 528

Fig. 1: Sponge holding forceps.

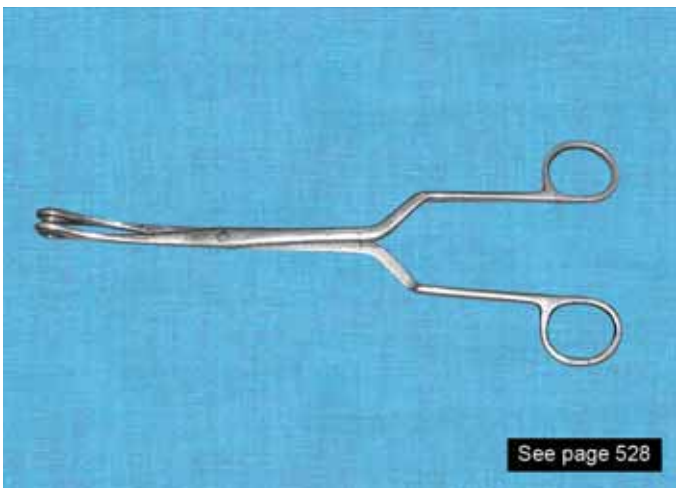
See page 528

Fig. 2: Ovum forceps.

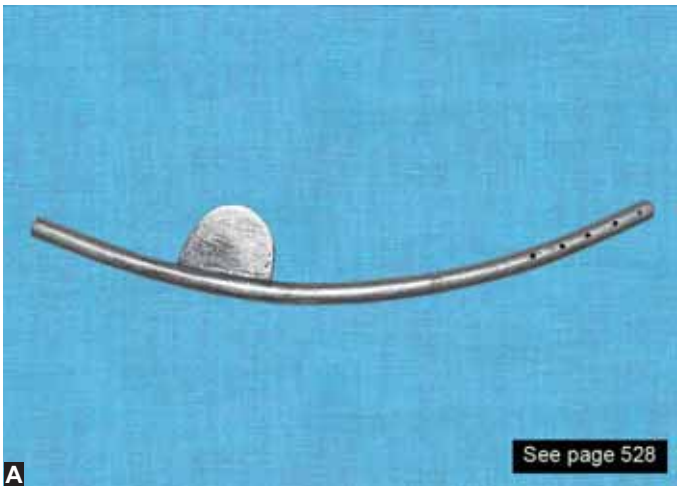



Figs 3A and B: (A) Female metallic catheter; (B) Procedure of holding metal catheter during evacuation.



Fig. 4: Simple rubber catheter.



Fig. 6: Sims' posterior vaginal speculum (double-bladed).



Fig. 5: Foley catheter.

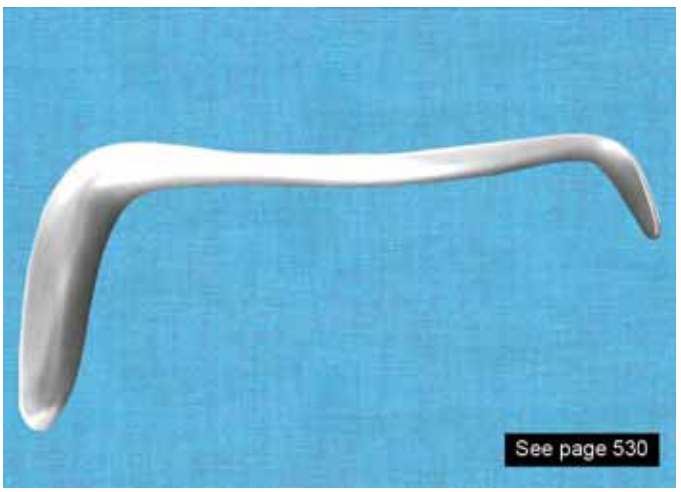

Fig. 7: Single-bladed posterior vaginal speculum.

JAYPEE BROTHERS

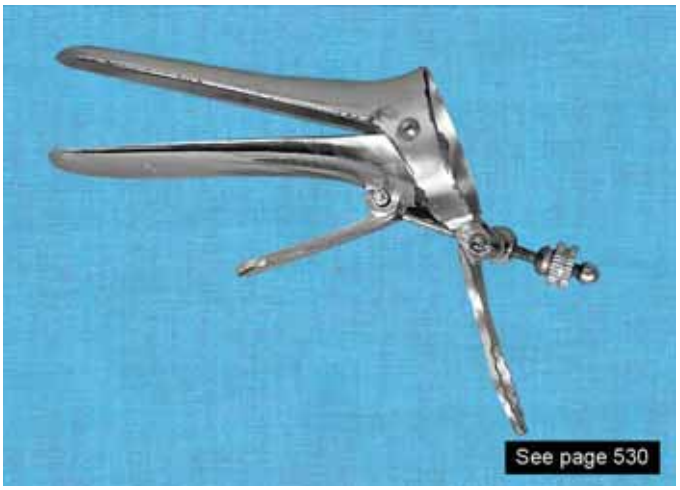

Fig. 8: Cusco's speculum.



Fig. 11: Allis tissue forceps.

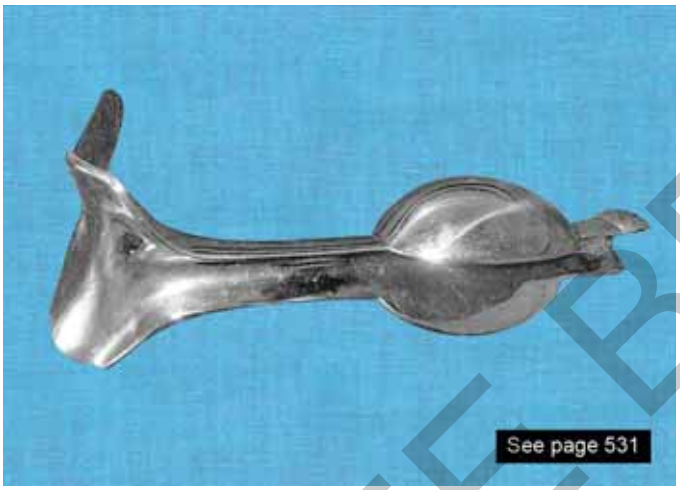

Fig. 9: Auvard's self-retaining speculum.

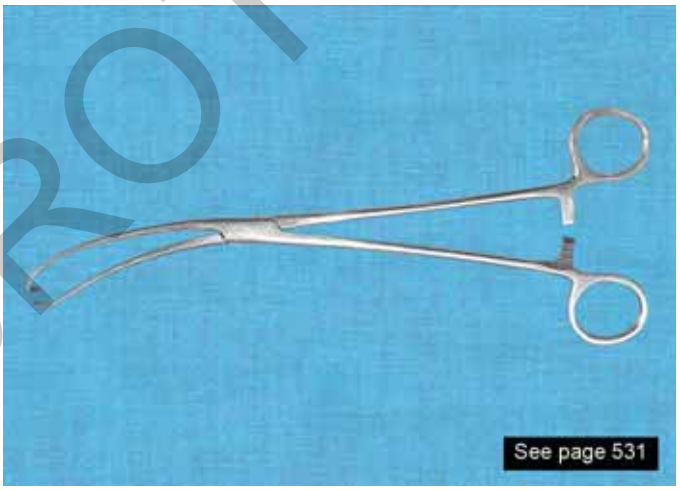

Fig. 12: Multiple teeth vulsellum.

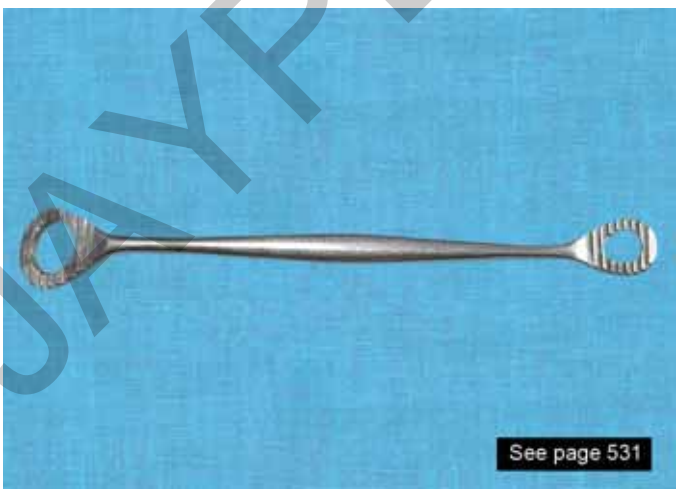

Fig. 10: Anterior vaginal wall retractor.

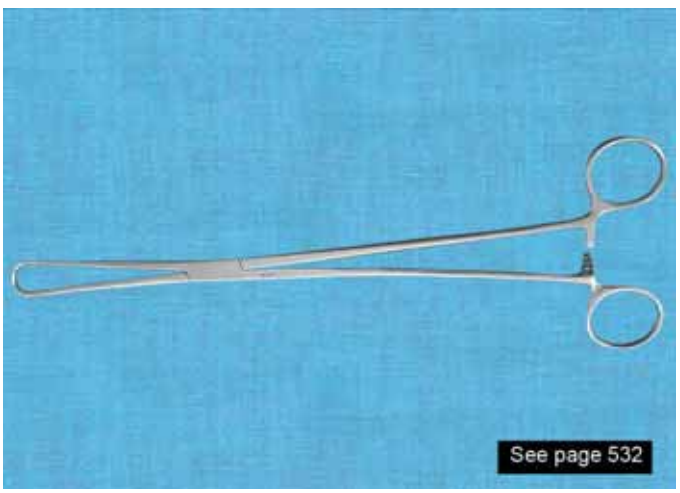

Fig. 13: Single tooth vulsellum.

JAYPEE BROTHERS



Fig. 36: Deaver's retractor.



Fig. 39: Aneurysm needle.



Fig. 37: Balfour abdominal self-retaining retractor.



Fig. 39A: Right angled forceps (Meigs-Navratil forceps) for ligation of internal iliac artery or deep vessel.



Fig. 38: Uterus holding forceps—uterus held in tubal surgery.



Fig. 40: Needle holder.

JAYPEE BROTHERS

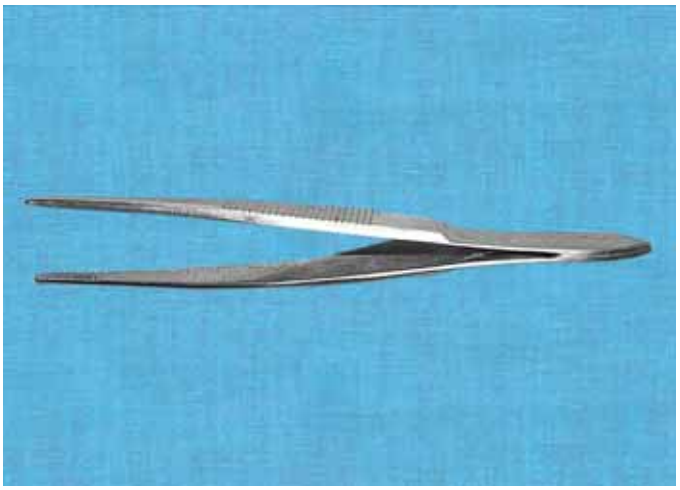

Fig. 41: Dissecting forceps—nontoothed.

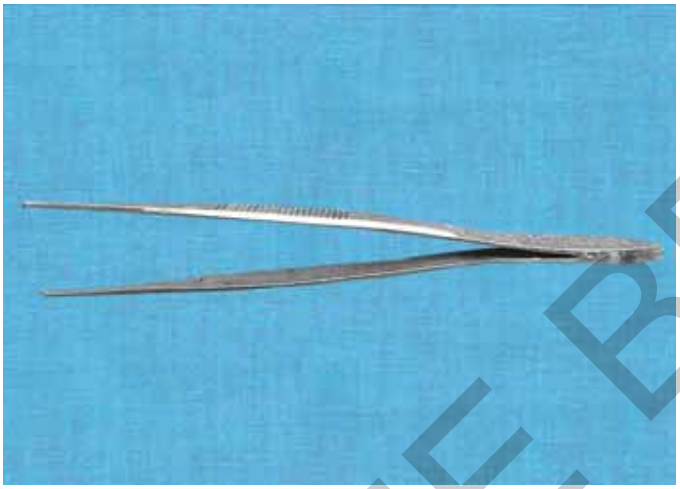

Fig. 42: Dissecting forceps—toothed.



Fig. 43: Curved round body needle atraumatic with vicryl.



Fig. 44: Pack of catgut.



Fig. 45: Pack of vicryl delayed absorbable suture.

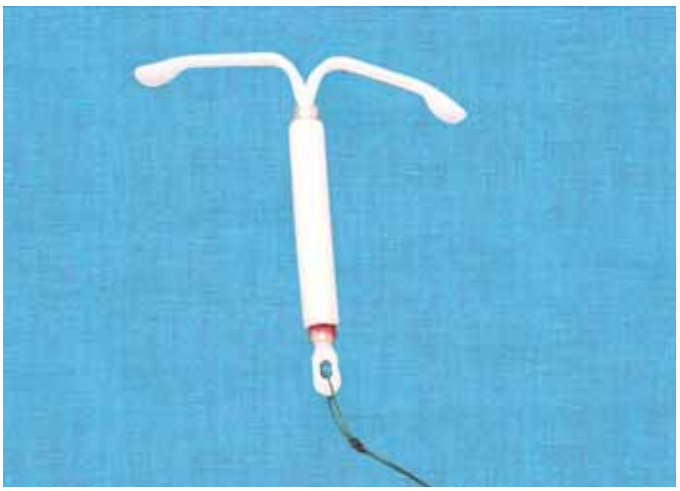

Fig. 46: LNG-IUS Mirena used for contraceptive, AUB, endometriosis, fibroid (*see* Chapter 22).

JAYPEE BROTHERS

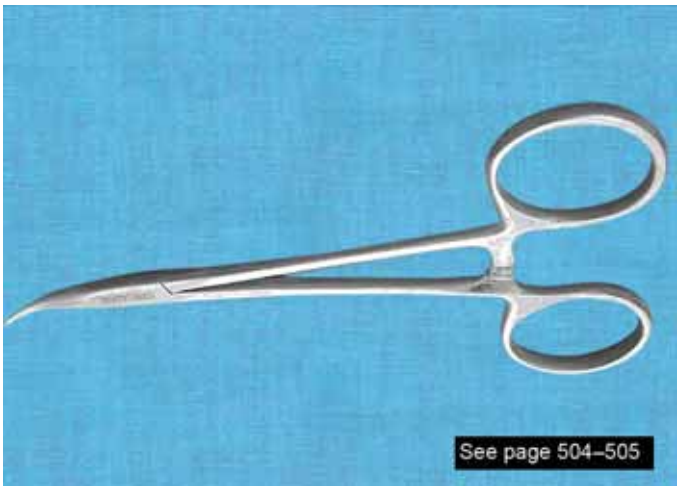

Fig. 59: Dissecting forceps for nonscalpel vasectomy (NSV).



Fig. 62: Telescope of laparoscope.

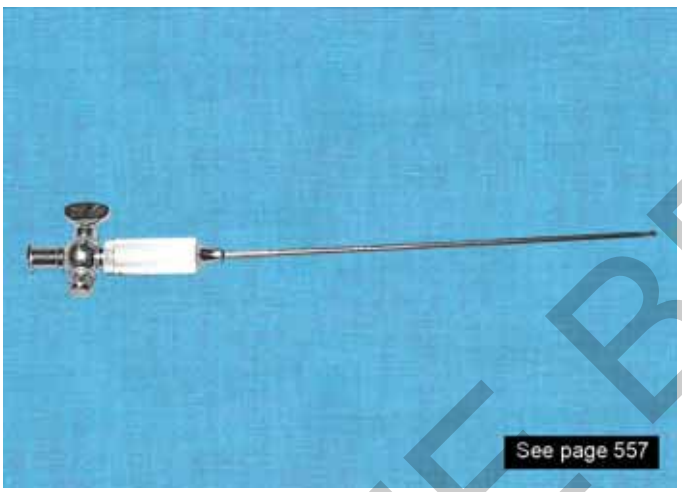

Fig. 60: Veress needle—used for pneumoperitoneum in laparoscopy.



Fig. 63: Laparoscopic ligation set: (1) Tong, (2) loader, (3) pusher and (4) Falope ring.



Fig. 61: Trocar and cannula for laparoscope.



Fig. 64: Hysteroscopic telescope.

JAYPEE BROTHERS

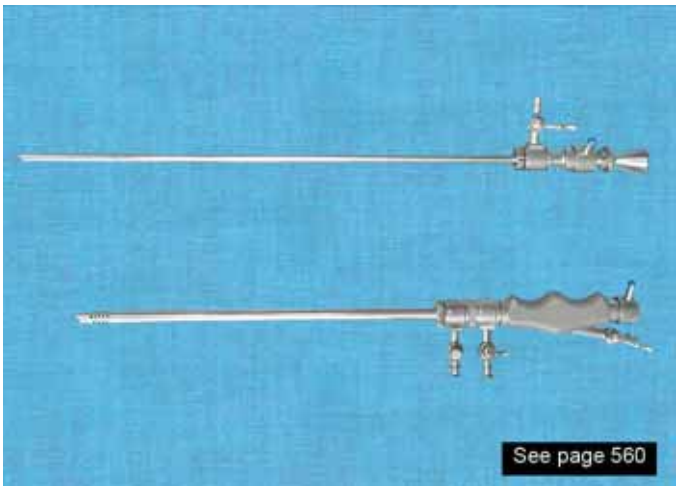

Fig. 65: Operative hysteroscope.



Fig. 66: Tension-free vaginal tape (TVT) needle.



Fig. 67: Transobturator tape (TOT) needle and tape (outside in).

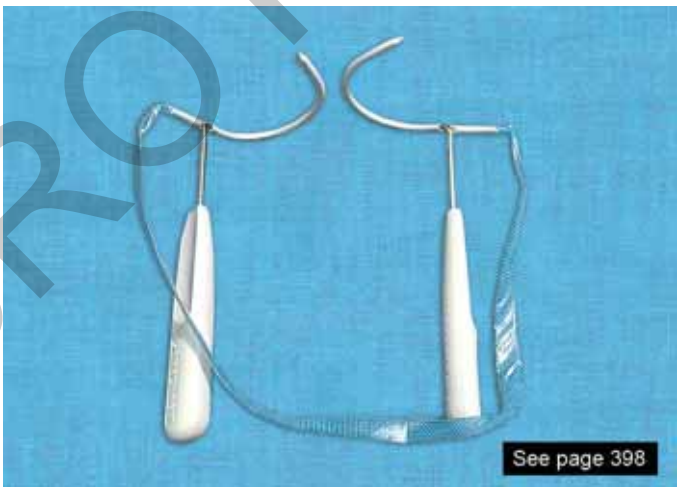

Fig. 68: Composite set of obturator device, helical passars and atraumatic-winged guide for TOT (for inside out).



Fig. 69: Cryoprobe with cryogun for cyocautery of cervix.

JAYPEE BROTHERS

SPONGE HOLDING FORCEPS (ALSO CALLED SWAB HOLDING OR RING FORCEPS) (FIG. 1)

It is a long forceps with rings at the anterior end and with a catch near handle which differentiates it from ovum forceps which has no catch.

Uses of Sponge Holding Forceps in Gynecology

- Antiseptic dressing in abdominal and vaginal operations
- Polypectomy
- Packing of roller gauze in secondary hemorrhage following vaginal or abdominal hysterectomy
- To hold the lip of cervix in pregnant uterus, e.g., cerclage operation
- Can be used instead of ovum forceps
- Can be used to anterior vaginal wall retractor
- To occlude the ovarian vessels during myomectomy.

Sterilization

Autoclaving or boiling.

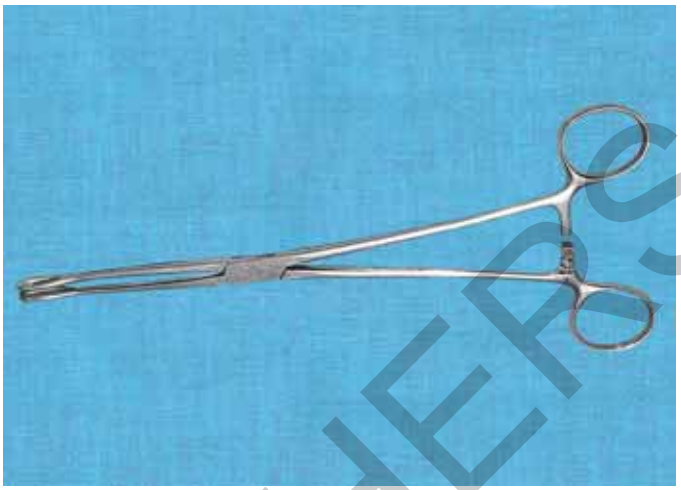

Fig. 1: Sponge holding forceps.

OVUM FORCEPS (FIG. 2)

Uses

- To remove the product of conception in dilatation and evacuation (D and E) operation
- To remove the retained bits of placenta and membranes.

Q. How to differentiate from sponge holding forceps?

- In sponge holding there is catch, in ovum forceps there is no catch.
- In ovum holding forceps the tip is spoon-shaped, in sponge holding forceps the tip is ring-shaped with grooves.

Sterilization

Autoclaving or boiling.

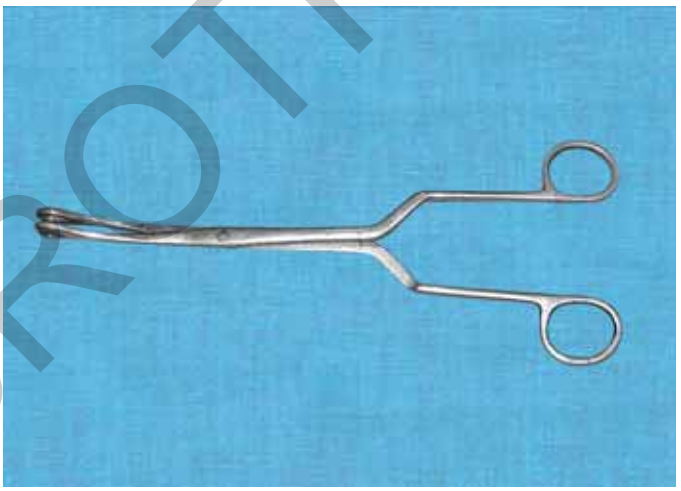

Fig. 2: Ovum forceps.

FEMALE METALLIC CATHETER (FIGS. 3A AND B)

Uses

- Evacuation of bladder routinely before vaginal operation
- Retention of urine
- To diagnose vesicovaginal fistula (VVF)
- To differentiate VVF and ureterovaginal fistula (UVF)
- To note the limit of bladder in anterior colporrhaphy operation.

Q. What are the causes of retention of urine in gynecology?

- Cervical fibroid
- Cryptomenorrhea
- Retroverted gravid uterus
- Ovarian tumor impacted in pouch of Douglas (POD)
- Pelvic hematocele due to chronic ectopic
- Postoperative retention following any vaginal surgery
- Pelvic organ prolapse (POP)
- Urethra stricture
- Urethral caruncle.

Q. How to hold the female catheter during evacuation (Fig. 3B)?

- Patient in dorsal position with thigh abducted or lithotomy position.
- With glove hands—left thumb and index finger—labia are retracted. Swabing of external urethral meatus is by using cotton soaked in antiseptic solution from anterior to posterior. For collection of urine for culture and sensitivity purpose, normal saline or distilled water is used instead of antiseptic solution.
- Urethral meatus is a longitudinal slit situated 2.5 cm below and behind the clitoris and identified by pink mucosa.
- Catheter is held on no touch technique holding the flat disk with thumb and index finger keeping convexity upwards.

JAYPEE BROTHERS

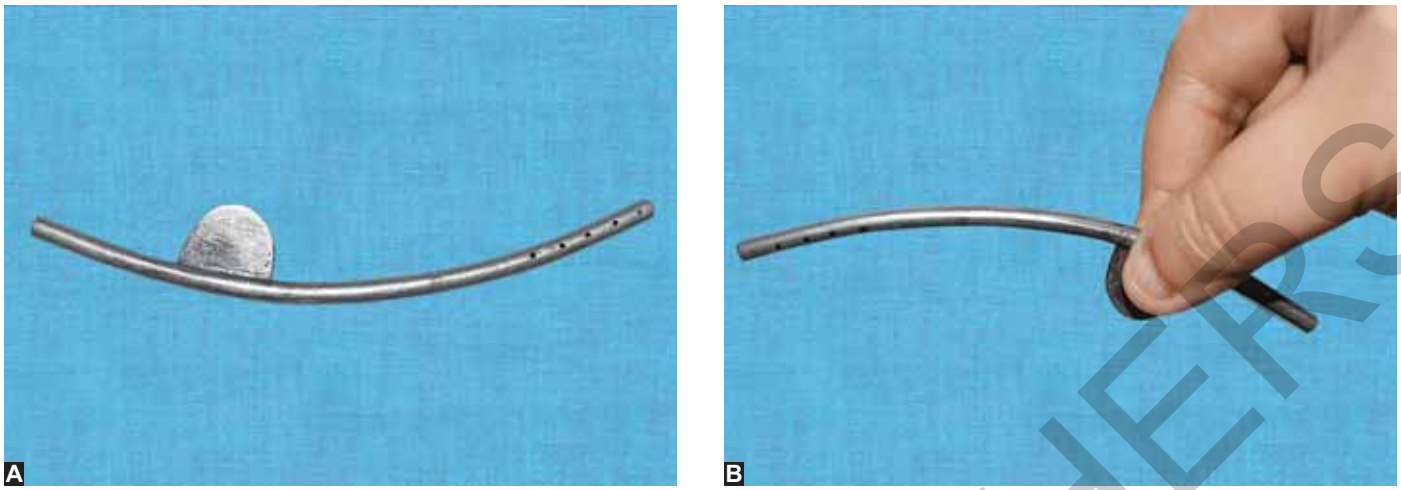

Figs. 3A and B: (A) Female metallic catheter; (B) Procedure of holding metal catheter during evacuation.

Q. How the metal catheter is sterilized?

By autoclave or by boiling for half an hour.

Q. Why does retention of urine occur in retroverted gravid uterus? When does it occur?

In retroverted gravid uterus, uterus is impacted in POD, hence the anterior vaginal wall becomes stretched causing stretching of urethra and the lumen of the urethra becomes narrowed.

Commonly occurs at 12th week of gestation.

Q. How will you manage urinary retention in retroverted gravid uterus?

Patient is admitted and continuous catheterization done with Foley catheter. Patient is asked to lie in prawn position or exaggerated left lateral position. After 14 weeks when the uterus becomes abdominally palpable, spontaneous correction occurs and patient can pass urine herself.

Complications of Catheterization

- Urinary tract infection
- Trauma by metal catheter.

FOLEY CATHETER (FIG. 5)

It is used for continuous drainage of urine available of different sizes made of rubber silicone. Commonly 14, 16 and 18 sizes are used. 8 size is used for sonohysterosalpingography. It is a two-channel tube, one for drainage of urine and other for inflation of bulb with distilled water, 5–10 mL water is given. The size of catheter and capacity of bulb are written on pack.

Uses

- For evacuation of bladder in retention of urine.
- For continuous drainage of urine following gynecological surgery like pelvic floor repair, vaginal hysterectomy, Wertheim's operation, repair of VVF and vaginoplasty.
- To monitor output in ill patients where it is required.



Fig. 5: Foley catheter.

- Sonosalpingohysterography (with 8-0 size)
- As tamponade—in abnormal uterine bleeding
- In obstetrics—to control postpartum hemorrhage (PPH) with multiple Foley, induction of labor, in obstructed labor, amnioinfusion.

Sterilization

It is available in sterilized pack—gamma-sterilized or by ethylene tetraoxide.

SIMS' DOUBLE-BLADED POSTERIOR VAGINAL SPECULUM (FIG. 6)

Uses

Diagnostic and therapeutic.

Diagnostic

- To visualize any lesion over cervix and anterior vaginal wall.
- Investigation—cervical biopsy and PAP smear.

JAYPEE BROTHERS

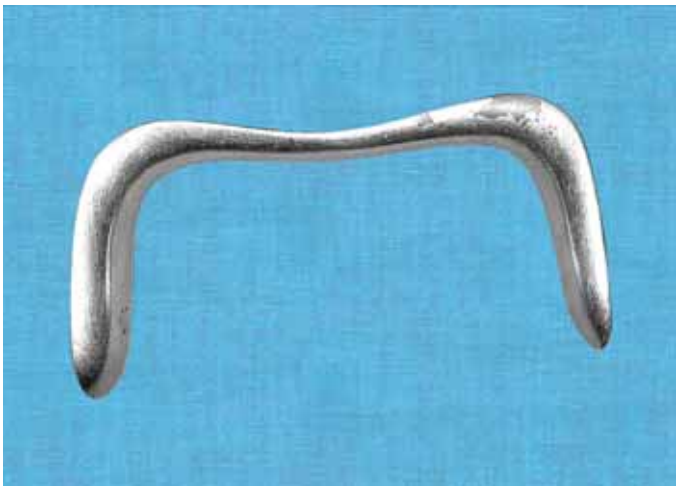

Fig. 6: Sims' posterior vaginal speculum (double-bladed).



Fig. 7: Single-bladed posterior vaginal speculum.

Q. Tell some lesions on anterior vaginal wall.

Vesicovaginal fistula, cystocele, Gardner duct cyst.

Q. Tell some lesions of cervix.

Cervical erosion, chronic cervicitis, cervical polyp, cervical intraepithelial neoplasia (CIN), cancer cervix, cervical tear, bacterial and fungal cervicitis.

To *see* the cervix anterior vaginal wall may be needed to retract especially in presence of cystocele.

Therapeutic

Any vaginal operation/procedure other than operation on perineum, e.g., D and C, diathermy, cryocautery, intrauterine contraceptive device (IUCD) insertion, anterior colporrhaphy, vaginal hysterectomy, Fothergill's operation, hysteroscopy (diagnostic and operative both).

Q. Why called Sims?

It was after the name of Marion Sims who was the pioneer of VVF repair and used this instrument for VVF repair.

Q. What is Sims' triad?

See details in Chapter 17

Sims' position, Sims' speculum and Sims' silver wire used for VVF repair.

Q. How to introduce Sims' speculum?

Sims' speculum is inserted laterally first and then to be rotated 90° posteriorly to retract the posterior vaginal wall with the blade.

For details of introduction, *see* Chapter 1 (**Figs. 63A and B and 65** of Chapter 1).

Disadvantages of Sims' speculum over Cusco:

- It is not self-retaining, so assistant is needed to retract it in operative procedure.
- In presence of cystocele, an anterior vaginal wall retractor is needed to retract anterior vaginal wall.

Advantage of Sims' speculum over Cusco:

Lesions on anterior vaginal wall (VVF) can be seen whereas by Cusco anterior vaginal wall is not visible.

SINGLE-BLADED (UNIVERSAL) POSTERIOR VAGINAL SPECULUM (FIG. 7)

Same as above, it is single-bladed, universal and in double-bladed two blades are of different sizes. The advantage is that patient may not be needed to come to the edge of the table which is needed in double-bladed.

CUSCO'S BIVALVE SELF-RETAINING SPECULUM (FIG. 8)

Uses

In outpatient department (OPD), the speculum which is mostly used is Cusco's speculum.

Diagnostic

- Mostly diagnostic.
- To see the lesions over cervix as described in Sims' speculum—cervical erosion, chronic cervicitis, cervical polyp, CIN, cancer cervix, cervical tear, bacterial and fungal cervicitis.
- Lesions over lateral vaginal walls.

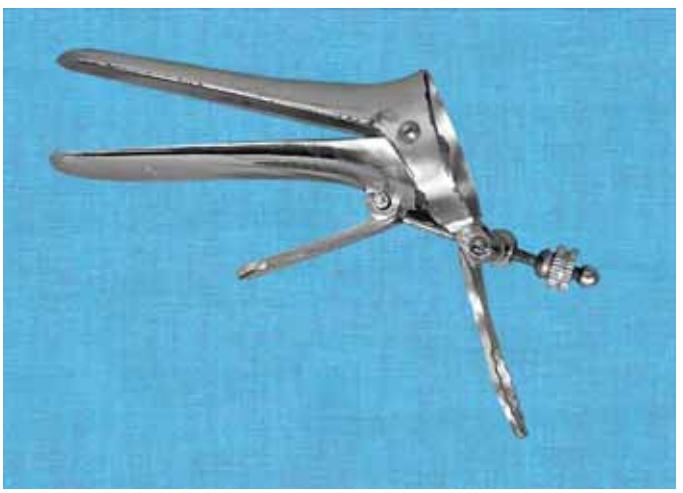

Fig. 8: Cusco's speculum.

JAYPEE BROTHERS

Diagnostic: Collection of PAP smear, swab, punch biopsy, colposcopy.

Therapeutic: Diathermy cautery.

Advantages: Self-retaining. Less discomfort to the patent.

Disadvantages: Anterior wall of vagina is not visible.

Q. How to introduce?

After separating the labia with left thumb and index finger, transverse blades of Cusco's speculum (lubricated by jelly) is introduced in anteroposterior direction (as vaginal introitus is anteroposterior slit and depressed from side to side) and is rotated 90° to bring the transverse blades transversely (upper part of vagina transversely enlarged). Details in Chapter 1 (**Figs. 57 to 61** of Chapter 1).

AUVARD'S SELF-RETAINING SPECULUM (FIG. 9)

It is like single-bladed posterior vaginal speculum but wide and heavy.

Due to its heaviness and postoperative pain, it is rarely used.

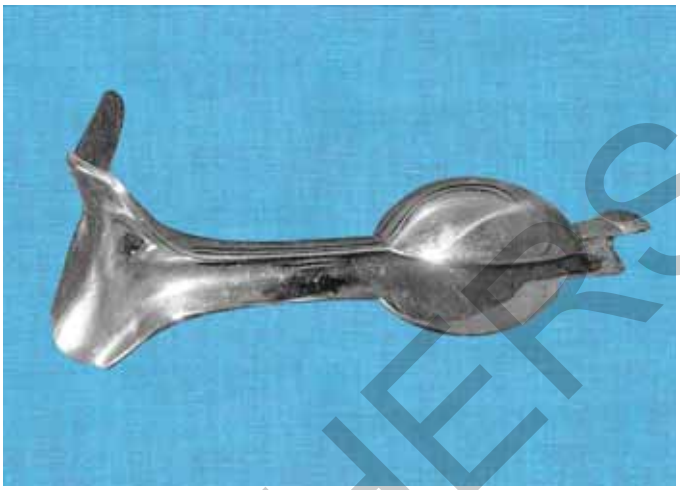

Fig. 9: Auvard's self-retaining speculum.

ANTERIOR VAGINAL WALL RETRACTOR (FIG. 10)

In both sides, ring is present and serrated. Shape is like double-ended uterine curette but much larger and heavier.

Use

To retract the anterior vaginal wall along with Sims' speculum used posteriorly to visualize the cervix well.

Sterilization

Boiling or autoclave.

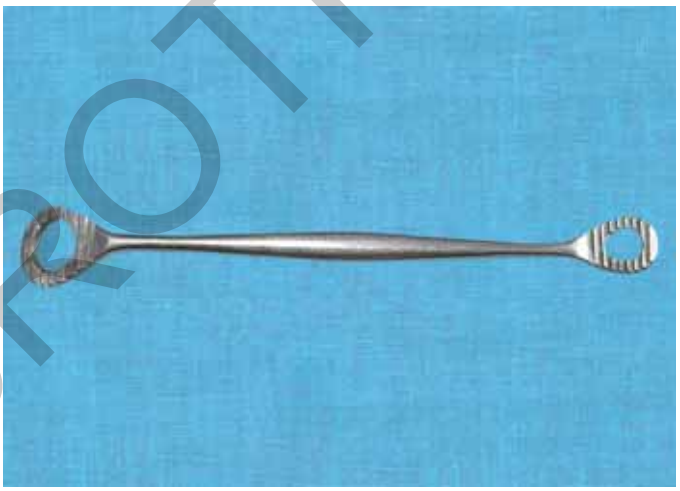

Fig. 10: Anterior vaginal wall retractor.

ALLIS TISSUE FORCEPS (FIG. 11)

It has 5–6 teeth with a catch near handle. It has two sizes: (i) smaller and (ii) larger.

Uses

- To hold the lip of cervix in vaginal surgery instead of vulsellum, e.g., D and C, IUCD insertion, vaginal hysterectomy, Fothergill's operation.
- To hold the tough structures like rectus sheath, peritoneum.
- To hold the vaginal cuff during vault transaction and during repair of vaginal cuff.
- To hold the vagina in vaginal incision and to hold the cut margins of vagina in vaginal operation, e.g., Ward-Mayo's, Fothergill and repair of CPT, etc.

Sterilization

Boiling or by autoclave.

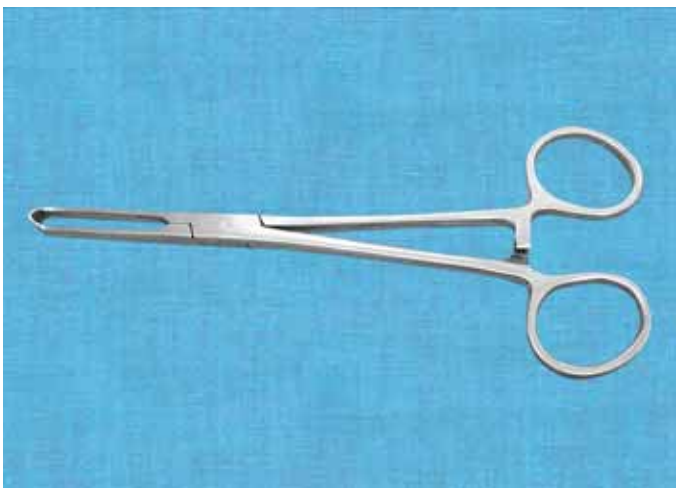

Fig. 11: Allis tissue forceps.

MULTIPLE TEETH VULSELLUM (FIG. 12)

It is tough instrument with 3–4 teeth to grasp any structure and it is provided with catch, much heavier than Allis tissue forceps.

JAYPEE BROTHERS

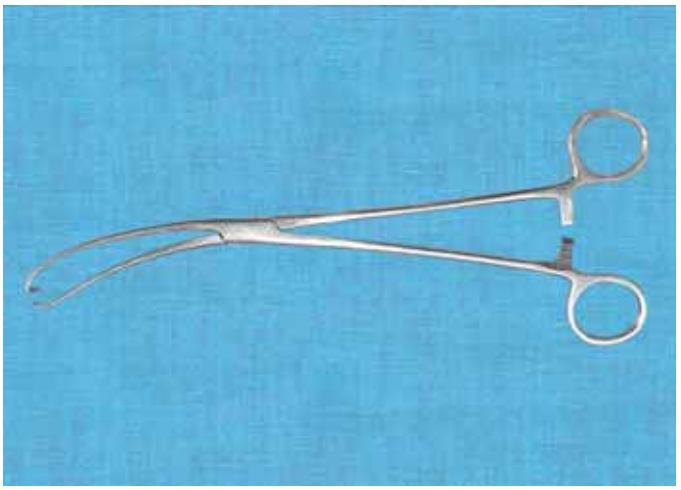

Fig. 12: Multiple teeth vulsellum.

Uses

- To hold the anterior lip of cervix in D and C, vaginal hysterectomy, amputation of cervix and Fothergill's operation.
- To hold the uterus at fundus during abdominal hysterectomy to fix the uterus.
- To hold the myoma during myomectomy.
- To remove large fibroid polyp vaginally.

Q. When you need to hold the posterior lip of cervix?

- Vaginal hysterectomy, Fothergill's operation before incision over posterior fornix
- Posterior colpotomy
- To take biopsy from anterior lip of cervix and anterior lip friable
- Vaginal ligation.

SINGLE TOOTH VULSELLUM (FIG. 13)

It has single tooth and penetrates in tissue much deeper and size is like multiple teeth vulsellum.

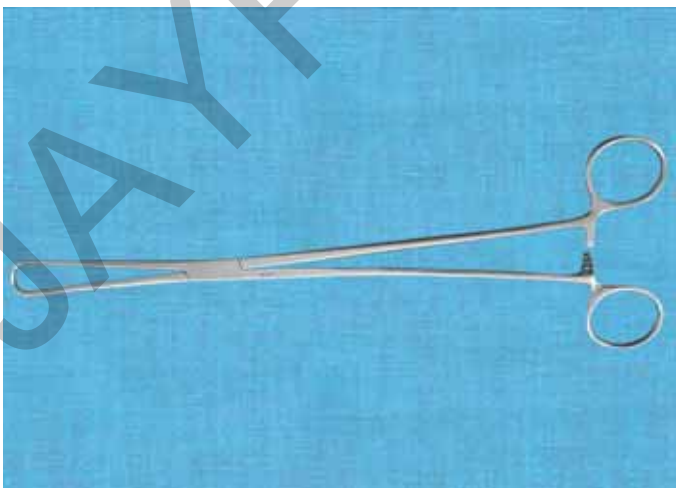

Fig. 13: Single tooth vulsellum.

Uses

- To catch nulliparous cervix
- To hold cervical stump after amputation of cervix
- To hold the myoma during myomectomy
- During abdominal hysterectomy, after opening the vault of vagina, cervical lip is held to cut the rest of the vault.

UTERINE SOUND (FIG. 14)

It is olive pointed, metallic, graduated, malleable uterine sound.

Q. Why graduated?

To measure the length of the uterus.

Q. Why malleable?

To adjust the position of uterus.

Q. Why olive pointed?

To prevent the perforation of uterus.

Q. Why called sound?

Originally used for sounding of bladder stone.

Uses

- In D and C operation
- Acts as a first dilator
- To detect the position of uterus—anteverted, retroverted or midposition
- To measure the length of uterus.

Q. What is the normal length of uterocervical canal?

- Uterocervical canal is 6.5 cm, cervix—2.5 cm and cavity of uterus—4 cm and fundus—1 cm.
- Total length of uterus including fundus—7 cm, breadth—5 cm and anteroposterior—2.5 cm.
- At childhood cervix:corpus ratio is 2:1 and at puberty and thereafter ratio of cervix: corpus is 1:2.

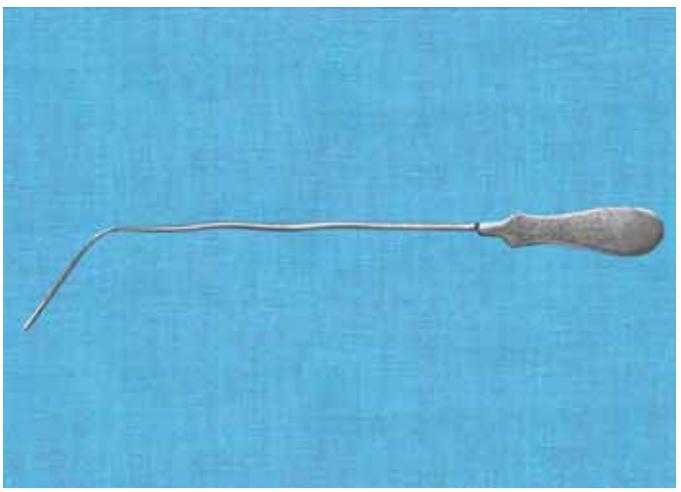

Fig. 14: Olive pointed graduated metallic malleable uterine sound.

JAYPEE BROTHERS

Q. Tell the conditions where length of uterus is increased?

- Pregnancy
- Hematometra, pyometra
- Fibroid uterus
- Adenomyosis
- Endometrial cancer
- Uterine prolapse (acquired elongation of cervix)
- Congenital elongation of cervix.

Q. In which conditions the length of uterus is decreased?

- Hypoplastic uterus—Turner syndrome is a condition
- After menopause
- Submucosal polyp
- Uterine inversion.

Q. What is the normal position of uterus?

- It is anteverted and anteflexed.
- Anteversion (V for vagina)—angle between axis of body of uterus and axis of vagina—normal angle is 90°.
- Anteflexion means angle between the axis of body of uterus and cervix—normal angle is 140°.

Sterilization of Uterine Sound

Autoclaving or boiling.

CERVICAL DILATORS (FIGS. 15 AND 16)

Q. What is the use of cervical dilators?

To dilate the cervical canal, external os and internal os gradually.

Q. What are the different types of cervical dilators?

- Das's dilator
- Hegar's dilator **(Fig. 15)**
- Hawkin–Ambler's dilators **(Fig. 16)**

Dilator may be single-ended or double-ended.

Q. What are the measurements of different dilators and what is the total number of dilators in one set?

Das's Dilator or Hegar's Dilator (Fig. 15)

In double-ended dilators the lowest size is 1/2 mm and the largest size is 23/24 mm. So, one set consists of twelve dilators. However, as the larger dilators are not used nowadays, the dilators from 1/2 mm to 15/16 mm sizes (a set of 8 dilators) are sufficient. Single-ended dilators are also available. Das's dilator and Hegar's dilator are similar types. Das's dilator is more gradual (longer) than Hegar's dilator.

The name of Das's dilator is after the name of its inventor, Sir Kedar Nath Das, a famous obstetrician. The length of the uterus is measured by introducing uterine sound before introduction of dilators, otherwise there is a chance of perforation. The purpose of use of dilator is fulfilled when its maximum diameter crosses the internal os.



Fig. 15: Hegar's cervical dilator.



Fig. 16: Hawkin–Ambler's cervical dilator.

Q. How will you understand that maximum diameter has passed through the internal os?

Following resistance at a point, there will be loss of resistance during introduction. There will be gripping of dilator by internal os and it will not fall down if left without any support.

Q. In case of difficult dilatation what will you do?

To start with very small dilator starting with uterine sound and good anesthesia. Once there is false passage there may be a problem. Preoperative administration of misoprostol 200 mg orally or vaginally before 4 hours makes the cervix soft and makes the procedure easy.

Sterilization

Autoclaving or boiling.

Hawkin–Ambler's (H–A) Dilators (Fig. 16)

The lowest size is 3/6 mm and maximum size is 18/21 mm. One set consists of 16 dilators. In 3/6, 3 and 6 denote diameters at the tip and at the widest part behind the tip respectively. H–A dilators are only single-ended.

JAYPEE BROTHERS

UTERINE CURETTE (FIGS. 17 TO 19)

Q. What are the different types of curette?

It may be blunt curette or sharp curette. The curette may be single-ended or double-ended. One curette may be both blunt and sharp types **(Fig. 17)**. Each type in two different ends.

Flushing curette (Fig. 18): It is a special type of blunt curette where there is facility of flushing of uterine cavity with antiseptic solutions.

Sharman's curette (Fig. 19): It is used for taking biopsy from uterine cavity. It is used only for gynecological purpose and can be done as office procedure.

Q. What is the use of sharp curette and blunt curette?

- Sharp curette is commonly used in gynecology for curetting endometrial cavity.
- Blunt curette for D and E.

Q. What is the use of flushing curette?

It is a blunt curette used in dilatation evacuation and especially in old incomplete abortion. Placental polyp can be curetted with the help of it. Previously, antiseptic solution was used to pass through the channel.

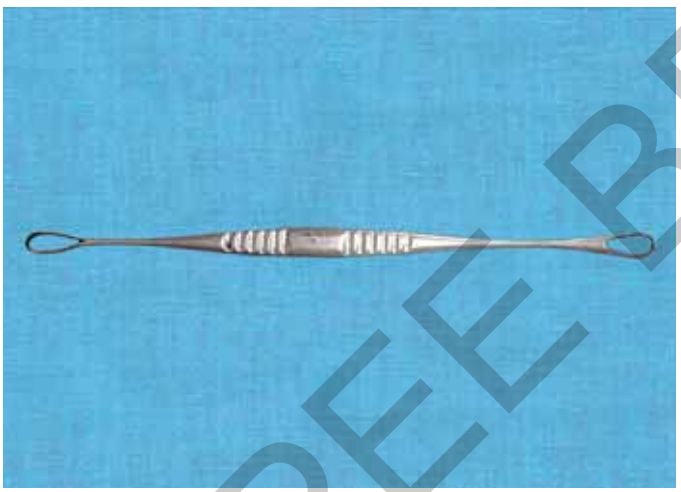

Fig. 17: Uterine curette (blunt and sharp).

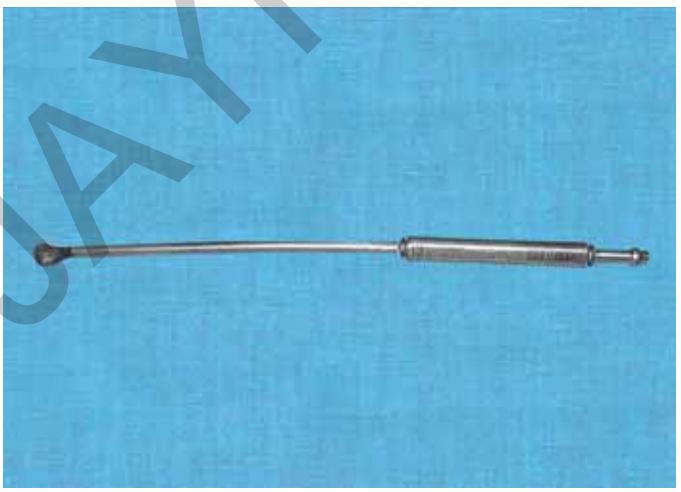

Fig. 18: Flushing curette.

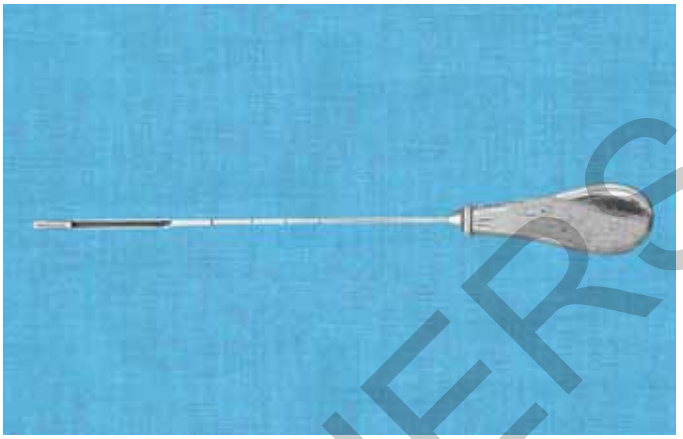

Fig. 19: Sharman's curette.



Fig. 20: Uterine dressing forceps.

Sterilization

Autoclave or boiling.

UTERINE DRESSING FORCEPS (FIG. 20)

- Its use is less in pure gynecological, mostly in pregnancy-related condition.
- It is used to dress the endometrial cavity following surgical evacuation.
- To dilate the cervix, to drain pyometra or lochiometra in puerperium.
- Pelvic abscess can be drained through posterior colpotomy approach.

LANE'S TISSUE FORCEPS (FIG. 23)

- To retract the upper cut margin of parietal wall during abdominal operation.
- Polypectomy of large cervical fibroid polyp.
- It can also be used in myomectomy to hold the myoma tissue.

JAYPEE BROTHERS

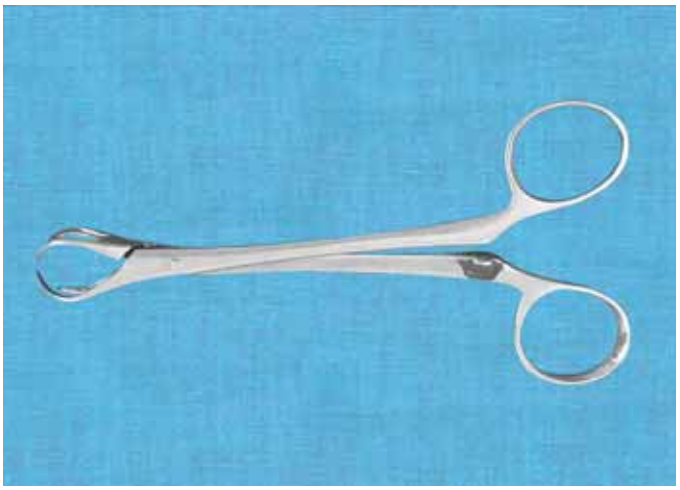

Fig. 23: Lane's tissue forceps.

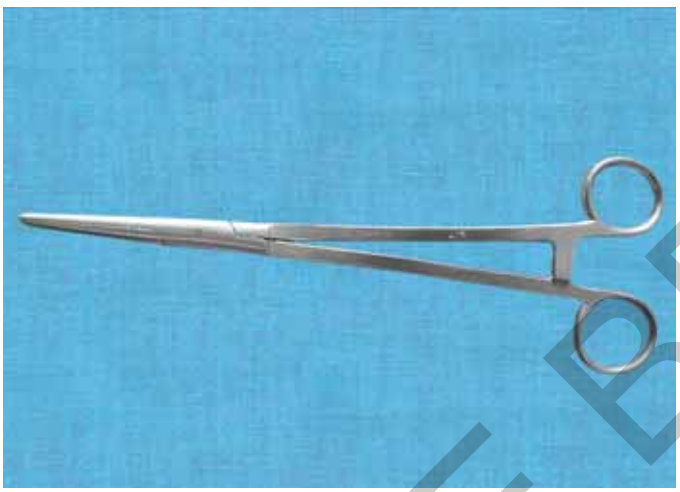

Fig. 26: Hysterectomy clamp (straight).

HYSTERECTOMY CLAMP (STRAIGHT/ CURVE) (FIG. 26)

Uses

- Hysterectomy
- Salpingo-oophorectomy
- Tubal ectopic
- To fix the uterus by holding on two cornua during hysterectomy.
- May be used as hemostatic clamp.

Sterilization

Autoclave or boiling.

BABCOCK'S TISSUE FORCEPS (FIG. 27)

It is used to grasp the structures where gentleness is needed in comparison to Allis tissue forceps as it has no tooth.

Uses

- In surgery of fallopian tube—in tubal ligation and tuboplasty



Fig. 27: Babcock's tissue forceps.

- To hold the ureter in radical hysterectomy and repair of ureteric injury.
- To hold the bladder margin to repair the VVF.
- To hold lymph nodes in lymphadenectomy.
- To hold the appendix during appendicectomy.
- During internal iliac artery ligation.

Sterilization

Autoclave or boiling.

MYOMA SCREW (FIG. 32)

Uses

- In myomectomy to hold the myoma during enucleation (*see* detail in Chapter 4 Myomectomy) (*see* **Figs. 38 and 39** of Chapter 4).
- In hysterectomy in fibroid uterus to hold and fix the uterus.

Sterilization

Autoclave or boiling.

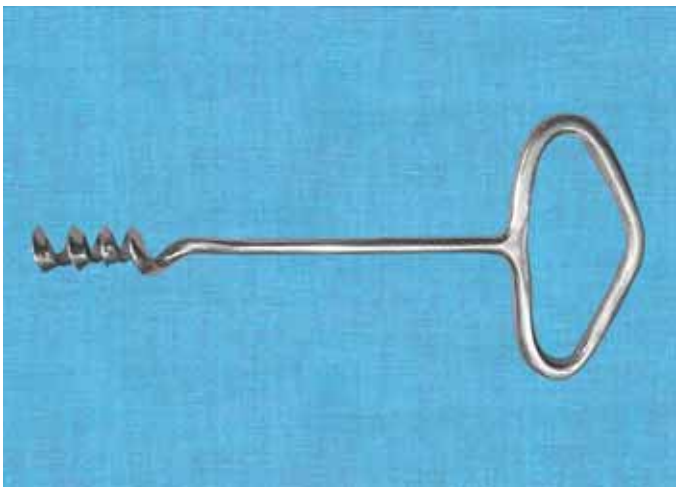

Fig. 32: Myoma screw.

JAYPEE BROTHERS

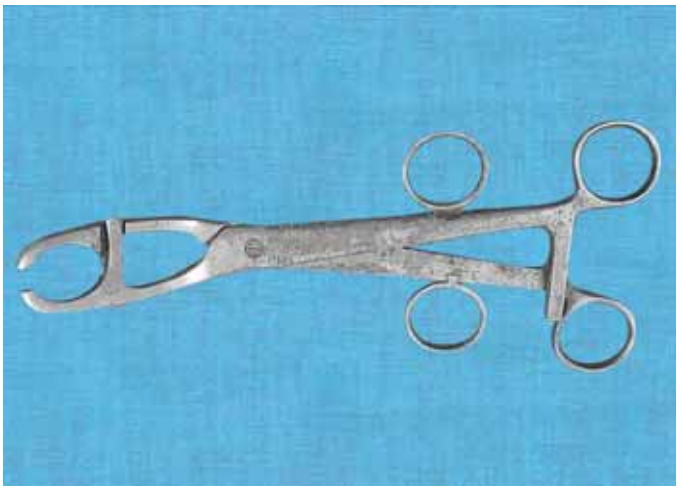

Fig. 33: Bonney's myomectomy clamp.



Fig. 34: Landon's bladder retractor.

BONNEY'S MYOMECTOMY CLAMP (FIG. 33)

Uses

- For reduction of blood loss in myomectomy by compressing the uterine arteries temporarily.
- It is applied from the leg ends of the patient keeping the handle in between thighs, the concavity of the instrument fits with the convexity of symphysis pubis. The blades grasp both the round ligaments in the region of isthmus and compress uterine arteries. Inclusion of round ligament prevents slipping. After repair of myoma, blade clamps are released.
- Use of rubber tourniquets (rubber catheter) or local injection of vasopressin almost replaced its use. Before infiltration of vasopressin anesthetist must be informed.

Sterilization

Autoclaving or boiling.

LANDON'S BLADDER RETRACTOR (FIG. 34)

Uses

- To retract the bladder during vaginal hysterectomy after opening of uterovesical fold of peritoneum (*see* Vaginal Hysterectomy in Chapter 10)
- It can also be used to retract lateral vaginal wall in repair of VVF
- Can be used as posterior vaginal wall in narrow vagina.

Sterilization

Boiling or autoclave.

ANEURYSM NEEDLE WITH THREAD (FIG. 39)

Uses

- For internal iliac artery, ligation mostly for obstetric reasons. Sometimes done in radical hysterectomy.
- Venesection.

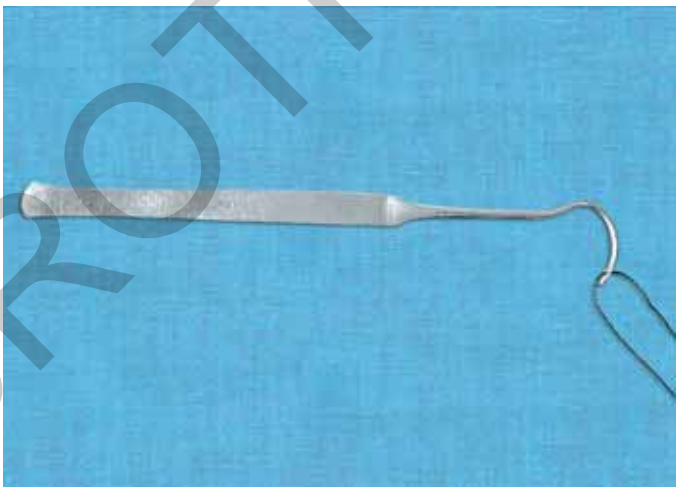

Fig. 39: Aneurysm needle.

Sterilization

Autoclave or boiling.

RING PESSARY (FIGS. 47A AND B)

It is made up of rubber or polyethylene.

Use

In pelvic organ prolapse (POP).

Q. What are the indications of vaginal pessary in POP?

For palliative treatment in POP, it acts by stretching the vaginal wall and elevating the vagina.

The indications are:

- Women who decline surgery
- Medically unfit for surgery
- During pregnancy
- Desires childbearing
- Pending for surgery.

And for pessary test before surgery whether woman will be relieved of symptoms by surgery.

JAYPEE BROTHERS



Fig. 48: Hodge–Smith pessary for correction of mobile retroversion.



Fig. 47A: Ring pessary used for pelvic organ prolapse (rubber).

Vaginal pessary—types, introduction, follow-up and complications—details are written in Chapter 10, Pelvic Organ Prolapse, Page 223.

Sterilization

By Savlon solution for 12 hours.

HODGE–SMITH PESSARY (FIG. 48)

Uses

- In retroversion (mobile) of uterus
- In retroverted puerperal uterus.

Procedure of Introduction

Measurement: It will be 1.25 cm less between the stretched posterior fornix and symphysis pubis.

Correction of retroversion: Patient is asked to pass urine. Position is lithotomy. By introducing right index and middle finger up to posterior fornix fundus of retroverted uterus is pushed anteriorly and left hand is kept behind the uterus per abdominally to keep it anteverted.

Placing of pessary: Broader end of pessary keeping anteriorly pessary is introduced laterally while the concavity lies medially. Now the pessary is rotated 90° and the broader end is pushed up to posterior fornix and narrow end is pushed behind the symphysis pubis. It stretches the uterosacral ligament and keeps the uterus anteverted.

It is made up of hard rubber or silicone and chemically sterilized.



Fig. 47B: Ring pessary made of silicone.



Fig. 49: Hysterosalpingography cannula.

HYSTEROSALPINGOGRAPHY CANNULA (FIG. 49)

It is a metallic cannula used for hysterosalpingography (HSG) where radiological visualization of uterocervical canal is done.

Q. What are the indications of HSG?

- Tubal patency test as infertility workup—the most common.
- Recurrent abortion or preterm labor for detection of uterine anomaly—septate, subseptate, bicornuate, unicornuate.

Q. What are the other tubal patency tests?

- Sonohysterosalpingography
- Laparoscopic dye test.

JAYPEE BROTHERS

Q. When it is done?

Day 7 to day 10 of menses period.

Q. Which dye is used?

Lipid based or water based. Commonly water-based dye is used as complication is less but delineation is good in lipid based dye. Urografin or conray 420 is used.

Q. Where it is done?

In radiology department.

Q. What are the complications?

- Embolism
- Extravasation
- Pelvic infection.

Q. Describe the procedure.

For details *see* Chapter of Infertility (Chapter 11) and Chapter 29 (HSG)—procedure, advantage, disadvantage and contraindications (*see* Page 258).

AYRE'S SPATULA (FIG. 50)

It is wooden spatula for taking cervical cytology and vaginal cytology. Heart-shaped end is used for cervix and round-shaped side is used for vaginal cytology.

Q. What are the indications of cervical cytology?

- Cytological status of genital cancer.
- Cytohormonal study—mostly lateral wall of vagina.
- Determination of sex chromatin—it is usually done from buccal smear.

Q. Why wooden, not metallic?

As only superficial cells are collected. Plastic spatula is better than wooden spatula as cells enter into micropore of wooden spatula. Three types of plastic devices are used for cervical cytology **spatula**, **cytobrush**, and **broom**. It is available in presterilized pack.

For details and other questions, *see* Chapter of Carcinoma Cervix in Chapter 8—cervical cytology (*see* Page 175).



Fig. 50: Ayre's spatula (wooden).



Fig. 51: Cytobrush.

CYTOBRUSH (FIG. 51)

Use

- For taking cytology from the cervical canal.
- It is available in presterilized pack.

For details and other questions, *see* Chapter of Carcinoma Cervix in Chapter 8—cervical cytology (*see* Page 175).

JAYPEE BROTHERS

for detailed information on obstetrics & gynecology books, visit our website www.jaypeebrothers.com, for detailed information on obstetrics & gynecology books, visit o

Bedside Clinics in Gynecology

Clinics to Care with Illustrations

The book is written, realizing the basic needs of a student appearing for the oral, practical and theoretical examinations. Though this book is primarily meant for the MBBS students, it would be of immense help for the postgraduates too, encompassing the new curriculum led down by NMC. The first chapter of this book covers the general scheme of clinical history taking and examination with detailed discussions and a lot of illustrations on clinical methods and diseases, both live and diagrammatic.

This book comprises of individual cases, which have been described in an order of case taking, history writing, examination, diagnosis and management. In some areas to simplify, the author has also made question-answer format wherever necessary. The most attractive part of this book is a huge number of illustrations of various disease entities, operative findings and procedures, both original and diagrammatic. This book will not only help the students understand the subject better but also assist them in scoring more in examination. Apart from this, all the items in oral and practical examinations including research methodology have been covered in detail.

Clinical methods, modern investigations, imaging and surgical procedures including the instruments have been analytically depicted with more than 845 original photographs and 330 colored illustrations. In the new edition, most of the chapters have been updated and some topics and areas which were essential are added.



Arup Kumar Majhi MD DNB FICOG is a renowned Professor, Department of Obstetrics and Gynecology, Santiniketan Medical College, Bolpur, Birbhum, West Bengal. He was *Formerly* Head, Department of Obstetrics and Gynecology, RG Kar Medical College and Hospital, Kolkata, with a teaching experience of more than three decades in different Government Medical Colleges and Hospital. From the very early days of his medical career, he had a special interest in teaching both undergraduate and postgraduate students. He is well-known for his extraordinary teaching capability, clinical acumen, decision making, surgical skills and sincerity to the patients. He is an examiner, for both undergraduate and postgraduate examination of different universities of India including DNB. He is very popular in the obstetrics and gynecology fraternity and also amongst his students for his academic and teaching skills. He is also the author of *Operative Obstetrics—An Illustrative Manual* published by Jaypee Brothers and *Bedside Clinics in Obstetrics* published by Academic Publishers. He is the National President Elect, Indian Society of Perinatology and Reproductive Biology (ISOPARB); and Past President, Bengal Obstetrics and Gynecology Society. A regular contributor to various journals, he has to his credit around 100 articles in national and international journals and books. He is the Emeritus Editor of Indian Journal of Perinatology and Reproductive Biology and past National Corresponding Editor of Journal of Obstetrics and Gynecology of India (FOGSI Journal).

Printed in India

Available at all medical bookstores
or buy online at www.jaypeebrothers.com



JAYPEE BROTHERS
Medical Publishers (P) Ltd.
EMCA House, 23/23-B, Ansari Road,
Daryaganj, New Delhi - 110 002, INDIA
www.jaypeebrothers.com

Join us on facebook.com/JaypeeMedicalPublishers

Shelving Recommendation
OBSTETRICS & GYNECOLOGY

