gology books, visit our website www.jaypeebrothers.com, for detailed information on otolaryngology books, visit our website www.jaypeebrothers.com, for detailed information on otolaryngology books

An Illustrated Textbook of



Ear, Nose & Throat and Head & Neck Surgery

Editor-in-Chief

Rakesh Prasad Shrivastav
Pabina Rayamajhi Rana

Section Editors

Sarita KC ▪ Rabindra B Pradhananga ▪ Urmila Gurung
Kunjan Acharya ▪ Heempali Das Dutta

Foreword
Satish Jain

3rd *Edition*

Scan to Download the App

diginerve
A Jaypee Initiative
Your Guide at Every Step
Video Lectures | Notes | Self-Assessment

JAYPEE

Contents

SECTION I: ENT Examination

Section Editor: Rabindra B Pradhananga

1. Examination of the Ear, Nose and Throat 3
Rabindra B Pradhananga

- General Instruments and Equipment for ENT *3*
- Specific Instruments and Equipment for ENT Examination *3*

SECTION II: The Ear

Section Editor: Rabindra B Pradhananga

2. Anatomy of the Ear, Facial Nerve and Eustachian Tube.....7
Kripa Dongol

- External Ear *7*
- Middle Ear Cleft *8*
- Inner Ear *11*
- Facial Nerve *15*

3. Physiology of Auditory and Vestibular System18
Shankar Shah

- Physiology of Hearing *18*
- Mechanism of Hearing *18*
- Physiology of Equilibrium *20*

4. Symptoms of Ear Diseases.....22
Pabina Rayamajhi Rana

- Earache (Otalgia) *22*
- Hearing Loss *23*
- Discharge *23*
- Vertigo *23*
- Tinnitus *24*
- Facial Nerve Paralysis *24*
- Itching/Irritation *24*
- Others *24*
- Symptoms Suggestive of Possible Complications due to Otitis Media 24

5. Clinical Assessment of Patients with Auditory and Vestibular Diseases 25
Pabina Rayamajhi Rana

- Auricle, External Auditory Canal and Surrounding Area 25
- Tympanic Membrane *26*
- Hearing Tests *27*
- Fistula Test *29*
- Eustachian Tube Function *29*
- Facial Nerve *30*
- Nystagmus *30*
- Standing Test *30*
- Dix-Hallpike Maneuver *30*

6. Investigations for Ear Diseases.....32
Sanjeev Thakur

- Audiological Investigations *32*
- Vestibular Investigations *35*
- Radiological Investigations *36*

7. Diseases of the External Ear 38
Bishow Tulachan

- Diseases of the Auricle *38*
- Diseases of the External Auditory Canal 39

8. Diseases of the Middle Ear: Otitis Medias, Myringitis, Eustachian Tube Disorders 46
Bikash Shrestha

- Infections of the Tympanic Membrane (TM) 46
- Infections of the Middle Ear Cleft *46*
- Eustachian Tube Dysfunction *54*

9. Complications of Otitis Media 56
Monika Pokhrel

- Routes of Spread *56*
- Extracranial Complications *56*
- Intracranial Complications *58*

10. The Mastoidectomy Operation 60
Rakesh Prasad Shrivastav

- Canal Down Mastoidectomy *60*
- Canal Up Mastoidectomy *61*

11. Traumatic Injury to the Ear 63
Anupama Shah Rijal

- Physical Trauma *63*
- Barotrauma *64*

12. Otosclerosis.....66
Rakesh Prasad Shrivastav

- Definition *66*
- Types *66*
- Pathology *66*
- Characteristic Features of Otosclerosis *66*
- Clinical Features *66*
- Investigations *67*
- Treatment *67*

13. Neoplasms of the Middle Ear and Mastoid.....69
Dipesh Shakya

- Glomus Tumor *69*
- Osteoma *69*
- Middle Ear Adenoma *70*
- Choristomas *70*
- Hemangiomas *70*

JAYPEE BROTHERS

- Langerhans Cell Histiocytosis *70*
- Peripheral Nerve Sheath Tumors *70*
- Malignant Tumors *70*
- Management *71*

14. Diseases of the Inner Ear and Tinnitus 72
Hari Bhattarai

- Inflammatory Diseases *72*
- Trauma *73*
- Neoplasms *75*
- Autoimmune Diseases *75*
- Others *75*
- Tinnitus *79*

15. Ototoxicity 81
Hari Bhattarai

- Clinical Features *81*
- Common Ototoxic Drugs *81*
- Treatment of Ototoxicity *81*

16. Vertigo and its Differential Diagnosis 83
Yogesh Neupane

- Definition *83*
- History *83*
- Causes of Vertigo *84*
- Examination *84*
- Investigations *84*
- Diagnosis of Common Causes of Vertigo *84*
- Treatment *84*

17. Rehabilitation of Hearing Impairment 86
Pabina Rayamajhi Rana

- Hearing Aids *86*
- Cochlear Implants *88*
- Auditory Brainstem Implant *89*

18. Facial Nerve Anatomy and its Disorders.....90
Rabindra B Pradhananga

- Bell's Palsy (Idiopathic Facial Nerve Paralysis) *90*

SECTION III: The Nose, Paranasal Sinuses and Nasopharynx

Section Editor: Urmila Gurung

19. Anatomy of Nose, Paranasal Sinuses and Nasopharynx.....95
Meera Bista

- The Nose *95*
- The Paranasal Sinuses *98*
- Anatomy of Nasopharynx *101*

20. Physiology of the Nose, Paranasal Sinuses and Nasopharynx 103
Tilak Raj Limbu

- The Nose *103*
- The Paranasal Sinuses *104*
- The Nasopharynx *105*

21. Symptomatology of Diseases of the Nose, Paranasal Sinus and Nasopharynx 106
Shiva C Shahi

- Pain *106*
- Nasal Obstruction *106*
- Nasal Discharge *107*
- Nasal Bleeding (Epistaxis) *107*
- Sneezing *107*
- Disorders of Smell *107*
- Nasal Deformity *108*
- Nasal Intonation of Voice (Rhinolalia) 108

22. Clinical Examination of the Nose, Paranasal Sinuses and Nasopharynx.....109
Bhawana Dongol

- Inspection and Palpation of the External Nose, Orbit and the Face 109
- Palpation of the Paranasal Sinuses *109*
- Assessment of Nasal Patency *110*
- Inspection of the Nasal Vestibule *110*
- Anterior Rhinoscopy *110*
- Posterior Rhinoscopy *112*
- Endoscopic Examination of the Nasal Cavity and Nasopharynx 113
- Examination of Other Relevant Areas 113

23. Investigations for Diseases of the Nose, Paranasal Sinuses and Nasopharynx.....115
Kripa Dongol

- Nasal Endoscopy *115*
- Radiology *116*
- Angiography *117*
- Biopsy *117*
- Tests for Allergy *117*
- Microbiology *118*

24. Diseases of the External Nose 119
Sangita Regmi Chalise

- Infections of the External Nose and Nasal Vestibule 119
- Neoplasms of the External Nose *120*
- Injuries to the External Nose *121*
- Congenital Anomalies of the External Nose 121
- Others *121*

25. Noninfective Rhinitis: Allergic Rhinitis and Nonallergic Rhinitis 123
Rishi Bhatta

- Allergic Rhinitis *123*
- Nonallergic Rhinitis *126*

26. Rhinosinusitis 129
Urmila Gurung

- Acute Rhinosinusitis *129*
- Chronic Rhinosinusitis *131*
- Procedures for Specific Sinuses *133*
- Fungal Rhinosinusitis *134*
- Acute or Fulminant Invasive Fungal Rhinosinusitis 134

JAYPEE BROTHERS

- Rhinosinusitis Secondary to Systemic Diseases 135

27. Complications of Rhinosinusitis 136
Urmila Gurung
- Orbital Complications *137*
- Intracranial Complications *137*
- Local Spread *138*
- Nasal Complications *138*
- Otological, Pharyngeal, Laryngeal and Pulmonary Complications 139
- Distant Complications *139*

28. Diseases of Nasal Septum 140
Urmila Gurung
- Septal Trauma *140*
- Septal Hematoma/Abscess *140*
- Deviated Nasal Septum *141*
- Septal Perforation *144*
- Septal Neoplasms *144*

29. Nasal Polyposis 145
Bibhu Pradhan
- Introduction *145*
- Etiology *145*
- Types of Nasal Polyps *145*
- Differences between Antrochoanal and Ethmoidal Polyps 145
- Investigations *147*
- Treatment *147*

30. Specific Chronic and Granulomatous Conditions and Other Diseases of the Nasal Cavity.....149
Sriti Manandhar
- Chronic Infections *149*
- Granulomatous Conditions of the Nose 152
- Other Diseases *153*

31. Neoplasms of the Nasal Cavity and Paranasal Sinuses 155
Narmaya Thapa
- Benign Neoplasms *155*
- Malignant Neoplasms *156*

32. Neoplasms of the Nasopharynx and Skull Base including Basic Principles of Skull Base Surgery 159
Narmaya Thapa
- Nasopharyngeal Carcinoma *159*
- Juvenile Angiofibroma *160*
- Basics of Skull Base Surgery *161*

33. Nasal and Maxillofacial Trauma.....163
Narmaya Thapa
- Fracture of the Nasal Bone *163*
- Fracture of the Orbital Floor *164*
- Midfacial Fracture *164*
- Central—Maxillary, Nasal, Naso-orbitoethmoid Fractures 164
- Lateral—Zygomaticomaxillary Complex Fracture (Tripod Fracture) 165
- Fracture of the Mandible *165*

34. Epistaxis and its Management 167
Kripa Dongol
- Classification *167*
- Etiology *167*
- Anterior versus Posterior Epistaxis *167*
- Key Sites of Bleeding *167*
- Management *168*

35. Facial Pain, Headache and Neuralgias 172
Sangeeta Shrestha
- Primary Headaches *172*
- Secondary Headaches/Facial Pain *173*
- Pain of Vascular Origin *174*
- Neuropathies and Facial Pain *174*
- Atypical Facial Pain/Persistent Idiopathic Facial Pain 174

36. Functional Endoscopic Sinus Surgery and Other Endoscopic Procedures 176
Bibhu Pradhan
- Goals of Functional Endoscopic Sinus Surgery 176

SECTION IV: The Oral Cavity and Head and Neck

Section Editor: Sarita KC

37. Embryology and Applied Anatomy of the Oral Cavity 181
Dharma Kanta Baskota
- Embryology *181*
- Applied Anatomy *181*

38. Physiology of the Oral Cavity: Perception of Taste Sensation, Formation and Functions of Saliva and Swallowing Mechanism 183
Prashant Tripathi
- Perception of Taste Sensation *183*
- Saliva—Formation and Functions *184*
- Swallowing *184*
- Neural pathway *185*

39. Symptoms of Oral Cavity and Head and Neck Diseases 186
Prashant Tripathi
- Oral Cavity *186*
- Head and Neck *187*

40. Clinical Examination of Oral Cavity and Head and Neck.....189
Krishna Koirala
- Oral Cavity *189*
- Head and Neck *190*

JAYPEE BROTHERS

41. Investigations for Oral Cavity and Head and Neck Diseases 193
Prashant Tripathi
- Imaging *193*
- Thyroid Hormone Assay *194*
- Endoscopy (Sialendoscopy) *195*
- Tests to Assess Taste Sensation *195*
- Pathological Tests *195*

42. Inflammatory Diseases of the Oral Cavity, Diseases of the Tongue and Immune Disorders of the Oral Cavity.....196
Bimal Kumar Sinha
- Inflammatory Diseases of the Oral Cavity 196
- Diseases of the Tongue *197*
- Immune Disorders of the Oral Cavity *198*

43. Neoplasms, Tumor-like Lesions and Premalignant Conditions of the Oral Cavity.....199
Dej Kumar Gautam
- Benign *199*
- Tumor-like Lesions *199*
- Premalignant Conditions *199*
- Malignant Neoplasms *200*
- Other Malignant Neoplasm *201*

44. Oral Manifestations of Systemic Diseases.....203
Deepak Yadav

45. Infection of the Salivary Glands and Sialolithiasis.....204
Sarita KC
- Infections of the Salivary Glands *204*
- Sialolithiasis *205*

46. Neoplasms of the Salivary Glands.....207
Sarita KC
- Investigations for Salivary Neoplasm 207
- Benign Neoplasms *207*
- Malignant Neoplasm *208*

47. Neoplasms of the Thyroid Gland.....210
Sarita KC
- Thyroid Gland *210*
- Solitary Thyroid Nodule *210*
- Multinodular Goiter *211*
- Malignant Neoplasms *211*
- Classification of Malignant Neoplasms of the Thyroid 212

48. Non-neoplastic Diseases of the Thyroid Gland 214
Bimal Kumar Sinha
- Investigations for Thyroid Lesions *214*
- Infections/Inflammation of the Thyroid Gland 214
- Goiter (Nontoxic Goiter) *215*
- Endocrine Disorders *216*

49. Applied Anatomy and Diseases of Deep Neck Spaces and Parapharyngeal Space 218
Deependra Shrestha
- Layers of Deep Cervical Fascia *218*
- Classification of Deep Neck Spaces *218*
- Retropharyngeal Space *219*
- The Carotid Space *220*
- Parapharyngeal Space *220*
- Peritonsillar Space *221*
- Submandibular Space *222*
- Parotid Space *222*
- Masticator Space *222*
- Danger Space *222*

50. Swellings of the Neck 223
Anup Acharya
- Diagnosis of Neck Swellings *223*
- Classification of Neck Swellings according to Site 223

SECTION V: The Pharynx and Larynx

Section Editor: Kunjan Acharya

51. Relevant Anatomy of the Pharynx 229
Suman Dongol
- Anatomy of the Pharynx *229*

52. Relevant Anatomy of the Larynx.....232
Namita Shrestha
- Spaces of Larynx *233*
- Muscles of the Larynx *234*
- Mucous Membrane of Larynx *235*
- Pediatric Larynx *236*

53. Physiology of the Pharynx and Larynx.....237
Bigyan Raj Gyawali
- Physiology of the Pharynx *237*
- Physiology of the Larynx *237*

54. Symptoms of Pharyngeal and Laryngeal Diseases.....239
Inku Shrestha Basnet
- Pharynx *239*
- Larynx *241*

55. Clinical Examination of the Pharynx and Larynx 243
Bigyan Raj Gyawali
- Pharynx *243*
- Larynx *244*

56. Investigations for Pharyngeal and Laryngeal Diseases including Endoscopy and Imaging 247
Prabhat Chandra Thakur
- Imaging *247*
- Histopathological Investigations *248*

JAYPEE BROTHERS

- Flexible and Rigid Endoscopy *248*
- Tests for Esophageal Diseases *249*

57. Diseases of the Tonsils.....250
Kunjan Acharya
- Acute Tonsillitis *250*
- Ulcers of the Tonsil *250*
- Tonsillar Cysts and Tonsillolith *250*
- Unilateral Tonsillar Enlargement *250*

58. Inflammatory Diseases of the Pharynx.....252
Bijaya Kharel
- Infections of the Pharynx *252*
- Noninfective Diseases of the Pharynx *253*
- Pharyngeal Manifestations of Systemic Diseases *254*

59. Neoplasms of the Pharynx.....256
Kunjan Acharya
- Neoplasms of the Nasopharynx *256*
- Neoplasms of the Oropharynx *256*
- Neoplasms of the Hypopharynx *257*

60. Infections and Non-neoplastic Diseases of the Larynx 259
Leison Maharjan
- Inflammations of the Larynx *259*
- Non-neoplastic Lesions of the Larynx 262

61. Neoplasms of the Larynx 265
Kunjan Acharya
- Benign Neoplasms of the Larynx *265*
- Malignant Neoplasms of the Larynx *265*

62. Neurological Lesions of the Larynx and Pharynx 269
Brihaspati Sigdel
- Central Versus Peripheral Involvement 269
- Etiology *269*
- Intracranial Causes *269*
- Extracranial Causes *269*
- Investigations *269*
- Laryngeal Paralysis *270*

63. Laryngotracheal Injuries.....273
Yogesh Neupane
- Acute Laryngeal Trauma *273*
- Chronic Laryngeal Stenosis *274*

64. Voice Disorders including Phonosurgery 275
Toran KC
- Voice Disorders *275*
- Phonosurgery *276*
- Outpatient Department Laryngeal Procedures *277*

65. Stridor and Management of Obstructed Airway 278
Heempali Das Dutta
- Stridor *278*
- Management of Obstructed Airway *278*

66. Snoring and Obstructive Sleep Apnea.....285
Yogesh Neupane
- Snoring *285*
- Sleep Apnea *285*
- Obstructive Sleep Apnea *285*

SECTION VI: Aerodigestive Tract

Section Editor: Heempali Das Dutta

67. Anatomy and Physiology of Oesophagus and Tracheobronchial Tree 289
Arun KC
- The Esophagus *289*
- The Tracheobronchial Tree *290*

68. Foreign Bodies in the Aerodigestive Tract.....292
Heempali Das Dutta
- Foreign Bodies in the Airway *292*
- Foreign Bodies in the Digestive Tract *294*

69. Dysphagia 297
Ajit Nepal
- Acute Dysphagia *298*
- Chronic Dysphagia *298*

SECTION VII: Pediatric ENT

Section Editor: Heempali Das Dutta

70. Congenital Diseases of the Ear, Nose, Throat and Neck.....303
Apar Pokhrel
- Congenital Diseases of the Ear *303*
- Congenital Anomalies of the External Auditory Canal (EAC) *304*
- Congenital Anomalies of the Inner Ear *304*
- Congenital Diseases of the Nose *305*
- Congenital Diseases of Oral Cavity and Head and Neck *305*
- Congenital Diseases of the Pharynx *307*
- Congenital Diseases of the Hypopharynx *307*
- Congenital Diseases of the Larynx *308*
- Congenital Diseases of the Trachea and Esophagus 309

71. Acute Otitis Media 310
Rajendra PS Guragain
- Predisposing Factors *310*
- Bacteriology *310*
- Clinical Features *311*
- Course of the Disease *311*
- Investigations *311*
- Treatment *311*

72. Otitis Media with Effusion including Ventilation Tube Insertion 313
Rajendra PS Guragain
- Synonyms *313*

JAYPEE BROTHERS

- Etiology *313*
- Clinical Features *313*
- Investigations *314*
- Differential Diagnosis *314*
- Natural History of OME *314*
- Sequelae *314*
- Treatment *314*

73. Diseases of the Tonsils and Adenoids in Children.....316
Dhundi Poudel

- Surgical Anatomy of the (Palatine) Tonsil *316*
- Infections of the Tonsils *317*
- Adenoid *321*
- Snoring and Obstructive Sleep Apnea *323*

74. Pediatric Upper Airway Problems, Stridor and Pediatric Tracheostomy.....324
Heempali Das Dutta

- Upper Airway Problems *324*

75. Pediatric Neck Swellings 327
Rupesh Raj Joshi

- Inflammatory Conditions *327*
- Congenital Conditions *328*
- Neoplasia *328*
- Others *328*

76. The Deaf Child.....329
Rabindra B Pradhananga

- How to Detect Deafness in an Infant or Child? *330*

SECTION VIII: Related Topics

Section Editor: Heempali Das Dutta

77. Emergencies in ENT and Head and Neck 335
Heempali Das Dutta

- Ear *335*
- Nose and Paranasal Sinuses *336*
- Oral Cavity, Pharynx, Larynx and Head and Neck *336*

78. Imaging in ENT and Head and Neck Diseases 337
Dharma Kanta Baskota

- Magnetic Resonance Imaging *337*
- Radioisotopes and Radiotracers (Nuclear Medicine) *338*

79 Radiotherapy in ENT and Head and Neck Cancers.....339
Mukesh Kumar Sah

- 5 Rs of Radiotherapy *339*
- Units of Radiation Measurement *339*
- Treatment Modalities *339*
- Curative Radiotherapy *339*
- Adjuvant Radiotherapy *339*
- Palliative Radiotherapy *339*
- Types of Radiotherapy *340*
- Sources of Radiation *340*
- Conventional Fractionation of Radiotherapy 340
- Side Effects of Radiotherapy *340*
- Advances in Radiotherapy *340*
- Application of Radiotherapy in Noncancerous Conditions 341

80. Chemotherapy in ENT and Head and Neck Cancers.....342
Bijaya Kharel

- Types of Chemotherapy *342*
- Chemotherapeutic Agents *342*

81. Laser in ENT and Head and Neck Surgery.....345
Bigyan Raj Gyawali

- Principle of Laser Action *345*
- Types of Lasers *345*
- Advantages of Lasers Over Conventional Surgery 346

82. Common Instruments Used in ENT and Head and Neck.....347
Sovit Baral

- Ear Instruments *347*
- Nasal Instruments *349*
- Throat Instruments *351*

83. Common X-rays in ENT and Head and Neck.....354
Bijaya Kharel

- Ear *354*
- Nose and Paranasal Sinuses *355*
- Head and Neck *357*
- Contrast Imaging *360*

Index *361*

JAYPEE BROTHERS

CHAPTER

65 Stridor and Management of Obstructed Airway

Heempali Das Dutta

JAYPEE BROTHERS

STRIDOR

Stridor is defined as noisy breathing due to partial obstruction of the major airway either in the oropharynx, hypopharynx, larynx, trachea or bronchi. Stertor is a term used to define noisy breathing due to rattling or rumbling of secretions in the pharynx and larynx. Rales and crepitations arise from the distal portion of bronchial tree and alveoli. Stertor, rales and crepitations are not stridor. Stridor may be:

- Inspiratory
- Expiratory (wheeze)
- Biphasic (both inspiratory and expiratory)

Airway obstruction at or above the level of vocal cord produces inspiratory stridor. Airway obstruction in the subglottis or trachea produces biphasic stridor. Airway obstruction at the level of bronchioles and alveoli produces expiratory stridor and is commonly referred to as wheeze (e.g., in asthma) and is not true stridor. **Table 65.1** gives the clinical difference according to the subsite.

TABLE 65.1: Clinical differences according to subsites of airway obstruction.

Subsites	*Airway noise*	*Voice/cry*	*Cough*
Naso-/oropharynx	Stertor	Muffled	Typically absent
Supraglottis/glottis	Stridor-inspiratory	Hoarse (glottis)	Barking
Subglottis/upper trachea	Stridor-biphasic	Unchanged	Brassy
Lower trachea	Stridor-expiratory	Unchanged	Wet sounding

Differential Diagnosis of Stridor

Neonates and children are at greater risk than adults when there is upper airway obstruction because their airway is narrower and also because they have softer cartilage in their airway which collapse more easily. Differential diagnosis and causes of upper airway obstruction leading to stridor is given in **Box 65.1**.

All the above-listed conditions have been described elsewhere in this book and hence will not be discussed here.

Box 65.1: Differential diagnosis of stridor.

Neonates
- Laryngomalacia
- Congenital laryngeal webs
- Congenital cysts and tumors of the larynx
- Subglottic stenosis

Children
- Acute laryngotracheobronchitis
- FB in the larynx/tracheobronchial tree
- Retropharyngeal abscess
- Respiratory papillomatosis
- Acute epiglottitis
- Acute bacterial laryngitis
- Acute laryngeal edema
- Bilateral abductor paralysis of vocal cords
- Diphtheria

Adults
- Malignancies of the larynx and hypopharynx
- Laryngotracheal injuries
- Acute bacterial laryngitis
- FB in the larynx/tracheobronchial tree
- Angioneurotic edema of vocal cords
- Bilateral abductor paralysis of vocal cords

MANAGEMENT OF OBSTRUCTED AIRWAY

Upper Airway Obstruction

Patients with upper airway obstruction will present as:

- Acute life-threatening respiratory obstruction or
- Gradual onset respiratory obstruction

Acute Life-threatening Respiratory Obstruction (Upper Airway Obstruction)

All the conditions mentioned in **Box 65.1** can present as life-threatening respiratory obstruction (upper airway obstruction). However, common causes of acute life-threatening respiratory obstruction are inhalation of food bolus or a foreign body, trauma, infections of the larynx and upper trachea and late presentation of large neoplasms of the larynx or laryngopharynx (frequently seen in countries of this subcontinent and Third World countries).

Treatment

Acute respiratory obstruction due to food bolus or any other foreign

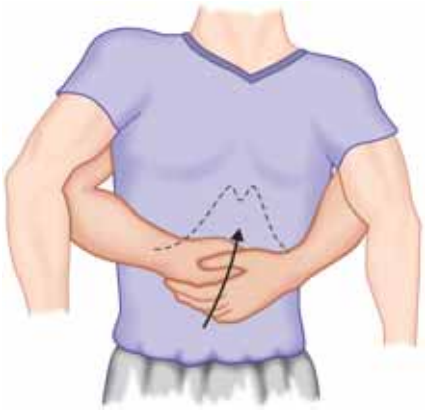

Fig. 65.1: The Heimlich maneuver.

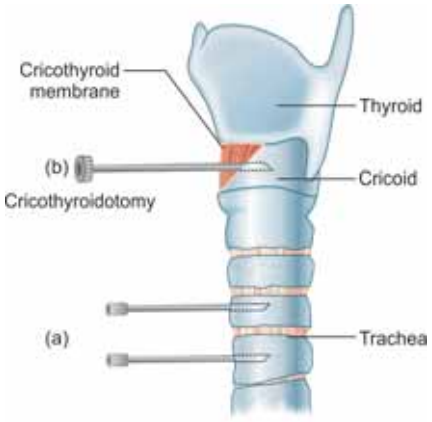

Fig. 65.2: Emergency methods to secure airway in acute life-threatening upper airway respiratory obstruction: (A) Needles inserted directly into the trachea; (B) The airway is entered through cricothyroid membrane (cricothyrotomy). In this instance, a wide bore intravenous cannula has been used.

body should be managed by Heimlich maneuver. This procedure uses the residual air in the lungs to expel the foreign body. Pressure should be exerted by sudden and rapid squeezing motion applied against the xiphoid region of the sternum **(Fig. 65.1)**. Other alternative airway access for management of stridor is given in the **Box 65.2**.

When the obstruction lies in the oral cavity, oropharynx or base of the tongue, placing an oropharyngeal or nasal airway will help. Intubation can be done provided appropriate instruments, trained personnel and adequate facilities are available.

When the obstruction lies in the hypopharynx or at the level of or above the glottis, wide bore needles may be inserted directly into the trachea of children to provide temporary relief **(Fig. 65.2)** until either intubation or tracheostomy can be performed.

In adults, it is better to perform a cricothyroidotomy (laryngotomy) through the cricothyroid membrane. Entry into the airway can be achieved quickly through the cricothyroid membrane because it is superficial and relatively avascular and also because it is an easily identifiable landmark.

Box 65.2: Alternative airway management for obstructed airway.

- Oral airway (Guedel airway)
- Nasopharyngeal airway
- Endotracheal intubation
- Transtracheal cannulation
- Cricothyrotomy/Minitracheostomy/Laryngotomy
- Tracheostomy

Cricothyrotomy should never be done as a substitute for regular tracheostomy because of the possibility of subglottic stenosis associated with the former procedure. Cricothyrotomy can be done by one of the three techniques listed in **Box 65.3**.

Gradual Onset Respiratory Obstruction

It is important not to allow the initial mild stridor to become worse; otherwise it will proceed to life-threatening respiratory obstruction. If the stridor is increasing and the patient has any one of the signs listed here **(Box 65.4)** then an alternate airway, either intubation or tracheostomy must be established immediately.

Intubation versus Tracheostomy

Many medical and surgical conditions (see below) require either tracheostomy or intubation in order to establish, secure and maintain the airway. When is the time to do tracheostomy? The old teaching was that the time to do a tracheostomy is "when you first think about it." However, advances in anesthetic techniques, modern anesthetic facilities and safer endotracheal tubes (high volume and low pressure type) have made intubation a relatively safe procedure and nowadays intubation is preferred to tracheostomy in most conditions. The advantages of intubation over tracheostomy are many **(Box 65.5)**.

In view of this, the present teaching should be that when you think of doing a tracheostomy, "intubate first and then think again whether a tracheostomy should be done."

A patient can be safely intubated for a maximum period of 2 weeks. If the patient is intubated for >2 weeks (prolonged intubation), there is a

Box 65.3: Techniques of cricothyrotomy (minitracheostomy/laryngotomy).

- **Using intravenous cannula Figure 65.2:** A 14-gauge intravenous cannula with needle is introduced into the lumen of the trachea either directly through the tracheal wall or through the cricothyroid membrane with the patient's neck in an extended position. Air is then drawn to confirm the position of the cannula. The cannula is then directed and advanced caudally and the needle removed
- **Using a scalpel—formal surgical procedure:** The thyroid cartilage is steadied with thumb and middle finger of the left hand and cricothyroid space identified with the index finger of the right hand. A scalpel is used to cut the skin, subcutaneous tissue, and cricothyroid membrane horizontally to enter the subglottic area and then turned vertically to admit a thin endotracheal or tracheostomy tube. Alternately an artery forceps is introduced after cutting through the cricothyroid membrane and twisted to gain adequate opening. A thin endotracheal or tracheostomy tube is then introduced and the artery forceps is withdrawn
- **Using a cricothyrotome or minitracheostomy set:** A specially designed cricothyrotome or a minitracheostomy set may be used in a similar manner as an intravenous cannula described above but these are not available in most hospitals in this part of the world

Box 65.4: Signs of increasing stridor requiring immediate intubation or tracheostomy.

- Patient has stridor at rest
- Is restless
- Cannot lie flat in bed
- Has a rising pulse rate
- Is using the accessory muscles of respiration with intercostal recession
- Patient becomes cyanotic

JAYPEE BROTHERS

Box 65.5: Advantages of intubation over tracheostomy.

- Intubation is a noninvasive procedure whereas tracheostomy is an invasive procedure
- Intubation takes less time to perform than tracheostomy
- Intubation is associated with fewer complications than tracheostomy
- Intubation is always preferred to tracheostomy in children because:
  - Anatomical factors make tracheostomy both difficult and risky in children
  - Most airway obstruction is due to acute infections which will probably resolve within 72 hours of treatment and, therefore, tracheostomy is not justified
  - Removal of tracheostomy tube (decannulation) is difficult in children because of frequent occurrence of post-tracheostomy subglottic edema and granulations and also because of psychological dependence of the child on the tracheostomy tube

possibility of the patient of developing subglottic stenosis. Prolonged pressure due to the inflated cuff of the endotracheal tube can result in ischemia of that segment of the tracheal mucosa resulting in necrosis, granulation tissue formation and subsequent scarring and stenosis. If intubation is needed beyond 2 weeks or if prolonged intubation is anticipated or expected at the beginning itself then tracheostomy is preferred to intubation. Subglottic stenosis can be very difficult to treat and is a major complication after prolonged intubation.

Tracheostomy

Tracheostomy is a surgical procedure in which an opening is made in the anterior wall of the trachea along with the underlying soft tissues so as to make a communication between the tracheal lumen and the skin of the neck. This communication is maintained (kept patent) with the help of a specially designed tube—the tracheostomy tube. It differs from "tracheotomy," in which the trachea is also opened but at the end of the procedure this opening is closed and no further communication is present between the tracheal lumen and the skin of the neck.

Tracheostomy may be either an emergency or an elective (or planned) procedure. Nowadays percutaneous tracheostomy (Seldinger and Schachner method) has also gained popularity. Percutaneous tracheostomy set is available, which contains trocar and cannula, guide wire, series of dilators and other accessories.

A permanent or "end" tracheostomy is an elective procedure carried out as part of a surgical procedure involving the removal of the larynx, such as a laryngectomy or pharyngolaryngectomy. A permanent tracheostomy is also created in laryngeal diversion procedures used to prevent aspiration. The continuity between the laryngopharynx and the trachea is permanently disrupted and the cut end of the trachea is sutured to the skin.

Indications

There are mainly four broad indications for doing tracheostomy **(Table 65.2)**.

In developed countries, mechanical respiratory insufficiency is the most common indication for tracheostomy; upper airway obstruction being the least common indication. However, in developing countries, upper airway obstruction (due to neglected and undiagnosed neoplasia of larynx or hypopharynx) is still a common indication for tracheostomy.

Technique

Tracheostomy is much easier to perform in an already intubated/anesthetized patient. Local anesthesia can be used if the patient need not or cannot be intubated.

TABLE 65.2: Indications for tracheostomy.

Broad Indications	*Specific Conditions*
• **Upper airway obstruction** ➢ Real ➢ Anticipated	• Infections—supraglottis and subglottis, laryngotracheobronchitis • Neoplasms—carcinoma of larynx and hypopharynx • Neurological—bilateral abductor paralysis of the vocal cords [bilateral recurrent laryngeal nerve (RLN) nerve paralysis] • Trauma—acute laryngotracheal injuries • Foreign body in the larynx • Laryngeal, subglottic, and upper tracheal stenosis • Others—laryngeal edema and subglottic narrowing/edema due to other causes • Major head and neck surgery where postoperative airway obstruction is anticipated such as major surgeries of the oral cavity, oropharynx or hypopharynx (elective tracheostomy)
Mechanical respiratory insufficiency	• Comatose patients without cough reflex—head and chest injuries, poisoning or post-neurosurgical procedures • Neurological conditions—Guillain–Barré syndrome, myasthenia gravis and poliomyelitis • Chronic obstructive pulmonary disease (COPD) • Pneumonia
Remarks: Tracheostomy provides the easiest and safest means of ventilator assistance, eliminates upper airway dead space, and allows frequent and adequate pulmonary aspiration	
Respiratory difficulty due to secretions already present	• Pulmonary edema • Congestive heart failure • Chronic lung disease and infections such as severe bronchiectasis or large lung abscess
Remarks: Accumulations of secretions in lower respiratory tract prevents proper gas diffusion at the alveoli. Tracheostomy allows frequent and adequate pulmonary aspiration and clearance of tracheobronchoalveolar passage	
Protection from overspill and aspiration	Neoplasia of hypopharynx and esophagus and various bilateral laryngeal paralysis causes overspill due to pooling of saliva in and around the laryngeal inlet
Remarks: Tracheostomy allows secretions to be sucked out as and when required	

JAYPEE BROTHERS

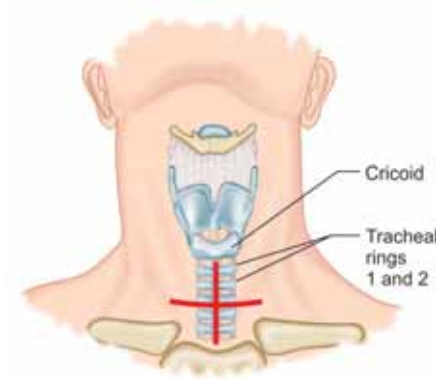

Fig. 65.3: Incisions for tracheostomy. The transverse incision is preferred for elective procedures but the vertical incision is quicker in an emergency and is preferred in young children.

Position

Supine with the neck extended by placing a pillow/sand bag between the shoulder blades. In infant and young children, overextension of the neck should be avoided because overextension increases the risk of injury to the great vessels in the root of anterior neck.

Incision

Horizontal skin incision is made midway between the lower border of cricoid cartilage and suprasternal notch. A horizontal incision gives a cosmetically acceptable scar. Alternatively, a vertical incision is made in the midline between the two abovementioned points **(Fig. 65.3)**. Vertical incision is preferred in infants and young children and in emergency as it gives a better exposure. The inexperienced surgeon should use a vertical incision in children as well as in adults.

Operative Steps (Fig. 65.4)

- The incision is made through the skin, subcutaneous tissue and the platysma to expose the strap muscles of the neck
- The strap muscles are separated in the midline (linea alba) and then retracted. Further dissection should be carried out in the midline and the trachea should be palpated from time to time so as to confirm that the dissection is indeed being carried out in the midline
- The thyroid isthmus is then exposed. The isthmus is dissected out, clamped, tied and transected to expose the trachea. The isthmus will bleed profusely if it is not clamped and tied before transecting it. Alternately, the isthmus may be retracted superiorly without transecting it. The trachea is identified and a needle (with syringe) is inserted in the lumen to aspirate air in order to confirm that it is indeed the trachea. The pretracheal fascia is then incised

  In adults, a circular hole (the size of the tracheostomy tube) is cut out in the anterior aspect of trachea either between the 2nd and 3rd or between the 3rd and 4th tracheal rings by removing the anterior aspect of the tracheal rings.

  In young children, a vertical incision is made in the anterior aspect of the trachea (rather than making a hole) in order to avoid transecting the trachea. In infant and young children, the edge of the skin incision is sutured with edge of the tracheal incision (maturation sutures). This helps to secure tracheal opening so that tracheostomy tube can be placed easily
- The cricoid and 1st tracheal ring should not be cut or traumatized as there is a high risk of late subglottic or tracheal stenosis
- An appropriate-size metal tracheostomy tube is then inserted and secured in position by tying ribbon tapes around the neck. The ribbon tapes always should be tied with the head in neutral position and not with the head in extended position. This will avoid loosening of the ribbon tapes when the neck is returned to the neutral position or flexed, which may lead to extrusion of the tube during coughing. A high-volume and low-pressure cuffed silastic tracheostomy tube is necessary if patient needs positive pressure ventilation

After tracheostomy certain physiological and pathological effects occur in the patients due to the altered breathing route as shown in **Box 65.6**.

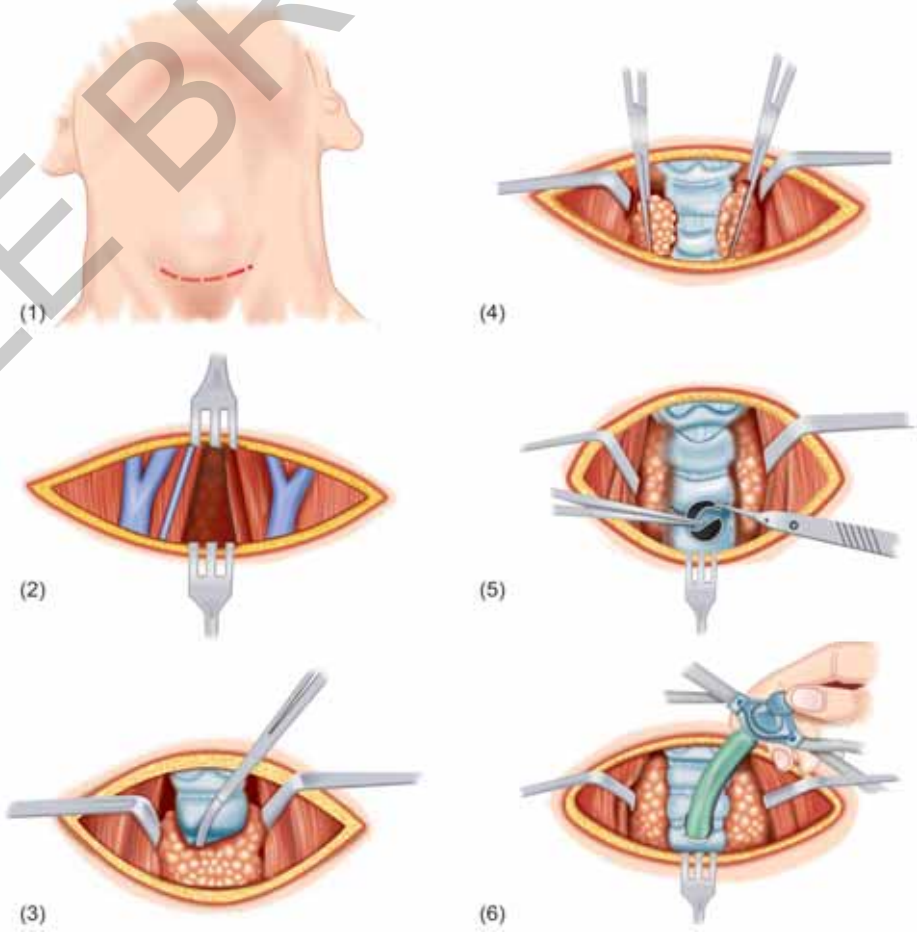

Fig. 65.4: Tracheostomy—operative steps.

JAYPEE BROTHERS

Box 65.6: Effects of tracheostomy.

- Laryngeal bypass—loss of cough and phonation
- Reduction in respiratory dead space
- Loss of nasal mucosa filtration and humidification
- Increased risk of infection
- Tube acts as foreign body leading to local inflammation
- Sump above tracheostome and below larynx where mucus collects

Complications

Complications of tracheostomy are listed in **Box 65.7**.

Types of Tracheostomy Tube

There are basically two types of tubes—metal and nonmetal (silastic).

Metal Tube

Metal tubes come in a set consisting of an outer tube, an inner tube, and an introducer **(Fig. 65.5)**. The introducer fits into the outer tube. The introducer is used only initially to guide the outer tracheostomy tube into the trachea and the introducer is removed immediately. The outer tube is fastened to the neck with ribbon straps. Then the inner tube is slipped into the outer tube and fixed to it by a locking device.

The main advantage of the metal tube is that if crusts or mucus plug block the inner tube and patient has difficulty in breathing, the inner tube can be removed while the outer tube remains in the trachea and maintains the patency of the airway allowing the patient to breathe. It is also inert, easy to clean, can be autoclaved, can be used repeatedly and is relatively inexpensive as compared to silastic tubes. Some metal tubes come with a speaking valve, which makes it possible for the patient to speak.



Fig. 65.5: Metal tracheostomy tubes—outer tube, inner tube, and the introducer.

The main disadvantage of metal tubes is that these do not have a cuff and, therefore, cannot produce an airtight seal that is needed to: (1) Protect lower respiratory passage from seepage of secretions and blood from the surgical site, (2) When the patient requires a ventilator (assisted positive pressure ventilation) and (3) For initiating general anesthesia.

The other disadvantages are that it cannot be used in patients undergoing radiotherapy treatment and if the metal tube does not fit properly then the lower end can cause injury to the trachea wall and even lead to erosion of the posterior tracheal wall occasionally resulting in tracheoesophageal fistula.

Fuller's Bivalve Tracheostomy Tube

This is a specially designed tracheostomy tube for young children, which needs special mention **(Fig. 65.6)**. This tube-like other metal tubes has an outer as well as inner tube. The inner tube is a complete solid tube like any other metal tracheostomy tube. However, the outer tube is split into two flanges (bivalved) and the flanges are compressible. The main advantage of this type of tube is that the two flanges can be compressed together by fingers particularly at the lower part so that the lower end of the tube can be significantly narrowed down. This makes introduction of the

Box 65.7: Complications of tracheostomy.

Intraoperative

- **Hemorrhage:** From anterior jugular or thyroid veins and in children from the brachiocephalic artery
- **Apnea:** The high level of retained CO_2 in the lungs which was driving the respiratory center is suddenly flushed out once an opening is made in the trachea resulting in apnea
- **Cardiac arrest:** It is due to—1. Excessive production of adrenaline in an anxious patient, 2. Rise of pH due to sudden washout of retained CO_2 and 3. Hyperkalemia due to respiratory alkalosis
- **Air embolism:** It usually due to trauma to the great veins in the neck (very rare)
- **Injury to surrounding structures:** Cricoid and rarely thyroid cartilage injury can later lead to subglottic/tracheal stenosis. Injury of contents of the carotid sheath, esophagus. Recurrent laryngeal nerve injury, which is very unlikely will lead to immediate hoarseness

Early Postoperative

- **Dislodgment/displacement of the tracheostomy tube:** It is due to—1. Short length of tracheostomy tube, 2. Great thickness of soft tissues of the neck, 3. Malposition of the tracheostomy tube, 4. Improper tightening (usually during extended neck position) of the ribbon tape as mentioned above
- **Surgical emphysema:** It is due to tight skin sutures along with a large opening in trachea as compared to the size of the tracheostomy tube causing air to leak out of the trachea into the soft tissue of the neck. Surgical emphysema may result in cardiopulmonary embarrassment if it extends to the mediastinum
- **Pneumothorax:** It is due to injury to the pleura
- **Blockage of the tracheostomy tube:** It is due to—1. Lack of humidification and 2. Inadequate suction leading to mucus plug, crusts and scab formation
- **Mild dysphagia:** It is due to—1. Loss of subglottic pressure and 2. Pressure exerted on the esophagus by the cuffed tube
- **Tracheitis, bronchitis and pneumonia:** It is due to infection and aspiration
- **Tracheoesophageal fistula:** It is due to erosion of posterior wall of trachea because of trauma caused by the lower end of the tube
- **Tracheoarterial fistula:** It is due to erosion of the brachiocephalic artery in children

Late Postoperative

- **Stenosis of trachea:** It is due to—1. Cricoid injury, 2. Tracheal infections, 3. Prolonged use of cuffed tracheostomy tube, 4. Improper tracheostomy care
- **Difficulty in decannulation:** It frequently occurs in children because after tracheostomy the child quickly forgets to breathe through the nose and becomes psychologically dependent on the tracheostomy tube for breathing in spite of the fact that the child has a patent airway at the time of decannulation. This may be also due to subglottic edema and granulations or stricture formation in cases of long-standing tracheostomy.
- **Tracheocutaneous fistula:** It is due to failure of the tracheal stoma to close (heal) after decannulation

JAYPEE BROTHERS



Fig. 65.6: Fuller's metal tracheostomy tube.

tube into the tracheostomy opening of young children (which is usually very small) easy. Moreover, young children will almost always cry during change of the tracheostomy tube, which results in further narrowing and sometimes even total closure of the tracheostomy opening. The Fuller's tube is very useful in such patients. The surgeon will first compress the outer tube during introduction thereby narrowing the lower end of the outer tube. The narrow lower end of the outer tracheostomy tube can be guided into the trachea through the opening. Once the outer tube is secure in the trachea, then the inner tube is introduced, which will widen the outer tube.

Nonmetal Tube (Silastic)

Nonmetal tubes are made of silastic **(Fig. 65.7**). They usually consist of a single tube but a set consisting of both outer and inner tubes (like that of the metal tube) is also available. The main advantage is that they have an inflatable cuff and can be connected to a ventilator. Inflated cuff protects lower respiratory tract from seepage of secretion and blood from above. It can be used safely in patients undergoing radiotherapy treatment. Some silastic tubes come with a speaking valve and special filter, which is quite beneficial for speech and filtration of inspired air.

Paradoxically, the disadvantage is that the inflatable cuff itself can be the cause of excess cuff pressure leading to subglottic stenosis if used for >2 weeks.



Fig. 65.7: "Portex" cuffed tube made of silastic with introducer.

The main disadvantage of the single silastic tube is that it can get blocked due to mucus plug or crust leading to respiratory obstruction. Moreover, these tubes are relatively expensive.

Care of Tracheostomy

Meticulous postoperative care of tracheostomy is necessary to avoid complications **(Box 65.8).**

The nose helps to warm and humidify inspired air and this function is bypassed after tracheostomy. Copious tracheal secretion and crusting occur as a result. Regular suction, humidification and chest physiotherapy help to overcome these problems. Humidification can be done by inhalation of steam or alternately by an electric humidifying unit.

The first change of tracheostomy tube should be done preferably after 72 hours. If tracheostomy tube is removed earlier then there is likelihood of the soft tissue of the neck around the tracheostomy collapsing and obstructing air entry. After 72 hours a tract usually forms and remains patent when the tracheostomy tube is removed during changing.

Metal tracheostomy tubes and also some silastic tubes have two tubes—inner and outer and even if the inner tube is blocked, say due to crusts, it can be removed leaving the outer tube undisturbed for the patient to breathe through. This is unfortunately not possible in single lumen tubes (such as a cuffed "Portex" tracheostomy tube made of silastic). If such a tube gets blocked within the first 48–72 hours, removal of the single lumen tube will result in the soft tissue collapsing over the tracheostomy site causing airway obstruction.

Decannulation

Decannulation should be done in an ordered sequence. The tube should be

Box 65.8: Postoperative care of tracheostomy.

- **Suction:** Regular tracheal suction (after putting 2–3 mL of sterile saline into the trachea if the secretion is thick and tenacious)
- **Humidification:** Regular humidification either by steam inhalation or nebulizer unit
- **Chest physiotherapy:** Regular chest physiotherapy
- **First change of tube:** The first change of tracheostomy tube is done after 72 hours of surgery
- **Subsequent change of tube:**
  - When a metal tube is used, the inner tube is removed twice a day, cleaned and reinserted without disturbing the outer tube and the outer tube is similarly removed, cleaned and reinserted preferably once a day
  - When a single lumen silastic tracheostomy tube is used, this tube should also be removed, cleaned and reinserted once a day
- **After change of tracheostomy tube each time, it is mandatory to check:**
  - Air blast from the tube
  - Any bleeding or abnormal secretion from the tracheal lumen or stoma site
  - Presence of surgical emphysema
  - Tightness of the ribbon tape used to tie tracheostomy tube around the neck
- **Deflating of cuffed tube:** When a cuffed silastic tube is used, the cuff should be deflated every 2 hours for a few seconds (even if it is of high volume/low pressure type) in order to prevent subglottic stenosis
- **Dressing:** Daily dressing is required to keep the stoma site clean and to prevent infection. It is necessary to keep "Vaseline" or antibiotic ointment smeared ("Sofratule") gauze piece in between tube and skin in order to prevent excoriation of the skin due to friction of the tube. Secretions around the tube must be cleaned as and when necessary

JAYPEE BROTHERS

blocked during the day and unblocked at night for the first 24 hours. If the patient tolerates this then the tube can be occluded for a full 24-hour period and if this is tolerated then the tube can then be removed. If the patient is unable to tolerate this occlusion of the tube, then it may be necessary to downsize the tube to give more room around it. Patients who have been dependent on the tracheostomy for a long time may require a more prolonged decannulation process as it may take some time for them to overcome their anxiety about being unable to breathe without the tube in place. Once the tube has been removed an airtight dressing must be applied to occlude the stoma.

POINTS

- Acute life-threatening airway obstruction may require immediate relief by cricothyroidotomy (laryngotomy)
- Intubation is safer than tracheostomy in children
- It is always better to intubate than to do tracheostomy provided appropriate facility for intubation and care of an intubated patient is available
- When intubation is necessary beyond 2 weeks, it is better to do a tracheostomy
- Tracheostomy should be done between 2nd and 3rd or between 3rd and 4th tracheal rings. Tracheostomy should not be done above the 2nd tracheal ring because injury to 1st tracheal ring and the cricoid cartilage will lead to postoperative laryngotracheal stenosis (subglottic stenosis)
- Meticulous postoperative care of tracheostomy such as care of tracheal stoma, regular suction, humidification, chest physiotherapy, cleaning and regular change of tracheostomy tube is needed to avoid complications

JAYPEE BROTHERS

for detailed information on otolaryngology books, visit our website www.jaypeebrothers.com, for detailed information on otolaryngology books, visit our website www.jaypeebrothers.com, for detailed

An Illustrated Textbook of Ear, Nose & Throat and Head & Neck Surgery

Salient Features

- This book is aimed at undergraduates, however, DLO students and first year postgraduate ENT residents will also benefit.
- Very latest advances in the specialty have been included such as Skull Base Surgery, Functional Endoscopic Sinus Surgery, Cochlear Implantation, Hearing Implants, etc.
- Diseases prevalent in this part of the world and other third world countries have been given due importance.
- A separate section on Pediatric Otolaryngology has been included.
- 'Key Points' (in colored boxes) have been given after every chapter for easy and quick revision before the examination.

Rakesh Prasad Shrivastav MS FRCS joined the Department of Ear, Nose and Throat and Head and Neck Surgery (ENT-HNS) in Tribhuvan University Teaching Hospital, Maharajgunj Medical Campus, Institute of Medicine, Kathmandu, Nepal in January 1983, as an Assistant Lecturer after obtaining Master of Surgery (MS) degree from All India Institute of Medical Sciences (AIIMS), New Delhi, India. Since then, he underwent postgraduate training in middle ear surgery and FESS in Japan and United Kingdom respectively. He was awarded Fellowship of the Royal College of Surgeons (FRCS) ad eundem by the Royal College of Surgeons of England (London) in 2009. He is Former Dean, Institute of Medicine and Former Head, Department of ENT and Head and Neck Surgery, Tribhuvan University Teaching Hospital, Kathmandu. He has more than 70 scientific publications in International and National Journals.

Pabina Rayamajhi Rana MS joined the Department of Ear, Nose and Throat and Head and Neck Surgery (ENT-HNS) in Tribhuvan University Teaching Hospital, Maharajgunj Medical Campus, Institute of Medicine, Kathmandu, Nepal after obtaining Master of Surgery (MS) degree from the same institute in 2006. She did her one-year fellowship in Implant Otology from Madras ENT Research Foundation, Chennai, Tamil Nadu, India in 2018. She is presently involved in the Otology, Neurotology and Lateral Skull Base Unit in the department. She has 50 scientific publications in National and International Journals till date.

Printed in India

Available at all medical bookstores or buy online at www.jaypeebrothers.com

JAYPEE BROTHERS
Medical Publishers (P) Ltd.
EMCA House, 23/23-B, Ansari Road,
Daryaganj, New Delhi - 110 002, INDIA
www.jaypeebrothers.com

Join us on facebook.com/JaypeeMedicalPublishers

Shelving Recommendation
OTOLARYNGOLOGY

ISBN 978-93-5696-143-2