e www.jaypeebrothers.com, for detailed information on nursing books, visit our website www.jaypeebrothers.com







Manual of MIDWIFERY and Gynecological NURSING

Annamma Jacob

4th Edition

JAYPEE

CONTENTS

A

1. Abdominal Examination 1
2. ABO Incompatibility 4
3. Abnormal Uterine Action 5
4. Abnormal Uterine Bleeding 13
5. Abortion 19
6. Adenomyosis 33
7. Adoption 34
8. AIDS in Pregnancy 40
9. Amniocentesis 47
10. Amniotic Fluid Embolism 49
11. Anemia in Pregnancy 50
12. Antenatal Assessment 61
13. Antepartum Hemorrhage 65
14. Assisted Reproductive Technology 83

B

15. Basic Life Support/Cardiopulmonary Resuscitation 88
16. Biophysical Profile 93
17. Birth Injuries in Newborns 95
18. Breastfeeding 104
19. Breast Cancer 108
20. Breast Infection in Puerperium 143
21. Breech Presentation 145
22. Brow Presentation 153

C

23. Cesarean Section 155
24. Carcinoma Cervix 163
25. Cancer Uterus 166
26. Cardiac Disease in Pregnancy 169
27. Cephalopelvic Disproportion 181
28. Chromosome Abnormalities in Newborns 184
29. Congenital Uterine Anomalies/Abnormalities 190

30. Congenital Anomalies in Newborns 195
31. Contracted Pelvis 215
32. Contraction Stress Test 217
33. Contraception 219
34. Convulsions in Newborns 236
35. Cordocentesis (Percutaneous Umbilical Blood Sampling) 238
36. Cord Presentation 240
37. Cord Prolapse 241

D

38. Diabetes in Pregnancy 243
39. Diagnosis of Pregnancy 257
40. Diagnostic Procedures in Gynecology and Obstetrics 263
41. Diarrhea in Newborns 297
42. Disseminated Intravascular Coagulation 299
43. Drugs in Obstetrics 302
44. Dysmenorrhea 317
45. Dyspareunia 318

E

46. Eclampsia 319
47. Ectopic Pregnancy 322
48. Endometriosis 327
49. Endoscopic Surgery in Gynecological Patients 332
50. Episiotomy 335
51. External Cephalic Version 338

F

52. Face Presentation 340
53. Fetal Circulation 345
54. Fetal Distress 347
55. Fetal Heart Rate Monitoring Cardiotocography (CTG) 348
56. Fetal Imaging 353
57. Fetal Skull 356
58. Fibroid Tumors in Uterus 363
59. Forceps Delivery 374

G

60. Gene Disorders, Genetic Screening and Genetic Counseling 378
61. Gynecological Disorders in Pregnancy 392

H

62. Hyaline Membrane Disease/Respiratory Distress Syndrome 406
63. Hydatidiform Mole/Vesicular Mole 408
64. Hydramnios/Polyhydramnios 411
65. Hyperemesis Gravidarum 416
66. Hysterectomy 419
67. Hysterosalpingography 421

I

68. Immediate Care of the Newborn 422
69. Immunization 425
70. Induction of Labor 429
71. Infections in Newborns 437
72. Infectious Conditions of Pelvic Organs 441
73. Infections in Pregnancy 446
74. Infertility 449
75. Instruments in Obstetrics and Gynecology 456
76. Intrauterine Growth Restriction (Retardation) 488
77. Intrauterine Tamponade Using Bakri Balloon 491
78. Inversion of Uterus 495

J

79. Jaundice in Neonate 498

L

80. Labor—Stage I 501
81. Labor—Stage II 508
82. Labor—Stage III 515
83. Lactation 520
84. Low Birth Weight Baby 525

M

85. Maternal Pelvis 526
86. Meconium Aspiration Syndrome 531
87. Medical Termination of Pregnancy 533
88. Menopause 535
89. Minor Disorders of Pregnancy 540
90. Minor Disorders of Newborn 544
91. Minor Surgeries in Gynecological Patients 550
92. Multifetal Pregnancy 557

N

93. National Family Welfare Programs 563
94. Neonatal Intensive Care Unit 576
95. Newborn Assessment 593
96. Newborn Care 596
97. Non-stress Test 605
98. Nursing Diagnosis 606
99. Nursing Care of Newborn in Incubator/Isolette 619

O

100. Obstructed Labor 621
101. Occipitoposterior Position 625
102. Oxytocin Challenge Test 627

P

103. Partograph 628
104. Pelvic Inflammatory Disease 633
105. Physiological Changes in Pregnancy 637
106. Physical Examination of Newborn 644
107. Polycystic Ovary Syndrome 651
108. Postpartum Care 654
109. Postdated Pregnancy/Post-term Pregnancy 667
110. Postnatal Assessment (Postdelivery Assessment) 670
111. Precipitate Labor 674
112. Pregnancy-induced Hypertension 676
113. Premature Rupture of Membranes 686
114. Premenstrual Syndrome 687
115. Preterm Baby 689
116. Preterm Labor 692
117. Prolonged Labor 695
118. Psychiatric Disorders during Pregnancy 697
119. Psychiatric Disorders in Puerperium 701
120. Puberty 704
121. Puerperal Sepsis 707

R

122. Rectovaginal Fistula 710
123. Respiratory Distress in Newborns 712
124. Respiratory Distress Syndrome 713

125. Resuscitation of the Newborns 715
126. Retained Placenta 722
127. Retroversion of Uterus 723
128. Rhesus Incompatibility 724
129. Rupture of Uterus 726

S

130. Shock in Obstetrics 729
131. Shoulder Dystocia 733
132. Sexually Transmitted Diseases 735
133. Sexual Violence 744
134. Single Parent 747
135. Stillbirth 750

T

136. Teenage Pregnancy and Adolescent Pregnancy 753

U

137. Ultrasonics in Obstetrics 755
138. Unwed Mother 759
139. Uterine Prolapse 763
140. Urinary Tract Infections 767

V

141. Vasa Previa 771
142. Vasectomy Operation/Male Sterilization 772
143. Vesicovaginal Fistula 775
144. Ventouse Delivery (Vacuum-assisted Birth) 778
145. Vomiting in Newborns 780

Study Questions *782*

Bibliography *799*

Index *803*

1. ABDOMINAL EXAMINATION

An abdominal examination followed by a physical examination is done for every pregnant woman at each clinic visit. Abdominal examination includes inspection, measurements, palpation and auscultation.

INSPECTION

- Visual assessment of the abdomen helps to know the size, shape, and contour of the abdominal wall and to note skin changes of pregnancy and scars
- Measuring fundal height provides information regarding the progressive growth of the fetus in relation to presumed gestational age by dates
- Palpation using Leopold's maneuvers gives information about the lie, presentation, position and variety of the fetus
- Auscultation of the fetal heartbeats confirms the presence a live fetus and aids to add to the information gathered about the position, presentation and lie of the fetus.

PROCEDURE OF PERFORMING AN ABDOMINAL EXAMINATION AND PALPATION (Figs. 1.1A to D)

- Explain to woman what will be done and how she may co-operate
- Instruct the woman to empty her bladder
- Draw curtains around the bed.

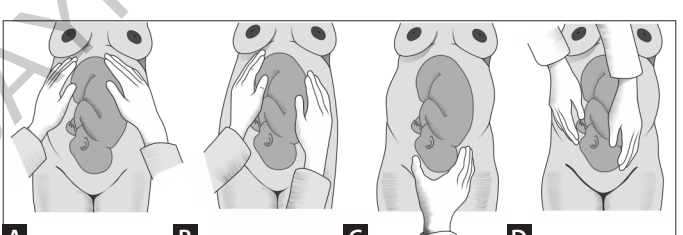

Figs. 1.1A to D: Abdominal palpation (Leopold's maneuvers). **A.** First maneuver (fundal palpation); **B.** Second maneuver (lateral palpation); **C.** Third maneuver (Pawlik's grip); **D.** Fourth maneuver (pelvic palpation).

JAYPEE BROTHERS

Inspection and Measurements

- Position the woman for examination with a pillow under head and upper shoulders, arms by side, and abdomen exposed from below the breasts to the symphysis pubis
- Inspect the abdomen for scars, hernia, linea nigra, striae gravidarum, and state of umbilicus, skin condition and contour
- Determine the fundal height using the ulnar side of the palm
- Measure fundal height using measuring tape or pelvimeter
- Measure abdominal girth by encircling the woman's abdomen with a tape, measure at the level of the umbilicus.

Palpation

- Instruct the woman to relax her abdominal muscles by bending her knees slightly and doing relaxation breathing
- Be sure your hands are warm before beginning to palpate, rest your hands lightly on the mother's abdomen, while giving explanation about the procedure
- Keeping fingers of hands together, apply smooth deep pressure as firm as is necessary to obtain accurate findings (for palpation, use the flat palmar surface of fingers and not finger tips).

Perform Fundal Palpation (First Maneuver)

- Face the woman's head
- Place your hands on the sides of the fundus and curve the fingers around the top of the uterus
- Palpate for size, shape, consistency and mobility of the fetal part in the fundus.

Perform Lateral Palpation (Second Maneuver)

- Continue to face the woman's head
- Place your hands on the sides of the uterus about midway between the symphysis pubis and the fundus
- Apply pressure with one hand against the side of the uterus pushing the fetus to the other side and stabilizing it there
- Palpate the other side of the abdomen with the examining finger from the midline to the lateral side, and from the fundus

JAYPEE BROTHERS

to the symphysis pubis using smooth pressure and rotatory movements
- Palpate both sides of the abdomen.

Pawlik's Grip (Third Maneuver)

- Continue to face the woman's head and make sure the woman has her knees slightly bent
- Grasp the portion of the lower abdomen immediately above the symphysis pubis between thumb and middle finger (If the head is above the brim it will be readily movable and ballotable. If not movable, it is indicative of an engaged head).

Pelvic Palpation (Fourth Maneuver)

- Turn and face the woman's feet, make sure her knees are slightly bent
- Place your hands on the sides of the uterus, with the palm of your hands just below the level of umbilicus and your fingers directed towards the symphysis pubis
- Press deeply with your fingertips into the lower abdomen and move them towards the pelvic inlet
- The hands converge around the presenting part when the head is not engaged
- The hands will diverge away from the presenting part and there will be no give or mobility if the presenting part is engaged
- In order to ascertain the attitude, the occipital and sincipital prominences are located:
  - If the head is well flexed, the sinciput will be felt on the opposite side from the back and higher than the occiput
  - If the head is deflexed the prominences are on the same level
  - If the head is extended as in a face presentation, the bulk of the head is felt on the same side as the back.
- This maneuver helps ascertain the presenting part (by palpating the cephalic prominences); the attitude of the head (from the position of the sinciput and occiput) and engagement by noting whether there is convergence or divergence of the finger tips.

JAYPEE BROTHERS

Auscultation

- Place fetoscope or stethoscope over the convex portion of the fetal back closest to the anterior uterine wall (left scapular region) and listen to fetal heart sounds
- Inform the mother of your findings, make her comfortable

Location of the Maximum Intensity of Fetal Heart Tones

- **Cephalic presentation:** Midway between umbilicus and level of anterior superior iliac spine
- **Breech presentation:** At level with or above umbilicus
- **Transverse lie:** In lateral abdominal area
- **Anterior variety:** Close to the abdominal midline
- **Posterior variety:** In the flank area.

2. ABO INCOMPATIBILITY

The mother with blood group O has naturally occurring anti-A and anti-B antibodies. The antibodies are usually of immunoglobulin M (IgM) class and are too large to cross the placenta. However, some women produce antibodies of immunoglobulin G (IgG) class, which are smaller than IgM and can cross the placenta. Once in fetal circulation the IgG anti-A and anti-B antibodies attach to the red cells of fetuses with blood group A or B and cause variable amount of hemolysis due to antigen-antibody reaction. Although 20% of babies have ABO blood group incompatibility, only in 5%, hemolysis occurs and in affected babies jaundice appears within 24 hours. Both first and subsequent babies are at risk. The diagnosis is made only after birth and the baby is either blood group A or B, while the mother is group O.

The management of ABO isoimmunization depends on the severity of the hemolysis. In most cases, hemolysis is mild and no treatment is required. Adequate hydration is maintained and sepsis is avoided. Phototherapy may be required in few cases.

ABO incompatibility protects the fetus from rhesus incompatibility because the mother's anti-A and anti-B antibodies will destroy any fetal cells leaking into maternal circulation.

JAYPEE BROTHERS

3. ABNORMAL UTERINE ACTION

Any deviation of the normal pattern of uterine contractions affecting the course of labor is designated as abnormal or disordered uterine action.

ASSOCIATED CLINICAL CONDITIONS

- First pregnancy in older women
- Prolonged pregnancy
- Over distension of the uterus due to twins and/or hydramnios
- Contracted pelvis
- Malpresentation and deflexed head
- Full bladder and loaded rectum
- Injudicious administration of sedatives, analgesics and oxytocics
- Premature attempt at vaginal delivery or attempted instrumental delivery.

TYPES OF ABNORMAL UTERINE ACTION

- Excessive contraction:
  - Precipitate labor if no obstruction
  - Tonic uterine contraction and retraction ring (Bandl's ring) in presence of obstruction.
- Uterine inertia:
  - Spastic lower segment
  - Constriction ring
  - Generalized tonic contraction
  - Cervical dystocia.

Precipitate Labor

The total duration of labor is less than two hours. Rapid expulsion of fetus occurs due to hyperactive uterine contractions associated with diminished soft tissue resistance.

Risks

Maternal

- Excessive laceration of cervix, vagina and perineum
- Postpartum hemorrhage

JAYPEE BROTHERS

- Inversion of uterus
- Infection.

Fetal

- Intracranial hemorrhage
- Bleeding from torn cord
- Injury to skull and other hazards if delivery occurs in standing position.

Obstetrical Management

- Hospitalization prior to delivery of women with history of previous precipitate delivery
- Suppression of contraction during labor
- Elective induction of labor by low rupture of membranes
- Controlled delivery of head with liberal episiotomy.

Tonic Uterine Contraction and Retraction

Gradual increase in intensity, duration and frequency of uterine contraction occurs. The relaxation phase becomes less and less, leading to a state of tonic contraction. Retraction continues and lower segment elongates and becomes progressively thinner to accommodate the fetus. A circular groove encircling the uterus is formed between the active upper segment and the distended lower segment called the retraction ring or Bandl's ring.

Clinical Features

- Patient is restless from continuous pain and discomfort
- Features of exhaustion and ketoacidosis
- Hard, convex and tender, upper segment and distended, tender lower segment
- Pathological retraction ring felt obliquely between the umbilicus and symphysis pubis
- Fetal parts may not be well defined
- Fetal heart sound (FHS) usually is absent
- Dry, hot vagina with offensive discharge
- Cervix fully dilated and membranes absent.

JAYPEE BROTHERS

Obstetrical Management

Supportive therapy
- Morphine intramuscularly
- Intravenous (IV) infusion with 5% Dextrose and Ringers lactate
- Prophylactic antibiotic.

Definitive therapy
- Forceps or Ventouse delivery if the pelvic outlet is adequate
- Cesarean section if there is evidence of cephalopelvic disproportion (CPD).

Spastic Lower Segment

A state in which there is lack of fundal dominance, inadequate relaxation between contractions and raised basal tone of contractions.

Clinical Features

- Severe pain referred to the back with evidence of dehydration and ketoacidosis
- Distended bladder and stomach
- Premature attempts to bear down
- Uterus tense and tender even after contraction passes of
- Evidence of fetal distress
- Thick edematous cervix, which is not well applied to presenting part
- Inappropriate dilatation of cervix, absence of membranes and meconium stained liquor.

Obstetrical Management

- Correction of dehydration and ketoacidosis with IV infusion
- Sedation, nutrition by IV and careful watch of fetal condition
- Cesarean section in the presence of complicating factors such as contracted pelvis, malpresentation or maternal or fetal distress.

Constriction Ring

One form of incoordinate uterine action where there is localized spastic contraction of a ring of circular muscle fibers of the uterus.

JAYPEE BROTHERS

It is usually formed at the junction of the upper and lower segments around a constricted part of the fetus, usually around the neck in cephalic presentation. It is usually reversible and maternal condition is not much affected.

Associated factors for Occurrence

- Injudicious administration of oxytocics
- Premature rupture of membranes
- Premature attempt at instrumental delivery.

Diagnosis

Constriction ring may develop in all stages of labor. Failure of the presenting part to advance even with effective contractions with the cervix lying loose is suspicious.

It is diagnosed during cesarean section in the first stage, during forceps application in the second stage and during manual removal of placenta in the third stage.

Obstetrical Management

- **First stage:** The ring may have to be cut vertically during cesarean section to deliver the baby
- **Second stage:** Cesarean section, if the baby is in good condition Forceps delivery after administering medications to relax the ring, e.g. adrenaline hydrochloride and amyl nitrate inhalation alternatively
- **Third stage:** Manual removal of placenta under anesthesia.

Generalized Tonic Contraction (Uterine Tetany)

Pronounced retraction occurs involving whole of the uterus up to the internal os. There is no physiological differentiation of the active upper segment and the passive lower segment of the uterus. The uterine contraction ceases and the whole uterus undergoes tonic muscular spasm holding the fetus inside.

JAYPEE BROTHERS

Causes

- Injudicious administration of oxytocin
- Repeated unsuccessful attempt at artificial delivery
- Powerful contractions of the uterus in an attempt to overcome the obstruction.

Clinical Features

- Prolonged labor with severe and continuous pain
- Dehydration and ketoacidosis
- Uterus tense, tender and smaller in size
- Fetal parts not well-defined and FHS not audible
- Jammed fetal head with big caput
- Dry, edematous vagina.

Obstetrical Management

- Deep sedation
- Correction of dehydration and ketoacidosis
- Administration of antibiotics
- In active management spontaneous delivery after the abnormal action passes off, if no obstruction. In the presence of obstruction, destructive operation followed by exploration of uterus.

Cervical Dystocia

The normal pattern of uterine contraction is maintained, but the external os fails to dilate. Cervical dystocia is common during the first stage of labor.

Management

- Ventouse extraction
- Cesarean section if vaginal delivery is unsafe.

NURSING PROCESS

Assessment

- Obstetric history, note history of precipitous labor
- Nature of uterine contractions; duration, intensity and interval

JAYPEE BROTHERS

- Length of labor and status of membranes
- Fetal heart sounds
- Maternal health and psychological status
- Progress of labor as per vaginal examination.

Nursing Diagnosis

- Risk for maternal injury
- Risk for fetal injury
- Risk for deficient fluid volume
- Ineffective coping.

Expected Outcomes

The client will:

- Accomplish cervical dilation up to at least 1.2 cm/hour for primipara, 1.5 cm/hour for multipara in active phase, with fetal descent at least 1 cm/hour for primipara and 2 cm/hour for multipara
- Display fetal heart rate (FHR) within normal limits, with good variability and no decelerations noted
- Maintain fluid balance as evidenced by moist mucous membranes, appropriate urine output and palpable pulses
- Verbalize understanding of what is happening (identify and use) and effective coping techniques.

Nursing Interventions

1. **Accomplishing cervical dilation and fetal descend:**
   - Review history of labor, onset and duration
   - Note timing and type of medications. Avoid administration of narcotics or of epidural block anesthetics until cervix is 4 cm dilated
   - Assess uterine contractile pattern manually or electronically via external or internal monitor with internal uterine pressure catheter
   - Note condition of cervix. Monitor signs of amnionitis such as elevated temperature, white blood cell (WBC), odor and color of vaginal discharge

JAYPEE BROTHERS

- Note effacement, fetal station and fetal presentation
- Place client in lateral recumbent position and encourage bed rest or sitting position/ambulation, as tolerated
- Encourage client to void every 1 to 2 hours. Assess for bladder fullness over symphysis pubis
- Assess degree of hydration (note amount and type of intake)
- Review bowel habits and regularity of evacuation
- Remain with client if possible and provide quiet environment as indicated
- Have emergency delivery kit available when precipitate labor is suspected
- Palpate abdomen of thin client for presence of pathological retraction ring between segments
- Investigate reports of severe abdominal pain. Note signs of fetal distress, cessation of contractions and presence of vaginal bleeding
- Prepare client for amniotomy and assist with the procedure, when cervix is 3–4 cm dilated
- Initiate infusion of oxytocin (pitocin) or prostaglandins as ordered
- Administer narcotic or sedative as ordered
- Prepare for forceps delivery as necessary
- Assist with preparation for cesarean delivery as indicated.

2. **Maintaining fetal heart rate within normal limits:**
   - Assess FHR manually or electronically
   - Note uterine pressures during resting and contractile phases via intrauterine pressure catheter
   - Identify maternal factors such as dehydration, acidosis, anxiety or vena caval syndrome
   - Note frequency of uterine contractions. Notify physician if frequency is 2 minutes or less
   - Assess for fetal malpositioning, using Leopold's maneuvers and findings on internal examination. Review results of ultrasonography
   - Monitor fetal descent in birth canal in relation to ischial spines
   - Prepare client for the most expedient method of delivery if fetus is in brow or face presentation

JAYPEE BROTHERS

- Assess for deep transverse arrest of the fetal head
- Have client assume hands-and-knees position, or lateral Sim's position on side opposite that to which fetal occiput is directed, if fetus is in occiput posterior (OP) position
- Note color and amount of amniotic fluid when membranes rupture
- Observe for visible cord prolapse when membranes rupture, and occult cord prolapse as indicated by variable decelerations on monitor strip, especially if fetus is in breech presentation
- Note odor and change in color of amniotic fluid with prolonged rupture of membranes
- Administer antibiotic to client as indicated
- If fetus fails to rotate from OP to occiput anterior (OA) position, prepare for delivery in posterior position with vacuum extractor
- Prepare for cesarean delivery of breech presentation, if fetus fails to descend, labor progress ceases or CPD is identified.

3. **Maintaining fluid balance:**
   - Keep accurate record of intake and output, test urine for ketones and assess breath for fruity odor
   - Monitor vital signs. Note reports of dizziness with change of position
   - Assess lips and oral mucous membranes and degree of salivation
   - Note abnormal FHR response
   - Encourage oral fluids as appropriate
   - Review laboratory data, e.g. hemoglobin, hematocrit, serum electrolytes and serum glucose
   - Administer fluids intravenously.
4. **Improving coping behaviors:**
   - Determine progress of labor. Assess degree of pain in relation to dilation and effacement
   - Acknowledge reality of client's reports of pain/discomfort
   - Determine anxiety level of client and partner. Note manifestations of frustration
   - Provide comfort measures and reposition client, encourage ambulation as appropriate

JAYPEE BROTHERS

for detailed information on nursing books, visit our website www.jaypeebrothers.com, for detailed information o

Manual of
MIDWIFERY
and Gynecological
NURSING

Salient Features

- Fourth edition of the manual presents the topics of midwifery and gynecological nursing in brief form.
- The topics included in the book provide comprehensive coverage of the subjects–midwifery and gynecological nursing.
- Topic-wise arrangement of the content in alphabetic order serves for quick and easy-reference.
- Study questions of multiple choice type are included to serve students.
- The book is intended to be used as a handy reference and study material for nursing students, professional nurses and practicing midwifery.

Annamma Jacob MSc (N) did her BSc (N) in 1966 and MSc (N) in 1976 from Christian Medical College and Hospital, Vellore, Tamil Nadu, India. She has worked in various capacities as clinical practitioner, nurse educator, nurse manager and nursing college principal in India, Kuwait and the United States of America. Other books authored by her–'A Comprehensive Textbook of Midwifery and Gynecological Nursing', 'Maternal and Neonatal Nursing Care Plans', and 'Clinical Nursing Procedures: The Art of Nursing Practice' by the same publisher.

Printed in India

Available at all medical bookstores
or buy online at www.jaypeebrothers.com



JAYPEE BROTHERS
Medical Publishers (P) Ltd.
EMCA House, 23/23-B, Ansari Road,
Daryaganj, New Delhi - 110 002, INDIA
www.jaypeebrothers.com

Join us on facebook.com/JaypeeMedicalPublishers

