website www.jaypeebrothers.com, for detailed information on dermatology books, visit our website www.jaypeebrothers.com

Handbook and Atlas of Regional Clinical Dermatology in Indian Skin



Editor-in-Chief
DG Saple

Co-Editor
Swagata Tambe

Assistant Editors
Kirti Jangid
Vidya Kharkar
Sushrut Save
Resham Vasani

Forewords
Sarvajnamurthy Aradhya Sacchidanand
Rashmi Sarkar

JAYPEE

Contents

1. Face, Ear and Neck Dermatoses **1**
Swagata Tambe, Kirti Jangid, Kavita Ingle, DG Saple

Facial Skin **3**

Dermatoses of External Ear **85**

2. Disorders of Scalp and Hair **103**
Sushrut Save, DG Saple, Kirti Jangid, Swagata Tambe

3. Disorders of Oral Cavity **141**
Kirti Jangid, Swagata Tambe, DG Saple, Kopal Agrawal

4A. Dermatoses of Upper and Lower Extremity **175**
Sushrut Save, Swagata Tambe, Kirti Jangid, Anushka Rakesh

4B. Palmoplantar Dermatoses **243**
Swagata Tambe, Prachi Bodkhe, Surabhi Deshpande, Kirti Jangid

5. Dermatoses of Trunk **287**
Vidya Kharkar, Swagata Tambe, Kirti Jangid, Tejas Vishwanath

6. Dermatoses of Breast **349**
Kirti Jangid, Swagata Tambe, Kopal Agrawal, Anushka Rakesh

7A. Genital Dermatoses **365**
DG Saple, Swagata Tambe, Kirti Jangid, Nishant Rao

7B. Dermatoses of Perineal, Perianal, and Gluteal Region **419**
Vidya Kharkar, Swagata Tambe, Shreya Singh, Deepali Tarate

8. Flexural Dermatoses **443**
Swagata Tambe, Deepali Tarate, Prachi Bodkhe, Kirti Jangid

9. Nail Disorders **467**
Swagata Tambe, Kirti Jangid, Dhananjay Malage, Sushrut Save

10. Pregnancy Dermatoses **499**
Swagata Tambe, Dhananjay Malage, Kirti Jangid

11. Pediatric and Neonatal Dermatoses **511**
Resham Vasani, DG Saple, Kirti Jangid, Swagata Tambe

Index **553**

1

Face, Ear and Neck Dermatoses

Swagata Tambe, Kirti Jangid, Kavita Ingle, DG Saple

JAYPEE BROTHERS

FACIAL SKIN

Introduction

Facial skin is thinner than the rest of the body's skin. The facial dermis has more blood vessels than most other areas of the body. The dermis of the face contains a higher number of sebaceous glands, about 900 glands/cm^2 of skin. This makes facial skin more prone to develop acne- and related disorders. Facial sensory innervation is derived from branches of the trigeminal nerve, while muscles of the face are supplied by branches of the facial nerve.

Infections

- *Bacterial*: Impetigo, staphylococcal scalded skin syndrome, cellulitis, furuncle, folliculitis, cervicofacial actinomycosis, sycosis barbae, erysipelas, and gram-negative folliculitis
- *Fungal*: Tinea faciei and pityriasis versicolor
- *Viral*: Facial wart, verruca plana, epidermodysplasia verruciformis (EDV), filiform wart, herpes simplex, herpes zoster, and molluscum contagiosum (MC)
- *Parasitic*: Demodecidosis
- *Mycobacterial*: Tuberculosis [lupus vulgaris, scrofuloderma, and tuberculosis verrucosa cutis (TBVC)]
- *Leprosy*: Histoid Hansen's, hypopigmented, patches, type 1 lepra reaction, and saddle nose
- Atypical mycobacterial infection
- Syphilis
- *Subcutaneous and systemic fungal infections*: Cryptococcosis, histoplasmosis, penicilliosis, and rhinoentomophthoromycosis

Connective Tissue Disorders

- Lupus erythematosus (LE)
- Dermatomyositis (DM)
- Scleroderma
- Lichen sclerosus

Noninfectious Granuloma

- Sarcoidosis
- Granuloma annulare
- Granuloma faciale
- Actinic granuloma (AG)

Inflammatory Skin Disease

- Polymorphous light eruption (PMLE)
- Photoallergic dermatitis
- Chronic actinic dermatitis (CAD)
- Pellagra
- Parthenium dermatitis
- Photoaging
- Irritant contact dermatitis (ICD)
- Retinoid dermatitis
- Atopic dermatitis
- Seborrheic dermatitis
- Psoriasis
- Pityriasis rubra pilaris
- Lichen planus
- Drug reactions

Acne and Related Disorders

- Acne vulgaris
- Rosacea
- Periorificial dermatitis
- Lupus miliaris disseminatus faciei (LMDF)
- Acneiform eruption

JAYPEE BROTHERS

Vesiculobullous Disorders
- Pemphigus vulgaris (PV)
- Pemphigus foliaceus (PF)
- Epidermolysis bullosa acquisita

Disorders of Hypopigmentation
- Pityriasis alba
- Pityriasis versicolor
- Segmental vitiligo
- Focal vitiligo
- PMLE
- Postinflammatory hypopigmentation and depigmentation

Nevi
- Nevus of Ota
- Hori's nevus
- Bule nevus
- Compound nevi
- Junctional nevi
- Intradermal nevi
- Nevus depigmentosus
- Congenital melanocytic nevus (CMN)
- Port-wine stain
- Hemangioma

Benign Skin Tumors
- Seborrheic keratosis and dermatosis papulosa nigra (DPN)
- Syringoma
- Hidrocystoma
- Acrochordons
- Angiokeratoma
- Colloid milium
- Sebaceous hyperplasia
- Angiofibromas
- Trichoepithelioma
- Neurofibroma
- Spiradenoma
- Clear cell carcinoma

Disorders of Hyperpigmentation
- Lichen planus pigmentosus
- Melasma
- Postinflammatory hyperpigmentation
- Erythema dyschromicum perstans (EDP)
- Riehl's melanosis
- Periorbital hypermelanosis
- Pigmentary demarcation lines (PDL)
- Exogenous ochronosis (EO)
- Post-chikungunya hyperpigmentation
- Acanthosis nigricans
- Addisonian hyperpigmentation
- Familial progressive hyperpigmentation
- Freckles
- Lentigines
- Café-au-lait macules (CALMs)

Malignant Growths
- Basal cell carcinoma (BCC)
- Squamous cell carcinoma
- Malignant melanoma
- Spiradenocarcinoma
- Merkel cell carcinoma
- Mucinous eccrine carcinoma
- Bowen's disease
- Cutaneous T-cell lymphoma (CTCL)

Genodermatoses
- Xeroderma pigmentosum (XP)
- Porokeratosis
- Ectodermal dysplasia
- Pachyonychia congenita
- Ichthyosis

JAYPEE BROTHERS

Impetigo



Figures 1A and B: (A) Multiple erosions showing honey-colored crust; and (B) Closer view of erosions showing honey-colored crust over the face.

Impetigo is a bacterial infection of children caused by *Staphylococcus aureus* and group A *Streptococcus*. Nonbullous type usually presents as a small vesicle or pustule, which progresses to erosion covered with a honey-colored crust **(Figures 1A and B)**. Lesions heal without scarring. Extensive involvement may resemble staphylococcal scalded skin syndrome or PF. Bullous impetigo is characterized by painless flaccid bullae and moist erosions with surrounding erythema **(Figure 1B)**. Occasionally, the bullae spread peripherally with central clearing and annular lesions (impetigo circinata).

Treatment: Topical antibiotics such as mupirocin and fusidic acid are sufficient to treat mild cases while severe cases need systemic antistaphylococcal antibiotics.

Ecthyma



Figure 2: Gray black eschar covering an ulcerative lesion with surrounding erythema.

Bacterial infections caused by Group A streptococci, such as *Streptococcus pyogenes*, *Pseudomonas aeruginosa*, and *S. aureus*. Initially, there are small bullae and pustules over the erythematous base which dry up to form a hard chocolate-colored eschar **(Figure 2)**. Removal of the crust reveals an irregular ulcer. The wound heals with scarring.

Differential diagnosis: Ecthyma gangrenosum, pyoderma gangrenosum, and tick bites

Treatment: It includes broad-spectrum oral antibiotics active against *S. pyogenes*, *S. aureus*, and *Pseudomonas*. Removal of necrotic infected adherent eschar should be done after soaking with a disinfectant and softening with an oily cream. Topical antibiotics should be applied twice daily.

JAYPEE BROTHERS

Furuncle

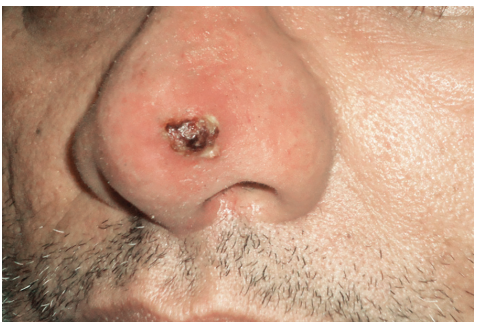

Figure 3: Single inflammatory nodule with a central necrotic core on the nose.

A furuncle is an acute infection of hair follicles caused by *S. aureus*. Predisposing factors include poor hygiene, malnutrition, human immunodeficiency virus (HIV), diabetes mellitus or intake of steroids, and retinoid therapy. It usually presents as single or multiple tender small, follicular, inflammatory nodules that soon become pustular, and then a central necrotic core discharges pus **(Figure 3)**. It heals with a pigmented macule or a permanent scar. Common sites include the face and neck. Furuncles on the upper lip and cheek may lead to cavernous sinus thrombosis.

When there are three or more episodes of furunculosis within a year, it is called *recurrent furunculosis*. It can be caused by colonization of *S. aureus* in anterior nares, postauricular skin folds, inframammary and groin region: ***Recurrent furunculosis can be seen in cases of immunosuppression, diabetes, poor hygiene, anaemia, obesity, and atopic dermatitis***.

Treatment: Usually, it improves with oral and topical antistaphylococcal antibiotics. Some patients may need incisions and drainage.

Erysipelas



Figure 4: Erythematous, indurated plaque (peau d'orange appearance) with sharply demarcated margin on the face.

Erysipelas and cellulitis are bacterial infections of the dermis and subcutaneous tissue caused by *Group A streptococci* and are usually seen in adults. Malnutrition and diabetes mellitus are common predisposing factors.

Clinical presentation: It is a rapidly spreading tense, erythematous, indurated plaque (peau d'orange appearance) with sharply demarcated margins in patients of erysipelas while in cellulitis margins may not be apparent due to the involvement of deeper subcutaneous tissue **(Figure 4)**. Blistering is common, and there may be superficial hemorrhage in the blisters of elderly people. The face is one of the commonly affected sites. ***Constitutional symptoms such as fever, chills, and malaise are seen except in mild cases.*** Recurrent episodes may lead to lymphatic damage leading to chronic lymphedema of the affected site. Rarely necrotizing fasciitis may develop.

Treatment: Broad-spectrum systemic antibiotics and anti-inflammatory agents are the drugs of choice. ***In the author's experience, a short course of oral steroids is very useful in preventing permanent lymphatic damage.***

JAYPEE BROTHERS

Staphylococcal Scalded Skin Syndrome (Ritter Disease)



Figure 5: Erosions, crusting and peeling of skin over the periocular, perinasal and perioral areas of face with sparing of oral mucosa.

Staphylococcal scalded skin syndrome (SSSS) (Ritter disease) is caused by *S. aureus* in children (under the age of 6 years) and neonates. It presents as exfoliative dermatitis, characterized by tenderness, erythema, and peeling of superficial epidermis affecting most of the body surface area. Painful erosions are seen after erythematous sheets of skin shrink and fall (potato-chip desquamation) **(Figure 5)**. The initial site of involvement usually is the face and proximal flexures, but soon the process generalizes. Involvement of the face, especially of the paranasal and perioral areas produces distinctive facies. ***Nikolsky sign is positive.*** Cutaneous eruptions may follow an upper respiratory tract infection or purulent conjunctivitis. Mucous membranes except lips are spared.

Prognosis: Prognosis is good in children and the mortality rate is only 2–3%. It should be differentiated from toxic epidermal necrolysis (demonstration of bacteria in a detached skin in SSSS may be helpful in differentiating).

Treatment: It includes parenteral administration of antistaphylococcal antibiotics and maintaining fluid and electrolyte balance.

Scarlet Fever

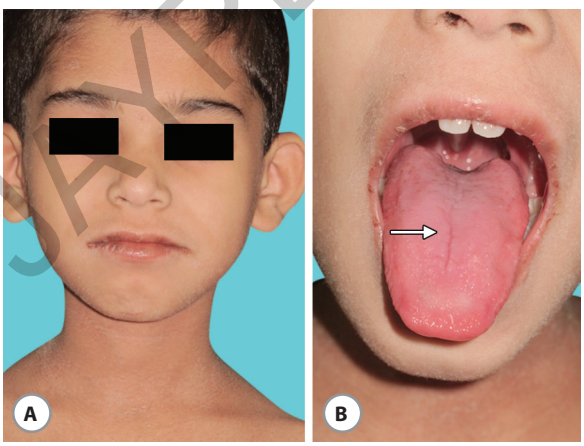

Figures 6A and B: (A) Diffuse maculopapular rash with fine scaling on face; and (B) Red strawberry tongue.

Scarlet fever is a disease of young children (age group of 5 and 15 years). It has been associated with rheumatic fever, poststreptococcal glomerulonephritis, and osteomyelitis. It is caused by *S. pyogenes* producing pyrogenic exotoxin. Cutaneous presentation includes

JAYPEE BROTHERS

a fine punctuate erythema referred to as "sunburn with goose pimples" seen first on the upper trunk. Characteristically, the face is flushed with relative pallor around the mouth **(Figure 6A)**. ***The rash disappears by 7–10th day with desquamation on the palms and soles.*** Tongue may become dark red referred to as "red strawberry tongue" **(Figure 6B)**. Associated constitutional symptoms include fever, anorexia, and acute follicular or membranous tonsillitis, with painful lymphadenopathy.

Conditions such as Kawasaki disease, viral exanthem, and maculopapular drug reactions should be ruled out. Differentiating features of viral exanthem and drug reactions are enlisted in **Table 1**.

Treatment includes penicillin or amoxicillin, a first-generation cephalosporin, clindamycin, or erythromycin.

TABLE 1: Difference between viral exanthem and drug rash.

Parameter	Viral exanthem	Drug reaction
Age	Common in young	Common in elderly
Associated fever	Common	Uncommon
Pruritus	Mild or absent	Moderate or severe
Drug history	May be absent	Present
Evolution of rash	Cephalocaudal	Begins on trunk
Constitutional signs and symptoms	Common	Less common
Enanthem	Common	Less common
Lymphadenopathy	Common	Less common
Blood counts	Lymphocytosis	Eosinophilia
Skin biopsy	Sparse lymphocytic infiltrate and vacuolar change	Parakeratosis, moderate infiltrate of lymphocytes and eosinophils, necrotic keratinocytes, and spongiosis
Dissolution	Subsides spontaneously in 3–5 days	Subsides in 1–2 weeks after discontinuation of the offending drug

Note: Scarlet fever can be differentiated from viral exanthem and drug reaction by the presence of tonsillitis, strawberry tongue, and raised antistreptolysin O (ASO) titer.

JAYPEE BROTHERS

Sycosis Barbae



Figure 7: Multiple erythematous follicular papules and pustules centered by the hair on the beard region.

This condition is usually seen in young males. Clinically, it is characterized by an erythematous follicular papule or pustule centered by a hair **(Figure 7)**. Plaques may be formed by coalescing papules or they may remain discrete. Appearance of similar lesions over the nape of neck, is called as *sycosis nuchae*. A variant of deep folliculitis associated with the destruction of the hair follicles and atrophic scarring is known as lupoid sycosis.

Differential diagnosis: Tinea barbae [potassium hydroxide (KOH) preparation]

Treatment: Topical and systemic antistaphylococcal antibiotics. As the condition is recurrent oral doxycycline or cotrimoxazole can be considered on a long-term basis.

Gram-negative Folliculitis



Figure 8: Erythematous papulopustular lesions over face.

Gram-negative folliculitis is usually seen after long-term antibacterial treatment in acne and rosacea patients. The causative factor is a replacement of gram-positive bacteria on the face and mucous membrane of the nose by gram-negative bacteria, such as *Escherichia coli*, *P. aeruginosa*, *Serratia marcescens*, *Klebsiella*, and *Proteus*. Clinically it presents as erythematous papulopustular lesions over the central area of the face, around the lip, under the nose, chin, and cheeks **(Figure 8)**. It is often mistaken as a worsening of acne and or poor response to usual antiacne antibiotics.

Treatment: Treatment of choice is isotretinoin (0.5–1 mg/kg daily for 4–5 months).

JAYPEE BROTHERS

Cervicofacial Actinomycosis



Figure 9: Indurated plaque studded with multiple nodules, sinuses, and fistulas over the jaw and surrounding cheek.

Cervicofacial actinomycosis is an *invasive destructive infectious* disease, caused by gram-positive, branching filamentous bacteria, *Actinomyces*. Most of the cases are traced to an odontogenic source with periapical abscess and post-traumatic or surgical complications with poor hygiene and immunosuppression as contributing factors. It manifests clinically as an acute pyogenic infection with a tender, fluctuant mass with trismus, firm swelling, and fistulas with drainage containing the characteristic sulfur granules **(Figure 9)**. Bone is not involved early in the disease, but periostitis, mandibular osteomyelitis, or perimandibular abscess may develop. Infection may spread through sinus tracts to the cranial bones.

Diagnosis: It can be established by the culture of specimens, such as incisional biopsies. Imaging techniques help in identifying the extent of involvement.

Treatment: It includes 3–6 weeks of oral antibiotic therapy, combined with surgical drainage. The addition of sulfonamides can be considered in case of slow response to therapy.

Tinea Faciei



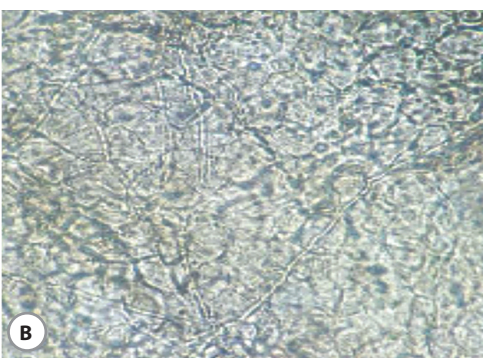

Figures 10A and B: (A) Erythematous annular scaly plaque with active border and central clearing over midface; and (B) Potassium hydroxide mount shows the presence of fungal hyphae.

Tinea faciei is a superficial dermatophyte infection limited to the glabrous skin of the face. It affects any surface of the face in women and pediatric groups. In men, the condition is known as tinea barbae when a dermatophyte infection of bearded areas occurs. Clinically presents as erythematous or hyperpigmented annular scaly patches with active border with

JAYPEE BROTHERS

central clearing **(Figure 10A)**. Inadvertent and chronic use of topical steroids can lead to topical steroid-damaged face (TSDF) in Indian patients. Diagnosis is usually clinical but in patients of modified tinea KOH mount **(Figure 10B)** may show the presence of fungal hyphae.

Treatment: It includes oral and topical antifungal agents and oral antihistamines.

Pityriasis Versicolor



Figure 11: Multiple hypopigmented macules covered with branny scales on the face.

It is a mild chronic superficial fungal infection of the stratum corneum caused by *Malassezia furfur* or pityrosporum. It usually presents as hypopigmented, hyperpigmented, or erythematous macules coalescing to form large patches on the face, neck, trunk upper extremities. Macules are covered with branny scales which can be made more prominent by stroking the skin (scratch sign) **(Figure 11)**. Wood's lamp examination shows yellowish fluorescence on the lesions.

Treatment: It includes topical antifungal agents. In extensive cases, oral fluconazole or ketoconazole (in adults) can be considered.

The patient should be counseled that repigmentation takes prolonged time even after resolution of infection.

Facial Warts

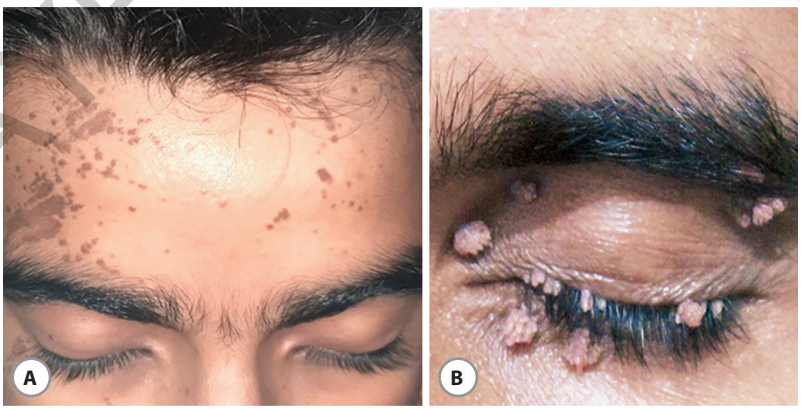

Figures 12A and B: (A) Multiple flat-topped papules on the forehead; and (B) Slender, soft, thin finger-like growths around the eye.

Continued

JAYPEE BROTHERS

Continued



Figure 12C: (C) Slender, soft, thin finger-like growths around the mouth.

They are mostly associated with human papillomaviruses (HPVs) 3, 10, and 28. Verruca plana presents as flat topped papules **(Figure 12A)**. A linear arrangement of the lesions (pseudo-koebner phenomenon) due to autoinoculation is a characteristic feature.

Filiform wart: Slender, soft, thin finger-like growths **(Figures 12B and C)**, mainly seen on the face and neck

Treatment: It includes topical keratolytic, and physical methods of wart removal such as ablation with carbon dioxide laser, radiofrequency, and electrofulguration. Topical and oral retinoids are commonly used in the treatment of verruca plana. Oral isotretinoin 10 mg or cap acitretin 10 mg daily for 3–6 months helps to prevent recurrence.

Epidermodysplasia Verruciformis



Figure 13: Multiple hypopigmented scaly macules on the neck resembling pityriasis versicolor.

Courtesy: Dr Chitra Nayak, Department of Dermatology, TNMC and BYL Nair Hospital, Mumbai.

Epidermodysplasia verruciformis is seen in genetically predisposed or in immunosuppressed patients. It is associated with >30 HPVs, more commonly with HPVs 3, 5, 8, 9, 10, 12, 14, 15, 17, and 19–25. ***Clinically it may resemble pityriasis versicolor, verruca plana or pityriasis rosea*** **(Figure 13)**. Non-melanoma skin cancers like squamous cell carcinoma may develop in untreated and long standing lesions.

Treatment: Treatment modalities include acitretin and imiquimod, interferons, and topical calcipotriol. Frequent follow-up is required to evaluate for the risk of malignancy.

JAYPEE BROTHERS

Molluscum Contagiosum



Figures 14A to C: (A) Dome-shaped, pearly white, shiny umbilicated papules on the face; (B) Dome-shaped, pearly white, shiny umbilicated papules around the mouth; and (C) Multiple and giant lesions of molluscum on the face in an immunocompromised male.

Molluscum contagiosum (MC) is caused by a DNA virus belonging to the pox family. MC is a self-limiting disease characterized by dome-shaped, pearly white, shiny umbilicated papules distributed on the face, neck, cheek, and extremities in children **(Figures 14A and B)**. Periorbital lesions are also common in children. "Immunocompromised patients (immunodeficiency syndromes in children and HIV infections in adults) may show ***multiple and giant lesions*** of molluscum **(Figure 14C)**".

Treatment: Needling and curettage. Topical imiquimod, topical tretinoin. In HIV-positive patients, initiation of antiretroviral therapy is also helpful. Local application of potassium hydroxide solution may be used in pediatric patients.

JAYPEE BROTHERS

for detailed information on dermatology books, visit our website www.jaypeebrothers.com, for detailed information on derma

Handbook and Atlas of Regional Clinical Dermatology in Indian Skin

Salient Features

- Skin does not have a uniform composition throughout the body.
- The site determines the structure and function of the skin at that particular site.
- Different skin characteristics at different body sites may affect the skin's susceptibility to developing certain diseases.
- Also, there are variable presentations of the same dermatological diseases in different body areas.
- This handbook and atlas introduces readers to a unique concept of regional clinical dermatology, which deals with dermatological diseases appearing on particular body areas and their management aspects.
- This handbook would thus serve as a quick, handy reference guide for both practising dermatologists and postgraduate students for routine OPD practice and bedside diagnosis without resorting to the use of heavy textbooks.
- It exclusively deals with high-quality clinical, dermoscopic, and histopathological images involving Indian skin.

DG Saple MD FCPS
Fellow of Johns Hopkins University, Bloomberg, USA
Former Head, Department of Dermatology, Venereology and Leprology at Grant Medical College and JJ Group of Hospitals, Mumbai
Consultant in Dermato-Venereology, Leprology and HIV/AIDS at Breach Candy Hospital and SL Raheja Hospital, Mumbai
Ex-President of IADVL (Maharashtra Branch)
Ex-President of College of Physicians and Surgeons, Mumbai
Consultant in Dermatology, Cosmetology and Trichology
La'Mer Clinic – Center for Dermatology and Cosmetology
Mumbai (Dadar), Maharashtra, India



Swagata Tambe
MD DNB FCPS DDV (Dermatology)
Head and Senior Consultant, Department of Dermatology
Seth VC Gandhi and MA Vora Municipal General Hospital,
Rajawadi Ghatkopar East, Mumbai, Maharashtra, India



Printed in India

Available at all medical bookstores or buy online at www.ejaypee.com

JAYPEE BROTHERS
Medical Publishers (P) Ltd.
EMCA House, 23/23-B, Ansari Road,
Daryaganj, New Delhi - 110 002, INDIA
www.jaypeebrothers.com

Join us on facebook.com/JaypeeMedicalPublishers
Follow us on instagram.com/JaypeeMedicalPublishers

Shelving Recommendation
DERMATOLOGY

ISBN 978-93-5696-174-6