rmation on orthopaedics books, visit our website www.jaypeebrothers.com, for detailed information on orthopaedics books, visit our website www.jaypeebrothers.co

Free! Complementary Online Access to
Musculoskeletal Examination for Undergraduates

Scan to Download the App

diginerve
A Jaypee Initiative
Your Guide at Every Step
Video Lectures | Notes | Self-Assessment



2nd Edition

*As per the Competency Based Medical Education Curriculum (NMC)*

# MANIPAL MANUAL OF ORTHOPAEDICS

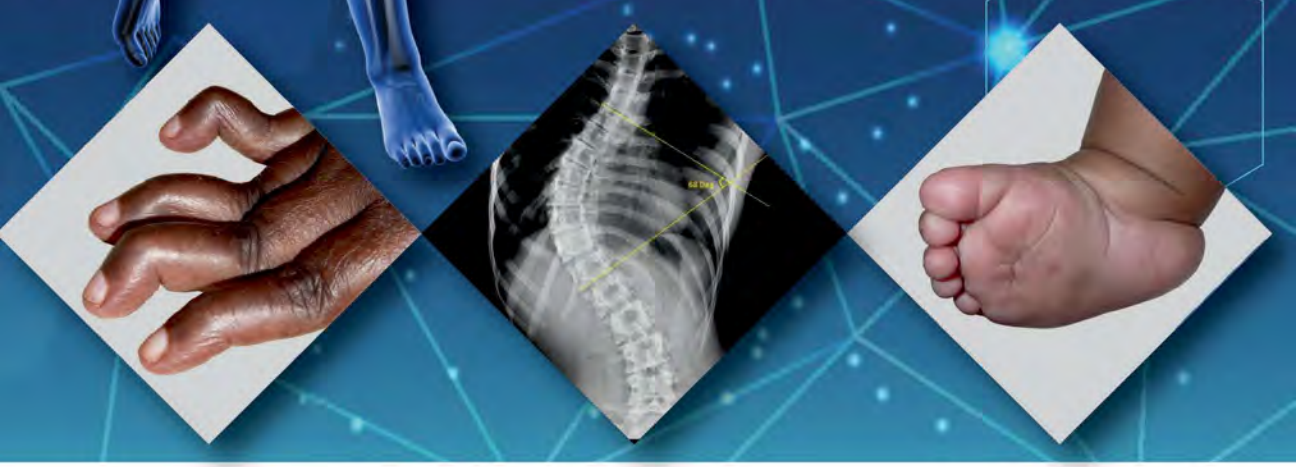

**Vivek Pandey**

*Foreword*
**P Sripathi Rao**

JAYPEE

# Contents


| Chapter No. | Chapter Name | Competency No. | Page No. |
|---|---|---|---|
| | ***Section 1: Skeletal Trauma and Polytrauma*** | | |
| 1. | **Principles of Triage**<br>• A Note on Geriatric Triaging *10* | OR1.1 | **3** |
| 2. | **Shock and its Management** | OR1.2 | **13** |
| 3. | **Soft Tissue Injuries–Part 1** | OR1.3 | **19** |
| 4. | **Soft Tissue Injuries–Part 2** | OR1.4 | **24** |
| 5. | **Dislocation of Major Joints**<br>• Introduction to Dislocations *28*<br>• Dislocations around the Shoulder *33*<br>• Acute Anterior Dislocation of the Shoulder Joint *34*<br>• Recurrent Anterior Dislocation of Shoulder *37*<br>• Posterior Dislocation of the Shoulder Joint *39*<br>• Acromioclavicular Joint Dislocation *41*<br>• Elbow Dislocations *44*<br>• Common Dislocations around the Wrist *46*<br>• Hip Dislocation *47*<br>• Posterior Dislocation of the Hip Joint *48*<br>• Anterior Dislocation of Hip Joint *51*<br>• Central Fracture Dislocation of the Hip *52*<br>• Dislocation around the Knee *53*<br>• Knee Dislocation *53*<br>• Patella Dislocation *55* | OR1.5 | **28** |
| | ***Section 2: Fractures and Ligament Injuries*** | | |
| 6. | **Basics of Orthopaedics** | OR2.01 | **61** |
| 7. | **Introduction to Fractures** | OR2.02 | **69** |
| 8. | **Fracture in Children and Physeal Injuries**<br>• Peculiarities of Bone and Fractures in Children *83*<br>• Physeal Injuries *83* | OR2.03 | **83** |
| 9. | **Fracture Clavicle**<br>• Fracture Clavicle Mid-Shaft *88*<br>• Lateral Third Clavicle Fracture *90*<br>• Medial Third Clavicle Fracture *91* | OR2.1 | **87** |
| 10. | **Fractures around the Shoulder**<br>• Fracture Proximal Humerus *92*<br>• Fracture Greater Tuberosity of the Humerus *96*<br>• Fracture Scapula *97* | OR2.2 | **92** |
| 11. | **Relief of Joint Pain**<br>• Pathogenesis of Joint Pain *99* | OR2.3 | **99** |

| Chapter No. | Chapter Name | Competency No. | Page No. |
|---|---|---|---|
| 12. | **Fracture Shaft Humerus, Supracondylar Humerus and Other Fractures around Elbow**<br>• Fracture Shaft Humerus *103*<br>• Fracture Supracondylar Humerus *106*<br>• Intercondylar Fracture of Humerus *115*<br>• Lateral Condyle Fracture *117*<br>• Fracture Olecranon *119*<br>• Radial Head Fracture *121*<br>• Pulled Elbow (Nursemaid Elbow) *122* | OR2.4 | **103** |
| 13. | **Fracture of Forearm Bone, Galeazzi and Monteggia Fracture**<br>• Fracture of Radius Ulna Shaft *124*<br>• Monteggia Fracture Dislocation *126*<br>• Galeazzi Fracture Dislocation (Piedmont's Fracture) *128* | OR2.5 | **124** |
| 14. | **Fractures around the Wrist and Hand**<br>• Colles' Fracture *131*<br>• Smith's Fracture (Reverse Colles') *135*<br>• Barton Fracture *136*<br>• Chauffeur's Fracture/Hutchinson Fracture/Backfire Fracture *137*<br>• Scaphoid Fracture *138*<br>• Metacarpal and Phalangeal Fractures *140* | OR2.6 | **131** |
| 15. | **Fracture Pelvis** | OR2.7 | **143** |
| 16. | **Injuries of the Spine and Spinal Cord**<br>• Acute Spinal Cord Injury *155*<br>• Urinary Bladder Innervation, Function and Dysfunction *159*<br>• Spine/Vertebral Injuries *162*<br>• Specific Fractures of the Spine *169* | OR2.8 | **150** |
| 17. | **Fracture Acetabulum** | OR2.9 | **173** |
| 18. | **Fracture Femur Neck and Intertrochanteric Femur**<br>• Fracture Femur Neck *177*<br>• Fracture Intertrochantric Femur *184* | OR2.10 | **177** |
| 19. | **Fracture around Knee—Patella, Distal Femur and Proximal Tibia**<br>• Fracture Patella *187*<br>• Distal Femur Fracture *191*<br>• Tibial Plateau Fracture *193* | OR2.11 | **187** |
| 20. | **Fracture Shaft Femur and Subtrochanteric Femur**<br>• Fracture Shaft Femur *197*<br>• Fracture Subtrochanteric Femur *200* | OR2.12 | **197** |
| 21. | **Fractures of Both Bone Leg, Tibial Plafond, Calcaneum and Small Bones of Foot**<br>• Fractures of Shaft Tibia Fibula *201*<br>• Fracture Fibula *203*<br>• Fractures of Tibial Plafond/Pilon *204*<br>• Fracture of Calcaneum *206*<br>• Fracture of Talus *210*<br>• Lisfranc's Injury (Tarsometatarsal Dislocation) *212*<br>• Fracture of Metatarsals *214* | OR2.13 | **201** |

| Chapter No. | Chapter Name | Competency No. | Page No. |
|---|---|---|---|
| 22. | **Fracture of the Ankle**<br>• Pott's/Bimalleolar Fracture *217* | OR2.14 | **217** |
| 23. | **Complications of Fracture**<br>• Volkmann's Ischemia (Compartment Syndrome) *222*<br>• Fat Embolism Syndrome (FES) *225*<br>• Injury to Major Blood Vessels *229*<br>• Deep Vein Thrombosis (DVT) *230*<br>• Pulmonary Thromboembolism (PTE) *231*<br>• Myositis Ossificans (MO) *232*<br>• Nonunion of Fracture *238*<br>• Delayed Union *241*<br>• Malunion *242*<br>• Joint Stiffness *244*<br>• Limb Shortening *245* | OR2.15 | **221** |
| 24. | **Open Fracture** | OR2.16 | **248** |
| 25. | **Ligament Injury of Knee, Ankle and Other Sports Injuries**<br>• General Description of Ligament Injury *255*<br>• Ligament and Meniscal Injury of the Knee *257*<br>• Anterior Cruciate Ligament (ACL) Tear *257*<br>• Posterior Cruciate Ligament (PCL) Tear *261*<br>• Meniscal Injuries *263*<br>• Collateral Ligaments of the Knee *266*<br>• Ankle Ligament Injury/Sprain *269*<br>• Miscellaneous Sports Injuries *271* | OR2.17 | **255** |
| | ***Section 3: Musculoskeletal Infection*** | | |
| 26. | **Osteomyelitis**<br>• Osteomyelitis *279*<br>• Acute Bacterial (Pyogenic) Osteomyelitis *280*<br>• Chronic Osteomyelitis *287*<br>• Brodie's Abscess and Garre's Sclerosing Osteomyelitis *293* | OR3.1 | **279** |
| 27. | **Septic Arthritis**<br>• Septic Arthritis *295*<br>• Tom Smith Arthritis *300* | OR3.1 | **295** |
| 28. | **HIV Infections and Orthopaedics** | OR3.1 | **301** |
| 29. | **Spirochetal Infections of Bones and Joints** | OR3.1 | **304** |
| | ***Section 4: Mycobacterial Musculoskelatal Infections*** | | |
| 30. | **Skeletal Tuberculosis**<br>• Tuberculosis of the Hip Joint *312*<br>• Tuberculosis of the Knee Joint *318*<br>• Tuberculosis of the Spine *320*<br>• Tuberculosis of Shoulder *327*<br>• Tubercular Osteomyelitis *327*<br>• Hansen's Disease *327* | OR3.1, OR4.1 | **309** |

| Chapter No. | Chapter Name | Competency No. | Page No. |
|---|---|---|---|
| | ***Section 5: Arthritis*** | | |
| **31.** | **Overview of Arthritis, Osteoarthrosis Knee**<br>• Osteoarthritis/Osteoarthrosis *335*<br>• Primary Degenerative Osteoarthrosis of the Knee *338* | OR5.1 | **333** |
| **32.** | **Rheumatoid Arthritis** | OR5.1 | **343** |
| **33.** | **Seronegative Arthritis and Other Arthritis**<br>• Psoriatic Arthritis *357*<br>• Reactive Arthritis/Reiter's Syndrome *359*<br>• Enteropathic Arthritis *361*<br>• Crystalline Arthritis: Gout *362*<br>• Crystalline Arthritis: Pseudogout *365*<br>• Neuropathic/Charcot's Arthropathy *367*<br>• Miscellaneous Arthritis *370* | OR5.1 | **352** |
| | ***Section 6: Degenerative Conditions of the Spine*** | | |
| **34.** | **Approach to Neck and Low Back Pain**<br>• Intervertebral Disc Prolapse (IVDP) *377*<br>• Cauda Equina Syndrome (CES) *387*<br>• Conus Medullaris Syndrome (CMS) *388*<br>• Spondylosis *388*<br>• Spondylolysis and Spondylolisthesis *390*<br>• Lumbar Canal Stenosis *393* | OR6.1 | **377** |
| | ***Section 7: Metabolic Diseases of the Bone*** | | |
| **35.** | **Metabolic Diseases of the Bone**<br>• Brief Review of Role of Calcium, Phosphorus, Magnesium, Vitamin D and their Regulations *399*<br>• Rickets *400*<br>• Osteomalacia *408*<br>• Osteoporosis *410*<br>• Osteosclerosis Disorders *416*<br>• Osteopetrosis/Albers-Schönberg Disease/Marble Bone Disease *416*<br>• Paget's Disease/Osteitis Deformans *418*<br>• Fluorosis *421*<br>• Hyperparathyroidism *423*<br>• Scurvy *426* | OR7.1 | **399** |
| | ***Section 8: Neuromuscular Disorders*** | | |
| **36.** | **Neuromuscular Disorders**<br>• Poliomyelitis *431*<br>• Myopathies *433*<br>• Duchenne Muscular Dystrophy *434* | OR8.1 | **431** |

| Chapter No. | Chapter Name | Competency No. | Page No. |
|---|---|---|---|
| | ***Section 9: Cerebral Palsy*** | | |
| **37.** | **Cerebral Palsy** | OR9.1 | **439** |
| | ***Section 10: Bone Tumors*** | | |
| **38.** | **Basics of Bone Tumors** | OR10.1 | **447** |
| **39.** | **Benign Bone Tumors and Tumor-like Lesions**<br>• Osteochondroma (Solitary Exostosis) *456*<br>• Multiple Exostoses/Diaphyseal Aclasis/Hereditary Multiple Exostosis *458*<br>• Unicameral Bone Cyst/Simple Bone Cyst *459*<br>• Aneurysmal Bone Cyst (ABC) *460*<br>• Fibrous Dysplasia *461*<br>• Osteoid Osteoma *463*<br>• Osteoma *465*<br>• Giant Cell Tumor of Bone (GCTB) *465*<br>• Enchondroma (Chondroma) *468*<br>• Chondroblastoma/Codman's Tumor *469* | OR10.1 | **456** |
| **40.** | **Malignant Bone Tumors**<br>• Osteosarcoma *470*<br>• Ewing's Sarcoma *473*<br>• Multiple Myeloma/Kahler's Disease *475*<br>• Chondrosarcoma *477* | OR10.1 | **470** |
| | ***Section 11: Peripheral Nerve and Brachial Plexus Injuries*** | | |
| **41.** | **Approach to Peripheral Nerve Injuries** | OR11.1 | **481** |
| **42.** | **Specific Nerve Injuries**<br>• Common Nerve Injuries *494* | OR11.1 | **494** |
| **43.** | **Brachial Plexus Injury** | OR11.1 | **512** |
| | ***Section 12: Congenital and Other Pediatric Disorders*** | | |
| **44.** | **Congenital and Other Pediatric Disorders**<br>• Congenital Talipes Equinus Varus (CTEV) *521*<br>• Congenital Vertical Talus *530*<br>• Developmental Dysplasia of Hip *531*<br>• Multiple Congenital Contractures *539*<br>• Coxa Vara *540*<br>• Slipped Capital Femoral Epiphysis (SCFE) *541*<br>• Perthes' Disease and Other Osteochondrosis *544*<br>• Perthes' Disease (Legg-Calve-Perthes Disease) *545*<br>• Flat Foot/Pes Planus *551*<br>• Pes Cavus *554*<br>• Spina Bifida *554*<br>• Skeletal Dysplasias *557*<br>• Congenital Pseudoarthrosis of Tibia (CPT) *561*<br>• Congenital Knee Dislocation *562* | OR12.1 | **521** |

| Chapter No. | Chapter Name | Competency No. | Page No. |
|---|---|---|---|
| | ***Section 13: Regional Conditions*** | | |
| **45.** | **Upper Limb Disorders**<br>• Frozen Shoulder *565*<br>• Rotator Cuff Tendinopathy/Tendinitis *567*<br>• Acute Calcific Rotator Cuff Tendinitis *568*<br>• Rotator Cuff Tear *569*<br>• Painful Arc Syndrome *571*<br>• Tennis Elbow (Lateral Epicondylitis) *572*<br>• Golfer's Elbow (Medial Epicondylitis) *574*<br>• De Quervain's Tenosynovitis *575*<br>• Carpal Tunnel Syndrome *576*<br>• Dupuytren's Contracture *578*<br>• Ganglion *579*<br>• Compound Palmar Ganglion *581*<br>• Trigger Finger *581* | — | **565** |
| **46.** | **Spine and Lower Limb Disorders**<br>• Torticollis *583*<br>• Congenital Torticollis *583*<br>• Kyphosis *585*<br>• Scoliosis *586*<br>• Cervical Rib *592*<br>• Avascular Necrosis of the Femoral Head *593*<br>• Femoroacetabular Impingement (FAI) *596*<br>• Baker's Cyst *597*<br>• Genu Varum and Valgum *598*<br>• Genu Valgum (Knock Knee) *599*<br>• Genu Varum/Bow Legs *601*<br>• Osteochondritis Dessicans (OCD) Knee *602*<br>• Synovial Chondromatosis *604*<br>• Discoid Meniscus *605*<br>• Osgood–Schlatter Disease *606*<br>• Chondromalacia Patella *606*<br>• Plantar Fasciitis *607*<br>• Morton's Neuroma *609*<br>• Retrocalcaneal Bursitis (Hump-Bump/Haglund's Deformity) *609*<br>• Various Toe Deformities *610*<br>• Various Bursitis *610* | — | **583** |

| Chapter No. | Chapter Name | Competency No. | Page No. |
|---|---|---|---|
| | ***Section 14: Miscellaneous Topics*** | | |
| **47.** | **Common Procedural Skills**<br>• Casts in Orthopaedics *613*<br>• Splints in Orthopaedics *620*<br>• Lower Limb Splint *620*<br>• Upper Limb Splint *624*<br>• Spine *625*<br>• Strappings *626*<br>• Traction *628*<br>• Intravenous Cannulation *634*<br>• Peripheral Venous IV Cannulation *634*<br>• Central Line Cannulation *636*<br>• Urinary Catheterization *638*<br>• Endotracheal Intubation *640* | OR13.1, OR13.2 | **613** |
| **48.** | **Overview of Common Orthopaedic Procedures**<br>• Closed Reduction, Open Reduction, Internal Fixation, External Fixation *645*<br>• Methods of Joint Reconstruction *647*<br>• Arthroplasty *647*<br>• Arthrodesis *648*<br>• Osteotomy *649*<br>• Bone Grafting *650*<br>• Tendon Transfer Procedure *651*<br>• Arthroscopy *652*<br>• Amputations *653*<br>• Tourniquets *656*<br>• Synovial Fluid Analysis *657* | OR13.1, OR13.2 | **645** |
| **49.** | **Overview of Physiotherapy** | — | **658** |
| **50.** | **Basics of Imaging in Orthopaedics** | — | **662** |
| ***Index*** | | | **667** |

5 CHAPTER

# Dislocation of Major Joints

## INTRODUCTION TO DISLOCATIONS

### DEFINITION

**Dislocation:** A joint is said to be dislocated if two articulating surfaces are "no more in contact" with each other **(Fig. 5.1)**.

**Subluxation:** A joint is said to be subluxated if two articulating surfaces are still in "partial contact" with each other.

A joint that can dislocate or subluxate intermittently, known as *recurrent dislocation* or *subluxation*.

**Fracture–dislocation:** This term is used when the joint is dislocated, and one or both articulating surfaces are fractured **(Fig. 5.2)**. Some authors also term fracture-dislocation as ***'complex dislocation.'***

### HOW A JOINT REMAINS STABLE?

A joint remains stable due to the ***integrity of static*** (bone, ligaments, capsule) and ***dynamic*** (muscle-tendon unit) stabilizers. They can also be considered as ***bony (articulating surface***

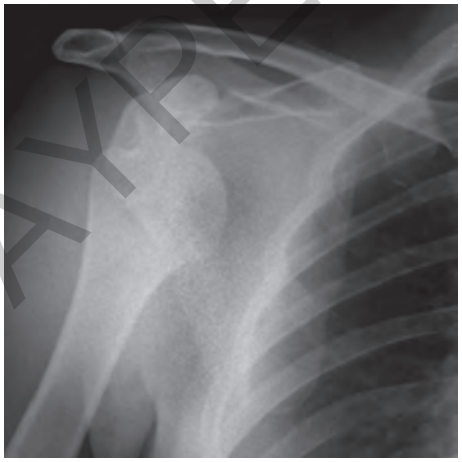

**Fig. 5.1:** Anterior dislocation of the shoulder showing empty glenoid and humeral head lying inferior to the coracoid process.



**Fig. 5.2:** Fracture dislocation of the knee. Note that the contact between tibia and femur is lost and lateral femoral condyle is fractured.

JAYPEE BROTHERS

***morphology)*** and ***soft tissue stabilizers***. Apart from these factors, ***negative pressure in the joint*** also contributes for the stability of a joint.

- **The normal bony morphology of the articulating surfaces:** The normal bony morphology of both articulating surfaces is a *static stabilizer of the joint.* Any morphological anomaly, congenital or acquired, of one or both surfaces, could result in dislocation or subluxation of the joint. Several examples are mentioned below:
  - In recurrent patella dislocation, the *shape of the femoral trochlea* (a longitudinal groove between two femoral condyles in which patella descends and ascends during knee flexion and extension, respectively) *is often flat (trochlear dysplasia)*, causing less lateral restraint on the patella resulting in lateral patella dislocation.
  - In developmental dysplasia of the hip, the congenitally abnormal shape of the acetabulum and femoral head results in dislocation or subluxation of the hip.
- **Intact ligaments and capsule:** Ligaments and capsule are *static stabilizers of a joint*. They permit enough flexibility to allow normal movement but prevent abnormal motion of the joint in any one direction. Injury to the ligament or capsule may happen during dislocation. Furthermore, *excess laxity of ligaments/capsule may predispose a joint for recurrent dislocation*.
- **The muscle cover around the joint:** Muscles are *dynamic stabilizers of the joint as they* can contract and relax to provide adequate stability. For example, in the shoulder's abduction–external rotation (ABER) position, the shoulder is not only stabilized anteriorly by labrum and glenohumeral ligaments but also by intact subscapularis muscle, which contracts to support already stretched ligaments. However, in the case of a complete subscapularis tear, the joint may subluxate or dislocate in an extreme abduction-external rotation position as there is no further anterior support to stretched or torn ligament.

## CLASSIFICATION OF DISLOCATION

- **Traumatic dislocation:** It occurs after a *significant trauma* in an *"otherwise morphologically normal" joint*. The force causing dislocation is severe enough to overcome the restraint provided by the static and dynamic stabilizers.
- **Atraumatic dislocation:** It occurs after insignificant or no trauma in an *"otherwise morphologically abnormal"* joint. The force causing dislocation or subluxation is minimal as the stability of static or dynamic structures is already compromised. For example, *atraumatic shoulder dislocators often exhibit abnormal generalized soft tissue laxity, faulty muscle patterns of contraction, or bony dysplasia resulting in compromised stability*. Such patients can dislocate their shoulders with ease or sometimes voluntarily. The latter is also called "habitual dislocators."
- **Pathological dislocation:** The joint surfaces and/or static stabilizers are destroyed during an infective or inflammatory process affecting the joint, leading to subluxation or dislocation.
  For example, hip or knee tuberculosis destroys the joint, leading to persistently dislocated joint.
- **Paralytic dislocation:** A joint can dislocate if there is paralysis/spasticity of surrounding supporting muscles. A classic example—poliomyelitis, wherein the joints (hip) dislocate due to paralysis of muscles. It is also observed in the shoulder joint after hemi/quadriplegia due to atony in shoulder muscles. Paralytic dislocations are also seen in cerebral palsy.
- **Congenital:** It is present by birth due to congenital malformation of articulating surfaces and other soft tissues. It is commonly observed in hip and knee.

JAYPEE BROTHERS

## PATHOANATOMY OF A DISLOCATION

- **Traumatic dislocation or subluxation** cannot happen without damage to the bony or soft tissue (capsule and ligament) restraints.

  During an episode of traumatic dislocation, soft tissue restraints are almost always torn. For example, *in anterior shoulder dislocation,* the anteroinferior labrum is always torn (Bankart lesion), and the posterolateral head of the humerus shows an impaction fracture (Hill-Sachs lesion). *In lateral patella dislocation*, the medial restraint (medial patellofemoral ligament) is often torn. Further, an injury to the medial or lateral facet of the patella may lead to an osteochondral fracture.

  Occasionally, the ligament substance withstands the stress but pulls away along with a bony fragment where the ligament is attached to the bone. For example, bony avulsion of anterior cruciate ligament from tibia.

  The most significant point to remember is that during the traumatic dislocation, the ***adjacent neurovascular bundle is always at risk of compression or stretch, and that renders traumatic dislocation an orthopaedic emergency (Table 5.1).***

- **Atraumatic dislocation** may not show any damage as joints dislocate easily due to existing abnormal congenital morphology in bony or soft tissue. Also, there is less or no risk of nerve injury.

**Table 5.1:** Common joints predisposed for traumatic dislocation with associated nerve injury.

| Joint | Type or site of dislocation | Nerve injury |
|---|---|---|
| **Cervical spine** | Common at the cervical spine level | Spinal cord |
| **Dorsolumbar spine** | Commonly at the dorsolumbar junction | Spinal cord, conus medullaris, cauda equina |
| **Shoulder** | Most commonly, anterior<br>Sometimes, posterior or inferior | Axillary, brachial plexus |
| **Elbow** | Posterior | Median |
| **Wrist** | Lunate, perilunate | Median |
| **Hip** | Posterior (most common), anterior | Sciatic (in posterior dislocation), femoral (in anterior dislocation) |
| **Knee** | Posterior, anterior, posteromedial, or posterolateral | Tibial, common peroneal |
| **Patella** | Lateral | |
| **Ankle** | Anterolateral | Posterior tibial, deep or superficial peroneal at ankle level |
| **Foot** | Lisfranc (tarsometatarsal),<br>Chopart (intertarsal) | |

## CLINICAL FEATURES OF TRAUMATIC DISLOCATION

### Symptoms

Pain and swelling around the dislocated joint and inability to use a limb or bear weight (in case of lower limb joint dislocations).

JAYPEE BROTHERS

## Signs

- ***Often characteristic deformity:*** For example, flexion, adduction, and internal rotation deformity at the hip joint in posterior dislocation of the hip.
- *Loss of contour of the joint* may be observed, especially if the joint is not deep seated.
- *Painfully restricted range of movement*
- *Altered limb length:* Shortening (posterior dislocation of hip, elbow, knee dislocation) or lengthening (pubic type of anterior dislocation of the hip) of the limb.
- ***An accurate neurovascular assessment is mandatory.***
- Occasionally, a dislocation can result in ***compartment syndrome***. For example, there is a high chance of compartment syndrome in knee or elbow dislocation.

## INVESTIGATIONS

- **Plain X-ray** of the joint—two views are generally required to assess the direction of dislocation **(Figs. 5.3A and B)**.
- **CT scan** is required if there is an associated fracture **(Fig. 5.4)**. Furthermore, bony dysplasia of articular surface can be assessed better on CT scans. For example, trochlear and glenoid dysplasia in patella and shoulder dislocation, respectively.
- **Angiography:** If associated with vascular injury. Usually combined with a CT scan.
- **Magnetic resonance imaging:** Usually, it is acquired after the joint is reduced to assess ligament, capsule, muscle-tendon, or cartilage injuries.



**Fig. 5.4:** 3D CT scan shows posteriorly dislocated and fracture of the head of the humerus.

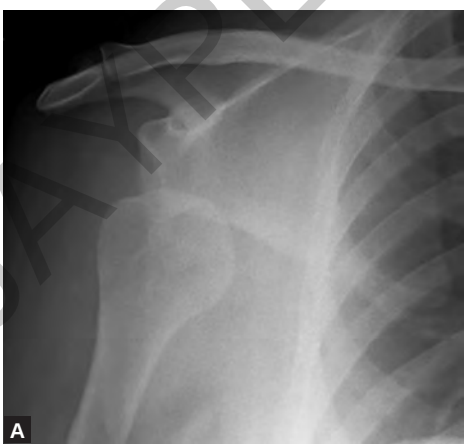





**Figs. 5.3A and B:** Anterior dislocation of the shoulder. (A) Anteroposterior view; (B) Axillary view showing anteriorly dislocated humeral head.

JAYPEE BROTHERS

- **Nerve conduction velocity (NCV) and electromyography (EMG):** In case of associated nerve injury.

## TREATMENT

The treatment of acute, chronic neglected and recurrent joint dislocation is different.

A. **Acute traumatic dislocation:** *All acute dislocations are orthopaedic emergencies due to impending/existing pressure over the neurovascular bundle.* Further, the nutrition of articular surface cartilage is compromised for the duration of dislocation, jeopardizing cartilage health.

***The essence of dislocation treatment is "reduction of dislocation" as early as possible.*** In most cases, closed reduction (CR) can be achieved. However, *if CR attempts fail, one must perform an open reduction of the dislocation.*

Several reasons for a failed CR of dislocation are—buttonholing of articulating surface through the capsule, entrapped bony fragment or soft tissue between the joint surfaces, or a chronic dislocation presenting after a few days to weeks.

- After CR of dislocation, ***joint is immobilized*** *for 2–3 weeks* to let the soft tissues (ligaments, capsule) heal to prevent the recurrence of dislocation.
- Immobilization is followed by ***rehabilitation*** through gentle mobilization of joints, progressive usage of limb or weight-bearing, muscle strengthening, and proprioceptive exercises.

B. **Chronic unreduced dislocation**

- Mostly, it requires open reduction due to fibrosis and contracture of soft tissues.
- Occasionally, the ligaments may require repair or reconstruction to achieve stability.
- Immobilization for 2–3 weeks.
- Rehabilitation.

C. **Chronic recurrent dislocators**: Ligament and bony repair/reconstructive procedures depend upon the existing pathological abnormality (soft tissue/bony/both).

## COMPLICATIONS OF TRAUMATIC DISLOCATION

### Immediate/Early

- Neurovascular damage
- Compartment syndrome
- Irreducible dislocation
- Associated fracture of articulating surfaces.

### Late

- Myositis ossificans
- Stiffness
- Recurrent dislocation
- Avascular necrosis
- Osteoarthritis of the joint.

JAYPEE BROTHERS

# DISLOCATIONS AROUND THE SHOULDER

## SURGICAL ANATOMY

- The true shoulder joint (glenohumeral) is formed between the glenoid and the humerus head **(Fig. 5.5)**.
- The glenoid is lined by fibrocartilagenous 'glenoid labrum.' The labrum acts like a 'chock-block,' deepening the glenoid cavity and thus enhancing the stability of the shoulder.
- Various **static and dynamic restraints** stabilizing the shoulder (glenohumeral joint) are:
  - ***Static restraints*:** Normal geometry of bony articular surfaces (humeral head and glenoid), joint capsule, glenoid labrum, glenohumeral ligaments (superior, middle, and inferior), and negative intra-articular pressure are static restraints.
  - ***Dynamic restraints*:** Rotator cuff muscles, various scapular muscles, the long head of the biceps, and the deltoid provide dynamic stability to the joint.



**Fig. 5.5:** X-ray of normal shoulder showing normal articulation between humeral head and glenoid cavity.

## RELEVANT PATHOANATOMY

- During a **traumatic shoulder dislocation (anterior or posterior)**, the labrum and/or capsule are torn**.** Also, there is an impaction fracture of the humeral head. Sometimes, it is accompanied by a glenoid rim fracture. Rarely, there could be a tear of the rotator cuff, especially in an older person. These pathological entities, if do not heal, result in a recurrently unstable shoulder.
- **Atraumatic shoulder dislocation** is generally due to ***pathological laxity of the joint capsule,*** or abnormal muscle patterning, which may result in instability. It is often multidirectional (2 or more directions—anterior, posterior and inferior).
- In cases of **posterior dislocation**, it is often accompanied by ***glenoid dysplasia***.

## TYPES OF SHOULDER DISLOCATIONS

The *shoulder is most commonly dislocated among all the joints*, accounting for up to 46% of all dislocations. The shoulder dislocates in three directions—anterior, posterior, and inferior, with respect to the glenoid.

1. **Anterior dislocation:** It is the *most common type (96%)*, wherein the head of the humerus lies anterior to the glenoid **(Fig. 5.6)**. There are three subtypes—subglenoid, subcoracoid, and subclavicular.



**Fig. 5.6:** X-ray right shoulder showing anterior shoulder dislocation (of humeral head) and empty glenoid.

JAYPEE BROTHERS



**Fig. 5.7:** X-ray of left shoulder showing posterior dislocation.




**Fig. 5.8:** X-ray of right shoulder showing luxatio erecta.

2. **Posterior dislocation:** In this less common type of dislocation (2–4%), the head of the humerus lies posterior to the glenoid **(Fig. 5.7)**.
3. **Inferior dislocation**: It is the rarest form of dislocation (0.5%), also known as ***luxatio erecta*,** wherein the head of the humerus lies inferior to the glenoid with a hyperabducted arm **(Fig. 5.8)**.

## ACUTE ANTERIOR DISLOCATION OF THE SHOULDER JOINT

### PATHOANATOMY

Anterior dislocation is the most common type of shoulder dislocation (96%). In the traumatic anterior shoulder dislocation, there are ***two essential lesions*** present on the glenoid (Bankart lesion) and humeral head (Hill-Sachs lesion).

1. ***Bankart lesion*:** It is the detachment of anteroinferior labrum from the glenoid margin. Sometimes, the labrum avulses along with a bony glenoid margin known as "Bony Bankart."
2. ***Hill-Sachs lesion:*** It is an impaction fracture on the posterolateral aspect of the head of the humerus. It occurs while the posterolateral part of the head humerus hitches against the anterior glenoid margin during anterior dislocation.

### MECHANISM OF INJURY

1. Fall on an outstretched hand with arm in abduction and external rotation
2. Anterior directed force on the shoulder from behind.

### CLINICAL FEATURES OF ACUTE TRAUMATIC ANTERIOR SHOULDER DISLOCATION

#### Symptoms

There is pain and swelling over the affected shoulder and an inability to move the shoulder.

JAYPEE BROTHERS

## Signs

1. The ***shoulder contour is lost*** with ***fullness in front of the axilla (Fig. 5.9).***
2. Typically, the *arm is held in slight abduction and external rotation* with an *inability to internally rotate and touch the opposite shoulder.* Even passively, internal rotation cannot be performed *(c.f., posterior dislocation of shoulder where external rotation is impossible).*

## Specific Signs in an Acute Shoulder Dislocation (Fig. 5.9)

**A: A**xillary concavity is reduced due to inferiorly dislocated humeral head
**B: B**ryant's test: Anterior axillary fold is at a lower level when compared to the normal side
**C: C**allaway's test: Increased anteroposterior diameter of the axilla
**C: C**ontour of the shoulder lost due to flattening
**D: D**uga's test: Inability to touch the opposite shoulder (as patient cannot internally rotate shoulder)
**H: H**amilton ruler test: A ruler placed on the lateral aspect of the arm touches the acromion (ruler fails to touch the acromion on the normal side)
**H: H**ollow posterior aspect of the shoulder
**I: I**ncreased length of arm compared to normal side
**R: R**egimental badge sign: Loss/decrease in sensation over axillary nerve distribution area over the upper lateral aspect of the arm.



**Fig. 5.9:** Loss of right shoulder contour due to anterior dislocation.

## INVESTIGATIONS

1. **Plain X-ray of the shoulder:** AP and axillary view **(Figs. 5.10A and B)**. *Note: the axillary view is usually required to confirm anterior/posterior direction of dislocation of humeral head with respect to the glenoid.*

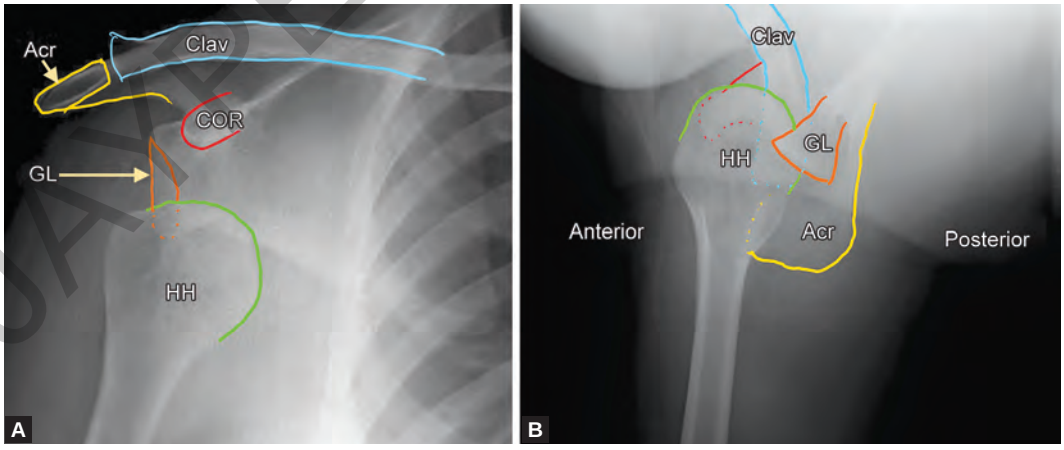


**Figs. 5.10A and B:** Anterior dislocation of the shoulder: (A) Anteroposterior view; (B) Axillary view shows that humeral head is lying anterior to the glenoid.

(HH: humeral head; GL: glenoid cavity; Acr: acromion; Clav: clavicle; Cor: coracoid process; Ant: anterior; Post: posterior)

JAYPEE BROTHERS

2. **MRI:** It is the ***confirmatory investigation to detect Bankart and Hill-Sachs lesion.*** It is important to note that MRI is performed after the reduction of the shoulder.
3. **CT scan:** It is performed if there is an associated fracture of the glenoid, head of the humerus, or greater tuberosity (GT) avulsion.

## TREATMENT OF ACUTE ANTERIOR DISLOCATION

- The **reduction of dislocation must be performed as early as possible** in sedation/general anesthesia, followed by **immobilization** of the shoulder in an arm sling for 3 weeks.
- **Rehabilitation:** Shoulder mobilization and muscle strengthening exercises must be initiated once immobilization is over to regain movement and power of the shoulder.

## VARIOUS MANEUVERS FOR REDUCTION OF ANTERIOR DISLOCATION

1. **Leverage technique:** Kocher's method, Milch method
2. **Traction-countertraction technique:** Hippocratic method, Stimson method, Matsen technique
3. **Scapular manipulation**.

### Kocher's Method

- Quite popular
- **Method:** With the patient sitting/lying supine, the elbow is bent to 90 degrees, the arm adducted, and gradually externally rotated till the forearm lies in the coronal plane of the body. Then, internally rotate the arm. Once the shoulder is reduced, the patient will be able to touch the tip of the opposite shoulder.
- **Disadvantage:** Excess rotational stress over the arm could result in a spiral fracture of the humerus and tear of subscapularis tendon.

### Hippocratic Method (Fig. 5.11)

- **Method:** The examiner pushes his leg into the axilla (counter traction) of the patient and pulls the arm toward himself (traction).
- Currently, almost obsolete.

### Stimson's Method (Fig. 5.12)

- Used in patients who present with *old unreduced anterior dislocation of the shoulder* between 3 weeks and 6 weeks
- **Method:** The patient lies prone on the couch, and a weight is applied over his wrist, which acts like traction. The edge of the bed is like countertraction.

## COMPLICATIONS OF ACUTE ANTERIOR DISLOCATION SHOULDER

### Acute

- ***Axillary nerve palsy***
- Injury to the brachial plexus and axillary vessels
- Associated fracture of the greater tuberosity or anterior glenoid rim
- Possibility of associated rotator cuff tear in older patients (>45–50 years).

JAYPEE BROTHERS



**Fig. 5.11:** Hippocratic method.

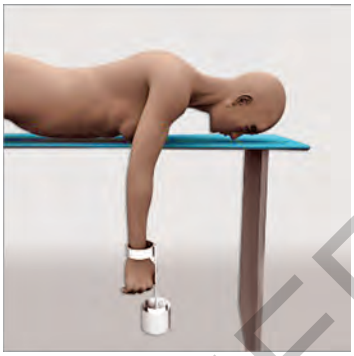

**Fig. 5.12:** Stimson's method.

### Chronic

- Shoulder stiffness (secondary frozen shoulder)
- ***Recurrent dislocation:*** Among all, it is *one of most common complications.*

## RECURRENT ANTERIOR DISLOCATION OF SHOULDER

Recurrent anterior dislocation of the shoulder is quite frequent. The younger the patient (<20–25 years) at the time of the first dislocation, the higher the chance of re-dislocation.

### PATHOANATOMY

1. **Bankart lesion:** Presence of anteroinferior glenoid labrum tear (Bankart lesion) or bony Bankart lesion.
2. **Hill-Sachs lesion:** It is an impaction fracture on the posterolateral aspect of the head of the humerus, which occurs when the head of the humerus impacts against the anterior glenoid margin.
3. **Erosion of anterior glenoid margin:** Often, the anterior margin of the glenoid suffers bony erosion due to repeated dislocation, wherein repeated head engagement with anterior glenoid margin results in glenoid bony erosion.

### CLINICAL FEATURES

The patient may come with an acutely dislocated shoulder or may have a history of repeated dislocations which might be self-reduced or reduced by the doctor.

In a reduced shoulder, several other signs are positive such as:

1. **Apprehension test**
2. **Relocation-release test**
3. *Always examine for generalized ligament laxity by assessing the Beighton score*, which may predispose to recurrent dislocation.

**Box 5.1:** Beighton score.

It is a ***9-point clinical scoring system*** to assess ***soft tissue laxity and hypermobility***. ***Five clinical parameters***—*little finger passive dorsiflexion >90°, thumb passive dorsiflexion to the flexor aspect of forearm, elbow passive hyperextension >10°, knee passive hyperextension >10°, and ability to touch the floor by flat palms while bending forward and keeping knee straight*. Each parameters gets score 0 or 1 on each side, while bending forward gets 0 or 1. ***Score of 4 or higher hyperlaxity***.

JAYPEE BROTHERS

## INVESTIGATIONS

1. **Plain X-ray** of the shoulder
2. **MRI of the shoulder:** It is the diagnostic investigation to detect a glenoid labrum tear and Hill-Sachs lesion.
3. **CT scan:** In case of chronic recurrent dislocation, CT scan is performed to assess the glenoid bone loss (from anterior margin) and Hill-Sachs lesion size. Based on Hill-Sachs lesion size, it is classified as on-track or off-track.

*Currently, two parameters-glenoid bone loss and Hill-Sachs lesion size are essential in surgical decision-making during the treatment.*

## TREATMENT OF RECURRENT ANTERIOR DISLOCATION

Currently, the treatment of recurrent dislocation of the shoulder depends upon the amount of glenoid bone loss [more or less than 25% of anteroposterior (AP) diameter of the glenoid] and Hill-Sachs lesion characteristics.

1. **Arthroscopic/open Bankart repair:** It is performed when the AP glenoid bone loss is <20–25% (compared to the normal side). The torn anteroinferior labrum is resutured onto the glenoid margin by arthroscopic or open method using suture anchors.
2. **Latarjet procedure:** It is performed when the anteroposterior diameter of the glenoid is eroded >20–25%. *In such a situation, the chance of lone arthroscopic labral repair failure increases due to high bone loss, and mere soft tissue repair cannot restore anterior stability.*

   In the Latarjet procedure, the tip of the coracoid (2 cm) is osteotomized along with the attachment of the coracobrachialis and the short head of the biceps. The osteotomized coracoid is then fixed onto the anterior glenoid margin with two screws **(Fig. 5.13)**. Once the bony coracoid is fixed to the anterior glenoid margin, it covers the anterior glenoid bony deficiency and provides enhanced anterior bony support. Furthermore, the attached coracobrachialis tendon over the tip of coracoid and inferior subscapularis fibers provide a sling effect to prevent anterior dislocation during abduction.
3. **Remplissage** is performed for large or an off-track Hill-Sachs lesion. It is performed in addition to Bankart repair. It is a procedure wherein the infraspinatus tendon is sutured over the Hill-Sachs defect to prevent the engagement of the Hill-Sachs lesion with the glenoid margin in external rotation of the shoulder.

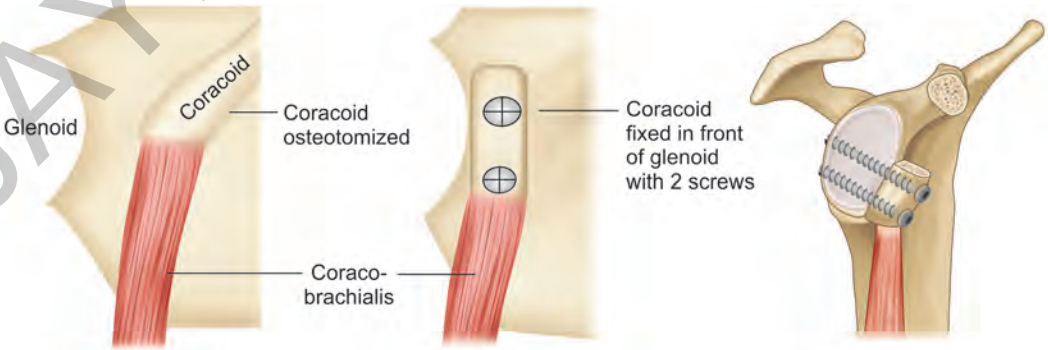


**Fig. 5.13:** Latarjet procedure.

JAYPEE BROTHERS

Note

**Procedures of historical importance**

1. **Putti-Platt procedure:** In this procedure, the subscapularis is divided vertically and sutured by double breasting it resulting in limited external rotation of the shoulder. Hence, Putti-Platt procedure prevents anterior dislocation of shoulder by limiting external rotation, as shoulder dislocates anteriorly in external rotation.
2. **Bristow's procedure:** Biomechanically, Bristow procedure is similar to Latarjet. However, in Bristow procedure the tip of coracoid process is fixed with single screw over glenoid margin (cf. Latarjet wherein two screws are used). Currently, Latarjet is preferred over Bristow's for better biomechanic performance.

## POSTERIOR DISLOCATION OF THE SHOULDER JOINT

- In comparison to anterior dislocation, posterior dislocation of the shoulder is rare. Note that posterior dislocation is *often missed due to subtle clinical and radiological signs.*
- Apart from trauma, posterior dislocation typically occurs after ***Epilepsy, Electric shock/ Electrocution, Ethanol intoxication, and Electroconvulsive therapy (4Es)***.

### MECHANISM OF INJURY

1. **Indirect trauma** results in posterior shoulder dislocation when the shoulder is in a position of *flexion, adduction, and internal rotation*. Electric shock may cause posterior dislocation owing to greater muscular force of internal rotators (latissimus dorsi, pec major, and subscapularis) than external rotators (infraspinatus and teres minor)
2. **Direct trauma:** This results from posteriorly directed force applied to the anterior part of the shoulder, resulting in posterior dislocation.

### PATHOANATOMY

- **Posterior labral tear with or without posterior glenoid margin erosion/fracture (Reverse Bankart lesion)**. Some patients may have ***glenoid dysplasia*** with increased retroversion of the glenoid.
- **Reverse Hill-Sachs lesion:** Impaction fracture over the *anteromedial aspect of the humeral* head.

### CLINICAL FEATURES

#### Symptoms

Pain and swelling of the shoulder with difficulty or inability to move the shoulder.

#### Signs

These patients present with an attitude of ***adduction and internal rotation*** at the shoulder with an inability to ***externally rotate the shoulder*** (active and passive). (*cf., anterior dislocation, wherein the patient cannot perform internal rotation at the shoulder*).

- There is posterior fullness and anterior emptiness with loss of shoulder contour
- Examination of neurovascular structure is a must, especially axillary nerve.

JAYPEE BROTHERS

r detailed information on orthopaedics books, visit our website www.jaypeebrothers.com, for detailed information on orthopaedics books, visit our website www.jayp

# MANIPAL MANUAL OF ORTHOPAEDICS

***Salient Features***

- All essential orthopaedic topics have been covered in accordance with the CBME curriculum.
- Additional chapters and requirements have been added to the current curriculum, benefiting students taking postgraduate competitive exams.
- Each chapter is organized around fundamental principles with numerous illustrations and X-rays, that are simple to read and comprehend.
- The book's point-by-point organization would make it easy for students to remember the ideas.
- The flowcharts used to present the treatment plans for practically all conditions allow the reader to create an algorithm for management.
- Countless crucial ideas have been highlighted in "notes" and "important" boxes. These ideas would be helpful in competitive exams.
- Free complimentary online access to Musculoskeletal Examination for Undergraduates will let students easily understand the concept of examination without adding any bulk to the book.

**Vivek Pandey** is Professor and Unit Head of the Sports Medicine and Arthroscopy Division, Department of Orthopaedic Surgery, Kasturba Medical College, Manipal, Karnataka, India. He received his undergraduate degree (MBBS) from Kasturba Medical College, Manipal and his postgraduate degree (MS Orthopaedics) from KGMC, Lucknow, Uttar Pradesh, India. He won numerous accolades in academia and research, including a Gold Medal for MBBS. He is passionate about his clinical work, research, and teaching. His more than 70 indexed papers in several national and international journals and his chapters in numerous textbooks, demonstrate his love for academics and research. His original studies on platelet-rich plasma, rotator cuff repair, shoulder instability and stem cells in osteoarthritis have received many citations in the literature. He is a guide to postgraduates and PhD candidates. In addition to the *Manipal Manual of Orthopaedics*, he has written three more books that are well-liked by medical students and orthopaedic residents both in India and abroad: *Musculoskeletal Examination for Postgraduates, Musculoskeletal Examination for Undergraduates,* and *Manipal Practical Orthopaedics.* Furthermore, students from all over the world heavily subscribe to the online digital version of 'orthopaedics for undergraduates' at the DigiNerve platform (Jaypee Brothers), which aids in their preparation of fundamentals of orthopaedics. Numerous 'Excellence in Teaching' awards at KMC Manipal and Sikkim Manipal Institute of Medical Sciences (SMIMS), Gangtok, Sikkim, India highlight his love of instructing undergraduate and postgraduate students. His passion for clinical work is primarily managing sports injuries, especially knee and shoulder injuries. By giving guest lectures, carrying out live surgeries, fellowship programs, and training orthopaedic surgeons in sports injuries and arthroscopy, he has contributed significantly to advancing the science and art of arthroscopy.

*Printed in India*

**Available at all medical bookstores**
**or buy online at www.jaypeebrothers.com**




**JAYPEE BROTHERS**
**Medical Publishers (P) Ltd.**
**EMCA House, 23/23-B, Ansari Road,**
**Daryaganj, New Delhi - 110 002, INDIA**
**www.jaypeebrothers.com**

Join us on facebook.com/JaypeeMedicalPublishers

Shelving Recommendation
**ORTHOPAEDICS**

