sit our website www.jaypeebrothers.com, for detailed information on otolaryngology books, visit our website www.jaypeebrothers.com

Scan to Download the App

diginerve
A Jaypee Initiative
Your Guide at Every Step
Video Lectures | Notes | Self-Assessment

OSCE in Otorhinolaryngology

(Ear, Nose & Throat)

As per the Competency Based Medical Education Curriculum (NMC)







Sumanta Kumar Dutta
Sanchari Nandi

JAYPEE

Contents

Section 1: Ear

1. Anatomy 3
2. Physiology 13
3. Clinical Methods 19
4. Surgical Procedures 27
5. Development 31
6. Audio-Vestibulometry 37

Section 2: Nose and Paranasal Sinuses

7. Anatomy 49
8. Physiology 56
9. Clinical Methods 59
10. Surgical Procedures 71
11. Development 78

Section 3: Throat

12. Oral Cavity 83
13. Salivary Glands 93
14. Pharynx and Esophagus 96
15. Larynx and Trachea 105

Section 4: Neck

16. Neck Proper 119
17. Thyroid and Parathyroid Glands 128

Section 5: Instruments

18. OPD Instruments 135
19. OT Instruments 142

Section 6: Imaging

20. X-rays in ENT 157
21. Miscellaneous Imaging 169

JAYPEE BROTHERS

Section 7: Recent Advances

22. Recent Advances **175**

Section 8: Skill Assessment Topics

23. Skill Assessment Topics **197**

Bibliography *201*
Index *203*

JAYPEE BROTHERS

CHAPTER 9

Clinical Methods

Q1. **The image below shows a procedure being performed:**

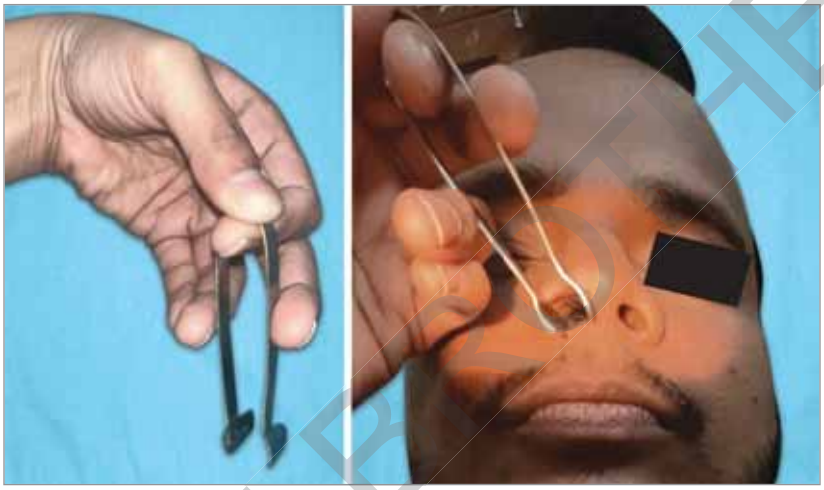

a. What is the test being performed here?
b. Draw and label the structures as seen in this test?
c. What is the instrument being used for this?

JAYPEE BROTHERS

Q2. The image below shows a test being performed on a patient:



a. What is the test being shown?
b. How is this test interpreted?

Q3. The image below shows a test being performed on a patient with the complaint of nasal obstruction:



a. What is the test being shown?
b. "Improvement in the nasal airway, suggests the test is positive"—True/False?
c. This test checks which anatomical area of the nose?

JAYPEE BROTHERS

Q4. **The image below shows a test being performed on a patient:**



a. What is the test being shown?
b. How is this test interpreted?

Q5. **The following images show some tests being performed on a patient:**



a. What is being checked in these images?
b. What is a positive finding in this test suggestive of?

JAYPEE BROTHERS

Q6. The image below shows a test being performed in a patient:



a. What is the test being performed here?
b. Draw and label the structures as seen in this test?

Q7. The following images show a technique being performed in a 25-year-old male who underwent a road traffic accident 7 days ago:

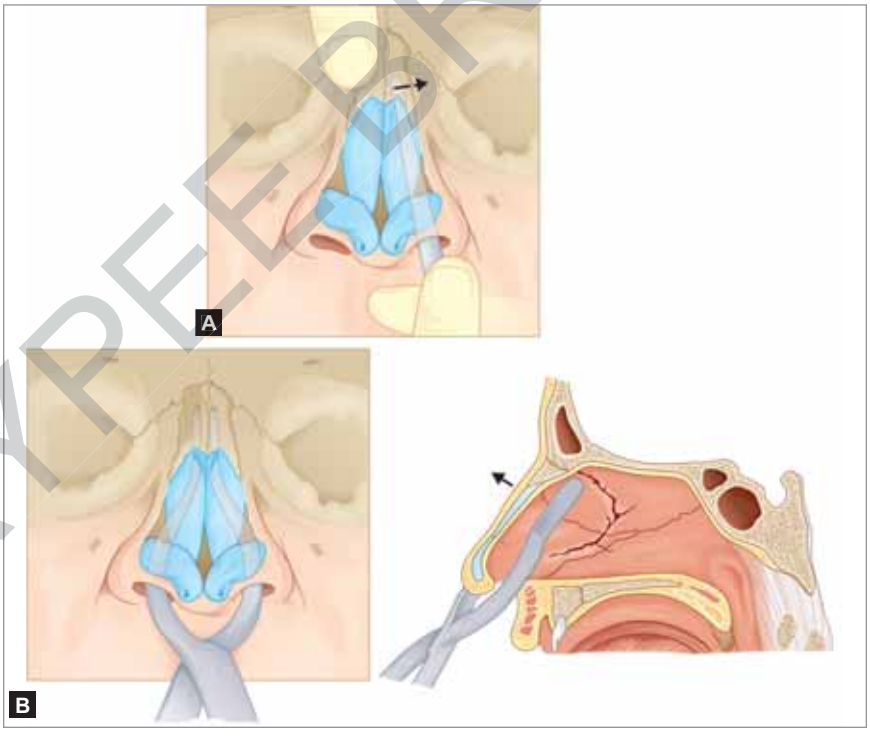

a. What is the procedure being shown in Figure 'A' and Figure 'B'?
b. What is the instrument being used in the Figure 'B'?
c. What is the best time to reduce a nasal fracture?

JAYPEE BROTHERS

Q8. The following image shows a 15-year-old boy with fullness on the right side of face and right side nasal obstruction. On palpation there is a diffuse, firm swelling on the right side of face.

a. Give the two most probable diagnoses for this patient.
b. What is the investigation you will order for the patient?
c. From what does ameloblastoma arise?

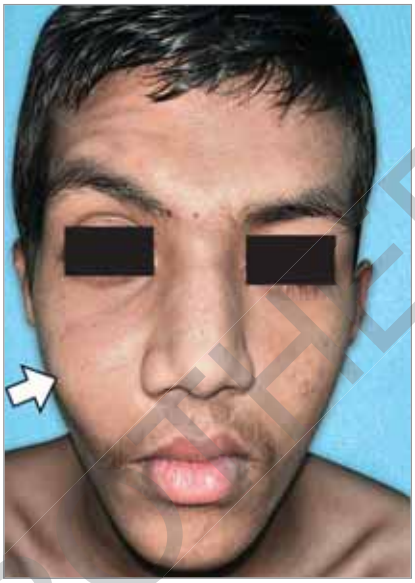

Q9. The following image shows a 53-year-old lady with right sided facial swelling, pain, nasal obstruction and blood-stained nasal discharge. There is also mass present in the nasal cavity.

a. What is the most probable diagnosis?
b. What is the extent of the Ohngren's line?
c. What is the significance of Ohngren's line?



JAYPEE BROTHERS

Q10. The following image shows a 55-year-old lady with a huge, non-tender swelling in the frontal region developing over 1 year. Imaging confirmed a cystic swelling involving the frontal and ethmoidal sinuses, causing displacement of the orbit.



a. What is the most probable diagnosis?
b. What is the most common sinus to be involved in this entity?
c. What is the treatment you will do?

Q11. The following diagram shows the complications of sinusitis:

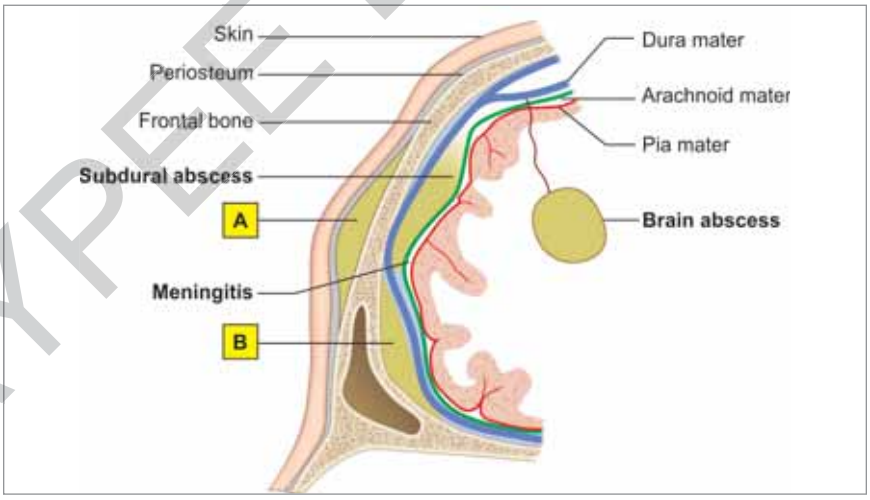

a. What are the two complications marked as 'A' and 'B' in the diagram above?
b. What is the key point of difference between orbital apex syndrome and superior orbital fissure syndrome?
c. Mention two symptoms of cavernous sinus thrombosis.

JAYPEE BROTHERS

Q13. The following image is of the vestibule of a 38-year-old gentleman, with this swelling inside:

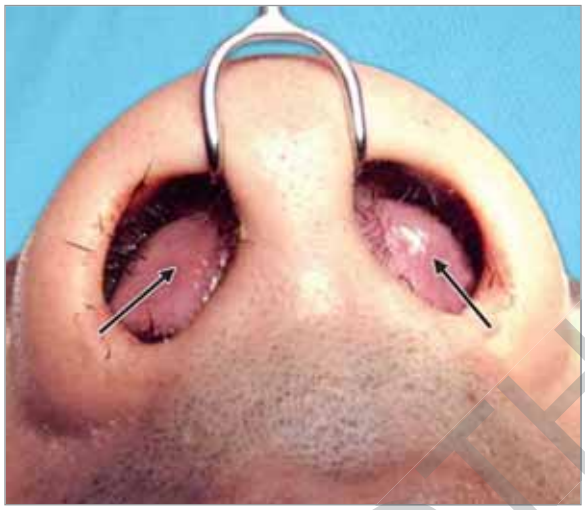

a. What is the most probable diagnosis from the picture shown above?
b. What is the treatment of choice?

Q14. This is a 40-year-old gentleman with an unilateral polypoidal nasal mass, with occasional history of epistaxis:



a. What is the diagnosis shown in the picture?
b. Name the pathogen causing it.
c. What is the treatment?

JAYPEE BROTHERS

ANSWERS

Ans 1:

a. Anterior rhinoscopy
b. Labelled diagram of anterior rhinoscopy:

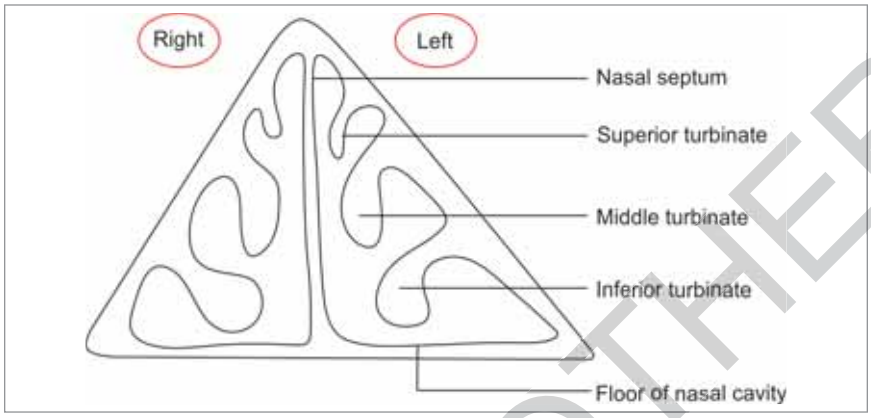

c. Thudicum's nasal speculum

Ans 2:

a. Cold spatula test
b. The side with reduced misting signifies that there is nasal obstruction on that side

Ans 3:

a. Cottle's test
b. True
c. Internal nasal valve area

Ans 4:

a. Cotton-wool test
b. In case of nasal obstruction due to polyp/septum deviation, the movement of the cotton fluff on that side would be reduced

Ans 5:

a. Paranasal sinus tenderness
b. Acute sinusitis

JAYPEE BROTHERS

Ans 6:

a. Posterior rhinoscopy
b. Labelled diagram of posterior rhinoscopy:

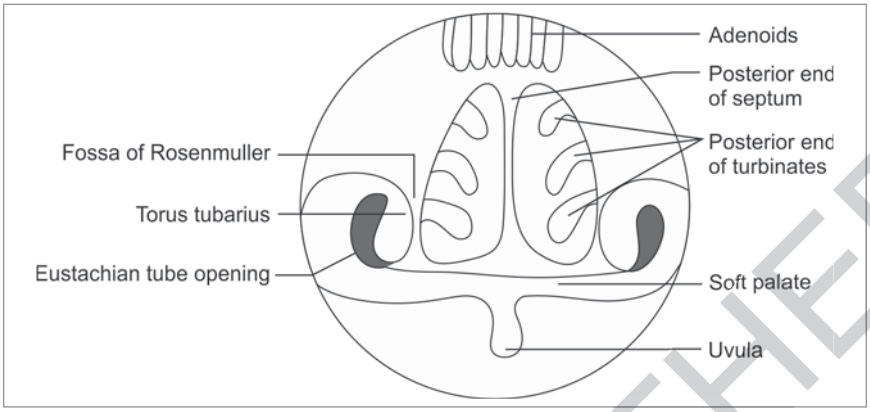

Ans 7:

a. 'A': Closed nasal bone fracture reduction using elevator
'B': Closed septal reduction
b. Asch's septal forceps
c. Presence of edema interferes with accurate reduction by closed methods. Thus, the best time to reduce is before the appearance of edema or after it has subsided which is usually in 5–7 days

Ans 8:

a. i. Fibrous dysplasia
ii. Ossifying fibroma
b. NCCT nose and paranasal sinuses
c. Odontogenic tissue

Ans 9:

a. Carcinoma of the maxillary sinus
b. Ohngren's line extends from the medial canthus of the eye to the angle of the mandible
c. Growths posterosuperior to this line (suprastructural) have a poorer prognosis than those anteroinferior to it (infrastructural)

Ans 10:

a. Fronto-ethmoidal mucocele
b. Frontal sinus: Most common paranasal sinus to be involved by mucocele
c. Frontal sinusotomy with ethmoidectomy (by endoscopic, external or combined approach) with free drainage of the frontal sinus into the middle meatus

JAYPEE BROTHERS

for detailed information on otolaryngology books, visit our website **www.jaypeebrothers.com,** for detailed information on otolaryngolog

OSCE in Otorhinolaryngology *(Ear, Nose & Throat)*

Salient Features

- Targeted to benefit undergraduates appearing for their otorhinolaryngology examinations.
- OSCE-based questions in otorhinolaryngology, as per the new CBME curriculum laid down by NMC.
- Image-based learning—to aid in clearer understanding and better retention of concept for various examinations.
- Interesting read for a postgraduate trainee having OSCE-based questions in their examination.

Sumanta Kumar Dutta MBBS MS (ENT) DNB ORL completed his undergraduate medical education from North Bengal Medical College (NBMC), Kolkata, West Bengal, India and his postgraduate training in ENT from the Institute of Post Graduate Medical Education and Research (IPGMER and SSKM Hospital), Kolkata with gold medals. He is currently Head of the Department of ENT and Head-Neck Surgery at NRS Medical College, Kolkata. He is an eminent ENT surgeon, with dedicated service for the last 30 years and a teacher with good repute for the last 24 years. Besides publishing numerous articles in various reputed journals, he has taken a special interest in shaping young trainees into successful ENT surgeons over the years. He has brought about transformational changes in the department of ENT since the start of his journey at NRS Medical College, Kolkata.

Sanchari Nandi MBBS MS (ENT) completed her undergraduate medical education from Calcutta National Medical College (CNMC), Kolkata, West Bengal, India and her postgraduate training in ENT from the All India Institute of Medical Sciences, Jodhpur, Rajasthan, India. She is currently working as a Senior Resident in the Department of ENT and Head-Neck Surgery at NRS Medical College, Kolkata. As a budding surgeon, she is extremely passionate about teaching and shaping young minds. She strongly advocates conceptual learning as a key to retention.

Printed in India

Available at all medical bookstores or buy online at www.jaypeebrothers.com

JAYPEE BROTHERS
Medical Publishers (P) Ltd.
EMCA House, 23/23-B, Ansari Road, Daryaganj, New Delhi - 110 002, INDIA
www.jaypeebrothers.com

Join us on facebook.com/JaypeeMedicalPublishers

Shelving Recommendation
OTORHINOLARYNGOLOGY

ISBN 978-93-5696-205-7