ebrothers.com, for detailed information on dermatology books, visit our website www.jaypeebrothers.com, for detailed information on dermatology books

The ACNES

2nd Edition





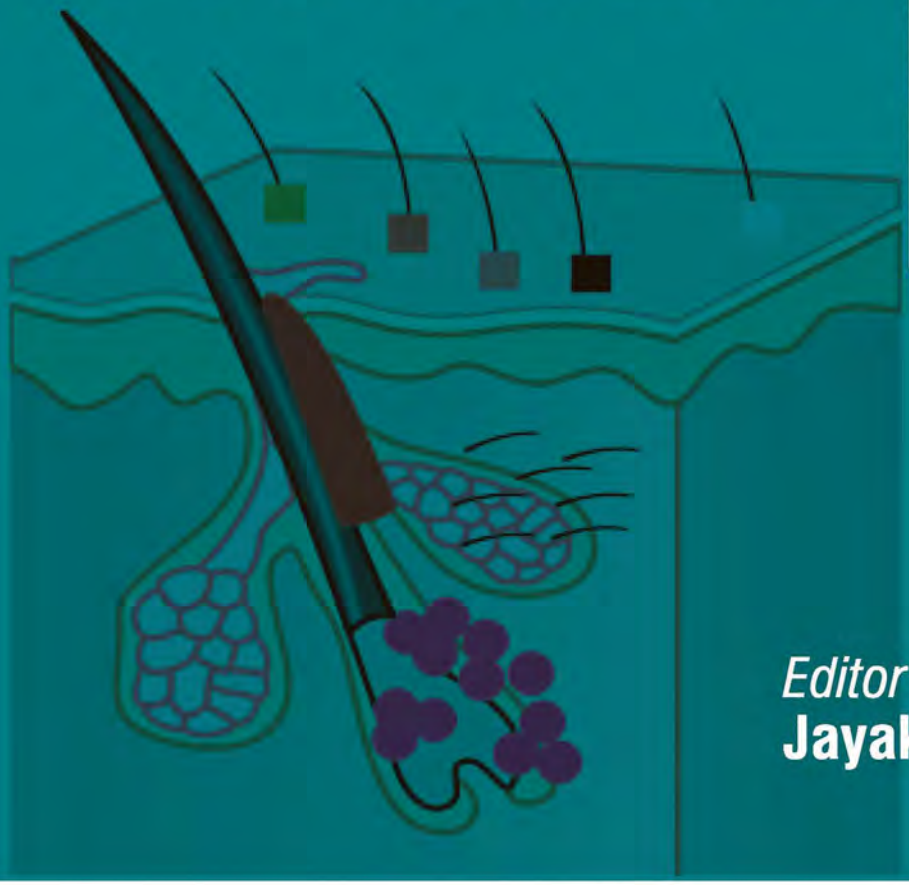

Editor
Jayakar Thomas

Co-editor
Parimalam Kumar

Foreword
D Prabhavathy

JAYPEE

Contents

CHAPTER 1: Introduction 1

CHAPTER 2: Etiopathogenesis 3

CHAPTER 3: Clinical Features 26

CHAPTER 4: Types and Variants of Acne 39

CHAPTER 5: Course and Complications 87

CHAPTER 6: Assessment and Investigation 99

CHAPTER 7: Treatment 106

CHAPTER 8: What is New in Acne Vulgaris—from Recent Literature 143

Suggested Readings 165

Index 171

CHAPTER 3

Clinical Features

It is important to elicit proper history to gather information regarding onset, evolution symptoms such as itching, burning, and photosensitivity, details about menstrual history, associations like diabetes, and drug history in all patients with acne. Detailed history of treatments pertaining to intake of drugs for acne including specifics of contraceptive pills and procedures undergone, if any, should also be recorded. Daily routine, diet habits, and cleansers used should be noted, as well. Family history of acne will give a clue to the course of the disease and, therefore, will help assess the patient well. Complete and thorough examination is mandatory, which includes both dermatological and systemic examination wherever applicable. Assessment of quality of life (QOL) will certainly help manage the patients better and more effectively. Most patients, both males and females, report gradual onset of lesions around puberty. However, acne can manifest from newborn period to adulthood as late as sixth decade.

CLINICAL MANIFESTATIONS (FIGS. 1 TO 50)

Onset and Evolution

By and large, adolescent acne vulgaris is usually gradual in onset. Hence, history of an abrupt onset should give a clue to suspecting an underlying cause. Similarly, in females with severe acne even if the onset is gradual, hyperandrogenism should be considered and evaluated. More so, if acne is resistant to treatment. This should be taken more seriously toward endocrine workup if there is an associated menstrual irregularity and hirsutism.



FIG. 1: Oily skin, the first clinical presentation and complaint from the preadolescent.



FIG. 2: Oily skin of 6 months' duration; increased sebum production starts manifesting well before the clinical onset of acne.

JAYPEE BROTHERS



FIG. 3: Comedone papule pustule; all primary lesions of acne seen in this man.



FIG. 4: Sandpaper comedones consist of multiple closed comedones predominantly distributed over the forehead with androgenetic alopecia.



FIG. 5: White heads or closed comedones are often inconspicuous requiring adequate lighting and stretching of skin as in this girl.



FIG. 6: A boy with open comedones; the black color is thought to be due to melanin, deposited within the cellular debris.



FIG. 7: Same patient as in Figure 6 with white heads which have no visible follicular opening.



FIG. 8: Comedones starting in the T-zone; note the V-zone is not involved.

JAYPEE BROTHERS

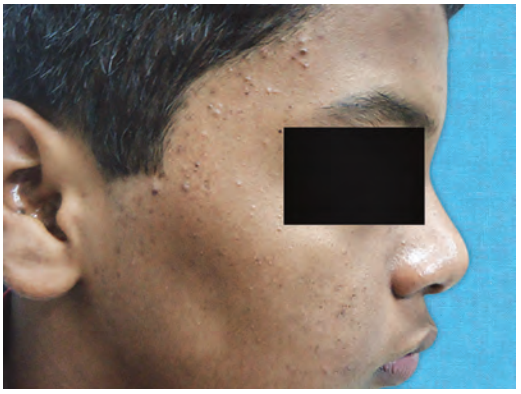

FIG. 9: Noninflamed lesions, the earliest lesions developing in younger patients embrace both white and black comedones.



FIG. 10: Submarine comedones are greater than 0.5 cm residing deeply which are the common cause for recurrent inflammation.



FIG. 11: Sandpaper comedones in a child consisting of multiple, very small whiteheads over the forehead.

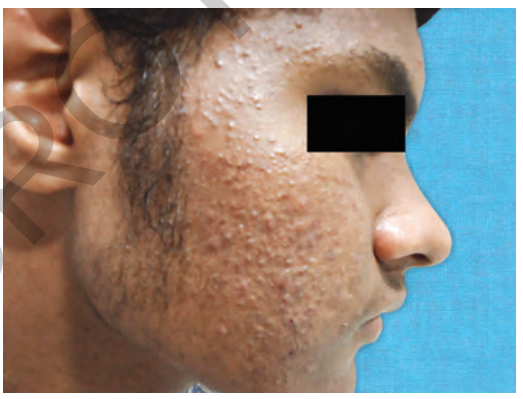

FIG. 12: Face is the most common site of involvement in acne.

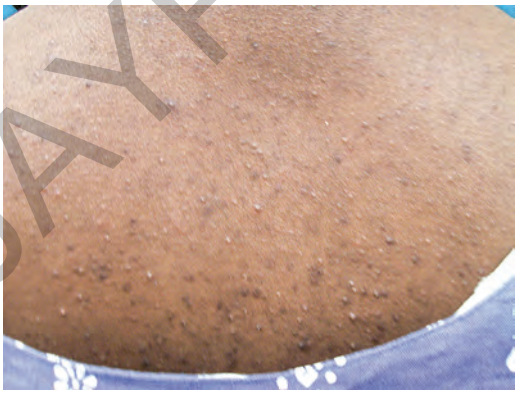

FIG. 13: A girl showing truncal involvement.



FIG. 14: A girl showing truncal involvement; same patient as in Figure 13.

JAYPEE BROTHERS

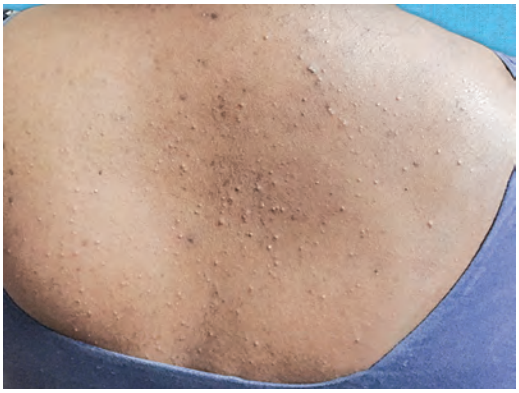

FIG. 15: Truncal acne in an older woman.



FIG. 16: A girl with truncal acne whose face was spared.



FIG. 17: Truncal involvement lesions predominately seen over the shoulder.



FIG. 18: Comedones over the back; note the pigmentation over shoulder following topical application.



FIG. 19: A boy showing comedones and few papules; the picture can vary from mild to aggressive form with or without systemic features.



FIG. 20: Noninflammatory papules; note the receding hair line.

JAYPEE BROTHERS

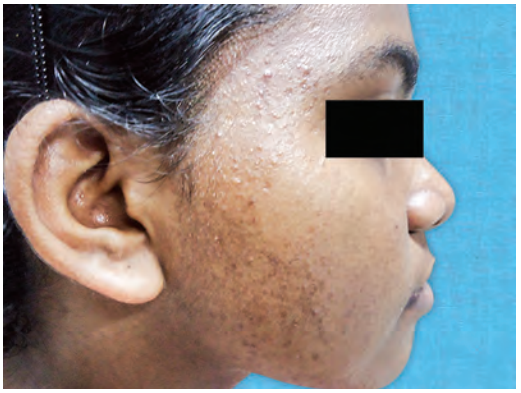

FIG. 21: Noninflamed lesions in a preadolescent; note the temporal involvement.



FIG. 22: Acne polymorphic inflammatory disease of the skin occurring most commonly on the face.



FIG. 23: Keratotic papules seen over the arm.



FIG. 24: Same patient as in Figure 23 showing lesions over the arm.



FIG. 25: Predominantly pustules; note the seborrhea.



FIG. 26: V-zone acne with pustule.

JAYPEE BROTHERS

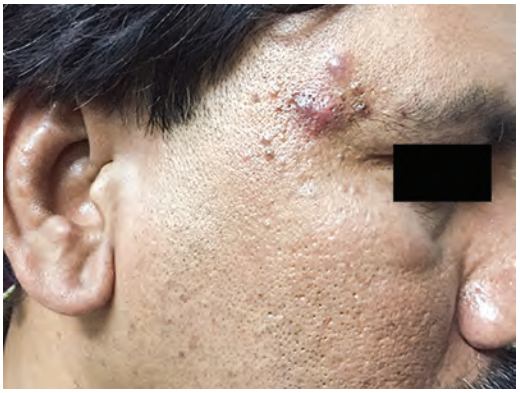

FIG. 27: Cystic lesion; temporal acne.



FIG. 28: Same patient as in Figure 27.



FIG. 29: Persistent nodular lesions of acne; note the resultant scars.



FIG. 30: Persistent nodular lesions of acne; same person as in Figure 29; note the resultant scars.



FIG. 31: Acne cysts are not true cysts as they are not lined by epithelium.



FIG. 32: Classical cystic lesion in a boy with acne.

JAYPEE BROTHERS



FIG. 33: Middle-aged woman with few nodulocystic lesions healing with scar.



FIG. 34: Classical nodulocystic acne; note the androgenetic alopecia.



FIG. 35: Therapy-resistant acne with nodular lesions.



FIG. 36: Mild acne in a teenager.



FIG. 37: Mild acne in a teenager; same patient as in Figure 36.



FIG. 38: Mild acne in a teenager; note that the open comedones are better seen than the closed ones.

JAYPEE BROTHERS



FIG. 39: Mild-to-moderate acne in a 15-year-old boy.



FIG. 40: Moderate acne showing predominantly pustules.



FIG. 41: Moderate acne showing predominantly pustules; same patient as in Figure 40.



FIG. 42: Moderate acne with scar.



FIG. 43: Severe acne; it is not necessary to investigate unless there are other features of hyperandrogenism.



FIG. 44: Severe acne who also had polycystic ovary syndrome.

JAYPEE BROTHERS



FIG. 45: Severe acne; same patient as in Figure 44.

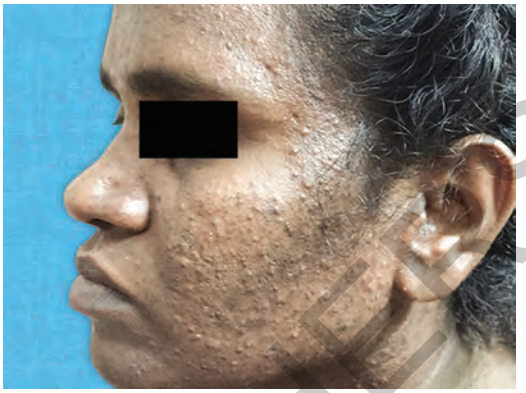

FIG. 46: Very severe acne, resistant to treatment will need hormone assessment.



FIG. 47: Very severe acne, resistant to treatment; same patient as in Figure 46.



FIG. 48: Erythema is one of the major causes for concern in patients with acne.



FIG. 49: Pigmentation is a common manifestation in acne.



FIG. 50: Scarring and dilated pores are the telltale evidence of acne.

JAYPEE BROTHERS

Symptoms

Acne vulgaris in majority of the patients is asymptomatic. However, increased sebum production which results in oily skin starts manifesting well before the clinical onset of acne. Thus, the first clinical presentation and complaint from the adolescents is that of an oily skin which is not uncommon in prepubertal children. Itching is not an uncommon symptom in patients with acne. According to some, the itching is possibly due to the release of histamine-like compound from *Cutibacterium acnes*. In some patients with itching, scratching and picking may lead to scarring if not attended appropriately. Thus, history of persistent scratching and picking should give a clue to elicit more details to rule out psychological stress in such persons. Repeated excoriation leading to itch–scratch cycle can only be detected and alleviated by proper history-taking. **Box 1** gives important points to include while eliciting history in acne patients and in those who are suspected to have drug-induced origin.

BOX 1 **Points to be noted while eliciting history in drug-induced acne.**

- Occupation
- Dietary habits
- Duration of lesion
- Onset of drug intake in chronological order
- *Details of each drug*:
  - Dosage
  - Duration
- *Exacerbating factors*:
  - Hormonal therapy
  - Use of cosmetics (type, frequency, duration)
- Environmental factors
- *Relationship with the drug*:
  - Time interval between initiation of drug and onset of lesion
  - Time interval between improvement and withdrawal of drug

Signs

Even before development of acne lesions, many patients present with oily skin as a result of increased sebum production. Apart from seborrhea, the primary manifestations of acne include comedones, papules, pustules, cysts, and nodules. Secondary changes include erythema, scaling usually secondary-to-topical treatment, pigmentation, scarring, and keloid formation. Systemic association like fever is not uncommon in severe form of acne like acne fulminans.

Many clinical signs such as patterned hair loss, hirsutism, and acanthosis nigricans are seen in patients with endocrine acne.

Cutaneous Lesions

Face is the primary site of acne. Shoulders and front and back of chest are quite frequently involved in many patients. Men are more prone for involvement of the back. It is not surprising to see patients with severe involvement of trunk while face remains spared. Many lesions over the trunk tend to involve the interscapular region. The T- and V-zone distribution of facial acne is an important observation which may give a clue to the underlying endocrine abnormality. The T-zone of the face starts from the midpoint and sides of the forehead extending downward to include the nose and midportion of chin. This area is the most acne-prone zone of the face. The T-zone involvement or central face involvement is a common manifestation in acne vulgaris, while the V-zone involvement affecting the lower third of face involving the jaw line and chin is seen in adult-onset acne or acne associated with endocrine problems like polycystic ovarian syndrome (PCOS). Involvement of trunk is quite common in acne and severe inflammatory lesions with deep nodules over the trunk that are seen in acne fulminans and acne conglobata.

JAYPEE BROTHERS

Acne is one disease where many types of skin lesions are seen in the same patient at a given point of time as it is characterized by several clinical lesions as mentioned earlier. Some patients may still have monomorphic lesions with few lesions of different morphology, particularly during the early stage of evolution of the disease. By and large, most patients present with polymorphic skin lesions.

The three important aspects to concentrate while inspecting an acne patient include:

1. Noninflammatory lesions
2. Inflammatory lesions
3. Signs of sequelae like pigmentation and scars

The skin type and presence of findings such as oily skin, excoriation marks, hirsutism, other features of hyperandrogenism, and insulin resistance have to be assessed before deciding on the treatment protocol.

Noninflammatory Lesions

Comedones are the noninflammatory lesions of acne and are pathognomonic of the disease. Comedones are of two types, namely the open and closed types. The open comedones are also referred to as the black comedones while the closed ones are called the white comedones. The dark appearance of the open comedone corresponds to the impacted keratin and/or lipid in the dilated follicular orifice which is seen at the summit of a slightly raised skin-colored papule. Because of this distinct brownish-black color, open comedones are easily visualized, whereas the closed comedones may not be easily visualized in the early stages. They are small skin-colored papules but do not have clinically visible follicular orifice. Stretching the skin will make the comedones slightly prominent and visible. Apart from the closed and open comedones, sandpaper comedones, macrocomedones, and submarine comedones are also described in acne patients. **Box 2** gives the list of various types of comedones seen in patients with acne.

BOX 2 Types of comedones in acne.

- Open comedones
- Closed comedones
- Sandpaper comedones
- Macrocomedones
- Submarine comedones

Sandpaper comedones consist of multiple closed comedones predominantly distributed over the forehead. Macrocomedones are large, closed comedones seen over the forehead giving a rough, gritty feel. While submarine comedones are closed comedones of size greater than 0.5 cm in diameter and are placed deeply when compared to the other types of comedones. Presence of submarine comedones may indicate recurrence and evolution into a severe form of inflammatory nodular lesions.

Inflammatory Lesions

Inflammatory lesions of acne develop from the abovementioned comedones including the microcomedones. The inflammatory lesions of acne include small papules to large fluctuant nodules resembling abscesses. Papules, pustules, nodules, and abscess formation are seen in many patients during different stages of the diseases or all the lesions can be present in a patient at a particular time of examination. The term cyst should not be used to describe the large fluctuant nodules, as in acne, there is no true cyst formation. These are better referred to as nodular acne. Inflammatory lesions, if left untreated or inappropriately treated, may lead to disfiguring sequelae such as fistula, sinus tract formation, scars, and keloids.

Papules are usually skin-colored but may be erythematous. Sometimes, because of excoriation in psychologically disturbed patients, these papules may have central excoriation mark which can, sometimes bleed. In patients who are on topical treatment, especially keratolytic agents such as benzoyl

JAYPEE BROTHERS

peroxide and retinoic acid, and those using face wash containing peeling agents like salicylic acid may, in addition, show scaling. Location and extent of the inflammatory infiltrate in the dermis greatly determines the type of inflammatory lesion whether papule, pustule, nodule, or abscess.

Presence of grouped comedones and severe deep-seated inflammatory lesions should raise suspicion of acne conglobata.

Those with acne vulgaris are also more prone to develop chemical-induced acne. In some patients, in addition to the abovementioned lesions in the classical sites of T- or V-zone of the face, presence of comedones in the temporal region and retroauricular area, with a straw-colored cyst may indicate associated acne of chemical origin and will give a clue to the diagnosis of chloracne.

SEQUELAE

Pigmentary changes and scar formation are very common sequelae of acne often associated with excoriation in psychologically disturbed individuals to such an extent to lead on to development of prurigo nodularis. Patients may present at a given point of time with different stages of evolution of the disease and its complications.

Multiple excoriations, postinflammatory pigmentary changes, and scarring can be seen in a patient along with active lesions. The self-inflicted excoriations are mostly seen only over the accessible sights. Invariably the interscapular area will be spared as this anatomical region is unreachable by the patient. In some patients, excoriations can also be seen over not only acne lesions but also other lesions like that of folliculitis. It will be interesting to note that anxious patients with acne excoriee often spend many hours in a day in front of the mirror injuring the skin either by picking or traumatizing the lesions with instruments like tweezers in order to get temporary relief from their anxiety. In such anxious patients with acne, severely pruritic papulonodules of size up to 2 cm in diameter located preferentially on the extensor aspect of the extremities resembling prurigo nodularis are considered as an extreme variant of acne excoriee.

Scarring

Scarring is a frequent sequel of acne. Both inflammatory and noninflammatory acne can lead on to scar formation and is seen as a consequence of acne in majority of patients. It can present as atrophic scar resulting from loss of tissue or as hypertrophic scar or keloid due to excessive fibrous tissue laying.

Acne scars are broadly divided into four types namely ice pick scars, rolling scars, box scars, and hypertrophic scars.

Ice pick scars represent narrow, deep scars which are widest on the skin surface and taper as they go deeper into the dermis.

Rolling scars are shallow, wide scars that have an undulating appearance.

Box scars are wide, sharply demarcated scars. The width of box scar is same at the surface and at the base.

Hypertrophic scars are usually seen over the trunk and tend to be much elevated from the skin surface.

Keloids

These are not uncommon in patients with acne. Keloids are firm skin-colored papules or plaques seen over the healed acne lesions and extend beyond the original size of the lesion. They can be itchy and sometimes even painful.

GRADING OF ACNE

It is important to grade acne to plan appropriate therapy. Grading also helps in assessing treatment response, modification of therapy, and to convince the patient during follow-up. Severity of acne can be graded

JAYPEE BROTHERS

by different methods. Assessing the severity using standard assessment methods will help not only in the treatment and follow-up in individual cases but also in scientific studies and clinical trials.

Type, number of lesions, and distribution are taken into consideration for assessing the severity of acne. Most common grading system which is easily applicable in daily practice is grading acne as mild, moderate, and severe.

The evaluation of acne can be done by any of the following methods:

- Overall or global assessment
- Evaluation of individual lesions
- Evaluation according to the predominant lesion type

For academic purpose, Leeds photometric grading scale that uses a scale of 0–10 and includes face, chest, and back is the most commonly used method. However, severity of lesions is not taken into consideration in this method of grading.

Other methods adopted in the assessment of acne severity are listed below. Some of which also use the psychological effects and the QOL.

- The comprehensive acne severity system (CASS)
- Cardiff acne disability index (CADI)
- Assessment of the psychosocial effects of acne (APSEA)
- Acne quality of life scale (Acne-QOL)
- Acne quality of life four-item index (Acne-Q4)

The authors have personally experienced a better patient compliance by assessing the severity of acne and QOL. Therefore, they are of the opinion that every patient from prepubertal age onward should be assessed for both disease severity and QOL. **Table 1** gives the measures available to assess the QOL of acne patients.

A user-friendly grading system is given in **Box 3** for easy practical approach.

TABLE 1: Assessment of quality of life of acne patients.

Generic measures	• EuroQoL-5D • Short form 36 (SF-36)
General health questionnaire	• UK sickness impact profile • Preference-based measures of utility
Dermatology-specific measures	• Dermatology life quality index • Skindex • Dermatology quality of life scales • Dermatology-specific quality of life instrument • Children's dermatology life quality index
Acne-specific quality of life instruments	• Cardiff acne disability index • Acne-specific quality of life questionnaire • Acne quality of life scale • Acne quality of life index • Assessments of the psychological and social effects of acne

BOX 3 User-friendly grading system for acne.

- *Mild*: 0–5 lesions*
- *Moderate*: 6–20
- *Severe*: 21–50
- *Very severe*: >50

*Papules and pustules on one side of the face.

JAYPEE BROTHERS

for detailed information on dermatology books, visit our website www.jaypeebrothers.com, for detailed information on dermatology books, visit our webs

The ACNES

Salient Features

- Acne is among the most common skin conditions worldwide.
- Despite this fact, accurate information about acne is scarce.
- Myths about acne are as common as the skin problem. It is essential that all medical practitioners know about acne.
- This book, *The Acnes*, 2nd edition, is aimed to serve both general practitioners and dermatologists—mainly for the latter.
- It is a helpful tool, not only for the student who needs an expert source of basic knowledge in the different forms of acne.
- At times, the science presented might seem overwhelming. But one can start reading from any chapter, based on one's interests, tastes, and preferences.
- This second edition has been updated and also carries a separate chapter on newer concepts.

Professor Jayakar Thomas is known to be a prolific writer of dermatology books. He has more than 12 titles to his credit, apart from authoring chapters in textbooks of Dermatology, Pediatrics, Adolescents, and Allergy. He has also authored more than 300 original scientific articles in various national and international journals.

Printed in India

Available at all medical bookstores
or buy online at www.jaypeebrothers.com



JAYPEE BROTHERS
Medical Publishers (P) Ltd.
EMCA House, 23/23-B, Ansari Road,
Daryaganj, New Delhi - 110 002, INDIA
www.jaypeebrothers.com

Join us on facebook.com/JaypeeMedicalPublishers

Shelving Recommendation
DERMATOLOGY

