site www.ejaypee.com, for detailed information on pediatric books, visit our website www.ejaypee.com, for detailed information on pediatric books, visit our website www.ejaypee.com

8th Edition

Bestselling Review Book of Pediatrics

REVIEW OF PEDIATRICS & NEONATOLOGY

A Must-buy Book for NEET-PG, INI-CET and FMG Exams



Most comprehensive and highly recommended Pediatrics book by the toppers, for quick revision and MCQ based exams on Pediatrics

Revised and updated from latest editions of Nelson (22/e), Ghai (10/e), Harrison (22/e) and latest recommendations and guidelines

Meenakshi Bothra Gupta
Taruna Mehra

JAYPEE

Contents

Annexures *xvii*

SECTION 1: General Pediatrics

1. Normal and Abnormal Growth **1**
Pretext *1*; Questions *13*; Answers with Explanations *19*

2. Development **27**
Pretext *27*; Questions *34*; Answers with Explanations *39*

3. Nutrition and Malnutrition **46**
Pretext *46*; Questions *57*; Answers with Explanations *66*

4. Fluid and Electrolyte Disturbances **77**
Pretext *77*; Questions *86;* Answers with Explanations *90*

5. Genetics and Genetic Disorders **97**
Pretext *97;* Questions *111;* Answers with Explanations *124*

6. Inborn Errors of Metabolism **138**
Pretext *138*; Questions *155*; Answers with Explanations *163*

7. Diseases of Immune System **174**
Pretext *174*; Questions *183*; Answers with Explanations *188*

8. Infectious Diseases **194**
Pretext *194*; Questions *216*; Answers with Explanations *228*

9. Immunization **247**
Pretext *247*; Questions *256*; Answers with Explanations *263*

10. Pediatric Basic and Advanced Life Support **273**
Pretext *273*; Questions *283*; Answers with Explanations *284*

SECTION 2: Neonatology

11. Normal Neonate and Neonatal Resuscitation **287**
Pretext *287*; Questions *298*; Answers with Explanations *304*

12. Diseases of Newborn **315**
Pretext *315*; Questions *336*; Answers with Explanations *346*

SECTION 3: Systemic Pediatrics

13. Pediatric Cardiology **362**
Pretext *362*; Questions *380*; Answers with Explanations *390*

14. Pediatric Hematology **402**
Pretext *402*; Questions *417*; Answers with Explanations *427*

15. Tumors of Infancy and Childhood **441**
Pretext *441*; Questions *449*; Answers with Explanations *453*

16. Pediatric Gastrointestinology **459**
Pretext *459*; Questions *468*; Answers with Explanations *474*

17. Pediatric Hepatology **483**
Pretext *483*; Questions *488*; Answers with Explanations *491*

18. Pediatric Respiratory Disorders **495**
Pretext *495*; Questions *507*; Answers with Explanations *516*

19. Disorders of Kidney and Urinary Tract **528**
Pretext *528*; Questions *545*; Answers with Explanations *556*

20. Pediatric Endocrinology **571**
Pretext *571*; Questions *587*; Answers with Explanations *596*

21. Pediatric Neurology **607**
Pretext *607*; Questions *622*; Answers with Explanations *633*

22. Behavioral Disorders in Children **651**
Pretext *651*; Questions *655*; Answers with Explanations *658*

23. Musculoskeletal System **662**
Pretext *662*; Questions *671*; Answers with Explanations *674*

24. Pediatric Surgical Disorders **679**
Pretext *679*; Questions *687*; Answers with Explanations *692*

CHAPTER 13 Pediatric Cardiology

High Yield Points

- **4 chambered structure** of heart develops by **6 weeks** of IU life
- **Ductus venosus** is a bypass shunt between **portal vein & IVC**
- **Ductus arteriosus** a shunt between **pulmonary trunk** and **descending aorta**

FETAL CIRCULATION

Differences between Fetal and Adult Circulation

- In **adults** gas exchange occurs in the **lungs**, while in **fetus placenta** provides exchange
- In **fetus, lungs are collapsed**, **pulmonary vascular resistance is very high** & very little blood goes to lungs
- **Ductus arteriosus, ductus venosus & foramen ovale** are important structures taking part in fetal circulation.

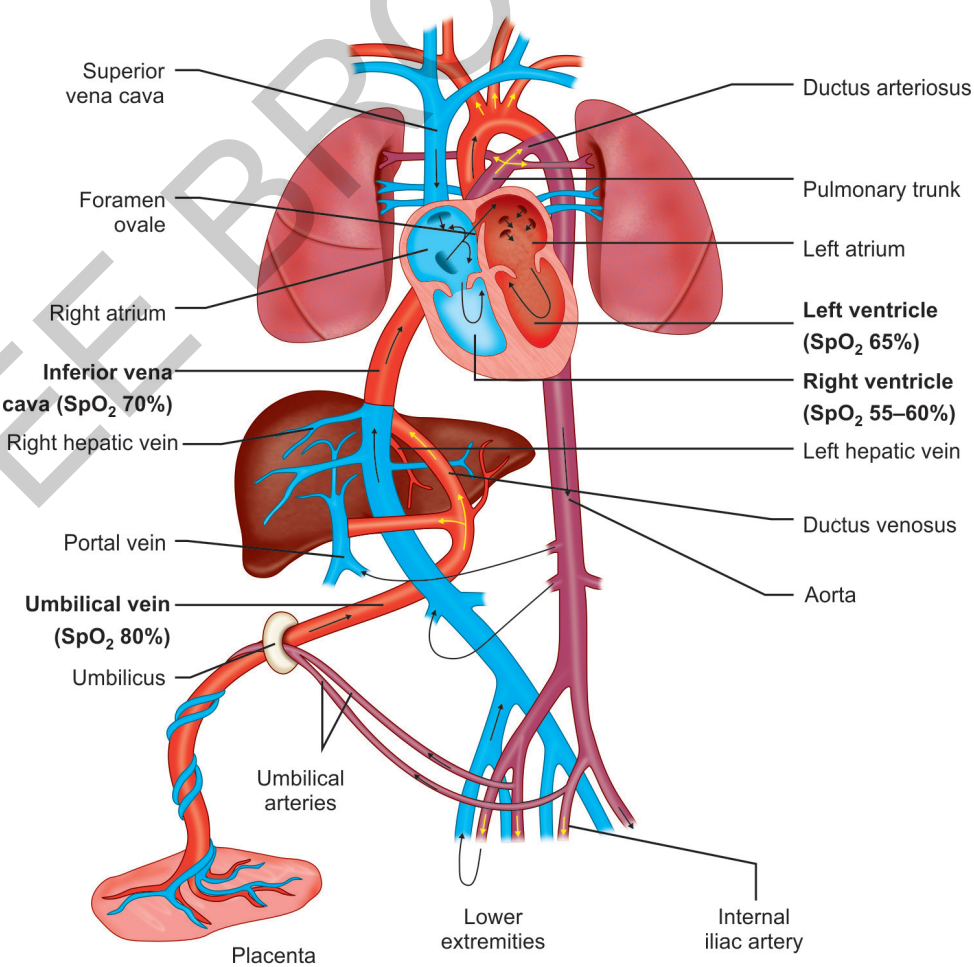

JAYPEE BROTHERS

Course of Fetal Circulation

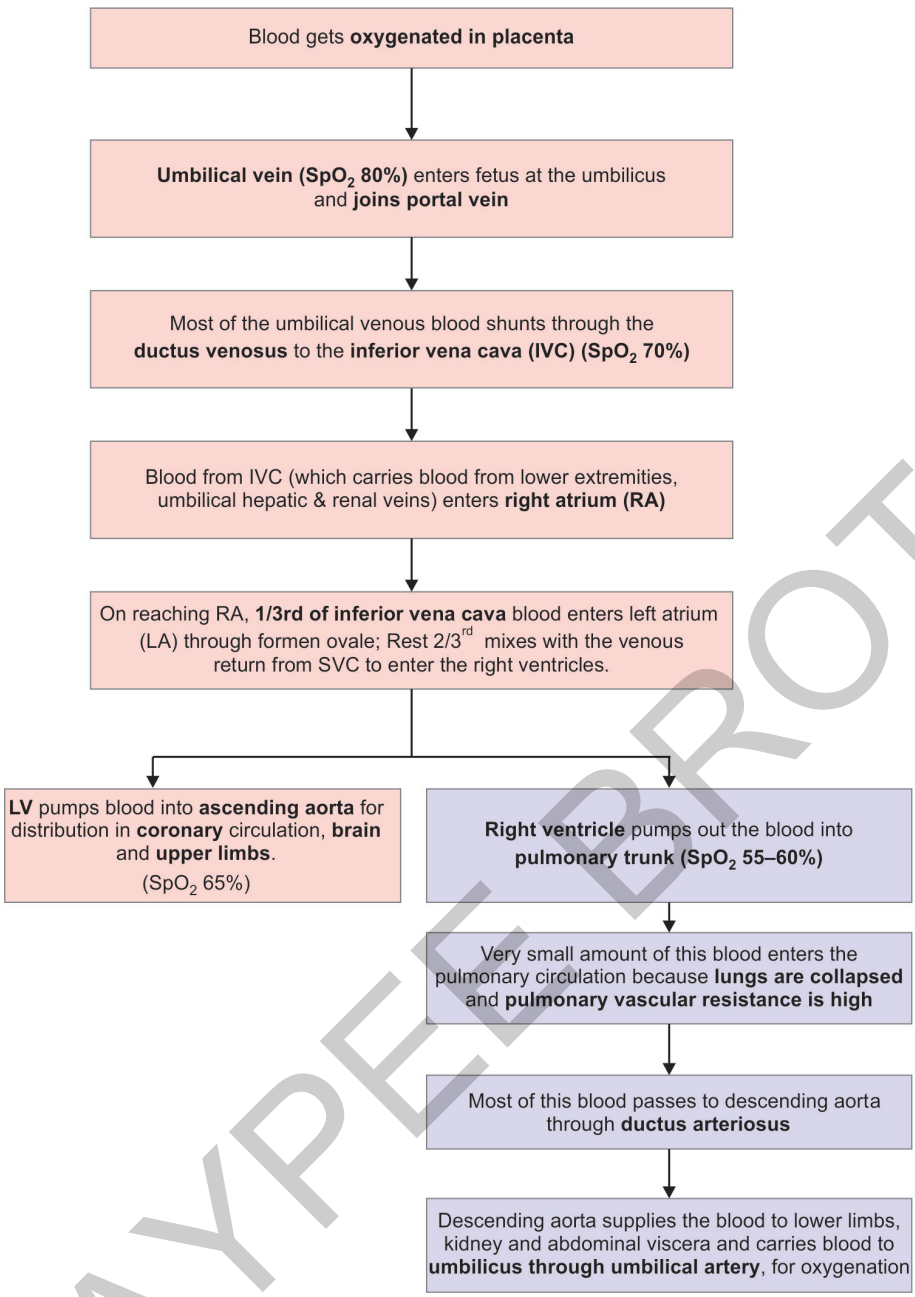

High Yield Points

In the fetal circulation:

- Blood in **IVC has more saturation than blood in SVC**
- **Left ventricular blood has more oxygen saturation than right**
- **Brain & coronary circulation receive blood with higher saturation** than the lower half of body
- **Left ventricular output is half** of right ventricular output
- Aorta and pulmonary trunk are connected by ductus arteriosus, and blood flows **from pulmonary trunk to aorta**

Remnants of Fetal Circulation

Structure	Remnant
Ductus arteriosus	Ligamentum arteriosum
Umbilical artery	Median umbilical ligament
Umbilical vein	Ligamentum teres hepatis
Ductus venosus	Ligamentum venosum

Structure	Physiological closure	Anatomical closure
Ductus venosus	10–96 hours	2–3 weeks
Ductus Arteriosus	Within 10–15 hours of birth	10–21 days
Foramen Ovale	At birth	3 months

High Yield Points

Changes in circulation after birth:

- **Lungs** become the **source of oxygen**
- **Pulmonary vascular resistance decreases** & blood flow to lung increases
- **Systemic vascular resistance increases**
- **Foramen ovale closes**
- **Ductus venosus closes** by day 7 of life
- **Ductus arteriosus closes**
- Increase in arterial **O_2** tension & decrease in concentration of **prostaglandins** plays an important role in closure of ductus

JAYPEE BROTHERS

Pressure in Different Chambers of Heart after Birth (in mm Hg)

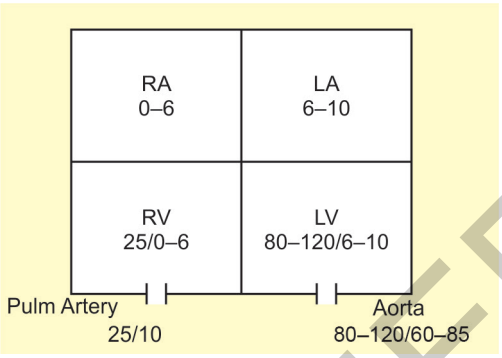

Note: These pressures in different chambers of heart usually **get established by 2–3 weeks** after birth; but, in presence of heart diseases like **VSD or PDA, it may take 6–10 weeks**.

MNEMONIC

Abnormalities in 22q del or velocardiofacial syndrome causes:

- **CATCH 22** (**conotruncal anomalies**)—**c**ardiac defects, **a**bnormal facies, **t**hymic hypoplasia, **c**left palate, **h**ypocalcemia.

High Yield Points

- Most congenital heart diseases are transmitted by **multifactorial inheritance pattern**
- **Strongest Familial tendency** for CHD is **Holt-Oram syndrome (AD)**—ASD with limb abnormalities
- **High altitude** delivery is a **risk factor** for development of **ASD and PDA**

CONGENITAL HEART DISEASE (CHD)

- Occurs in **0.8%** of live births
- Develop **between 3rd and 8th weeks** of Intrauterine life
- Transposition of the great arteries and **left-sided obstructive lesions** are slightly more **common in males**

NADA's Criteria

Used in the past to **diagnose presence of congenital heart disease**[Q].

Major	Minor
• Systolic murmur grade 3 or more • Any diastolic murmur • Cyanosis • Congestive heart failure	• Systolic murmur less than grade 3 • Abnormal S2 • Abnormal ECG • Abnormal chest X-ray • Abnormal BP

Presence of **1 major** or **2 minor criteria** indicate very **high probability of a CHD.**

Important Syndromes Associated with Congenital Heart Diseases

Syndrome	Associated congenital heart diseases
Down's syndrome (Trisomy 21)	**AV septal defect** (Most common)[Q], VSD, ASD
Noonan syndrome	**Pulmonary stenosis** and hypertrophic cardiomyopathy, ASD
Apert syndrome	Coarctation of aorta and VSD
Holt Oram syndrome	ASD[Q] and VSD
Ellis Van Creveld syndrome	Single atrium, ASD
TAR syndrome	***(Thrombocytopenia Absent Radius) syndrome*** ASD and TOF
DiGeorge syndrome	Cardiac outflow tract defects
Alagille syndrome	**Pulmonary artery stenosis**, Tetralogy of Fallot
William syndrome	Supravalvular aortic stenosis
Cri du chat syndrome ($5p^-$)	VSD, PDA, ASD

NEET PG PATTERN QUESTION

1. **A child with supravalvular aortic stenosis presents with the following facies. What is the syndrome this child is suffering from?**

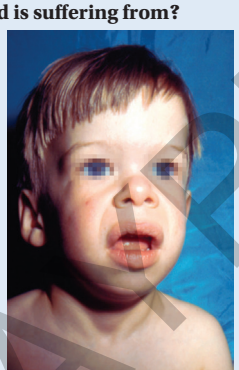

a. Williams syndrome
b. Turner syndrome
c. Noonan syndrome
d. Di George syndrome

JAYPEE BROTHERS

Classification of Congenital Heart Diseases

I. **Left to right shunts:**
   - **VSD** (Ventricular septal defects)
   - **ASD** (Atrial septal defects)
   - **PDA** (Patent ductus arteriosus).

II. **Ductus dependent Pulmonary blood flow: Right sided obstructive lesions like:**
   - Critical **pulmonary valve stenosis** with intact ventricular septum
   - Severe **Tetralogy of Fallot**
   - **Pulmonary atresia**
   - **Tricuspid atresia**
   - **Ebstein anomaly**

III. **Ductus dependent Systemic flow:** Left sided obstructive lesions like:
   - **Congenital severe aortic stenosis**
   - Severe **Coarctation** of the aorta
   - **Interrupted aortic arch**
   - Hypoplastic left heart syndrome **(HLHS).**

   These newborns present with **severely decreased cardiac output** leading to pallor, diminished peripheral pulses, low urine output & cool extremities.

IV. **Parallel circulation/Ductus dependent oxygenation**
   These are babies who are born with CHD that requires a patent ductus for adequate mixing of saturated and desaturated blood like **Transposition of great vessels** (TGV).

V. **Ductus independent cyanotic heart diseases**
   - **Total anomalous pulmonary venous return** (TAPVR)
   - **Truncus arteriosus**

High Yield Points

Common Points for all left to right lesions: (ASD, VSD and PDA)

- More common in **females**
- **Congestive cardiac failure** manifests around **6 weeks,** when pulmonary vascular pressures fall
- Due to **increased pulmonary blood flow**, they have recurrent lower **respiratory tract infections**
- **Infective endocarditis** is an important complication:
  - **Most common** in **VSD**[Q]
  - **Least likely: Ostium secundum ASD**[Q]
- Most **dangerous complication**: **pulmonary hypertension**[Q] **(PHT)**, which if left untreated will lead on to reversal of shunt (**Eissenmenger's syndrome**)
- PHT develops earliest in **PDA,**[Q] followed by VSD and comparatively late in ASD.

ATRIAL SEPTAL DEFECT (ASD)

Types: 4 Types

- Ostium primum
- **Ostium secundum (most common)**[Q]
- Sinus venosus type, (in upper part of atrial septum, where SVC enters)
- Coronary sinus type

Note: All the features discussed below are of Ostium secundum ASD (unless mentioned otherwise).

NEET PG Pattern Question

2. A patient with cyanosis presents with LVH and pulmonary complications. ECG, shows left axis deviation. Most likely diagnosis is:

a. TOF
b. Tricuspid atresia
c. TAPVC
d. VSD

Mnemonic

Important syndromes associated with ASD:

PeTAR FED HER

- **P**ierre-Robin syndrome
- **TAR** (Thrombocytopenia absent radius) syndrome
- **F**etal alcohol syndrome
- **E**llis-Van Crevald syndrome
- **D**own syndrome
- **H**olt-Oram syndrome
- **E**hler-Danlos syndrome
- **R**ubinstein-Taybi syndrome

NEET PG Pattern Question

3. Which congenital heart disease is associated with this child's condition?



a. ASD
b. VSD
c. PFO
d. PDA

JAYPEE BROTHERS

Hemodynamics

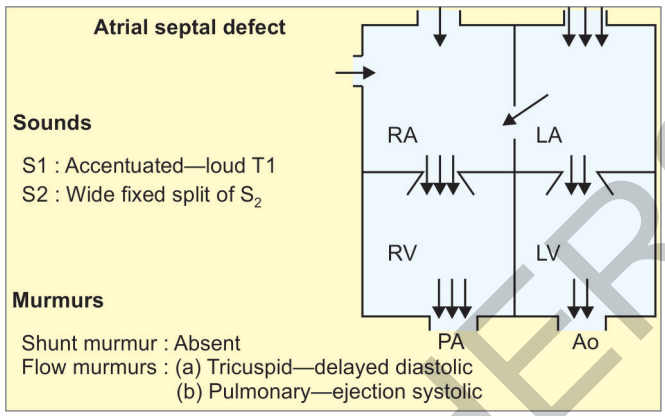

Assessment of severity

Larger the shunt→**louder** the pulmonary & tricuspid murmurs & more cardiomegaly.

Clinical Presentation

Usually asymptomatic.

Chambers Enlarged

Right atrium & right ventricle.

Chest X-ray Finding

RAH, RVH, pulmonary artery dilated.

ECG Finding

- **Right axis deviation** in **ostium secundum ASD (R-S)**
- **Left axis deviation** in **ostium primum ASD** (due to RV conduction defect).

Treatment

- In **asymptomatic cases**: Treatment is not required
- **Indications for Surgery:** All symptomatic patients and also for asymptomatic patients with a Qp: Qs (pulmonary blood: systemic blood) ratio of at least 2:1
- **Timing for elective closure** is usually after the 1st year and before entry into school
- **Procedure of choice** is percutaneous catheter device closure using an atrial septal occlusion device, implanted transvenously in the cardiac catheterization laboratory.

PATENT FORAMEN OVALE (PFO)

- Embryological **connection between left & right atrium** which usually closes after birth.
- Can be a channel for ***paradoxical embolization*** **(right to left)**.

High Yield Points

Katz-Wachtel phenomenon—common ventricular hypertrophy in **moderate VSD** is associated with **equiphasic QRS complexes in all precordial leads**

OSTIUM PRIMUM ASD

Defect is situated in the **lower portion of the atrial septum** and overlies the mitral and tricuspid valves.

JAYPEE BROTHERS

AV SEPTAL DEFECT/AV CANAL DEFECT/ENDOCARDIAL CUSHION DEFECT

Consists of contiguous **atrial & ventricular septal defects** with markedly abnormal AV valves. Common in children with **Down's syndrome**.

VENTRICULAR SEPTAL DEFECT (VSD)

Types: Membranous (more common)[Q] & Muscular.

High Yield Points

- **Restrictive VSD**—size of the lesion < 0.5 sq. cm
- **Nonrestrictive VSD**—size usually > 1.0 sq. cm, right and left ventricular pressure equalized
- **Qp:Qs ratio > 2:1** Indicates a large VSD with pulmonary blood flow more than double of systemic blood flow
- **Swiss Cheese septum**—is a special type of muscular VSD with multiple defects—difficult to close surgically

High Yield Points

- **Most common** congenital heart disease is **VSD**
- Most common congenital heart disease affected by **infective endocarditis** is **VSD.**

Hemodynamics

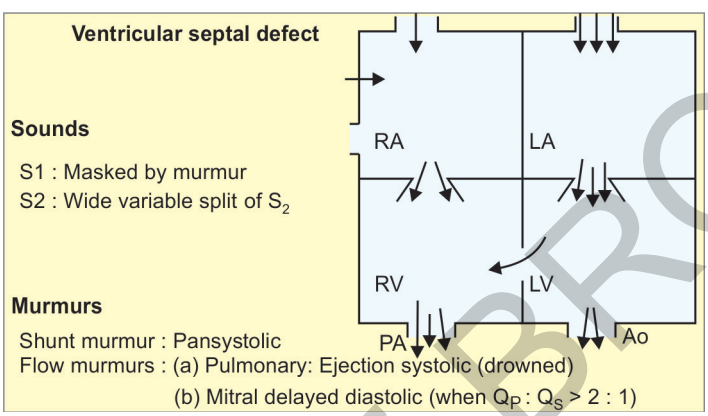

Assessment of severity

Larger the shunt: Shorter the systolic murmur and presence of Mid diastolic murmur in mitral area.

- **Chambers Enlarged:** Left atrium & left ventricle.
- **ECG:** Left Axis Deviation, Left atrial hypertrophy & left ventricular hypertrophy.
- **CXR:** Cardiomegaly with left ventricular apex and pulmonary plethora.

Management

Medical: Digoxin and Frusemide for treatment of heart failure.

Indications for surgery:

- **Any age** with **large defects in whom symptoms cannot be controlled medically**
- **6 to 12 months age** with **large defects** associated with pulmonary hypertension
- Patients **older than 24 months** with a **Qp:Qs ratio greater than 2:1**
- **Supracristal VSD of any size** (high risk of aortic regurgitation.
- Contraindication to closure of VSD: Severe pulmonary vascular disease non-responsive to pulmonary vasodilators.

Complications

Eisenmenger syndrome & infective endocarditis are 2 important complications of VSD.

NEET PG Pattern Question

4. A child with VSD develops the following findings. There is no history of fever. What is the probable cause of these findings?



a. Infective endocarditis
b. Eisenmenger syndrome
c. Cyanotic spell
d. Patent ductus arteriosus

JAYPEE BROTHERS

PATENT DUCTUS ARTERIOSUS (PDA)

Ductus arteriosus is a **connection between aorta & pulmonary artery.**

Hemodynamics

High Yield Points

- Drug used **to keep ductus open** in duct dependent conditions is **Alprostadil (PGE1 analogue)**[Q]
- **Differential cyanosis**[Q] is caused by **PDA with** pulmonary artery hypertension or reversal of shunt and **severe coarctation of aorta**

High Yield Points

- **Continuous murmur** is heard in—**PDA**, pulmonary and systemic **AV fistulas**, **ruptured sinus of Valsalva**, aorto-pulmonary defect, venous hum and persistent truncus arteriosus
- **To and fro murmur** (mimics continuous murmur)—**VSD with AR, repaired TOF**, combined AR and MR

Patent ductus arteriosus

Sounds

S1 : Accentuated—loud M1
S2 : Paradoxical splitting of S_2 in large PDA
S3 : With large shunt

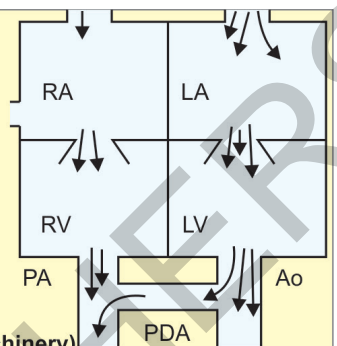

Murmurs

Shunt murmur : **Continuous (machinery)**
Flow murmurs : (a) Mitral delayed diastolic
(b) Aortic ejection systolic (drowned)

Assessment of severity

Larger the shunt—more cardiomegaly, MDM in mitral area and wider the pulse pressure.

Clinical features: Similar to VSD

Signs of PDA in a preterm baby:

- **Apnea** for unexplained reasons in an infant recovering from RDS
- **Hyperdynamic precordium** with **bounding peripheral pulses**
- **Wide pulse pressure**
- **Continuous or systolic murmur**
- **CO_2 retention** ±±Increasing oxygen dependence
- **Hepatomegaly**

ECG

Left atrial & left ventricular hypertrophy & left axis deviation.

CXR

Similar to VSD.

Management of PDA

High Yield Points

Indomethacin or Ibuprofen are **not effective in full term** infants or children with PDA

Medical

- In **preterm infants Ibuprofen or**, **Indomethacin**, inhibitors of prostaglandin synthesis can be used for medical closure of PDA; alternatively, paracetamol may also be used
- Management of **heart failure (Furosemide, Digoxin).**

Surgical

- If indomethacin is not successful and the ductus remains hemodynamically significant, **surgical ligation or coil embolisation (by cardiac catheterisation)** should be performed
- **Surgical closure** is done through **left thoracotomy approach**. Preferably **closed before 1 year of age**.

JAYPEE BROTHERS

EISENMENGER SYNDROME

Also called	Reversal of shunt
Definition	Reversal of shunt at the level of atria/ventricles/PDA, due to **irreversible pulmonary vascular obstructive changes**
Clinical features	Cyanosis & clubbing
Sequence of changes[Q]	Left to right shunt (VSD/PDA/ASD) ↓ Increased flow through the pulmonary vasculature (Hyperkinetic PAH) ↓ **Irreversible/obstructive pulmonary hypertension** ↓ Increased pressure in the right side of the heart and **right ventricular hypertrophy** ↓ **Right to left shunt** (Reversal of shunt)
Clinical features	Cyanosis & clubbing

BICUSPID AORTIC VALVE

- It is the **most common** heart disease in **Turner syndrome**[Q]
- **Treatment of choice** is **balloon valvuloplasty** for moderate to severe AS.

COARCTATION OF AORTA

- **Most common site:** 90% occur just **below the origin of the left subclavian artery at the origin of the ductus arteriosus (juxtaductal coarctation)**
- **More common in males**: Associated with **Turner syndrome** & **bicuspid aortic valve**.

Clinical Features

- **Severe CoA** presents in **newborn** period with **CCF with weak femoral pulses**
- Milder forms can present in older children with **weakness and pain in legs after exercise** and incidentally detected hypertension
- **Disparity in pulsation and blood pressure** in the arms and legs
- The **femoral**, **popliteal**, posterior tibial, and dorsalis pedis **pulses are weak** (or absent in up to 40% of patients), in contrast to the bounding pulses of the arms and carotid vessels.

Chest X-ray

- **'Figure of 3 appearance'** due to pre-stenotic & post-stenotic dilatation
- **'E sign'** seen on contrast esophagogram, due to pressure on anterior wall of esophagus
- **Notching of the inferior border of 3rd-9th ribs** from pressure erosion by enlarged collateral vessels, usually seen beyond the age of 3 years.

Treatment

- **Severe** COA is ductus dependent and using **PGE1** can be life saving
- **Surgery** is done after stabilisation—resection of the coarctation with end to end anastamosis is the treatment of choice
- For recoarctation, **balloon angioplasty** is the treatment of choice.

NEET PG Pattern Question

5. A 6-year-old child presents with hypertension. A chest X-ray was done, which showed the following picture. What is the congenital heart disease this child is suffering from?

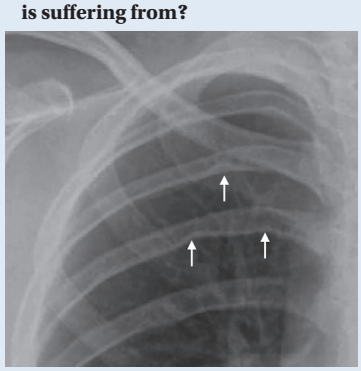

a. Atrial septal defect
b. Bicuspid aortic valve
c. Patent ductus arteriosus
d. Coarctation of aorta

JAYPEE BROTHERS

CYANOTIC CONGENITAL HEART DISEASES (CCHD)

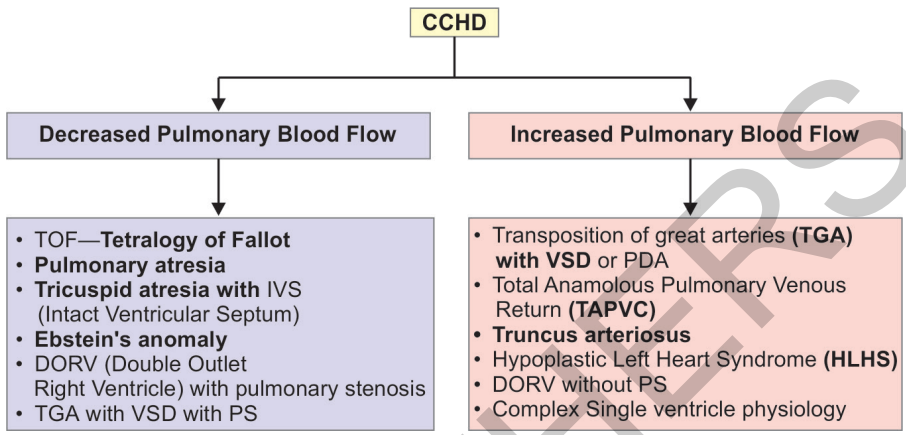

High Yield Points

- **Acyanotic/Pink tetralogy of Fallot:** When obstruction to right ventricular outflow is mild-moderate, the patient is not cyanotic
- **Heart Failure is uncommon in TOF** except in anemia, Infective endocarditis, hypertension, myocarditis

TETRALOGY OF FALLOT (TOF)

High Yield Points

- **Trilogy of Fallot** = ASD + RVH + PS
- **Pentalogy of Fallot** = TOF + ASD

Four Components

① **Obstruction to RV outflow tract** (mostly **infundibular pulmonary stenosis**)
② **VSD—large unrestricted** outlet type of VSD
③ Dextroposition of aorta (**over-riding of Aorta**)
④ **Right ventricular hypertrophy** (RVH).

Hemodynamics

NEET PG Pattern Question

6. In which cyanotic heart disease the following chest X-ray findings are seen?

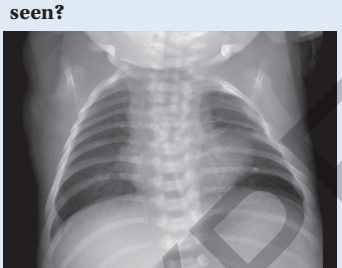

a. TOF b. TGA
c. VSD d. TAPVC

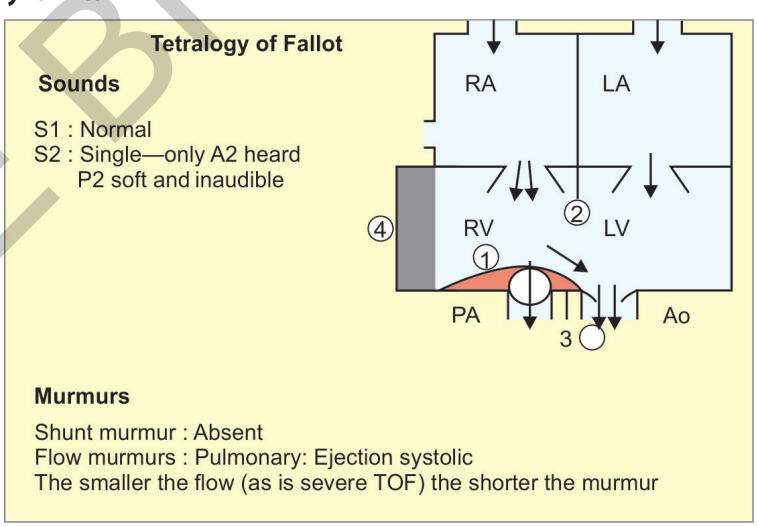

High Yield Points

Severity of TOF is directly proportional to severity of cyanosis, while it is inversely proportional to duration & intensity of murmur

Clinical Features

- **Infants** — May present as a **ductal dependent lesion**
- Older children —C**yanosis**, **clubbing,** dyspnea on exertion & cyanotic spells.

High Yield Points

Murmur of TOF becomes **less** prominent with severe obstruction and **hypercyanotic spell**

Examination Findings

- Prominent left anterior hemithorax in older children (due to long standing RVH)
- A **systolic thrill/systolic murmur** in left sternal 2nd-3rd parasternal space caused by turbulence through right ventricular outflow tract
- **Single 2nd heart sound** or soft pulmonary component.

JAYPEE BROTHERS

Why Cyanotic Spell Occurs?

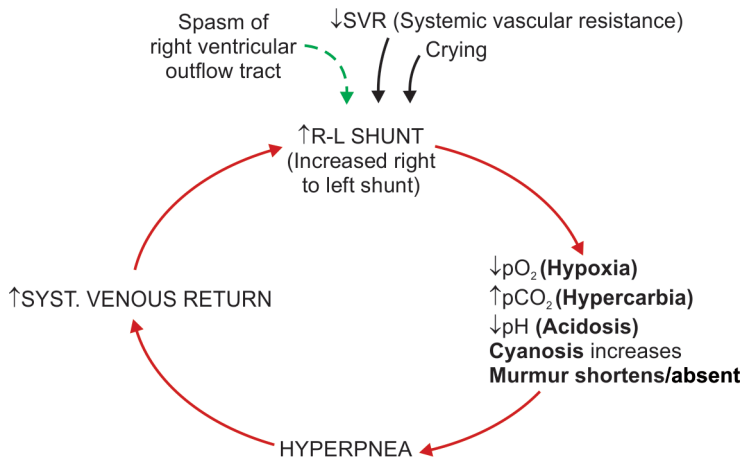

High Yield Points

Chest X-ray in TOF shows

"Cor en sabot" (Boot shaped heart) due to cardiac apex elevation (due to right ventricular hypertrophy), **pulmonary oligemia**.

High Yield Points

Complications of TOF

- **Cerebral thromboses:**
  - Common in **children < 2 years**
  - Involves **cerebral veins or dural sinuses** & occasionally cerebral arteries.
  - Iron deficiency anemia, polycythemia & dehydration aggravate thromboses.
- **Brain abscess**
  - Common **after 2 years** age
  - Insidious onset of **fever** or gradual **behavior change** are the common presentations.
- **Bacterial endocarditis** may occur

Treatment of TOF

i. Treatment of Cyanotic Spell

Treatment modality	How it helps?
Squatting or knee chest position[Q]	Increases systemic vascular resistance & Decreases venous return
100% oxygen	Combats hypoxia
IV/SC morphine[Q] ***0.1–0.2 mg/kg***	Depresses respiratory centre
Soda bi carbonate[Q]	Neutralizes acidosis
β blocker (IV propranolol)[Q]	Causes systemic **vasoconstriction**
Methoxamine or phenylephrine	**α agonist** → Causes systemic vasoconstriction

ii. Supportive Therapy

Correction of **iron-deficiency anemia**; prevention of spell (propranolol).

iii. Surgical Treatment of TOF

Corrective—

- **Resection of RVOT obstruction** and patch closure of VSD
- Electively between 4–6 months of age in case of less severe cyanosis without spells
- Immediately in infants with severe cyanosis (marked right ventricular outflow obstruction)

Palliative—shunt surgeries that connect aorta or its branch to pulmonary artery & increase pulmonary blood flow.

NEET PG Pattern Question

7. **A neonate presenting with heart failure on day 7 of life has this chest X-ray. What is the most probable diagnosis?**

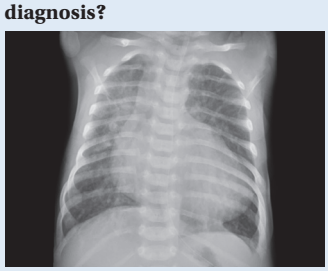

a. TOF b. VSD
c. TAPVC d. TGA

High Yield Points

Shunt surgeries for Tetralogy of Fallot

Name of shunt	Pulmonary artery to
Blalock Taussig	**S**ubclavian artery
Waterston's	**A**scending aorta
Pott's	**D**escending aorta

High Yield Points

- **TGA** is the **most common CCHD** in a **neonate** and 2nd most common CCHD in infancy
- TGA is associated with **uncontrolled Phenylketonuria in mother.**[Q]
- TGA is the most **specific heart disease** in **infant of diabetic mother**

JAYPEE BROTHERS

TRANSPOSITION OF GREAT ARTERIES (TGA)

Transposition of Great vessels is a condition characterized by **aorta arising from the right ventricle** and **pulmonary artery from the left ventricle**.

Hemodynamics

- In TGA, there is **complete separation** of **systemic and pulmonary circulation**
- Since systemic and pulmonary circulations are separate, **survival depends on mixing** of oxygenated pulmonary blood and deoxygenated systemic blood which can occur:

  At **Atrial level** : Through **ASD**

  At **Ventricle level** : Through **VSD**

  At **Great vessel level** : Through **Patent ductus arteriosus**
- Oxygenation is normal in fetus but after birth as ductus arteriosus closes, severe hypoxia occurs & in absence of VSD, or ASD, child presents with cyanosis & tachypnea at birth

High Yield Points

X-ray Features of TGA

- **Cardiomegaly with "Egg on Side"** appearance[Q]
- **Plethoric lung fields** (Increased pulmonary vascularity)
- Absent thymic shadow

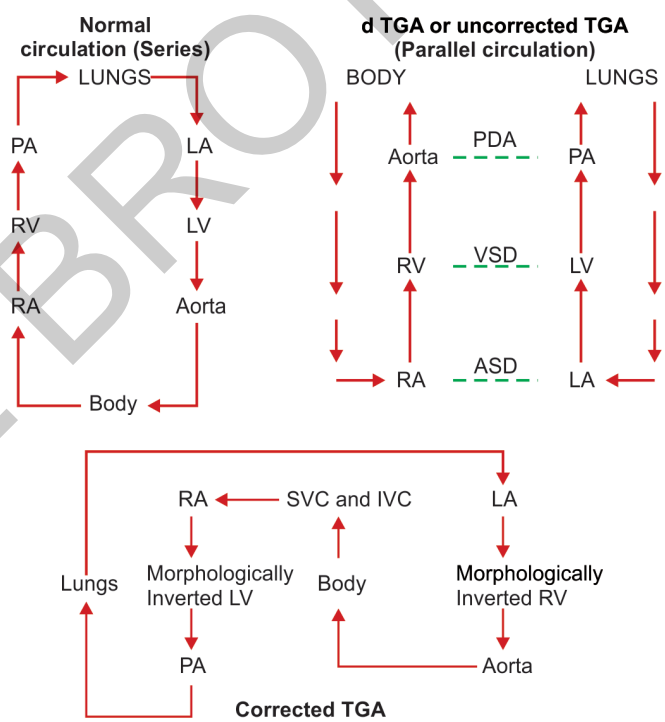

High Yield Points

- CHD which present with **cyanosis at birth** are: **TGA, TAPVC, Tricuspid atresia, pulmonary atresia, Ebstein anomaly**
- In TOF cyanosis usually presents after neonatal period

- In **d TGA**, **aorta** lies to the **right & anterior** of pulmonary artery
- In **Corrected TGA**, there is **atrioventricular and ventriculoarterial discordance.**

Clinical Features of TGA

- **Time of presentation depends** on whether the **ventricular septum** is intact or VSD is present
- Patients of TGA with **intact septum** are **cyanotic at birth**, with CHF occurring in first week because adequate mixing does not occur
- Patients of TGA **with VSD** presents with mild cyanosis and CHF occurs in **6–8 weeks**.

JAYPEE BROTHERS

- **Important manifestations are:**
  - Cyanosis
  - CHF
  - Ejection systolic murmur
  - Single S2
  - Normal S1

Treatment

- Administration of **PGE1** will keep the ductus arteriosus open temporarily & allow mixing of blood of pulmonary & systemic circulation & cause **transient improvement**
- **Balloon atrial septostomy** is a an **emergency procedure** to save the life of this neonate.
- **Definitive surgery: Arterial switch operation or 'Jatene repair'.**

TAPVC (TOTAL ANOMALOUS PULMONARY VENOUS CONNECTION)

Basic Defect

Pulmonary veins instead of draining into Left atrium drain into **right atrium** directly or indirectly.

Three Types

Supracardiac: Common pulmonary vein drains into Superior vena cava or left innominate vein

Cardiac: Pulmonary veins drain into **right atrium or coronary sinus**

Infracardiac: Pulmonary veins drain into **hepatic veins or portal vein or inferior vena cava**

Chest X-ray Findings

Supracardiac TAPVC: **Snowman** or '**figure of 8**' appearance

Obstructive TAPVC: **Ground glass appearance** of lung fields (d/d hyaline membrane disease)

HYPOPLASTIC LEFT HEART SYNDROME (HLHS)

HLHS is a group of anomalies that include **underdevelopment of the left side of the heart** & hypoplasia of ascending aorta.

Clinical Features: Cyanosis & heart failure seen **within first few days of life**.

High Yield Points

HLHS is the most common congenital heart disease causing **mortality in the 1st week of life**.

TRICUSPID ATRESIA

- **Congenital absence of tricuspid valve is called tricuspid atresia**
- There is **Hypoplastic right ventricle** with absence of inflow portion of RV
- So, blood cannot flow directly from right atrium to right ventricle and following associated defect, are necessary for survival:
  - For flow of blood from RA to LA: **Patent foramen ovale or ASD**.
  - For flow of blood from LV to RV: **VSD**
- **Left ventricular hypertrophy** with **left axis deviation** is seen in ECG

EBSTEIN ANOMALY

Ebstein anomaly consists of **downward displacement of an abnormal tricuspid valve** into the right ventricle, leading to **atrialization of right ventricle.**

NEET PG Pattern Question

8. The following X-ray picture is seen in which CCHD?

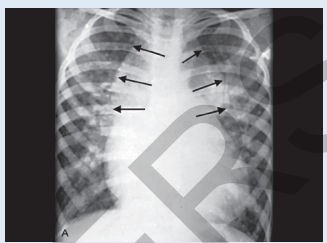

a. TGA
b. TAPVC
c. TOF
d. Tricuspid atresia

High Yield Points

- **Most common** type of TAPVC is **supracardiac**
- **Infracardiac** TAPVC is **always obstructive**

NEET PG Pattern Question

9. A 2-month-old baby with central cyanosis presented with the following findings on chest X-ray & ECG. What is the most probable underlying diagnosis?

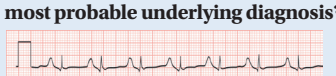

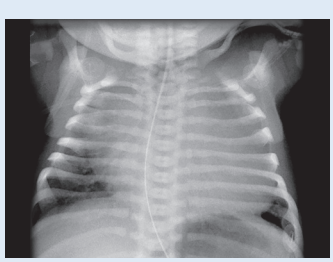

a. Tetralogy of Fallot
b. Hypoplastic left heart syndrome
c. Coarctation of aorta
d. Ebstein anomaly

JAYPEE BROTHERS

High Yield Points

Anomalous origin of left coronary artery from pulmonary artery (Alcapa):

- **Blood supply** to the **left ventricular** myocardium is **severely compromised**
- Soon after birth, as pulmonary arterial pressure falls, perfusion pressure to left coronary artery becomes inadequate; **myocardial ischemia**, infarction, & fibrosis result
- **ECG** resembles **lateral wall myocardial infarction**.

Hemodynamics

- **Right atrium is enlarged** as a result of **tricuspid valve regurgitation**
- Effective **output** from the right side of the heart is **decreased** because of poorly functioning small right ventricle, tricuspid valve regurgitation & obstruction of the right ventricular outflow tract produced by large, sail-like, anterior tricuspid valve leaflet
- **Right ventricle** is unable to generate enough force to open the pulmonary valve in systole, thus producing **"functional" pulmonary atresia**
- The increased volume of right atrial blood shunts through the foramen ovale (or through an associated atrial septal defect) to the **left atrium** and produces cyanosis.

Auscultation: A **gallop rhythm** with **multiple clicks** at lower left sternal border.

Chest X-ray: Box shaped heart[Q].

ECG: Himalayan P waves

RHEUMATIC FEVER/RHEUMATIC HEART DISEASE (RHD)

RHD is the **most common cause of heart disease in children** in **developing countries.**[Q]

High Yield Points

Valvular Involvement in RF:

- 100% of pts. with RF have pathological **mitral valve** involvement
- **95% have clinical MR**
- 5–8% presents with pure AR
- 20–25% have both AR and MR
- Clinical evidence of pulmonary valve involvement in acute RF never seen

Epidemiology

- Most common age group involved is **5–15 years**
- **Mitral valve disease** and **chorea** are more common in **females**
- **Aortic** valve involvement is more common in males
- **Most common major** manifestation of RHD in children is **Carditis**, seen in 50–60%
- **Second** most common manifestation in children—**arthritis**—30–50%

Diagnostic Criteria for Rheumatic Fever

Modified Jone's Criteria

Low risk	Moderate to high risk
Incidence ≤2/lakh school going children	Incidence >2/lakh school going children
Rhd prevalence ≤1/1000	Rhd prevalence >1/1000

Major Criteria

- **Carditis** (clinical or subclinical): 50–60%
- **Arthritis** (low risk population: polyarthritis, moderate to high risk population: polyarthritis, monoarthritis, polyarthralgia): 75%
- **Chorea** (Sydenham's chorea): 10–15%
- **Erythema marginatum:** 1%
- **Subcutaneous nodules:** <1%

Minor Criteria

- Polyarthralgia (low risk population), monoarthralgia (moderate to high risk population)

JAYPEE BROTHERS

- Fever
- Increased ESR/CRP
- Prolonged PR interval

Essential Criteria

Evidence of antecedent group A streptococcal infection (increased or rising ASO titres)

Modified Jone's Criteria

- Initial episode of RF = 2 major or 1 major + 2 minor criteria
- Recurrence of RF = 2 major or 1 major + 2 minor or 3 minor

Treatment of RF

- For all patients with carditis **bed rest** is recommended
- **Antibiotic Therapy**—(to eradicate streptococci in throat) single dose benzathine penicillin, or 10 days oral penicillin V or erythromycin
- **Anti-inflammatory Therapy:**

Aspirin	Steroid
• Given in **Arthritis or mild carditis**. • Dosage is 100 mg/kg/day for 2–3 weeks. • Then dose is tapered and given for a total period of 12 weeks	• Given in **carditis with CCF & cardiomegaly** • Prednisolone is the drug of choice • Dosage: 2 mg/kg/day for 2–3 weeks (or till ESR normalizes) and then tapered • Total duration of treatment 12 weeks.

Secondary Prophylaxis in Rheumatic Heart Disease (as per AHA)

Drug used & Dosage: inj. Benzathine penicillin IM 6 lakh IU in children </= 27 kg
Inj. Benzathine penicillin IM 1.2 million IU in > 27 kg every 3-4 weeks

Recommended duration:

- **ARF with carditis and residual heart disease:** Until age 40 years or for 10 years after last ARF (whichever is longer); lifetime prophylaxis may be needed
- **ARF with carditis but no residual heart disease:** Until age 21 years or 25 years (as per WHO) for 10 years after last ARF (whichever is longer)
- **ARF without carditis:** Until age 18 years or for 5 years after last ARF (whichever is longer)

NEET PG Pattern Question

10. The skin lesions shown in this picture are seen in which heart disease?



a. Eisenmenger syndrome
b. Rheumatic heart disease
c. Infective endocarditis
d. Heart failure

High Yield Points

Prophylaxis for RF should be started **within 9th day** of onset of symptoms of acute streptococcal **pharyngitis** for being effective.

HEART FAILURE (HF)

Definition

Heart failure occurs when the **heart cannot deliver adequate cardiac output to meet the metabolic needs** of the body. HF can be due to **systolic dysfunction** (decreased EF) or **diastolic dysfunction** (normal EF).

Timing of Heart Failure

Birth 1 week	1–4 weeks	1–2 months	2–6 months
• Ductus dependent systemic circulation – HLHS – Critical AS – Severe coarctation – Interrupted Aortic arch • Obstructed TAPVC • D-TGA with Intact ventr septum • Cong. severe MR or TR • Ebstein anomaly	• PDA in pre term • VSD with coarctation • Truncus arteriosus • TGA with VSD or PDA	• PDA in term • VSD • ALCAPA • Non-obstructive TAPVC	• PDA • VSD • ALCAPA • Coarctation of aorta • Endocardial cushion defect

High Yield Points

- The **leading cause** of HF in infants and children is congenital heart diseases **(CHD)**
- Most common cause of heart failure in **older children** is **rheumatic heart disease**.

JAYPEE BROTHERS

Clinical Features

- **Symptoms** of CCF in **infant**: **Feeding difficulty**, forehead **sweating**, fast breathing and signs of **tachycardia**, **tachypnea**, **hepatomegaly** and **cardiomegaly**
- Most common symptoms of HF in **older** children is—**fatigue** and shortness of breath.
- **Right heart** failure: Elevated JVP, facial puffiness, tender hepatomegaly, edema of feet
- **Left heart** failure: Tachypnea, tachycardia cough, wheezing, rales in chest, dyspnea on exertion orthopnea, PND (Paroxysmal nocturnal dyspnoea)
- Features of **both right and left heart failure**—cardiac enlargement, gallop rhythm, peripheral cyanosis, small volume pulse, absence of weight gain.

Chest X-ray Finding

- **Cardiomegaly** is a very important sign on CXR in almost all types of Heart failure.
- **A cardiothoracic ratio of > 60% in neonates** and **> 55% in older children** is suggestive of cardiomegaly.

Treatment of CCF

- **Diuretics (Furosemide):** Usual 1st line treatment
- Next line: **ACE inhibitors** and Angiotensin Receptor Blockers
- **Digoxin** helps by improving cardiac contractility
- Chronic treatment with **beta blockers** like carvedilol, metaprolol—is used in patients with cardiomyopathy with chronic failure
- **Milrinone**—is useful in treating patients with low cardiac output who are refractory to standard therapy esp. after open heart surgery.

NEET PG Pattern Question

11. A 4-year-old girl always had to wear warm socks even in summer season. On physical examination, it was noticed that she had high blood pressure and her femoral pulse was weak as compared to radial and carotid pulse, a chest radiography showed 'figure of 3'. This was due to:

a. Femoral artery thrombosis
b. Coarctation of aorta
c. Raynaud's disease
d. Takayasu arteritis

High Yield Points

- In children **most common** cause of hypertension is **secondary** hypertension
- Secondary hypertension in children is mostly due to **renal** abnormalities (90%)

SYSTEMIC HYPERTENSION

Definition

Hypertension in children is defined as average systolic blood pressure (SBP) and/or diastolic blood pressure (DBP) that is ≥**95th percentile** for age, sex, and height on ≥ three occasions.

Prehypertension

Prehypertension is defined as average SBP or DBP that are ≥ **90th percentile but< 95th** percentile.

Etiology of Hypertension in Children

High Yield Points

- **Renal parenchymal disease** is the **most common cause** followed by renovascular hypertension.
- **Chronic glomerulonephritis** accounts for most common cause of HT in children.
- Most common cause of hypertension in the **newborn** period—associated with **umbilical artery catheterization** and renal artery thrombosis
- Most common congenital **cardiovascular cause** of hypertension—**coarctation of aorta**.

Renal
- Chronic pyelonephritis
- Chronic glomerulonephritis
- Congenital dysplastic kidney
- Multicystic kidney
- Vesicoureteral reflux nephropathy

Vascular
- Coarctation of aorta
- Renal artery stenosis/Renal vein thrombosis
- Umbilical artery catheterization with thrombus formation
- Neurofibromatosis (intrinsic or extrinsic narrowing of vascular lumen)
- Vasculitis

Endocrine
- Hyperthyroidism
- Hyperparathyroidism
- Congenital adrenal hyperplasia (11β-hydroxylase and 17-hydroxylase defect)
- Cushing syndrome
- Primary aldosteronism
- Apparent mineraolcorticoid excess
- Glucocorticoid remedial aldosteronism (familial aldosteronism type 1)
- Pheochromocytoma
- Neuroblastoma

Central nervous system
- Intracranial mass/Hemorrhage

JAYPEE BROTHERS

Treatment

- For **asymptomatic mild** hypertension without evidence of target organ damage: lifestyle **modification** with dietary changes and regular exercise
- Indications for **pharmacologic** therapy: **Symptomatic** hypertension, **secondary** hypertension, hypertensive **target organ damage**, **diabetes** (types 1 and 2), and persistent hypertension despite non-pharmacologic measures
- **Drugs used:** ACE inhibitors, angiotensin receptor blockers, β-blockers, calcium channel blockers, and diuretics.

High Yield Points

High-risk cardiac lesions for which **endocarditis prophylaxis is advised** before dental procedures are:

- **Prosthetic heart valves**
- **Prior endocarditis**
- Congenital heart disease

INFECTIVE ENDOCARDITIS (IE)

Clinical Features

Prolonged low grade fever with **new or changing murmurs** is the most common clinical manifestation.

High Yield Points

- **Staphylococcal** endocarditis is more common in patients with **no** underlying heart disease;
- **Viridans** group streptococcal infection is more common after **dental procedures**;
- **Fungal** organisms are encountered **after open heart** surgery.
- **Coagulase-negative staphylococci** are common in the presence of an **indwelling central venous catheter**
- **Most common symptom** of infective endocarditis is **fever**
- Other manifestations due to **vasculitis** produced by circulating antigen-antibody complexes include:
  - **Osler nodes** (tender, pea-sized nodules in pads of fingers).
  - **Janeway lesions** (painless erythematous lesions on palms & soles)
  - **Splinter hemorrhages** (linear lesions beneath the nails).
- **Investigation of choice** is **blood culture** (3 sets at least 1 hour apart).

Diagnosis

Modified Duke criteria help in the diagnosis of endocarditis:

Major criteria include:

(1) **Positive blood cultures** (2 separate cultures for a usual pathogen, 2 or more for less typical pathogens), and (2) **evidence of endocarditis on echocardiography** (intracardiac mass on a valve or other site, regurgitant flow near a prosthesis, abscess, partial dehiscence of prosthetic valves, or new valve regurgitant flow).

Minor criteria include: predisposing conditions, **fever**, embolic-**vascular signs**, **immune complex phenomena** (glomerulonephritis, arthritis, rheumatoid factor, Osler nodes, Roth spots), a single positive blood culture or serologic evidence of infection, and echocardiographic signs not meeting the major criteria.

2 major criteria or **1 major and 3 minor**, or **five minor** criteria suggest definite endocarditis.

Treatment

- **Empirical therapy** before the identifiable agent is recovered initiated with **vancomycin plus ceftriaxone** to cover S. aureus, enterococcus or viridans streptococci
- **6 weeks** treatment is recommended.

High Yield Points

Most common cause of myocarditis in Infant = Coxsackie virus

NEET PG Pattern Question

12. Choose the TRUE statement regarding the disease depicted in the images below:

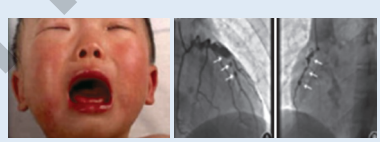

a. IV immunoglobulin is used in treatment
b. Bilateral purulent conjunctivitis
c. Lymphadenopathy is rare
d. Aspirin is contraindicated

NEET PG Pattern Question

13. Children born to mothers with systemic lupus erythematosus are likely to have one of the following anomalies:

a. Atrial septal defect
b. Tetralogy of Fallot
c. Transposition of great vessels
d. Complete heart block

JAYPEE BROTHERS

CARDIOMYOPATHY

Definition

Cardiomyopathy refers to a group of **diseases of heart muscle** that is not secondary to structural heart disease, hypertension or pulmonary vascular disease.

Classification

Three main categories—**dilated, hypertrophic & restrictive.**

High Yield Points

- **Dilated cardiomyopathy** is the **most common** form of cardiomyopathy **in children**.
- **Vitamin deficiency** associated with cardiomyopathy: **Thiamine** deficiency (beri beri)
- **Mineral deficiency** associated with cardiomyopathy: **Selenium** deficiency (**Keshan** disease)
- Dilated cardiomyopathy is the **most common cause for cardiac transplantation** in children.

Etiology

- **Primary cardiomyopathy**–etiology unknown
- **Secondary cardiomyopathy**—
  - **Infection**–Viral, bacterial, parasitic, rickettsial
  - **Collagen** vascular diseases–SLE, dermatomyositis
  - **Metabolic**–Beriberi, Pompe disease, Mucopolysaccharidosis
  - **Medications**–Adriamycin, phenothiazine, lead
  - **Neoplastic**–Rhabdomyoma, myxoma, Leukemia, Lymphoma
  - **Neurological**–Friedrich ataxia, muscular dystrophies
  - **Hematological**–Sickle cell anemia, TTP.

JAYPEE BROTHERS

Answer Keys for Image-based Questions

Answers	Explanations/Identifying features
1. Ans. a. Williams syndrome	This child has round face, long philtrum, upturned nostrils (elfin facies) with **supravalvular aortic stenosis**, as seen in William syndrome
2. Ans. b. Tricuspid atresia	Left axis deviation in a child with congenital cyanotic heart disease is suggestive of tricuspid atresia
3. Ans. a. ASD	This child with **micrognathia & retrognathia** has **Pierre Robin syndrome**, which is associated with ASD
4. Ans. b. Eisenmenger syndrome	**Clubbing & cyanosis** in a child with VSD, with no history of fever, has **Eisenmenger syndrome**
5. Ans d. Coarctation of aorta	Chest X-ray showing **notching of inferior border of ribs**, in a child with hypertension suggests Coarctation of aorta
6. Ans. a. TOF	Chest X-ray showing **boot shaped heart** is seen in **Tetralogy of Fallot** (TOF)
7. Ans. d. TGA	Chest X-ray showing **'egg on side' appearance** in a neonate presenting with **heart failure** on day 7 of life has **TGA** (Transposition of great arteries)
8. Ans. b. TAPVC	Chest X-ray showing **'snowman' or 'figure of 8'** appearance is seen in **supracardiac TAPVC**
9. Ans. d. Ebstein anomaly	ECG showing **tall (Himalayan) P waves** & chest X-ray showing '**box shaped heart'** are seen in Ebstein's anomaly
10. Ans. b. Rheumatic heart disease	Skin lesions suggestive of **erythema marginatum** are seen in Rheumatic heart disease
11. Ans. b. Coarctation of aorta	**Hypertension, Weak femoral pulses and notching of inferior margin of ribs** point towards **Coarctation** of aorta.
12. Ans. a. IV immunoglobulin is used in treatment	*The given clinical picture shows **erythematous rash and strawberry tongue** and the angiography image shows **Coronary artery aneurysm**. These findings point towards a diagnosis of **Kawasaki disease.*** **IV Immunoglobulin is used as treatment of choice for Kawasaki disease.** For details about Kawasaki disease refer chapter 8, Diseases of Immune system.
13. Ans. d. Complete heart block	**Congenital complete AV block** • It is presumed to be caused by **autoimmune injury of fetal conduction system by maternally derived anti-SSA/Ro, anti-SSB/La antibodies in a mother with systemic lupus erythematosus (SLE) or Sjögren syndrome** • **Autoimmune disease accounts for 60-70% of all cases of congenital complete heart block**

JAYPEE BROTHERS

Questions

FETAL CIRCULATION

1. Which of the following causes the closure of ductus arteriosus? *(INI CET Nov 2024)*

a. Increase in oxygen
B Decrease in CO_2
c. Increase in pulmonary vascular resistance
d. Fall in concentration of catecholamines

2. In children diagnosed with congenital heart disease, NADA's criteria include all of the following, *except*: *(INI CET Nov 2024)*

a. Diastolic murmur-Any grade
b. Increased troponin-T
c. Abnormal X-ray
d. Congestive cardiac failure

3. Nada's Minor Criteria includes: *(INI CET May 2023)*

1. Systolic murmur Grade 3
2. Diastolic murmur
3. Abnormal second heart sound
4. Abnormal BP

a. 3 and 4 b. 1, 2 and 3
c. 1, 2, 3 and 4 d. 2, 3 and 4

4. The parents notice that the child is tired, and notice that he feels shortness of breath on climbing stairs and in supine position. First investigation that you would do: *(INI CET Nov 2022)*

a. Chest X-ray
b. MRI to rule out enlarged heart
c. Spirometry
d. Echo

5. Which vessel is responsible for carrying deoxygenated blood back to the placenta in fetal circulation? *(NEET PG 2021 Pattern)*

a. Umbilical artery
b. Umbilical Vein
c. Descending Aorta
d. Pulmonary Artery

6. Which of the vessels carries deoxygenated blood back to placenta in fetal circulation? *(NEET PG 2021 Pattern)*

a. Umbilical vein
b. Umbilical artery
c. Descending aorta
d. Pulmonary artery

7. In fetal circulation, maximum oxygen saturation is seen in: *(NEET Pattern 2020)*

a. SVC
b. IVC
c. Ascending aorta
d. Right ventricle

8. Oxygenated blood from fetus is carried by: *(Recent Question 2015, WBPG 2010)*

a. Umbilical artery
b. Umbilical vein
c. Ductus venosus
d. Hypogastric artery

9. Umbilical cord has: *(DNB Dec 2010)*

a. 1 vein and 2 arteries
b. 2 vein and 2 arteries
c. 1 vein and 1 artery
d. 2 veins and 1 artery

ACYANOTIC CONGENITAL HEART DISEASES

10. A child presents with recurrent pneumonia and respiratory distress but no cyanosis. A continuous murmur is heard below the left clavicle. What is the most probable diagnosis? *(INICET Nov 2025)*

a. Ventricular septal defect (VSD)
b. Atrial septal defect (ASD)
c. CoA
d. Patent ductus arteriosus (PDA)

11. What is the most likely diagnosis for a newborn with weak lower limb pulses and strong upper limb pulses? *(FMGE July 2024)*

a. Tetralogy of Fallot
b. Coarctation of aorta
c. Transposition of great arteries
d. Ebstein's anomaly

12. A child presented with decrease pulse in lower limb and delay as compared to pulse felt in upper limb. What can be the underlying condition?

a. Transposition of great arteries *(INI CET Nov 2022)*
b. Ventricular septal defect
c. Tetralogy of Fallot
d. Coarctation of Aorta

13. Which drug is preferred in premature neonates for closure of PDA? *(FMGE June 2021)*

a. Ibuprofen
b. Indomethacin
c. Mefenamic acid
d. Paracetamol

JAYPEE BROTHERS

for detailed information on pediatric books, visit our website www.ejaypee.com, for detailed information on pediatric books, visit our website www.ejaypee.com, for detailed informatio

REVIEW OF PEDIATRICS & NEONATOLOGY

10 reasons why you should buy this book:

- Fully colored book with point-wise pretexts of all chapters for concept-building
- Exam-oriented, high-yield rapid revision tool for last-minute revision and exam confidence
- Integrated Pediatrics and Neonatology in one compact resource
- Focused coverage for NEET PG, INI-CET and FMGE exams
- Also useful for MBBS prof exams, UPSC CMS exams and DM entrance exams
- Bullet points, tables, and flowcharts for quick recall
- Image-based and case scenario-based exam preparation as per the NEXT pattern
- Important Annexures for last-minute revision
- Updated with latest guidelines and recent advances
- Useful for repeated rapid revisions and self-assessment.

Meenakshi Bothra Gupta has done her MBBS from Medical College, Kolkata and post-graduation along with senior residency from All India Institute of Medical Sciences, New Delhi, India. She has been a recipient of many prestigious awards, including Best MBBS student from Medical College (Kolkata), Gold Medals in Pathology, Preventive and Social Medicine and Gynecology and Obstetrics during her MBBS. She also received Honours in Anatomy, Physiology, Pathology, Forensic and State Medicine, ENT, PSM, Surgery and Pediatrics. During her tenure at AIIMS, she was awarded as the Best Postgraduate Student in Pediatrics from AIIMS, Best Clinical Research Award in Oncology from AIIMS, best Pediatrics Thesis Award from Indian Journal of Pediatrics. She has many National and International publications and has authored several book chapters & books. Teaching is her passion and she has been teaching undergraduate and postgraduate students for more than 14 years now and more than 1,00,000 medical students have benefitted from her teaching.

Taruna Mehra is a Gold Medalist who completed her MBBS and MD in Pediatrics from the prestigious Maulana Azad Medical College (MAMC), New Delhi, India. She is a distinguished pediatrician and currently serves as the Head of Department at Vidya Jeevan Ortho and Pedics Super Specialty Center, New Delhi, India. She is also a Consultant Pediatrician at Max Super Specialty Hospital, New Delhi, and is associated with Maharaja Agrasen Center, New Delhi, Arogyadham Healthcare Centre, New Delhi, and Ahinsa Dham Bhagwan Mahavir Health Center, New Delhi. Dr Mehra is recognized for her dedication to child healthcare and her commitment to excellence in pediatric practice.

Buy from ejaypee

JAYPEE BROTHERS

Shelving Recommendation
PEDIATRICS

ISBN 978-93-5696-301-6