w.ejaypee.com, for detailed information on surgery books, visit our website www.ejaypee.com, for detailed information on surgery books, visit our website www.ejaypee.com

11th Edition

SURGERY ESSENCE

A Must-buy Book for NEET-PG, INI-CET and FMG Exams



Thoroughly Revised and Updated Edition Including Latest Exam Pattern Questions (Updated up to 2025), Important Annexures and Image-based Questions

Updated from Bailey and Love 28/e, Sabiston 21/e, Schwartz 11/e, Smith 18/e, Campbell Urology 11/e and Harrison's 20/e

Pritesh Singh

JAYPEE

Contents

Image-based Questions *p1*
Annexures *p29*

SECTION 1: ENDOCRINE SURGERY

1. Breast★★★★★ 3
2. Thyroid★★★★★ 52
3. Parathyroid and Adrenal Glands★★★ 93

SECTION 2: HEPATOBILIARY PANCREATIC SURGERY

4. Liver★★★★ 113
5. Portal Hypertension★★★ 151
6. Gallbladder★★★ 172
7. Bile Duct★★★ 203
8. Pancreas★★★★★ 238

SECTION 3: GASTROINTESTINAL SURGERY

9. Esophagus★★★★★ 287
10. Stomach and Duodenum★★★★★ 331
11. Peritoneum★★★★ 383
12. Intestinal Obstruction★★★★ 401
13. Small Intestine★★★★ 429
14. Large Intestine★★★★ 455
15. Ileostomy and Colostomy★★★★ 489
16. Inflammatory Bowel Disease★★★★★ 494
17. Vermiform Appendix★★★★ 509
18. Rectum and Anal Canal★★★★ 523
19. Hernia and Abdominal Wall★★★★★ 550
20. Spleen★★★★ 580

SECTION 4: UROLOGY

21. Kidney and Ureter★★★★★ 595
22. Urinary Bladder★★★★ 659
23. Prostate and Seminal Vesicles★★★★ 678
24. Urethra and Penis★★★★ 696
25. Testis and Scrotum★★★★ 721

SECTION 5: CARDIOTHORACIC VASCULAR SURGERY

26. Arterial Disorders★★★★★ 751
27. Venous Disorders★★★★ 789
28. Lymphatic System★★★★ 808
29. Thorax and Lung★★★★★ 817

SECTION 6: PLASTIC SURGERY

30. Burns★★★★★ 867
31. Plastic Surgery and Skin Lesions★★★★★ 882
32. Wound Healing, Tissue Repair and Scar★★★★ 907

SECTION 7: NEUROSURGERY

33. Cerebrovascular Diseases★★★★ 923
34. CNS Tumors★★★★ 951

SECTION 8: HEAD AND NECK

35. Oral Cavity★★★★ 971
36. Salivary Glands★★★★★ 987
37. Neck★★★★ 1006
38. Facial Injuries and Abnormalities★★★ 1018

SECTION 9: ONCOLOGY

39. Oncology★★★★ 1031
40. Sarcoma★★★★★ 1053

SECTION 10: OTHERS

41. Pediatric Surgery★★★★ 1063
42. Trauma★★★★★ 1066
43. Transplantation★★★★★ 1106
44. Anesthesia and Perioperative Complications★★★ 1125
45. Robotics, Laparoscopy and Bariatric Surgery★★★★ 1128
46. Sutures and Anastomoses★★★★★ 1140
47. Sterilization and Infection★★★★ 1152
48. Fluid, Electrolyte and Nutrition★★★ 1175
49. Blood Transfusion★★★ 1188
50. Shock★★★★★ 1195
51. Miscellaneous★★★★ 1205

★★★★★ Most Important
★★★★ Very Important
★★★ Important

CHAPTER 19

Hernia and Abdominal Wall

HERNIA

Hernia

- **Hernia** is derived from the Latin word for **rupture**.
- A hernia is defined as an **abnormal protrusion** of an organ or tissue **through a defect**[Q] in its surrounding walls.

Nyhus Classification System	
Type **I**	• **Indirect hernia**; **internal ring normal**; typically **in infants**, **children**, **young adults**[Q]
Type **II**	• **Indirect hernia**; **internal ring enlarged**[Q] without impingement on the floor of the inguinal canal; does not extend to the scrotum
Type **IIIA** Type **IIIB** Type **IIIC**	• **Direct hernia**[Q] (size is not taken into account) • **Indirect hernia** enlarged enough to **encroach upon** the **posterior** inguinal **wall**; **indirect sliding** or **scrotal hernias** and **pantaloon hernias**[Q] • **Femoral hernia**[Q]
Type **IV** **A** **B** **C** **D**	• **Recurrent hernia** • **Direct**[Q] • **Indirect** • **Femoral** • **Combined**

Gilbert Classification System			
Type **1**	**Small, indirect**	Type **5**	**Diverticular,** direct
Type **2**	**Medium,** indirect	Type **6**	**Combined** (**pantaloon**)
Type **3**	**Large,** indirect	Type **7**	**Femoral**[Q]
Type **4**	**Entire floor, direct**[Q]		

Schumpelick Classification System

- The major feature is the **addition of orifice sizing** to traditional systems.
- The **defects** are then **graded according to size**.

• **L**: **Lateral indirect** site • **M**: **Medial direct** • **F**: **Femoral**	• **Type I**: Defect size **<1.5** cm in diameter • **Type II:** Defect size **1.5-3 cm** • **Type III:** Defect size **>3 cm**

RISK FACTORS FOR HERNIA

Risk Factors for Hernia	
Weakness of Abdominal Muscles	**Increased Intra-abdominal Pressure**
• **Patent processus vaginalis**[Q] • Patent canal of nuck causing indirect inguinal hernia in females • **Connective tissue disorders**[Q] like Ehlers Danlos syndrome • Congenital conditions like **Extrophy of bladder**, **Prune Belly syndrome**[Q] • **Advancing age**[Q] • **Chronic debilitating disease**[Q] • **Defective collagen synthesis**[Q] • Previous **right lower quadrant incision**[Q] • **Cigarette smoking**[Q]	• **Chronic cough**[Q] (Bronchitis, tuberculosis) • **Chronic obstructive pulmonary disease**[Q] • **Obesity**[Q] • Chronic **constipation** with **straining** at stool • **Enlarged prostate** with **straining** at micturition • **Pregnancy**[Q] • **Cirrhosis** with **ascites**[Q] • **Heavy weight lifting**[Q] • Chronic ambulatory peritoneal dialysis • Intra-abdominal tumors • Chronically enlarged pelvic organs

JAYPEE BROTHERS

Other Risk Factors	
• **Birth weight <1500 gm (Pre-term)**[Q]	• **Arterial aneurysms**[Q]
• **Family history** of a hernia	• **Sex:** Indirect inguinal hernia is more common in **boys**[Q]

- **MC type** of hernia **in males**: **Indirect inguinal hernia**[Q]
- **MC type** of hernia **in females**: **Indirect inguinal hernia**[Q]
- **Femoral hernia** is **more common in females**[Q].
- **Direct inguinal hernia** is **more common in** the **elderly**[Q]

INDIRECT INGUINAL HERNIA

Types of Indirect Inguinal Hernia

- **Bubonocele**: Hernia is **limited to inguinal canal**
- **Funicular: Processus vaginalis is closed just above** the **epididymis**, contents of sac can be felt separately from testis
- **Complete (Vaginal): Hernial sac is continuous with tunica vaginalis of testis. Testis** appear to **lie within** the **lower part of hernia**

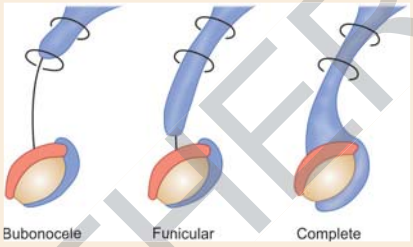

DIRECT INGUINAL HERNIA

Direct Inguinal Hernia

- In **adult males**, **35% of inguinal hernias** are **direct**[Q]
- At presentation, **12%** of patients will have a **contralateral hernia**[Q]
- **Fourfold increased risk of** future **development of** a **contralateral hernia** if one is not present at the original presentation.
- **Always acquired**[Q]
- **Sac passes through** a **weakness** or **defect of transversalis fascia** in the **posterior wall** of the inguinal canal.
- Patient has **poor lower abdominal musculature**, presence of elongated bulgings (**Malgaigne's bulges**).

> • **Women** practically **never develop** a **direct inguinal hernia.**[Q]

Predisposing Factors

- **Smoking**[Q]
- Occupations that involve **straining** and **heavy weight lifting**[Q]

> • **Damage** to the **iliohypogastric nerve** (**previous appendectomy**) is another cause, because of the resulting **weakness of** the **conjoined tendon.**[Q]
> • **IH → IH** (IlioHypogastric nerve → Inguinal Hernia[Q])

Clinical Features

- Direct hernias **do not attain a large size** or **descend into the scrotum**.
- In contrast to an indirect inguinal hernia, a **direct inguinal hernia lies behind** the **spermatic cord.**
- **Sac** is often **smaller than hernial mass would indicate**, the **protruding mass** mainly consisting of **extraperitoneal fat**[Q].

> • As the **neck of the sac is wide**, **direct inguinal hernias do not often strangulate.**[Q]

Management of Inguinal Hernia

- **Objectives** of treatment:
  - **Treatment of hernia sac**
  - **Inguinal floor reconstruction**

Treatment of Hernia Sac	Inguinal Floor Reconstruction
• Basic operation is **inguinal herniotomy**, which entails **dissecting out** & **opening** the **hernial sac, reducing any contents** and then **transfixing the neck** of the sac & **removing the remainder.**[Q]	• **Management of** the **hernia sac** is **sufficient for children** & **young adults**[Q] • **Reconstruction** (repair or strengthening) of the inguinal floor is **necessary in all adult hernias to prevent recurrence.**[Q] • **Types of repair:** – Primary **tissue repair**[Q] – **Anterior tension-free mesh repair**[Q] – **Preperitoneal repairs**: **Open** & **laparoscopic** approach[Q]
• **Direct sacs** are usually too broad for ligation and should not be opened but instead are simply **inverted into peritoneal cavity.**[Q]	

JAYPEE BROTHERS

Inguinal Floor Reconstruction		
Primary Tissue Repair	**Anterior Tension-free Mesh Repair**	**Laparoscopic and Preperitoneal Repairs**
• **Posterior wall** of inguinal wall is **strengthened by approximation of tissues with sutures**[Q]. • There is **no use of prosthetic material**[Q]. • **Advantages**: **Simplicity** of repair & **absence of** any **foreign body** in groin • **Disadvantage**: **Higher recurrence rates** due to **tension** on the repair & **slower return to unrestricted physical activity**[Q]. **Types:** – **Bassini repair**[Q] – Halsted repair – **McVay**[Q] (Cooper ligament) repair – **Shouldice repair**[Q] – Darn repair	• Current practice in hernia management employ **synthetic mesh** to **bridge the defect** • **Recurrence** is **very low** • **Types:** – **Lichtenstein repair**[Q]**: Mesh** is used to reconstruct the inguinal floor. – **Patch & plug repair**[Q]**: Plug** of mesh is **inserted into** the hernia **defect** and sutured in place. Then another piece of **mesh** is **placed over** the **inguinal floor.**	• Preperitoneal space is reached by either transabdominal laparoscopy (**TAPP**) or by totally extraperitoneal repair (**TEP**). • **Both techniques** are **similar in actual repair** but **differ in the manner** by which the **preperitoneal space is accessed**. • **TAPP** (**Transabdominal PrePeritoneal**) [Q]: – Peritoneal space is reached by conventional laparoscopy and preperitoneum overlying the inguinal floor is dissected away as a flap. • **TEP** (**Totally ExtraPeritoneal**) [Q]: – Preperitoneal space is accessed without entering the peritoneal cavity

Landmarks in Laparoscopic Repair

Triangle of Doom	Triangle of Pain	Corona Mortis
• Bounded **laterally** by **gonadal vessels**[Q] • **Medially** by **vas deferens**[Q] • **Apex** oriented superiorly at the **internal ring**[Q] • Contain **external iliac vessels**[Q], deep circumflex iliac vein, femoral nerve & genital branch of genitofemoral nerve.	• Also known as **Electrical hazard zone**[Q] • Bounded **medially** by **gonadal vessels**[Q] • **Superiorly** by **iliopubic tract**[Q] • **Laterally** by **peritoneum**[Q] • This triangle **contains** from lateral to medial: – Lateral femoral cutaneous nerve[Q] (MC injured nerve in laparoscopic hernia repair) – Anterior femoral cutaneous[Q] – Femoral branch of the genitofemoral nerve[Q] – Femoral nerve[Q]	• Also known as **Crown of death**[Q] – Vascular connections between the obturator and external iliac systems[Q] • **Aberrant obturator artery** arises from **inferior epigastric** artery, **arches over** the **Coopers ligament** and **joins** the **normal obturator artery**[Q] to complete a vascular ring • **Significant hemorrhage**[Q] may occur **if accidentally cut** and it is **difficult to achieve** subsequent **hemostasis**

1.

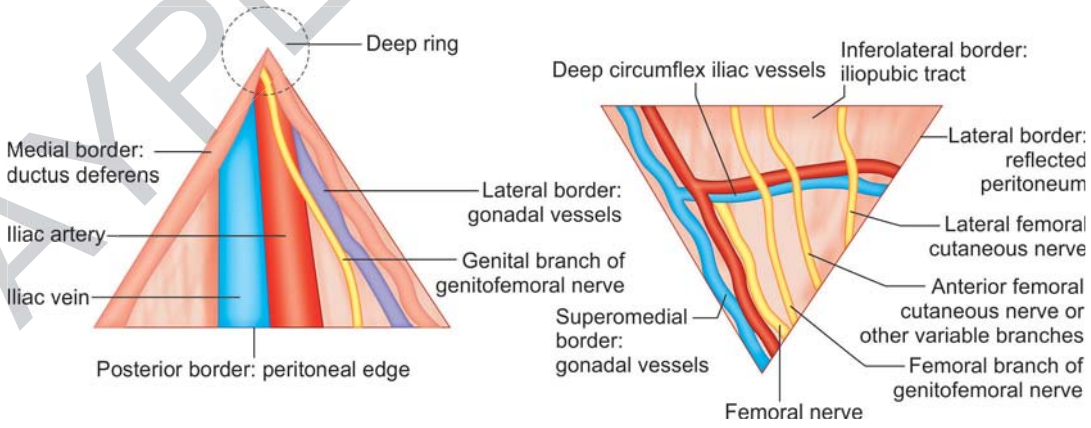

Space of Retzius (Retropubic space)	• Extra-peritoneal space between pubic symphysis & urinary bladder[Q]
Space of Bogros (Retroinguinal space)	• Extra-peritoneal space situated deep to inguinal ligament[Q] • Situated laterally & cranially to Retzius space

JAYPEE BROTHERS

Complications of Groin Hernia Repairs	
• **Recurrence** • Chronic groin pain • **Seroma** • Hematoma • **Ischemic orchitis** • **Testicular atrophy**	• Bladder injury • Wound infection • **Osteitis pubis** • Prosthetic complications (Contraction, Erosion, Infection)

- **MC injured nerve** in **laparoscopic** hernia repair: **Lateral cutaneous nerve of thigh**[Q] > **Genitofemoral nerve (GFN)**[Q]
- **MC injured nerve** in **open hernia repair**: **Ilioinguinal nerve**[Q] > **IlioHypogastric nerve**[Q] > **Genital branch of GFN**[Q] (GHI in reverse sequence)

STRANGULATED INGUINAL HERNIA

Strangulated Inguinal Hernia

- **Indirect inguinal hernias strangulate more commonly**, the direct variety not so often because of wide neck of the sac.
- Strangulation occurs **more often in patients** who have **worn a truss for a long time** and in those with a partially reducible or an irreducible hernia.

- **MC constricting agent**: **Neck of the sac**[Q] >External inguinal ring in children >Adhesions within the sac (rarely).
- **MC contents: Small intestine**[Q] >**Omentum**

- It is **rare for** the **large intestine to become strangulated in** an **inguinal hernia**, even when the hernia is of the sliding variety.

Strangulation During Infancy
• Incidence of strangulation in infancy is 4% and the **ratio of girls to boys** is **5:1.** • **More frequently**, the **hernia is irreducible** but not strangulated. • **In most cases** of **strangulated inguinal hernia** occurring **in female infants**, the **content of the sac** is **an ovary** or an **ovary plus its fallopian tube**[Q].

Diagnosis

- **Diagnosis of strangulation** is made **on clinical grounds.**

Clinical Features of Strangulated Inguinal Hernia
• In addition to patient having developed an **irreducible hernia** and an **intestinal obstruction**, patient develops **sudden pain**, at **first situated over hernia**, followed by **generalized abdominal pain.** • **Hernia** is **tense** & **extremely tender**[Q]. • **Overlying skin** may be **discolored** with a **reddish** or **bluish tinge**[Q]. • There is **no expansile cough impulse**[Q].

Treatment

- **Vigorous resuscitation** with IV fluids, **nasogastric aspiration** & **antibiotics** is **essential** followed by **emergency operation**[Q].
- **Inguinal herniotomy for strangulation:**
  - An **incision** is made **over the most prominent part** of the swelling.

- **Each layer covering** the **anterior surface** of the body of the sac "**near fundus**"[Q] is **incised** and, if possible, stripped off the sac.
- The sac is then incised and **any fluid**, which may be **highly infective**, **drained effectively**[Q].

- **Devitalised omentum** is **excised** after being securely ligated.
- **Viable intestine** is **returned to** the **peritoneal cavity**[Q].
- **Doubtfully viable** and **gangrenous intestine** is **excised**[Q].

- If the **incision** has been **soiled** or **gangrenous bowel resected**[Q], prosthetic mesh should not be used[Q].
- **Biosynthetic meshes** made **from collagen** or **dermis** are totally absorbed, are more suited to use in a contaminated environment[Q].

JAYPEE BROTHERS

FEMORAL HERNIA

Femoral Hernia

- Femoral hernia is the **3rd MC type of primary hernia**.
- Accounts for **20% of hernias in women**[Q] and **5% in men**.
- **More common** in **multipara**[Q]
- **More common** on **right side; Bilateral** in **20%**[Q]

- It **cannot be controlled by a truss**[Q]
- Of all hernias it is the **most liable to become strangulated**[Q] because of:
  - **Narrowness of the neck** of sac[Q]
  - **Rigidity of femoral ring**[Q]
- **Strangulation** is the **initial presentation** of **40%** of femoral hernias[Q]
- Should be **operated** on **as soon as possible**[Q]

Anatomy

- **Femoral canal** occupies the **most medial compartment** of the **femoral sheath** and **extends from femoral ring** to **saphenous opening**[Q].
- **Femoral canal** is **1.25 cm long** & **1.25 cm wide at its base**[Q], which is directed upwards.
- Femoral canal **contains fat, lymphatic vessels** & **lymph node of Cloquet**[Q].

Boundaries of Femoral Ring
• **Anteriorly** by the **inguinal ligament**[Q]
• **Posteriorly** by Astley **Cooper's** (iliopectineal) **ligament**, **pubic bone** & **pectineus fascia**[Q]
• **Medially** by **Gimbernat's** (lacunar) **ligament**[Q], which is also prolonged along the iliopectineal line, as Astley Cooper's ligament
• **Laterally** by a **thin septum separating** it from the **femoral vein**[Q]

Clinical Features

- **Rare before puberty**
- Prevalence rises between **20-40 years**[Q] of age and this continues to old age.
- A small femoral hernia may be unnoticed by the patient or disregarded for years, perhaps **until the day it strangulates**[Q].
- **Mass** or **bulge below** & **lateral to pubic tubercle**[Q]

Treatment

- **Low inguinal** operation (**Lockwood**[Q])
- **Inguinal** operation (**Lotheissen**[Q])
- **High inguinal** operation (**McEvedy**[Q])
- Midline Abdominal Extraperitoneal Femoral Hernioplasty **(Henry Procedure**[Q]**):** This is now considered as the **procedure of choice**; does not damage the transversalis fascial floor; reducing the risk of a subsequent inguinal hernia.

Variants of Femoral Hernia	
Laugier's femoral hernia[Q]	• Hernia through a **gap in** the **lacunar** (Gimbernats) **ligament** • Diagnosis is based on **unusual medial position** of a **small femoral hernia sac** • **Always strangulated**
Narath's femoral hernia[Q]	• Occurs in patients with **congenital dislocation of hip** • Due to **lateral displacement of** the **psoas muscle** • Hernia lies hidden **behind** the **femoral vessels**
Cloquet's hernia[Q]	• **Sac lies under** the **pectineus** fascia

SPIGELIAN HERNIA

Spigelian Hernia

- Spigelian hernia **occurs through** the **spigelian fascia**[Q]
- **Spigelian fascia** is composed of **aponeurotic layer** between **rectus muscle** medially & **semilunar line** laterally[Q].

- Nearly **all spigelian hernias occur at** or **below** the **arcuate line**[Q].
- **Absence of posterior rectus fascia** may **contribute to** an **inherent weakness** in this area[Q].
- These hernias are **often interparietal**, with the **hernia sac dissecting posterior** to **external oblique aponeurosis**[Q].
- **Spigelian hernia** sac **always penetrates** the **spigelian aponeurosis** & **usually penetrates** the **internal oblique** musculature[Q].

Contd…

JAYPEE BROTHERS

Contd…

Clinical Features

- **Most spigelian hernias** are **small** (**1-2 cm** in diameter)
- Develop during **4** to **7 decades** of life.
- Patients often present with **localized pain** in the area **without a bulge** because the **hernia lies beneath** the intact **external oblique aponeurosis**Q.

Diagnosis

- **Ultrasound** or **CT** of the abdomen can be **useful to establish** the **diagnosis**Q.

Treatment

- A spigelian hernia is **repaired** because of the **risk for incarceration**Q associated with its **relatively narrow neck.**
- **Defect** is **closed transversely by simple suture repair**Q of the transversus abdominis and internal oblique muscles, followed by closure of the external oblique aponeurosis.
- **Larger defects** are repaired using a **mesh prosthesis**Q.
- **Recurrence** is **uncommon**Q.

SLIDING HERNIA (HERNIA EN GLISSADE)

Sliding Hernia (Hernia en Glissade)

- Hernias in which **posterior wall of** the **sac** is **formed by a viscus**Q
- **Viscera** is **liable to be injured,** if the **hernia sac** is **resected during surgery**Q
- **More common** on **left side**Q

Most Common Content	
• **Left side**: **Sigmoid colon**Q & its mesentery (**MC**)	• **Right side**: **Cecum**Q

- **Other contents**: Appendix, urinary bladder, uterus, fallopian tube, ovary or ureter
- **Primary danger**: **Failure to recognize** the **visceral component** of hernia sac **before injury to** the **bowel** or **bladder**Q.

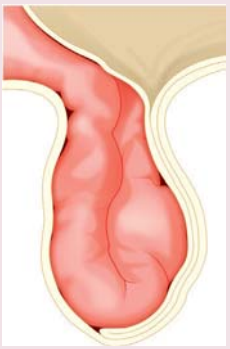

Clinical Features

- **Occurs almost exclusively in men**Q.
- **More common** on the **left side**Q; **rarely bilateral**
- Patient is **nearly always over 40 years of age**, the **incidence rising with age**Q.

> • Occasionally, **large intestine is strangulated** in a **sliding hernia**; **more often, non-strangulated large intestine** is **present behind the sac containing strangulated small intestine**Q.

Treatment

- **Operation** is indicated
- **Sliding hernia contents** are **reduced into the peritoneal cavity**, and **any excess hernia sac** is **ligated** & **divided**Q.

> • Sliding hernia is a cause of considerable discomfort, **impossible to control with a truss**Q.

LUMBAR HERNIA

Lumbar Hernia

- Lumbar hernias can be either **congenital (20%)** or **acquired (80%)**Q
- **Occur in** the **lumbar region** of the **posterior abdominal wall**Q.
- **More common** on **left side,** in **men**Q

> • Hernias through the **superior lumbar triangle** (**Grynfeltt's triangle**) are **more common**Q.
> • **Grynfeltt's triangle** is bounded by the **12th rib**, **paraspinal muscles** & **internal oblique muscle**Q.

- **Less common** are hernias through the **inferior lumbar triangle** (**Petit's triangle**)Q
- **Petit's triangle** is bounded by **iliac crest, latissimus dorsi muscle**, & **external oblique muscle**Q.
- **Weakness of lumbodorsal fascia** through either of these areas results in **progressive protrusion of extraperitoneal fat** and a **hernia sac**Q.

Clinical Features

- **MC presentation**: **Unilateral bulge** in the flankQ.
- Lumbar hernias are **not prone to incarceration**Q.

Contd…

JAYPEE BROTHERS

Contd…

Treatment

- **Lumbar hernia** be **repaired** at the **time of discovery**; the *except*ion is in **newborns** and be undertaken after a child is **6 months of age**[Q].
- **Dowd's operation** is done for **lumbar hernia**[Q].
- **Repair** is **best done by placement of prosthetic mesh**, which can be sutured to the margins of the hernia[Q].

OBTURATOR HERNIA

Obturator Hernia

- Also known as **skinny old lady hernia** or **French hernia**[Q].
- **Thin, elderly**, & **debilitated women** are at greatest risk.
- More common in **female** secondary to the **larger** & **more oblique** design of the **obturator canal**[Q].
- Occur more frequently on the **right** in **female** patients and on the **left** in **male** patients[Q].
- **Bilateral** in **6%** cases.

Predisposing Factors	
• Women with **wider pelvis** & **more triangular obturator canal**[Q] • **Malnutrition**[Q]	• Chronic constipation, COPD, ascites, kyphoscoliosis[Q] • Multiparity[Q] • Age **70-79 years**[Q]

Clinical Features

- Patients present **most commonly with intestinal obstruction**[Q] (**jejunum** or **ileum** within the hernial sac).

Howship-Romberg Sign[Q]	• **Pain radiating down** the **medial thigh to** the **knee** due to **compression of obturator nerve** (anterior division) by the hernial sac • **Pathognomonic for** an **incarcerated hernia** • Present in **25-50%** cases
Hannington Kiff sign[Q]	• **Absence of** the **obturator reflex** in the thigh **due to compression of obturator nerve.**

Treatment

- **Operation** is **indicated**
- **Posterior approach** (either open or laparoscopic) **is preferred**[Q].

PARADUODENAL HERNIA

Paraduodenal Hernia

- It is the **MC** variety of **congenital internal hernia**[Q]
- Nearly **75%** are **left-sided, more common** in **male**s

> • Herniation into the **left Paraduodenal fossa** (**Fossa of Landzert**[Q]) **occurs more frequently** than herniation into the **right fossa** (**Fossa of Kolb**[Q]).

- **Small bowel herniate** through the **vascular arch of Treitz** formed by the **inferior mesenteric vein** and the **ascending branch of left colic artery**[Q]
- **Herniated bowel** is **posterior** to the **mesocolon**; with the **afferent limb** being the **4 part of** the **duodenum** and **efferent limb** being the **terminal ileum**[Q].

Clinical Features

- Occur between **4 to 5 decade**

> • **Postprandial pain with postural variation** is a **characteristic symptom**[Q]

- Commonly PDH manifest as **acute intestinal obstruction.** Life time risk of **incarceration** is **50%**.

Diagnosis

- On barium study the **small bowel** is **clustered** to the **left of the midline** with a well-circumscribed edge that corresponds to the hernial sac.
- However **all radiologic studies may be normal** especially in **chronic intermittent cases**, because hernia may **reduce spontaneously**. These investigations are **most often diagnostic** during an **acute episode**[Q].

Treatment

- **Reduction of hernia sac** and **closure of the defect**[Q] or incision of the hernia sac

JAYPEE BROTHERS

UMBILICAL HERNIA

Umbilical Hernia

- Umbilical hernias **in infants** are **congenital**[Q] and are quite common.
- **Strong predisposition** in individuals of **African descent**.
- **Close spontaneously in most cases** by the **age of 2 years**[Q].
- **Complications** are **unusual**[Q]
- Those that **persist after the age of 5 years** are frequently **repaired surgically**[Q]

Indications of Surgery in Umbilical Hernia	
• Persisting **beyond 5 years**[Q] • **Symptomatic**[Q] • **Strangulated**[Q]	• Defect **size >2 cm**[Q] • **Progressive enlarging**[Q] hernia after the age 1-2 years

Treatment

- **Small defects: Closed primarily**[Q]
- **Defects >3 cm: Closed using prosthetic mesh**[Q].

Mayo's Repair
• **Vest-over-pants repair** proposed by Mayo employs **imbrication of superior** and **inferior fascial edges**[Q]. • Because of **increased tension on** the **repair** and **recurrence rates** of 30%, it is **rarely performed today**[Q].

Abdominal Wall Defects	
Omphalocele	**Gastroschisis**
• **Intestine fails to return**, abdominal **contents protruding** directly **through** the **umbilical ring** with a **sac covering** the **bowel**[Q] • **Abdominal contents** are **covered with peritoneum** on the **inside** & **amnion** on the **outside**[Q] • **Size of defect** is **variable**, ranging from a small opening through which a **small portion of intestine** is herniated to a **large one** in which **entire bowel** & **liver** are included[Q]. • **Chromosomal abnormalities**[Q] are present in roughly **30%** of infants, including **trisomies 13, 18** & **21**[Q]. • **More than half** of infants have other **major** or **minor malformations**, with **cardiac being** the **most common**[Q], followed by musculoskeletal, gastrointestinal & genitourinary. • Close association with **Beckwith-Wiedemann syndrome**[Q] (omphalocele, hyperinsulinemia, and macroglossia). • **Poor prognosis**[Q] due to **associated abnormalities.**	• **Fetal gut** is **extruded** through a defect in abdominal wall • **Defect** is **always on** the **right side of umbilical ring** with an **intact umbilical cord**[Q] • **Covering sac** is **absent**[Q] • **Risk for associated anomalies** is **low**[Q]. • **Association with intestinal atresia** in up to 15%. • Atresias may involve the **small** and **large intestine**[Q]. • Babies are more often **small for gestational age** and **born to mothers with** a history of **cigarette, alcohol**, and **recreational drug use** and intake of **aspirin, ibuprofen**, and **pseudoephedrine** during the first trimester[Q] • **Increased** risk in **mothers younger than 20 years**[Q]. • In patients with gastroschisis, the **intestine** is often **thickened, edematous**, **matted together,** and **foreshortened**[Q]. • **Good prognosis**[Q]

EPIGASTRIC HERNIA (FATTY HERNIA OF THE LINEA ALBA, EPIGASTRIC LIPOMA)

Epigastric Hernia (Fatty Hernia of the Linea Alba, Epigastric Lipoma)

- About 3% to 5% of the population has epigastric hernias.
- **More common** in **men**[Q].
- **Located between** the **xiphoid process** & **umbilicus**[Q]
  - **Multiple in** up to **20%** of patients, and **about 80%** are **just off**[Q] **the midline**.
- Usually **within 5 to 6 cm of** the **umbilicus**.
- **Defects** are **small** and often **produce pain out of proportion** to their size owing to **incarceration of preperitoneal fat**[Q].

Clinical Features

- **Majority** of these hernias are **asymptomatic**
- Sometimes such a hernia gives rise to **attacks of local pain**. This may be because the **fatty contents become nipped sufficiently** to produce **partial strangulation**[Q].
  - **Referred pain**: It is not uncommon to find that the patient, who may not have noticed the hernia, complains of **pain suggestive of a peptic ulcer**[Q].

Treatment

- Repair usually consists of **excision of** the **incarcerated preperitoneal tissue** & **simple closure of the fascial defect**[Q].

JAYPEE BROTHERS

INCISIONAL HERNIA

Incisional Hernia

- **Postoperative ventral abdominal wall hernia** or incisional hernia is the result of a **failure of fascial tissues to heal** & **close** following laparotomy[Q].
- As the approximated **fascial tissue separates**, **bowel** & **omentum herniates** through the opening, **covered by a peritoneal sac**[Q].

> - **Highest incidence** is seen with **large, midline, vertical, lower abdominal incisions**[Q].
> - **Incidence** seems to be **lower in smaller incisions**

- Modern rates of incisional hernia range from **2-11%.**
- **One-third** of these hernias will present **5-10 years postoperatively**.

Risk Factors for Incisional Hernia		
Surgery Related	**Surgeon Related**	**Patient Related**
• **Emergency surgery**[Q] • **Wound infection**[Q] • **Midline vertical incisions**[Q]	• Wounds closed under **excessive tension**[Q] • **Poor technique**[Q] • Use of **absorbable sutures**[Q]	• **Advanced age, malnutrition**[Q] • **Ascites, Steroid use**[Q] • **Diabetes, obesity**[Q] • **Smoking, coughing**[Q] • **Vomiting & distension**[Q]

Clinical Features

- **Bulge** in the abdominal wall originating deep to the skin scar.
- **Symptoms aggravated** by **coughing** or **straining** as the hernia contents protrude through the abdominal wall defect.
- In **large ventral hernias**, the **skin** may present with **ischemic** or **pressure necrosis** leading to **frank ulceration**[Q].

Treatment

- **Operative repair**: Primary **suture repair** of the hernia, **open repair** with prosthetic mesh, and **laparoscopic incisional hernia repair**[Q].

> - Laparoscopic incisional hernia repair (**IPOM**- Intraperitoneal onlay mesh repair) has the **lowest rate of recurrence**[Q]

- **Major complication** from **open, nonmesh incisional hernia repair**: **Recurrence**[Q]
- **Recurrence rates** vary between **10-50%**, typically reduced by **>50%** with the use of prosthetic mesh
- **Risk of recurrence** is likely **related to the tension** placed on the repair in large hernias
- Incisional hernias with a **diameter >4 cm** should be **repaired with mesh**[Q].

UMBILICAL ADENOMA OR RASPBERRY TUMOUR

Umbilical adenoma or Raspberry tumour



- **Commonly seen in infants** but only occasionally later in life[Q].
- Due to a **partially** (occasionally a completely) **unobliterated vitellointestinal duct**[Q].
- **Mucosa prolapsing through** the **umbilicus** gives rise to a **raspberry-like tumour**[Q]
- **Moist** and **tends to bleed**

Treatment

- **Pedunculated tumour**: A **ligature is tied around**[Q] it, in a few days, the polypus drops off.
- If tumour reappears after this procedure: **Umbilectomy**[Q]

DESMOID TUMOR

Desmoid Tumor

- **MC primary malignant neoplasm of the mesentery: Desmoid tumor**
- Arises from **musculoaponeurotic structures** of abdominal wall, especially **below** the **level of umbilicus**[Q].
- It is a **completely unencapsulated fibroma**[Q] and is **so hard** that it **creaks when** it is **cut**[Q].
- **Distribution: Extra-abdominal (60%), abdominal wall (25%), intra-abdominal (15%).**
- About **80% of cases** occur **in women**[Q], many of whom have borne children

> - Occurs **occasionally in scars**[Q] of old hernial or other abdominal **operation wounds**.
> - **Surgical trauma**[Q]**: Important etiological factor**
> - **Estrogens stimulate**[Q] desmoid growth
> - Occur in cases of **FAP**[Q] **(Gardener's syndrome)**

Contd…

JAYPEE BROTHERS

Contd…

Pathology

- Tumour is composed of **fibrous tissue** containing **multinucleated plasmodial masses** resembling **foreign body giant cells**Q.
- Usually of **very slow growth**, it **tends to infiltrate muscle** in the **immediate area**Q.
- Eventually it **undergoes a myxomatous change** and it then **increases in size more rapidly**.
- **Metastasis does not occur**Q**, no sarcomatous change**

Clinical Features

- **Desmoids classically arise in pregnancy** as an **abdominal mass independent of uterus**.
- **MC presentation: Abdominal mass**
- Affected patients may present with a **painful versus asymptomatic firm mass, bowel obstruction, or bowel ischemia**.

Diagnosis

- **MRI** is **investigation of choice** for **extremity** & **abdominal wall desmoids**Q**.**
- **Biopsy** is required to **establish the diagnosis**.

Treatment

- **Wide local excision** (with **2 cm margin**) is **treatment of choice**Q.
- **Surgery + Radiotherapy:** For **recurrent desmoid tumors**Q

Prognosis

- Involvement of margins is associated with **recurrence rates** as high as **80%**.

JAYPEE BROTHERS

Multiple Choice Questions

CLASSIFICATION OF HERNIA

1. Type IIIA in Nyhus classification of hernia: *(FMGE Nov 2017, DNB 2011)*
a. Direct inguinal hernia
b. Indirect inguinal hernia
c. Femoral hernia
d. Umbilical hernia

2. Type 7 Gilbert hernia is:
a. Direct inguinal hernia
b. Indirect inguinal hernia
c. Femoral hernia
d. Umbilical hernia

3. Femoral hernia in Nyhus classification: *(WBPG 2014)*
a. IIIA
b. II
c. IIIC
d. IV

RISK FACTORS FOR HERNIA

4. The following are the risk factors for inguinal hernia:
a. Family history of inguinal hernia *(PGI Dec 2007)*
b. Weight lifter
c. COPD
d. Female
e. Obesity

INGUINAL HERNIA

5. Most common type of hernia in females is: *(AIIMS Feb 97, DPG 2005, JIPMER GIS 2011)*
a. Direct inguinal hernia
b. Indirect inguinal hernia
c. Femoral hernia
d. Umbilical hernia

6. Which of the following is the most common in hernia in females? *(INI-CET May 2024)*
a. Direct inguinal hernia
b. Indirect inguinal hernia
c. Femoral hernia
d. Obturator hernia

7. For differentiating inguinal hernia and femoral hernia the landmark will be: *(AIIMS Nov 98)*
a. Public symphysis
b. Femoral artery
c. Inferior epigastric level
d. Public tubercle

8. A patient presents with a swelling in the groin region and it is diagnosed as a direct inguinal hernia. Weakness in which of the following structures is most likely to cause this condition? *(NEET-PG 2023)*
a. Pectineal ligament
b. Conjoint tendon
c. Reflected part of inguinal ligament
d. Lacunar ligament

INDIRECT INGUINAL HERNIA

9. True about inguinal hernia: *(PGI June 2003)*
a. It is more common in female
b. Right sided is more common than left side
c. Direct hernia is less likely to undergo strangulation
d. Femoral hernia is more common in female

10. A 54-year-old male presented with right groin swelling, located below inguinal ligament, medial to inferior epigastric artery. Cough impulse was present. What is the type of hernia and its management? *(NEET-PG 2021)*
a. Direct hernia and Bassini repair
b. Direct hernia and Lichtenstein repair
c. Indirect hernia and Bassini repair
d. Indirect hernia and Lichtenstein repair

11. All of the following statements are true about repair of groin hernias *except*: *(AIIMS Nov 2004)*
a. Lichtenstein tension free repair has a low recurrence rate
b. TEP repair is an extraperitoneal approach to laparoscopic repair of groin hernia
c. In Shouldice repair, non-absorbable mesh is used
d. The surgery can be done under local anesthesia in selected cases

12. Most important step in the repair of an indirect inguinal hernia is:
a. Herniotomy
b. Narrowing of the internal ring
c. Bassini's repair
d. Transfixation of the neck of the sac

13. The treatment of choice for inguinal hernia in infants is:
a. Herniotomy *(FMGE June 2018)*
b. Herniorrhaphy
c. Truss
d. Hernioplasty

14. On examination of the patient for a hernia, it is useful to realize that:
a. An impulse is often much better seen than felt
b. The internal abdominal ring lies 1.25 cm above the midpoint of poupart's ligament
c. The external abdominal ring lies 1.25 cm above and medial to ASIS
d. None of the above

15. A patient is advised to avoid strenuous activity following herniorrhaphy for a period of:
a. One day
b. One week
c. 3 weeks
d. 6 weeks

16. Which one of the following is not performed in Lichtenstein tension free hernioplasty? *(Karnataka 2006)*
a. High ligation of indirect hernia sac
b. Mesh sutured to the conjoint tendon and inguinal ligament
c. Conjoint tendon sutured to inguinal ligament
d. Spermatic cord is placed in two tails of the internal ring

17. True statement regarding direct inguinal hernia: *(UPPG 2008)*
a. Most common inguinal hernia in women is direct
b. Direct hernia is medial to inferior epigastric artery
c. Repair of the transversalis fascia and the internal ring
d. Descends downwards and inwards towards the scrotum

18. Content of epilocele is: *(DNB 2011)*
a. Omentum
b. Intestine
c. Colon
d. Urinary bladder

JAYPEE BROTHERS

19. Which of the following statements are correct about boundaries of triangle of Doom and Myopectineal orifice? *(AIIMS Nov 2020)*

1. Medially vas deferens, laterally gonadal vessels in triangle of Doom
2. Medially gonadal vessels, laterally vas deferens in triangle of Doom
3. Rectus is medial to myopectineal orifice
4. Iliopsoas is the lateral boundary of myopectineal orifice

a. 1 and 4 b. 3 and 4
c. 1, 3 and 4 d. 1, 2, 3 and 4

20. Triangle of Doom is bounded by all of the following *except*: *(AIIMS Nov 2008)*

a. Cooper's ligament
b. Vas deferens
c. Gonadal vessels
d. Peritoneal reflection

21. Which of the following is correct regarding the boundaries of triangle of Doom? *(AIIMS May 2018)*

a. Medially vas deferens, laterally gonadal vessels, inferiorly peritoneum
b. Laterally vas deferens, medially gonadal vessels, inferiorly peritoneum
c. Laterally medial umbilical ligament, medially gonadal vessels, inferiorly peritoneum
d. Laterally gonadal vessels, medially lateral umbilical ligament, inferiorly peritoneum

22. What is the name of this triangle?

a. Triangle of doom b. Triangle of pain
c. Triangle of death d. Corona mortis

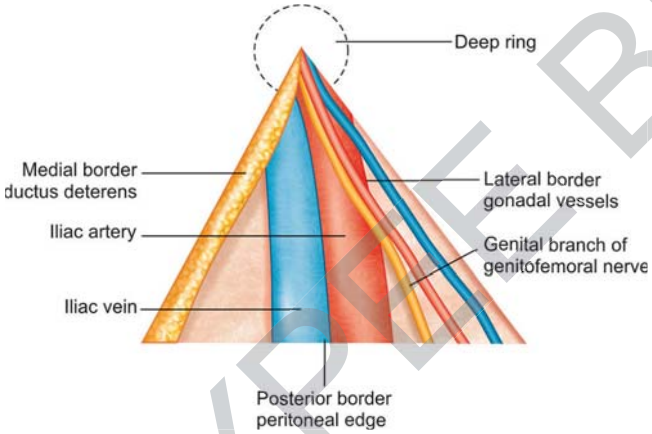

23. True regarding indirect inguinal hernia are all *except*: *(FMGE March 2008)*

a. Most common type of hernia
b. Always unilateral
c. Inguinal herniotomy is the basic operation
d. Transillumination distinguishes it from hydrocele

24. Arrange the steps of hernioplasty in correct order: *(INI-CET Nov 2025)*

1. Skin incision
2. Identify the sac and reduce the content
3. Place the mesh
4. Close the wound

a. 1, 2, 3, 4 b. 1, 3, 2, 4
c. 2, 1, 3, 4 d. 3, 1, 2, 4

25. Most common type of hernia in the young age group: *(FMGE Sept 2006)*

a. Femoral hernia b. Direct inguinal hernia
c. Indirect inguinal hernia d. Umbilical hernia

26. Least recurrence rate in incisional hernia repair is following: *(JIPMER 2010)*

a. On lay mesh repair
b. Intraperitoneal mesh repair
c. Inlay mesh repair
d. Shouldice repair

27. Inguinal herniotomy includes all of the following *except*: *(Orissa 2011)*

a. Dissection and opening of the hernial sac
b. Reduction of contents
c. Transfixation of the neck and excision of redundant sac
d. Repair of stretched inguinal ring and fascia transversalis

28. Hesselbach's triangle is bounded by the following, *except*: *(Orissa 2011)*

a. Rectus abdominis muscle
b. Transversus abdominis muscle
c. Inferior epigastric artery
d. Inguinal ligament

29. Ilioinguinal nerve is damaged while incising: *(MHSSMCET 2006)*

a. External oblique aponeurosis
b. Internal oblique muscle
c. Transverse abdominis
d. Linea alba

30. Shouldice repair is: *(PGI SS June 2007)*

a. Multilayered repair of inguinal canal
b. Conjoint tendon is sutured to inguinal ligament
c. Conjoint tendon is sutured to Cooper's ligament
d. Transabdominal repair

31. Are true about hernia repair *except*: *(JIPMER GIS 2011)*

a. Bassini's repair is between inguinal ligament and conjoint tendon
b. Shouldice repair is involvement of the posterior wall strengthening
c. Mcvay's repair is for femoral hernia
d. Lichtenstein is a tension free-mesh repair

32. Funicular hernia is type of: *(DNB 2007)*

a. Direct inguinal hernia b. Indirect inguinal hernia
c. Femoral Hernia d. Umbilical hernia

33. A child presented with a swelling in the right groin region. When the swelling was reduced, a gurgling sound was heard. Which of the following is an incorrect statement? *(AIIMS Nov 2015)*

a. The sac contains omentum only
b. The hernia lies above and medial to pubic tubercle
c. Patent processus vaginalis
d. This type of hernia is most common in children

34. A 3-year-old child comes with hydrocele of the hernia sac. Management will include: *(AIIMS May 2015)*

a. Herniotomy b. Herniorrhapy
c. Observation only d. Operate after 5 years of age

35. Triangle of doom is related to: *(NEET-PG 2014)*

a. laparoscopic Nissen's fundoplication
b. laparoscopic hernia surgery
c. endoscopic thyroidectomy
d. thoracoscopic thymectomy

36. Inguinal hernia in a child is associated with:

a. Patent processus vaginalis *(NEET-PG 2017)*
b. Ectopia vesicae
c. Undescended testis
d. All are correct

37. Triangle of doom is seen during which type of hernia surgery: *(NEET-PG 2017)*

a. Laparoscopic b. Open
c. Both d. None

JAYPEE BROTHERS

COMPLICATIONS OF HERNIA

38. Which of these would you like to do for a case of strangulated hernia? *(PGI June 2002)*
a. X-ray
b. USG abdomen
c. Aspiration of contents of sac
d. Correction of hypovolemia
e. Prepare OT for urgent surgery

39. A 45-year-old male underwent bilateral laparoscopic hernia repair for inguinal hernia. Postoperatively, he complained of pain in the right thigh. Which of the following nerve entrapment leads to this symptom? *(NEET-PG 2023)*
a. Ilioinguinal nerve
b. Hypogastric nerve
c. Femoral nerve
d. Lateral cutaneous nerve of thigh

40. A patient developed loss of sensations in the root of penis after a laparoscopic hernia surgery. Which of the following nerves would have been damaged? *(INI-CET May 2022)*
a. Iliohypogastric nerve
b. Ilioinguinal nerve
c. Medial cutaneous nerve of thigh
d. Lateral cutaneous nerve of thigh

41. A 45-year-old male operated for inguinal hernia. Laparoscopic inguinal hernia repair was done. During surgery, nerve was stuck in the fixator. Post-operatively, he complains of loss of sensation in the right lower limb because of nerve entrapment in the mesh. Which nerve involvement leads to this complication? *(NEET-PG 2023)*
a. Ilioinguinal nerve
b. Iliohypogastric nerve
c. Femoral nerve
d. Lateral cutaneous nerve of thigh

42. During surgery of hernia, the sac of a strangulated inguinal hernia should be opened at the: *(AIIMS Nov 96, AIIMS June 2004)*
a. Neck
b. Body
c. Fundus
d. Deep ring

43. Treatment of strangulated hernia is: *(Kerala 94)*
a. Observation
b. Immediate surgery
c. Manual reduction
d. Analgesics

44. Which is the 1st sign of strangulation of inguinal hernia? *(UPPG 96)*
a. Tense
b. Tenderness
c. Irreducible
d. Redness

45. During laparoscopic inguinal hernia repair a tacker was accidently placed below and lateral to the iliopubic tract. Postoperatively the patient complained of pain and soreness in the thigh. This is due to the involvement of: *(AIIMS Nov 2015, May 2015)*
a. Lateral cutaneous nerve of thigh
b. Ilioinguinal nerve
c. Genital branch of genitofemoral nerve
d. Obturator nerve

46. Most common nerve injured during hernia surgery: *(NEET-PG 2017, 2014)*
a. Ilioinguinal nerve
b. Iliohypogastric nerve
c. Genitofemoral nerve
d. None of the above

FEMORAL HERNIA

47. True about femoral hernia is: *(PGI Dec 98)*
a. Occurs exclusively in females
b. Pregnancy is common cause
c. Doesn't strangulate
d. In males associated with cryptorchidism

48. A young female presenting with pain and vomiting in ER. Clinical examination reveals a swelling lateral and below pubic tubercle. X-ray shows intestinal obstruction. What is most probable diagnosis? *(INI-CET Nov 2023)*
a. Adhesions
b. Strangulated inguinal hernia
c. Strangulated femoral hernia
d. Appendicular mass

49. Which structures live immediately lateral to femoral hernia?
a. Lateral cutaneous nerve of thigh *(AIIMS Nov 2011)*
b. Femoral nerve
c. Femoral artery
d. Femoral vein

50. Femoral hernia is characteristically ….. the public tubercle.
a. Lateral and below *(MHPGMCET 2007, TN 89)*
b. Medial and above
c. Lateral and above
d. Medial and below

51. In the treatment of femoral hernia, Lockwood's operation refers to: *(Karnataka 2006)*
a. Low inguinal operation
b. High inguinal operation
c. Inguinal operation
d. Laparoscopic surgery

52. Strangulation most commonly occurs in:
a. Femoral hernia *(DNB 2012, FMGE Sept 2005)*
b. Direct inguinal hernia
c. Indirect inguinal hernia
d. Lumbar hernia

53. Medial boundary of femoral ring is formed by:
a. Inguinal ligament *(JIPMER 2011)*
b. Pectineal ligament
c. Lacunar ligament
d. Septum separating it from femoral vein

54. A patient with femoral hernia can be managed by:
a. Bassini repair
b. Hunters repair
c. Shouldice repair
d. McVay repair

55. Hernia that lies under the fascia of pectineus muscle is:
a. Cloquet's hernia *(MHSSMCET 2006)*
b. Laugier's hernia
c. Narath's hernia
d. Obturator hernia

56. In Laugier's hernia opening is in the: *(WBPG 2014)*
a. Lacunar ligament
b. Conjoint tendon
c. External oblique
d. Peritoneum

57. Neck of sac of femoral hernia lies: *(NEET-PG 2013)*
a. Below and lateral to pubic tubercle
b. Above and lateral
c. Above and medial
d. Below and medial

JAYPEE BROTHERS

SPIGELIAN HERNIA

58. All are true about Spigelian hernia *except*: *(JIPMER GIS 2011)*
a. Usually occurs above arcuate line
b. Picked up by USG or CT
c. Hernia sac will be posterior to the external oblique aponeurosis
d. Usually small and asymptomatic

59. Spigelian hernia is seen in: *(All India 99)*
a. Lumbar triangle
b. Subumbilical region
c. Paraumbilical region
d. Supraumbilical region

60. Spigelian hernia is a type of hernia occurring at: *(NEET-PG 2013, PGI June 95, PGI June 2000)*
a. Medial border of rectus abdominis
b. Lateral border of rectus abdominis
c. Lumbar region
d. Femoral canal

61. Spigelian hernia is: *(FMGE March 2005)*
a. Passes through the obturator canal
b. Hernia occurring through the linea alba
c. Hernia through the triangle of Petit
d. Hernia occurring at the level of arcuate line

62. Spigelian hernia is a defect within the following muscle: *(COMEDK 2004)*
a. Rectus abdominis
b. Internal oblique
c. Transversalis abdominis
d. External oblique

SLIDING HERNIA

63. Most common content in 'Hernia en glissade' is: *(PGI June 96, All India 95)*
a. Omentum
b. Urinary bladder
c. Caecum
d. Sigmoid colon

64. What is the name of this hernia?
a. Ogilvie's hernia
b. Hernia-en-Glissade
c. Pantaloon's hernia
d. Spigelian hernia

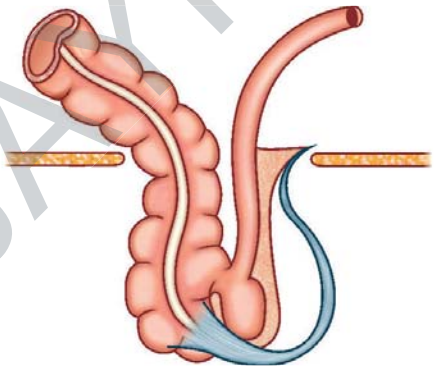

65. Sliding constituent of a large direct hernia is: *(All India 88)*
a. Bladder
b. Sigmoid colon
c. Caecum
d. Appendix

66. If caecum is involved as a part of the wall of hernia sac and is not its content, then it will be known as: *(NEET-PG 2014, 2008)*
a. Richter's hernia
b. Spigelian hernia
c. Sliding hernia
d. Interstitial hernia

LUMBAR HERNIA

67. About lumbar hernia, false statements:
a. Superior triangle is Grynfeltt's triangle
b. Inferior triangle is Petit's triangle
c. Mostly acquired
d. More common on right side

68. Which of the following statement is incorrect about this hernia?

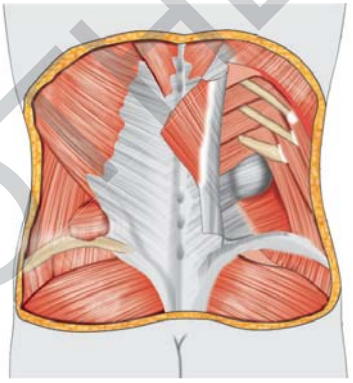

a. More commonly congenital
b. Hernia through Grynfeltt's triangle is more common
c. Petit's triangle is bounded by the iliac crest, latissimus dorsi and external oblique muscle
d. Grynfeltt's triangle is bounded by 12th rib, paraspinal and internal oblique muscle

OBTURATOR HERNIA

69. True about obturator hernia in adults: *(PGI Nov 2009)*
a. More common in space of Lorentz
b. Common in female
c. Chronic constipation risk factor
d. Surgical treatment should be done
e. May present with intestinal obstruction

70. Howship-Romberg sign is seen in: *(JIPMER SS 2016, NEET-PG 2016)*
a. Sliding hernia
b. Obturator hernia
c. Lumbar hernia
d. Paraduodenal hernia

PARADUODENAL HERNIA

71. False about paraduodenal hernia: *(PGI Nov 2009)*
a. Congenital
b. Found in fossa of Kolb
c. Found in fossa of Landzert
d. Common on right side

JAYPEE BROTHERS

72. **False about paraduodenal hernia:** *(AIIMS GIS 2003)*
a. Left sided is found in fossa of Landzert
b. Right sided is found in fossa of Kolb
c. Congenital
d. More common on right side

73. **After retrocolic gastrojejunostomy, hernia occurring through window in the transverse mesocolon is:** *(MHSSMCET 2008)*
a. Stammer's hernia
b. Left paraduodenal hernia
c. Right paraduodenal hernia
d. Hernia-en-glissede

UMBILICAL HERNIA

74. **The covering over an omphalocele is:**
a. Skin
b. Amniotic membrane
c. Chorionic membrane
d. None of the above

75. **A patient with history of umbilical swelling initially asymptomatic for many years, now complains of pain over the swelling. It was reducible initially now it is irreducible. What is the appropriate management?** *(NEET-PG 2024)*



a. Umbilectomy with herniorrhaphy
b. Umbilectomy
c. Conservative management with antibiotics
d. Incision and drainage

76. **Omphalocele is caused by:** *(DNB 2010)*
a. Duplication of intestinal loops
b. Abnormal rotation of the intestinal loop
c. Failure of gut to return to the body cavity from its physiological herniation
d. Reversed rotation of the intestinal loop

77. **In Moore's classification of omphalocele (exomphalos), type I umbilical defect is less than .. cm:**
a. 0.5
b. 2.5
c. 3.5
d. 4.5

78. **Which of the following statements are correct about umbilical hernia in adults?** *(NEET-PG 2024)*
1. Patients are commonly overweight with a thinned and attenuated midline raphe.
2. Most patients complain of pain due to increased tension.
3. Men are affected more commonly than women.
4. Hernia repair can be done by the technique described by Mayo.
a. 1, 2 and 3
b. 1, 2 and 4
c. 1, 3 and 4
d. 2, 3 and 4

79. **Exomphalos major should be operated at:** *(DNB 91)*
a. Birth
b. 3 months of age
c. 1 year
d. 3 years

80. **Mayo's operation is done for:** *(NEET-PG 2016)*
a. Spigelian hernia
b. Femoral hernia
c. Richter's hernia
d. Umbilical hernia

81. **What is the most probable diagnosis based on the given image?** *(NEET-PG 2017)*



a. Omphalocele
b. Gastroschisis
c. Umbilical hernia
d. Ectopia vesicae

82. **Umbilical hernia in a child - indication for surgery is/are:**
a. Failure to disappear by 3 years *(MAHE 2007)*
b. >2 cm size
c. Symptomatic
d. All of the above

83. **What is false regarding gastroschisis and omphalocele?** *(DNB 2012, AIIMS 2000)*
a. Intestinal obstruction is common in gastroschisis
b. Gastroschisis is associated with multiple anomalies
c. Umbilical cord is attached in normal position in gastroschisis
d. Liver is the content of omphalocele

84. **What is the diagnosis based on the given image?** *(NEET-PG 2020)*



a. Omphalocele
b. Gastroschisis
c. Umbilical hernia
d. Spigelian hernia

85. **Hernia that is least likely to strangulate is:** *(AIIMS Nov 93)*
a. Femoral hernia
b. Direct inguinal hernia
c. Indirect inguinal hernia
d. Umbilical hernia

86. **Incidence of exomphalos:** *(MHPGMCET 2006)*
a. 1 in 1,000
b. 1 in 3,000
c. 1 in 5,000
d. 1 in 10,000

87. **True regarding gastroschisis is:** *(DNB 2003)*
a. An omphalocele
b. An anterior abdominal wall tumor
c. A variant of gastric carcinoma
d. Herniation of abdominal contents through body wall

MAYEE BROTHERS

88. What is the diagnosis based on the given image?

a. Gastroschisis
b. Omphalocele
c. Umbilical hernia
d. Ectopia vesicae



89. What is the diagnosis based on the given image? *(NEET-PG 2017)*

a. Gastroschisis
b. Omphalocele
c. Umbilical hernia
d. Epigastric hernia

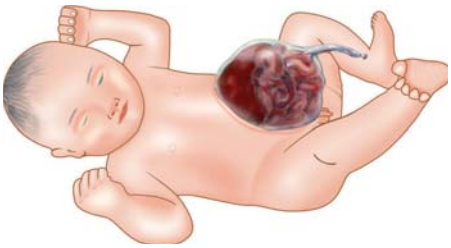

90. In omphalocele abdominal wall defect is more than:

a. 0.5 cm
b. 2.5 cm *(WBPG 2014)*
c. 4 cm
d. 6 cm

91. Omphalocele is caused by: *(NEET-PG 2019)*

a. Duplication of intestinal loops
b. Abnormal rotation of intestinal loops
c. Failure of gut to return to body cavity after its physiological herniation
d. Reversed rotation of intestinal loops

EPIGASTRIC HERNIA

92. The hernia which often simulates a peptic ulcer is: *(WB PG 2015, FMGE March 2007, Karnataka 94)*

a. Umbilical hernia
b. Fatty hernia of the linea alba
c. Incisional hernia
d. Inguinal hernia

93. True about epigastric hernia is: *(AIIMS May 2012)*

a. Located below the umbilicus and always in the midline
b. Located above the umbilicus and always in the midline
c. Located above the umbilicus and on either side
d. Can be seen anywhere on abdomen

RICHTER'S HERNIA

94. The sac contains only a portion of the circumference of the intestine: *(UPPG 2007, 2005)*

a. Richter's hernia
b. Littre's hernia
c. Spigelian hernia
d. Lumbar hernia

95. Strangulation without obstruction is seen in: *(DNB 2005)*

a. Inguinal hernia
b. Femoral hernia
c. Richter's hernia
d. Littres hernia

96. Richter hernia is most common in: *(NEET-PG 2014)*

a. Hiatus hernia
b. Femoral hernia
c. Lumbar hernia
d. Direct inguinal hernia

LITTRE'S HERNIA

97. Which of the following is content of Littre's hernia? *(DNB 2012, MHPGMET 2005)*

a. Urinary bladder
b. Meckel's diverticulum
c. Circumference of intestinal wall
d. Appendix

98. Hernia containing Meckel's diverticulum is: *(MHSSMCET 2005)*

a. Richter's hernia
b. Pantaloon hernia
c. Littre's hernia
d. Mydel's hernia

99. Which of the following hernia is being operated in the image given below? *(INI-CET Nov 2025)*



a. Litters hernia
b. Amyand's hernia
c. Gibbon's hernia
d. Richter's hernia

MISCELLANEOUS HERNIA

100. About hernia, false statements: *(PGI Dec 2003)*

a. In children, indirect inguinal hernia is treated medically
b. In Richter's hernia, absolute constipation seen
c. Indirect inguinal hernia is the MC type
d. Deep inguinal ring is lateral and above the public tubercle

101. Causes of recurrent hernia:

a. Absorbable sutures
b. Sliding hernia
c. Missed sac
d. Infection

102. Hernia with hydrocele is ..... hernia. *(NEET-PG 2016)*

a. Gibbon's
b. Fruber's
c. Dobson's
d. Leobel's

103. Hernia into pouch of Douglas is ..... hernia.

a. Beclard's
b. Bochdaleks
c. Blandin's
d. Berger's

104. The person whose work on the radical cure of hernia immortalised his name was: *(Karnataka 96)*

a. William Halsted
b. Eduardo Bassini
c. Mc Vay
d. Koontz

105. Truss cannot prevent progression of which type of inguinal hernia? *(UPPG 99)*

a. Sliding
b. Littre's
c. Indirect
d. Direct

JAYPEE BROTHERS

106. What is the name of this hernia?

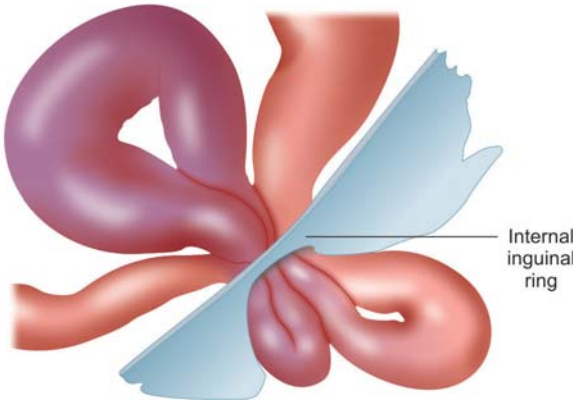

a. Pantaloons' hernia
b. Sliding hernia
c. Maydl's hernia
d. Spigelian hernia

INCISIONAL HERNIA

107. Which of the following does not predispose to abdominal wall dehiscence? *(JIPMER 92)*
a. Faulty technique
b. Malignancy
c. Raised intra-abdominal pressure
d. Old age

108. According to European Hernia Society (EHS), M3 type of hernia is: *(AIIMS Nov 2020)*
a. Suprainguinal
b. Infrainguinal
c. Umbilical
d. Femoral

109. Ventral hernia is a/an: *(AMC 99)*
a. Incisional hernia
b. Umbilical hernia
c. Femoral hernia
d. Inguinal hernia

110. Incisional hernia, not true is: *(DPG 2006)*
a. Faulty operative technique
b. There is distension of abdomen
c. Associated with infection of the wound
d. Caused by use of local anesthesia

111. Hernia prone to re-occur apter primary repair: *(JIPMER 2013)*
a. Femoral
b. Epigastric
c. Spigelian
d. Incisional

112. Point A in the given image represents which type of repair for ventral hernia? *(NEET-PG 2016)*
a. Onlay
b. Inlay
c. Retromuscular
d. Preperitoneal

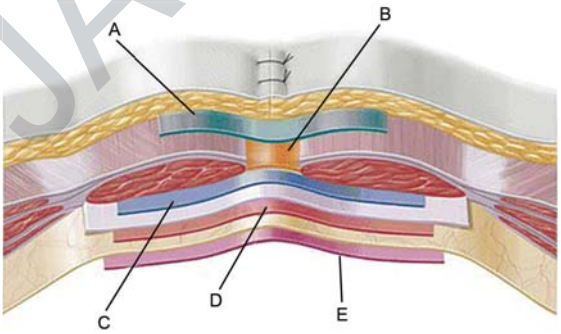

HERNIA AND ABDOMINAL WALL ANATOMY

113. A patient operated for direct inguinal hernia developed anesthesia at the root of the penis and adjacent part of the scrotum, the nerve likely to be injured is: *(AIIMS Nov 2001)*
a. Genital branch of genitofemoral nerve (supply dartos muscle)
b. Femoral branch of genitofemoral nerve
c. Iliohypogastric nerve
d. Ilioinguinal nerve

114. A patient is diagnosed with an inguinal hernia which is lateral to the inferior epigastric vessels. The structure through which this hernia emerges is a modification of: *(NEET-PG 2023)*
a. Internal oblique muscle
b. External oblique muscle
c. Fascia transversalis
d. Transversus abdominus

115. During repair of indirect inguinal hernia, while releasing the constriction at the deep inguinal ring, the surgeon takes care not to damage one of the following structures:
a. Falx inguinalis (conjoint tendon) *(AIIMS Nov 2003)*
b. Interfovelar ligament
c. Inferior epigastric artery
d. Spermatic cord

116. Preservation of ilioinguinal nerve is an important step in inguinal hernia operation while: *(UPSC 97)*
a. Incising the subcutaneous tissue
b. Incising the external oblique aponeurosis
c. Incising the cremasteric fascia
d. Isolating the sac

117. All of the following structures pass through the inguinal cannal in females *except*: *(All India 2012)*
a. Ilioinguinal nerve
b. Round ligament of uterus
c. Lymphatics from uterus
d. Inferior epigastric artery

118. Which of the following is true about deep inguinal ring?
a. Defect in fascia transversalis *(DPG 97)*
b. Transmits deep inferior epigastric artery
c. Lies just above and lateral to public tubercle
d. Opening in external oblique aponeurosis

119. On an average, the distance between femoral ring and saphenous opening (length of femoral canal) is:
a. 1.25 cm
b. 2.50 cm
c. 3.75 cm
d. 5.00 cm

120. The fibers of internal oblique and transverse abdominis contribute to which components of inguinal canal:
a. Anterior wall *(INI-CET Nov 2023)*
b. Roof
c. Floor
d. Posterior wall

UMBILICAL ADENOMA

121. Treatment of choice of umbilical adenoma in a new born is:
a. Occlusion with a coin
b. Strapping
c. Surgery
d. Masterly inactivity

122. "Raspberry tumour" is another name for: *(NEET-PG 2013)*
a. Umbilical fistula
b. Umbilical granuloma
c. Umbilical adenoma
d. Meckel's diverticulum

123. Raspberry tumour is: *(JIPMER 98)*
a. Neoplastic
b. Inflammatory
c. Traumatic
d. Congenital

JAYPEE BROTHERS

DESMOID TUMOR

124. Treatment of desmoid tumor is: *(AIIMS Nov 93)*
a. Conservative
b. Radiotherapy
c. Surgery
d. Radiotherapy following chemotherapy

125. Regarding desmoid tumour which is not correct?
a. Often seen below the umbilicus *(DNB 2002)*
b. Unencapsulated
c. More common in women
d. Metastasis does not occur
e. Highly radiosensitive

126. Recurrent fibroma refers to desmoid tumor arising in:
a. Uterus
b. Scar tissue
c. Ovary
d. Muscle

127. Treatment of choice of desmoid tumour is: *(AIIMS June 94)*
a. Surgery
b. Chemotherapy
c. Radiotherapy
d. Surgery + Radiotherapy

128. What is the treatment of choice in desmoid tumors?
a. Irradiation *(DNB 2009, UPSC 2008)*
b. Wide excision
c. Local excision
d. Local excision following radiation

129. Regarding desmoid tumour, true is: *(MHSSMCET 2011)*
a. Mostly females are affected
b. Well-capsulated tumor
c. Common above the level of umbilicus
d. Radiotherapy is treatment of choice

130. Most common presentation of abdominal desmoid tumor is: *(AIIMS Nov 2017)*
a. Abdominal pain
b. Abdominal mass
c. Fever
d. Rectal prolapse

PATENT VITELLO-INTESTINAL DUCT

131. Patent vitello-intestinal duct should preferably be operated at:
a. Birth
b. 6 months of age
c. 12 months of age
d. 3 years of age

132. The patent vitello-intestinal duct most often discharges:
a. Mucus
b. Pus
c. Urine
d. Faeces

PATENT URACHUS

133. A new born presents with discharge of urine from the umbilicus for 3 days. Diagnosis is: *(UPPG 2008)*
a. Meckel's diverticulum
b. Mesenteric cysts
c. Urachal fistula
d. Umbilical hernia

134. A child complains of fluid coming out of umbilicus on straining. What is the diagnosis? *(AIIMS Nov 2014)*
a. Urachal fistula
b. Gastroschisis
c. Patent vitellointestinal duct
d. Congenital umbilical hernia

MISCELLANEOUS

135. Which age group most often present with jaundice due to omphalitis in infants is?
a. At birth
b. 24-72 hours
c. 1-3 weeks
d. 3-6 weeks

136. Congenital hydrocele is best treated by: *(PGI 2001)*
a. Eversion of sac
b. Excision of sac
c. Lords procedure
d. Herniotomy

137. Bleeding from the umbilicus in an adult female during menstruation is suggestive of: *(All India 94)*
a. Bleeding diathesis
b. Vicarious menstruation
c. Persistent urachus
d. Purpura

138. A new born presents with mid anterior abdominal wall defect with characteristic spontaneous disappearance at age 4 years: *(UPPG 2008)*
a. Patent urachus
b. Omphalocele
c. Ectopia vesicae
d. Umbilical hernia

139. Most common cause of umbilicus not separated at age of 2 years: *(UPPG 2008)*
a. Raspberry tumour
b. Leukocyte adhesion deficiency
c. Patent urachus
d. Umbilical granuloma

140. Pascal's law is used in which technique of hernia repair?
a. Lichtenstein mesh repair *(DNB 2010)*
b. Stoppa's preperitoneal repair
c. Bassini's repair
d. Darning repair

141. All of the following are true about hernia surgery *except*: *(AIIMS Nov 2012)*
a. Surgery should not be done unless patient becomes symptomatic
b. Hernia in children is treated with herniotomy
c. Absorbable mesh should not be used for surgery
d. Surgery can be done using laparoscopy

142. Method of reduction of inguinal hernia: *(NEET-PG 2013)*
a. Kugel maneuver
b. Taxis
c. McVay procedure
d. Stoppa technique

JAYPEE BROTHERS

Explanations

CLASSIFICATION OF HERNIA

1. **Ans. a. Direct inguinal hernia** *(Ref: Sabiston 21/e p1111; Schwartz 11/e p1602)*
2. **Ans. c. Femoral hernia** *(Ref: Schwartz 11/e p1602; Schackelford 7/e p567-568)*
3. **Ans. c. IIIC**

RISK FACTORS FOR HERNIA

4. **Ans. a. Family history of inguinal hernia, b. Weight lifter, c. COPD, e. Obesity** *(Ref: Sabiston 21/e p1107; Schwartz 11/e p1604; Bailey 28/e p1059)*

INGUINAL HERNIA

5. **Ans. b. Indirect inguinal hernia** *(Ref: Sabiston 21/e p1105; Schwartz 11/e p1606; Bailey 28/e p1060; Schackelford 8/e p573)*

- **MC type** of hernia **in males**: **Indirect inguinal hernia**Q
- **MC type** of hernia **in females**: **Indirect inguinal hernia**Q
- **Femoral hernia** is **more common in females**Q.
- **Direct inguinal hernia** is **more common in** the **elderly**Q

6. **Ans. b. Indirect inguinal hernia**
7. **Ans. d. Public tubercle** *(Ref: Sabiston 21/e p1105; Schwartz 11/e p1606; Bailey 28/e p1160; Schackelford 7/e p561)*

Inguinal Hernia	Femoral Hernia
• **Neck of sac** lies **above** and **medial** to the **pubic tubercle**Q	• **Neck of sac** lies **below** and **lateral** to the **pubic tubercle**Q

8. **Ans. b. Conjoint tendon**

A direct inguinal hernia occurs due to weakness in the posterior wall of the inguinal canal, specifically the Hesselbach's triangle. The conjoint tendon, formed by the fusion of the internal oblique and transversus abdominis aponeuroses, reinforces this posterior wall. Weakness or attenuation of the conjoint tendon predisposes to protrusion of abdominal contents through the weakened area, leading to a direct hernia.

INDIRECT INGUINAL HERNIA

9. **Ans. b. Right sided is more common than left side, c. Direct hernia is less likely to undergo strangulation, d. Femoral hernia is more common in female** *(Ref: Sabiston 21/e p1106; Schwartz 11/e p1607; Bailey 28/e p1066)*
10. **Ans. b. Direct hernia and Lichtenstein repair** *(Ref: Bailey 28/e p1066; Sabiston 21/e p1106)*

Indirect inguinal hernia is lateral because its origin is lateral to the inferior epigastric vessels. Direct inguinal hernia is medial because its origin is medial to the inferior epigastric vessels. Direct hernia should be treated by Lichtenstein repair.

"An indirect hernia is lateral because its origin is lateral to the inferior epigastric vessels. It is also oblique as the hernia passes obliquely from lateral to medial through the abdominal muscle layers. The second type of inguinal hernia, referred to as direct or medial, is acquired. It is a result of stretching and weakening of the abdominal wall just medial to the inferior epigastric (IE) vessels."-*Bailey 28/e p1066*

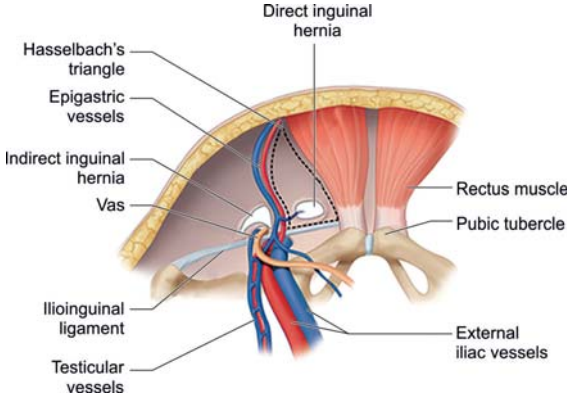

Indirect inguinal hernia (lateral to IEV) & Direct inguinal hernia (medial to IEV)

JAYPEE BROTHERS

"Inguinal hernias are classified as direct or indirect. The sac of an indirect inguinal hernia passes from the internal inguinal ring obliquely toward the external inguinal ring and ultimately into the scrotum. In contrast, the sac of a direct inguinal hernia protrudes outward and forward and is medial to the internal inguinal ring and inferior epigastric vessels." -Sabiston 21/e p1106

"Lichtenstein's repair is the most common operation for inguinal hernia in resource-rich countries."- Bailey 28/e p1069

11. **Ans. c. In Shouldice repair, non-absorbable mesh is used** *(Ref: Sabiston 21/e p1112; Schwartz 11/e p1607; Bailey 28/e p1068; Schackelford 8/e p603)*
In **Shouldice repair**, inguinal floor is strengthened by approximation of tissues using non-absorbable sutures, **mesh is not used**.

12. **Ans. b. Narrowing of the internal ring**
Most important step of hernia repair is narrowing of internal ring.

13. **Ans. a. Herniotomy**

14. **Ans. a. An impulse is often much better seen than felt**

15. **Ans. None**
After herniorrhapy, avoid strenuous activity for 6 months.

16. **Ans. c. Conjoint tendon sutured to inguinal ligament** *(Ref: Sabiston 21/e p1112; Schwartz 11/e p1612; Bailey 28/e p1068; Schackelford 8/e p602)*

Lichtenstein Tension-free Repair

- **Initial exposure** and **mobilization of cord structures** is identical to other open approaches.
- Lichtenstein repair **does not include routine division of** the **transversalis fascia**[Q].
- **Internal inguinal ring is not reconstructed** using canal structures.
- **Floor** and **internal ring** are **reinforced through** the application of the **mesh**.[Q]
- **Mesh** is **split to accommodate** the **spermatic cord**[Q].
- **Rounded edge** is **attached** to the **anterior rectus sheath**[Q] just medial to the pubic tubercle
- **Inferior margin** of the mesh is then **sutured to the shelving edge** of the **inguinal ligament**[Q]

17. **Ans. b. Direct hernia is medial to inferior epigastric artery** *(Ref: Sabiston 21/e p1106; Schwartz 11/e p1607; Bailey 28/e p1066)*

	Indirect Hernia	Direct Hernia
Age	• **Any age**	• Common in **elderly**[Q]
Herniation	• **Protrusion** through **deep inguinal ring;** Herniation occurs latter[Q]	• **Herniation** through **posterior wall** of inguinal canal
Shape	• **Pyriform/oval** in shape[Q]	• **Globular/round** shape
Descent	• **Obliquely** and **downwards**	• **Directly forwards**
Descent to scrotum	• **Descent to** the **bottom of scrotum** and becomes **complete**[Q]	• **Rarely** descent to the bottom of the scrotum
Neck	• Narrow[Q]	• **Wide**[Q]
Sac	• **Lateral** to **inferior epigastric artery**	• **Medial** to **inferior epigastric artery**
Zieman's test	• **Cough impulse** on **index finger**[Q]	• **Cough impulse** on **middle finger**
Invagination test	• **Tip** of **finger**	• **Pulp** of **finger**
Ring occlusion test	• **Does not bulge**	• **Bulge medial** to **occluding finger**
Coverings (from inside out)	• Extraperitoneal tissue • **Internal spermatic fascia**[Q] • **Cremasteric fascia**[Q] • External spermatic fascia • Skin	• Extraperitoneal tissue • **Fascia transversalis** • **Conjoint tendon** • External spermatic fascia • Skin
	• Commonly **unilateral**	• Commonly **bilateral**[Q]
Obstruction/strangulation	• **Common**	• **Rare**
Sac	• Should be **opened during surgery**	• **Not necessary,** unless obstruction is present

18. **Ans. a. Omentum** *(Ref: Bailey 28/e p1060)*

19. **Ans. c. 1, 3 and 4** *(Ref: Schwartz 11/e p1600, 1603; Sabiston 21/e p1115)*

The triangle of doom is bordered medially by the vas deferens and laterally by gonadal vessels. Myopectineal orifice (MPO) of Fruchaud is bounded medially by rectus abdominis and its fascial rectus sheath and laterally by iliopsoas muscle.

JAYPEE BROTHERS

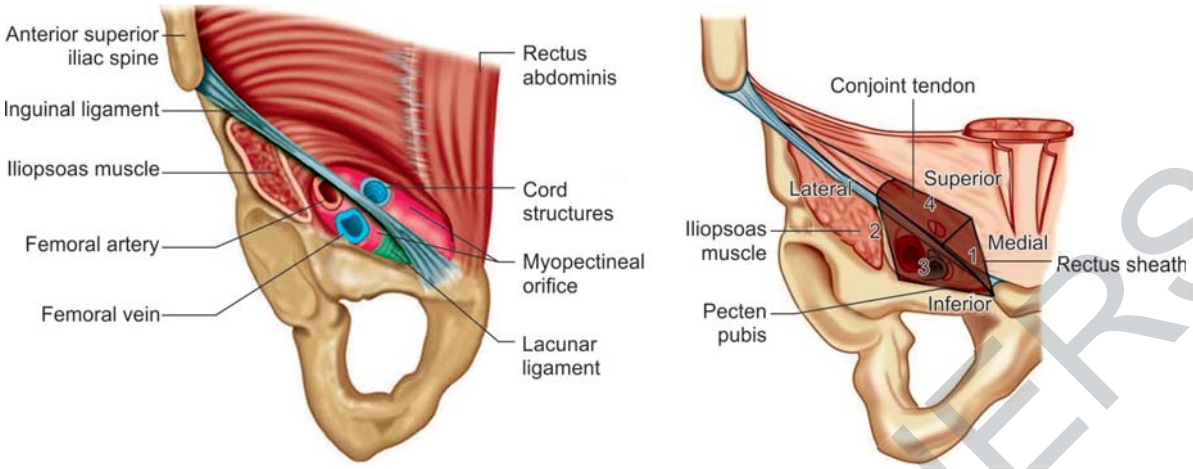

Boundaries of Myopectineal orifice of Fruchaud

Myopectineal orifice (MPO) of Fruchaud
MPO is bordered: • **Above** by the **arching fibres of internal oblique & transversus abdominis** muscle[Q] • **Medially** by **rectus abdominis** and its fascial **rectus sheath**[Q] • **Inferiorly** by **Cooper's ligament**[Q] • **Laterally** by **iliopsoas muscle**[Q] • **Running diagonally through the MPO is inguinal ligament**[Q]

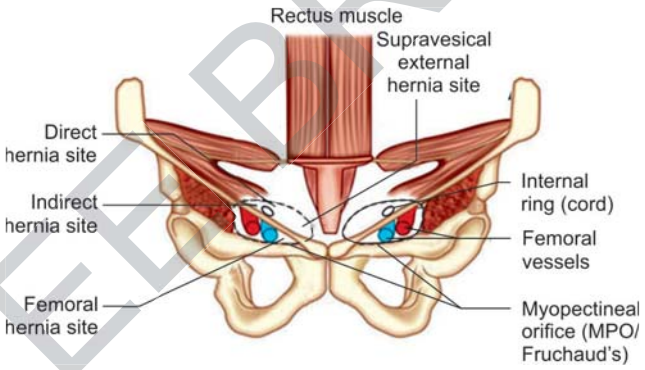

Myopectineal orifice of Fruchaud

20. **Ans. a. Cooper's ligament** *(Ref: Sabiston 21/e p1115; Schwartz 11/e p1607)*

21. **Ans. a. Medially vas deferens, laterally gonadal vessels, inferiorly peritoneum** *(Ref: Schwartz 11/e p1605; Sabiston 21/e p1115)*

22. **Ans. a. Triangle of Doom**

23. **Ans. b. Always unilateral**

24. **Ans. a. 1, 2, 3, 4**

25. **Ans. c. Indirect inguinal hernia**

26. **Ans. b. Intraperitoneal mesh repair**

27. **Ans. d. Repair of stretched inguinal ring and fascia transversalis**

28. **Ans. b. Transversus abdominis muscle** *(Ref: Sabiston 21/e p1109; Bailey 28/e p1066; Schackelford 8/e p599)*

Hesselbach's Triangle		
Lateral Border	**Medial Border**	**Base**
• **Epigastric artery**[Q]	• **Lateral border** of **rectus abdominis**[Q] where it is attached to pubic crest	• **Inguinal ligament**

- **Indirect inguinal hernia** comes out of abdominal cavity **through deep inguinal ring**[Q], travel inguinal canal and becomes superficial through superficial inguinal ring.
- **Direct inguinal hernia** enters inguinal canal through **medial half** of **weak posterior wall** (**Hesselbach's triangle**[Q]) and becomes superficial through superficial inguinal ring.

JAYPEE BROTHERS

29. Ans. a. External oblique aponeurosis *(Ref: Sabiston 21/e p1109; Schwartz 11/e p1605; Bailey 28/e p1053)*

External oblique aponeurosis is in close relation to ilioinguinal nerve and hence during operation for inguinal hernia, prevention of injury to ilioinguinal nerve to avoid later development of incisional hernia is very important.

Nerves in Relation to Inguinal Hernia

Ilioinguinal Nerve	Iliohypogastric Nerve	Genitofemoral Nerve
• **Pierces transversus abdominis** and **internal oblique** above the iliac crest and **inters inguinal canal**[Q].	• **Pierces transversus abdominis**, travels **between transversus abdominis** and **internal oblique** until it **pierces** the aponeurosis of **both obliques**[Q] just above the external ring	• Divides into two branches – **Genital branch** of genitofemoral nerve **enters** the **inguinal canal** at **deep ring** and **supplies**[Q] **cremaster** and **scrotal skin** – **Femoral branch** of genitofemoral nerve **passes behind** the **inguinal ligament**, enters femoral sheath lateral to femoral artery, pierces the anterior layer of femoral sheath and fascia lata and **supplies** the **skin anterior** to **upper part of femoral triangle**[Q].
• It **emerges from superficial** inguinal **ring** to **supply skin of**: – **Proximomedial skin** of **thigh**[Q] – **Skin** over **penile root**[Q] – **Upper part** of **scrotum**[Q]	• It divides into two branches. – **Lateral cutaneous** supplies **posterolateral gluteal skin**[Q] – **Anterior cutaneous** supplies **suprapubic skin**[Q]	

30. Ans. a Multilayered repair of inguinal canal *(Ref: Sabiston 21/e p1112; Schwartz 11/e p1610; Bailey 28/e p1068; Schackelford 8/e p603)*

Shouldice Repair

- Primary tenets of the procedure involve **extensive dissection** and **reconstruction of inguinal canal anatomy**[Q].
- The use of a **continuous suture in multiple layers** resulted in the **dual advantage of distributing tension** over several layers and **preventing subsequent herniation** between interrupted sutures[Q].
- Consists of division and **double breasting** of the **transversalis fascia**[Q]

31. Ans. None *(Ref: Sabiston 21/e p1112; Schwartz 11/e p1610; Bailey 28/e p1068; Schackelford 8/e p603)*

- **Bassini's repair:** A **triple-layer repair** is then performed to restore integrity to the floor. The **medial tissues**, including the **internal oblique**, **transversus abdominis** muscle and **transversalis fascia**, are **fixed to the shelving edge of the inguinal ligament** and **pubic periosteum** with interrupted sutures (**Inguinal ligament** is **sutured to conjoint tendon**[Q]).
- **Shouldice repair** leads to **posterior wall strengthening**[Q]
- The **advantage of the McVay** (Cooper's ligament) **repair** is the ability to **address both inguinal** and **femoral canal defects**[Q].

32. Ans. b. Indirect inguinal hernia

33. Ans. a. The sac contains omentum only *(Ref. Schwartz 11/e p1607; Bailey 28/e p1060)*

Content of Hernia	Name	Reduction
Omentum	Omentocele[Q]	• Omentum is doughy[Q] • The last portion is more difficult to reduce than the first[Q].
Intestine	Enterocele[Q]	• Gurgles on reduction[Q] • First portion is more difficult to reduce than the last[Q].

34. Ans a. Herniotomy *(Ref. Sabiston 20/e p1884; Schwartz 11/e p1607; Bailey 28/e p1565)*

35. Ans. b. Laparoscopic hernia surgery

36. Ans. d. All are correct *(Ref: Campbell 11/e p3182)*

37. Ans. a. Laparoscopic *(Ref: Sabiston 21/e p1115; Schwartz 11/e p1613)*

COMPLICATIONS OF HERNIA

38. Ans. d. Correction of hypovolemia, e. Prepare OT for urgent surgery *(Ref: Sabiston 21/e p1118; Schwartz 11/e p1620; Bailey 28/e p1376)*

39. Ans. d. Lateral cutaneous nerve of thigh

40. Ans. b. Ilioinguinal nerve *(Ref: Sabiston 21/e p1083)*

Ilioinguinal nerve fibres** are distributed to the skin of upper and medial part of thigh, and to the following locations in the male and female: In the male (**"anterior scrotal nerve"**): to the **skin over root of penis** & **upper part of scrotum;** In the female (**"anterior labial nerve"**): to the **skin covering mons pubis & labia majora.

JAYPEE BROTHERS

41. **Ans. d. Lateral cutaneous nerve of thigh** *(Ref: Sabiston 21/e p1103)*

> ***"The mesh is carefully secured with a tacking stapler to Cooper ligament from the pubic tubercle to the external iliac vein, anteriorly to the posterior rectus musculature and transversus abdominis aponeurotic arch at least 2 cm above the hernia defect, and laterally to the iliopubic tract. The mesh extends beyond the pubic symphysis and below the spermatic cord and peritoneum. The mesh is not fixed in this area and tacks are not placed inferior to the iliopubic tract beyond the external iliac artery. Staples placed in this area may injure the femoral branch of the genitofemoral nerve or lateral femoral cutaneous nerve."*** *-Sabiston 21/e p1115*

42. **Ans. c. Fundus**
43. **Ans. b. Immediate surgery**
44. **Ans. b. Tenderness**
45. **And. a. Lateral cutaneous nerve of thigh** *(Ref: Sabiston 21/e p1115; Schwartz 11/e p1619)*

> *"**Neuropathic groin pain is caused by damage to a nerve in the groin region and** may be due to partial or complete division, stretching, contusion, crushing, suturing, or electrocautery. The **nerves that are usually involved** are the **ilioinguinal nerve, iliohypogastric nerve, both the genital and femoral branches of the genitofemoral nerve,** and the **lateral femoral cutaneous nerve of the thigh.** The **first two are especially prone to injury during an open herniorrhaphy,** while the **latter (i.e. Lateral cutaneous nerve of thigh) are more likely damaged during laparoscopy.** The **genital and femoral branches of the genitofemoral nerve** and the **lateral cutaneous nerve of the thigh are most at risk** when the surgeon staples below the iliopubic tract when lateral to the internal spermatic vessels. A **burning, tingling pain along the lateral aspect of the thigh in the distribution of the lateral femoral cutaneous nerve** is known as **meralgia paresthetica,** and is **due to entrapment of that nerve;** the affected skin area may be hyperaesthetic and/or pruritic, and patients may complain of the tactile hallucination of a sensation of small insects creeping under the skin (formication)." (Schwartz 11/e p1619)*

46. **Ans. a. Ilioinguinal nerve**

FEMORAL HERNIA

47. **Ans. b. Pregnancy is common cause** *(Ref: Sabiston 21/e p1117; Schwartz 11/e p1607; Bailey 28/e p1062; Schackelford 8/e p606)*
48. **Ans. c. Strangulated femoral hernia**
49. **Ans. d. Femoral vein**
50. **Ans. a. Lateral and below**
51. **Ans. a. Low inguinal operation**
52. **Ans. a. Femoral hernia**
53. **Ans. c. Lacunar ligament**
54. **Ans. d. McVay repair** *(Ref: Schwartz 11/e p1610)*

    McVay repair closes the femoral space, is effective for femoral hernia.
55. **Ans. a. Cloquet's hernia** *(Ref: Bailey 25/e p978-979)*
56. **Ans. a. Lacunar ligament**
57. **Ans. a. Below and lateral to pubic tubercle**

SPIGELIAN HERNIA

58. **Ans. a. Usually occurs above arcuate line** *(Ref: Sabiston 21/e p1128; Bailey 28/e p1075; Schackelford 8/e p580)*
59. **Ans. b. Subumbilical region**
60. **Ans. b. Lateral border of rectus abdominis**
61. **Ans. d. Hernia occurring at the level of arcuate line**
62. **Ans. b. Internal oblique**

SLIDING HERNIA

63. **Ans. d. Sigmoid colon** *(Ref: Sabiston 21/e p1118; Bailey 28/e p1066)*
64. **Ans. b. Hernia-en-Glissade** *(Ref: Sabiston 21/e p1118; Bailey 28/e p1066)*
65. **Ans. b. Sigmoid colon**
66. **Ans. c. Sliding hernia**

LUMBAR HERNIA

67. **Ans. d. More common on right side** *(Ref: Sabiston 21/e p1129; Schwartz 11/e p1554; Bailey 28/e p1076; Schackelford 8/e p606)*
68. **Ans. a. More commonly congenital** *(Ref: Sabiston 21/e p1129; Bailey 28/e p1076)*

> **Lumbar hernias can be either congenital (20%) or acquired (80%).**

JAYPEE BROTHERS

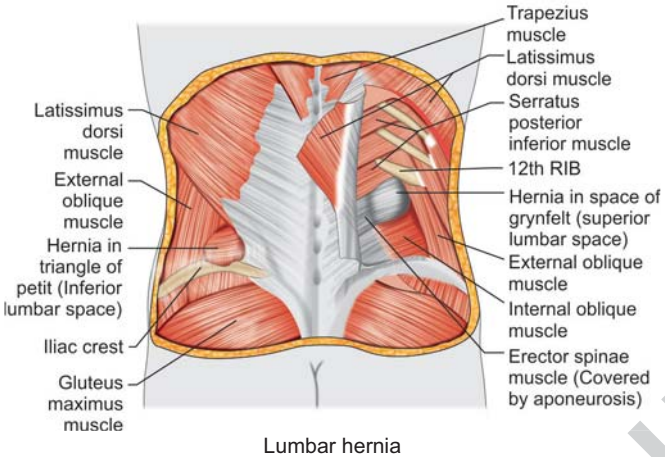

Lumbar hernia

OBTURATOR HERNIA

69. **Ans. b. Common in female, c. Chronic constipation risk factor, d. Surgical treatment should be done, e. May present with intestinal obstruction** *(Ref: Sabiston 21/e p1129; Bailey 28/e p1079; Schackelford 8/e p611)*
70. **Ans. b. Obturator hernia**

PARADUODENAL HERNIA

71. **Ans. d. Common on right side** *(Ref: Sabiston 21/e p1097; Schackelford 8/e p861)*
72. **Ans. d. More common on right side**
73. **Ans. a. Stammer's hernia** *(Ref: www.ncbi.nlm.nih.gov› Ann Surg › v.177(5); May 1973)*

Stammer's Hernia

- **Internal hernia** occurring **through window in** the **transverse mesocolon after** retrocolic **gastrojejunostomy** is known as Stammer's hernia[Q].
- Stammer's Hernia **can lead to colonic ischemia**

UMBILICAL HERNIA

74. **Ans. b. Amniotic membrane** *(Ref: Sabiston 21/e p1121, 1889; Schwartz 11/e p1554; Bailey 28/e p1072)*
75. **Ans. a. Umbilectomy with herniorrhaphy**
76. **Ans. c. Failure of gut to return to the body cavity from the physiological herniation**
77. **Ans. b. 2.5** *(Ref: pubmedcentralcanada.ca/e ppmcc/articles/.../annrcse01490-0010.pdf)*

Moore's Classification of Omphalocele	
Type	**Diameter of Defect**
Type 1	**<2.5 cm[Q]**
Type 2	**2.5 to 5 cm**
Type 3	**>5 cm**

78. **Ans. b. 1, 2 and 4**
79. **Ans. a. Birth** *(Ref: Sabiston 21/e p1121, 1889; Schwartz 11/e p1554; Bailey 28/e p1072)*
80. **Ans. d. Umbilical hernia** *(Ref: Sabiston 21/e p1121; Schwartz 11/e p1554; Bailey 28/e p1072; Schackelford 8/e p579)*
81. **Ans. c. Umbilical hernia** *(Ref: Sabiston 21/e p1121; Schwartz 11/e p1554; Bailey 28/e p1072)*
82. **Ans. d. All of the above**
83. **Ans. b. Gastroschisis is associated with multiple anomalies**
84. **Ans. b. Gastroschisis** *(Ref: Bailey 28/e p270; Schwartz 11/e p1554; Sabiston 21/e p1867)*

In this newborn image, the bowel is exposed and located on the right side of umbilical cord is highly suggestive of gastroschisis.

JAYPEE BROTHERS

"Gastroschisis is another congenital defect of the abdominal wall in which the umbilical membrane has ruptured in utero, allowing the intestine to herniate outside the abdominal cavity. The defect is almost always to the right of the umbilical cord, and the intestine is not covered with skin or amnion."- Sabiston 21/e p1083

85. Ans. b. Direct inguinal hernia

86. Ans. c. 1 in 5000

87. Ans. d. Herniation of abdominal contents through the body wall

88. Ans. a. Gastroschisis

89. Ans. b. Omphalocele

90. Ans. c. 4 cm

Omphalocele/exomphalos: Congenital herniation of abdominal contents at the umbilicus (i.e. into the umbilical cord). Occasionally divided into:

- **< 4 cm—Umbilical cord hernia**
- **> 4 cm—Omphalocele**

91. Ans. c. Failure of gut to return to body cavity after its physiological herniation *(Ref: Schwartz 11/e p1554; Sabiston 21/e p1083,1867; Bailey 28/e p270)*

EPIGASTRIC HERNIA

92. Ans. b. Fatty hernia of the linea alba *(Ref: Sabiston 21/e p1122; Schwartz 11/e p1554; Bailey 28/e p1074; Schackelford 8/e p573)*

93. Ans. c. Located above the umbilicus and on either side

- **Epigastric hernias are multiple in** up to **20%** of patients, and **about 80%** are **just off the midline**Q.

RICHTER'S HERNIA

94. Ans. a. Richter's hernia *(Ref: Bailey 28/e p1060)*

Richter's Hernia

- Richter's hernia is a hernia in which the **sac contains only a portion** of the **circumference** of the **intestine**Q (usually small intestine).
- It usually **complicates femoral** and, rarely, obturator hernias.

Strangulated Richter's Hernia

- **Operation** is frequently **delayed** because the **clinical features mimic gastroenteritis**Q.
- The **local signs of strangulation** are often **not obvious**Q
- Patient may not vomit and, although colicky pain is present
- **Bowels** are often **opened normally** or there **may be diarrhea**Q
- **Absolute constipation** is **delayed** until paralytic ileus supervenes.
- For these reasons, **gangrene of the knuckle of bowel** and **perforation** have often **occurred before operation** is undertakenQ.

95. Ans. c. Richter's hernia

96. Ans. b. Femoral hernia

LITTRE'S HERNIA

97. Ans. b. Meckel's diverticulum *(Ref: Bailey 28/e p1312)*

98. Ans. c. Littre's hernia

Littre's Hernia

- **Littre's hernia** is the **protrusion of a Meckel's diverticulum**Q through a potential abdominal opening.

99 Ans. a. Litters hernia

In the image, the content of hernia is Meckel's diverticulum, known as Littre's hernia.

MISCELLANEOUS HERNIA

100. Ans. a. In children, indirect inguinal hernia is treated medically, b. In Richter's hernia, absolute constipation seen, d. Deep inguinal ring is lateral and above the public tubercle *(Ref: BDC 4/e pvol II/e p208)*

- **Surgery** is the **only treatment option for hernia in any age group**, there is no role of medical treatment.
- **Deep ring** is **situated 1.25 cm above** the **inguinal ligament**, **midway between** the **symphysis pubis** and **ASIS**Q.
- **Deep ring** is an **opening in** the **fascia transversalis**Q.
- **Superficial ring** lies **immediately above the pubic tubercle**, as a **triangular gap in** the **external oblique aponeurosis**Q.
- **Clinical features** mimic **gastroenteritis** in **strangulated Richter's hernia**Q.

JAYPEE BROTHERS

101. Ans. a. Absorbable sutures, c. Missed sac, d. Infection *(Ref: Bailey 28/e p1062)*

Recurrent Hernias

- **Reported recurrence rates** vary between **0.2% and 15%** depending on the technique employed.
- Only **50% of recurrences** will become apparent **within 2 years**Q.
- Causes of **recurrent inguinal hernias**, especially those that appear in the **first postoperative year**, are usually due to **errors of observation**, **judgment,** or **surgical technique**Q.

Causes of Recurrence	
• **Failure to perform high ligation** or **reduce the peritoneal sac** with an indirect herniaQ • **Inadequate closure** of the **internal ring**Q • Missed sacQ	• **Metabolic problems** of the tissues in the groinQ • **Infection**Q that destroys the repair • **Continuing failure** of the floor of the canalQ

Dual (Saddle-bag or Pantaloon) Hernia

- This type of hernia **consists of two sacs** that **straddle the inferior epigastric artery, one sac being medial** and the **other lateral** to this vessel.
- The condition is not rare and is a **cause of recurrence**, one of the sacs having been overlooked at the time of operation.

102. Ans. a. Gibbon's

Gibbon's hernia	• Hernia with hydroceleQ
Berger's hernia	• **Hernia** into **pouch** of **Douglas**Q
Beclard's hernia	• **Femoral hernia** through **opening of saphenous vein**Q
Amyand's hernia	• Inguinal hernia **containing appendix**Q
Ogilve's hernia	• Hernia through the **defect in conjoint tendon** just lateral to where it inserts with the rectus sheathQ
Stammer's hernia	• **Internal hernia** occurring **through window in** the **transverse mesocolon after** retrocolic **gastrojejunostomy**Q
Peterson hernia	• Hernia **under Roux limb** after **Roux-en-Y gastric bypass**Q
Velpeau hernia	• Hernia **in front** of **femoral vessels**
Holthouse hernia	• Inguinal hernia with **extension of the loop of intestine along inguinal ligament**.

103. Ans. d. Berger's **104. Ans. b. Eduardo Bassini** **105. Ans. a. Sliding**

106. Ans. c. Maydl's hernia *(Ref: Abdominal Wall Hernias: Principles and Management by Robert Bendavid (2012)/p563)*

Maydl's hernia (Hernia-in-W)

- In **Maydl's hernia, a loop of bowel in the form of 'W' lies in the hernial sac** & **central portion of the 'W' loop is strangulated** and **lies within the abdominal cavity.**
- **Maydl's hernia** is a **complication of large hernial sacs**

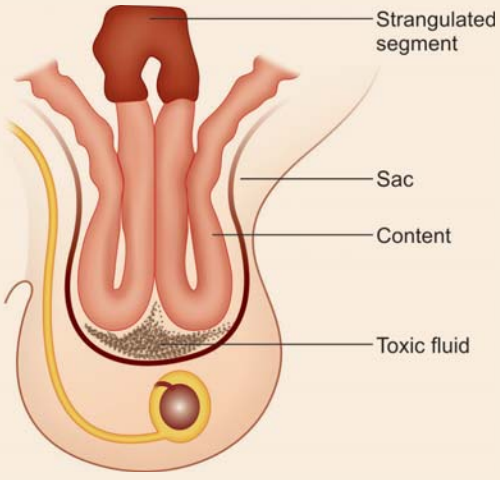

JAYPEE BROTHERS

INCISIONAL HERNIA

107. Ans. d. Old age *(Ref: Sabiston 21/e p1122; Schwartz 11/e p1555; Bailey 28/e p1077; Schackelford 8/e p574)*

Old age is a risk factor for incisional hernia, but not for wound dehiscence.

108. Ans. c. Umbilical: *(Ref: Management of Abdominal Hernia by Karl A. LeBlanc, Andrew Kingsnorth, David L. Sanders (2018)/e p366)*

According to European Hernia Society (EHS), M3 type of hernia is umbilical.

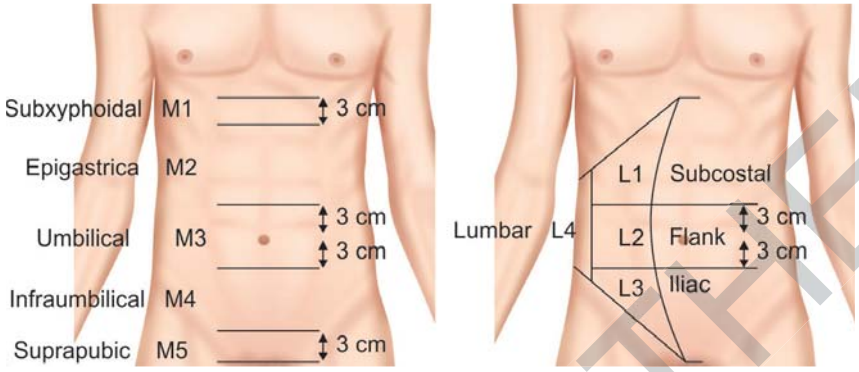

EHS Incisional Hernia Classification

EHS Incisional Hernia Classification				
Midline		Lateral		
M1	Subxiphoidal	L1	Subcostal	
M2	Epigastric	L2	Flank	
M3	Umbilical°	L3	Iliac	
M4	Infraumbilical	L4	Lumbar	
M5	Suprapubic			
Recurrent incisional hernia		Yes O		No O
Length: cm		Width: cm		
Width: cm	W1 <4 cm O	W2 ≥4–10 cm O		W3 ≥10 cm O

109. Ans. a. Incisional hernia

110. Ans. d. Caused by use of local anesthesia

111. Ans. d. Incisional

112. Ans. a. Onlay *(Ref: Sabiston 21/e p1125)*

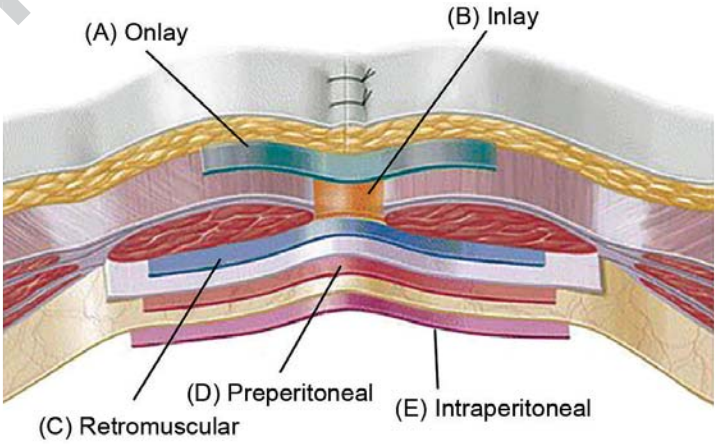

JAYPEE BROTHERS

Mesh Placement in Abdominal Wall Reconstruction		
Onlay (Overlay)	**Underlay (Sublay)**	**Inlay**
• Placement of **mesh over anterior fascia** after closure of the fascial defect[Q] • Mesh is **placed outside the abdominal cavity** avoiding direct contact with abdominal viscera[Q]	• Placement of **mesh below the fascial components**[Q] **(retrorectus, preperitoneal, or intraperitoneal** position) • **Intra-abdominal pressure** acts to **hold the mesh** and **prevent migration** due to wide overlap of mesh and fascia[Q].	• **Mesh** is **sutured to the fascial edge without overlap**[Q] • Associated with **high recurrence rate**[Q] because high intra-abdominal pressure pulls away the mesh from fascial edges
	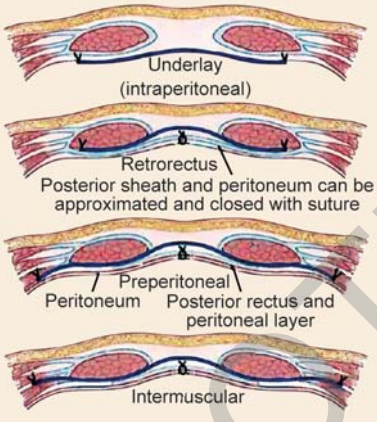	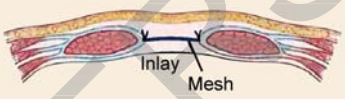

HERNIA AND ABDOMINAL WALL ANATOMY

113. Ans. d. Ilioinguinal nerve

114. Ans. c. Fascia transversalis *(Ref: Bailey 28/e p1065)*

Inguinal hernia lateral to inferior epigastric artery is indirect, which comes out via deep ring. Deep ring is a defect in fascia transversalis.

115. Ans. c. Inferior epigastric artery *(Ref: BDC 4/e pvol II/e p208)*

Deep ring lies immediately lateral to inferior epigastric artery, so artery is being in danger of getting damaged while releasing the constriction at the deep ring.

Openings in Inguinal Canal

Superficial Inguinal Ring	Deep Inguinal Ring
• **Triangular defect in** the **external oblique aponeurosis**[Q]. • Lies **immediately above** the **pubic tubercle**[Q]	• **Defect in** the **fascia transversalis**[Q] • **Situated 1.25 cm above** the **inguinal ligament**, **midway between** the **symphysis pubis** and **ASIS**[Q]. • Lies **immediately lateral to inferior epigastric artery**[Q]

116. Ans. b. Incising the external oblique aponeurosis

117. Ans. d. Inferior epigastric artery *(Ref: BDC 5/e pvol II/e p224)*

Structures Passing through Inguinal Canal

Males	Females
• **Spermatic cord**[Q] • **Ilioinguinal nerve**[Q]	• **Round ligament of uterus**[Q] (accompanied by **lymphatics** and **remains** of **processus vaginalis**[Q]) • **Ilioinguinal nerve**[Q]

JAYPEE BROTHERS

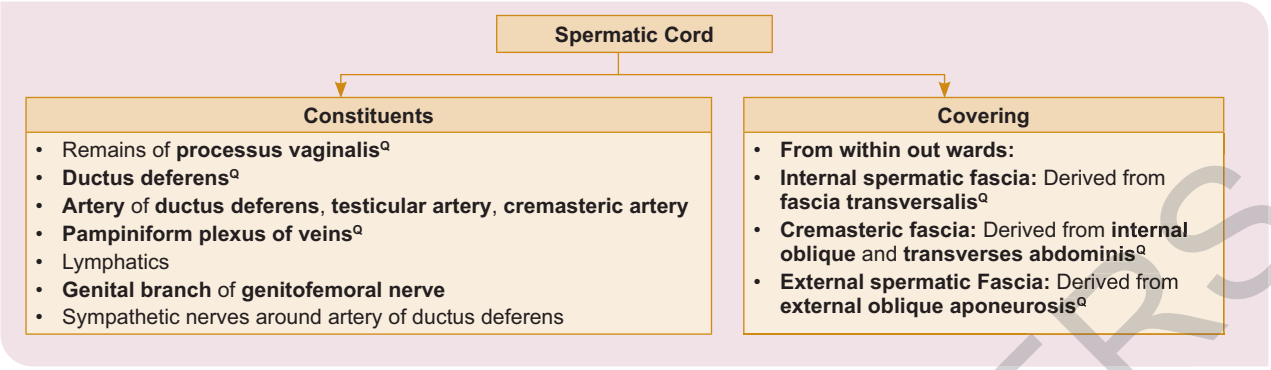

118. Ans. a. Defect in fascia transversalis **119. Ans. a. 1.25 cm** **120. Ans. b. Roof**

UMBILICAL ADENOMA

121. Ans. None *(Ref: Bailey 26/e p968)* **122. Ans. c. Umbilical adenoma** **123. Ans. d. Congenital**

DESMOID TUMOR

124. Ans. c. Surgery *(Ref: Sabiston 21/e p745; Schwartz 11/e p1557; Bailey 28/e p1082; Schackelford 8/e p1967)*

125. Ans. e. Highly radiosensitive **126. Ans. b. Scar tissue** **127. Ans. a. Surgery**

128. Ans. b. Wide excision *(Ref: Devita 9/e p1573)*

- Devita says "In desmoid tumors, **postoperative radiation** is **not recommended** in patients **with negative margins**. **Residual tumor** from a primary lesion **does not invariably lead to treatment failure** and **adjuvant radiation may be omitted** as long as local progression would not cause significant morbidity."

129. Ans. a. Mostly females are affected

130. Ans. b. Abdominal mass *(Ref: Sabiston 21/e p745; Schwartz 11/e p1557; Bailey 28/e p1082)*

"Patients with a desmoid tumor present with an asymptomatic mass or with symptoms related to mass effect from the tumor." *(Sabiston 20/e p1073)*

PATENT VITELLO-INTESTINAL DUCT

131. Ans. b. 6 months of age *(Ref: Bailey 28/e p1080)*

Patent Vitellointestinal Duct

- The **resulting umbilical fistula discharges mucus**Q and, rarely, feces.
- A **patent vitellointestinal duct** should be **excised, together with** a **Meckel's diverticulum** if present, preferably when the child is about **6 months**Q old.

132. Ans. a. Mucus

PATENT URACHUS

133. Ans. c. Urachal fistula *(Ref: Bailey 28/e p1080)*

Patent Urachus

- A **patent urachus seldom reveals** itself **until maturity** or **even old age**Q.
- This is because the **contractions of** the **bladder commence at the apex** of the organ and **pass towards the base**Q.
- Because it opens into the apex of the bladder a **patent urachus is closed temporarily during micturition** and so the potential urinary stream from the bladder is cut off.
- Thus, the **fistula remains unobtrusive until a time when** the **organ is overfull**, usually due to **some form of obstruction**Q.

Treatment

- **Remove the obstruction**Q in the lower urinary tract.
- If the **leak continues** or a **cyst develops** in connection with the urachus: **Umbilectomy** and **excision of the urachus**Q

134. Ans. a. Urachal fistula

JAYPEE BROTHERS

MISCELLANEOUS

135. Ans. d. 3-6 weeks *(Ref: Bailey 27/e p1044)*

Omphalitis

- Incidence of an **infected umbilicus** is much higher in **communities that do not practice aseptic severance** of the umbilical cord.
- When the stump of the umbilical cord becomes inflamed, **antibiotic therapy** usually **localizes the inflammation.**
- By employing warm, moist dressings, the crusts separate, giving exit to pus.
- **Exuberant granulation tissue** requires a **touch of silver nitrate**.
- In more serious cases, infection is liable to spread along the **defunct hypogastric arteries** or **umbilical vein**.
  - **Jaundice in the newborn**: **Infection reaching** the **liver via** the **umbilical vein** may cause a stenosing intrahepatic cholangiolitis, appearing some **3-6 weeks after birth**Q.

136. Ans. d. Herniotomy

137. Ans. b. Vicarious menstruation

138. Ans. d. Umbilical hernia

139. Ans. b. Leukocyte adhesion deficiency

- **Leukocyte adhesion deficiency** is associated with **recurrent bacterial infection** and **impaired wound healing**Q.

140. Ans. b. Stoppa's preperitoneal repair *(Ref: Recent advances in surgery 10/e p166)*

Stoppa's Preperitoneal Repair

- In **Stoppa's preperitoneal repair**, the expanding intra-abdominal pressure holds the mesh in place without suture fixation.
- According to **Pascal's law,** any additional pressure exerted upon an enclosed fluid mass is transmitted equally in all directions.
- Use of large mesh extending 3-5 cm beyond the edge of defect in all sides **utilizes Pascal's law.**

141. Ans. a. Surgery should not be done unless patient becomes symptomatic *(Ref: Sabiston 21/e p1111; Schwartz 11/e p1608; Bailey 28/e p1062)*

- Sabiston says "**Most surgeons recommend operation on discovery of an inguinal hernia** because the natural history of a groin hernia is that of **progressive enlargement** and **weakening**, with the **potential for incarceration** and **strangulation."**
- Bailey says " The **basic operation** is **inguinal herniotomy**, which entails dissectiong out and opening the hernial sac, reducing any content and then transfixing the neck of the sac and removing the remainder. It is employed either by itself or as the first step in a repair procedure (herniorrhaphy). By itself, it is **sufficient for** the **treatment of hernia in infants, adolescents** and **young adults**."
- **Non-absorbable mesh** is **used in hernia surgery**.
- **Surgery can be done using laparoscopy (TEP or TAPP)**

142. Ans. b. Taxis *(Ref: Schwartz 10/e p1505)*

JAYPEE BROTHERS

for detailed information on surgery books, visit our website www.ejaypee.com, for detailed information on surgery books, visit our website www.ejaypee.com, for detailed infor

SURGERY ESSENCE

Salient Features

- Synopsis added before questions to build concepts and to save precious time
- New NBE based pattern (wider coverage, concept development, one-liner approach)
- Image-based Questions with Answers (According to Recent Examinations) have been added
- Solved MCQs (PGMEEs 2025–1985) including All Recent Questions (2025–2013)
- Thoroughly revised, updated and fully colored edition
- Thoroughly verified answers from MCh aspirants and residents
- Explanations in tabulated form
- Explanations incorporating only relevant and high yielding facts
- Highlighted important and golden facts
- Explanations from most authentic surgery books
- Repeated questions grouped together to save your precious time
- Line diagrams to minimize tedious efforts
- Mnemonics for faster learning
- Controversial questions have been handled with special care.

This book is an attempt to provide you with the thorough knowledge of the subject but with a viewpoint that the most important thing is to clear the exam as the competition is intense. There is a difference between just preparing for an exam and preparing to achieve the topmost score. So, the book has covered all the topics but with special emphasis on the important and high-yielding facts to minimize your tedious efforts and to save your precious time. Remember that without proper revision it is of no use to cover huge amount of syllabus. Last but not least, the surest way not to fail is to determine to succeed. All the best…

Dr Pritesh Singh MBBS (MAMC) MS (Surgery) FMAS FIAGES is graduate from Maulana Azad Medical College and postgraduate from Lady Hardinge Medical College, New Delhi, India, is an excellent teacher and has been taking awe inspiring classes in various countries since 2009. He is amongst the best faculty and is very popular with students because of his spellbinding classes. He is a renowned educationist and the author of Surgery Essence, a benchmark resource that needs no introduction. He has also written several other leading titles, including NEET/NEXT Essence, INI-CET Essence, Quick Revision of Surgery, and AIIMS Essence. The students all over the country admire the way he teaches. He is not just a source of inspiration for his pupils rather he is their role model, as he is young and dynamic. He sets a positive example with his style of teaching, courtesy, cooperation and professionalism. Some students say he is a magician who keeps his students spellbound throughout his class. His performance speaks volumes about his knowledge and precision.



Dr Pritesh Singh
Director
Dr Pritesh Institute

Shelving Recommendation
SURGERY

ISBN 978-93-5696-302-3

Buy from ejaypee

JAYPEE BROTHERS