Information on pathology books, visit our website www.jaypeebrothers.com, for detailed information on pathology books, visit our website www.jaypeebrothers.com.

REVIEW OF
POSTGRADUATE
PATHOLOGY

d information on pathology books, visit our website www.jaypeebrothers.com, for detailed information on pathology books, visit our website www.jaypeebrothers.com

REVIEW OF
POSTGRADUATE
PATHOLOGY

SYSTEMIC PATHOLOGY
VOLUME 1

HIGHLIGHTS

- Simplified Systemic Pathology for MD and DNB Postgraduates: Enhancing Comprehension and Recall
- Guaranteed Achievement: Excelling in Written Exams and Oral Assessments
- Curated Frequently Posed Queries in Systemic Pathology for MD and DNB Scholars
- Encompassing Unexplored Subjects in Pathology beyond Standard Texts
- Focus on Essentials: Signposted Core Concepts for Rapid Grasp



Ramadas Nayak
Rakshatha Nayak

JAYPEE

UME 2

JAYPEE

Look Inside the Book

CONTENTS

VOLUME 1

1. Blood Vessels and Lymphatics **1**

1.1 Vascular Structure and Function, Vascular Anomalies, Vascular Wall Response to Injury, and Hypertensive Vascular Disease *1*

1.2 Arteriosclerosis and Atherosclerosis *23*

1.3 Aneurysms, Dissection, Vasculitis, Veins, and Lymphatics *44*

1.4 Vascular Malformations, Reactive Vascular Proliferations, and Vascular Tumors *69*

1.5 Lymphatic Tumors, Perivascular Tumors, and Pathology of Vascular Intervention *89*

2. The Heart **96**

2.1 Cardiac Structure *96*

2.2 Heart Failure *106*

2.3 Embryologic Development of Heart and Congenital Heart Disease *116*

2.4 Ischemic Heart Disease, Hypertensive Heart Disease, Arrhythmias, and Sudden Cardiac Death *138*

2.5 Valvular Heart Disease *170*

2.6 Cardiomyopathy, Myocarditis, and Other Myocardial Diseases *193*

2.7 Pericardial Disease, Tumors of the Heart, Cardiac Transplantation, Cardiac Devices, and Myocardial Biopsy *211*

3. Lung, Pleura, and Mediastinum **225**

3.1 Normal Respiratory System, Congenital Anomalies, Cystic Diseases, Atelectasis, Pulmonary Edema, Acute Lung Injury, and Acute Respiratory Distress Syndrome *225*

3.2 Obstructive Lung Diseases *242*

3.3 Chronic Diffuse Interstitial (Restrictive) Diseases *265*

3.4 Diseases of Vascular Origin *292*

3.5 Pulmonary Infections and Lung Transplantation *300*

3.6 Tumors of Lung *329*

3.7 Pleura *355*

3.8 Mediastinum *362*

JAYPEE BROTHERS

4. Head and Neck **373**

4.1 Oral Cavity and Oropharynx *373*
4.2 Nose, Paranasal Sinuses, and Nasopharynx *394*
4.3 Larynx *407*
4.4 Ears *415*
4.5 Neck *421*
4.6 Salivary Glands *424*

5. Gastrointestinal Tract **447**

5.1 Normal Anatomy and Diseases of Esophagus *447*
5.2 Stomach *462*
5.3 Small Intestine and Large Intestine *497*
5.4 Appendix *558*
5.5 Anus and Miscellaneous *562*
5.6 Neuroendocrine Neoplasms in Non-endocrine Organs *577*
5.7 Peritoneal Cavity *592*

6. Liver **597**

6.1 Normal Anatomy, General Features of Liver Disease, Liver Failure and Portal Hypertension *597*
6.2 Infectious Disorders *615*
6.3 Autoimmune Hepatitis and Drug- and Toxin-induced Liver Injury *635*
6.4 Fatty Liver Disease *642*
6.5 Cirrhosis *657*
6.6 Inherited Disease of Liver *659*
6.7 Cholestatic Disease *671*
6.8 Miscellaneous Non-neoplastic Liver Disease *687*
6.9 Tumors and Tumor-like Conditions *695*
6.10 Gallbladder *713*

7. Pancreas **729**

7.1 Normal Anatomy, Congenital Anomalies, and Pancreatitis *729*
7.2 Non-neoplastic Cysts and Exocrine Neoplasms of Pancreas *746*
7.3 Neuroendocrine Neoplasms of Pancreas *766*

8. Kidneys **775**

8.1 Anatomy and Clinical Manifestations of Renal Disease *775*
8.2 Introduction to Glomerular Diseases and Renal Biopsy *784*
8.3 Nephritic Syndrome *799*
8.4 Nephrotic Syndrome *806*

JAYPEE BROTHERS

8.5 Tubular and Interstitial Diseases *833*
8.6 Vascular Diseases of Kidney and Chronic Kidney Injury *858*
8.7 Congenital Anomalies and Cystic Diseases of Kidney *873*
8.8 Urinary Tract Obstruction (Obstructive Uropathy) and Renal Transplant Pathology *882*
8.9 Tumors and Tumor-like Conditions of Kidney *899*

9. Lower Urinary Tract **927**
9.1 Normal Anatomy, Ureters, and Non-neoplastic Lesions of Urinary Bladder *927*
9.2 Urinary Bladder Tumors and Lesions of Urethra *940*

10. Male Genital System **960**
10.1 Penis and Scrotum *960*
10.2 Non-neoplastic Diseases of the Testis *974*
10.3 Testicular Tumors *989*
10.4 Lesions of Testicular Adnexa *1015*
10.5 Prostate *1021*

VOLUME 2

11. Female Genital Tract **1052**
11.1 Embryology, Infections, Vulva, and Vagina *1052*
11.2 Cervix *1068*
11.3 Body of Uterus and Endometrium *1094*
11.4 Mesenchymal Tumors of the Uterus and Lower Genital Tract *1128*
11.5 Fallopian Tubes *1138*
11.6 Ovaries, Cysts, Classification of Tumors and Epithelial Tumors *1147*
11.7 Sex Cord-Stromal Tumors *1176*
11.8 Germ Cell Tumors *1187*
11.9 Diseases of Placenta *1203*

12. Breast **1228**
12.1 Normal Anatomy and Benign Epithelial Lesions of Breast *1228*
12.2 Carcinoma of the Breast *1241*
12.3 Fibroepithelial, Epithelial–Myoepithelial Tumors, and Breast Diseases in Children and Adolescents *1279*
12.4 Mesenchymal and Hematolymphoid Tumors of the Breast *1287*
12.5 The Male Breast *1292*

JAYPEE BROTHERS

13. The Endocrine System **1295**

13.1 Pituitary Gland *1295*
13.2 Non-neoplastic Lesions of Thyroid Gland *1314*
13.3 Tumors of the Thyroid *1335*
13.4 Parathyroid Glands *1365*
13.5 The Endocrine Pancreas *1378*
13.6 Adrenal Glands: Adrenal Cortex *1402*
13.7 Adrenal Medulla and Paraganglia *1425*
13.8 Genetic Tumor Syndromes Associated with Endocrine Lesions and Tumors Paraneoplastic Syndromes *1433*

14. The Skin **1440**

14.1 Normal Anatomy *1440*
14.2 Disorders of Pigmentation and Melanocytes *1457*
14.3 Blistering (Bullous) Diseases *1481*
14.4 Benign Tumors Cysts of Epidermis, and Congenital Diseases *1495*
14.5 Adnexal (Appendage) Tumors *1504*
14.6 Premalignant and Malignant Epidermal Tumors *1521*
14.7 Granulomatous Inflammation *1533*
14.8 Soft Tissue Tumors and Tumors of Hematopoietic and Lymphoid Origin *1541*
14.9 Inflammatory Dermatoses *1551*
14.10 Disorders of Epidermal Appendages, Panniculitis, and Infection *1562*

15. Bone and Joints **1573**

15.1 Bone *1573*
15.2 Developmental Disorders of Bone and Cartilage and Metabolic Diseases of Bone *1584*
15.3 Fractures, Avascular Necrosis, and Osteomyelitis *1600*
15.4 Bone Tumors *1609*
15.5 Joints *1642*

16. Soft Tissue **1669**

16.1 Normal Anatomy and Introduction to Soft Tissue Tumors *1669*
16.2 Tumors of Adipose Tissue *1688*
16.3 Fibroblastic and Myofibroblastic Tumors *1700*
16.4 Tumors of Smooth Muscle and Skeletal *1716*
16.5 Peripheral Nerve Sheath Tumors *1729*
16.6 Tumors of Uncertain Differentiation *1741*
16.7 Undifferentiated Small Round Cell Sarcomas of Bone and Soft Tissue *1749*

JAYPEE BROTHERS

17. Peripheral Nerves and Skeletal Muscles **1754**

17.1 Peripheral Nervous System *1754*
17.2 Diseases of the Neuromuscular Junction *1771*
17.3 Skeletal Muscle *1775*
17.4 Diseases of Skeletal Muscles *1791*

18. Central Nervous System **1820**

18.1 Normal Anatomy and Cellular Pathology of the Central Nervous System *1820*
18.2 Raised Intracranial Pressure, Malformations, Developmental Disorders, and Perinatal Brain Injury *1832*
18.3 Trauma and Cerebrovascular Disease *1842*
18.4 Central Nervous System Infections *1864*
18.5 Demyelinating Diseases *1891*
18.6 Neurodegenerative Diseases *1896*
18.7 Metabolic, Nutritional, and Toxic Diseases *1921*
18.8 Tumors of the Central Nervous System *1932*

19. The Eye **1991**

20. Genetic Tumor Syndromes **2026**

Index **2039**

JAYPEE BROTHERS

CHAPTER 5

Gastrointestinal Tract

5.1 Normal Anatomy and Diseases of Esophagus

CHAPTER OUTLINE

- Normal anatomy
  - Layers of gastrointestinal tract
  - Normal anatomy of the esophagus
- Diseases of esophagus
  - Congenital abnormalities
  - Esophageal obstruction
  - Achalasia
  - Lacerations and perforations
  - Esophageal varices
  - Hiatus hernia
  - Esophagitis
  - Barrett esophagus
- Tumors of the esophagus
  - Squamous cell carcinoma
  - Adenocarcinoma

The digestive system includes the gastrointestinal tract (GIT) and accessory organs of digestion. The accessory organs include the salivary glands, liver, gallbladder, and exocrine pancreas. The GIT (alimentary canal) can be divided into the upper and lower GIT. The upper GIT includes the oral cavity (mouth), esophagus, and stomach. The lower GIT comprises the small intestine, large intestine, rectum, and anus.

NORMAL ANATOMY

Layers of Gastrointestinal Tract

Microscopically, the GIT consists of four layers. From the inside out, these include the (1) mucosa, (2) submucosa, (3) muscularis propria, and (4) serosa or adventitia (esophagus only). Mnemonic "MSMS"—**m**ucosa, **s**ubmucosa, **m**uscularis propria, and **s**erosa.

- **Mucosa:** It has an epithelial lining and an underlying lamina propria. The lamina propria consists of loose connective tissue rich in blood vessels, lymphatics, lymphocytes, and smooth muscle cells and usually contains small glands. A thin layer of smooth muscle called the **muscularis mucosae** separates mucosa from the submucosa. The **mucosa is also called a mucous membrane**.
- **Submucosa:** It contains denser connective tissue with larger blood and lymph vessels and the submucosal (Meissner) plexus of autonomic nerves. There may be glands and significant lymphoid tissue.
- **Muscularis:** It is a thick layer of smooth muscle cells organized as two or more sublayers. In the internal sublayer (closer to the lumen), the muscle fiber is generally oriented circularly and longitudinal in the external sublayer. The connective tissue between the muscle sublayers contains blood and lymph vessels, as well as the myenteric (Auerbach) nerve plexus (described below).
- **Serosa:** It is the outermost layer of the digestive tract. It comprises a thin sheet of loose connective tissue rich in blood vessels, lymphatics, and adipose tissue. It is covered with a simple squamous covering epithelium or mesothelium. The serosa of the small and large intestines is continuous with portions of the mesentery. Mesentery is a large fold of adipose connective tissue, covered on both sides by mesothelium and suspends the intestines and is continuous with the peritoneum. Peritoneum is the serous membrane lining the abdominal cavity. The esophagus lacks a serosa but has a thick adventitia (a layer of connective tissue continuous with surrounding tissue).

JAYPEE BROTHERS

Enteric nervous system: Neurons form the enteric nervous system and are located solely within the GIT. They are controlled by local and autonomic nervous system stimuli. The enteric nervous system consists of three nerve plexuses, and are located in different layers of the gastrointestinal (GI) walls.

- **Submucosal plexus (Meissner plexus):** It is located in the muscularis mucosae.
- **Myenteric plexus (Auerbach plexus):** It is located between the inner circular and outer longitudinal muscle layers in the muscularis.
- **Subserosal plexus**: It is present just beneath the serosa.

Normal Anatomy of the Esophagus

Embryologically, the gut and respiratory tract arise from the foregut. This foregut then divides into two separate tubes, the dorsal esophagus and the ventral trachea. The esophagus is the simplest organ that develops from the foregut's cranial portion. It is recognizable by the third week of gestation. The esophagus is a hollow, highly distensible muscular tubular structure that connects the epiglottis in the pharynx to the gastroesophageal junction (GEJ). It is fixed superiorly at the cricopharyngeal and inferior pharyngeal constrictor muscles. These two together form the upper esophageal sphincter. It begins at the cricopharyngeus muscle and courses inferiorly through the posterior mediastinum, passing behind the trachea, left main bronchus, aorta, and left atrium. It exits the thorax through the diaphragm and terminates at the GEJ (several centimeters beneath the diaphragm). Esophagus lacks significant secretory or absorptive function. It transfers food and liquid into the stomach.

Length: The total length of the esophagus varies with the individual's height. The average length in adults is about 25 cm.

Sphincters: Each end of the esophagus is demarcated by a sphincter. The upper esophageal sphincter is an anatomically distinct structure. It comprises fibers of the cricopharyngeus and inferior pharyngeal constrictor muscles at the level of the sixth cervical vertebra about 15–18 cm from the incisors. The lower esophageal sphincter, on the other hand, lacks a single anatomic counterpart. It is formed from the distal esophagus's intrinsic muscles, the proximal stomach's sling fibers, and the crural diaphragm. It is usually 40 cm from the incisors but is subject to considerable individual variations. Tonic muscular contraction at its lower end creates the lower esophageal sphincter. This is a functional sphincter rather than a true anatomic one.

Microscopy

Like the rest of the GIT, the esophagus wall consists of four microscopic layers: Mucosa (with muscularis mucosae), submucosa, muscularis propria, and serosa or adventitia.

Mucosa: The mucosa is **lined by a nonkeratinizing, stratified squamous epithelium**. The epithelium is formed by two basic zones. The basal layer (zone) of esophageal mucosa is one to four cells thick and consists of a proliferative layer of basophilic cells with little cytoplasm. Normally, this zone does not exceed 15% of the total epithelial thickness except in the most distal esophagus. Overlying the basal zone is a superficial layer of maturing glycogen-rich squamous cells. These cells progressively flatten as they mature and approach the lumen. Melanocytes, endocrine cells, T lymphocytes (may have irregularly shaped nuclei and be mistaken for neutrophils), and Langerhans cells are scattered within the epithelium. Melanocytes and neuroendocrine cells may be seen in this layer. The underlying supporting lamina propria consists of fibrovascular tissue folded into slender papillae that project into the epithelium. These papillae usually extend to less than two-thirds of the epithelial thickness, except in the distal 2–3 cm of the esophagus, where there may be mild elongation. The lamina propria contains loose connective tissue, capillaries, lymphatic vessels, elastic fibers, scattered mononuclear cells, and lymphoid aggregates. These lymphoid aggregates should not be interpreted as evidence of esophagitis. It is composed of a longitudinally oriented band of muscularis mucosae. The lamina propria of the distal portion of the esophagus contains mucous glands, referred to as (esophageal) cardiac glands. These cardiac glands produce neutral mucins, resemble the mucous glands of the stomach, and may contain a few parietal or chief cells. A transition to gastric mucosa at the GEJ occurs abruptly at the level of the diaphragm. The esophageal muscularis mucosae are thicker than the other portions of the GIT, especially in the distal portion of the esophagus.

Submucosa: The esophageal submucosa consists of a wide layer of loose connective tissue with blood vessels, rich lymphatics, nerve fibers, scattered lymphocytes, and lymphoid aggregates. It also contains tubuloalveolar mucous glands distributed throughout the esophagus. These submucosal glands secrete acidic mucins and are similar to the minor salivary glands of the oropharynx. These glands drain through cuboidal or squamous-lined ducts that obliquely penetrate the mucosa. Sometimes, these may be cystically dilated and surrounded by lymphoid collections.

Muscularis propria: It consists of a mixture of striated and smooth muscle in the upper quarter. The muscularis propria consists of a screw-like arrangement of both smooth and striated muscle fibers fashioned into inner circular and outer longitudinal layers.

Serosa or adventitia: A serosal lining covers short segments of the thoracic and abdominal esophagus. But most of the esophagus is instead ensheathed by an adventitia of loose connective tissue.

Gastroesophageal Junction

The GEJ is the **point at which the tubular esophagus joins the first fold of the saccular stomach**. It is recognized endoscopically by the proximal margin of the gastric folds. The junction between squamous and columnar mucosa represents the squamocolumnar junction (SCJ) or Z-line. GEJ does not necessarily correspond to the SCJ or "Z line," which is the irregular meeting point of the squamous and glandular epithelia. In many individuals, the SCJ may be found proximally displaced above the GEJ.

JAYPEE BROTHERS

Lymphatic Drainage

The esophagus **has rich lymphatic vessels**. They form freely anastomosing networks within the submucosa and with connecting longitudinal channels in the muscularis propria. Thus, the lymphatic flow runs longitudinally, coursing the cephalad in the upper two-thirds and the caudad in the lower third of the esophagus. This arrangement facilitates lengthwise intramural tumor dissemination. Lymphatics of the upper third of the esophagus (cervical esophagus) drain primarily to cervical lymph nodes (internal jugular and paratracheal nodes), those of the middle third (thoracic esophagus) to paraesophageal and paratracheal mediastinal and bronchial nodes and those of the lower third (abdominal esophagus) to subdiaphragmatic nodes (nodes around the aorta and celiac axis and gastric lymph nodes). These features are important in the spread of esophageal cancer. However, because of the rich lymphatic interconnections, esophageal carcinomas can show a wide and unpredictable distribution of nodal metastases. Unlike the colon, these lymphatic channels traverse the esophageal wall into the mucosa. Thus, there is a small but definite risk of lymph node metastasis even with intramucosal carcinoma.

Blood Supply

The arterial blood supply to the esophagus is from several primary sources. The cervical esophagus is supplied mainly by the inferior thyroid artery, the upper thoracic esophagus by the bronchial and intercostal arteries, the lower thoracic esophagus by branches directly from the aorta, and the abdominal esophagus by left gastric and inferior phrenic arteries. It shows numerous anastomoses of the various arterial supplies. Venous drainage of the esophagus is important. The venous drainage forms an extensive submucosal plexus. Venous plexuses communicate with longitudinally oriented periesophageal veins. They eventually flow into the inferior thyroid, azygos, and gastric veins. Thus, the caval and portal venous systems are connected, and if there is portal hypertension, it can result in the development of esophageal varices. Esophageal varices occur invariably in the lower third of the esophagus. This is because only the veins of the lower third drain into the portal vein via the gastric veins. The veins of the upper third of the esophagus drain into the superior vena cava, and those of the middle third drain into the azygous system.

Nervous plexuses: The autonomic nervous plexuses consist of the Meissner plexus in the submucosa (very sparse) and the Auerbach (myenteric) plexus between the two layers of muscularis propria.

DISEASES OF ESOPHAGUS

Congenital Abnormalities

Atresia, Fistulae, and Duplications

In a 3-week-old embryo, the esophagus is an annular constriction between the pharynx and stomach. Esophagus becomes tubular with the growth of the lung beds and elongation of the neck. At first, the cephalad portions of the esophagus and trachea form a single channel. Later, a septum grows in and separates the esophagus from the trachea.

Congenital esophageal atresia

In esophageal atresia, a segment of the esophagus does not develop or its development is incomplete **(Fig. 1)**. It results from the failure of the primitive foregut to recanalize. It leaves only a thin, noncanalized cord and causes mechanical obstruction. The **most common esophageal congenital anomaly is esophageal atresia** alone or, more often, **without tracheoesophageal fistula**. Its frequency is increased in preterm babies of the male gender. Atresia occurs most commonly at or near the tracheal bifurcation. Esophageal atresia without a fistula appears in about 8% of cases. Esophageal atresia is usually associated with a fistula connecting the upper or lower esophageal segments to a bronchus or the trachea. Half of the patients with developmental abnormalities of the esophagus are associated with a range of other congenital abnormalities. About 25% have other GI malformations. These include VACTERL syndrome (**v**ertebral defects, **a**nal atresia, **c**ardiac defects, **t**racheo**e**sophageal fistula, **r**enal dysplasia, and **l**imb abnormalities), TACRD (tracheal agenesis/atresia, complex congenital cardiac abnormalities, radial ray defects, and duodenal atresia), and other abnormalities involving the heart, lung, great vessels, genitourinary tract, and anus. The anus is imperforate due to a failure of the cloacal diaphragm to involute.

Tracheoesophageal fistula

In the tracheoesophageal fistula, the fistulous tract connects the upper or lower esophageal segments to a bronchus or the trachea. Various types of tracheoesophageal fistula are shown in **Figures 2A to D**. These can lead to aspiration, suffocation, pneumonia, and severe fluid and electrolyte imbalances. The most common type (86.5%) is esophageal atresia, with a fistula between the lower portion of the esophagus and the respiratory tree **(Fig. 2A)**. In this type, the upper portion of the esophagus is hypertrophied and

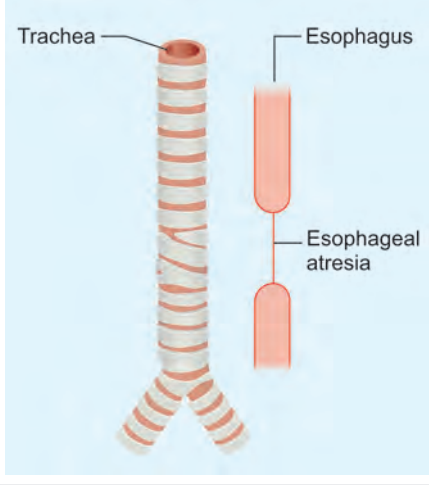

FIG. 1: Esophageal atresia. Blind upper and lower esophagus segments connected by a thin cord of connective tissue.

JAYPEE BROTHERS

dilated. It ends blindly at a variable distance below the larynx. The lower portion of the esophagus communicates with the trachea (usually about 0.5 cm above the bifurcation) or the right mainstem bronchus. In this type, the upper blind sac gets filled with mucus, and the infant then aspirates. Surgical correction is possible but difficult. In an H-type fistula **(Fig. 2B)**, there is communication between an intact esophagus and an intact trachea. Another type of tracheoesophageal fistula is a communication between the proximal esophagus and the trachea; the lower esophageal pouch communicates with the stomach **(Fig. 2C)**. The least type is tracheal fistulas between patent esophagus and trachea. In this type, the tracheal fistula communicates to both proximal esophageal pouch and distal esophagus **(Fig. 2D)**.

The etiology of esophageal atresias and fistulas is unknown. Genetic and environmental factors may be involved. Prenatal diagnosis of these anomalies is suggested by polyhydramnios, prominent esophageal pouch, and small or absent stomach bubble with fluid-filled loops of bowel on ultrasonography. Polyhydramnios occurs because amniotic fluid cannot reach the stomach.

Esophageal Stenosis

Stenosis is an incomplete form of atresia. In atresia, the lumen is markedly reduced in caliber due to the fibrous thickening of the wall. Esophageal stenosis is usually acquired but can be congenital. Acquired causes include inflammatory scarrings, such as chronic gastroesophageal (GE) reflux, irradiation, systemic sclerosis, or caustic injury. Stenosis usually occurs in the distal esophagus and reflects abnormal wall architecture. Stenosis causes either partial or complete obstruction.

Esophageal Obstruction

The main function of the esophagus is to deliver ingested solid food and fluids from the mouth to the stomach. This function can be impaired due to physical or functional obstruction. Functional obstruction may result from disruption of coordinated peristalsis after swallowing.

Functional Obstruction

Patterns of esophageal dysmotility: They belong to three main patterns.

1. **Nutcracker esophagus:** It is functional obstruction of the esophagus. It is produced due to severe, high amplitude, uncoordinated contractions of the inner circular and outer longitudinal smooth muscle of the esophagus. A barium swallow can be either normal or have a nutcracker-like (a nutcracker is a tool for breaking the shell of a nut) appearance, with narrow and distended regions. However, it requires manometry for diagnosis.
2. **Diffuse esophageal spasm:** It is also called a corkscrew esophagus because of its appearance on barium swallow. It is characterized by repetitive, simultaneous contractions of the distal esophageal smooth muscle. In contrast to the nutcracker esophagus, the contractions in this condition are of normal amplitude.
3. **Lower esophageal sphincter dysfunction:** This includes high resting pressure or incomplete relaxation. It may occur as an isolated anomaly or associated with a nutcracker esophagus or diffuse esophageal spasm.

Mechanical Obstruction

- **Strictures or cancer:** They can produce mechanical obstruction. They usually present with progressive dysphagia that begins with the inability to swallow solids.
- **Benign esophageal stenosis:** It is usually caused by fibrous thickening of the submucosa. It is associated with atrophy of the muscularis propria and secondary epithelial damage. Stenosis may be congenital (rare) or acquired. Most commonly, stenosis is acquired due to inflammation and scarring caused by chronic GE reflux, irradiation, or caustic injury.

Generally, functional obstruction or benign strictures are associated with retention of appetite and weight. In

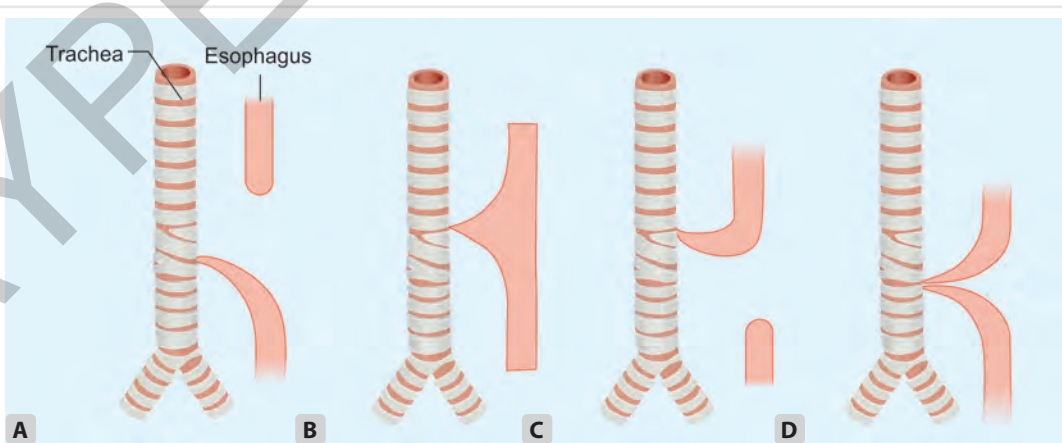

FIGS. 2A TO D: Various types of tracheoesophageal fistula. (A) The blind upper segment of esophagus with a fistula between the lower segment and trachea. (B) H-type fistula without esophageal atresia. In this type, the fistula is between the patent intact esophagus and intact trachea. (C) Fistula between proximal/upper segment of esophagus and trachea. The lower segment of the esophagus is blind. (D) Tracheal fistulas to both a proximal esophageal pouch and distal esophagus.

JAYPEE BROTHERS

contrast, malignant strictures are often associated with loss of weight. In patients with complaints of dysphagia, radiologists often find esophageal shadows with a configuration resembling rings and webs.

- **Esophageal mucosal webs:** These are uncommonly produced due to narrow horizontal thin mucosal membrane protrusions from an esophageal wall that projects into the esophageal lumen. They usually occur in women older than age of 40 years and present with difficulty in swallowing (dysphagia). Webs are typically single and thin (2 mm) and can occur anywhere in the esophagus. It may be associated with GE reflux, chronic graft-versus-host disease, or blistering skin diseases.
  - **Plummer–Vinson Syndrome:** Webs in the upper esophagus may occur as part of Plummer–Vinson or **Paterson–Kelly syndrome**. This syndrome is an exceedingly rare disorder **characterized by a cervical esophageal web associated with iron-deficiency anemia, mucosal lesions of the mouth** (glossitis and cheilosis), **and pharynx**. Morphologically, esophageal webs appear as semicircumferential lesions composed of a fibrovascular connective tissue core lined by normal mucosa and submucosa. There is **an increased incidence of carcinoma of the oropharynx and upper esophagus**.

    Esophageal webs cause a partial obstruction, primarily of incompletely chewed food, and nonprogressive dysphagia is often associated with aspiration of swallowed food.
- **Esophageal rings or *Schatzki rings*:** These are similar to esophageal webs but are **circumferential and thicker**. These rings include mucosa, submucosa, and occasionally hypertrophic muscularis propria. Schatzki rings are **usually asymptomatic** but may be associated with intermittent dysphagia.
  - **A rings (lower esophageal rings):** When rings are present **in the distal/lower esophagus, above the GEJ**, they are called A rings. These rings are covered by stratified squamous epithelium.
  - **B rings (esophagogastric rings):** When **rings are located at the SCJ of the lower esophagus,** they are called B rings. These rings may have gastric cardia-type mucosa on their undersurface.

Diverticula

A **true diverticulum** is defined as an **outpouching of the wall and contains all layers of the wall**. If a sac has **no muscular layer, it is a false diverticulum** (or pseudodiverticulum).

Zenker (pharyngoesophageal) diverticulum: Impaired relaxation and spasm of the cricopharyngeus muscle after swallowing can increase pressure within the distal pharynx. This may lead to the development of a Zenker (pharyngoesophageal) diverticulum. Zenker diverticula are uncommon but are the most common type of diverticulum in the upper aerodigestive tract. They usually develop after age of 50 years. They are **located immediately above the upper esophageal sphincter** (upper portion of the esophagus) **at the junction with the pharynx**. Therefore, they are designated as pharyngoesophageal and are classified pathogenetically as **pulsion diverticula**. They may reach several centimeters in size. Small Zenker diverticula may be asymptomatic, but larger ones may accumulate significant amounts of food. This may produce a mass, regurgitation, and halitosis.

Traction diverticula: They occur in the lower third of the esophagus and in the region of the hilum of the lung. At this site, inflammatory lymph nodes (usually tuberculous) can become firmly attached to the esophagus and produce traction diverticula.

Esophageal diverticula: In esophageal dysmotility, there is an **increase in wall stress**. This may lead to the development of small diverticula. The diverticula occur particularly in the epiphrenic region immediately above the lower esophageal sphincter.

Achalasia

Achalasia **(cardiospasm, megaesophagus)** is **due to a failure to relax the lower esophageal sphincter with swallowing and poor peristalsis in the body of the esophagus**. Triads of achalasia are (1) incomplete relaxation of the lower esophageal sphincter, (2) increased lower esophageal sphincter tone, and (3) aperistalsis of the esophagus. The defects in both the outflow tract and esophageal pumping mechanisms lead to food retention in the esophagus, and the esophagus hypertrophies and dilates. It is usually seen in adults but can also occur in children. It clinically presents with dysphagia (to both solids and liquids), difficulty in belching, odynophagia (pain on swallowing, painful swallowing), regurgitation of material retained in the esophagus, and chest pain. In long-standing cases, there is an increased risk for squamous cell carcinoma (SCC) of the esophagus. Achalasia may be primary or secondary.

Primary achalasia: It is rare and is due to the degeneration of nitric oxide-producing neurons that normally induce lower esophageal sphincter relaxation. Achalasia may be an inflammatory disease that causes loss of inhibitory neurons in the esophageal myenteric plexus. Chronic inflammation (mainly T cells) in the myenteric plexus leads to neuritis and ganglionitis. Eventually, there is a loss of ganglion cells and fibrosis. The cause of the inflammation is unknown, but genetic, viral, and autoimmune factors have been suggested. There may also be degenerative changes in the extraesophageal vagus nerve or the dorsal motor nucleus of the vagus.

Secondary achalasia: Various causes are as follows:

- **Chagas disease:** Secondary achalasia may occur in Chagas disease caused due to protozoan *Trypanosoma cruzi* infection. It causes the destruction of ganglion cells in the myenteric plexus, failure of peristalsis, and dilation of the esophagus. Chagas disease can also affect duodenal, colonic, and ureteric myenteric plexuses.
- **Syndromes:** Dysfunction of the lower esophageal sphincter can also **occur in Down syndrome or as part of Allgrove (triple-A) syndrome**. Allgrove syndrome is an autosomal recessive disorder characterized by **a**chalasia, **a**lacrima (abnormality in tear production), and **a**drenocorticotropic hormone-resistant adrenal insufficiency.

JAYPEE BROTHERS

- **Cricopharyngeal dysphagia (cricopharyngeal achalasia, cricopharyngeal spasm):** It has prominent clinical symptoms but only limited microscopic findings. Microscopically, it shows degeneration and regeneration of the fibers of the cricopharyngeal muscle, accompanied by interstitial fibrosis.
- **Other secondary causes:**
  - **Other disorders:** Achalasia-like disease may be due to diabetic autonomic neuropathy, infiltrative disorders (e.g., infiltrative malignancies, amyloidosis, sarcoidosis), systemic sclerosis, or lesions of dorsal motor nuclei (e.g., following polio).
  - **Immune-mediated destruction:** Some achalasia may also be due to immune-mediated destruction of inhibitory esophageal neurons. It may occur with remote herpes simplex virus 1 (HSV1) infection, linkage of immunoregulatory gene polymorphisms to achalasia, and occasional coexistence of Sjögren syndrome or autoimmune thyroid disease.

Diagnosis: Radiography may show a **"bird-beak" GEJ**. Manometry is the standard diagnostic test for confirming achalasia.

The aim of treatment in both primary and secondary achalasia is to overcome the obstruction. The methods include laparoscopic/endoscopic myotomys, endoscopic pneumatic balloon dilation, and botulinum neurotoxin (Botox) injection of the lower esophageal sphincter to inhibit contraction-promoting cholinergic neurons. After treatment, patients may develop GE reflux.

Lacerations and Perforations

Lacerations of the esophagus may result from external trauma (e.g., automobile accidents or medical instrumentation) or from severe vomiting (during which intraesophageal pressure may reach 300 mm Hg). Forceful retching may produce tears in the mucosa, first in the gastric epithelium, and then may extend into the esophagus.

Mallory–Weiss Syndrome

Q. Write a short essay on Mallory–Weiss syndrome.

Q. Write a short essay on esophageal causes of hematemesis.

Longitudinal mucosal tears near the GEJ (upper stomach and lower esophagus) **are called Mallory–Weiss tears.** It is **commonly associated with severe retching or vomiting secondary to acute alcohol intoxication**. Vomiting produces an **antiperistaltic contractile wave**. Usually, a reflex relaxation of the GE musculature precedes vomiting. During prolonged vomiting, this relaxation fails and produces the refluxing of gastric contents and causes stretching and tear in the esophageal wall. The tears in the lower esophagus usually cross the GEJ and may also be located in the proximal gastric mucosa. The linear lacerations of Mallory–Weiss syndrome are generally **longitudinally oriented**, and they may be millimeters to several centimeters in length. These tears lead to the vomiting of bright red blood. Bleeding may be severe and require a transfusion of many units of blood. Up to 10% of upper GI bleeding (often manifests as hematemesis) is due to superficial esophageal lacerations of Mallory–Weiss syndrome. These tears usually do not require surgical intervention, and healing is generally rapid and complete. Rarely, it may result in transmural tearing, perforation, and rupture of the distal esophagus into the mediastinum. This is a serious condition (catastrophic event) called as Boerhaave syndrome. It produces severe mediastinitis and usually requires surgical intervention. These patients can present with severe chest pain, tachypnea, and shock. Hence, the initial differential diagnosis can include myocardial infarction.

Esophageal Varices

Esophageal varices are **dilated veins within the lower esophagus beneath the mucosa**. Most small varices never bleed, but large varices are prone to rupture and hemorrhage. They occur in the lower third of the esophagus.

Pathogenesis

Esophageal varices almost always **occur in patients with cirrhosis of the liver and portal hypertension**. Portal hypertension is due to impaired blood flow through the portal venous system and liver. Increased portal venous pressure leads to the development of collateral channels at sites where there is communication between the portal and caval systems. In the esophagus, collateral channels develop as GE anastomoses between the lower esophageal veins and the portal system. These collateral veins allow some drainage of portal blood. When the portal pressure exceeds a critical level, it results in congestion and dilation of subepithelial and submucosal venous plexuses within the lower (distal) esophagus and upper (proximal stomach). These dilated vessels are termed varices. They are common in patients with cirrhosis of the liver, most frequently due to alcoholic liver disease.

MORPHOLOGY

Esophageal varices are characterized by **tortuous dilated veins within the mucosa and submucosa of the distal esophagus and proximal stomach**. Esophageal varices may rupture in about one-third of patients and produce life-threatening hemorrhage into the lumen or the esophageal wall. These ruptures may be associated with mucosal ulceration and necrosis. If varices have ruptured in the past, they may show venous thrombosis, inflammation, and evidence of prior sclerotherapy.

Clinical Features

Gastroesophageal varices occur in 30% of patients with compensated cirrhosis and in 60% with decompensated cirrhosis. Variceal hemorrhage is an emergency. It can be treated medically by inducing splanchnic vasoconstriction or endoscopically by sclerotherapy (injecting thrombotic agents), balloon tamponade, or variceal ligation. However, each episode of variceal hemorrhage is associated with a 15–20% risk of mortality. About 50% of patients who survive first variceal bleeding are likely to develop recurrent hemorrhage within 1 year. Factors predisposing to hemorrhage include large or tortuous varices, elevated hepatic venous pressure

JAYPEE BROTHERS

gradient, previous bleeding, and advanced liver disease. Various esophageal causes of hematemesis are presented in **Box 1**.

Hiatus Hernia

Hiatus (hiatal) hernia is a **protrusion of the stomach into the chest through an enlarged diaphragmatic opening**.

Types

There are **two main types** of hiatus hernia **(Figs. 3A and B)**.

Sliding hernia: It is characterized by **upward movement and herniation of the GEJ above the diaphragm into the thorax**. This occurs due to enlargement of the diaphragmatic hiatus and laxity of the circumferential connective tissue. This is a common condition and **constitutes about 85% of hiatal hernias**. It is usually asymptomatic. The most commonly associated symptom is GE reflux. It is not known whether this type of hiatus hernia is the cause or result of reflux.

Box 1: Various esophageal causes of hematemesis.

- Esophageal varices (cirrhosis)
- Lacerations (Mallory–Weiss syndrome): Caused tears in the esophageal mucosa produced by prolonged and vigorous retching
- Esophageal perforation (cancer or Boerhaave syndrome)
- Esophageal-aortic fistula (usually with cancer)
- Esophagitis
  - Chemical and pill esophagitis
  - Infectious esophagitis (*Candida*, herpes simplex, cytomegalovirus)
  - Reflux esophagitis (erosive)
  - Eosinophilic esophagitis
- Benign strictures
- Vasculitis (autoimmune, cytomegalovirus)
- Esophageal ulcers (many etiologies)
- Barrett esophagus
- Hiatal hernia
- Radiation
- Iatrogenic: For example, following endoscopy
- Malignant tumors
  - Adenocarcinoma
  - Squamous cell carcinoma

Paraesophageal (rolling) hernia: This is an uncommon type of hiatal hernia. In this type, a portion of the **gastric fundus herniates through a defect in the diaphragmatic connective tissue** (phrenoesophageal membrane), **and it lies beside the esophagus**. This type of hernia progressively enlarges and causes a widening of the hiatus. This can compress the esophagus and lead to a decrease in the reflux of gastric contents. In severe cases, the entire stomach and other abdominal organs can herniate and lie in the thorax. This type is most common in older people.

A mixed or transitional hernia may also be observed, which is a combination of sliding and rolling hiatus hernia.

Clinical Features

Sliding hiatus hernia: It usually presents with heartburn and regurgitation. This is due to the reflux of gastric contents into the esophagus because of the incompetence of the lower esophageal sphincter. Generally, the symptoms are worse when the individual recline, as this position facilitates acid reflux. Sliding hiatal hernias usually do not require surgery, and symptoms are treated medically.

Paraesophageal hernias: It may present with dysphagia, fullness after meals, shortness of breath, painful swallowing, and occasionally bleeding peptic ulcers. As the stomach rolls up into the chest, it may undergo rotation. Large hernias may carry a risk of gastric volvulus or intrathoracic gastric dilation. An enlarging paraesophageal hernia should be surgically corrected, even if it is asymptomatic.

Esophagitis

Esophagitis is inflammation of the esophagus. A variety of irritants may damage the stratified squamous mucosa of the esophagus. Diverse etiologic agents, such as physical, chemical, and biological agents, may cause esophagitis. The most common cause is GE reflux, followed by infectious organisms. Other causes include alcohol, corrosive acids or alkalis, excessively hot (boiling) fluids, and heavy smoking. Symptoms of esophagitis range from self-limited pain (particularly on swallowing—odynophagia) to hemorrhage, stricture, or perforation in severe cases.

Chemical Esophagitis

Ingestion of corrosive agents produces chemical injury to the esophagus and causes chemical esophagitis. In children, chemical injury to the esophagus is usually secondary to accidental ingestion (poisoning) of household cleaning

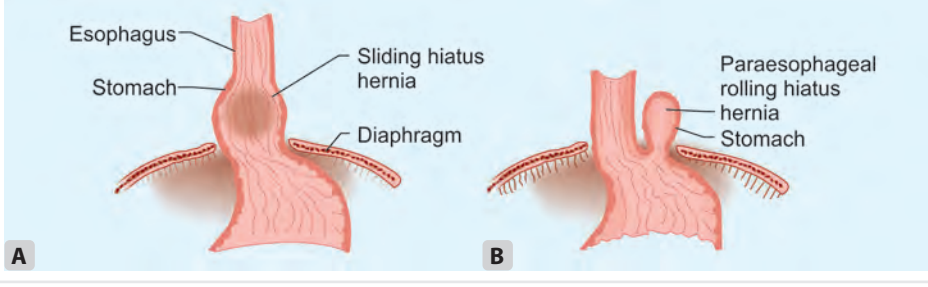

FIGS. 3A AND B: Diagrammatic representation of two types of hiatus hernia: (A) Sliding and (B) paraesophageal (rolling) hiatus hernia.

JAYPEE BROTHERS

products. These include various cleaning solutions, such as strong alkaline agents (e.g., lye) or strong acids (e.g., sulfuric or hydrochloric acid). In adults, it is due to attempted suicide or contact with medication ("pill esophagitis"). Less severe chemical injury to the esophageal mucosa can occur when medicinal pills lodge and dissolve in the esophagus. This is called pill-induced esophagitis.

Iatrogenic injury to the esophagus may be caused by cytotoxic chemotherapy, instrumentation, intubation, radiation therapy, or graft-versus-host disease. Esophagitis may also develop in desquamative skin diseases (e.g., bullous pemphigoid), epidermolysis bullosa, and, rarely, Crohn disease.

MORPHOLOGY

Dense neutrophil infiltration is usually present but may be absent following injury induced by chemicals (lye, acids, or detergent) that cause necrosis of the esophageal wall. The morphology of chemical esophagitis varies with etiology.

- **Alkaline agents:** They produce liquefactive necrosis with conspicuous inflammation and saponification of membrane lipids of all layers of the esophagus and stomach. Small vessel thrombosis may develop and may produce ischemic necrosis. Liquid alkali usually produces severe damage, but only <25% who ingest granular preparations have severe complications.
- **Strong acids:** They produce immediate coagulative necrosis. The protective eschars formed limit injury and penetration. About 50% of patients who ingest concentrated hydrochloric or sulfuric acid develop severe injury to the esophagus.
- **Pill-induced esophagitis:** It is usually caused by direct chemical effects on the squamous-lined mucosa of the esophagus, especially with capsules. It usually occurs at the site of strictures that prevent the passage of luminal contents. Dysmotility of the esophagus and cardiac enlargement (which impinges on the esophagus) may be contributing factors. A wide range of drugs may cause esophagitis. Most common agents include doxycycline and other antibiotics, aspirin and nonsteroidal anti-inflammatory drugs (NSAIDs), slow-release potassium preparations, ferrous salts, and alendronate.
- **Radiation:** Esophageal irradiation produces damage similar to that observed in other tissues. It causes intimal proliferation and luminal narrowing of submucosal and mural blood vessels. The mucosal damage is partly secondary to radiation-induced vascular injury.
- **Graft-versus-host disease:** Microscopic findings of esophageal are similar to those in the skin. These include apoptosis of basal epithelial cells, mucosal atrophy, and submucosal fibrosis without significant acute inflammatory infiltrates.
- **Others:** The microscopic features of esophageal involvement in bullous pemphigoid, epidermolysis bullosa, and Crohn disease are also similar to those in the skin.

Infectious Esophagitis

Esophageal infections in otherwise healthy individuals are **usually caused due to HSV**. Infectious esophagitis is more common in debilitated or immunosuppressed patients. It may be caused by HSV, cytomegalovirus (CMV), or fungus. Among fungi, candidiasis is the most common, and others include mucormycosis and aspergillosis. Infection by bacteria or fungi can either cause injury or complicate a preexisting ulcer. Nonpathogenic oral bacteria are frequently found in ulcer beds. Pathogenic bacteria and fungi are responsible for about 10% of infectious esophagitis, and they may invade and cause mucosal necrosis.

***Candida* esophagitis:** It can complicate the ulcers of herpes or CMV esophagitis or develop in the absence of viral infection. In the absence of viral infection, this fungal infection is common in immunocompromised patients. This may occur due to chemotherapy for malignant disease, immunosuppression after organ transplantation, or acquired immunodeficiency syndrome (AIDS). Esophageal candidiasis also occurs in patients with diabetes, patients on antibiotic therapy or acid-suppressive therapy, or individuals using inhaled or swallowed corticosteroids. It is uncommon in the absence of known predisposing factors. Usual symptoms include dysphagia and severe pain on swallowing.

MORPHOLOGY

Candida may involve only the superficial epithelium. Mild cases show a few small, elevated white mucosal plaques surrounded by a hyperemic zone in the middle or lower third of the esophagus. In severe cases, it produces confluent adherent, gray–white **pseudomembrane (plaque)** covering the hyperemic and edematous esophageal mucosa. **Candidal pseudomembrane is composed of densely matted fungal hyphae, necrotic debris, fibrin, and inflammatory cells**. This can be easily scraped away. Pseudohyphae can be seen in the background of active esophagitis. Sometimes, special stains [periodic acid–Schiff (PAS), silver stain] may be helpful in their identification. Invasion deeper into the esophageal wall by candida can lead to disseminated candidiasis or fibrosis. Sometimes, fibrosis may be severe enough to create a stricture.

Herpes simplex esophagitis: Infection with herpesvirus type I can occur in both immunosuppressed and immunocompetent healthy individuals. Most commonly, it follows solid organ or bone marrow transplantation. It may be asymptomatic or result in odynophagia, retrosternal chest pain, and fever. The endoscopic appearance frequently indicates the cause of viral esophagitis. At **endoscopy**, the diagnosis of herpes esophagitis should be suspected in the presence of **"volcano ulcers"**. A double-contrast esophagogram shows discrete, diffusely scattered, punched-out ulcers.

JAYPEE BROTHERS

MORPHOLOGY

Gross: Well-developed lesions of herpetic esophagitis resemble those of candidiasis. Early stages cases show vesicles, small erosions, or plaques. As it progresses, these coalesce and form larger lesions.

Microscopy (Figs. 4A and B): It shows inflammation, ulcerations, and **epithelial cells show typical nuclear herpetic (Cowdry type A) inclusions** (hallmarks of the disease) and **occasional multinucleated epithelial cells**. Cowdry type A inclusion consists of acidophilic material of droplet-like masses surrounded by clear halos within nuclei. An important diagnostic clue is the presence of aggregates of large mononuclear cells with convoluted nuclei (CD68+) adjacent to the inflamed epithelium. Necrosis of infected cells leads to ulceration. Candidal or bacterial superinfection may cause pseudomembrane.

Cytomegalovirus esophagitis: Involvement of the esophagus or other segments of the GIT, with CMV, is usually due to systemic viral disease in severely immunosuppressed patients (e.g., those with AIDS, transplant recipients, etc.). Shallow mucosal ulceration (in herpesviruses, punched-out ulcers) is common, and endoscopic appearance is similar to that of herpes esophagitis.

MORPHOLOGY

Microscopy: The diagnosis is made by finding the typical **large cells with basophilic cytoplasm and large oval, eosinophilic CMV intranuclear inclusion bodies**. They are **usually seen in capillary endothelial cells and granulation tissue fibroblasts** (stromal cells) at the base of the ulcer. Though the microscopic appearance is characteristic, immunohistochemical stains for virus-specific antigens are sensitive and specific ancillary diagnostic tools.

Reflux Esophagitis

Q. Write a short essay on gastroesophageal reflux disease (GERD).

Reflux esophagitis is caused by the **reflux of gastric contents into the lower esophagus. It is the most frequent cause of esophagitis.**

Etiopathogenesis

The lower esophageal sphincter prevents the reflux of gastric contents into the esophagus. Episodic reflux is normal, particularly after a meal. **Reflux esophagitis develops when episodes of reflux are frequent and prolonged.**

Reflux esophagitis is associated with a clinical condition called GERD. Esophagitis in GERD occurs because the esophageal epithelium is sensitive to acid despite being resistant to abrasive injury. **Transient relaxation of the lower esophageal sphincter is a major cause of GERD.** The sphincter relaxation is mediated via vagal pathways and may be triggered by gastric distention. GE reflux can also occur following sudden increases in intra-abdominal pressure, such as after coughing, straining, or bending. Decrease of lower esophageal sphincter pressure associated with GERD can occur with agents such as alcohol, chocolate, fatty foods, cigarette smoking, abdominal obesity, central nervous system depressants (e.g., morphine, diazepam), pregnancy, estrogen therapy, hiatus hernia (refer to page 453), delayed gastric emptying, presence of a nasogastric tube, and increased gastric volume. Alcohol, hot beverages, and spicy foods may also directly injure the mucosa. Gastric acid damages the esophageal mucosa, but the combination of acid and pepsin is more injurious. Also, the gastric fluid contains refluxed bile from the duodenum, which may add to the injury of the esophageal mucosa. The alkaline secretions of submucosal glands in the esophagus partially protect the esophageal mucosa.

MORPHOLOGY

Gross: The first grossly evident effect of GE reflux is simple hyperemia, which may be the only alteration in mild GERD. It appears as redness of the affected area on the endoscopic examination. The affected region of the esophagus is susceptible to superficial mucosal erosions and ulcers, and they usually appear as vertical linear streaks.

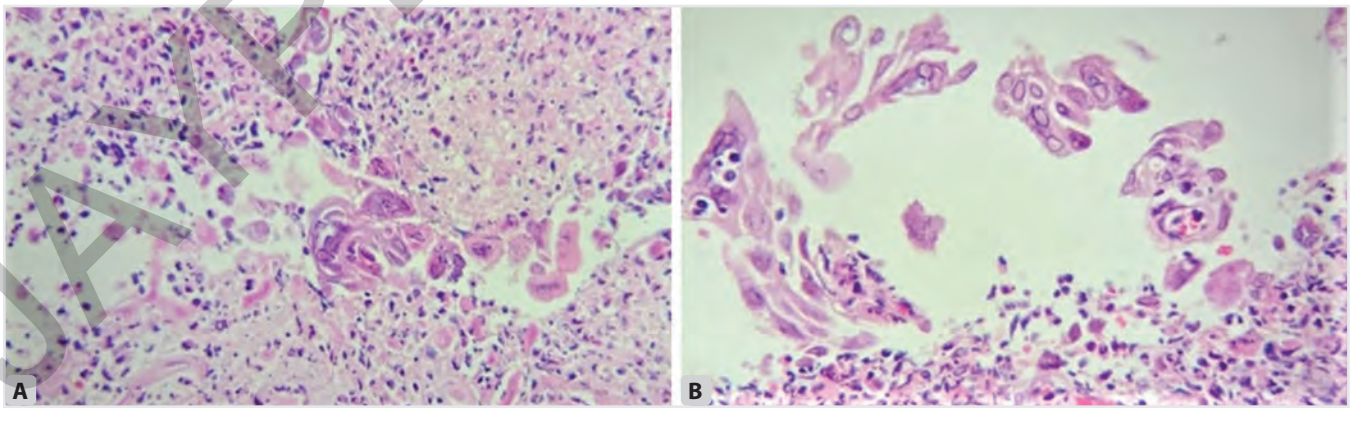

FIGS. 4A AND B: Herpes esophagitis showing infected epithelial cells with glassy nuclear changes. There is dense acute inflammatory infiltrate.

JAYPEE BROTHERS

Microscopy: Mucosal changes histology is generally unremarkable. A mild injury to the squamous epithelium causes swelling of cells (hydropic change). More significant gastric reflux may cause erosions and infiltration of eosinophils into the squamous mucosa. With the continued injury, the basal zone undergoes hyperplasia (increased thickness of basal epithelium) along with elongation of lamina propria papillae (and may approach the surface) are observed. Capillaries in the papillae are often dilated. Neutrophil infiltration is less frequent and is generally associated with bacterial or fungal infection or chemical damage. In severe cases, the mucosa may undergo ulceration. If the ulcer persists, it may lead to esophageal stricture, and reactive fibrosis can narrow the lumen of the esophagus.

Clinical features

Gastroesophageal reflux disease can occur at any age but is more common in individuals older than 40 years. It can be nonerosive, erosive, or involved by the Barrett esophagus. It presents with heartburn, dysphagia, and regurgitation of sour-tasting gastric contents, most often postprandially. Rarely, GERD may be associated with chest pain and may be mistaken for ischemic heart disease. Treatment with proton pump inhibitors to reduce gastric acidity generally provides symptomatic relief. Endoscopy is not required for the diagnosis but may be necessary for patients who are refractory to proton pump inhibitors. An endoscopic biopsy can be helpful in the detection of eosinophilic esophagitis as well as Barrett esophagus, strictures, ulcerations, and other GERD complications. The severity of symptoms is not closely related to the degree of microscopic damage, and significant microscopic abnormalities may be found in individuals without typical symptoms of GERD. A hiatal hernia may be associated with the incompetence of the lower esophageal sphincter and symptoms similar to GERD, but it is symptomatic in only <10% of cases.

Eosinophilic Esophagitis

Eosinophilic (allergic) esophagitis is an acute esophageal inflammation associated with infiltration by eosinophil and atopic disease. It is an allergic eosinophilic disorder, and its incidence has increased dramatically. Its pathogenesis is not entirely understood. Many patients have atopic dermatitis, allergic rhinitis, asthma, or modest peripheral eosinophilia. It probably represents local hypersensitivity (allergies) to ingested food and inhaled allergens. Antigen-presenting cells and mast cells play an important role in its pathogenesis. In addition to GERD-like symptoms, patients often complain of dysphagia, feeling food "sticking" upon swallowing (food impaction) related to specific foodstuffs, dysphagia, and vomiting. Infants may also suffer from feeding intolerance.

Endoscopic appearance: This condition may result in many endoscopic appearances. The most characteristic endoscopic finding is stacked, concentric (circular) mucosal rings (termed as feline esophagus because of endoscopic resemblance to a striped cat's tail or trachealization because it resembles the trachea), narrow esophagus, strictures, vertical linear furrows, and small white plaques/exudates.

MORPHOLOGY

Microscopy: The epithelium shows hyperplasia (papillary and basal layer hyperplasia) and intercellular edema. The characteristic microscopic feature is the **presence of many intraepithelial eosinophils, particularly superficially** (superficial layering of eosinophils). These eosinophils may form clusters, sheets, and eosinophilic microabscesses. The presence of numerous eosinophils (≥15 per high-power field) can help to distinguish eosinophilic esophagitis from GERD, Crohn disease, and other causes of esophagitis. Although eosinophilic microabscesses and lamina propria fibrosis favor the diagnosis of eosinophilic esophagitis, these microscopic findings are not entirely specific to this condition. So, a diagnosis of eosinophilic esophagitis requires clinical, endoscopic, and pathologic data.

Affected patients are often first identified after they fail to respond or improve on standard antireflux therapy. Therefore, GERD should be ruled out with several weeks of proton pump inhibitor therapy before biopsy or with pH monitoring. Some patients with extensive intraepithelial eosinophil infiltration may respond at high doses of proton pump inhibitors. Based on skin patch or immunoglobulin E (IgE) testing, dietary elimination/restrictions of inciting food from the diet can prevent lead to remission in many patients. Also, the elimination of cow's milk, eggs, soy or legumes, and wheat from the diet may be beneficial. When there is no response to dietary treatment, topical or, less frequently, systemic corticosteroids can be used. Sometimes corticosteroids can be combined with proton pump inhibitors. In contrast to GERD, eosinophilic esophagitis is not associated with an increased risk of Barrett esophagus.

Barrett Esophagus

Q. Write a short essay on pathogenesis, risk factors, dysplasia, morphology, diagnostic criteria, recent advances, and malignant progression in Barrett esophagus.

Definition: Barrett esophagus is defined as the **replacement of esophageal squamous mucosa by metaplastic columnar epithelium with goblet cells** (intestinal metaplasia). According to the American College of Gastroenterology guidelines, this condition requires an endoscopic abnormality (columnar-lined esophagus) and the identification of unequivocal goblet cells in a biopsy from the area of the endoscopic abnormality.

Age and gender: Barrett esophagus is most common in adult males between 40 and 60 years of age. However, it can occur in children, sometimes in association with cystic fibrosis (a condition known to induce GE reflux) and following chemotherapy.

Etiopathogenesis: Because of the lack of an exact definition of the nature and location of the GEJ and the microscopic variations at this GEJ, it is not clear whether this is a congenital

JAYPEE BROTHERS

or acquired disorder. But presently, this is believed to be an acquired disorder that develops due to acid-induced ulceration of the esophagus with subsequent re-epithelialization by columnar cells. The origin of the columnar cells is uncertain. They may arise from the migration of gastric mucosa as a result of a phenotypic switch of undifferentiated elements in the stem cell population or as a repopulation from underlying submucosal glands.

Barrett esophagus is a result (complication) of chronic GERD. Smokers have twice the risk of Barrett esophagus as nonsmokers. Obesity is another risk factor. It is associated with an **increased risk of developing esophageal adenocarcinoma**. However, most individuals with Barrett esophagus do not develop esophageal tumors. Genomic sequencing of biopsies involved in Barrett esophagus has shown the presence of pathogenic driver mutations in cancer genes that are also found in esophageal adenocarcinoma. Oncogenic mutations are more in number when biopsies show Barrett with dysplasia, longer segment length, and increased patient age.

MORPHOLOGY

Gross: By endoscopy, Barrett esophagus **appears as tongues of red (salmon–pink) color, velvety mucosa extending upward from the GEJ**. This metaplastic mucosa alternates with residual smooth, pale squamous (esophageal) mucosa and interfaces with light-brown columnar (gastric) mucosa distally.

- **Subclassification:** Barrett esophagus occurs in the lower third of the esophagus but may extend higher. Metaplastic Barrett epithelium may either partially involve the circumference of short segments or may line the entire lower esophagus. Barrett esophagus can be subclassified as a **long segment** (the classic form, in which the **changes involve 3 cm or more of the esophagus)** or a **short segment (<3 cm)**. The risk of transformation into adenocarcinoma correlates with the length of the esophagus involved and the degree of dysplasia. Individuals with short-segment Barrett esophagus may not experience GERD symptoms, and the risk of developing dysplasia or carcinoma is low compared to those with the long-segment disease.

Microscopy (Figs. 5A and B): Barrett esophagus shows a **distinctive "specialized intestinal-type metaplastic epithelium" that replaces the squamous esophageal epithelium**. This intestinal metaplasia is diagnostic of this condition. The epithelium consists of an admixture of **intestine-like epithelium with well-formed goblet cells mixed with gastric foveolar cells (Figs. 5A and B)**. **Goblet cells are diagnostic** of Barrett esophagus. These goblet cells show distinct mucous vacuoles that stain pale blue and impart the shape of a wine goblet (barrel-shaped configuration) to the remaining cytoplasm. Complete intestinal metaplasia with Paneth cells and absorptive cells may occasionally be seen. The extension of columnar epithelial may be circumferential or in the form of finger-like projections or islands. Inflammatory changes are usually seen. The majority of patients never develop dysplasia or adenocarcinoma. In a minority of patients, dysplasia develops in the epithelium.

Diagnostic categories in Barrett esophagus: Dysplasia in a Barrett esophagus is classified as negative, indefinite, low grade, or high grade.

- **Negative for dysplasia:** The architecture is within normal limits. The nuclei do not show variation in size or shape and are located basally. The nuclear-to-cytoplasmic (N:C) ratio is not increased, and nucleoli are not markedly enlarged.
- **Indefinite (IND):** It may show moderately distorted architecture. Nuclear abnormalities are less marked than those seen in dysplasia. The diagnosis of IND should be restricted to cases where the changes are too marked for negative but insufficient for diagnosing dysplasia.
- **Positive for low-grade dysplasia (LGD) or high-grade dysplasia (HGD):** Dysplasia is classified as LGD or HGD. The diagnosis of LGD or HGD depends on the severity of both architectural and cytologic alterations. Both grades **show atypical mitoses, hyperchromatic nucleus, irregularly clumped chromatin, increased N:C ratio, and failure of epithelial cells to mature as they migrate to the esophageal surface**. Dysplastic glands show budding, irregular shapes, and cellular crowding. HGD shows more severe cytologic and architectural changes than LGD. The cytology and architecture of HGD overlap intramucosal adenocarcinoma but without invasion into the lamina propria.
- **Intramucosal adenocarcinoma:** It is defined as carcinoma that has penetrated through the basement membrane of the glands into the lamina propria or muscularis mucosae but not below.

Histochemistry: Most of the mucin present in the specialized columnar epithelium is of neutral type. In more than 70% of the cases, goblet cells contain both sialomucins and sulfomucins (sulfated mucins) that stain positively with Alcian blue at pH 2.5.

Complications of Barrett esophagus: These are the same as those for reflux esophagitis, including peptic ulcer, stricture, and bleeding. Other complications are the development of dysplasia and adenocarcinoma.

The **diagnosis of Barrett esophagus** is established by **endoscopy with biopsy in a patient with GERD symptoms**. Once diagnosed, most patients with Barrett esophagus undergo endoscopic surveillance at regular intervals to detect early microscopic evidence of dysplastic mucosa. Treatment includes surgical resection, esophagectomy, and newer modalities (e.g., photodynamic therapy, laser ablation, and endoscopic mucosectomy).

Various non-neoplastic disorders of the esophagus are depicted in **Figure 6**.

TUMORS OF THE ESOPHAGUS

World Health Organization (WHO) (2019) classification of epithelial tumors of esophagus is presented in **Box 2**.

MEDBROWSERS

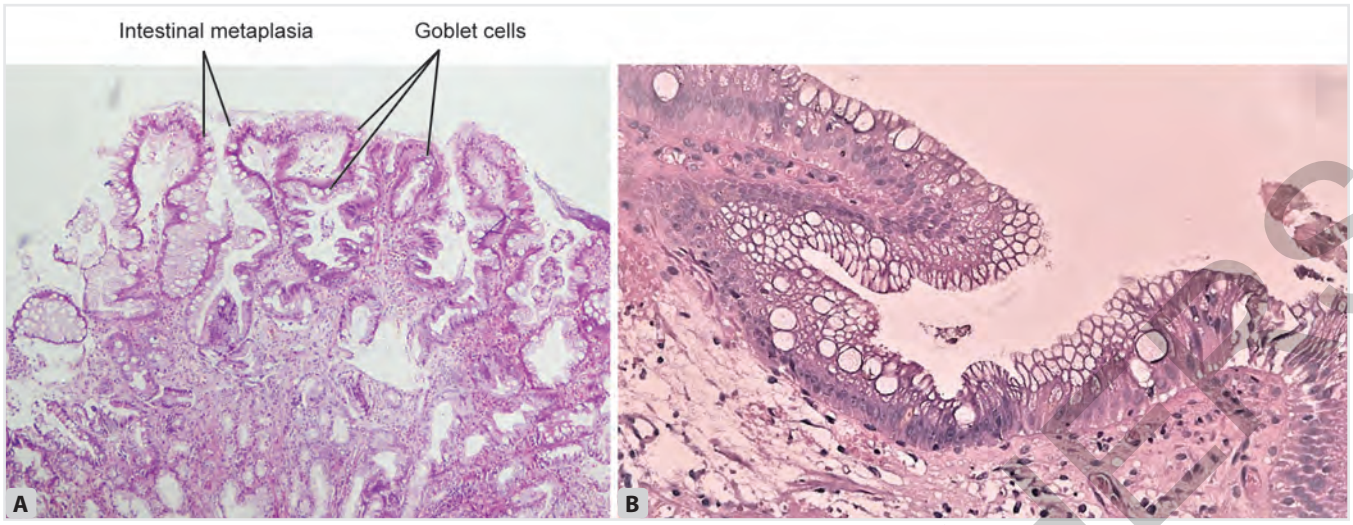

FIGS. 5A AND B: Barrett esophagus with intestinal metaplasia containing goblet cells. (A) Low magnification and (B) higher magnification

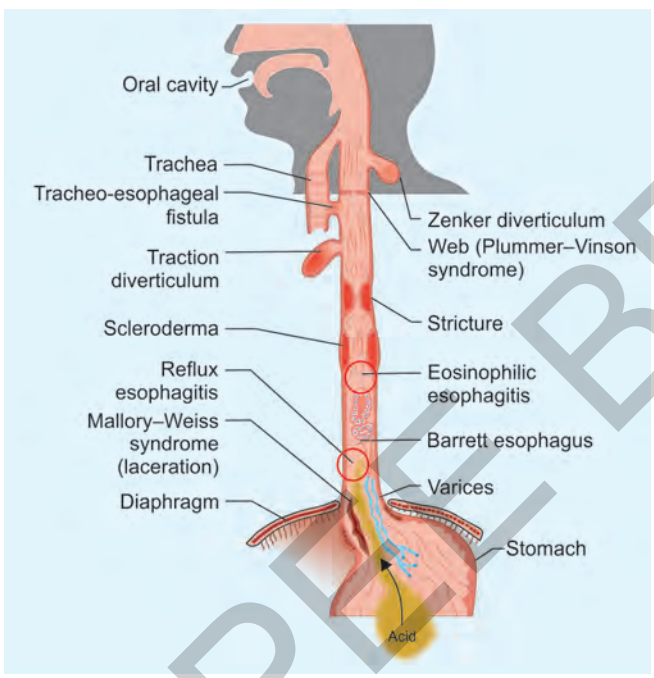

FIG. 6: Diagrammatic representation of various nonneoplastic disorders of the esophagus.

Box 2: World Health Organization (WHO) (2019) classification of epithelial tumors of esophagus.

Benign epithelial tumors and precursors

- Esophageal squamous papilloma
- Barrett dysplasia
- Esophageal squamous dysplasia

Malignant epithelial tumors

- Adenocarcinoma of the esophagus and esophagogastric junction NOS
- Esophageal adenoid cystic carcinoma
- Esophageal adenosquamous and mucoepidermoid carcinomas
- Esophageal squamous cell carcinoma NOS
- Esophageal undifferentiated carcinoma
- Esophageal neuroendocrine neoplasms

Malignant tumors of the esophagus are either adenocarcinoma or SCC. SCC is more common. Other malignant tumors of the esophagus are less common and include unusual forms of adenocarcinoma, undifferentiated carcinoma, neuroendocrine carcinoma, melanoma, lymphoma, and sarcoma. Benign tumors of the esophagus are usually mesenchymal in origin and arise within the esophageal wall. Leiomyomas are the most common benign mesenchymal tumors. They do not arise from interstitial cells of Cajal [gastrointestinal stromal tumors (GISTs)]. Squamous papillomas in the esophagus are uncommon and may be related to infection by human papillomavirus (HPV).

Squamous Cell Carcinoma

Squamous cell carcinoma of the esophagus is more frequent in males (four times more frequent than in females) over 50 years of age.

Risk Factors

Two important and well-known environmental risk factors that strongly affect the development of esophageal SCC are **alcohol and tobacco use** (smoking). They have a synergistic rather than additive effect. Most esophageal SCC are linked to the use of alcohol and tobacco. However, it is also common in individuals without the use of alcohol and tobacco. It can develop in association with poverty (more common in rural and low-income populations), prior caustic esophageal injury (lye strictures), achalasia, Plummer–Vinson syndrome, diverticula, tylosis palmaris et plantaris (an autosomal dominant disorder characterized by hyperkeratosis of palms and soles), diets that are deficient in fruits or vegetables, dietary nitrates and nitrosamines, and frequent consumption

JAYPEE BROTHERS

of very hot beverages (e.g., ingestion of very hot tea). Previous irradiation to the mediastinum also predisposes to esophageal carcinoma, most occurring after 5–10 or more years. Other predisposing factors include nutritional deficiencies, polycyclic hydrocarbons, nitrosamines, and other mutagenic compounds, such as those found in fungus-contaminated foods. Another association is SCC in other sites (particularly the oropharynx and larynx). It may be due to infection by high-risk HPV.

Molecular Pathogenesis

It is not completely known. SCC of the esophagus **develops in a stepwise manner through the accumulation of somatic mutations and epigenetic changes** in oncogenes, tumor suppressor genes, and cell adhesion molecules. These genetic abnormalities drive progression from histologically normal squamous mucosa to low-grade intraepithelial neoplasia (dysplasia) to high-grade intraepithelial neoplasia and finally to invasive SCC. *TP53* mutation and/or overexpression is an early driver mutation. Genetic alterations at the intraepithelial neoplasia stage include aneuploidy, copy-number variations, changes related to the amplification of genes such as *EGFR*, and the silencing of genes such as *CDKN2A* due to promoter hypermethylation. Other recurrent abnormalities include amplification of the transcription factor gene *SOX2* (involved in stem cell self-renewal), overexpression of the cell cycle regulator cyclin D1, and loss-of-function mutations, *CDH1* (which encodes E-cadherin) and *NOTCH1*.

MORPHOLOGY

Localization: About half of esophageal SCC cases involve the middle thirds of the esophagus. In contrast, adenocarcinoma of the esophagus occurs in the distal location.

In situ lesions: Squamous cell carcinoma begins as an in situ lesion termed **squamous dysplasia**. This lesion is called intraepithelial neoplasia or carcinoma in situ at sites outside the GIT (e.g., uterine cervix).

Gross (Figs. 7A to C): They may be endophytic or exophytic. But mixtures of the following types are common. At the time of diagnosis, most are advanced lesions, and they invade into or beyond the muscularis propria.

- **Fungating (exophytic) type:** It presents as an exophytic mass that protrudes into the lumen and tends to obstruct early.
- **Ulcerative type:** This type presents as deep, irregular ulcers with nodular margins. They are more likely to bleed.
- **Diffusely infiltrative (stenotic) type:** They can also infiltrate, grow and spread within the esophageal wall. This may produce thickening, rigidity, and gradual narrowing of the lumen by circumferential compression. It may also be plaque-like and produce mural thickenings.

Cut section: The tumor is grayish white in color and may invade part or all of the muscular wall. It may also extend into the surrounding soft tissues and trachea.

Microscopy: The **microscopic features are the same as SCCs in other site**. Any degree of differentiation may be observed, and variation within a single tumor is common. Most SCCs are moderate to well differentiated. In well-differentiated tumors **(Fig. 8)**, mild nuclear atypia and cellular pleomorphism are accompanied by keratinization with squamous "pearls." In poorly differentiated tumors, there may be no evidence of squamous differentiation; keratinization is sparse and cytologic abnormalities are more pronounced. Less common microscopic variants include verrucous SCC, spindle cell carcinoma, and basaloid SCC.

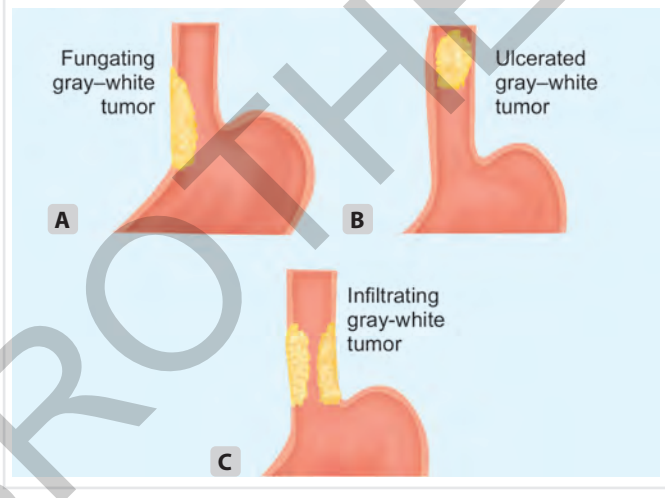

FIGS. 7A TO C: Gross types of carcinoma esophagus: (A) Fungating or exophytic type, (B) ulcerative type, and (C) infiltrative/stenotic type.

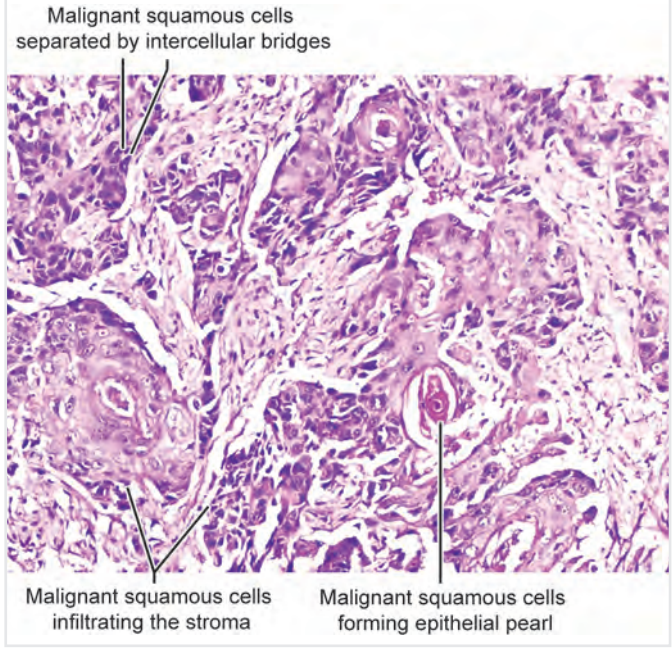

FIG. 8: Microscopic appearance of well-differentiated squamous cell carcinoma.

JAYPEE BROTHERS

Spread of Tumor

Esophagus has a rich lymphatic network. This promotes metastases as well as the circumferential and longitudinal spread of esophageal carcinoma.

Local spread: Tumors may invade surrounding structures. It may spread into the respiratory tree (causing pneumonia), aorta (causing catastrophic bleeding), mediastinum, and pericardium. Tumors in the distal esophagus often invade the stomach.

Lymphatic spread: Esophagus has rich lymphatic drainage, providing a route for most metastases. It may spread into regional lymph nodes. The sites of lymph node metastases vary with the location of the tumor.

- Cancers in the upper third spread to the cervical, internal jugular, and supraclavicular lymph nodes.
- Cancers of the middle third metastasize to mediastinal, paratracheal, tracheobronchial, and hilar lymph nodes and to nodes in the aortic, cardiac, and paraesophageal regions.
- Lower third of the esophagus is supplied by the left gastric artery. Hence, tumors of the lower esophagus spread through accompanying lymphatics to retroperitoneal, celiac, and left gastric lymph nodes.

Hematogenous spread: Occurs late and spreads to the liver, lungs, adrenals, kidneys, and bones. But almost any organ may be affected.

Clinical features: Esophageal SCCs are insidious in onset. Most symptomatic tumors are usually large and invasive, and most are inoperable at the time of diagnosis. Typically, dysphagia is the most common presenting complaint. Patients may become cachectic due to anorexia, difficulty swallowing, and cancer effects. Other symptoms include odynophagia (pain on swallowing) or obstruction. When the tumor ulcerates, hemorrhage and sepsis may accompany it. Symptoms due to iron deficiency may often present. Occasionally, symptoms such as a chronic cough may be caused due to aspiration of food via a tracheoesophageal fistula (caused by the extension of the tumor into the trachea). Persistent pain may be due to extension to the mediastinum or to spinal nerves. Compression of the recurrent laryngeal nerve causes hoarseness. Endoscopic screening has led to earlier detection of esophageal SCC.

Prognosis: Five-year survival rates are 75% in patients with superficial lesions but much lower in patients with more advanced tumors. Metastases to lymph nodes are associated with poor prognosis. The overall 5-year survival rate varies by tumor stage and patient age, race, and sex.

Adenocarcinoma

Adenocarcinoma is a carcinoma displaying glandular differentiation. It more often affects men than women.

Etiology

Esophageal adenocarcinoma usually **arises in a background of Barrett esophagus and long-standing GERD**. Other major risk factors include the use of tobacco, diet, obesity, exposure to radiation, and genetic factors. Also, risk factors that lead to increased gastric acid production or reflux also increase the risk. These include lower esophageal sphincter dilation or myotomy, scleroderma, Zollinger–Ellison syndrome, or the use of drugs that relax the lower esophageal sphincter. Risk is reduced by diets rich in fresh fruits and vegetables. Few serotypes of *Helicobacter pylori* are associated with decreased risk of esophageal adenocarcinoma, probably by causing gastric atrophy. This, in turn, reduces the secretion of acid and also reflux-induced esophageal damage.

Pathogenesis

Progression of Barrett esophagus to adenocarcinoma develops in a stepwise pattern with genetic and epigenetic alterations. Genetic changes include chromosomal abnormalities and mutation or overexpression of tumor suppressor genes *TP53* and *CDKN2A*. *CDKN2A* encodes two tumor suppressor proteins, p16 and p19-ARF. Both allelic loss and hypermethylation-induced epigenetic silencing are involved in these genes. These changes are detected in the early stages. As the tumor progresses, there may be an amplification of several oncogenes. These include the *EGFR*, *ERBB2*, *MET*, *cyclin D1*, and *cyclin E* genes.

MORPHOLOGY

Gross

Site: Most adenocarcinomas (up to 80%) occur **in the distal third of the esophagus or GEJ.** They may invade or extend into the adjacent cardia of the stomach (proximal stomach).

Appearance: Early lesions appear as flat or raised patches in otherwise intact esophageal mucosa. As they grow, they form large masses of 5 cm or more in diameter. They may **infiltrate diffusely or ulcerate** and invade deeply. The gross appearances are similar to SCC. Tumors may range from flat, irregular plaques or slightly depressed lesions to advanced ulcerating, polypoid, or fungating masses.

Microscopy: It may show a range of histologic patterns **similar to gastric adenocarcinoma**. Most are well differentiated, consisting of well-developed glands or moderately differentiated. Usually, tumors produce extracellular mucin and form glands, often with intestinal-type morphology. Tumors most commonly produce mucin. Poorly differentiated tumors do not have glandular differentiation, and some may have signet ring cellular morphology. Barrett esophagus may be present adjacent to the tumor.

Differential diagnosis: In a biopsy obtained from the lower esophageal tumor, it may be difficult to distinguish a poorly differentiated adenocarcinoma from a poorly differentiated SCC.

- **Squamous cell carcinomas:** They are strongly positive for CK5/6, p63 (usually >75% positive), and p40 (which is more specific than p63).
- **Adenocarcinomas:** They are strongly positive for CK7 (usually >75% positive) and negative for squamous markers.

JAYPEE BROTHERS

Clinical Features

The symptoms and clinical course of esophageal adenocarcinoma are similar to esophageal squamous carcinoma. Symptoms include pain, difficulty in swallowing, chest pain, reflux, progressive weight loss, hematemesis, or vomiting.

Prognosis: Overall 5-year survival is less than 25%. However, 5-year survival is about 80% in patients whose adenocarcinoma is limited to the mucosa or submucosa.

Tumor, node, and metastases (TNM) staging of tumors of the esophagus is presented in **Table 1**.

Table 1: Tumor, node, and metastases (TNM) staging of tumors of the esophagus.

TNM clinical classification	
T—primary tumor	
TX	Primary tumor cannot be assessed
T0	No evidence of primary tumor
Tis	Carcinoma in situ/high-grade dysplasia
T1	Tumor invades lamina propria, muscularis mucosae, or submucosa
• T1a	• Tumor invades lamina propria or muscularis mucosae
• T1b	• Tumor invades submucosa
T2	Tumor invades muscularis propria
T3	Tumor invades adventitia
T4	Tumor invades adjacent structures
• T4a	• Tumor invades pleura, pericardium, azygos vein, diaphragm, or peritoneum
• T4b	• Tumor invades other adjacent structures such as the aorta, vertebral body, or trachea
N—regional lymph nodes	
NX	Regional lymph nodes cannot be assessed
N0	No regional lymph node metastasis
N1	Metastasis in one to two regional lymph nodes
N2	Metastasis in three to six regional lymph nodes
N3	Metastasis in seven or more regional lymph nodes
M—distant metastasis	
M0	No distant metastasis
M1	Distant metastasis
pTNM—pathological classification	
The pT and pN categories correspond to the T and N categories	
pN0	Histological examination of a regional lymphadenectomy specimen will ordinarily include seven or more lymph nodes. If the lymph nodes are negative, but the number ordinarily examined is not met, classify them as pNO
pM	Distant metastasis*
pM1	Distant metastasis microscopically confirmed

*pM0 and pMX are not valid categories.

JAYPEE BROTHERS

for detailed information on pathology books, visit our website www.jaypeebrothers.com, for detailed information on pathology books, visit our website www.jaypeebro

REVIEW OF
POSTGRADUATE PATHOLOGY
SYSTEMIC PATHOLOGY

Salient Features

- **Comprehensive Coverage:** Encompasses fundamental and sophisticated aspects of systemic pathology, essential for postgraduate scholars
- **Accessible Presentation:** Presents systemic pathology insights in a clear, uncomplicated, and easily graspable manner
- **Convenient Memorization:** Facilitates quick review through the use of significant points emphasized in bold
- **Exam-Centric Approach:** Includes customary questions encountered in MD and DNB systemic pathology theory examinations
- **Visual Enrichment:** Augmented with illustrations, flowcharts, tables, gross images, photomicrographs, clinical visuals, and radiographs to enhance content understanding

Ramadas Nayak MBBS MD, graduated from Mysore Medical College, Mysuru, Karnataka, India. He completed his postgraduation in Pathology from Kasturba Medical College, Mangaluru, Karnataka, India. Currently, he holds the position of Professor (former Head) in the Department of Pathology at Yenepoya Medical College, Yenepoya (Deemed-to-be University), Mangaluru, Karnataka, India. With an extensive teaching career spanning 41 years, he served as the Head of the Department of Pathology at Kasturba Medical College, under Manipal Academy of Higher Education, Karnataka, India. He boasts a remarkable portfolio of 83 published scientific papers in both national and international journals. Ramadas Nayak is actively engaged as an examiner for undergraduate and postgraduate examinations across multiple universities. He has also contributed significantly to various projects. Notably, he worked as a Project Officer for the development of an Atlas of Cancer in India, a project sponsored by the Indian Council of Medical Research (ICMR) in collaboration with the World Health Organization (WHO). Additionally, he played a crucial role as an Editorial Committee Member for the South Asia Edition of the British Medical Journal. Ramadas Nayak is the author of 10 notable books, including Essentials in Hematology and Clinical Pathology (Second Edition), Textbook of Pathology and Genetics for Nurses (Second Edition), Rapid Review of Hematology, Exam Preparatory Manual for Undergraduates: Pathology (Fourth Edition), Exam Preparatory Manual for Undergraduates: Pathology for Dental Students, Textbook of Pathology for BPT Students, Textbook of Pathology for Allied Health Sciences, Histopathology Techniques and Their Management, Manual of Transfusion Medicine, and Review of Postgraduate Pathology—General Pathology. His excellence in teaching has been acknowledged through accolades such as the "Good Teacher Award" twice and the "Best Audio-Visual Award" eight times during his tenure at Kasturba Medical College. Notably, he secured the "Teacher of the Year Award 2022" at Yenepoya Medical College.

Rakshatha Nayak MBBS MD DNB is an accomplished professional who graduated from KS Hegde Medical Academy, Constituent of Nitte (Deemed-to-be University), Mangaluru, Karnataka, India. She pursued her postgraduate studies in Pathology at Yenepoya Medical College, Yenepoya (Deemed-to-be University), Mangaluru, Karnataka, India. Currently, she holds the position of Assistant Professor in the Department of Pathology at Kasturba Medical College, Mangaluru, under Manipal Academy of Higher Education, Karnataka, India. Rakshatha's educational journey includes serving as a tutor in the Department of Forensic Medicine at Kasturba Medical College from 2014 to 2015. She also served as a tutor in the Department of Pathology at Yenepoya Medical College. Her commitment to continuous learning is evident through her completion of the ISN-ANIO Clinical Nephropathology Certificate Programme organized by the International Society of Nephropathology in 2018. Furthermore, she successfully cleared the Diplomate of National Board Examination in Pathology in the same year. Rakshatha's contributions to academia and research are notable. She has authored and presented several scientific papers in esteemed national and international journals and conferences. Her dedication to Excellence has been recognized through awards such as the Short Term Studentship (STS) granted by the Indian Council of Medical Research (ICMR) in 2011. Throughout her academic journey, Rakshatha has demonstrated outstanding performance. She secured accolades as the highest scorer in Pathology at KS Hegde Medical Academy and attained the 3rd rank in the Phase-II MBBS (Pathology) Examination held in 2010 by Rajiv Gandhi University of Health Sciences (RGUHS), Bengaluru. Additionally, she excelled as the top scorer in KS Hegde Medical Academy, Mangaluru in General Medicine during the final-year MBBS examination conducted by RGUHS, Bengaluru, in 2012. In her postgraduate studies, Rakshatha continued to shine as the highest scorer in Pathology and earned the title of University Topper in the postgraduate examination conducted by Yenepoya in 2018. With 5 years of valuable teaching experience, Rakshatha has imparted knowledge to students pursuing Medical, Dental, and Allied Health Sciences. She has contributed as a co-author to the Exam Preparatory Manual for Undergraduates: Pathology (Fourth Edition), Manual of Transfusion Medicine, and Review of Postgraduate Pathology—General Pathology. Her dedication to education was further acknowledged when she secured the second prize for the "Best Audio-Visual Award" at Kasturba Medical College in 2022.

Printed in India

Available at all medical bookstores
or buy online at www.jaypeebrothers.com



JAYPEE BROTHERS
Medical Publishers (P) Ltd.
EMCA House, 23/23-B, Ansari Road,
Daryaganj, New Delhi - 110 002, INDIA
www.jaypeebrothers.com

Join us on facebook.com/JaypeeMedicalPublishers

Shelving Recommendation
PATHOLOGY

