tal books, visit our website www.jaypeebrothers.com, for detailed information on dental books, visit our website www.jaypeebrothers.com, for detailed information on dental books

CERVICAL CYTOLOGY

Special Emphasis on Liquid-based Cytology

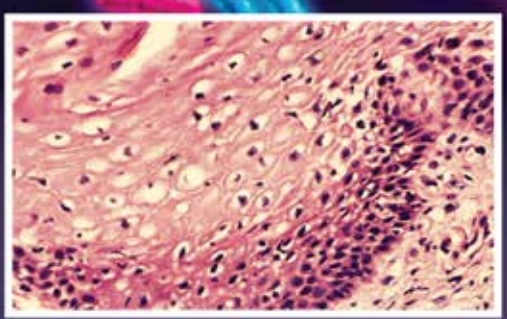
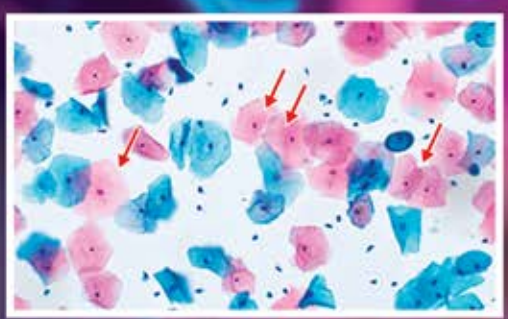
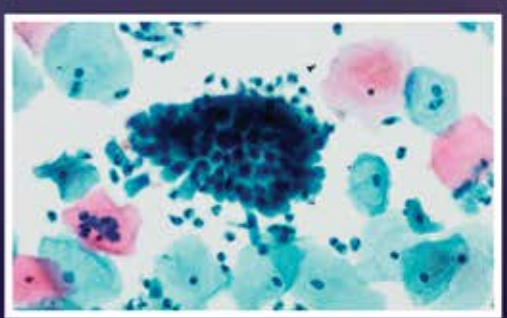
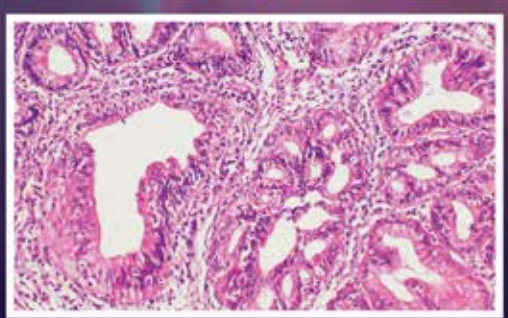

SECOND EDITION

PRANAB DEY

JAYPEE

Contents

1. Anatomy, Normal Cytology of the Female Genital Tract, and Approach of Reporting **1**

Normal Anatomy and Histology of the Female Genital Tract 1
Cytology 5
Cells of Adjacent Organ 19

2. Sample Collection, Liquid-based Cytology, and Automated Screening **25**

Cervical Smear Sampling 25
Procedure of Sample Collection 26
Liquid-based Cytology 27

3. Bethesda System of Reporting Cervical Cytology **34**

Introduction to Different Classification 34
Bethesda System 2014 35
Predominant Changes in Bethesda 2014 Classification 37
Explanations 37
Epithelial Cell Abnormalities 42

4. Negative for Intraepithelial Lesion or Malignancy **44**

Reactive Cellular Changes 44
Organisms 53
Atrophic Changes 59
Glandular Cell Status Posthysterectomy 60

5. Atypical Squamous Cells **61**

Definition of Atypical Squamous Cell 62
Atypical Squamous Cells of Undetermined Significance 62
Liquid-based Cytology 65
Atypical Squamous Cell, cannot Exclude High-grade Squamous Intraepithelial Lesion 69

6. Squamous Intraepithelial Lesions and Invasive Carcinoma **76**
Low-grade Squamous Intraepithelial Lesions 77
High-grade Squamous Intraepithelial Lesions 89
Keratinizing High-grade Squamous Intraepithelial Lesion 102
Squamous Cell Carcinoma 107

7. Epithelial Cell Abnormality: Atypical Glandular **116**
Atypical Endocervical Cells 117
Atypical Endometrial Cells 119
Endocervical Adenocarcinoma in Situ 129
Endocervical Adenocarcinoma 132
Endometrial Adenocarcinoma 138
Endometrial Versus Endocervical Adenocarcinoma 142

8. Endometrial Cells Present **145**
Endometrial Cells 145

9. Other Malignant Tumors **151**
Cervical Malignancies 151
Metastatic Tumors 154

10. Screening and Quality Control of Cervical Lesions **159**
Screening Strategy 159
Different Screening Methods for Cervical Precancer 160
Quality Control of Cervical Cytology 166
Indicators of Good Screening Program 167
Management 169

11. Sample Cases **173**

Index ***191***

Scan the QR code to access the *Digital Slides*

Sample Collection, Liquid-based Cytology, and Automated Screening

2

CERVICAL SMEAR SAMPLING

Optimal collection of cervical cytology specimen is the first important step for proper interpretation. The following things are needed for cervical cytology smear collection:

- *Instrument*:
  - *Devices to collect the cervical sample*: Ayre's spatula/Cervex-Brush/endocervical brush **(Fig. 2.1)**
  - *Speculum*: To examine the cervix and to take smear
- *Fixative*:
  - Coplin jar with 95% ethanol
  - Spray fixative
  - Fixative supplied by the company for liquid-based cytology (LBC)
- Glass slide for conventional preparation (CP)
- *Laboratory form*: The laboratory form with full clinical details

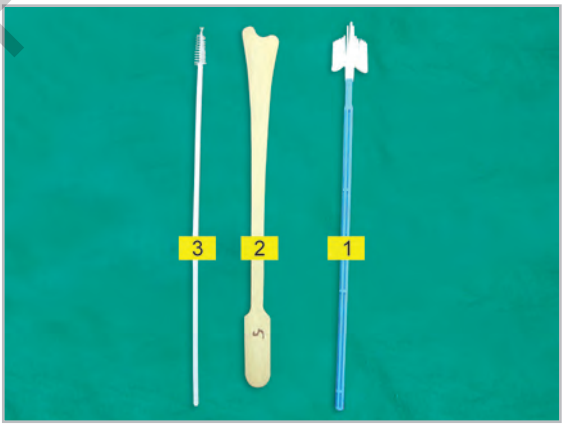

FIG. 2.1: Different devices to collect the cervical smear—(1) Cervex-Brush, (2) Ayer's spatula, and (3) Endocervical brush.

JAYPEE BROTHERS

Optimum Clinical Condition and Required Information

- It is preferable that the patient should be in the mid-cycle and by any chance she should not be in the menstruation.
- The patient should be restrained from sexual intercourse 2 days prior to the test.
- Any sort of vaginal cream, lubricant jelly, or tampon should also be avoided.
- Name of the patient, age, date of last menstrual period, any symptoms, and previous screening history.

PROCEDURE OF SAMPLE COLLECTION

The patient should be in the dorsolithotomy position as in this position the cervix is better visualized **(Box 2.1)**. The speculum is introduced through vagina without using any lubricant jelly. Water can be used to moisturize the speculum and rarely water-soluble lubricant is used. Usually, broomstick-like device is used for LBC preparation. The broom is introduced so that the central part enters into the endocervical canal and the shorter bristles of the broom touch to the ectocervix **(Fig. 2.2)**. The broom is rotated four

BOX 2.1: Sample collection.

- *Precautions*: Avoid lubricant jelly or alcoholic swab, menstrual time, patient should abstain from sexual intercourse for 2 days
- *Instruments and form*: Cervex-Brush, spatula, collection vial with fixative, and glass slides
- *Position*: Dorsolithotomy
- *Collection procedure*:
  - Clean the vagina with wet swab
  - Introduce the spatula in the cervical canal
  - Rotate the spatula by 360°
  - Dip the spatula in the supplied vial filled with collection fluid

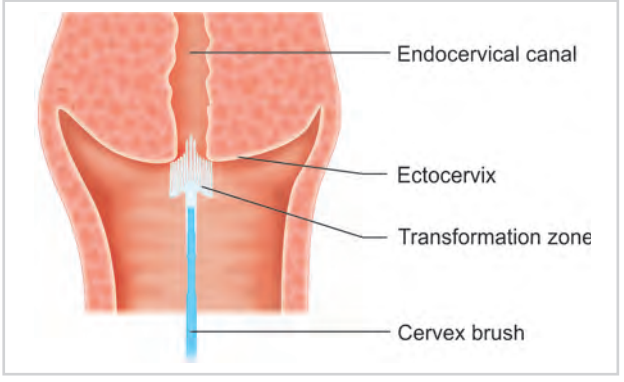

FIG. 2.2: Sample collection technique.

JAYPEE BROTHERS

to five times in a clockwise direction. Then the broom is withdrawn and is dipped in the fixative solution provided by the company. The broom should be repeatedly swirled to shake the material into liquid. Finally, the broom should be discarded and the vials should be labelled properly and sent to the laboratory.

In case of CP either broom or spatula is used. The collection of the cervical sampling method is almost same. The smear is prepared on the glass slide and immediately fixed in the 95% ethyl alcohol for 30 minutes. Alternatively, spray fixative can be used. Spray fixative contains alcohol base and carbowax. Before Papanicolaou's staining, the carbowax must be removed by dipping the slide in alcohol.

LIQUID-BASED CYTOLOGY

Presently two companies are available for LBC—(1) ThinPrep (TP) (Cytyc Corp, Marlborough, MA) and (2) SurePath (SP) (TriPath Imaging Inc., Burlington, NC). Both these companies are approved by Food and Drug Administration (FDA). Unlike smear preparation and fixation in the CP, these techniques provide the methods of immediate fixation of the cells in liquid fixative.

ThinPrep Preparation Technique (Figs. 2.3A and B)

The ThinPrep 5000 processor is now presently available in the market. The processor can automatically prepare up to 20 samples in 45-minute time period. The microscopic slides are always provided by the TP (Cytic, UK) company.

Dispersion

The sample is collected in 20 mL of PreservCyt solution for fixation.

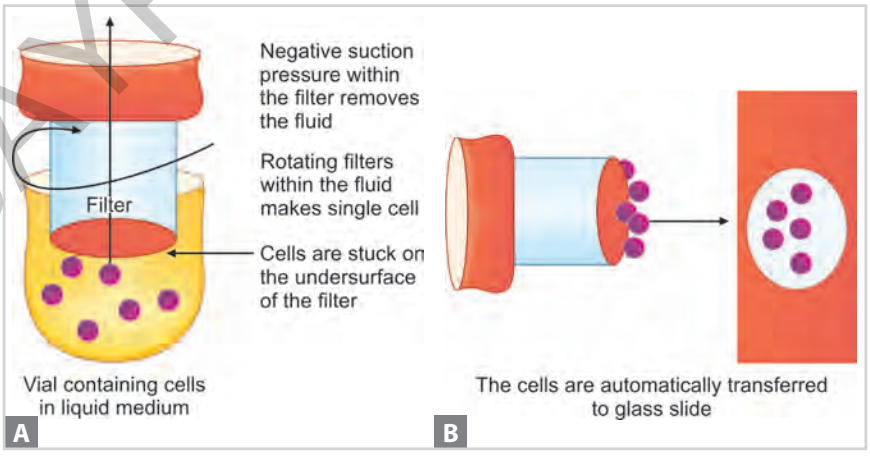

FIGS. 2.3A AND B: Schematic diagram showing the basic principle of ThinPrep.

JAYPEE BROTHERS

A cylindrical tube with attached filter in one end is dipped within the vial containing the specimen in PreservCyt solution. The cylinder is rotated within the vial rapidly and this rotatory movement disperses the cells singly.

Cell Collection

A gentle negative suction pressure is used through the cylinder and the fluid from the vial is drained out whereas the cells are struck on the external surface of the filter. The collection of the cell is controlled by adjusting the negative pressure with the help of in-built software in the TP processor.

Cell Transfer

Now the TP filter is inverted and the cells attached to the surface of the filter are imprinted automatically on the circular area of the glass slides. The cells are adhered on the glass slide by positive air pressure. The slide is immediately immersed within a fixative.

SurePath Preparation Technique

Currently, BD Totalys™ is available on the market, which is a fully automated machine and is able to process 96 samples at a time **(Fig. 2.4)**. In SP technique, at first the cells are collected in the SP preservative fluid in a vial. The vial is transferred to the laboratory for further processing. The details of the technique is described below **(Figs. 2.5A and B)**.



FIG. 2.4: BD Totalys™ multiprocessor machine which is completely automatic.

JAYPEE BROTHERS

Vortexing

The sample is vortexed to disperse the cells. A total of 48 sample can be vortexed in each time **(Fig. 2.6)**.

Cell Enrichment

The sample is then mixed with PREPSTAIN® Density Reagent and is centrifuged for 2 minutes in 200 g **(Figs. 2.7 and 2.8)**. The unwanted elements such as blood, mucus, and necrotic debris are separated by the centrifugation. The supernatant fluid is decanted by using vacuum suction. The reaming fluid is again centrifuged by 800 g for 10 minutes **(Fig. 2.8)**. A cell-rich pellet is formed.

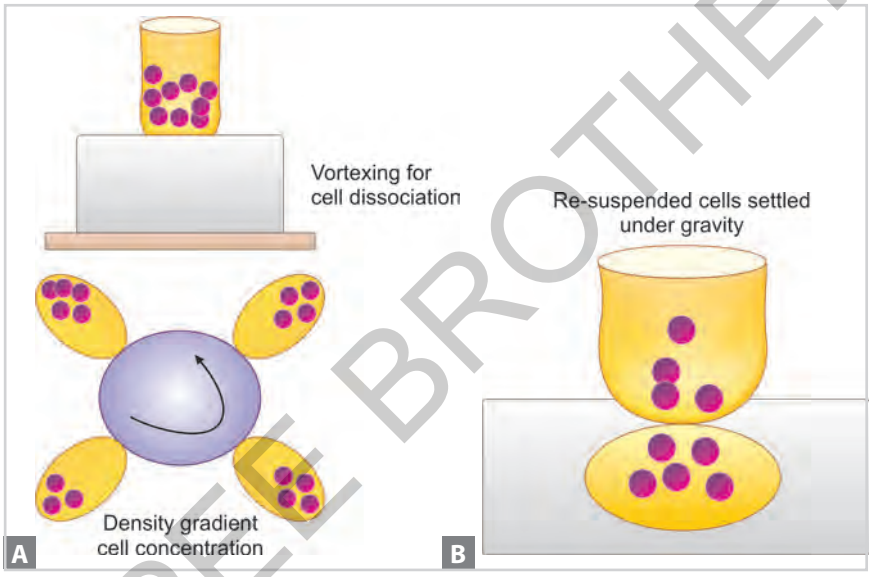

FIGS. 2.5A AND B: Schematic diagram showing the basic principle of SurePath.



FIG. 2.6: Vortexing: The specimen is vortexed for 15 seconds.

JAYPEE BROTHERS



FIG. 2.7: The sample is mixed with PrepStain density reagent.



FIG. 2.8: The tubes are centrifuged and then the supernatant fluid is discarded.

JAYPEE BROTHERS

Resuspension

The cell pellet is revortexed for 15–20 seconds to resuspend the cellular material within the fluid and then transferred into the PrepStain slide processor.

Density Gradient Sedimentation (Fig. 2.9)

In the PREPSTAIN® settling chamber, the cells are deposited with the help of gravity on a precoated slide (modified poly-L-lysine). Simultaneously, Papanicolaou's stain is automatically done with the help of program software.

Table 2.1 shows comparison of TP and SP technique.[1]



FIG. 2.9: Specimen finally ran into BD PrepStain slide processor.

Table 2.1: Comparison of ThinPrep versus SurePath.

Features	*ThinPrep*	*SurePath*
Fixative	PreservCyt fluid is methanol-based fixative	SurePath preservative fluid is ethanol based
Sample preparation	Easy	Time consuming
Cell dissociation	By rotatory motion of the vial	By vortexing
Cell separation	By negative suction	Density gradient
Monolayer	Monolayer preparation	Multilayer
Hyperchromatic crowded group of cells	Infrequent	Frequent
Cell concentration	Relatively less	More
Inadequacy rate	More	Less

JAYPEE BROTHERS

Advantages and Disadvantages of Liquid-based Cytology Preparation

Advantages

Liquid-based cytology preparation of cervical smear has the following advantages:

- Better cellular preservation and no air-drying artifact
- Overall cellularity is much more than CP.
- Relatively clean background
- Lesser screening time as the cells are limited to a small area.
- Monolayer cell preparation in TP
- Multiple smears can be prepared from a single sample.
- Human papillomavirus (HPV) testing can be done from the residual sample.

Disadvantages of Liquid-based Cytology Preparation

- Costly instrument
- Training is required for interpretation.

Significant Differences of the Cytology in Liquid-based Cytology Compared to Conventional Preparation

There are few important features present in the LBC:

- *Background*: The background of the cytology smear is always clean and free from any blood, mucus, and necrotic debris **(Fig. 2.10)**.
- *Cell size*: The cells are immediately dipped in fluid and due to wet fixation overall cell shape is more rounded and cell size is also smaller compared to CP.

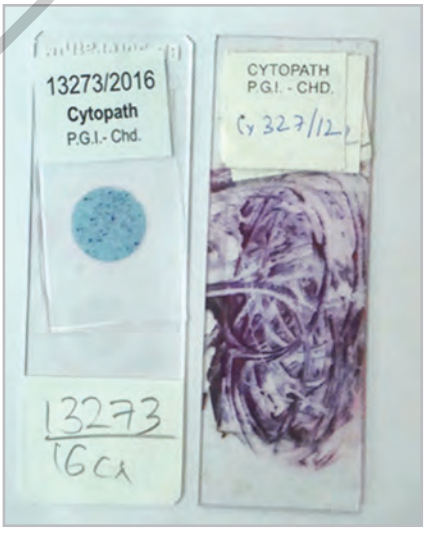

FIG. 2.10: Clean and small smear free from blood and mucus in liquid-based cytology compared to conventional smear.

JAYPEE BROTHERS

- *Cell crowding*: Cellular dispersion is overall more in TP than SP. Hyperchromatic crowded groups of cells are frequently seen in SP.
- *Hyperchromasia*: The nuclei of the cells are relatively less hyperchromatic compared to CP of cells.
- *Cytoplasmic and nuclear detail*: As the cells are immediately fixed in liquid fixative so the nuclear details are excellent in LBC.

Specific Changes in Liquid-based Cytology

Following specific changes are seen in LBC compared to CP:

- Atypical squamous cells of undetermined significance (ASCUS) is relatively easily recognized due to better cellular preservation.
- *ASC-H*: Here the cells look much smaller.
- *Low-grade squamous intraepithelial lesion (LSIL)*: The nuclear hyperchromasia is minimal.
- *High-grade squamous intraepithelial lesion (HSIL)*: The cells are usually more dispersed than in clusters. The nuclear hyperchromasia may be lost in many cells.
- *Squamous cell carcinoma*: Necrotic tissue debris are mostly removed in case of carcinoma and necrotic material is adhered in the periphery of the cell cluster giving the appearance of "clinging diathesis". The overall cellularity of the tumor cells may be low. At times, the cells are present in small round pattern and may simulate glands of adenocarcinoma.
- Feathering pattern of adenocarcinoma is better seen.
- *Endometrial cell*: The cells are mostly present as three-dimensional clusters. Single cells are also present. The nuclear morphology is better preserved with nucleoli and details chromatin pattern.
- *Follicular cervicitis*: The lymphoid cells are usually present in clusters instead of discretely.
- *Bacterial vaginosis*: Clue cells are seen in a clean background.
- *Trichomonas vaginalis*: The typical background is lost and the TVs are smaller in size and round in shape.
- *Candida*: Epithelial cells often show Shish–Kebab-like appearance.
- *Atrophic smear*: The granular background may be mistaken as granular debris of squamous cell carcinoma. The nuclei of the cells are small in size, and the bare nuclei are less in number.
- *Hyperchromatic crowded group of cells*: This type of cellular crowding is frequently seen in SP.

REFERENCES

1. Zhao FH, Hu SY, Bian JJ, Liu B, Peck RB, Bao YP, et al. Comparison of ThinPrep and SurePath liquid-based cytology and subsequent human papillomavirus DNA testing in China. Cancer Cytopathol. 2011;119(6):387-94.

JAYPEE BROTHERS

for detailed information on dental books, visit our website www.jaypeebrothers.com, for detailed information on dental books, visit our website www.jaypeebrothers.com, for detailed

CERVICAL CYTOLOGY

Special Emphasis on Liquid-based Cytology

Salient Features

- A concise practical handbook on cervical cytology
- Presents salient diagnostic features of different cervical lesions on cytology smears
- Provides detailed discussion on differential diagnosis and management of the lesions
- Emphasizes on cytomorphology in liquid-based cytology
- Includes a large number of microphotographs to facilitate the recognition of the lesions
- Very helpful to interpret the cervical smears by Bethesda System, particularly in liquid-based preparation
- Useful for practicing cytologists, students, and cytoscreeners

Pranab Dey MBBS MD MIAC FRCPath is Professor, Director of Pathology and Transfusion Medicine, National Institute of Medical Sciences, Jaipur, Rajasthan, India. He has been engaged in diagnosis, research, and teaching in cytology and gynecologic pathology for over 25 years. He has also authored five more books titled Fine Needle Aspiration Cytology: Interpretation and Diagnostic Difficulties, Diagnostic Cytology, Case-based Approach in Fine Needle Aspiration Cytology, Case-based Approach in Exfoliative Cytology, and Essentials of Gynecologic Pathology.

Printed in India

Available at all medical bookstores or buy online at www.jaypeebrothers.com



JAYPEE BROTHERS
Medical Publishers (P) Ltd.
EMCA House, 23/23-B, Ansari Road,
Daryaganj, New Delhi - 110 002, INDIA
www.jaypeebrothers.com

Join us on facebook.com/JaypeeMedicalPublishers

Shelving Recommendation
PATHOLOGY

ISBN 978-93-5696-317-7

9 789356 963177