ation on surgery books, visit our website www.jaypeebrothers.com, for detailed information on surgery books, visit our website www.jaypeebrothers.com,

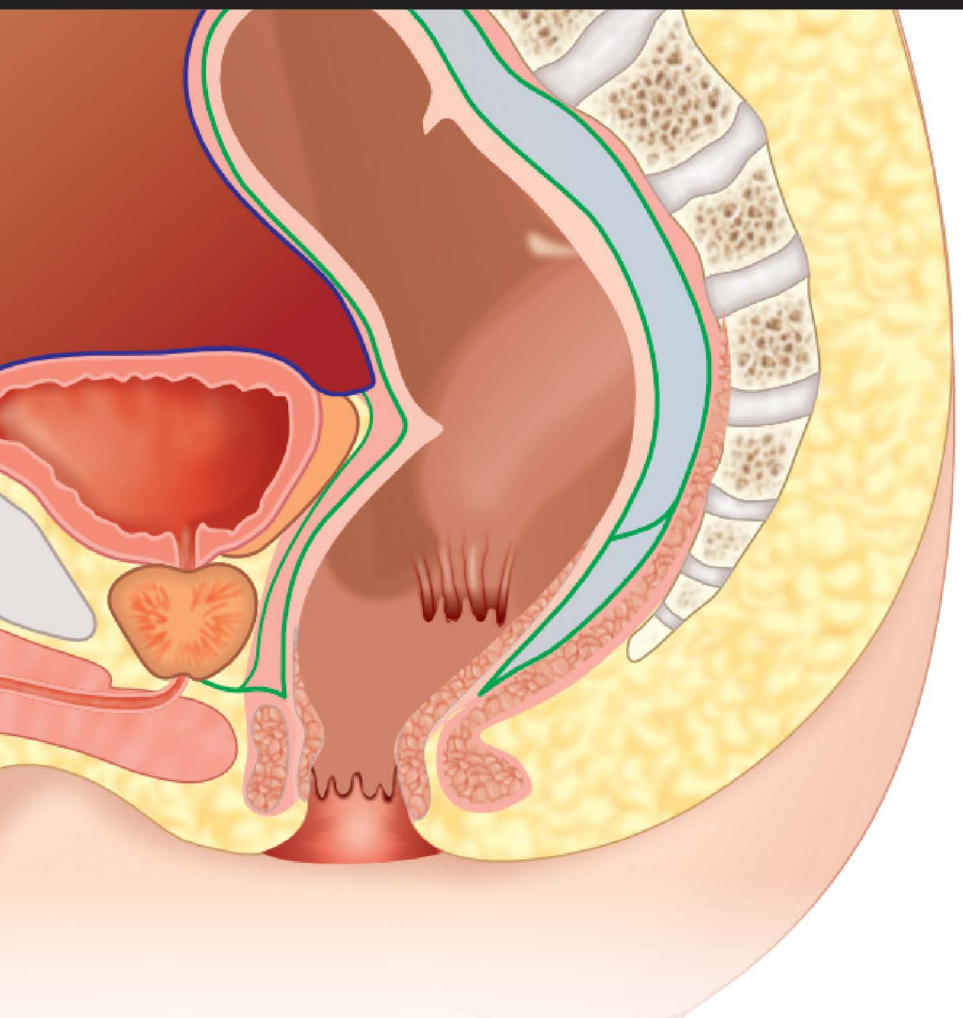

The Association of Colon & Rectal Surgeons of India
(A Section of ASI)

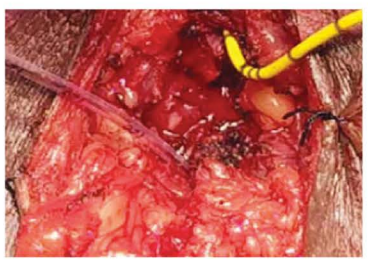

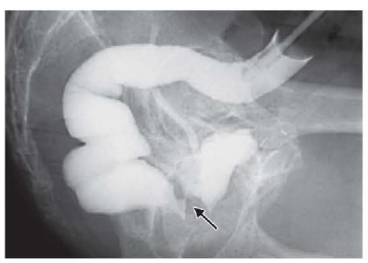

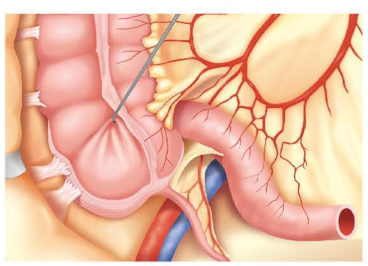

ACRSI TEXTBOOK OF COLORECTAL SURGERY

Editors
Niranjan Agarwal
Pradeep P Sharma
Parvez Sheikh

Forewords
VN Shrikhande
Indru Tekchand Khubchandani

JAYPEE

Contents

1. **Anatomy and Embryology of the Colon, Rectum, and Anus** 1
   Anthony Rozario, Rajashekar Mohan, Ann Sunny

2. **Physiology of Colon, Rectum, and Anus** 14
   Jayanthi Venkataraman, Mayank Jain, Umamakeswari Venkatesa, Melpakkam Srinivas

3. **Endoscopy in Colorectal Disease** 21
   Amit Maydeo, Ankit Dalal

4. **Imaging in Colorectal Diseases: Conventional, USG, CT, MRI, and PET-CT** 34
   Ravikumar B Thapar, Ritesh D Kamat

5. **Assessment of Pelvic Floor: Anal Manometry** 54
   Rajesh Sainani

6. **Colorectal Anastomosis and Its Complications** 60
   Rajiva Ranjan Das, Sridhar Dharmavaram

7. **Approach and Management of Anal Pain** 82
   Kiran Shah

8. **Hemorrhoids** 95
   Niranjan Agarwal, Kamal Gupta

9. **Fissure in Ano** 129
   Shekhar O Suradkar, Pravin P Gore

10. **Anorectal Abscess and Fistula-in-Ano** 146
    Parvez Sheikh, Arun Rojanasakul, Arshad Ahmad, Songphol Malakorn

11. **Rectovaginal and Rectourethral Fistulas** 178
    Mark Ranjan Jesudason

12. **Pilonidal Disease** 193
    Pradeep P Sharma, Ajay K Khanna

13. **Perianal Skin Diseases** 215
    Pradeep Mahajan, Balkrishna P Nikam

14. **Neoplasms of the Anal Canal** 230
    Narimantas Evaldas Samalavicius, Audrius Dulskas, Edgaras Smolskas, Edita Baltruskeviciene

15. **Cancer of the Rectum** 246
Avanish Saklani, Venkatesh Munikrishnan, Deepak Govil

16. **Colorectal Polyps, Molecular Screening, and Familial Cancers** 262
Varughese Mathai, Kishore V Alapati, Chinnaya Parimi

17. **Cancer of the Colon** 276
Nisar A Chowdri, Fazlul Qadir Parray, Asif Mehraj, Mudassir Ahmad Khan

18. **Quality of Life after Colorectal Surgery** 334
M Kanagavel

19. **Appendix** 345
Kumkum Singh, Shyam Bhutra

20. **Miscellaneous Tumors of the Colon and Rectum** 350
Subodh Varshney

21. **Diverticular Disease of the Colon** 371
Ricardo Escalante G, Giovanni Brandimarte, Leonardo Bustamante-Lopez, Antonio Tursi, Enio Chaves de Oliveira

22. **Large Bowel Obstruction** 385
Avinash N Supe, Ramkrishna Y Prabhu

23. **Lower Gastrointestinal Bleeding** 409
Chetan V Kantharia, Sharvari Gopal Pujari

24. **Trauma of the Colon, Rectum, Anus, and Foreign Bodies** 418
Satish B Dharap, Winston Noronha

25. **Tuberculosis of the Colon, Rectum and Anus** 432
Vinay K Kapoor, Saurabh Galodha, Avinash Tank, Prakash Kumar Sasmal

26. **Ulcerative Colitis: A Surgeon's Perspective** 446
S Rajapandian, R Parthasarathi, C Palanivelu

27. **Crohn's Disease** 505
Nilesh Doctor, Chintamani Godbole

28. **Intestinal Stomas** 523
Shahadot Hossain Sheikh, Ishtiaq Alam, Monoarul Islam Talukdar, Tamonas Chaudhuri

29. **Disorders of Pelvic Floor and Obstructed Defecation Syndrome** 563
Brij B Agarwal, Roy V Patankar

30. **Constipation, Functional Bowel Disorders, and Irritable Bowel Syndrome** 580
Uday C Ghoshal, Akash Mathur

31. **Rectal Prolapse** 591
Prajesh Bhuta, Paresh Jain

32. Fecal Incontinence 605
Francis Seow-Choen

33. Pediatric Colorectal Disorders 636
Kishore Adyanthaya, Ravindra Ramadwar, Amrish S Vaidya

34. Complications in Colorectal Surgery 652
Ashok Kumar, Kailash C Kurdia

35. Setting Up of Colorectal Clinic and Examination of an Anorectal Patient 675
KS Mayilvaganan, Sanjay K Singla

Index 689

Chapter 2

Physiology of Colon, Rectum, and Anus

Jayanthi Venkataraman, Mayank Jain, Umamakeswari Venkatesa, Melpakkam Srinivas

JAYPEE BROTHERS

INTRODUCTION

In the physiological environment, the colon has several important functions. These include absorption of water and electrolytes. It also propels the postdigestive residue in the lumen, toward the rectum for its expulsion. The caecum and ascending colon absorb the water present in the effluent in the terminal ileum. The resulting molasses are pushed by the strong muscular activity of the ascending and transverse colon and then molded into sausage-shaped mass via peristalsis in the descending and sigmoid colon. Thus, the final product entering the rectum is soft and thin enough to be expelled easily through the anal sphincter. Anatomically, the proximal segment mixes and stores the digested contents, whereas the distal segment serves as a conduit for propelling the feces toward the rectum. The entire coordinated movement of the colon ultimately revolves around the maintenance of the contiguity of the colon with the small intestine.

Anatomical or biochemical disturbances at any stage disrupt the defecatory process and may result in diarrhea or constipation. Unless one understands the pathophysiological cause of the problem, supported with appropriate investigations, treatment is, at best, a matter of chance.

PHYSIOLOGICAL FUNCTION OF THE COLON

The three major properties of colon are absorption, secretion, and propagation/propulsive action (motor). These processes are dictated by biochemical and physical pathways that are controlled by both extrinsic and intrinsic nerve systems. In this chapter, we highlight the physiological functions, particularly those related to secretion/absorption and motility of the colon, and anorectal physiology and thereafter extrapolate this information toward bench-side patient care.

Absorptive and Secretory Function

On an average, 80% of the water is absorbed by the small intestine (isotonic mechanism) and 20% by the colon (osmotic gradient). Of the 1,500 mL of semisolid contents that cross the ileocecal valve, the proximal colon absorbs most of the water and electrolytes, largely mediated by neurotransmitters, and <100 mL of fluid is finally eliminated with the feces.

An important secretory function of the goblet cells lining the colon is production of mucus that is constituted by large, highly glycosylated proteins called mucins.[1] The mucus protects the colonic epithelial layer from direct injury by bacteria and the luminal acid; the mucin also lubricates the feces for easy expulsion. It also serves as a nutrient source for intestinal bacteria; its utilization results in synthesis of short-chain fatty acids (acetate, propionate, and butyrate) that serve as an energy source for the colonocyte.[2] There are two types of mucin, i.e., sialomucin and sulfomucin. These are present in different proportions in colon cancer and inflammatory bowel disease. Variation in sialomucin and sulfomucin content influences microbial colonization. A recent study found mucin 2 (MUC2) and mucin 5AC (MUC5AC) to be expressed in colonic cancers; the former had mild-to-moderate expression and the latter moderate-to-intense expression. The expression was more in mucinous adenocarcinoma[3] compared to normal colonic mucosa.

Motor Functions of the Colon

Colonic motor activity involves coordination of ileal, colonic, and anorectal motility and is regulated by central and peripheral pathways.[4] The motor function is complex

and depends on an intimate interplay between the enteric ganglia and the non-neural interstitial cells of Cajal (ICCs), the pacemaker cells of the colon. These ICCs generate spontaneous electrical slow waves of rhythmic smooth muscle contractions within the colonic wall and also transmit signals from enteric neurons to smooth muscle cells of the gastrointestinal tract.[5]

The contractile activity of the colon includes the following:

- *Segmentation:* These nonpropagating low-amplitude contractions that have to and fro movements represent 80% of the overall colonic motor activity. Different segments of the colon contract randomly at different times with no apparent relationship between each other. These movements effectively help in mixing intraluminal contents and also cause maximal absorption.
- *Propagated/propulsive activity:* This activity is caused by random segmental contractions of two types. The first one is low-amplitude propagating contractions (LAPCs) (also known as rhythmic phasic contractions), which are the most frequent propagated waves occurring up to >120 times per day, with an amplitude of <50 mm Hg, moving short distances of about 20 cm, and transporting liquids and gas.[6,7] The second propulsive contractile activity is forceful high-amplitude or giant migrating propagating contractions (HAPCs), which are waves that start in the proximal colon and move aborally; they are responsible for mass movement of large amounts of intraluminal colonic contents through creating a right-left pressure gradient toward the rectum,[8] which in turn relaxes and serves as the receiving segment. This is the most common movement after waking up in the morning and after the first meal, i.e., breakfast, and gets initiated within 1–3 minutes of ingestion of food and lasts for 2–3 hours. This physiological colonic response to food manifests as increased gastrocolic reflex (intestinal hurry soon after a meal). HAPCs have a higher average amplitude, of about 100 mm Hg,[9-11] and are less frequent than the LAPCs.

  The regulatory mechanism underlying LAPCs and HAPCs remains unclear. Few factors that are known to stimulate HAPCs include viscoelastic properties of the colon, the differential diameter of the lumen, physical exercise, food rich in fat and carbohydrate, and nonfermented starch in the colon. Other mediators include peptides (gastrin, neurotensin, and cholecystokinin), prostaglandin, vagal, and serotoninergic pathways.
- *Circadian rhythm of colonic contractility:* Colonic movement is maximal during the day and least in the evenings, night, and during sleep. It is therefore not surprising that patients with irritable gut syndrome predominantly have increased bowel frequency during the day and settle down by evening with no symptoms at night. Nocturnal symptoms of increased bowel frequency indicate a deranged colonic contractility and herald an organic disease.

CONTINENCE AND DEFECATION

Both acts of continence and defecation depend on a subtle interplay of structural and functional components of the pelvic floor.[12] The rectum serves as a reservoir and stores the intraluminal residue until the desire to defecate arises.[13] Normally, the anorectal angle is maintained at approximately 90–110° with the anal sphincter contracted, providing an airtight seal, except when the subject consciously wants to defecate or pass flatus.[14]

The control on the defecation process is dependent on outlet resistance, resting pressure generated by the pelvic musculature, rectal capacitance, its compliance, and intraluminal contents. The resting pressure is generated largely by the internal sphincter (50–80%) and combination of tonic contraction of the puborectalis musculature and external anal sphincter (20%). The internal sphincter relaxes intermittently to allow descent of rectal contents into its upper portion and, based on the nature of the contents (solid, liquid, or gas), the rectum distinguishes these and responds by what is referred to as a sampling reflex.

Normal Defecation Process

During the defecation process,[15] there occurs simultaneous colonic propulsive activity (HAPCs), increase in intrarectal pressure, relaxation of the pelvic floor and puborectalis muscle, straightening of the anorectal angle, and involuntary relaxation of the anal sphincter with contraction of the external sphincter (the rectoanal inhibitory reflex).[13,16] The external sphincter cannot sustain the incremental squeeze pressure for more than a minute, and sphincter relaxation occurs along with reduction in anal canal pressure, resulting in expulsion of either gas, liquid, or solid feces (the expulsive phase). Apart from the physiological contractions and relaxations of the sphincters, voluntary straining by the Valsalva maneuver results in contraction of the diaphragm and

JAYPEE BROTHERS

abdominal wall muscles, thereby causing an increase in the intra-abdominal and intrarectal pressures at the suitable defecation posture.[17] Tightening of iliococcygeus muscles stabilizes the levator plate to counterbalance the intra-abdominal push. The anal sphincters and puborectalis muscle relax simultaneously. The resulting inversion of the pressure gradient between the rectum and anal canal allows stool evacuation. If defecation is deferred voluntarily, external sphincter and puborectalis muscles contract with an increase in outlet resistance, and rectum accommodates more stool.[13] In brief, the defecation process involves four phases, i.e., the basal phase, pre-expulsive phase, expulsive phase, and termination of defecation.[15] The entire act of defecation is controlled by central (cerebral) and peripheral (corticorectal) stimuli.

Fecal Incontinence and Obstructive Defecation Syndrome

Fecal incontinence occurs when any of the three core components of defecation process, namely, stool consistency (diarrhea), intactness of sphincter complex (postpartum perineal tear, post-traumatic, etc.), and rectal compliance (proctitis), is distorted.[18] Conversely, in the absence or diminished defecatory reflex (neurological causes such as parkinsonism), loss of urge to defecate, pelvic organ malposition, prolapse of pelvic organs, or functional problem (pelvic floor dyssynergia) results in obstructed defecation syndrome, which responds to biofeedback therapy. In long-standing cases, patients develop chronic pelvic pain with tenderness of levator ani on digital rectal examination (DRE).

In summary, the colonic physiology, although described as a distinct complex phenomenon, is mostly integrated with great intricacies and regulated by higher cerebral centers to deliver only one outcome, i.e., expulsion of postdigestive residual content.

INVESTIGATING PHYSIOLOGICAL DERANGEMENT OF THE COLON

Diarrhea may occur due to numerous causes, ranging from structural and functional issues of the small and large intestines, which can be evaluated by laboratory investigations, endoscopy, imaging, and histopathology. Further, various systemic (nongastrointestinal) conditions such as hyperthyroidism, diabetes mellitus, and drug effects need to be considered.

Once systemic causes such as hypothyroidism, hypercalcemia, and drug effects are excluded, constipation is almost always due to colonic issues such as anatomical luminal narrowing, colonic hypomotility, or issues with anal sphincter or pelvic floor. Except for the initial colonoscopy to exclude luminal structural problems such as any growth/stricture, all other investigations are directed to assess colonic function.

Digital Rectal Examination

Digital rectal examination is the first and foremost test conducted for assessing functional defecation disorder. Sequentially, it involves (1) palpation for tenderness, mass, stricture, and presence of stool; (2) resting anal tone assessment; (3) squeeze evaluation for 30 seconds for intensity and sustainability; and (4) perineal descent. The anal margin lies just below a line drawn between the tip of the coccyx and the pubic symphysis. In descending perineum syndrome, the anal canal is situated several centimeters below this imaginary line or it descends 3–4 cm during straining. Defecography confirms abnormal perineal descent.[19] DRE is a reliable test to detect pelvic floor dyssynergia and facilitates selection of patients for anorectal manometry (ARM);[19,20] it has high specificity (81.5%) and positive predictive value (PPV) (82.1%).[21,22] Studies have shown a good positive correlation between DRE and ARM for both chronic constipation and fecal incontinence.[20,23]

Physiological Tests

These determine the functional capacity of the colon and rectum. Tests include *sitz marker study*, wherein radio-opaque markers are used for determining normal transit of the colon; the use of *wireless motility capsule* to assess regional and whole gut transit time; *assessment of the frequency and amplitude of contraction* at various levels of the gastrointestinal tract including the colon; and *ARM*. MRI defecography provides additional information on structural changes in the anorectum and gives a clue to identify the cause of obstructive defecatory syndrome.

Colon Marker Transit Study

This simple test correlates well with other modalities to evaluate transit time, such as scintigraphy,[24] helps assess the propulsive capacity of the colon and the interplay between the rectum and pelvic floor muscles for effective rectal emptying. The subject is asked to swallow capsules

JAYPEE BROTHERS

containing a specific number of radio-opaque markers, which can be seen on a simple plain abdominal radiograph **(Figs. 1A to D)**. The choice of marker and the number and time interval for taking radiographs vary among centers. Few studies give one set of markers and take a radiograph at a fixed time to assess marker distribution in various parts of the colon. In another protocol called the "shape study", different shape markers (e.g., round, triangle, and star) are given on 3 consecutive days and radiographs are taken at various intervals ranging from 48 hours to 10 days. Normal colon transit time ranges between 20 and 56 hours, with most adults clearing the markers in 4–5 days.[24] A previous study from southern India reported whole gut transit time of 25 hours in healthy volunteers.[25] In view of the rapid transit times in Indians, it is recommended to administer 20 markers each at 0, 12, and 24 hours followed by radiography at 36 hours from Day 0. For interpretation,[26] the plain radiograph of the abdomen is divided into three quadrants by using bony landmarks.[27] Presence of <20% markers on the film is deemed normal. Based on the distribution of markers in the three segments, colonic transit is categorized as slow transit (several markers in right/left colon), normal transit, dyssynergic defecation disorder (several markers in rectum/rectosigmoid region), or a combination of slow transit with evacuation disorder.

Anorectal Manometry

Anorectal manometry helps in the evaluation of dyssynergy between the rectum, anal sphincters, and the pelvic floor, resulting in obstructive defecation. It is indicated in patients with symptoms suggestive of ineffective defecation or fecal incontinence (due to internal or external anal sphincter damage) or high marker count in the rectosigmoid region on the transit study. The test is also used to exclude Hirschsprung disease as evidenced by absent rectoanal inhibitory reflex. Early rectal fullness with an inflated balloon suggests irritable bowel syndrome or rectal hypersensitivity. Delayed or no rectal filling sensation suggests megarectum, commonly due to habitual chronic constipation. A delayed balloon expulsion test suggests pelvic floor dyssynergy, loss of rectal compliance, or anatomical conditions, which require further evaluation.

The disturbed interplay between rectum, anal sphincter, and pelvic muscles is a major cause of obstructive or dyssynergic defecation. This is assessed using the push maneuver during ARM. Dyssynergic defecation is classified into four types based on the rectal and anal pressures during simulated defecation **(Fig. 2)**. Effective push is depicted by high rectal pressure and low anal pressure. Adequate rectal pressures with paradoxical raised anal pressure or inadequate anal relaxation are called dyssynergic defecation types 1 and 3, respectively. Inadequate rectal pressures with paradoxical raised anal pressure or inadequate anal relaxation are called dyssynergic defecation types 2 and 4, respectively.

A patient with dyssynergic defecation with or without delayed balloon expulsion needs further evaluation with magnetic resonance defecography to delineate issues such as rectocele (bulge of the anterior rectal wall

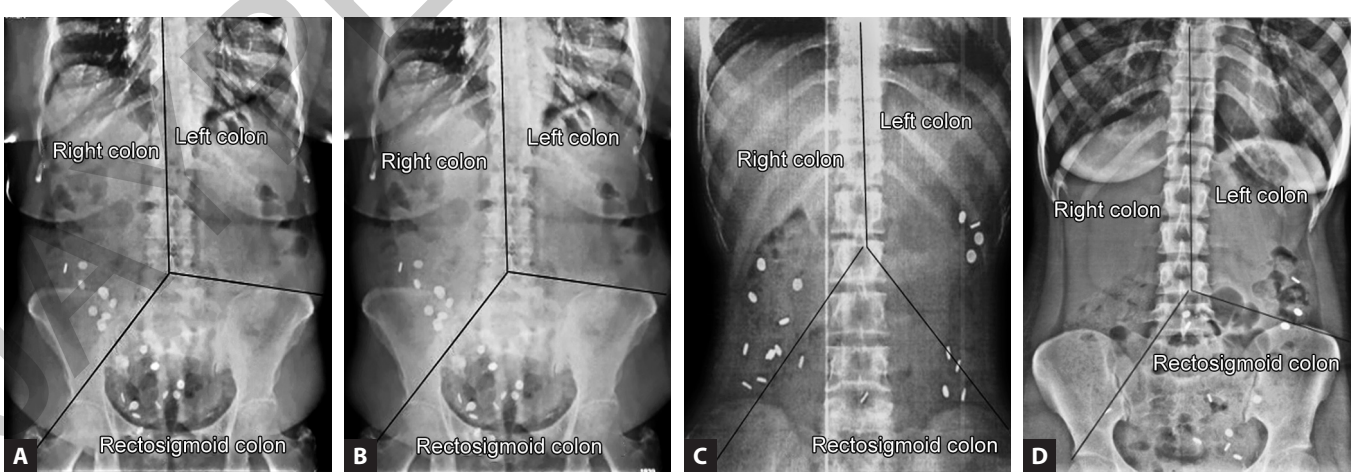

Figs. 1A to D: Sitz marker study showing markers in all the three segments indicating a combined colonic slow transit and an evacuation disorder. (A, B and D) Slow transit in combination with fecal evacuation disorder; (C) Slow transit constipation.

JAYPEE BROTHERS

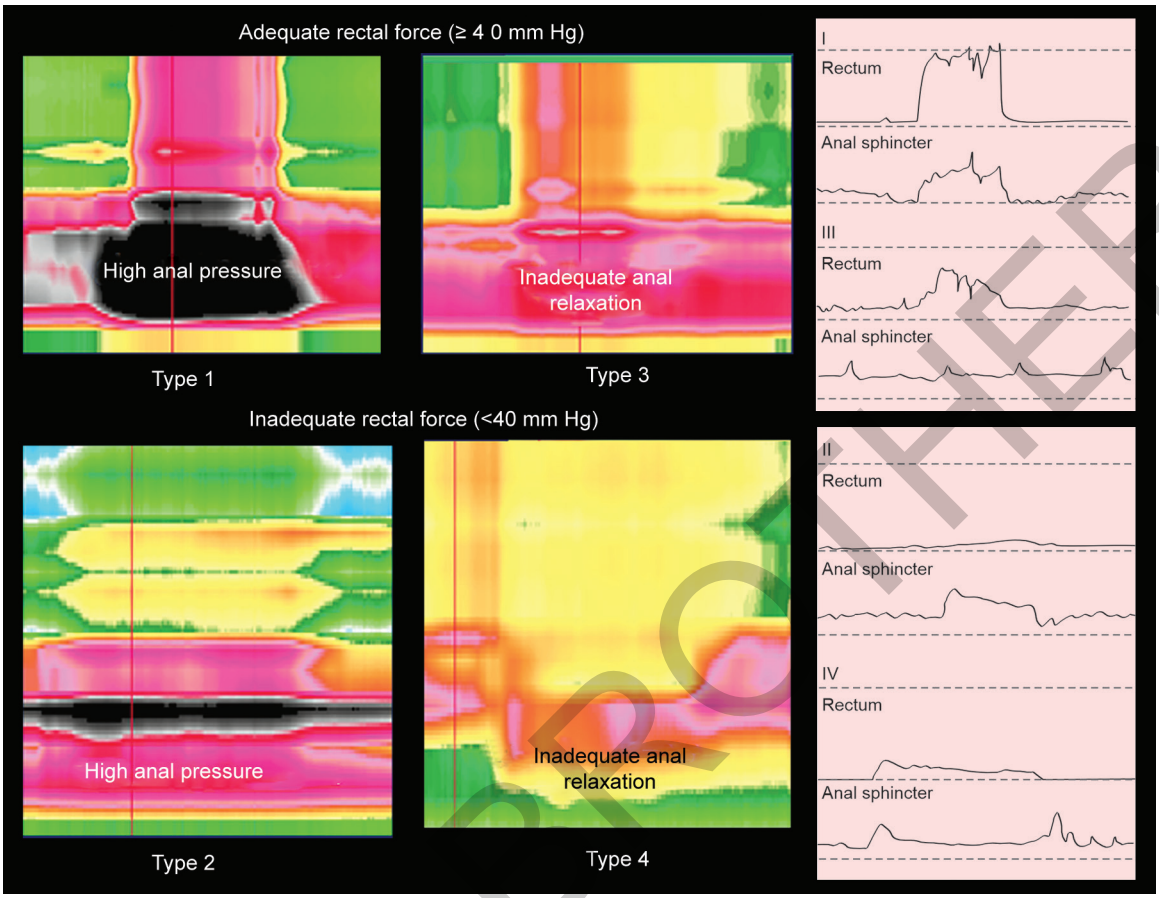

Fig. 2: Types of dyssynergia.

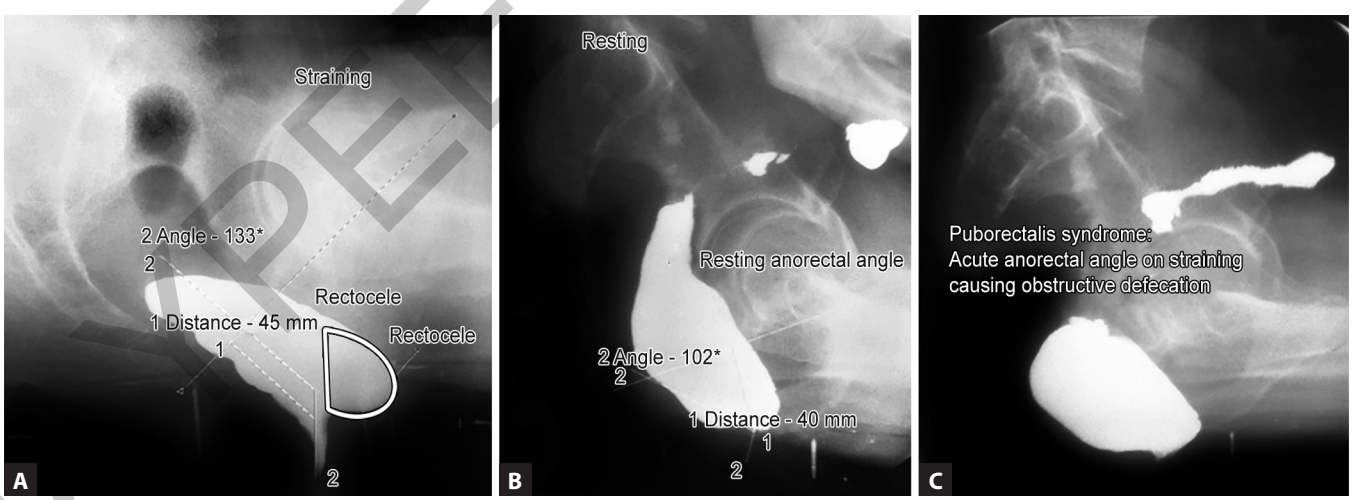

Figs. 3A to C: Magnetic resonance defecography.

>20–30 mm) or puborectalis sling dysfunction (anorectal angle becomes more acute, instead of its almost 180°, resulting in obstructive defecation) **(Figs. 3A to C)**.

Based on the findings of these tests, various combinations of pharmacotherapy (bulk or polyethylene glycol laxatives in slow transit constipation or bisacodyl

JAYPEE BROTHERS

Flowchart 1: Evaluation of patients with fecal evacuation disorder.

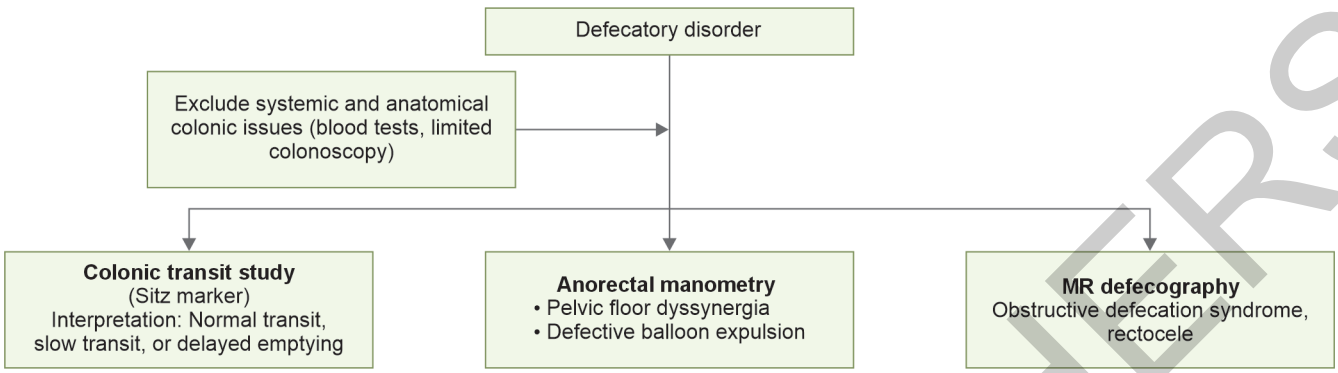

suppository in obstructive defecation) and biofeedback (appropriate exercises depending on type of dyssynergic defecation)[28] are used to optimize relief of symptoms. Surgery is reserved only for patients with structural problems such as rectal prolapse/intussusception or rectocele.

Understanding the physiological basis of fecal evacuation disorders and systematic workup **(Flowchart 1)** with the aforementioned tests is essential to tailor therapy appropriately for effective and mutually satisfactory (patient and treating physician) outcomes.

REFERENCES

1. McGuckin MA, Linden SK, Sutton P, Florin TH. Mucin dynamics and enteric pathogens. Nat Rev Microbiol. 2011;9:265-78.
2. Wong JM, de Souza R, Kendall CW, Emam A, Jenkins DJ. Colonic health: fermentation and short chain fatty acids. J Clin Gastroenterol. 2006;40:235-43.
3. Jayanth R, Devaraj H, Surendran R, Jain M, Venkataraman J. MUC2 and MUC5AC expression in colon cancer: a preliminary report from South India. Indian J Med Paediatr Oncol. 2019;40:402-5.
4. Brookes SJ, Dinning PG, Gladman MA. Neuroanatomy and physiology of colorectal function and defaecation: from basic science to human clinical studies. Neurogastroenterol Motil. 2009;21(Suppl 2):9-19.
5. Klein S, Seidler B, Kettenberger A, Sibaev A, Rohn M, Feil R, et al. Interstitial cells of Cajal integrate excitatory and inhibitory neurotransmission with intestinal slow-wave activity. Nat Commun. 2013;4:1630.
6. Bassotti G, Clementi M, Antonelli E, Pelli MA, Tononi M. Low amplitude propagated contract waves: a relevant propulsive mechanism of human colon. Dig Liv Dis. 2001;33:36-40.
7. Rao SS, Sadeghi P, Beaty J, Kavlock R, Ackerson K. Ambulatory 24-h colonic manometry in healthy humans. Am J Physiol Gastrointest Liver Physiol. 2001;280:G629-39.
8. Bassotti G, Crowell MD, Whitehead WE. Contractile activity of the human colon: lessons from 24 hour studies. Gut. 1993;34:129-33.
9. Bharucha AE. High amplitude propagated contractions. Neurogastroenterol Motil. 2012;24:977-82.
10. De Schryver AM, Samsom M, Smout AJ. In search of objective manometric criteria for colonic high amplitude propagated high pressure waves. Neurogastroenterol Motil. 2002;14:375-81.
11. Bassotti G, Betti C, Fusaro C, Morelli A. Colonic high amplitude propagated contractions (mass movements): repeated 24 h-studies in healthy volunteers. J Gastrointest Mot. 1992;4:157-91.
12. Kaiser AM, Ortega AE. Anorectal anatomy. Surg Clin North Am. 2002;82:1125-38.
13. Thorson AG. Anorectal physiology. Surg Clin North Am. 2002;82:1115-23.
14. Bassotti G, Germani U, Morelli A. Flatus-related colorectal and anal motor events. Dig Dis Sci. 1996;41:335-8.
15. Palit S, Lunniss PJ, Scott SM. The physiology of human defecation. Dig Dis Sci. 2012;15:1445-64.
16. Bharucha AE. Update of tests of colon and rectal structure and function. J Clin Gastroenterol. 2006;40:96-103.
17. Petros PE, Swash M. The musculoelastic theory of anorectal function and dysfunction. Pelviperineology. 2008;27:89-93.
18. Rasmussen OO. Anorectal function. Dis colon Rectum. 1994;37:386-403.
19. Tantiphlachiva K, Rao P, Attaluri A, Rao SSC. Digital rectal examination is a useful tool for identifying patients with dyssynergia. Clin Gastroenterol Hepatol. 2010;8:955-60.
20. Soh JS, Lee HJ, Jung KW, Yoon IJ, Koo HS, Seo SY, et al. The diagnostic value of a digital rectal examination compared with high-resolution anorectal manometry in patients

JAYPEE BROTHERS

with chronic constipation and fecal incontinence. Am J Gastroenterol. 2015;110:1197-204.
21. Jain M. Digital rectal examination—A reliable screening tool for dyssynergic defecation. Indian J Gastroenterol. 2018;37:176-7.
22. Jain M. Digital rectal examination compared to anorectal manometry in evaluation of fecal incontinence. Trop Gastroenterol. 2021;42(3):148-9.
23. Orkin BA, Sinykin SB, Lloyd PC. The digital rectal examination scoring system (DRESS). Dis Colon Rectum. 2010;53:1656-60.
24. Southwell BR, Clarke MC, Sutcliffe J, Hutson JM. Colonic transit studies: normal values for adults and children with comparison of radiological and scintigraphic methods. Pediatr Surg Int. 2009;25:559-72.
25. Jayanthi V, Chacko A, Gani IK, Mathan VI. Intestinal transit in healthy southern Indian subjects and in patients with tropical sprue. Gut. 1989;30:35-8.
26. Bhate PA, Patel JA, Parikh P, Ingle MA, Phadke A, Sawant PD. Total and segmental colon transit time study in functional constipation: comparison with healthy subjects. Gastroenterology Res. 2015;8:157-9.
27. Arhan P, Devroede G, Jehannin B, Lanza M, Faverdin C, Dornic C, et al. Segmental colonic transit time. Dis Colon Rectum. 1981;24:625-9.
28. Venkatesa U, Srinivas M, Jain M, Venkataraman J. Pelvic floor physiotherapy rehabilitation for dyssynergic defecation: An approach tailored to an Indian setting. Gastroenterol Hepatol Endosc Pract. 2021;1(2):82.

JAYPEE BROTHERS

etailed information on surgery books, visit our website www.jaypeebrothers.com, for detailed information on surgery books, visit our website www.jaype

ACRSI
TEXTBOOK OF COLORECTAL SURGERY

Salient Features

- *ACRSI Textbook of Colorectal Surgery* is the first textbook of its kind from India on the subject of colorectal surgery
- It is a comprehensive book which can serve as a study material as well as a reference book for surgeons interested in colorectal surgery. It comprehensively covers all the aspects of colorectal surgery from basics such as anatomy, physiology, radiology to cancers of colon and rectum
- It would be useful for General Surgeons, Surgical Gastroenterologists both practicing as well as trainee Surgeons
- The authors of each chapter have been carefully chosen and have wide experience in their respective fields.

Niranjan Agarwal MS DNB FACRSI is Consultant Surgeon, Bombay Hospital, Mumbai and Chief Surgeon, Salasar Nursing Home, Thane, Maharashtra, India. He is the Past President of the Association of Colon and Rectal Surgeons of India (ACRSI). He is a Member from India on the International Society of University Colon and Rectal Surgeons. He has organized many national and international conferences on colorectal surgery. He has a vast experience in various aspects of Coloproctology.

Pradeep P Sharma MS MNAMS DNB FACRSI FIAGES FALS PGTM (Israel) is a Senior Consultant Surgeon, Purunanda Clinic (Laparoscopy and Lasers) and Jehangir Hospital and Medical Centre, Pune, Maharashtra, India. He is the President of the Association of Colon and Rectal Surgeons of India (ACRSI) (2023–2025). He is a Member from India on the International Society of University Colon and Rectal Surgeons.

Parvez Sheikh MS FACRSI is Senior Consultant and Head, Department of Colorectal Surgery, Saifee Hospital, Mumbai, Maharashtra, India. He has been the Past President of the Association of Colon and Rectal Surgeons of India (ACRSI) and the Asian Federation of Coloproctology (AFCP).

Printed in India

Available at all medical bookstores
or buy online at www.jaypeebrothers.com

JAYPEE BROTHERS
Medical Publishers (P) Ltd.
EMCA House, 23/23-B, Ansari Road,
Daryaganj, New Delhi - 110 002, INDIA
www.jaypeebrothers.com

Join us on facebook.com/JaypeeMedicalPublishers

Shelving Recommendation
SURGERY

ISBN 978-93-5696-396-2