rothers.com, for detailed information on orthopedics books, visit our website www.jaypeebrothers.com, for detailed information on orthopedics books

An Official Publication of Trauma Society of India

Guidelines in Fracture Management

Fracture of Neck of the Femur



Series Editors
GS Kulkarni
Sushrut Babhulkar

Volume Editor
SC Goel

JAYPEE

Contents

List of Contributors v

Note from the Series Editors vii

Note from the Volume Editor ix

CHAPTER 1: Anatomy and Biomechanics of Hip **1**
Rajiv Chatterjee

CHAPTER 2: Classification **14**
SC Goel

CHAPTER 3: Clinical Evaluation **23**
Jake Spencer, Richard S Yoon, Frank A Liporace

CHAPTER 4: Femoral Neck Fractures in Children **31**
Sandeep Patwardhan, Shivan Marya

CHAPTER 5: Treatment of Femoral Neck Fractures **46**
Jake Spencer, Richard S Yoon, Frank A Liporace

CHAPTER 6: Reduction and Fixation by Cannulated Cancellous Screws **59**
SC Goel

CHAPTER 7: Dynamic Hip Screw in Femoral Neck Fractures **78**
Ulrich E Holz

CHAPTER 8: Ipsilateral Femoral Neck and Shaft Fracture **91**
Sudhir Babhulkar

CHAPTER 9: Arthroplasty in Fracture Neck Femur **104**
Sushrut Babhulkar

CHAPTER 10: Stress and Pathological Fractures of Neck of the Femur **123**
Alok C Agrawal, Roop Bhushan Kalia

CHAPTER 11: Nonunion Femoral Neck Fracture—Management **136**
SC Goel

CHAPTER 12: Muscle Pedicle Bone Graft in Nonunion of Femoral Neck Fracture 146
SC Goel

CHAPTER 13: Nonunion of Fracture Neck of Femur: Valgus Osteotomy 154
NK Magu, Amit Batra

CHAPTER 14: Fibular Grafting in Nonunion of Fracture Neck Femur 168
Sujit Kumar Tripathy, Ramesh Kumar Sen

CHAPTER 15: Avascular Necrosis 184
SC Goel

Index 195

2 CHAPTER

Classification

SC Goel

- Introduction
- Pauwels Classification
- Garden Classification
- AO Classification



INTRODUCTION

A good classification system should be a guide to treatment and facilitate the comparison of results. It must also have good intra- and inter-observer reliability. Many classification systems have been described for intracapsular fractures of the proximal femur, but none has been shown to be practical with satisfactory reproducibility and accurate predictive value.

Fracture of neck of the femur can be classified according to the anatomical site **(Fig. 1)**:

- Subcapital **(Fig. 2)**
- Transcervical **(Fig. 3)**
- Basal **(Fig. 4)**

JAYPEE BROTHERS

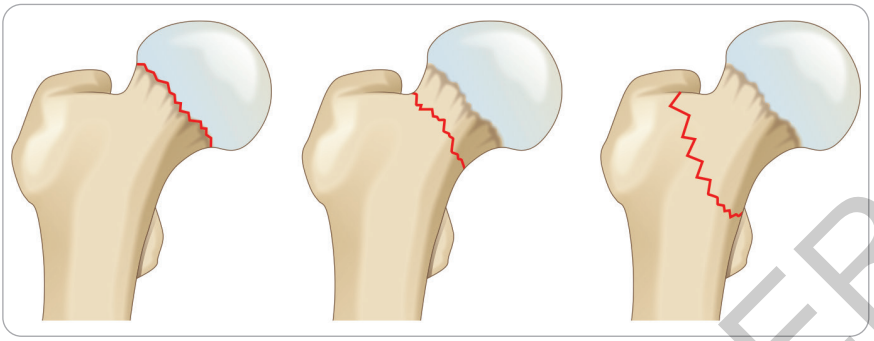

FIG. 1: Anatomical classification.

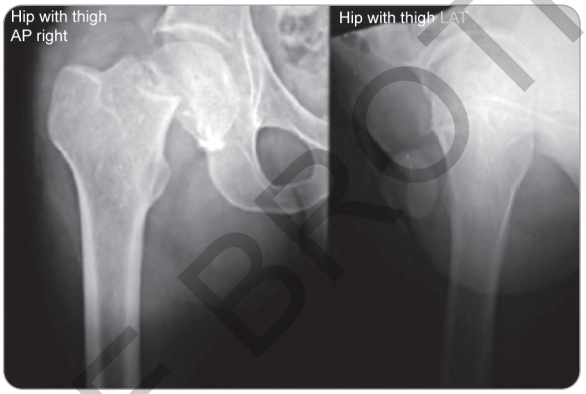

FIG. 2: Subcapital fracture.
(AP: anteroposterior; LAT: lateral)



FIG. 3: Transcervical fracture.

JAYPEE BROTHERS



FIG. 4: Basal fracture.

Subcapital fractures occur immediately beneath the articular surface of the femoral head along the old epiphyseal plate. Transcervical fractures pass across the femoral neck between the femoral head and the greater trochanter. Many authors have questioned the transcervical fracture and are of the view that all fractures are subcapital.[1] Basal or basicervical type is partially extracapsular and has a different treatment protocol.

PAUWELS CLASSIFICATION

Pauwels classification[2] is based on the angle of the fracture line with the femoral shaft with the premise that a higher-angle fracture has a poor prognosis. The theoretical principle behind this classification is that fractures with a more vertical orientation experience more shear than horizontal fractures, which primarily experience compression with loading. As the fracture orientation becomes more vertical joint, reaction forces tend to shear than compress the fracture, leading to healing problems and hardware failures.

Based on the angle of inclination (Pauwels angle), fractures of the neck of the femur can be of three types:
(Figs. 5 to 8).

- *Pauwels Type I*: Fracture line < 30°
- *Pauwels Type II*: Fracture line between 30° and 50°
- *Pauwels Type III*: Fracture line > 70°

Pauwels angle has been controversial, and it is believed that at different degrees of rotation, the same fracture line may appear to change. Neither the Pauwels angle nor the classification had any predictive value for the incidence of nonunion.[3,4]

JAYPEE BROTHERS

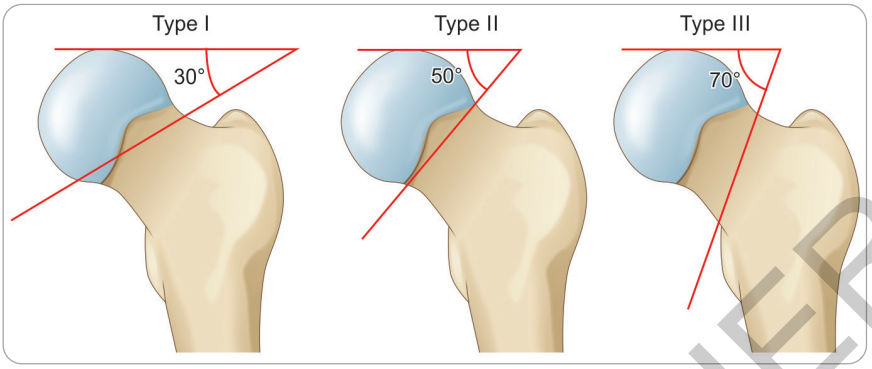

FIG. 5: Pauwels classification.

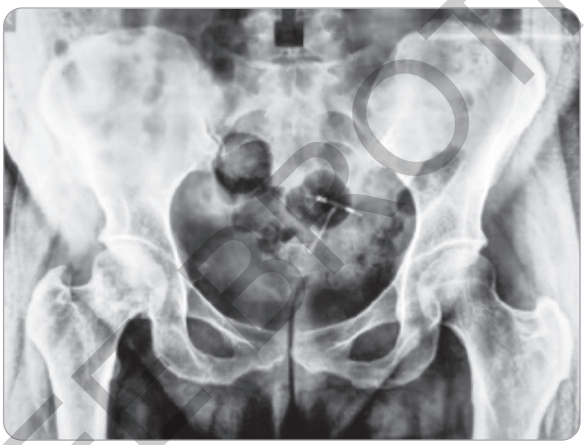

FIG. 6: Pauwels Type I fracture of the neck of femur.



FIG. 7: Pauwels Type II fracture of the neck of femur.

JAYPEE BROTHERS

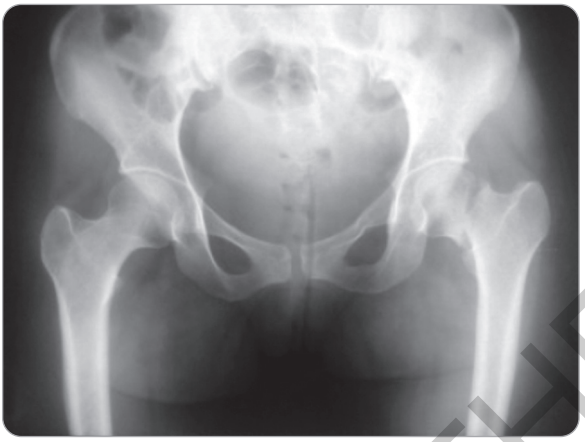

FIG. 8: Pauwels Type III fracture of the neck of femur.

GARDEN CLASSIFICATION

Garden[5] categorized femoral neck fractures into four groups using the degree of displacement or impaction. He classified the fracture on the principle that fracture starts in the superior cortex and the amount of damage to the strong retinaculum of Weitbrecht in the posterior capsule increases morbidity. He agreed that various types of subcapital fractures are in fact different degrees of displacements of a single fracture type **(Fig. 9)**. Garden Type I was described as undisplaced incomplete fracture, including valgus-impacted fractures **(Fig. 10)**. Type II is undisplaced complete fracture **(Fig. 11)**. Complete fracture that is incompletely displaced is classified as

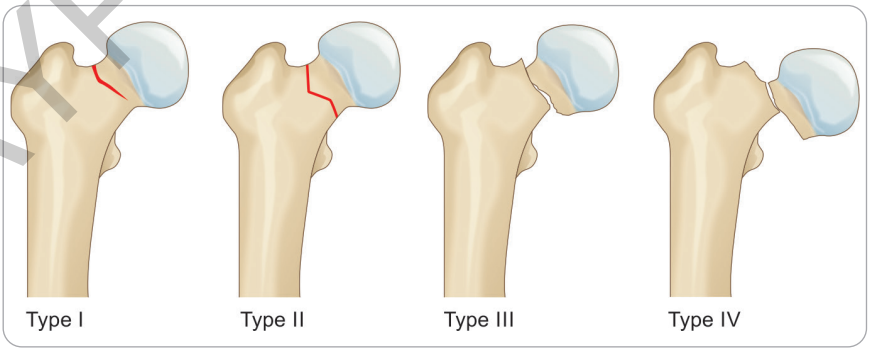

FIG. 9: Garden classification.

JAYPEE BROTHERS



FIG. 10: Garden Type I fracture.

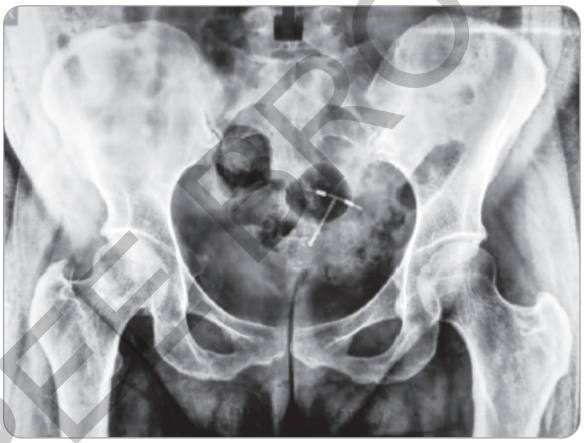

FIG. 11: Garden Type II fracture.

Type III **(Fig. 12)**, whereas Type IV **(Fig. 13)** is a complete fracture, completely displaced, and has a worse prognosis for healing and osteonecrosis. **Table 1** shows the Garden classification.

There is much controversy regarding Garden classification as there is significant intra- and inter-observer variation.[6,7] There is an improvement in interobserver agreement (from fair to moderate) on Garden classification and slight improvement in interobserver agreement on management plan when a lateral view is added to the anteroposterior (AP) view.[8] Chen et al.[9] have postulated that Garden Type I is a myth, and on computed tomography (CT) scan, all Garden I are actually Garden II fractures.

JAYPEE BROTHERS



FIG. 12: Garden Type III fracture.



FIG. 13: Garden Type IV fracture.

TABLE 1: Garden classification.

Types	Description
I	Stable fracture with impaction in valgus
II	Complete but nondisplaced
III	Partially displaced with varus displacement but with contact between the two fragments
IV	Completely displaced with no contact between the fracture fragments

AO CLASSIFICATION

The AO classification of intracapsular fractures of the hip is the most complex system **(Fig. 14)**. It is based on a combination of the level of the fracture, the degree of displacement, and the angle of the fracture line. It includes

JAYPEE BROTHERS

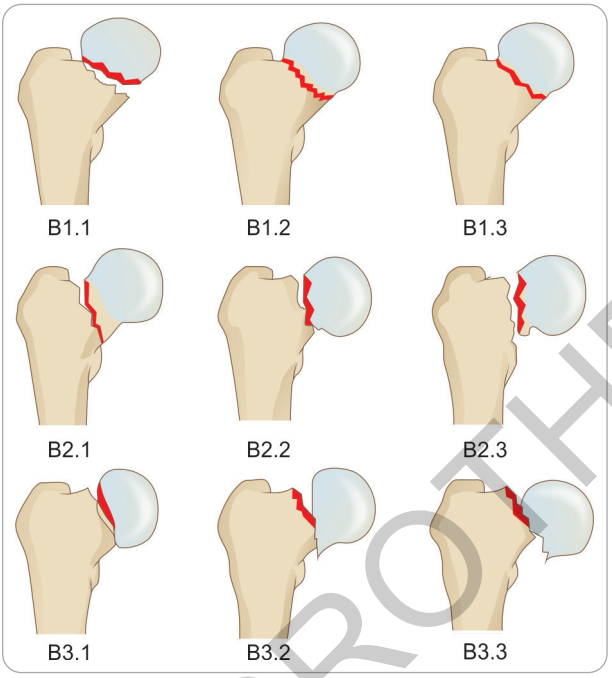

FIG. 14: AO classification of the fracture of the neck of femur.

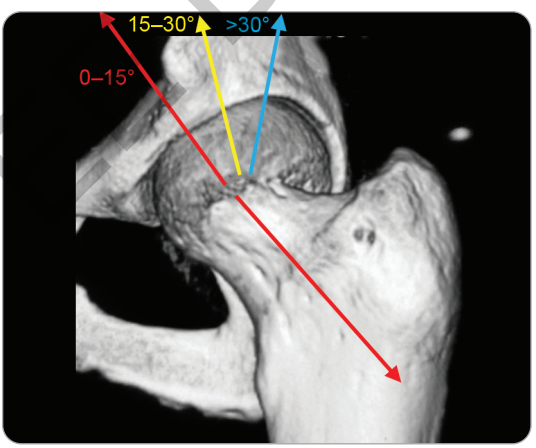

FIG. 15: Degree of posterior tilt.

basicervical or basal fractures. A simplified system based on the three main groups of the AO system is of value.

All these classifications lack reliability and reproducibility and have a high degree of intra- and inter-observer error and inaccuracy. None of them takes care of posterior tilt which is an important parameter and has impact on reduction and further management **(Fig. 15)**. To overcome this problem,

JAYPEE BROTHERS

it has been suggested that intracapsular fractures should be classified simply as either *displaced* or *undisplaced*. This simplified classification has a much higher rate of inter- and intra-observer reliability and predicts the method of treatment and the rate of nonunion more effectively.[7,10]

REFERENCES

1. Klenerman L, Marcuson RW. Intracapsular fractures of the neck of the femur. J Bone Joint Surg Br. 1970;52(3):514-7.
2. Pauwels F (Aachen). Der schenkelhalsbruch: Ein mechanisches Problem. Stuttgart: Ferdinand Enke; 1935.
3. Parker MJ, Dynan Y. Is Pauwels classification still valid? Injury. 1998;29:521-3.
4. van Embden D, Roukema GR, Rhemrev SJ, Genelin F, Meylaerts SA. The Pauwels classification for intracapsular hip fractures: Is it reliable? Injury. 2011;42(11):1238-40.
5. Garden RS. Low-angle fixation in fractures of the femoral neck. J Bone Joint Surg. 1961;43 B:647-63.
6. Zlowodzki M, Bhandari M, Keel M, Hanson BP, Schemitsch E. Perception of Garden's classification for femoral neck fractures: An international survey of 298 orthopaedic trauma surgeons. Arch Orthop Trauma Surg. 2005;125:503-5.
7. van Embden D, Rhemrev SJ, Genelin F, Meylaerts SA, Roukema GR. The reliability of a simplified Garden classification for intracapsular hip fractures. Orthop Traumatol Surg Res. 2012;98(4):405-8.
8. Aggarwal A, Singh M, Aggarwal AN, Bhatt S. Assessment of interobserver variation in Garden classification and management of fresh intracapsular femoral neck fracture in adults. Chin J Traumatol. 2014;17(2):99-102.
9. Chen W, Li Z, Su Y, Hou Z, Zhang Q, Zhang Y. Garden type I fractures myth or reality? A prospective study comparing CT scans with X-ray findings in Garden type I femoral neck fractures. Bone. 2012;51:929-32.
10. Blundell CM, Parker MJ, Pryor GA, Hopkinson-Woolley J, Bhonsle SS. Assessment of the AO classification of intracapsular fractures of the proximal Femur. J Bone Joint Surg. 1998;80-B:679-83.

JAYPEE BROTHERS

for detailed information on orthopedics books, visit our website www.jaypeebrothers.com, for detailed information on orthopedics books, visit our web

Guidelines in Fracture Management

Fracture of Neck of the Femur

Trauma Society of India is a pioneering initiative to promote knowledge in the fields of orthopedics and traumatology. The society took a giant leap in its endeavors by launching the first ever standard guidelines for orthopedic clinicians in 2014. These guidelines are meant to establish treatment protocols and provide a roadmap to clinicians for the assessment, decision-making, and management of complex fracture situations. The guidelines are being published in a series of books titled *Guidelines in Fracture Management*, compiled by eminent Indian and international clinicians. They illustrate all possible treatment options and latest management techniques that can be used, with special emphasis on the health scenario in the Asia–Pacific region.

The Second Edition has been brought with latest additions of newer knowledge and perspective.

Guidelines in Fracture Management—Fracture of Neck of the Femur discusses the anatomy, classification, and assessment of fracture patterns and treatment protocols pertaining to this area.

It also discusses in detail the management of complications such as nonunion and avascular necrosis.

Key Features of the Volume are:

- Provides a holistic view through chapters on various aspects of the condition, like anatomy, biomechanics, and classifications
- Highlights new management modalities along with traditional methods
- Includes insights of national and international Orthopedicians
- Explain management techniques for treating pediatric and geriatric groups too



GS Kulkarni MS(General Surgery) MS(Orthopedic) FRCS is a distinguished orthopaedician practicing for the last 50 years. He is the Chief Research Director of Swasthiyog Pratishthan Research Centre, Miraj, Maharashtra, India. He has treated over 1,000 case of nonunions, aseptic as well as infected, and is credited with devising techniques such as Miraj Nail for intertroch and subtroch fractures and the Ilizarov technique. He has been awarded the "Life Time Achievement Award" from Sancheti Institute of orthopaedics and Rehabilitation, Pune, India. He is also credited with authoring many acclaimed books.



Sushrut Babhulkar MS(Orthopedic) MCh(Orthopedic) (Liverpool, UK) a graduate and postgraduate from Nagpur, Maharashtra, India, further trained himself as a Trauma and Joint Replacement Surgeon at UK, USA, and Germany. After MCh (Orthopedic), he had extensive training at various places. Having decided to come back and join his roots in Nagpur, he also had the opportunity to get involved in training and teaching postgraduates since the last 18 years. He now enjoys the position of President, Trauma Society of India, and President of Interlocking Association and has to his credit more than 100 international and national publications. Been extensively traveled across the world, he demonstrates within himself an excellent blend of practical approach toward handling various levels of trauma situations.



SC Goel MS(Orthopedic) FAMS FICS Past President of the Trauma Society of India, is a Retired Professor of Orthopaedics, Institute of Medical Sciences, Banaras Hindu University, Varanasi, Uttar Pradesh, India. He received his training on arthroplasty and arthroscopy at Nuffield Orthopaedic Centre, Oxford University, UK, as a Girdlestone Scholar.

He has 36 years of teaching experience. Dr Goel has published 79 papers in various national and international journals and has written three books and contributed chapters in 11 books. He has been invited to deliver 18 orations, including Kini Oration and RJ Katrak Oration, and has also been invited to deliver 155 guest lectures. Dr Goel is the visiting professor at The Tamil Nadu Dr M.G.R. Medical University, Chennai, Tamil Nadu, India. He is the recipient of many national and international fellowships and is a Fellow of the National Academy of Medical Sciences. Dr Goel was the editor of Indian Journal of Orthopaedics from 2001 to 2006. In 2007–2008, he served as the President of Indian Orthopaedic Association.

Printed in India

Available at all medical bookstores
or buy online at www.jaypeebrothers.com

JAYPEE BROTHERS
Medical Publishers (P) Ltd.
EMCA House, 23/23-B, Ansari Road,
Daryaganj, New Delhi - 110 002, INDIA
www.jaypeebrothers.com

Join us on facebook.com/JaypeeMedicalPublishers

Shelving Recommendation
ORTHOPEDIC

ISBN 978-93-5696-477-8