nformation on medicine books, visit our website www.jaypeebrothers.com,for detailed information on medicine books, visit our website www.jaypeebrothers.com,



OSCEs in Medicine

A Primer for Postgraduate Students

Editors

Narinder Pal Singh • Jyotirmoy Pal

Associate Editors

Nandini Chatterjee
Amit A Saraf
Jayanta K Panda
PN Chaudhary
K Mugundhan

Technical Editor

Anish Kumar Gupta

1

JAYPEE

Contents

1. Infectious Diseases 1
2. Immunology 30
3. Rheumatology 42
4. Endocrinology 60
5. Diabetology 72
6. Hematology 87
7. Oncology 101
8. Nephrology 111
9. Cardiology 139
10. Gastroenterology 165
11. Hepatology 173
12. Neurology 181
13. Respiratory 261
14. Critical Care Medicine 279
15. Poisoning and Toxicology 286
16. Diagnostic Imaging 296
17. Dermatology 307
18. Medical Genetics 320
19. Psychiatry 330
20. Biostatistics 335
21. Test Yourself 341

Index *357*

SECTION 3

Rheumatology

QUESTIONS

Q1. A 35-year-old female presented with a fever of 102.2 for 1 week, arthralgia or arthritis lasting at least 2 weeks. She had the appearance of a pink or salmon-colored rash during fever spikes. She had an elevated white blood cell count (leukocytosis) and a negative antinuclear antibody (ANA) by immunofluorescence.

a. What diagnosis comes to your mind with the above presentation? *(3 marks)*
b. What further investigations would you carry out? *(4 marks)*
c. How would you manage? *(2 marks)*
d. Mention one recently approved drug in addition. *(1 mark)*

Q2. A 55-year-old female presented with swelling feet for 3 months. She had a long-standing history of rheumatoid arthritis (RA) diagnosed 20 years back. She tested positive 2+ for urine albumin to creatinine ratio (ACR).

a. What is the likely complication has she developed? Give full diagnosis. *(3 marks)*
b. How will you confirm the diagnosis? Mention the stain used. *(4 marks)*
c. Enumerate three drugs to control this disorder. *(3 marks)*

Q3. A enthusiastic PG teacher was teaching the residents importance of history-taking in rheumatology. He asked the following questions. Please answer them:

a. Enumerate three basic questions to be asked to a patient with joint pains. *(3 marks)*
b. Describe three conditions presenting with asymmetric joint pains of >3 weeks. *(3 marks)*
c. Enumerate three joints typically involved the ankylosing spondylitis. What is enthesitis? *(4 marks)*

Q4. A 24-year-old lady visited the general practitioner with history of joint pains and a rash. She was advised to get the ANA and rheumatoid factors (RFs) done:

a. Describe the methods of doing ANA. What titer is considered diagnostic of systemic lupus erythematosus (SLE) in a suspected case? *(2 marks)*
b. Name three conditions with a positive ANA apart from SLE. *(3 marks)*
c. Describe three conditions with a positive RF. *(3 marks)*
d. How do you confirm the diagnosis of RA with a biochemical test? Give its full form. *(2 marks)*

JAYPEE BROTHERS

Q5. A 30-year-old lady presented with a long-standing diastolic murmur. Her hand examination is shown in the image below.



a. Identify the condition. *(5 marks)*
b. List two causes. *(5 marks)*

Q6. A 62-year-old woman comes to the hospital due to activity-related joint pain in the hands and periodic morning stiffness that lasts 10–15 minutes. The pain is moderately severe and has begun to limit her activities. The patient has attempted to treat the pain with paracetamol, which provided only partial relief. Past medical history is notable for hypertension (HTN) and diabetes mellitus. Physical examination shows firm nodules over the distal interphalangeal joints bilaterally as shown in the image below.



What is the diagnosis? *(10 marks)*

JAYPEE BROTHERS

Q7.



a. What kinds of deformities are seen in the hands in the photograph? *(1 mark)*
b. Which inflammatory arthritis are these deformities characteristically seen in? *(2 marks)*
c. What are the serological and other tests that you would like to specifically order for this patient? *(1 mark)*
d. What are the ACR-EULAR (American College of Rheumatology and the European League Against Rheumatism) 2010 criteria for classification of RA? *(2 marks)*
e. What is the nondeforming form of inflammatory arthritis seen in SLE known as? *(1 mark)*
f. What is the eponymous name for arthritis resulting due to neuropathy? *(1 mark)*

Q8. The homunculus represents a 32-year-old male patient who has developed pain and swelling of the bilateral knee joints and left ankle joint over the last 3 months.

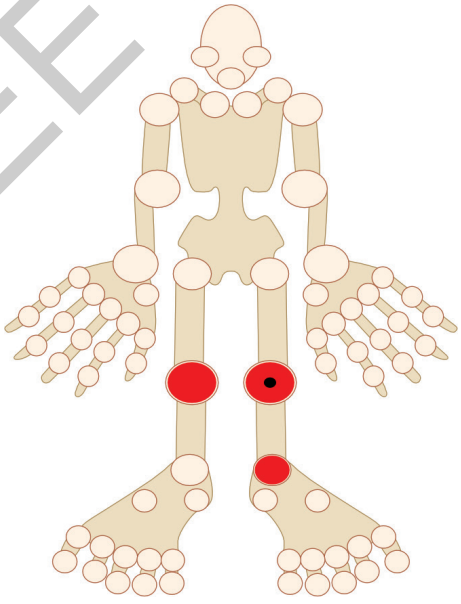

What is the pattern of arthritis? *(10 marks)*

JAYPEE BROTHERS

Q9.



a. What are the features seen on the radiograph? *(5 marks)*
b. What is the differential diagnosis of acroosteolysis? *(5 marks)*

Q10. A 45-year-old female comes to medicine outpatient department (OPD) with complaints of multiple joint pain (small > large) with morning stiffness lasting for >60 minutes for the last 2 years. On examination, following are seen:

a. What is RF and two conditions associated with positive RF? *(3 marks)*
b. What is Felty's syndrome? *(2 marks)*
c. Name some disease-modifying antirheumatic drugs (DMARDs) used in treatment. *(2 marks)*
d. How will you define remission in RA, mention any two criteria? *(3 marks)*





JAYPEE BROTHERS

Q11.



a. Identify the deformity. *(5 marks)*
b. EULAR criteria for RA. *(5 marks)*

Q12.



a. Identify the above X-ray and name the condition associated with it. *(5 marks)*
b. Name the extra-articular manifestations of above condition. *(5 marks)*

Q13.



a. Identify the clinical sign depicted in the image. *(2 marks)*
b. Describe dactylitis. *(2 marks)*
c. In which conditions are you likely to see dactylitis in a patient? *(2 marks)*
d. What are the clinical patterns of arthritis seen in psoriatic arthritis as described by Moll and Wright? *(2 marks)*
e. What are the CASPAR (Classification criteria for Psoriatic Arthritis) criteria for classification of psoriatic arthritis? *(2 marks)*

JAYPEE BROTHERS

Q14.



a. What is the clinical sign seen? *(5 marks)*
b. What is primary hypertrophic osteoarthropathy (PHO)? *(5 marks)*

Q15.

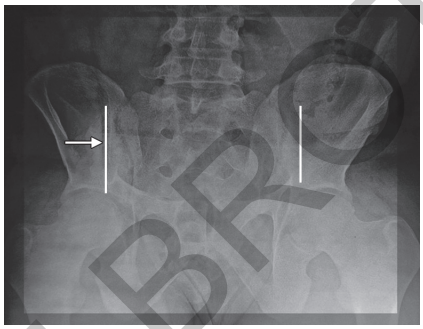

a. What is the pathological finding seen on the radiograph? *(4 marks)*
b. What are the grades of sacroiliitis (New York criteria)? *(3 marks)*
c. What is meant by active sacroiliitis on MRI as per ASAS (Assessment in Spondyloarthritis International Society) criteria? *(3 marks)*

Q16.

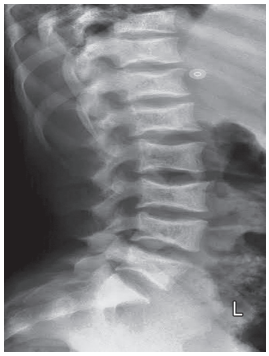

a. What abnormality does the X-ray lateral spine? *(3 marks)*
b. What are the differential diagnoses for this condition? *(4 marks)*
c. What specific investigations to be done for final diagnosis? *(3 marks)*

JAYPEE BROTHERS

Q17. A 48-year-old male presented with history of severe joint pain in bilateral knee and small joints of the foot with unable to walk due to severe pain. He is a known alcoholic for last 10 years. He has a history of cerebrovascular accident (CVA) [intracerebral hemorrhage (ICH)] with left sided hemiparesis 1 year back. No history of diabetes or HTN. There were multiple nodular lesions over the dorsum of the foot and bilateral knee was swollen and tender. Serum uric acid was 11.3 mg/dL.

Aspirate from knee joint and nodular swelling was taken. X-ray of bilateral foot was done.







Microscopy from the aspirate shows the following:

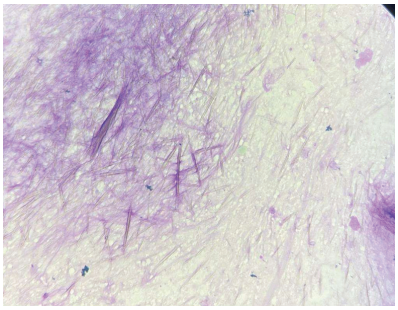

a. Read the X-ray findings. *(4 marks)*
b. What is your diagnosis? *(3 marks)*
c. What are the drugs used in the acute phase of the disease process? *(3 marks)*

JAYPEE BROTHERS

Q18. A 33-year-old female complains of (c/o) dry mouth and brittle eyes since 6 months and has now started having lower limb cramps and weakness since 1 month.
On evaluation, Hb—7.6 mg/dL, hypokalemia—2.9 mEq/L, ECG—U-waves, and urine pH—6.1

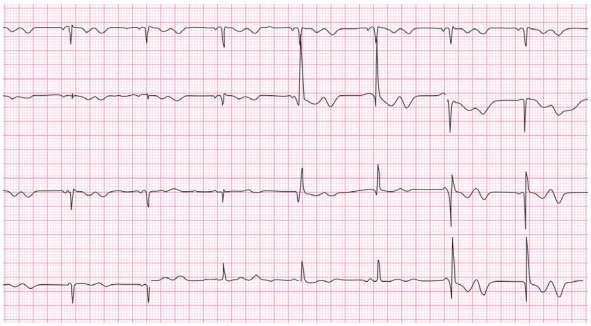



a. Identify the clinical image. *(4 marks)*
b. Diagnosis is: *(6 marks)*
- Type 1 (distal) renal tubular acidosis (RTA)
- Type 2 (proximal) RTA
- Type 3 RTA
- Type 4 RTA

Q19.

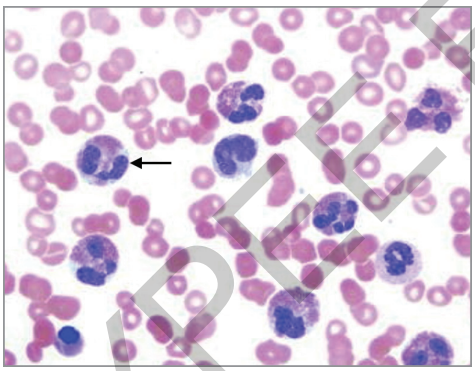

Image 1



Image 2

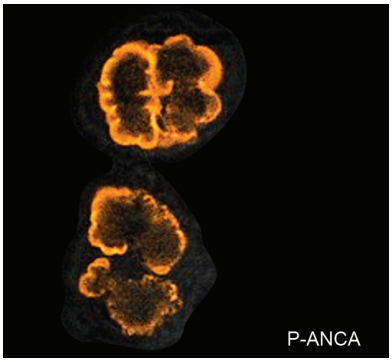

Image 3

a. Identify the condition. *(2 marks)*
b. Identify the clinical entity in Image 1, 2, and 3. *(4 marks)*
c. State the classification of type of renal involvement in this condition. *(4 marks)*

Q20. A 60-year-old male presented with complaints of progressive muscle weakness involving the proximal lower limb. Laboratory examination revealed mild increase in serum creatine kinase (CK) levels. Muscle biopsy was performed which showed cytoplasmic inclusions staining positive with p62 immunostain.
a. What is the most likely diagnosis? *(5 marks)*
b. Enumerate the skin manifestations seen in dermatomyositis. *(5 marks)*

JAYPEE BROTHERS

Q21. A 42-year-old woman presented with progressive shortness of breath on exertion. There is a history of episodic bluish discoloration of fingers on exposure of cold. On examination, fine bibasal inspiratory crepitations and thickening and hardening of the skin involving the fingers and face. Observations are as follows: heart rate 95 beats/min, respiratory rate 22 breaths/min, blood pressure 155/90 mm Hg, temperature 37.5°C, and oxygen saturation 94% on air. A high-resolution computed tomography (HRCT) is performed.

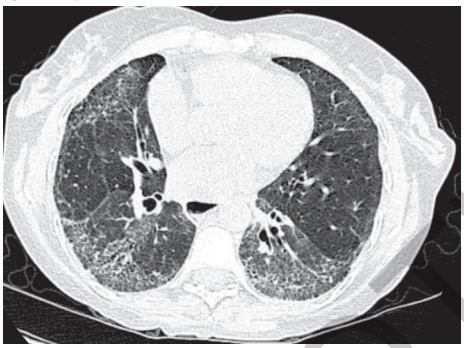

a. What is the most likely diagnosis? Mention other differential diagnosis of thickened tethered skin. *(2 marks)*
b. Mention antibodies present in this condition. *(2 marks)*
c. What antibody is associated with the high risk of interstitial lung disease (ILD)? *(2 marks)*
d. What is the CREST (calcinosis, Raynaud phenomenon, esophageal dysmotility, sclerodactyly, and telangiectasia) syndrome? *(2 marks)*

Q22. A 70-year-old presented with dyspnea on exertion and following features:







a. What is diagnosis? *(3 marks)*
b. What are specific antibodies? *(4 marks)*
c. What are pulmonary complications? *(3 marks)*

JAYPEE BROTHERS

Q23. A 44-year-old woman who has had Sjögren's syndrome for 4 years presents with diffuse muscle weakness. She uses carboxymethylcellulose eye drops. Physical examination findings and laboratory test results are shown in table below. A computed tomographic scan of the abdomen is shown in image below.

Component	*Finding*
Body mass index	19
Blood pressure, mm Hg	98/60
Pulse, beats per minute	98
Respiratory rate, breaths per minute	20
Edema	Absent
Sodium, mEq/L	134
Potassium, mEq/L	2.3
Chloride, mEq/L	114
Bicarbonate, mEq/L	12
Serum creatinine, mg/dL	0.8
Anion gap, mEq/L	8
Arterial blood gas: • pH • PCO_2, mm Hg	 7.27 27
Urinalysis: • pH • Protein • Glucose • Red blood cells per high-power field	 6.7 Trace Negative 3–10



a. What is the diagnosis? *(3 marks)*
b. What is the CT finding? *(3 marks)*
c. What are the other causes of this disease? *(4 marks)*

JAYPEE BROTHERS

ANSWERS

Ans. 1

a. Adult-onset Still's disease (AOSD)
b. Elevated inflammatory markers, namely the C-reactive protein (CRP) and erythrocyte sedimentation rate (ESR). Serum ferritin, which is frequently disproportionally elevated in AOSD. Liver function tests (LFTs) may be deranged.
c. Nonsteroidal anti-inflammatory drugs (NSAIDs) for symptomatic relief, corticosteroids, and methotrexate.
d. In 2020, the US Food and Drug Administration (USFDA) approved canakinumab to treat patients with active Still's disease including AOSD.

Ans. 2

a. She has developed AA type amyloidosis secondary to RA
b. Biopsy and histopathological examination from any of the sites, such as subcutaneous fat, spleen, adrenal gland, liver, labial salivary gland, and sites in the alimentary canal ranging from the tongue and gingiva to the rectum. The stain used is Congo Red. Deposits of amyloid bind Congo Red and exhibit apple-green birefringence when viewed by polarization light microscopy.
c. *Biologics:* Anti-tumor necrosis factor (anti-TNF), anti-interleukin-6 (anti-IL-6), rituximab, abatacept, tofacitinib, and antifibril drug—eprodisate.

Ans. 3

a. Duration, pattern of joint involvement, and symmetry
b. Reactive arthritis, rheumatic fever and arthritis, and psoriatic arthritis
c. Sacroiliac (SI) joint, hips, and vertebra. "Enthesitis is inflammation of the "enthesis," which is where a tendon or ligament attaches to bone.

Ans. 4

a. Enzyme-linked immunosorbent assay (ELISA), immunofluorescence. A positive ANA titer (>1:80) with the associated clinical signs (e.g., skin disease and polyarthritis) and laboratory findings (e.g., proteinuria and thrombocytopenia) is diagnostic for SLE.
b. Polymyositis/dermatomyositis, juvenile idiopathic arthritis, juvenile idiopathic arthritis with uveitis, Sjögren's syndrome, and RA
c. Rheumatoid arthritis, primary Sjögren's syndrome, and mixed connective tissue disease
d. Anti-cyclic citrullinated peptide (anti-CCP) antibody testing is particularly useful in the diagnosis of rheumatoid arthritis with high specificity.

Ans. 5

a. Jaccoud's arthropathy is a benign chronic arthropathy without functional impairment and needs to be differentiated from fixed and noncorrectable deformities of RA.
b. Rheumatic heart disease, systemic lupus erythematous, etc.

Ans. 6

Heberden's nodes in osteoarthritis

JAYPEE BROTHERS

Ans. 7

a. Swan neck deformity, Z deformity of the thumb, ulnar subluxation, and ulnar deviation at the MCPs.
b. Rheumatoid arthritis
c. Rheumatoid factor, anticyclic citrullinated polypeptide (ACCP), CRP quantitative, complete blood counts, LFTs, renal function tests (RFTs), virological markers [hepatitis B surface antigen (HBsAg), anti-hepatitis C virus (anti-HCV), and human immunodeficiency virus (HIV)], radiographs [X-ray both hands and wrists posteroanterior (PA) view, X-ray both knees anteroposterior (AP) and lateral, chest X-ray (CXR)—PA view].
d. There are four domains of the criteria and a patient is classified as RA if the cumulative score is 6/10 or more. The maximum possible is 10/10. Patient may fulfill the criteria prospectively or retrospectively.

Joint distribution (0–5):	
1 large joint	0
2–10 large joints	1
1–3 small joints (large joint not counted)	2
4–10 small joints (large joint not counted)	3
>10 joints (at least 1 large joint)	5
Serology (0–3):	
Negative RF and anticitrullinated protein auto-antibody (ACPA)	0
Low titer positive RF or ACPA	1
High titer positive RF or ACPA	3
Symptom duration (0–1):	
<6 weeks	0
>6 weeks	1
Acute phase reactants (0–1):	
Normal C-reactive protein (CRP) and erythrocyte sedimentation rate (ESR)	0
Raised CRP or ESR	1

e. Jaccoud's arthropathy
f. Charcot's arthritis

Ans. 8

The pattern is suggestive of inflammatory oligoarthritis.

Term	***Explanation***
Single joint involvement	Monoarthritis
Four or less joints involved	Oligoarthritis
More than four joints involved	Polyarthritis

Contd…

JAYPEE BROTHERS

or detailed information on medicine books, visit our website www.jaypeebrothers.com, for detailed information on medicine books, visit our website www.jaypeebr

OSCEs in Medicine

A Primer for Postgraduate Students

Salient Features

- 500 OSCEs divided into sections according to systems
- Clinical problems as well as investigation-based problems dealt with
- Marks distribution given
- Full explanatory answers provided
- A comprehensive guide for students on how to tackle OSCEs in the examination
- More OSCEs to follow as volume 2 in upcoming months.

Narinder Pal Singh MD FACP FRCP (Edinburgh) FASN ISHF FISN FAMS FICP MBA is the National Vice President, Association of Physicians of India (API), Dean Research at Eternal University, Baru Sahib, Himachal Pradesh, India, Advisor Research at FMHS, SGT University, Gurugram, Haryana, India, and Consultant—Academic Programs in Nephrology at Max Super Speciality Hospital, New Delhi, India. He is an experienced healthcare professional with over 35 years of expertise in clinical medicine, teaching, research, and administration in Internal Medicine and Nephrology. He has had the privilege of working in both public and private corporate institutions, gaining extensive knowledge of the healthcare industry and its complexities.

As a highly motivated speaker and influencer, he has had the opportunity to share his insights and expertise with various audiences. He has spoken at numerous conferences, workshops, and events, inspiring and educating professionals, students, and the general public.

Jyotirmoy Pal MD (General Medicine) FRCP FICP FACP WHO Fellow is the Professor, Department of General Medicine, University College of Medicine and Sagore Dutta Medical College, Kamarhati, West Bengal, India. He is the Dean of Indian College of Physician (ICP) and President-Elect of Association of Physician of India (API). His fields of interest are Infectious and Tropical Diseases and Geriatric Medical and Public Health. In the last 21 years, he has published more than 80 research articles in national and international indexed journals. He served as a Secretary and an Editor for the Journal of Indian Medical Association (JIMA). He contributed chapters in more than 30 books and is the Editor of Monograph Dengue, Clinical Methods in Respiratory Medicine, and Mucormycosis. He is also the Editor-in-Chief, MacMaster Textbook of Internal Medicine, South-Asian edition. He has been a Member of the Expert Committee on COVID Care, Dengue Management, Department of Health and Family Welfare, Government of West Bengal, India.

Printed in India

Available at all medical bookstores
or buy online at www.jaypeebrothers.com



JAYPEE BROTHERS
Medical Publishers (P) Ltd.
EMCA House, 23/23-B, Ansari Road,
Daryaganj, New Delhi - 110 002, INDIA
www.jaypeebrothers.com

Join us on facebook.com/JaypeeMedicalPublishers

Shelving Recommendation
INTERNAL MEDICINE

