ebrothers.com, for detailed information on nursing books, visit our website www.jaypeebrothers.com, for detailed information on nursing books

Nursing Q-Bank Series

*For BSc Nursing Students*

# Applied Anatomy & Physiology

*As per the Revised INC Syllabus*



***HIGHLIGHTS***

- University Examination Question Papers
- Model Test Paper
- Learning Pearls
- Applied Questions
- Image-Based Questions

**Monika Dean**
**Abha Narwal**
**Rachna Khanna**
**Nandani Kumari**

*Semester-I*

JAYPEE

# CONTENTS

**Unit 1:** General Anatomy and Physiology ..... 1
**Unit 2:** Respiratory System ..... 22
**Unit 3:** Digestive System ..... 39
**Unit 4:** Blood and Cardiovascular System ..... 57
**Unit 5:** Endocrine System ..... 90
**Unit 6:** Sensory System ..... 109
**Unit 7:** Musculoskeletal System ..... 128
**Unit 8:** Urinary System ..... 154
**Unit 9:** Reproductive System and Glands ..... 168
**Unit 10:** Nervous System ..... 201

**University Examination Question Papers**

- Atal Bihari Vajpayee Medical University, Uttar Pradesh 223
- Baba Farid University of Health Sciences, 2022 229
- Himachal University, 2022 233
- IP University, New Delhi, 2023 236
- PGMIS, Rohtak, 2023 239

**Model Test Paper** **243**
**Learning Pearls** **247**
**Applied Questions** **253**
**Image-Based Questions** **261**
**Bibliography** **275**

UNIT 3

# DIGESTIVE SYSTEM

## LONG QUESTIONS

**Q 1. Describe the structure of the stomach and nerve supply to stomach.**

**Ans:** Stomach is a J-shaped organ which plays an important role in digestion of food.

- **Location**: Upper and left part of abdomen epigastric, umbilical and left hypochondrial region
- In adult life, stomach located T10 and L3 vertebral segment.

### Relation of Stomach with Other Abdominal Organs

- **Anteriorly**: Diaphragm, liver and anterior abdominal wall
- **Posteriorly**: Omental bursa, pancreas, left kidney, adrenal glands, spleen, and splenic artery
- **Superiorly**: Esophagus, diaphragm
- **Inferiorly and laterally**: Transverse mesocolon.

### Structure of Stomach (Fig. 3.1)

The four main sections of the stomach are the **cardia, fundus, body, and pyloric** part:

1. As the name implies, the **cardia** surrounds the cardiac orifice, which is the opening between the esophagus and the stomach. It is the first section that ingested food passes through, representing the inflow part.

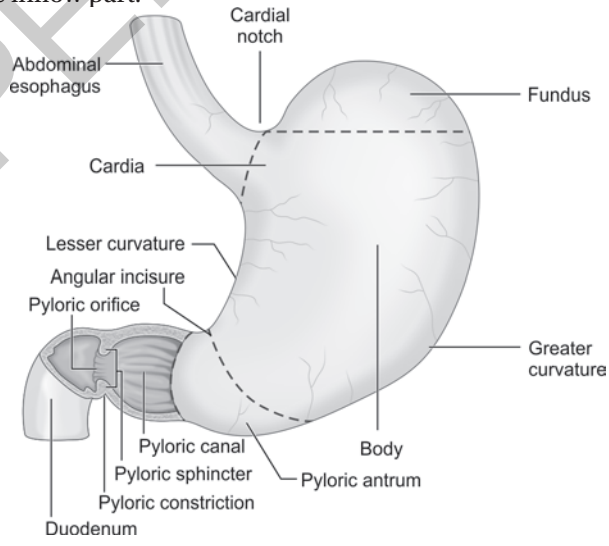


**Fig. 3.1:** Structure of stomach.

JAYPEE BROTHERS

2. The fundus is the superior dilation of the stomach, which is located superiorly relative to the horizontal plane of the cardiac orifice.
3. Next, we have the **corpus, or gastric body**, which is the largest part of the organ.
4. Finally, the **pyloric** part represents the outflow section of the stomach, passing stomach contents into the duodenum.
   - The pylorus is further divided into two distinct areas— the pyloric antrum connected to the stomach and the pyloric canal connected to the duodenum.
   - The contents of the pyloric canal enter into the duodenum via the pyloric orifice, the opening and closing of which are controlled by the pyloric sphincter, a circular layer of smooth muscle.

The longer and convex curvature located on the left of the stomach is called the **greater curvature**, this starts from the cardiac notch that is formed between the esophageal border and fundus. In contrast, the **shorter concave curvature** found to the right is the lesser curvature. The latter contains a small notch called the angular incisure which marks the line of intersection between the body and pyloric part of the stomach.

**Mnemonic**

You might be wondering if there is an easy way to remember the parts of the stomach. Of course, there is and we are about to tell you! Just remember the phrase' **'Cows Find Bulls Passionate'**, which stands for:

- Cardium
- Fundus
- Body
- Pylorus

### *Capacity*

- 30 mL—birth
- 1 L—puberty
- 1½ L—2 L or more—adult

### *Layers of Tissue*

Which forms the stomach are:

1. **Serous layer***:* It is the outermost layer.
2. **Muscle layer**: Also known as muscularis externa consisting of outer longitudinal, middle circular and inner oblique layer.
3. **Submucous layer:** It consists of blood, areolar tissue, lymph vessels and nerves.
4. **Mucous layer:** It is the innermost layer consists of columnar epithelium and goblet cells. Gastric glands are also present in this layer and consists of:
   a. *Mucus neck cells:* Secretes mucus.
   b. *Chief cells/peptic cells:* Secretes pepsinogen (the precursor of enzyme pepsin)
   c. *Oxyntic cell/parietal cells:* Secretes hydrochloric acid
   d. *G-cells* secretes hormone ***Gastrin***

### Nerve Supply to Stomach

Nerve supply to stomach is through autonomic nervous system. Parasympathetic fibers arise from vagus nerve. Sympathetic fibers arise from celiac plexus.

JAYPEE BROTHERS

| | Arises from | Supplied via | Function |
|---|---|---|---|
| **Parasympathetic fibers** | Left vagus nerve | Anterior vagal trunk | • Increases motility of stomach<br>• Increases secretion of gastric juice rich in pepsin and hydrochloric acid |
| | Right vagus nerve | Posterior vagal trunk | |
| **Sympathetic fibers** | T5- t12 spinal segments | • Celiac plexus<br>• Greater splanchnic nerve<br>• Greater splanchnic nerve | • Causes vasoconstriction<br>• Carry visceral pain sensations<br>• Inhibition of gastric motility |

***Innervation***

1. *Parasympathetic*: Vagus nerve (CN X)
2. *Sympathetic*: Celiac plexus

**Q 2. Describe in detail digestion and absorption of protein.**

Digestion is the process of breaking large, insoluble food molecules into smaller molecules for absorption into the bloodstream. This process involves the use of many digestive fluids and enzymes, such as saliva, mucus, bile and hydrochloric acid, among others.

Acids and enzymes in the stomach interact to digest protein. Proteins are broken down by the enzymes activated by the stomach acid.

## DIGESTION AND ABSORPTION OF PROTEINS

The digestion of proteins takes place in the stomach with the help of protease and pepsin enzymes, which breaks down the complex proteins into simple amino acids.

For this process to happen acidic medium is needed thus stomach is the favorable place for this process to occur. Amino acids are tiny elements which get absorbed into the blood system through the wall of the small intestine.

- At first, pepsin, an enzyme in the stomach, breaks down and splits the proteins in the food into shorter polypeptides.
- The pancreas further releases enzymes into the small intestine, where the polypeptide chains are broken, and breaking down peptides and amino acids begins.
- The small intestine releases more peptidases to digest the food by breaking down the proteins into amino acids.
- Finally, the amino acids are carried across the small intestinal wall and into the bloodstream. They are taken up and utilized by the tissues in the body to maintain normal, healthy functioning.

**The enzymes involved are:**

1. **Pepsin:**
   - The chief cells of the stomach secrete pepsin as pepsinogen.
   - Gastric $H^+$ triggers the conversion of pepsinogen into pepsin. A pH of 1–3 is ideal for pepsin.
   - Proteins are hydrolyzed by pepsin into peptides and proteoses.
   - Pepsin denatures when the pH exceeds 5. $HCO_3$ thereby increases pH in the duodenum and inactivates pepsin in the intestines as the pancreas secretes it.
2. **Pancreatic proteases:**
   - With the action of the pancreatic and intestinal juice, the digestion is completed in the small intestine.

JAYPEE BROTHERS

- Among the proteases are trypsin, elastase, chymotrypsin, carboxypeptidase A, and carboxypeptidase B.
- Inactive forms of these enzymes are secreted into the small intestine, which activates them as follows:
- By using enterokinase, trypsinogen is converted to trypsin.
- The enzyme trypsin converts the inactive forms of proelastase, chymotrypsinogen and procarboxypeptidase A and B into their active forms.

**Absorption of Proteins**

The absorption of proteins occurs in the small intestine, with various enzymes acting upon them.

1. **Free amino acids:**
   - In the luminal membrane, co-transport of $Na^+$ dependent amino acids takes place. Glucose and galactose co-transporters are analogous to this transporter.
   - The facilitated diffusion transports amino acids from the cells to the blood.
   - Four different carriers exist for neutral, acidic, basic, and amino acids.
2. **Dipeptides and tripeptides:**
   - As compared to free amino acids, they are absorbed faster.
   - The luminal membrane is also capable of transporting dipeptides and tripeptides.
   - The facilitated diffusion transports the amino acids from the cells to the blood.

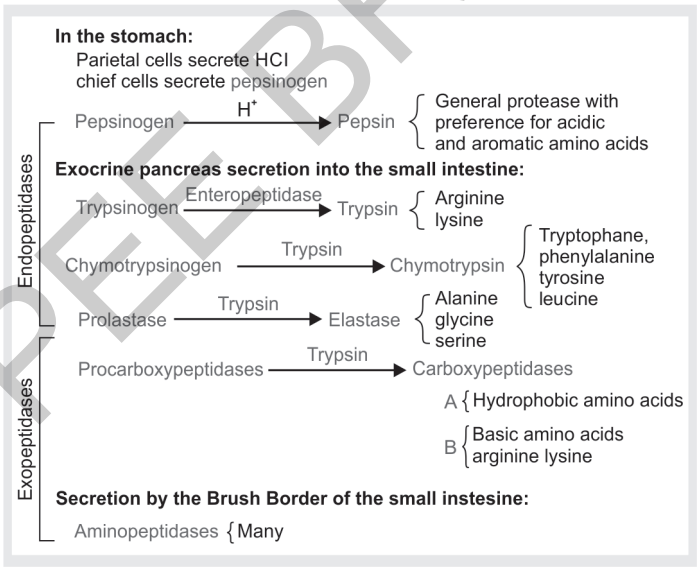


**Fig. 3.2:** Protein digestion and amino acid absorption.

**Q 3. Discuss the anatomy of liver. Name the structures present in the hilum of the liver.**

**Ans:**

a. **Anatomy of liver:**
*Refer Q. No. 2 of Short Questions of this Unit.*

b. **Structure present in the hilum of the liver**:

JAYPEE BROTHERS

**Anatomy:** Liver hilum or porta hepatitis is a opening that allows structures (e.g., common duct, hepatic artery, portal vein, etc.) to pass into and out of the liver. It divides in the Y-shaped manner into right and left hepatic artery.
**Location:** It is located on the center of the liver. It is almost present above the pancreas and small intestine. It is near the gallbladder.
**Structures passes through hilum are:**
a. Main portal vein (PV)
b. Proper hepatic artery (PHA)
c. Common hepatic duct (CHD)
d. Nerves
e. Parts of lymphatic system

## SHORT QUESTIONS

**Q 1. Explain accessory organs of digestion.**

**Ans:** The accessory organs are not the part of alimentary tract but play a prominent role in digestion. Their major function is to secrete juices needed for the proper digestion and lubrication of food.

Accessory organ of digestion are ***salivary glands, liver, gallbladder*** and ***pancreas***.

### 1. Salivary Glands

- There are three major saliva secreting glands—***parotid, submandibular and sublingual***.
- A normal adult secretes 0.1–1.5 liters of saliva in a day.
- Two main components of saliva are:
  1. **Ptyalin** (salivary amylase)—For the digestion of starch.
  2. **Mucin**—Protects the surface of oral cavity from pathogens.
- Parotid gland secrets only ptyalin, whereas submandibular and sublingual glands secret both ptyalin and mucin.

### 2. Pancreas

- Pancreas is located near the junction of stomach and small intestine.
- It secrets digestive juices into duodenum through a small tube called as pancreatic duct. Thus, pancreas also has exocrine function.
- Pancreas is responsible for the digestion of proteins, fat and starch
- Enzymes:
  a. ***Trypsin***, ***chymotrypsin*** and ***carboxypeptidase*** for protein digestion.
  b. ***Pancreatic amylase for*** carbohydrate digestion
  c. ***Pancreatic amylase, phospholipase*** for fat digestion

### 3. Liver and Gallbladder

- Liver is the largest gland of the body.
- It mainly secretes bile.
- **Bile serves as two functions:**
  1. It digests and absorbs fat.
  2. Excretes waste products from blood.

JAYPEE BROTHERS

### 4. Intestinal Glands

- **Brunner's gland:** Secretes alkaline mucus in order to protect wall of duodenum from acidic juices and neutralizes them.
- **Crypts of Lieberkuhn:** These are small pits spread all over the surface of small intestine, located between the intestinal villi. They are responsible for secreting mucous and absorbing water and electrolytes

**Q 2. Explain the structure and function of liver.**

**Ans:**

### Liver Anatomy

- The liver is ***reddish-brown*** and shaped approximately ***like a cone or a wedge***, with the small end above the spleen and stomach and the large end above the small intestine.
- The liver is the ***largest gland in the body***, weighing about ***1500 g***.
- It is situated in the upper part of the abdominal cavity occupying the greater part of the right hypochondriac region, part of the epigastric region and extending into the left hypochondriac region.
- Liver secretes ***bile.***
- Organs associated with the liver:

| | |
|---|---|
| **Superiorly and anteriorly** | Diaphragm and anterior abdominal wall |
| **Inferiorly** | Stomach, bile ducts, duodenum, hepatic flexure of the colon, right kidney and adrenal gland |
| **Posteriorly** | Esophagus, inferior vena cava, aorta, gallbladder, vertebral column and diaphragm |
| **Laterally** | Lower ribs and diaphragm |

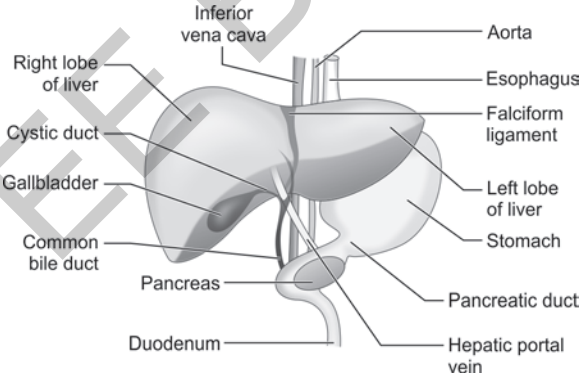


**Fig. 3.3:** Structure of liver.

### Lobes of Liver

- The liver consists of ***four lobes***—the larger right lobe and left lobe, and the smaller caudate lobe and quadrate lobe.
- The left and right lobe are divided by the falciform ("sickle-shaped" in Latin) ligament, which connects the liver to the abdominal wall.
- The liver's lobes can be further divided into eight segments, which are made up of thousands of lobules (small lobes).
- Each of these lobules has a duct flowing toward the common hepatic duct, which drains bile from the liver.

JAYPEE BROTHERS

3. **Intestinal phase:**
   - Presence of chyme, most probably amino acids in the intestine which triggers almost 5% of the gastric acids in the intestine.
   - Regulation of intestinal phases is regulated by nervous and hormonal mechanism.

**Q 10. Peritoneum.**

**Ans:** The peritoneum is the serous membrane that lines the abdominal cavity. It consists of two layers and a potential space between them is called peritoneal cavity.

**Layers**

a. **Parietal peritoneum:** It is an outer layer; lining the abdominal wall and pelvis walls.
b. **Visceral peritoneum:** Inner layer called visceral peritoneum covering the viscera. The mesentery is a double layer of visceral peritoneum that attaches to the GI tract.

The peritoneum serves to support the organs of the abdomen and acts as a conduit for the passage of nerves, blood vessels, and lymphatics.

**Subdivisions**

Peritoneal folds are omentum, mesenteries and ligaments. They connect organs to each other or with the abdominal wall. There are two main regions:

a. **Greater sac:** It is the cavity in the abdomen that is inside the peritoneum but outside the lessor sac. It is connected with the lessor sac via the omental foramen.
b. **Lessor sac:** The lessor sac is divided into two omentum:
   i. *Lessor omentum:* It is attached to the lesser curvature and liver
   ii. *Greater omentum:* It hangs from the greater curvature of the stomach and connects stomach with the diaphragm, spleen and transverse colon.

## VERY SHORT QUESTIONS

**Q 1. Name the bile salts.**

**Ans:**

- Bile salts are made of bile acids that are conjugated with glycine or taurine.
- Bile salts are one of the primary components of bile.
- Bile is a greenish-yellow fluid made by the liver and stored in the gallbladder.
- In addition to bile salts, bile contains cholesterol, water, bile acids, and the pigment bilirubin.
- Bile salts help in the digestion of fats. They also help the body absorb fat-soluble vitamins, such as vitamins A, D, E, and K.

In humans, ***taurocholic acid*** and ***glycocholic acid*** (derivatives of cholic acid) and ***taurochenodeoxycholic acid*** and ***glycochenodeoxycholic acid*** (derivatives of chenodeoxycholic acid) are the major bile salts.

**Q 2. Gallbladder.**

**Ans:**

**GALLBLADDER**

- Gallbladder is a ***small, pear-shaped organ*** that stores and releases bile.
- Bile is the fluid that liver produces which helps in the ***digestion of fats***.

**Location**

- Gallbladder is located in the upper right part of abdomen (belly).
- Also known as cholecyst.

JAYPEE BROTHERS

**Parts of Gallbladder (Fig. 3.7)**

It is divided into three parts:

**a. Fundus**: The rounded distal portion of the gallbladder.
**b. Body**: The largest and the main part of gallbladder.
**c. Neck**: Neck is continuous with the cystic duct leading into the biliary tree.

**Functions**

a. Its main function is to store bile.
b. Bile helps the digestive system to break down fats.
c. Bile is a mixture of mainly cholesterol, bilirubin and bile salts.

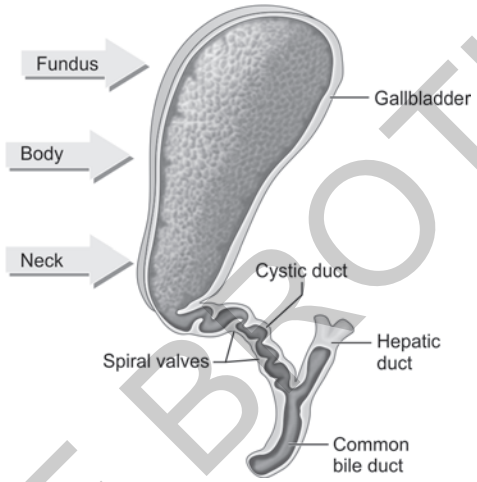


**Fig. 3.7:** Gallbladder.

**Q 3. Digestion in stomach.**

**Ans:** Stomach stores and mixes the food it received from the esophagus with gastric juices. About two liters of gastric juice are secreted daily by specialized secretory glands in the mucosa. Water, mineral salts, mucus secreted by mucous neck cells in the glands and surface mucous cells on the stomach surface hydrochloric acid, intrinsic factor are secreted by partial cell of the stomach.

Water further liquefies the food swallowed.

**Hydrochloric acid**: Acidifies the food and stops the action of salivary amylase—kills ingested microbes—provides the acid environment needed for the action of pepsins.

**Pepsinogens** are converted to pepsins by hydrochloric acid which is already present in the stomach. These enzymes begin the digestion of proteins, breaking them into smaller molecules. Pepsins have evolved to act most effectively at a very low pH, between 1.5 and 3.5.

**Intrinsic factor** (a protein) is necessary for the absorption of **vitamin $B_{12}$** from the ileum. (Deficiency leads to pernicious anemia)

**Mucus** prevents mechanical injury to the stomach wall by lubricating the contents.

It also prevents chemical injury by acting as a barrier between the stomach wall and the corrosive gastric juice—hydrochloric acid is present in potentially damaging concentrations and pepsins would digest the gastric tissues.

JAYPEE BROTHERS

**Q 13. Functions of tonsils.**

**Ans:**

1. **Provides immunity:** The main function of tonsils is to fight against infection. Tonsils contain lots of WBCs which helps to kill germs.
2. **Helps in the formation of lymphocyte** (T cells or T lymphocytes)
3. **Antibodies formation:** IgA, IgG, IgM, IgE and IgM are present in all tonsils
4. Acts as a **barrier to infection**.

**Q 14. Functions of saliva.**

**Ans:**

1. **Lubrication:** Saliva lubricates the food by mucin which helps in easy swallowing of food.
2. **Speech:** Lubricating action of saliva also helps in speech.
3. **Chemical digestion:** It breaks down starch by the function of salivary amylase.
4. **Line of defense:** Saliva contains many substances like lysozyme, immunoglobulin A (IgA), etc., which can kill microbes.
5. **Excretory function:** It excretes substances like mercury, potassium iodide, lead, etc.

## MULTIPLE CHOICE QUESTIONS

1. **The forward movement of food through the alimentary tract is:**
   a. Excretion
   b. Ingestion
   c. Digestion
   d. Propulsion
2. **The abdominal organs are covered by serous membrane called:**
   a. Peritoneum
   b. Perineum
   c. Pleura
   d. Meninges
3. **The sphincter at the junction of the esophagus and stomach is:**
   a. Cardiac sphincter
   b. Pyloric sphincter
   c. Cricopharyngeal
   d. Sphincter of Oddi
4. **The flow of pancreatic juice into the duodenum is controlled by:**
   a. Ampulla of Vater
   b. Pyloric antrum
   c. Sphincter of Oddi
   d. Duct of Wirsung
5. **The part of large intestine that is joined to the rectum is called:**
   a. Ascending
   b. Transverse
   c. Descending
   d. Sigmoid colon

JAYPEE BROTHERS

# IMAGE-BASED QUESTIONS

*Courtesy: Ashalatha PR, Deepa G. Textbook of Applied Anatomy and Physiology for Nurses, 7th ed. New Delhi; Jaypee Brothers Medical Publishers (P) Ltd., 2024*

**1. Identify the marking 7 in the following image.**

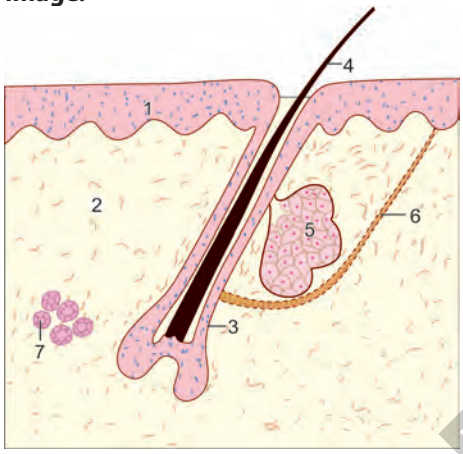


a. Dermis
b. Sebaceous gland
c. Sweat gland
d. Epidermis

**2. Identify the marking 2 in the following image.**

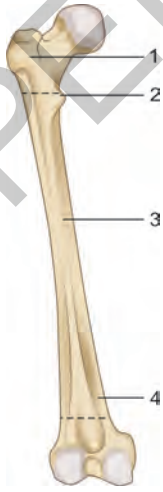


a. Epiphysis
b. Epiphyseal plate
c. Diaphysis
d. Metaphysis

**3. Identify the following muscle type.**

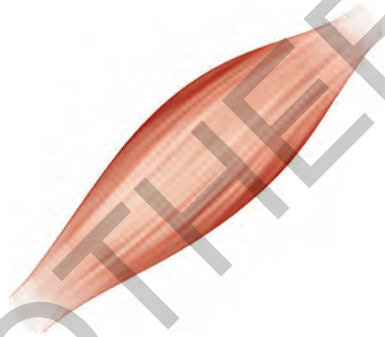

a. Multipennate
b. Convergent
c. Fusiform
d. Bipennate

**4. Which among the following marking represents the spinal ganglion?**

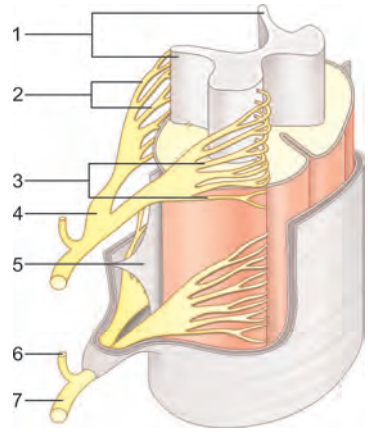


a. 1
b. 3
c. 4
d. 2

| Ans: | 1. c | 2. b | 3. c | 4. c |
|---|---|---|---|---|

JAYPEE BROTHERS

**5. Which among the following marking represents the lactiferous ducts?**

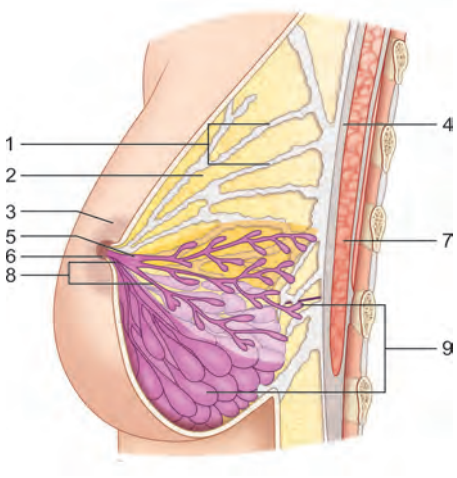


a. 4
b. 3
c. 2
d. 1

**6. What is the weight of the following organ depicted with arrow?**

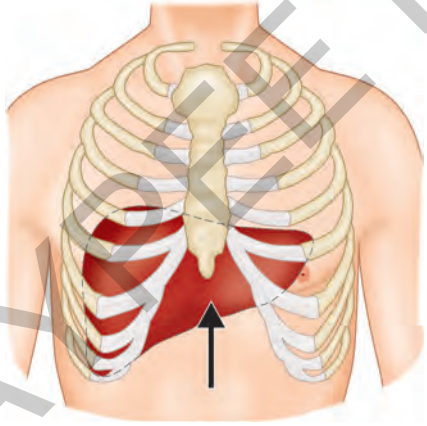

a. 500–800 g
b. 900–1200 g
c. 1400–1600 g
d. 1800–2000 g

**7. Identify the following cell.**

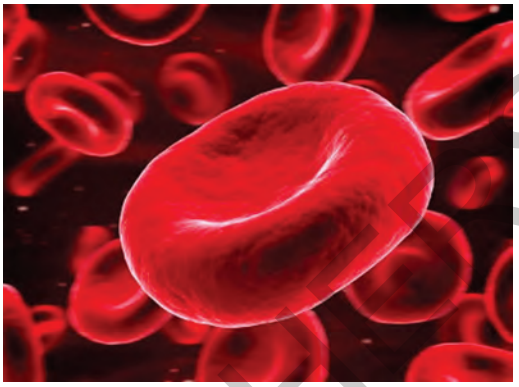

a. Leukocytes
b. Erythrocytes
c. Thrombocytes
d. Monocytes

**8. Identify the following cell.**

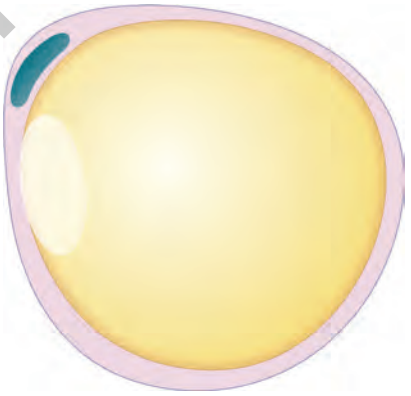

a. Fat cell
b. Muscle cell
c. Platelets
d. Basophil

| **Ans:** | 5. a | 6. c | 7. b | 8. a |
|---|---|---|---|---|

JAYPEE BROTHERS

for detailed information on nursing books, visit our website www.jaypeebrothers.com, for detailed information on nursing books, visit our websit

## Nursing Q-Bank Series *For BSc Nursing Students*

# Applied Anatomy & Physiology

*Salient Features*

- Covers recent applied anatomy and physiology university examination papers.
- Integrates theoretical understanding with practical nursing scenarios.
- Challenges critical thinking skills through varied question formats.
- Includes multiple choice questions (MCQs), short answer, long answer, practice and image-based questions.
- Provides clear explanations for each question to reinforce learning.
- Offers questions at different difficulty levels to accommodate student progression.
- Uses visual aids like diagrams and illustrations for better understanding.

**Monika Dean** MSc(N) (Obstetric and Gynecology), is currently working as Vice-Principal, Kailash Institute of Nursing and Paramedical Sciences, Greater Noida, Uttar Pradesh, India. She has done her postgraduation in Obstetrics and Gynecology from Chaudhary Charan Singh University, Meerut, Uttar Pradesh, and graduation from PGI University, Rohtak, Haryana. She has spent around 15 years in the healthcare sector, in teaching as well as in clinical practice. She has published 6 handbooks for auxiliary nurse midwife (ANM) with M/s Jaypee Brothers Medical Publishers (P) Ltd, New Delhi, India. She has also conducted an awareness program on COVID-19 for Paramedical Staff from different regions of the country. She is also motivated healthcare professional, public speaker and writer.

**Abha Narwal** MSc(N) (Community Health Nursing), is currently working as Professor, Shaheed Baba Deep Singh College of Nursing, Fatehabad, Haryana, India. She was born and brought up in Rohtak, Haryana. After completing her schooling in her hometown, she moved to Delhi in 2005 to pursue her BSc in Nursing. After completing her MSc from Bhopal's Barkatullah University, she worked as a Consultant Research Officer with the National Institute of Health and Family Welfare (NIHFW) in New Delhi.

**Rachna Khanna** MSc(N) (Obstetric and Gynecology), is working as Professor, Kailash Institute of Nursing and Paramedical Sciences, Greater Noida, Uttar Pradesh, India. She has done graduation in Nursing from Guru Nanak College of Nursing, Dhahan Kaleran, Punjab, and postgraduation from Dayanand Medical College and Hospital, Ludhiana, Punjab. She has been teaching Maternal Health Nursing, Child Health Nursing, Nursing Research & Statistics, and Nursing Management and Administration. She has many years of experience in teaching. She has also participated in various national and international conferences and workshops. She has reviewed textbooks of Obstetrics and Gynecology in Nursing.

**Nandani Kumari** MSc(N) (Medical Surgical Nursing), is Nursing Officer, Vardhman Mahavir Medical College (VMMC) and Safdarjung Hospital, New Delhi, India. She has done her MSc in Surgical Nursing from CCS University and BSc Nursing from Army College of Nursing, Jalandhar, Punjab; Baba Farid University of Health Sciences, Faridkot, Punjab. She has many years of experience in teaching, research, and clinical settings. She is an Ex-Faculty for BSc (Nursing) degree and diploma programs in Metro College of Health Sciences and Research, Greater Noida, Uttar Pradesh. She has published numerous articles in national and international journals and actively participates in various national and international workshops and conferences held by the Indian Nursing Council (INC).

*Printed in India*

**Available at all medical bookstores**
**or buy online at www.jaypeebrothers.com**




**JAYPEE BROTHERS**
**Medical Publishers (P) Ltd.**
**EMCA House, 23/23-B, Ansari Road,**
**Daryaganj, New Delhi - 110 002, INDIA**
**www.jaypeebrothers.com**

Join us on facebook.com/JaypeeMedicalPublishers

ISBN 978-93-5696-532-4

