formation on critical care books, visit our website www.jaypeebrothers.com, for detailed information on critical care books, visit our website www.jaypeebrothers.com

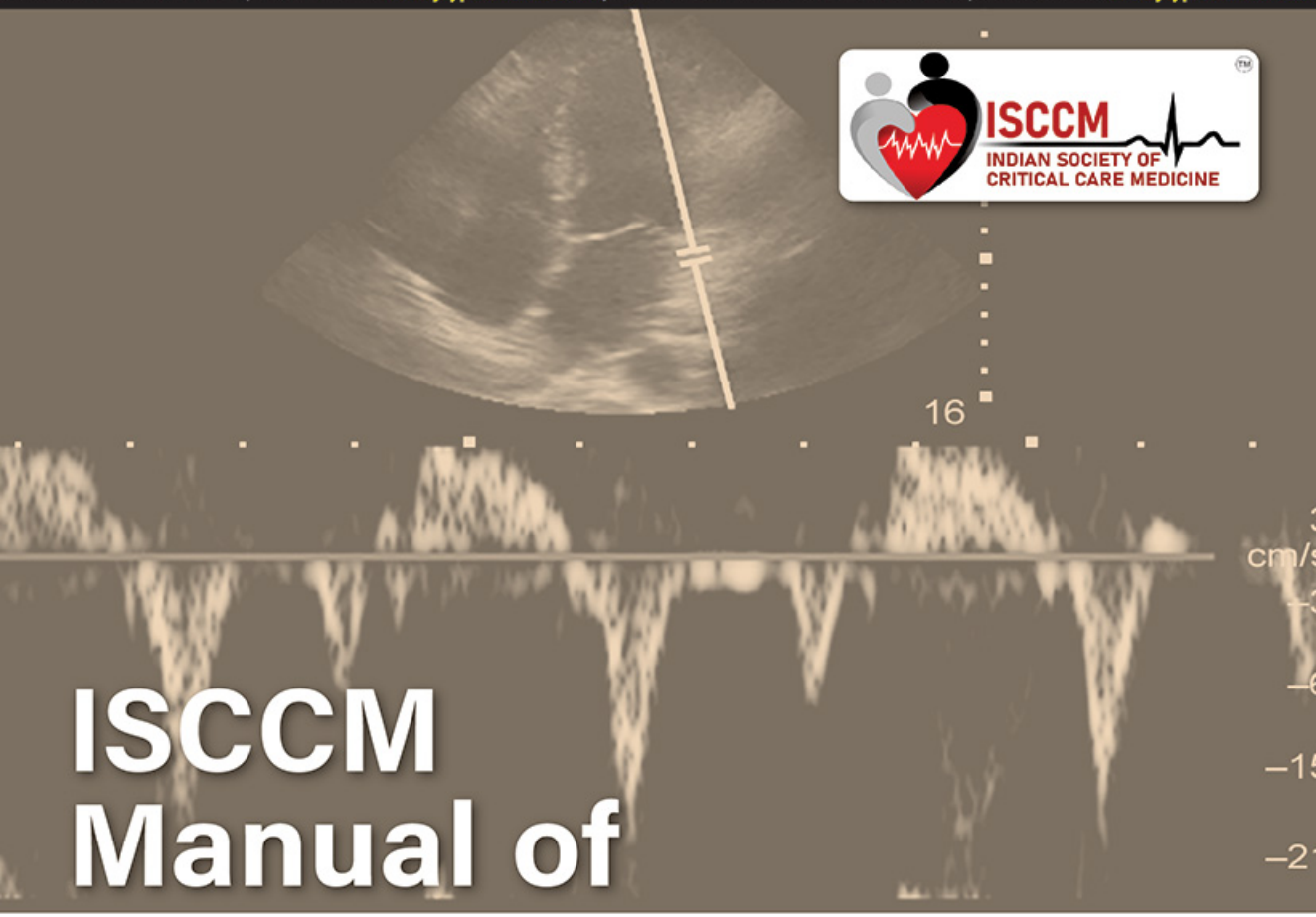

ISCCM Manual of Critical Care Ultrasound

Editors
Deepak Govil
Shrikanth Srinivasan
Sachin Gupta

2nd Edition

Foreword
Sheila Nainan Myatra

JAYPEE

Contents

SECTION 1: Introduction to Ultrasonography in Critical Care

1. **Introduction to Point-of-Care Ultrasound 3**
   Deepak Govil, Shrikanth Srinivasan, Sachin Gupta, Devireddy Madhava Reddy
2. **Physics of Ultrasonography 6**
   Rakesh Mohanty, Moosa Hussain, Amol Trimbakrao Kothekar
3. **Understanding the Machine: Probes, Knobs, and Utility 34**
   Ankit Sharma, Rahul Harne, Jagadeesh KN

SECTION 2: Neurosonography

4. **Ocular Ultrasonography and Optic Nerve 55**
   Jojo Kurien John
5. **Transcranial Doppler 66**
   Jojo Kurien John
6. **Cranial Ultrasound for Intracranial Pathology 77**
   Jojo Kurien John

SECTION 3: Airway Ultrasonography

7. **Airway Ultrasonography: A Comprehensive Approach 89**
   Kapil Dev Soni

SECTION 4: Respiratory System Ultrasonography

8. **Basics of Lung Ultrasound 101**
   Pradeep D'costa
9. **Lung and Pleural Pathology I: Pleural Effusion, Pneumothorax, Consolidation, and Atelectasis 113**
   Anuj M Clerk

10. **Lung and Pleural Pathology II: Pulmonary Edema, Lung Ultrasound Score, and ARDS** 126
Shrikanth Srinivasan

11. **The Diaphragm by Ultrasound** 136
Kishore Pichamuthu, Divya Pal, Parimal B Patel

SECTION 5: Cardiovascular Ultrasonography

12. **Basic Views on Transthoracic Echocardiography** 153
Kishore Pichamuthu

13. **Echocardiography: Left Heart** 166
Vivek Kumar

14. **Diastolic Dysfunction** 206
Vinay K, Sunil Karanth

15. **Right Heart Assessment** 215
Amol Trimbakrao Kothekar, Abhishek Singh, Rakesh Mohanty

16. **Pericardial, Valvular Assessment, and Intracardiac Masses** 238
Kedar Toraskar

17. **Dynamic Left Ventricular Outflow Tract Obstruction** 250
Rahul Pandit

18. **Deep Vein Thrombosis** 255
Sachin Gupta, Deeksha Singh Tomar

19. **Ultrasonography of Aorta** 265
Jayant R Shelgaonkar

20. **Transesophageal Echocardiography: Knobology and Views** 279
Vivek Kumar

SECTION 6: Abdominal Ultrasonography

21. **Hepatic and Biliary Assessment by Ultrasound** 313
Anant Vikram Pachisia, Swagat Pattajoshi, Rahul Harne

22. **Renal Ultrasound in Critically Ill** 327
Kapil Dev Soni

23. **Gastric Ultrasound** 334
Abhishek Mukundbhai Prajapati, Rachit Jayeshkumar Patel

24. **Bowel Ultrasound** 340
Vivek Kumar, Rachit Jayeshkumar Patel, Abhishek Mukundbhai Prajapati

SECTION 7: Soft Tissue Sonoanatomy, Gross Tissues, and Pathologies

25. Soft Tissue and Musculoskeletal Ultrasound—Normal Sonoanatomy and Pathologies 359
Divya Pal, Jagadeesh KN, Keerti Brar

26. Spine Ultrasound and Lumbar Puncture 371
Shrikanth Srinivasan

SECTION 8: Ultrasonography in Clinical Scenarios

27. Point-of-Care Ultrasound—EFAST Scan 385
Kapil Dev Soni

28. Approach to Acute Dyspnea 394
Sachin Gupta, Deeksha Singh Tomar, Ashish Devendra Mishra

29. Ultrasonography-guided Fine Tuning of Mechanical Ventilation 410
Shrikanth Srinivasan

30. Point-of-Care Ultrasound in Weaning 418
Devireddy Madhava Reddy, Sweta J Patel, Ronak Zatakiya

31. Approach to Undifferentiated Shock 424
Amol Trimbakrao Kothekar, Keyurkumar Bhupendrakumar Shah, Anand Vinaykumar Joshi

32. Fluid Stewardship Using Ultrasonography 443
Pooja Tyagi, Divya Pal, Sweta J Patel

33. Ultrasonography in Cardiac Arrest 461
Anuj M Clerk

SECTION 9: Ultrasound-guided Procedures

34. Airway-related Procedures 481
Shrikanth Srinivasan, Ajeet Singh

35. Invasive Abdominal Procedures 491
Sachin Gupta, Deeksha Singh Tomar

36. Vascular Access 500
Sudipta Mukherjee, Pralay Shankar Ghosh

37. Pericardiocentesis and Thoracocentesis 514
Rahul Pandit

Index 523

CHAPTER 3

Understanding the Machine: Probes, Knobs, and Utility

Ankit Sharma, Rahul Harne, Jagadeesh KN

JAYPEE BROTHERS

INTRODUCTION

Ultrasound has been used in medicine for almost half a decade and now it is one of the most widely used diagnostic tools in medicine. Traditionally, it has been the domain of radiologists, but this is rapidly changing. Technological advancements have yielded more compact and portable ultrasound machines with excellent imaging qualities which are rapidly getting integrated into standard of care. Especially in the field of critical care and emergency medicine, it has become an indispensible tool where instant evaluation of shock, trauma and sepsis, and cardiorespiratory failure gives that valuable sense of confidence and direction to the caregivers. Along with the ultrasound guidance in various procedures such as central venous access and drainage of fluid and pus from various sites it is also finding increasing usage in complex procedures like percutaneous tracheostomy and central-neuraxial blocks.

Acquaintance with sonography is like learning a new language hence familiarizing with the jargon of ultrasound and learning the basic principles is the first step in this direction. Ultrasound machine can look a bit intimidating to the new learner and this chapter aims to provide this basic information about the machine, its probes, various soft skills that can be employed for optimal imaging of the object under interrogation, and also teaches you about the safety aspects like sterilization disinfection of the probes.[1]

What is ultrasound?

Simply stating it is a high frequency sound wave and sound itself is a mechanical propagation of a series of compressions and rarefactions traveling through a medium. Upper limit of the audio frequency detected by the human ear is 20,000 Hz. The medical ultrasound uses frequency ranging from 2 to 20 MHz.

How is ultrasound produced?

Such high frequency sound waves are generated by utilizing the unique quality of the piezoelectrical crystals (lead zirconate titanate) through which if an electric current is passed, they expand and contract or simply saying they vibrate (think of the "Tuning Fork") and in the process release ultrasound waves. The other feature of these crystals is that they deform after encountering the returning ultrasound wave as they reflect back and in the process release small voltages which are utilized by the machine for image generation.[2]

ULTRASOUND TRANSDUCER

The probe which the operator utilizes for interrogating the particular body part for visualization is called a "transducer". Each probe basically harbors the piezoelectric crystals in a row just

beneath the scan-head. Crystals would spend only 1% of the time generating the sound waves and remaining 99% of the time would be utilized for listening to the returning echo thus effectively translating them for interpretation into an image.[3]

Various types are available according to the design, size, and frequency. Most commonly utilized probes are linear, curvilinear, and phased array **(Figs. 1 to 4)**.

- *Linear array:* This is a high frequency probe with frequency range of between 6 and 18 MHz, designed specifically for examination of superficial structures. Commonly used to perform musculoskeletal examination, vascular catheterizations, and other procedures like superficial nerve blocks. Scanning surface of the probe is flat, hence, the image generated is rectangular and similar to the length of the probe. Operator has the option of

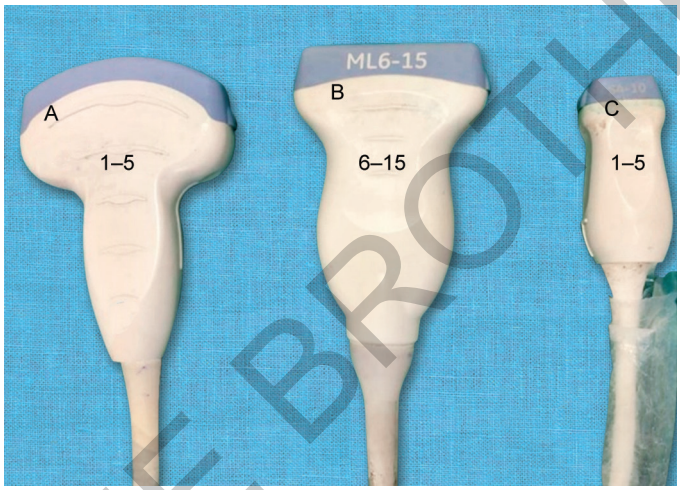

Fig. 1: Transducers (A) Curvilinear; (B) Linear; and (C) Phased array.

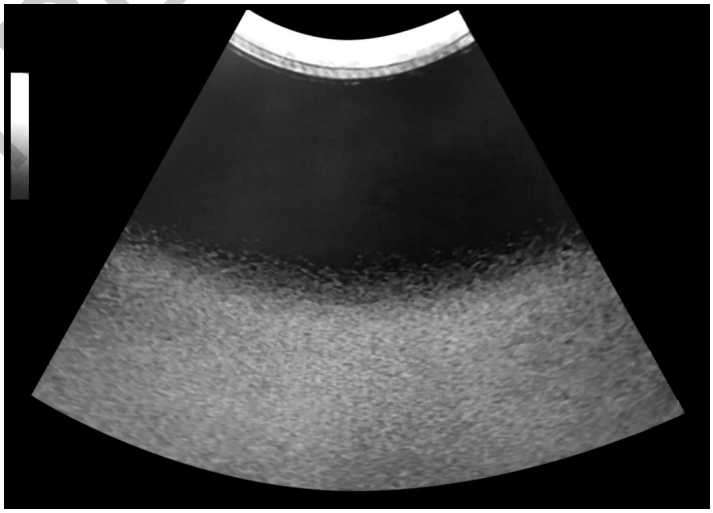

Fig. 2: Pie-shaped image sectoral image of curvilinear probe.

JAYPEE BROTHERS



Fig. 3: Rectangular image of linear probe.

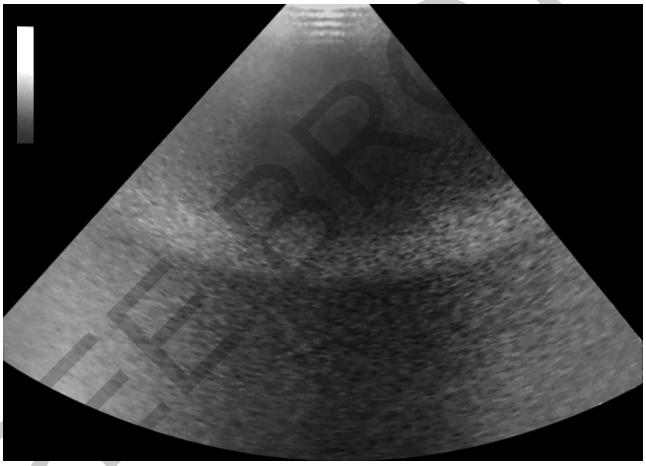

Fig. 4: Pie-shaped sectoral image of phased-array probe.

selecting the frequency desirable as per the area under interrogation. Some machines only allow the selection of the lowest, the highest, and the middle frequency by giving options of penetration, resolution, and general in the selection panel.

- *Curvilinear array:* This is a low frequency probe with frequency range between 1 and 5 MHz, designed for examination of structures lying deeper as in the abdominal, pelvic, and thoracic scans. The image sector on the screen is of the shape of a pie slice. It is larger than the actual length of the probe because the sound waves fan outward.
- *Phased array:* This is also a low frequency probe with frequency range between 1 and 5 MHz, designed mainly for echocardiography. The small scanning head allows for easy placement in intercostal space. The unique feature of this probe is that the wave-generating crystals are tightly packed in the scan head and get activated in a phasic way from one edge

JAYPEE BROTHERS

to the other along with each pulse (sweeping motion). Screen image generated is of the shape of a pie and is much larger than the probe length.

- *Hockey stick transducer:* This small footprint linear assay transducer has higher frequency compared to the other transducers (8–18 MHz). It is used for evaluating smaller superficial structures like peripheral nerves because of its superior image resolution **(Fig. 5)**.

Each probe has a marker, the marker helps the operator to orient the image on the screen with anatomical structures being interrogated. Marker may be a ridge, indentation, groove, or a nudge on one side of the probe **(Fig. 6)**.

Generally, the marker is kept cephalad or toward the right side of the patient and this correlates with the corresponding marker on the screen which is on the top left of the screen. Cardiac examination with phased-array probe—the marker on the screen is conventionally on the top right of the screen **(Figs. 7 and 8)**.



Fig. 5: Hockey stick transducer.



Fig. 6: Indicator (orientation marker) on probe.

JAYPEE BROTHERS

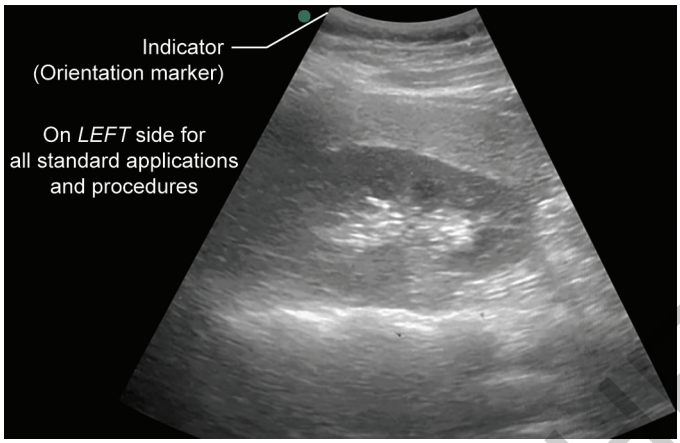

Fig. 7: Indicator on *left* side for all standard applications and procedures.

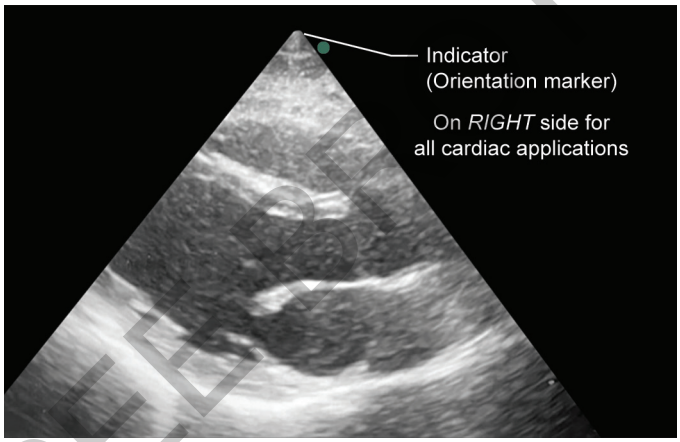

Fig. 8: Indicator on *right* side for all cardiac applications.

How is the image formed on the screen of ultrasound machine?

Ultrasound waves generated from the scan-head of the probe travel forward and after encountering various structures in the line of propagation like any other wave they reflect back as echo and these returning waves or echo signals again encounter the piezoelectric crystals leading to their deformation which in turn produces electrical signals in the form of small voltages. These voltages are finally interpreted by the machine and depicted as tiny dots of varying brightness on the screen depending upon the strength of the signals. Location of these dots on the screen is determined by the time it takes for echo to reach back the crystals on the scan-head. Utilizing the simple equation of "Distance = Velocity × Time" accurately depicts the depth of the structures encountered.

The returning echos have wide variety of strengths and integrating these values with their respective locations, the machine plots these dots on to the two-dimensional (2D) screen to form an image.

JAYPEE BROTHERS

DEPTH OF PENETRATION AND FREQUENCY OF ULTRASOUND WAVES

Frequency of the ultrasound waves determines two aspects of the wave dynamics.

1 Resolution or the quality
2. Depth of penetration

Points to remember are:

- Higher the frequency of the probe sharper will be the resolution and lesser will be the depth it will penetrate into the tissues, e.g., 12 MHz probe.
- Lesser the frequency of the probe higher will be the depth of penetration, but at the cost of losing the resolution, e.g., a 3-MHz probe.

What happens to the ultrasound wave once it enters the tissue?
As the ultrasound wave enters the tissue under interrogation, it is important to understand its interaction with the tissues that come in its path.

Concept of Attenuation

Weakening of the ultrasound wave as it travels deeper in the tissue. The parameters of strength, i.e., amplitude, power, and intensity, all decrease proportionally with penetration. Deeper imaging and higher resolution attenuate the most whereas shallower imaging and lower resolution attenuate the least. Hence, one must use optimal depth for optimal imaging of the target tissue.

Attenuation coefficient is the overall absorption of the acoustic energy held in the ultrasound beam which is measured in decibel/cm/MHz. Three major causes of attenuation are absorption, scatter, and reflection which are discussed in detail in the following text.

Concept of Acoustic Impedance

Ultrasound imaging is based upon the production and detection of the reflected echo which, in turn, is dependent upon the difference of the acoustic impedance between the two tissue types. Reflection of the ultrasound wave occurs at the interface of the tissues with different acoustic impedances. More the difference more will be the reflection. For example, when the ultrasound wave travels from tissue to air (lungs) because of very high difference in the acoustic impedances of the two structures almost 99% of the waves are reflected back and no further propagation of the wave can occur, and it results in production of bright white scatter on the screen. For the same reason, a gel is applied between the transducer scanning head and skin to eliminate any air for assisting the complete transmission of the sound wave. Various tissues have different acoustic impedances as described in **Table 1**.

Concept of Reflection, Refraction, Scatter, and Transmission

Reflection: Sound waves reflect from the interface between the two tissues and the amount of refection is directly proportional to the difference of the acoustic impedance as explained above. Another factor that determines the reflection is the smoothness of the surfaces between the two tissues.

JAYPEE BROTHERS

TABLE 1: Different acoustic impedances of various tissues.

Medium	*Acoustic impedance (kg/m^2/s)*	*Attenuation coefficient (dB/cm/MHz)*
Air	430	10.00
Water	1.48×10^6	0.00
Liver	1.66×10^6	0.94
Blood	1.67×10^6	0.18
Muscle	1.71×10^6	1.3–3.30
Bone	6.47×10^6	5.00

Refraction: This phenomenon occurs when the sound waves pass from one medium to the other with different propagation velocities. This leads to the alteration in the direction of the incident sound wave and apparent shift in the image formed by the machine. To overcome this artifact, it is suggested to direct the beam as perpendicular to the desired target as possible in order to reduce the artifact.

Scatter: When the sound wave reflects in many directions, very small percent of them would reach back to the transducer; thus, a weak image is generated and this occurs either because of the rough surface of the reflector or if the encountered tissue is smaller than the wavelength of the sound wave.

Transmission: The sound waves that travel further after getting unattenuated would ultimately reflect back from further down thus yielding more echo form structures deep below.

Image Acquisition

There are four basic movements of the probe that are performed to acquire the best image of the object under interrogation. These are sliding, tilting (fanning), rotating, and rocking **(Fig. 9)**. Another movement of the probe that is considered as a cardinal fifth movement is compression of the probe's footprint over the area where the best image acquisition is intended.

Image Resolution

The real aim of ultrasound wave is to generate a true image of the structures that it encounters in its path that differentiates between two unlike structures as closely as possible. This goal is accomplished by two factors:

1. Resolving capacity of the system that is characterized by:
   - *Axial/Lateral resolution:* Axial resolution determines the ability to identify two objects placed closely together along the axis of the sound wave as two separate entities. Higher the frequency better the axial resolution because the chances of the wave hitting the two objects at distinctly increases.
   - Lateral resolution determines the ability to identify the two objects placed closely together but lying perpendicular to the axis of the sound wave. Amplitude of the wave governs the lateral resolution.

JAYPEE BROTHERS

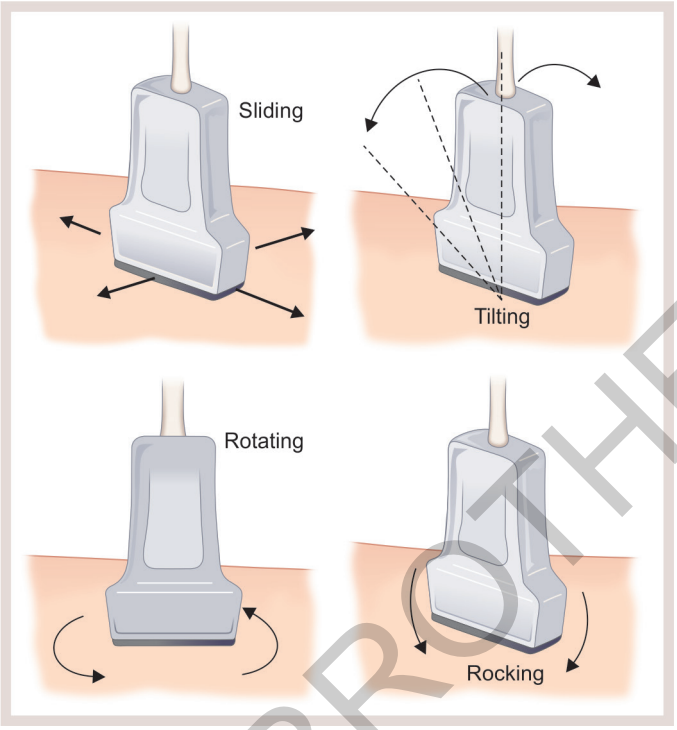

Fig. 9: Four basic movements of the probe.

- *Spatial resolution:* Combining the axial and lateral resolutions yields the ability to distinguish precisely between the two objects and display them as distinct entities. It is also known as "detail resolution".
- *Contrast resolution:* It is the ability to distinguish between two objects of similar echo properties to be identified as two distinct objects on the image. This feature is a dynamic range of the system. Dynamic range actually determines the number of shades of gray dots that can be depicted on the screen, thus, finely differentiating the similar looking tissues. Most of the modern machines can project 256 shades of gray appreciable to the naked eye.
- *Temporal resolution:* This feature determines the ability of the system which accurately locates the position of the structures that are mobile at any given instant in time like heart valves. This feature is dependent upon the frame rate of the system.

2. Processing power of the system which depends upon the ability of the machine capture. Preserve and display the images as accurately as possible.

In general, resolution of the image inherently depends upon the frequency of the sound wave and higher the frequency better will be the resolution.

Images on the screen are commonly described as following **(Fig. 10)**.

- *Anechoic*—an image that produces no echo and appears as black as it allows the whole of the wave to be transmitted, e.g., fluid-filled structures like cavity of cysts and urinary bladder.

JAYPEE BROTHERS

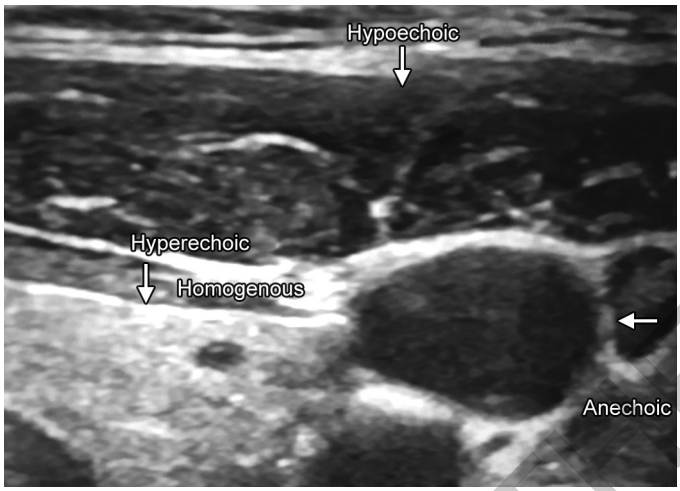

Fig. 10: Anechoic, hyperechoic, hypoechoic, and homogenous description of ultrasound images.

- *Hypoechoic*—an image that appears less brighter than the surrounding structures.
- *Hyperechoic*—an image that appears brighter than the surrounding structures.
- *Homogeneous and heterogeneous*—images with similar or differing echo characteristics respectively.

Display Modes

Returning echos are collated and the processor of the machine displays the information in the form of an image on the screen. Three main modes are:

1. *B (brightness) mode:* Depending upon the amplitudes of the reflected echos and integrating them with time of their arrival the image is formed with various shades of gray and white dots closely depicting the anatomical layout in the 2D section in which the sound wave had traveled. Also referred to as the 2D mode on the machine consoles.
2. *M (motion) mode:* This mode depicts the movement of the tissue under interrogation. Here, only one of the crystals on the scan head of the transducer is active and it sends off the beam and then listens to the returning echo. Sound wave is targeted in a particular direction and the stationary structures are displayed as straight lines whereas the mobile structures yield a sinusoidal pattern on the screen. Particularly used to measure the changes cavity sizes of structures such as heart chambers or vessels in various stages of contraction and relaxation.
3. *D (Doppler) mode:* Doppler imaging is an essential aspect of medical ultrasound that is used for determining the blood flow, its direction, velocity, and derived parameters like pressure gradients across a particular orifice under interrogation.

It is based on the principal of Doppler shift which is defined as is the change in frequency of a wave in relation to an observer who is moving relative to the wave source.[1] It is named after the Austrian physicist Christian Doppler, who described the phenomenon in 1842. This principal explains the reason behind the observation of perceiving a high pitch of the siren moving toward the listener and a low-pitched siren moving away from the listener.[4]

JAYPEE BROTHERS

$$\text{Doppler shift} = f_r - f_T = \frac{2 \times f_T \times \text{velocity of object} \times \cos\theta}{\text{Propagation velocity}}$$

where, f_r = reflected frequency, f_T = transmitted frequency, and cosθ = incident angle correction.

Angle of insonation for perceiving the Doppler shift should ideally be lesser than 60°, if the ultrasound beam is perpendicular to the flow, then there will be no Doppler shift in spite of flow because cosθ at 90° = 0.

Doppler shift is measured in Hertz and typical values are in the range of 20 Hz–20 KHz and hence can be perceived by the human ear and forms the basis of audible Doppler.

Medical ultrasound utilizes the red blood cells that are moving in a vessel or across an orifice for targeting the Doppler shift examination and subsequently analyzing the direction and speed of blood flow in an audible, color, or spectral display.

Four commonly used Doppler modalities are: (1) continuous wave (CW), (2) pulsed wave (PW), (3) color flow Doppler, and (4) power Doppler.

1. *Continuous wave (CW) Doppler:* Two crystals in the scan head of the transducer are active: One is continuously transmitting and the other is continuously listening. It helps in accurately measuring high velocities.
2. *Pulsed wave (PW) Doppler:* Single crystal alternates between sending and receiving the signals and the echos can be adjusted through the use of a sampling and a specific depth at which the observation has to be made can be adjusted. When the imaging is superimposed on the Doppler interrogation it is called as Duplex imaging. Both CW and PW Doppler are a form of spectral display of the observed shift in frequency. Here, the velocity information is displayed quantitatively using a spectrogram which depicts Doppler shift on y-axis and time on x-axis. Direction of flow is depicted in relation to the baseline, with positive flows (flow toward the transducer) displayed above the baseline and negative flows (flow away from the transducer) below the baseline **(Fig. 11)**.
3. *Color flow Doppler:* It is a form of a 2D multigated Doppler where the frequency shifts are color-coded and superimposed on to a 2D image of surrounding stationary tissues. It is based on the principle of pulsed ultrasound and provides information regarding the direction of flow and can be interpreted from the color map or coding legend. Generally, red (for artery) is toward the transducer and blue (for vein) is away from the transducer but can be adjusted as per need.
4. *Power Doppler:* It is a relatively newer addition to the ultrasound Doppler diagnostics, introduced in 1993. It only displays intensity information in the region of blood flow and depicts it as a monochromatic color map. Higher the power, brighter and lighter the color. Important features of power Doppler are its angle independence, hence, its usefulness in imaging of tortuous vessels such as collateral circulation and its independence from aliasing. Only shortcoming is its sensitivity to motion and care is needed to keep the transducer stationary while using this modality.

Concept of Pulse and Pulse Repletion Frequency

A pulse is collection of cycles (number of wavelengths) that is released from the transducer and its duration is measured in seconds (typically comprised of 2–4 wavelengths and ranges

JAYPEE BROTHERS

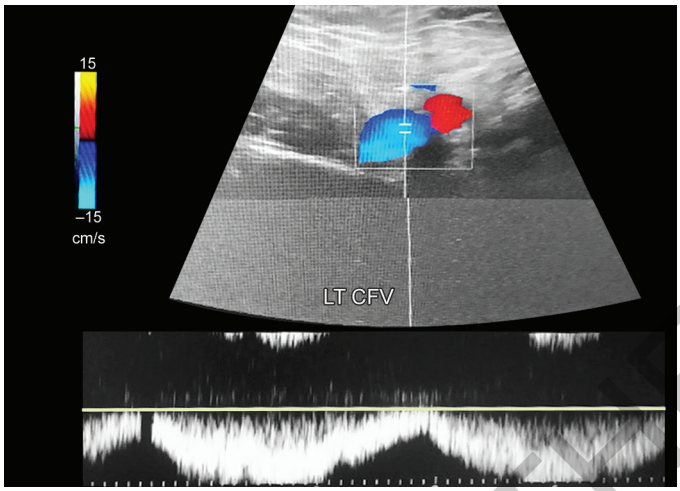

Fig. 11: Pulsed wave Doppler: Duplex image of common femoral vessels with color legend (red toward the probe and blue away from the probe).

from 0.5–3.0 μs). This aspect is fixed and cannot be changed. Pulse repletion frequency (PRF) is the number of pulses created per second (ranges from 1 to 10 kHz). PRF can be adjusted according to the depth of the desired interrogation. The dictum is decreasing the PRF for increasing depth and vice-versa.

Concept of Aliasing

Basic wave of physics principle states that the waveform can only be represented by its samples if they are obtained a minimum of twice its frequency. This is also known as a Nyquist limit and is defined as PRF divided by two since PRF is the sampling frequency at which the Doppler imaging is done.

Aliasing is the Doppler artifact that one must be aware of where high frequencies exceeding the Nyquist limit would be depicted as reverse flow colors and may be mistaken for true flow reversal. A common example is the appearance of reverse movements of the spokes of a forward moving wheel on the camera since the camera frequency is slower than the Nyquist limit. Thus, for higher velocities, a high PRF is set to avoid aliasing.

MACHINE: KNOBOLOGY—COMMON CONTROLS, FUNCTIONS, AND PRESETS

Some of the functions and controls are universal irrespective of the platform used to perform the ultrasound diagnostics and their familiarity aids the operator to get the most optimal images.

Depth

Frequency of the transducer predetermines its range of depth for interrogation. For example, high frequency of linear probes (10–15 MHz) cannot image deeper than 10–15 cm and

JAYPEE BROTHERS

conversely low frequency of curvilinear probes (2–5 MHz) is incapable of providing optimal images at superficial depth. With the use of appropriate transducer, depth can further be optimized to keep the desired target at the center of the screen where the image formation is the sharpest. Most of the machines display depth along the screen with hash marks denoting the units of measurement **(Figs. 12A and B)**.

Focus

Ultrasound waves leave the probe head and assume a shape of an hour-glass, typically having a narrow zone in the middle, where the echo generation is maximum. This zone is known as the focus of the beam. Focal point of the waves is generally marked by a symbol along the side of the screen as shown in **Figures 13A and B**. This focus zone can also be adjusted by the operator for optimal image acquisition. Point to remember is that this enhanced focus (read as lateral resolution) comes at the cost of lesser temporal resolution.

Zoom is another feature available which simply magnifies the area of interest, but this may occur at the cost of decreased resolution. Care must be taken while performing procedures

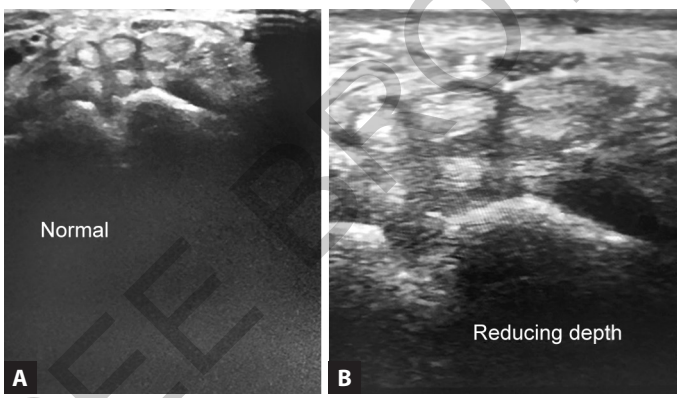

Figs. 12A and B: Reducing depth with linear probe to improve resolution of the structures on volar aspect of wrist in transverse section.

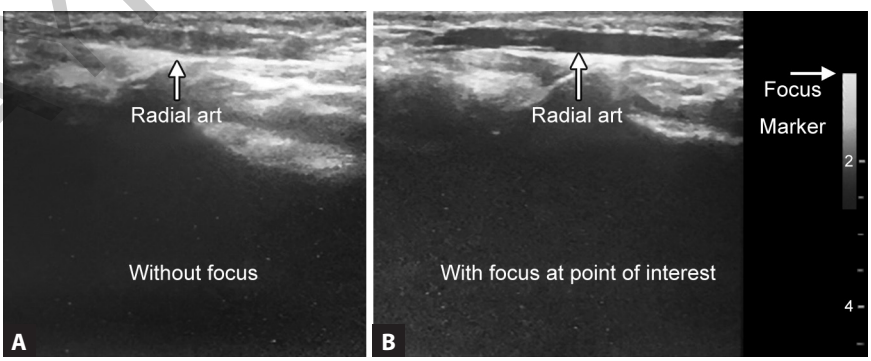

Figs. 13A and B: Using the focus feature for image optimization: Longitudinal section of wrist, volar aspect.

JAYPEE BROTHERS

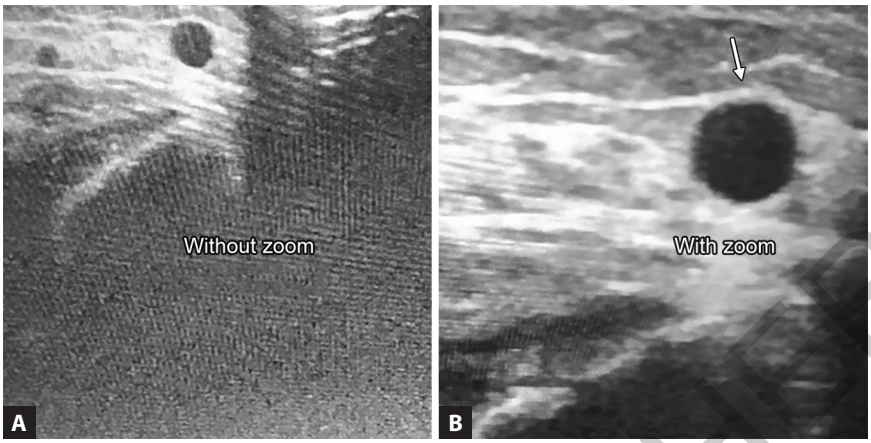

Figs. 14A and B: Zoom feature for optimal imaging of radial artery on the transverse section of volar aspect of wrist.

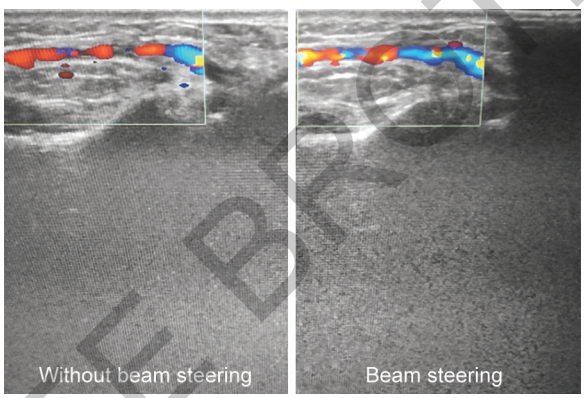

Fig. 15: Beam steering for optimal flow detection on color Doppler of radial artery.

using this mode in the sense that the topmost border in the zoomed area is not the most superficial zone **(Figs. 14A and B)**.

Beam steering is a feature that allows the operator to insonate a structure, typically a vessel, at an angle as close to being parallel to the flow as possible. Steering helps in optimizing the capture of the Doppler shift in the frequency and subsequent analysis of the velocities and gradients **(Fig. 15)**.

Gain, Automatic Gain Compensation, and Time Gain Compensation

As it is understood that the energy held in the ultrasound waves get attenuated as it traverses the tissues and the returning echos lose the strength and the resultant image appears less bright. Operator can compensate for this attenuation by adjusting the gain. By increasing the gain, overall brightness increases. Too much increase in gain can lead to a bright scatter on the screen as it indiscriminately enhances all signals including that of the associated noise. Gain feature is something like increasing the volume of the speakers of an audio system, whereby the loudness increases but the quality remains unaffected **(Fig. 16)**.

JAYPEE BROTHERS

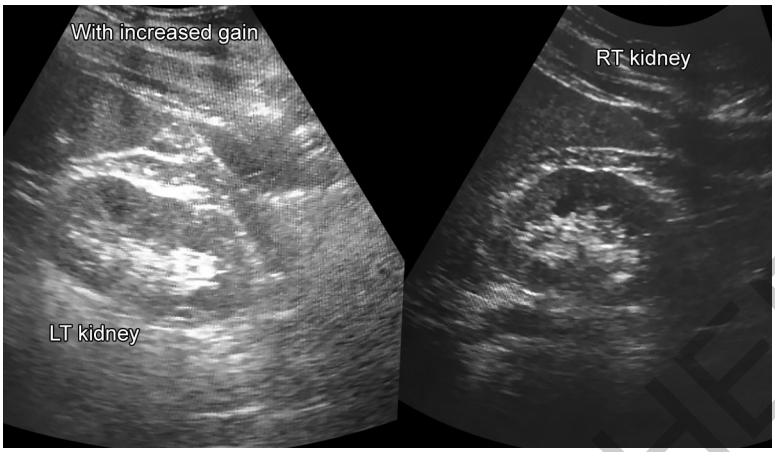

Fig. 16: Demonstration of increased gain leading to overall increase in brightness.

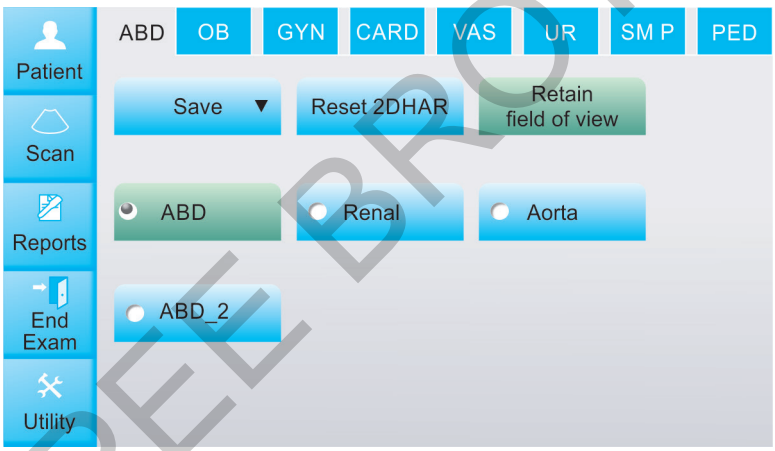

Fig. 17: Example of a preset configurations.

Since attenuation is a feature that increases with depth, most of the modern machines allow for the depth-wise alteration of the gain component in the form of a series of slider controls or knobs. This feature is known as "Time Gain Compensation". Automatic gain control feature as the name suggests automatically adjusts for attenuation loss at depths with a single button push.

Presets

Ultrasound machines are equipped with appropriate settings for select applications such as abdominal, thoracic, cardiovascular, superficial nerves, and vessels sonography. The operator can select the appropriate presets after choosing the specific transducer. It usually provides a reasonable starting point to begin the relevant interrogation **(Fig. 17)**.

JAYPEE BROTHERS

Artifacts

It is extremely important to understand the limitations of the ultrasound diagnostics and awareness of the commonly encountered false or inaccurate image display can prevent interpretation errors. On the other hand, the comprehending the origin of some of these artifacts can aid in finer assessments of structures that were conventionally though to be nonassessable with ultrasound, like lung sonography, which is mostly the evaluation of the artifacts. Some of the commonly encountered artifacts are:

- *Reverberation artifacts* result from sound waves bouncing back and forth between the two tissues which are strong reflectors. Resulting time delay in echo to finally reach the transducer is interpreted by the machine as increasing depth of location of that particular structure and, hence, displayed as multiple equidistant lines. These artifacts are oriented perpendicular to the axis of the wave, but get clustered in the line of the wave, one over the other.
- *Ring down or Comet-tail artifacts* are also reverberation artifacts arise from the scatter produced along two closely placed reflectors. They appear as a single long-hyperechoic image parallel to the sound axis. Their examination is of vital importance and finds detailed description in the chapter of lung sonography.
- *Mirror-image artifacts* occur when there is a strong reflection of an echo from a smooth reflector and redirection of the beam to another structure lying in its preceding path. This results in the formation of a mirror copy of that structure that is placed below the reflector. Unawareness of this artifact might result in interpretation of an abnormal anatomical finding. Liver mirror artifact may get misdiagnosed as a hepatized lung below the diaphragm.
- *Acoustic shadowing* is an artifact that is produced when the ultrasound wave encounters an object with very high acoustic impedance such as bone, stone, etc. It results in a formation of a hypoechoic or anechoic band below that object because of reflection of most of the sound waves from that object. Probe manipulation to avoid the attenuating structure would ablate this artifact.

Saving the Image

There is an option of freeze available on almost all of the ultrasound machines that allows the operator to take a snapshot of the screen at any given point. Before saving the image to the machine hard drive the operator can also scroll through the previous frames for selecting the best image. Also, there is provision to record a loop of frames prospectively by using the clip button and the length of the loop can be adjusted.

Newer Developments in Point-of-care Sonography

- *Sheer wave elastography:* It is a newer ultrasound technology that can be used to assess the tissue stiffness at the bedside. Transducer delivers high intensity pulses that produce shear waves, which generate high-intensity images. It is measured in shear modulus units after superimposition in the B-mode imaging using various algorithms **(Fig. 18)**.

  It can be used as a surrogate of transdiaphragmatic pressure in ventilated patients, assessment of diaphragm for weaning prediction, and also for noninvasive intracranial pressure assessment.

JAYPEE BROTHERS

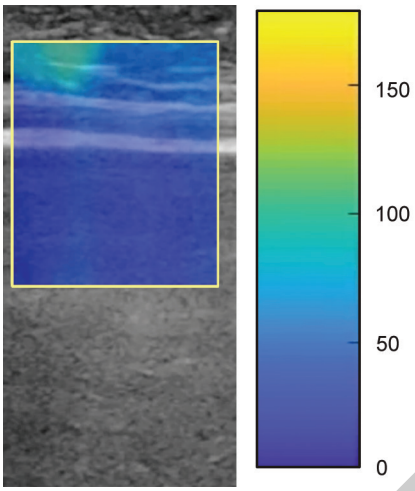

Fig. 18: Sheer wave imaging of diaphragm.

- *Advanced ultrasound probes:* Advancement in technology and refinement in construction of portable ultrasound machines have culminated in miniaturization of ultrasound machine and ultrasound probes. Major obstacle for the use of ultrasound in many clinical areas is availability of ultrasound machine, lack of experience, training in using the technology, guidance, and supervision. To facilitate proctored training and remote supervision, economical probes were brought into market. These are handheld or pocket probes.

Technology

Instead of costly piezoelectric crystals, on chip technology depicting linear, phased array, and curvilinear probes involving around 9,000 sensors are used. Voltage created by membrane sends waves into tissues and can be displayed on mobile screens. Frequency of the probe is between 1 and 5 Hz.

Single probe, in place of three probes, functions as linear, curvilinear, and phased-array probe thus reducing the overall cost of investing in three individual probes.

Added Features

Probes can be used with laptops and mobile devices operating on Macintosh, Windows, and Android, iOS respectively, after downloading proprietary software from respective website.

As in regular portable US machines, examination presets are provided to optimize examination modes, such as lungs, cardiac, abdomen, nerves, and small parts. Labeling of the various parts is also included. Examinations can be stored locally to the hard disk in laptop or transmitted to the cloud-based server for review immediately or later.

Safety features such as exposure time, mechanical index, and thermal index are inbuilt.

Augmented reality helps and guides in real time to obtain optimum images and interpret them. Procedural guidance in real time makes bedside procedures easy for the beginners.

JAYPEE BROTHERS

Artificial intelligence helps in giving feedback in real time about quality of images obtained and standard images guidance. This helps in maintaining quality of examinations and interpretation.

Advantages

- Overall cost is less in comparison to traditional portable US machine and individual probes.
- Network connectivity enables in real-time transmission of the images for the purpose of training and supervision among users.

Disadvantages

- Image quality is inferior in comparison to standard probes. PW, CW, and color Doppler quality are poor.
- Spectral Doppler is not feasible yet on this platform.
- Prolonged use of >15–20 minutes is the upper limit of usage, as the probe gets heated limiting the usage.
- Battery life at one charge is 2–3 hours.
- Storage of captured images on a server outside India incurs additional cost and ethical issues for now.

Disinfection and Sterilization of the Equipment[5]

Contamination risk: As the ultrasound finds increased point-of-care usage in intensive care setup, probe contamination becomes a real threat with its incidence ranging from 17.5 to 22.6%.[5] There are reports of bacterial outbreaks associated with inadequate cleaning of the probes prior to guided procedures.[6]

Transducer Decontamination

Before disinfection, it is recommended to perform proper cleaning of the probe and removal of any debris, gel, or other body fluid visible on the probe with soap and water. Many manufacturers follow *Spaulding classification scheme*[5] that classifies medical equipment decontamination based on the risk of infection transmission into:

- *Critical (probe is exposed to normally sterile tissue):* It pertains to intraoperative ultrasound use and mandates sterilization between each patient and use of a sterile sheath cover.
- *Semi-critical (probe is exposed mucous membrane or nonintact skin):* This requires high-level disinfection (HLD) that would eliminate all microbes except for spores and is recommended to use sterile sheath, e.g., procedures like central venous catheter insertions.
- *Noncritical (probe is exposed to intact skin):* Intact skin acts like a barrier to the microbes and a low-level disinfection (LLD) would be sufficient which shall remove most of the bacteria.

DECONTAMINATION OF ULTRASOUND PROBE (TABLE 2)

- For the purpose of *complete sterilization* for critical devices, it is recommended to use ethylene oxide or peracetic acid for the probes along with sterile sheath as cover before use.

JAYPEE BROTHERS

TABLE 2: Guide for cleaning the ultrasound probe.

Transducer	*Procedure*	*Use of transducer cover*	*Recommended cleaning method LLD or HLD*
External	Intact skin	No	LLD
	Open wound	Yes	HLD
	Intact infected skin	No	HLD
External needle-guided procedures	Peripheral IV line insertions/CVC or PICC insertions/pleural tap/ascites tap or pigtail insertions	Yes	HLD

(CVC: central venous catheter; HLD: high-level disinfection; LLD: low-level disinfection; PICC: peripherally inserted central catheter)

- For the purpose of achieving *HLD,* there is a range of products available that require the probe to be immersed in the disinfectant solution. Care must be taken to choose the disinfectant in order to ensure its compatibility with probe, instructions provided by the manufacturer and the level of disinfection required based on the *Spaulding classification*. Also, the operator must know the length of disinfection time and the risk of toxic exposure to the operator and patient.

  Glutaraldehyde is the most commonly used HLD. Time required for disinfection ranges from 5 to 45 minutes. Because of the associated toxicity, their use is not recommended for noncritical category of devices. Operator must be cautious as not to immerse the whole probe into the solution as the entire probe is not electrically insulated and this may lead to damage of the probe and carries the risk of causing electric shock. It must be noted that some of the manufacturers strictly discourage the use of alcohol-based solutions or betadine for the HLD instead they advocate the use water-based disinfectants like aqueous chlorhexidine solution.

  Hydrogen peroxide mist device can also be used for HLD which ablates the potential for errors in disinfection time and also eliminates the risk of toxicity to the patient or the operator.
- For the purpose of *LLD* of the noncritical devices, it is recommended to use either of the following disinfectants, after carefully scanning for contraindications in the manufacturer's instructions. These are isopropyl alcohol, quaternary ammonium compounds, and phenolics.

Sterile Sheath and Probe Cover

Commercially available transducer covers are available to wrap the entire probe along with cord. Risk of perforation of the cover is always there and, hence, even if the operator uses them, it is still recommended to perform the HLD for the critical and semi-critical devices.

A sterile Tegaderm film is commonly used to cover the probe after wrapping the rest of the cord and base of the probe with a sterile drape. Such techniques are useful for performing aseptic noncritical procedures like central line insertions and ascetic/pleural taps. The safety

JAYPEE BROTHERS

of such methods is still a matter of concern and there are no recommendations regarding their use in an established protocol, but there is no report of any increased risk of infection while using them in this way. Rate of infection with ultrasound guidance is similar to that of traditionally placed peripheral intravenous line placements. Currently, such procedures are deemed noncritical and at least the LLD must be performed for such procedures besides taking all general aseptic precautions.

As a word of caution regarding the risk of infection transmission following ultrasound examinations and guided procedures, author recommends that each intensive care setup where ultrasound-guided procedures and examinations are carried out the hospital infection control team and the intensive care physicians should collectively make a policy for ensuring a protocol-based method of sterilization and disinfection of the ultrasound probes and ensure strict adherence to it.

CONCLUSION

It is important to get acquainted with the machine and the knobs, so that it can be utilized to its fullest. Bedside ultrasonography has now become a standard of care in the intensive care unit, so acquiring the soft skills is important for better image optimization.

REFERENCES

1. Rippey J. Ultrasound guidance should be the standard of care for most invasive procedures performed by clinicians. Australas J Ultrasound Med. 2012;15(4):116-20.
2. Edelman SK. Ultrasound physics and instrumentation. Woodlands: ESP, Inc.; 2016.
3. Szabo TL, Lewin PA. Ultrasound transducer selection in clinical imaging practice. J Ultrasound Med. 2017.
4. Taylor KJ, Holland S. Doppler US. Part I. Basic principles, instrumentation, and pitfalls. Radiology. 1990;174:297-307.
5. Mirza WA, Imam SH, Kharal MS, Aslam M, Ali SA, Masroor I, et al. Cleaning methods for ultrasound probes. J Coll Physicians Surg Pak. 2008;18(5):286-9.
6. Australasian Society for Ultrasound in Medicine (ASUM). Guidelines for Reprocessing Ultrasound Transducers. Australas J Ultrasound Med. 2017;20(1):30-40.

JAYPEE BROTHERS

etailed information on critical care books, visit our website www.jaypeebrothers.com, for detailed information on critical care books, visit our website www.jaypeebro

ISCCM Manual of
Critical Care Ultrasound

Salient Features

- This is the Second Edition of the Indian Society of Critical Care Medicine (ISCCM) book on use of ultrasound in critically ill patients
- It covers evidence-based protocols of ultrasound that have been explained with illustrative images of pathologies
- It also has a separate section on utility of ultrasonography in different clinical scenarios
- This book covers head-to-toe aspects of ultrasound application in ICU patients
- It has been written by experts in the field of ultrasound with astute clinical acumen
- This manual will serve as a reference book for young intensivists, anesthesiologists, pulmonary and emergency physicians, and trainees who are working in acute care settings.

Deepak Govil MD EDIC FCCM FICCM
Vice Chairman
Institute of Critical Care and Anesthesiology
Medanta—The Medicity
Gurugram, Haryana, India

Shrikanth Srinivasan MD DNB FNB EDIC FICCM
Head
Department of Critical Care Medicine
Manipal Hospital, New Delhi, India

Sachin Gupta MD IDCCM IFCCM EDIC FCCM FICCM
Director
Department of Critical Care
Narayana Superspeciality Hospital
Gurugram, Haryana, India

Printed in India

Available at all medical bookstores
or buy online at www.jaypeebrothers.com

JAYPEE BROTHERS
Medical Publishers (P) Ltd.
EMCA House, 23/23-B, Ansari Road,
Daryaganj, New Delhi - 110 002, INDIA
www.jaypeebrothers.com

Join us on facebook.com/JaypeeMedicalPublishers

Shelving Recommendation
CRITICAL CARE

ISBN 978-93-5696-580-5