it our website www.jaypeebrothers.com, for detailed information on dermatology books, visit our website www.jaypeebrothers.com



Fungal Infections

with Color Atlas



SK Punshi

JAYPEE

Contents

CHAPTER 1:	Introduction of Fungal Infection (Basic Science)	1
CHAPTER 2:	Prevalence of Fungal Diseases	4
CHAPTER 3:	Classification of Fungal Infection	6
CHAPTER 4:	Fungal Infections (Mycosis)	9
CHAPTER 5:	Pityriasis Versicolor (Tinea Versicolor, Dermatomycosis, Furfuracea, Chromophytosis)	11
CHAPTER 6:	Candidiasis	18
CHAPTER 7:	Tinea Capitis	29
CHAPTER 8:	Tinea Corporis	33
CHAPTER 9:	Tinea Cruris	35
CHAPTER 10:	Tinea Unguium	37
CHAPTER 11:	Tinea Pedis	40
CHAPTER 12:	Indian Scenario	41
CHAPTER 13:	Sources of Fungal Infections with Causative Agents	43
CHAPTER 14:	Management of Dermatophytosis in Patients with Concomitant Systemic Diseases and Dermatoses	46
CHAPTER 15:	Topical Corticosteroid Modified Superficial Dermatophytosis: Morphological Patterns	47
CHAPTER 16:	Tinea Incognito and Topical Corticosteroid Abuse in Dermatology	52
CHAPTER 17:	Antifungal Drugs	64
CHAPTER 18:	Newer Drugs and Therapy of Fungal Infections	75

CHAPTER 19: Deep Fungal Infection 83

CHAPTER 20: Mucormycosis 87

CHAPTER 21: Recalcitrant Fungal Infection 91

CHAPTER 22: Reasons for Resistance of Fungal Infection 95

CHAPTER 23: Side Effect of Topical Corticosteroid 97

CHAPTER 24: Mixo Combination Topical Therapy in Superficial Fungal Infections 100

CHAPTER 25: Tips to Prevent Recurrence of Tinea Infection 104

CHAPTER 26: Superficial Fungal Infection and Its Effect on Quality of Life 107

CHAPTER 27: Dermatophytid 108

Color Atlas 110

Suggested Readings 121

Index 123

CHAPTER 5

Pityriasis Versicolor (Tinea Versicolor, Dermatomycosis, Furfuracea, Chromophytosis)

ETIOLOGY

Pityriasis versicolor is caused by the fungus, *Pilymsporuni orbiculare, Plasmodium ovale.* There are at least seven species of lipophilic yeast—*Malassezia* on the human skin: *Malassezia sympodialis* (most commonly found on the normal skin) and A. *gloltosa* (most frequently associated with tinea versicolor),

Malassezia restricta, A7. *demuilis, M. sloojjiac,* A. *ohlitsa,* and *M. furfuracea.* Pityriasis versicolor affects young adults. Lypopiginenled macules and patches covered with fine, powdery scales, that are accentuated with stroking, typify this condition. Upper trunk, neck, and axillae are usually involved. KOH mount demonstrates fungal spores and hyphae. Once-daily topical use of 1% clotrimazole or 2% selenium sulfide for 2 weeks is curative. Oral ketoconazole or fluconazole is also useful.

PIGMENTARY CHANGES IN PITYRIASIS VERSICOLOR

The fungi secrete dicarboxylic acids, such as azelaic acid, which inhibit tyrosinase and damage the melanocytes to induce hypopigmentation. Although the melanosomes are reduced in size and number, their number remains unchanged and the transfer of melanosomes to keratinocytes becomes defective. Secretion of tryptophan derivatives by the fungus interfering with the 3-4-dihydroxphenylalanine (DOPA) reactions and a "pseudoleukoderma" because of the screening effect of pityriasisitrine and pityrialactone has also been proposed.

DIFFERENTIAL DIAGNOSIS OF PITYRIASIS VERSICOLOR

The differential diagnoses of pityriasis versicolor include other common entities associated with cutaneous pigmentation/depigmentation. They should be differentiated from vitiligo, pityriasis alba, pityriasis rosea, tinea

JAYPEE BROTHERS

corporis, secondary syphilis, psoriasis, pinta leprosy (Hansen's disease), chloasma, nevus anemicus, postinflammatory hypopigmentation, and post-kala-azar dermal leishmaniasis (PKDL).

WOOD'S LAMP EXAMINATION

Woods lamp examination is last two diseases, as erythrasma fluoresce coral-red whereas tinea corporis does not fluoresce at all. The scaly lesions of pityriasis versicolor show reddish or yellowish green fluorescence. Moreover, pityriasis versicolor may present as circular dermatosis, thereby mimicking pityriasis rotunda. The tuberous sclerosis shows hypopigmented macules, which are also known as "as-leaf-spots".

OTHER CONDITIONS ASSOCIATED WITH AND CAUSED BY TINEA VERSICOLOR SEBORRHEIC DERMATITIS

In recent times, Gupta et al. found that the predominant species in patients with seborrheic dermatitis patients was *Malassezia globosa*, as opposed to *Malassezia sympodialis* in normal skin. It has been observed that both *M. globosa* and *M. restricta* are present on diseased skin, while *M. globosa* is predominantly found in the control group. *M. sympodialis* was detected in both individuals with seborrheic dermatitis and in the control group. Therefore this disease is mainly caused by *M. restricta*, *M. furfur*, *M. globosa*, *M. sympodialis*, and *Malassezia slooffiae*. It should be borne in mind that the relative prevalence of these lipophilic species appears to vary with geographical region and the method used for diagnosis i.e., conventional culture versus molecular. These studies strongly support the concept that *Malasseiza yeastis* contribute to the pathogenesis of seborrheic dermatitis. In a recent Indian study, a novel species, *Malasseiza arunalokei*, has been isolated from both individuals with seborrheic dermatitis and from those who are healthy.

Atopic Eczema Dermatitis

The yeasts of *Malassezia* species have also been implicated as an aggravating factor in atopic eczema or dermatitis. They have been found to act as allergens rather than infectious agents **(Flowchart 1)**.

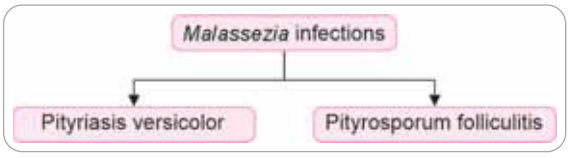

FLOWCHART 1: *Malassezia* infections.

JAYPEE BROTHERS

Follicultis

Folliculitis which is caused by *Malassezia* species is a chronic inflammatory skin disorder, usually characterized by florid, acneiform pruritic eruptions that rarely clear spontaneously.

DRUGS USED IN THE TREATMENT OF PITYRIASIS VERSICOLOR

Specific Therapy

- Oral and local ketoconazole
- Ketoconazole lotion, cream, soap and powder
- Luliconazole lotion
- Fluconazole itraconazole, etc.



These drugs are topical, and oral solution and ceremide shampoos may be used. Important drugs are ketoconazole, econazole nitrate, and sertaconazole.

Latest drugs such as Ciclopirox lotion show a positive result of 62–70%. The sales old drug is also used with good drugs.

Antifungal therapy for pityriasis versicolor

1. *Nonspecific topical antifungal therapy*:
   a. Selenium sulfide 2.5% suspension
   b. 50% propylene glycol in water
   c. Zinc pyrithione

DIAGNOSIS

Diagnosis of pityriasis versicolor is based on:

- Hypopigmented perifollicular macules which become continent. Lesions appear to be sitting on the skin.
- Upper torso, neck candidal stomatitis (oral thrush, candidal glossitis)

DIFFERENTIAL DIAGNOSIS

Pityriasis versicolor should be differentiated from the following:

Vitiligo: The lesions of vitiligo are well-defined depigmented macules with no scaling, while those of pityriasis versicolor are hypopigmented (sometimes

JAYPEE BROTHERS

hyperpigmented) with branny scales. The lesions of pityriasis versicolor are perifollicular; in vitiligo, hair may also be depigmented (leukotrichia) and on treatment perifollicular areas repigment first.

Leprosy: The hypopigmented lesions of leprosy show epidermal atrophy and sensory deficit and lack of the perifollicular character and the branny scaling of pityriasis versicolor.

INVESTIGATIONS

Potassium hydroxide mount is prepared from scrapping of the skin. It shows a mixture of short, branched hyphae and spores (spaghetti and meat ball appearance). Culture is of little help.

COURSE AND PROGNOSIS

The prognosis is good, with complete mycological cure after 3–4 weeks of treatment. Without therapy, pityriasis versicolor becomes a chronic disease and reoccurrence post-treatment is 60% after 2 years and 80% after 2 years.

Clinical photographs of tinea versicolor and pityriasis versicolor are shown in **Figures 1 to 7**.

Clinical photographs of tinea versicolor on arms are shown in **Figures 8A to C**.



FIG. 1: Pityriasis versicolor: Multiple scaly macules on the arm.

JAYPEE BROTHERS



FIG. 2: Pityriasis versicolor: Multiple scaly macules on the neck.

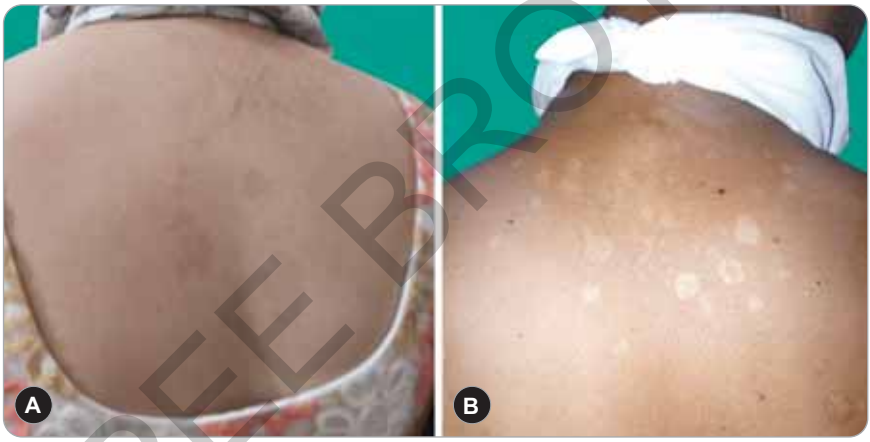

FIGS. 3A AND B: Pityriasis versicolor: Multiple scaly macules on the back.



FIGS. 4A AND B: Pityriasis versicolor: Multiple scaly macules on the chest.

JAYPEE BROTHERS



FIG. 5: Pityriasis versicolor: Multiple scaly macules on the face.



FIG. 6: Tinea versicolor: Hypopigmented macules with fine powdery scales.



FIG. 7: Tinea versicolor: Hypopigmented macules with fine powdery scales.

JAYPEE BROTHERS



FIGS. 8A TO C: Tinea versicolor on arms.

JAYPEE BROTHERS

for detailed information on dermatology books, visit our website www.jaypeebrothers.com, for detailed information on dermatology

Fungal Infections
with Color Atlas

The book is a concise, summarized, and succinct guide for practitioners and both medical and paramedical workers. An overview on epidemiology is given as well as pathology, clinical diagnosis, and recent updated treatment of fungal infections. The global panorama of fungal infections is discussed, including the Indian scenario. Both old and new recent advances have been thoroughly elaborated. It serves as a reckoner for family physicians, clinical dermatologists, paramedical workers like nurses, medical professionals, students, and interns. Simply put, it is an indispensable comprehensive book on all types of mycosis disease.

SK Punshi MBBS DDV FIMS FDS is a Senior Consultant Dermatologist at Rajkamal Chowk, Amravati, Maharashtra, India. He is a clinical research worker in vitiligo. His work on vitiligo has been mentioned in many books and journals. He has authored several books—"Vitiligo Diagnosis and Treatment" by Kothari Book Depot in 1971, "Vitiligo and Placental Extract", "Vitiligo Quarterly Medical Reviews" by Raptakos Brett & Co. LTD, Mumbai, in 1979, "Recent Advances in Vitiligo", "Handbook of Leprosy", "Handbook of Scabies", and "Dermatology for General Practitioners". He has contributed many chapters—Placental Extract Therapy in Vitiligo [In: Iyengar B, Singh A (Eds), Growth Disorders of Pigment. Churchill Livingstone in 1996] and Incidence of Vitiligo [In: Ortanne JP, Mosher DB, Fitzpatrick T (Eds), Vitiligo and Other Hypomelanosis of Hair and Skin. New York: Plenum]. He has also written "A Handbook of Vitiligo & Color Atlas", a unique book in the world, which has gone into its 3rd edition, and "Current Diagnosis and Management of Dermatologic Disorders Made Easy", which has gone for its 2nd edition. It is a handbook referred to by students, interns, and professionals alike, widely read in the medical field. This recent book "Fungal Infections with Color Atlas" is the latest in the series, which is very useful for practicing physicians and dermatologists. Dr SK Punshi was the former president of Indian Medical Association, Amravati Branch; Joint Secretary of Indian Medical Association, Maharashtra Branch; President of IADVL, Maharashtra State; Vice President of IADVL at the national level; and Ex-president of Vidarbha Dermatological Society, Nagpur. He has been honored with prestigious awards and trophies—All India Award by Skin Institute and School of Dermatology, New Delhi, for his research thesis on placental extract; Ambady Oration Award in IADVL Conference, Jabalpur, on the subject "vitiligo yesterday, today and tomorrow" in 1986; and a prestigious social service by Lions Clubs International for his contribution toward leprosy eradication. He writes numerous articles in literary journals and is the author of many literary works, one of which is titled "Divine Knowledge: A Scientific Approach to the Study of Bhagavad Gita." He is a true *Gita* man, "thou have the right to work, not the fruits there off..."

Printed in India

Available at all medical bookstores
or buy online at www.jaypeebrothers.com



JAYPEE BROTHERS
Medical Publishers (P) Ltd.
EMCA House, 23/23-B, Ansari Road,
Daryaganj, New Delhi - 110 002, INDIA
www.jaypeebrothers.com

Join us on facebook.com/JaypeeMedicalPublishers

Shelving Recommendation
DERMATOLOGY

